A 23-year-old woman is brought to the emergency department with a chest wound. She was in her house during a severe thunderstorm when a large tree branch fell through a window. The window was shattered and large fragments of wood and glass struck the patient. She did not lose consciousness, but her family found her bleeding profusely and rushed her to the hospital. Blood pressure is 80/50 mm Hg and pulse is 130/min. The patient appears to be in severe distress. Physical examination shows a deep penetrating wound in the fourth intercostal space along the left sternal border. Smaller lacerations are noted across the face and forearms. Which of the following structures is most likely injured in this patient?

A. Inferior vena cava

B. Left atrium

C. Left ventricle

D. Pulmonary trunk

E. Right ventricle

Submit

A 23-year-old woman is brought to the emergency department with a chest wound. She was in her house during a severe thunderstorm when a large tree branch fell through a window. The window was shattered and large fragments of wood and glass struck the patient. She did not lose consciousness, but her family found her bleeding profusely and rushed her to the hospital. Blood pressure is 80/50 mm Hg and pulse is 130/min. The patient appears to be in severe distress. Physical examination shows a deep penetrating wound in the fourth intercostal space along the left sternal border. Smaller lacerations are noted across the face and forearms. Which of the following structures is most likely injured in this patient?

- A. Inferior vena cava (1%)
- B. Left atrium (6%)
- C. Left ventricle (20%)
- D. Pulmonary trunk (6%)
- ✓ E. Right ventricle (65%)

Omitted
Correct answer
E

65%
Answered correctly

03 secs
Time Spent

06/13/2020
Last Updated

Explanation

Left parasternal impalement wound

Left parasternal impalement wound

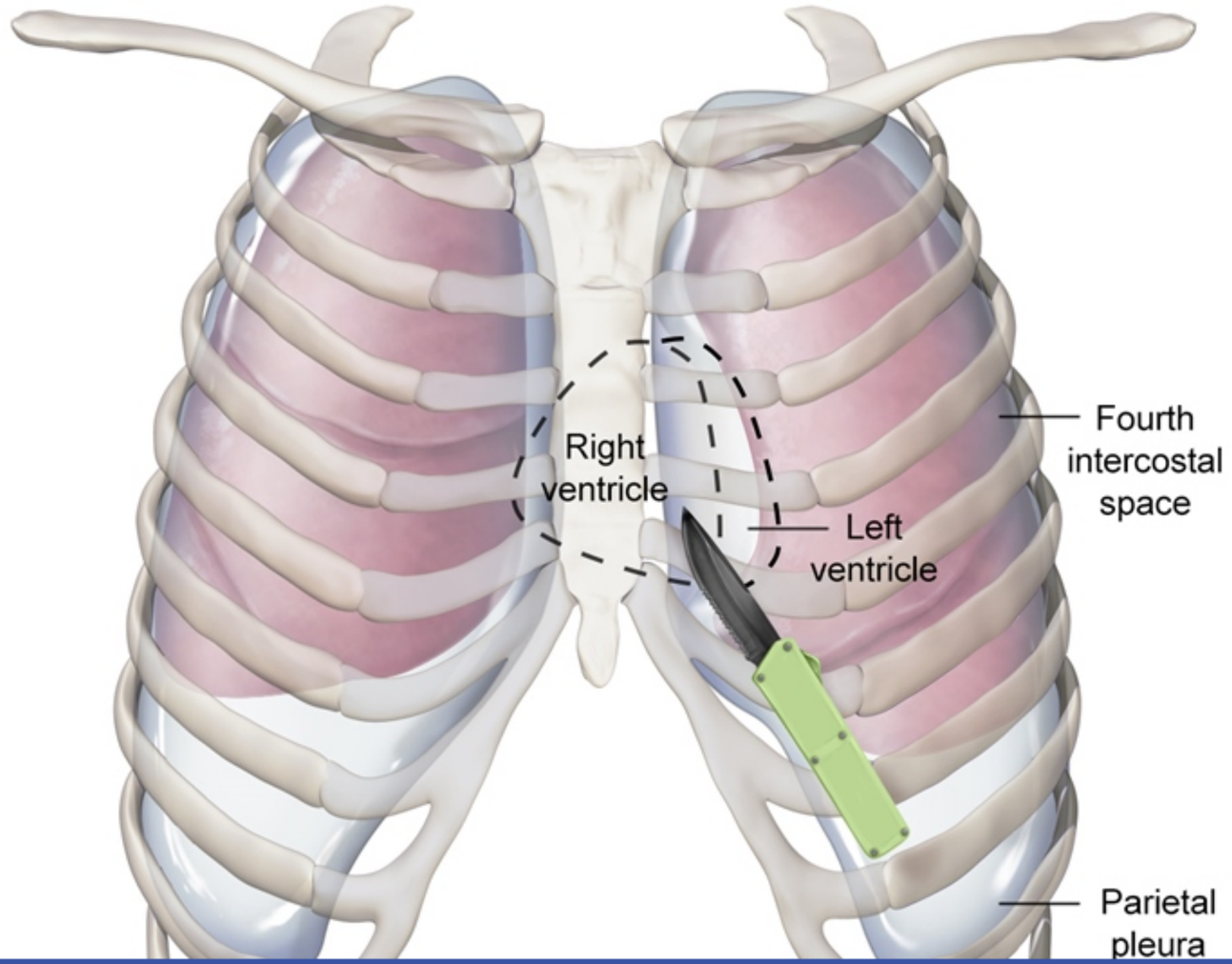

A penetrating injury at the left sternal border in the fourth intercostal space (level of the nipple) will pass through the following layers (in order):

1. Skin and subcutis
2. Pectoralis major muscle
3. External intercostal membrane
4. Internal intercostal muscle
5. Internal thoracic artery and veins
6. Transversus thoracis muscle
7. Parietal pleura
8. Pericardium
9. Right ventricular myocardium

The **right ventricle** composes the majority of the **anterior surface of the heart** and is at risk of injury with penetrating trauma at the mid- and lower-left sternal border. The parietal pleura would be injured as well, but the left lung itself would not be punctured as there is no middle lobe on the left side, and the superior lobe of the left lung is displaced laterally by the cardiac impression.

(Choice A) The inferior vena cava (IVC) passes through the right side of the central tendon of the diaphragm at the level of T8. A penetrating wound to the back at the immediate right of the vertebral bodies could strike the IVC.

(Choice B) The left atrium is located at the base of the heart (posterior surface, opposite the apex) and makes up most of the heart's posterior surface. Only the auricle of the left atrium is visible anteriorly (protruding between the pulmonary trunk and the left ventricle).

(Choice C) The left ventricle composes the left lateral aspect of the heart. A stab wound angled slightly medially in the fourth intercostal space at the midclavicular line could strike the left ventricle, but only after passing through the bulk of the left lung.

(Choice D) The pulmonary trunk could be pierced by a penetrating injury to the second intercostal space at the left sternal border.

Educational objective:
The right ventricle composes most of the heart's anterior surface. A deep, penetrating injury at the left sternal border in the fourth intercostal space would puncture the right ventricle.

5. Internal thoracic artery and veins
6. Transversus thoracis muscle
7. Parietal pleura
8. Pericardium
9. Right ventricular myocardium

The **right ventricle** composes the majority of the **anterior surface of the heart** and is at risk of injury with penetrating trauma at the mid- and lower-left sternal border. The parietal pleura would be injured as well, but the left lung itself would not be punctured as there is no middle lobe on the left side, and the superior lobe of the left lung is displaced laterally by the cardiac impression.

(Choice A) The inferior vena cava (IVC) passes through the right side of the central tendon of the diaphragm at the level of T8. A penetrating wound to the back at the immediate right of the vertebral bodies could strike the IVC.

(Choice B) The left atrium is located at the base of the heart (posterior surface, opposite the apex) and makes up most of the heart's posterior surface. Only the auricle of the left atrium is visible anteriorly (protruding between the pulmonary trunk and the left ventricle).

(Choice C) The left ventricle composes the left lateral aspect of the heart. A stab wound angled slightly medially in the fourth intercostal space at the midclavicular line could strike the left ventricle, but only after passing through the bulk of the left lung.

(Choice D) The pulmonary trunk could be pierced by a penetrating injury to the second intercostal space at the left sternal border.

Educational objective:
The right ventricle composes most of the heart's anterior surface. A deep, penetrating injury at the left sternal border in the fourth intercostal space would puncture the right ventricle.

Anatomy	Cardiovascular System	Penetrating thoracic trauma
Subject	System	Topic

Copyright © UWorld. All rights reserved.

A 54-year-old man comes to the office due to episodic burning substernal chest pain. His pain increases with activity and improves with rest. The patient has a history of hypertension and hyperlipidemia. He has smoked a pack of cigarettes daily for the past 30 years. His blood pressure is 140/85 mm Hg and pulse is 76/min. Cardiac auscultation reveals a S4 heart sound. Lung and abdominal examinations are unremarkable. An ECG at rest shows left ventricular hypertrophy. A myocardial perfusion scan reveals inducible ischemia of the inferior surface of the heart. Which of the following coronary arteries is most likely occluded in this patient?

A. Left anterior descending coronary artery
B. Left circumflex coronary artery
C. Left main coronary artery
D. Right coronary artery
E. Right marginal branch

Submit

A 54-year-old man comes to the office due to episodic burning substernal chest pain. His pain increases with activity and improves with rest. The patient has a history of hypertension and hyperlipidemia. He has smoked a pack of cigarettes daily for the past 30 years. His blood pressure is 140/85 mm Hg and pulse is 76/min. Cardiac auscultation reveals a S4 heart sound. Lung and abdominal examinations are unremarkable. An ECG at rest shows left ventricular hypertrophy. A myocardial perfusion scan reveals inducible ischemia of the inferior surface of the heart. Which of the following coronary arteries is most likely occluded in this patient?

- A. Left anterior descending coronary artery (25%)
- B. Left circumflex coronary artery (8%)
- C. Left main coronary artery (1%)
- ✓ D. Right coronary artery (52%)
- E. Right marginal branch (11%)

Omitted
Correct answer
D

52%
Answered correctly

02 secs
Time Spent

03/25/2020
Last Updated

Explanation

Coronary arteries: anterior view

Sinoatrial (SA)
nodal branch

Coronary arteries: anterior view

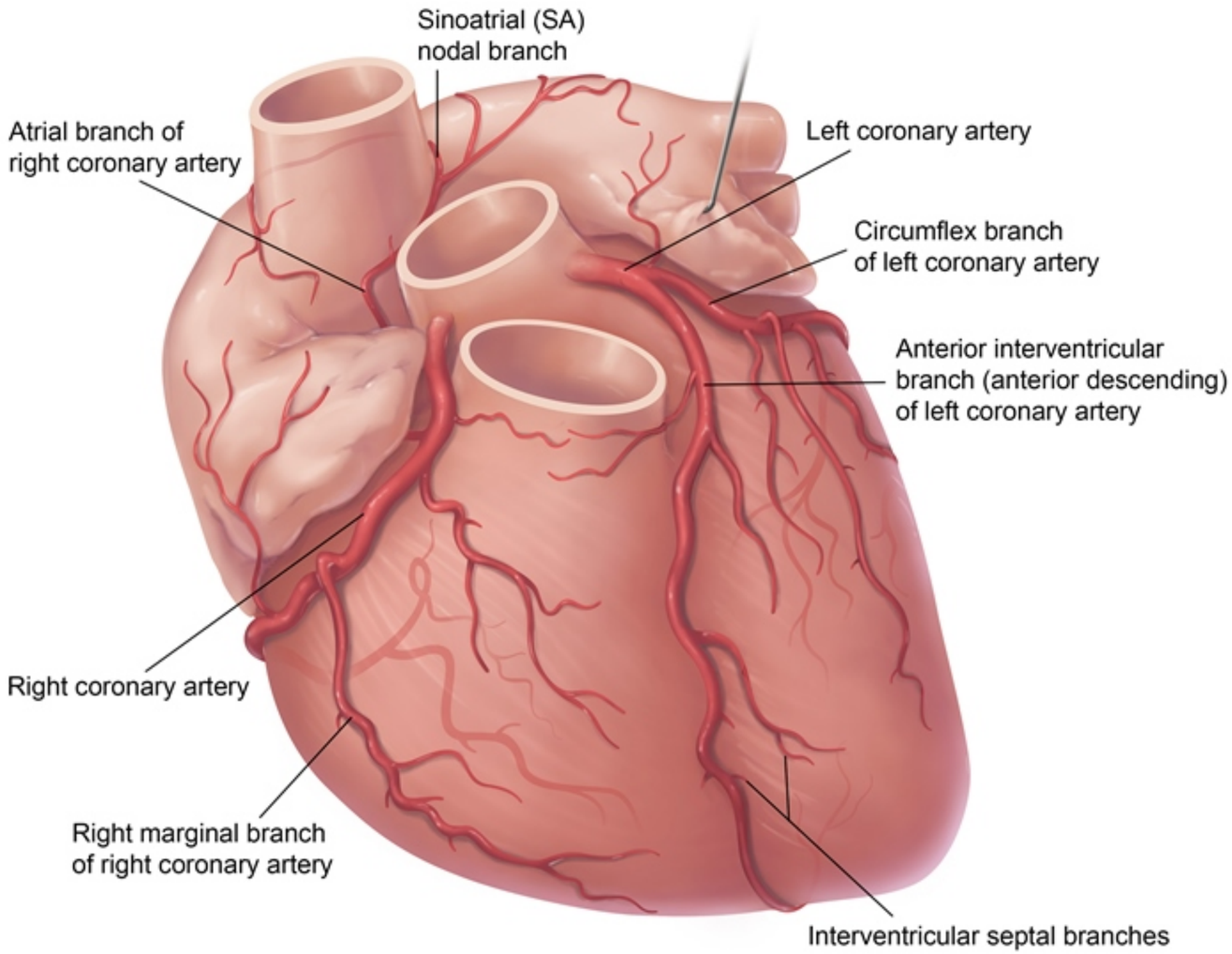

©UWorld

Click here for posterior view

The right and left main coronary arteries arise directly from the root of the aorta and provide the blood supply to the heart. The left main coronary artery divides into the left anterior descending (LAD) and circumflex coronary arteries, which supply most of the anterior and left lateral surfaces of the heart.

In 85%-90% of individuals, the **right coronary artery** gives rise to the **posterior descending artery**. Such patients are said to have **right dominant** coronary circulation. The posterior descending artery runs down the posterior interventricular groove and supplies the posterior one third of the interventricular septum and most of the inferior wall of the left ventricle.

The **inferior (diaphragmatic) surface** of the heart is formed by the left ventricle (two thirds) and right ventricle (one third), which are separated by the posterior interventricular groove. Because most individuals have right dominant circulation, occlusion of the right coronary artery is most likely to cause inducible ischemia of the inferior surface of the heart.

(Choice A) The LAD artery normally supplies the anterior two thirds of the interventricular septum (septal branches), the anterior wall of the left ventricle (diagonal branches), and part of the anterior papillary muscle.

(Choice B) The left circumflex coronary artery usually supplies the lateral and posterior superior walls of the left ventricle via obtuse marginal branches.

(Choice C) In approximately 10% of individuals, the posterior descending artery derives from the circumflex branch of the left main coronary artery (left dominant circulation); therefore, the left main coronary artery is not the artery most likely occluded in this patient.

(Choice E) The right marginal branch of the right coronary artery supplies the wall of the right ventricle and may provide collateral circulation in patients with LAD occlusion.

Educational objective:
The inferior wall of the left ventricle forms most of the inferior (diaphragmatic) surface of the heart and is supplied by the posterior descending artery. In 85%-90% of individuals, the posterior descending artery derives from the right coronary artery (right dominant coronary circulation).

References

dominant coronary circulation. The posterior descending artery runs down the posterior interventricular groove and supplies the posterior one third of the interventricular septum and most of the inferior wall of the left ventricle.

The **inferior (diaphragmatic) surface** of the heart is formed by the left ventricle (two thirds) and right ventricle (one third), which are separated by the posterior interventricular groove. Because most individuals have right dominant circulation, occlusion of the right coronary artery is most likely to cause inducible ischemia of the inferior surface of the heart.

(Choice A) The LAD artery normally supplies the anterior two thirds of the interventricular septum (septal branches), the anterior wall of the left ventricle (diagonal branches), and part of the anterior papillary muscle.

(Choice B) The left circumflex coronary artery usually supplies the lateral and posterior superior walls of the left ventricle via obtuse marginal branches.

(Choice C) In approximately 10% of individuals, the posterior descending artery derives from the circumflex branch of the left main coronary artery (left dominant circulation); therefore, the left main coronary artery is not the artery most likely occluded in this patient.

(Choice E) The right marginal branch of the right coronary artery supplies the wall of the right ventricle and may provide collateral circulation in patients with LAD occlusion.

Educational objective:
The inferior wall of the left ventricle forms most of the inferior (diaphragmatic) surface of the heart and is supplied by the posterior descending artery. In 85%-90% of individuals, the posterior descending artery derives from the right coronary artery (right dominant coronary circulation).

References

- Anatomy, histology, and pathology of coronary arteries: A review relevant to new interventional and imaging techniques--Part I.

Anatomy	Cardiovascular System	Coronary blood flow
Subject	System	Topic

Copyright © UWorld. All rights reserved.

Exhibit Display

Right dominant circulation: posterior view

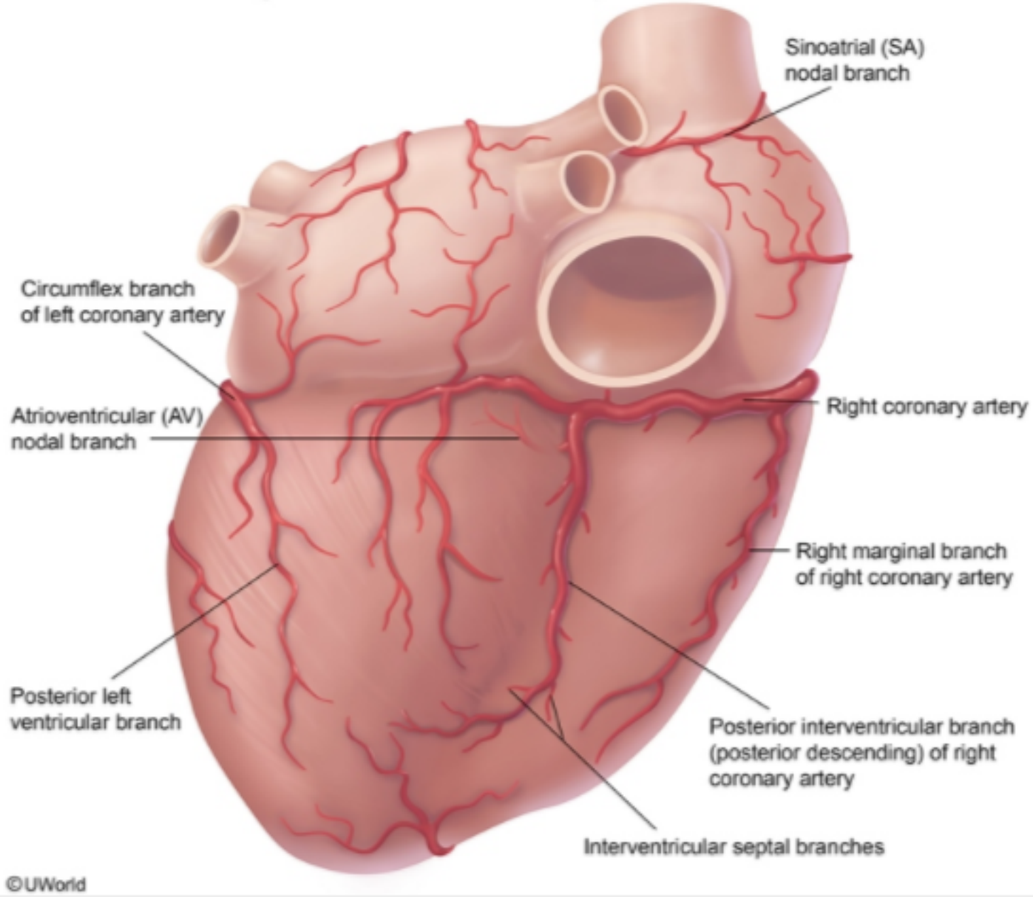

Zoom In | Zoom Out | Reset | Add To New Card | Existing Card

A 52-year-old man comes to the office due to a chronic cough for the last 3 weeks. The patient says, "I haven't been coughing up phlegm, but sometimes I notice some blood on the tissue when I cough particularly hard." He has smoked 2 packs of cigarettes daily for the past 30 years and drinks 3 or 4 cans of beer on weekends. He works as a welder on an assembly line and says his father died of lung cancer at age 70. Physical examination shows right-sided face and arm swelling and engorgement of subcutaneous veins on the same side of the neck. Which of the following veins is most likely obstructed in this patient?

- A. Axillary
- B. Brachiocephalic
- C. External jugular
- D. Internal jugular
- E. Subclavian
- F. Superior vena cava

Submit

A 52-year-old man comes to the office due to a chronic cough for the last 3 weeks. The patient says, "I haven't been coughing up phlegm, but sometimes I notice some blood on the tissue when I cough particularly hard." He has smoked 2 packs of cigarettes daily for the past 30 years and drinks 3 or 4 cans of beer on weekends. He works as a welder on an assembly line and says his father died of lung cancer at age 70. Physical examination shows right-sided face and arm swelling and engorgement of subcutaneous veins on the same side of the neck. Which of the following veins is most likely obstructed in this patient?

- A. Axillary (0%)
- ✓ B. Brachiocephalic (34%)
- C. External jugular (5%)
- D. Internal jugular (3%)
- E. Subclavian (21%)
- F. Superior vena cava (35%)

Omitted
Correct answer
B

34%
Answered correctly

02 secs
Time Spent

04/28/2020
Last Updated

Explanation

Right-sided brachiocephalic vein obstruction

1
2
3
4
5
6
7
8
9
10
11
12
13
14
15
16
17
18
19
20
21
22
23
24
25
26
27
28
29

Explanation

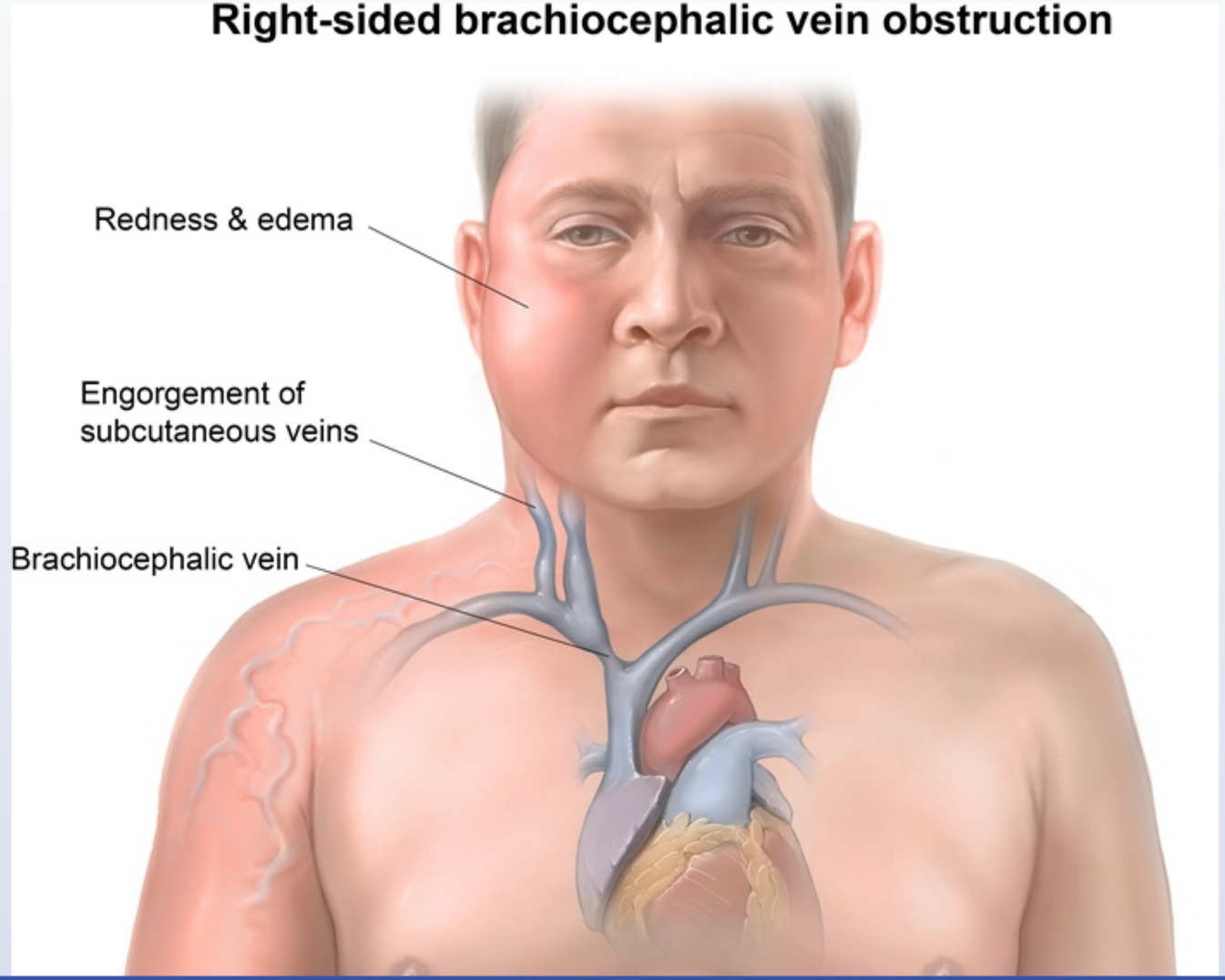

1
2
3
4
5
6
7
8
9
10
11
12
13
14
15
16
17
18
19
20
21
22
23
24
25
26
27
28
29

Exhibit Display

Right-sided brachiocephalic vein obstruction

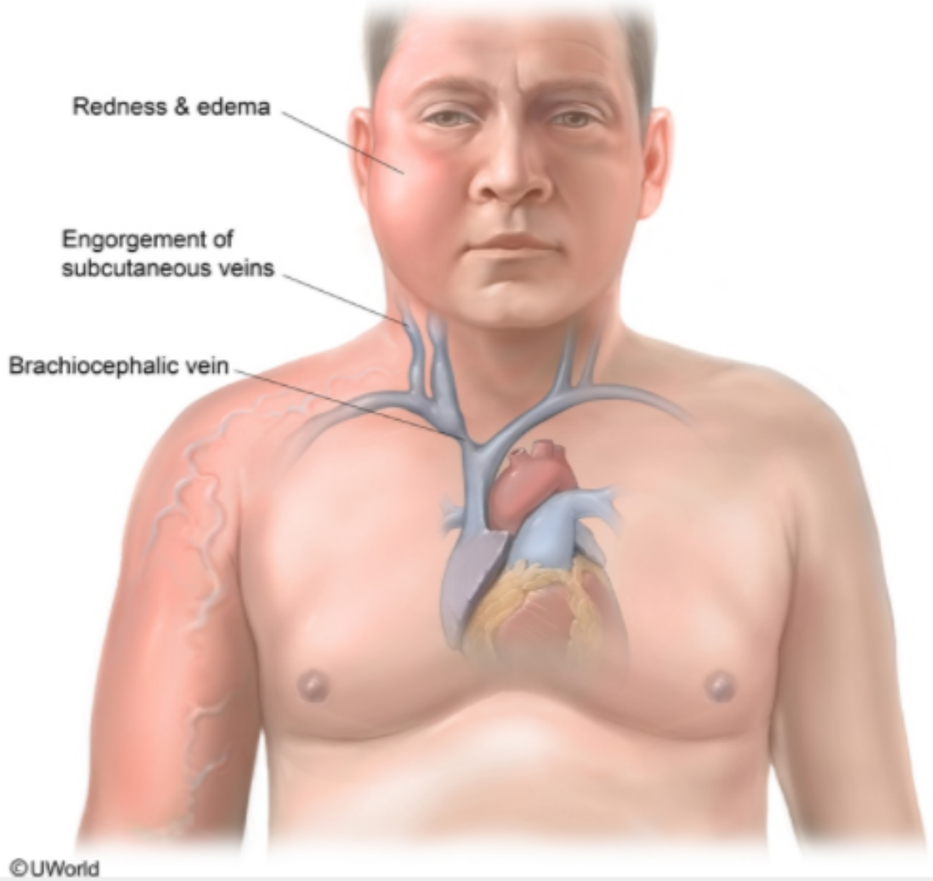

Zoom In | Zoom Out | Reset | Add To New Card | Existing Card

This patient has symptoms consistent with an **obstructed right brachiocephalic (innominate) vein**. This may be the result of external compression by an apical lung tumor or thrombotic occlusion as can occur when a central catheter has been in place for an extended period. The right brachiocephalic vein is formed by the union of the right subclavian vein and the right internal jugular vein. The right external jugular vein drains into the right subclavian vein, so obstruction of the right brachiocephalic vein will also cause venous congestion of structures drained by the external jugular vein. It is important to note that the right brachiocephalic vein also drains the right lymphatic duct, which drains lymph from the right upper extremity, the right face and neck, the right hemithorax, and the right upper quadrant of the abdomen.

(Choices A and E) The subclavian vein is the continuation of the axillary vein. Both drain blood from the upper extremity. Blockage at any of these 2 sites would cause unilateral arm swelling without associated facial swelling.

(Choices C and D) The external jugular vein drains the scalp and portions of the lateral face. The internal jugular vein drains the brain and superficial face and neck. Obstruction of the internal jugular veins would not cause arm swelling.

(Choice F) Superior vena cava (SVC) syndrome results when the superior vena cava is obstructed. The signs and symptoms of SVC syndrome are similar to those of obstructed right brachiocephalic (innominate) vein, except that both sides of the face, neck, and chest and both arms would be involved.

Educational objective:
The brachiocephalic vein drains the ipsilateral jugular and subclavian veins. The bilateral brachiocephalic veins combine to form the superior vena cava (SVC). Brachiocephalic vein obstruction causes symptoms similar to those seen in SVC syndrome, but only on one side of the body.

Anatomy	Cardiovascular System	Superior vena cava syndrome
Subject	System	Topic

Copyright © UWorld. All rights reserved.

A 62-year-old man comes to the emergency department due to fever, productive cough, and dyspnea for the past several days. His symptoms are becoming progressively worse. The patient has underlying mild chronic obstructive pulmonary disease and has smoked a pack of cigarettes daily for the last 40 years. On examination, temperature is 38.3 C (100.9 F), pulse is 110/min, and respirations are 24/min. Auscultation of the right lung reveals bronchial breath sounds and crackles. Laboratory evaluation shows leukocytosis. Chest x-ray is shown below.

The mediastinal contour obscured by the lung consolidation on this patient's chest x-ray is primarily formed by which of the following structures?

A. Coronary sinus
B. Inferior vena cava
C. Pulmonary artery
D. Right atrium
E. Right ventricle
F. Superior vena cava

Submit

1
2
3
4
5
6
7
8
9
10
11
12
13
14
15
16
17
18
19
20
21
22
23
24
25
26
27
28
29

A 62-year-old man comes to the emergency department due to fever, productive cough, and dyspnea for the past several days. His symptoms are becoming progressively worse. The patient has underlying mild chronic obstructive pulmonary disease and has smoked a pack of cigarettes daily for the last 40 years. On examination, temperature is 38.3 C (100.9 F), pulse is 110/min, and respirations are 24/min. Auscultation of the right lung reveals bronchial breath sounds and crackles. Laboratory evaluation shows leukocytosis. Chest x-ray is shown below.

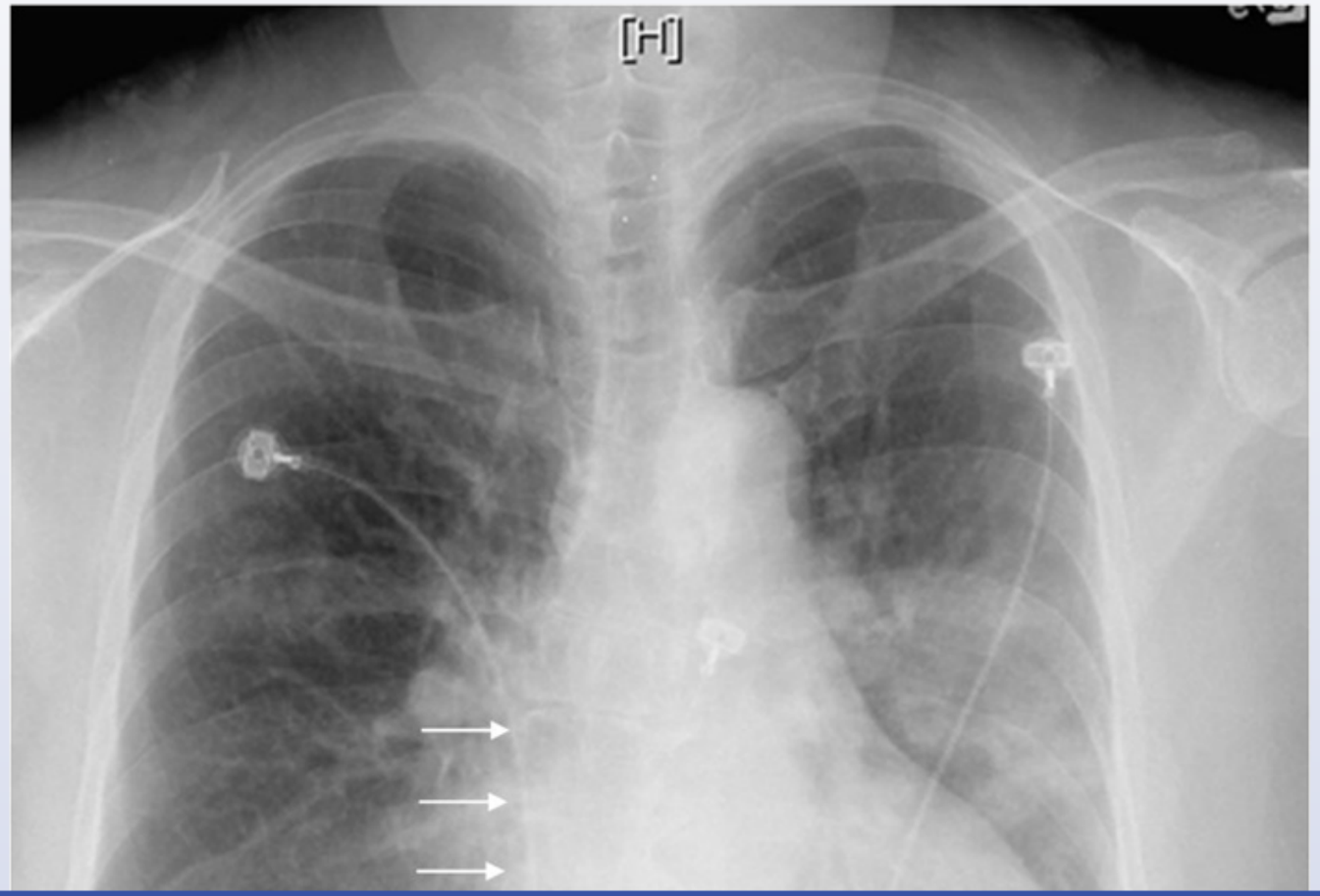

1
2
3
4
5
6
7
8
9
10
11
12
13
14
15
16
17
18
19
20
21
22
23
24
25
26
27
28
29

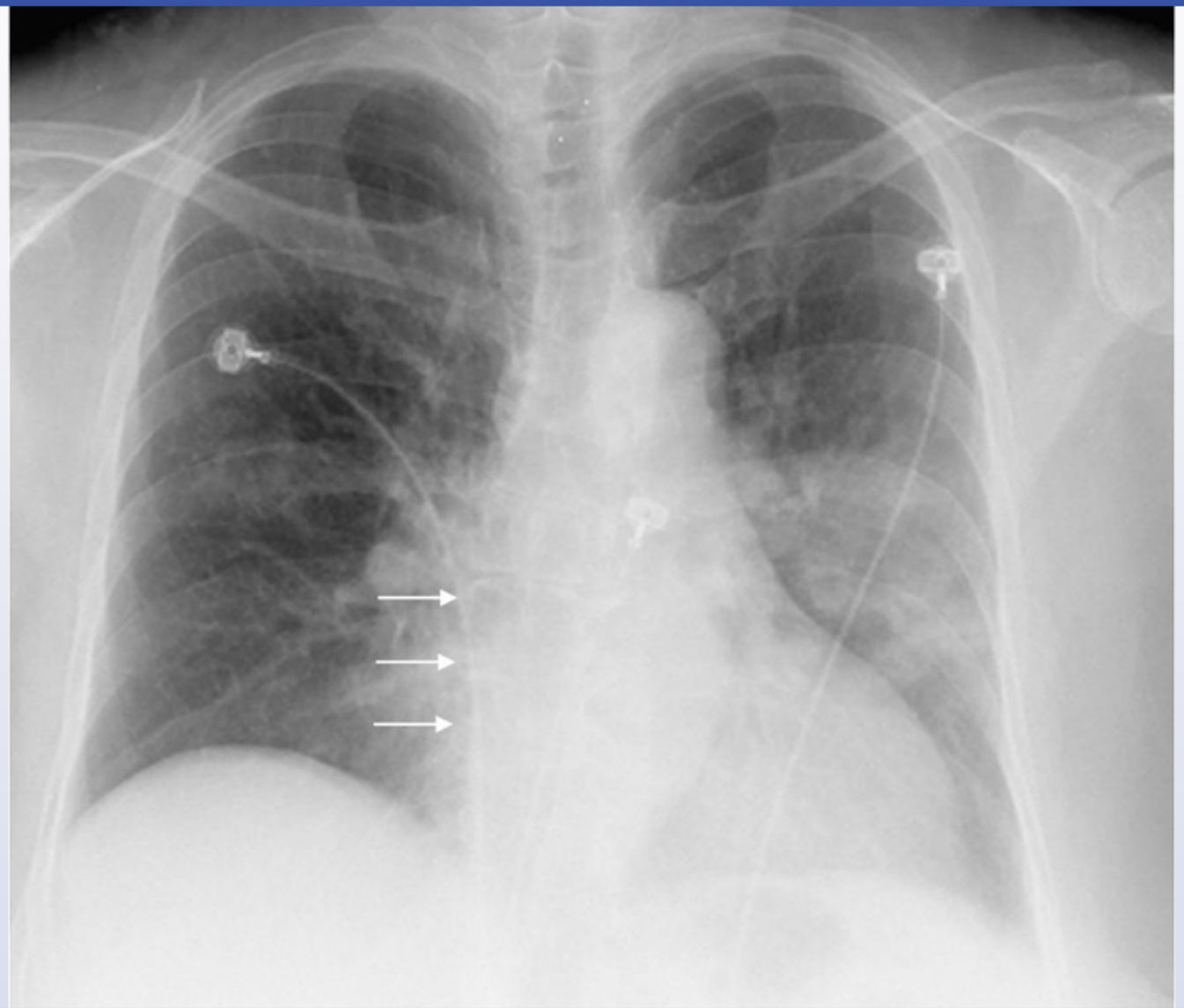

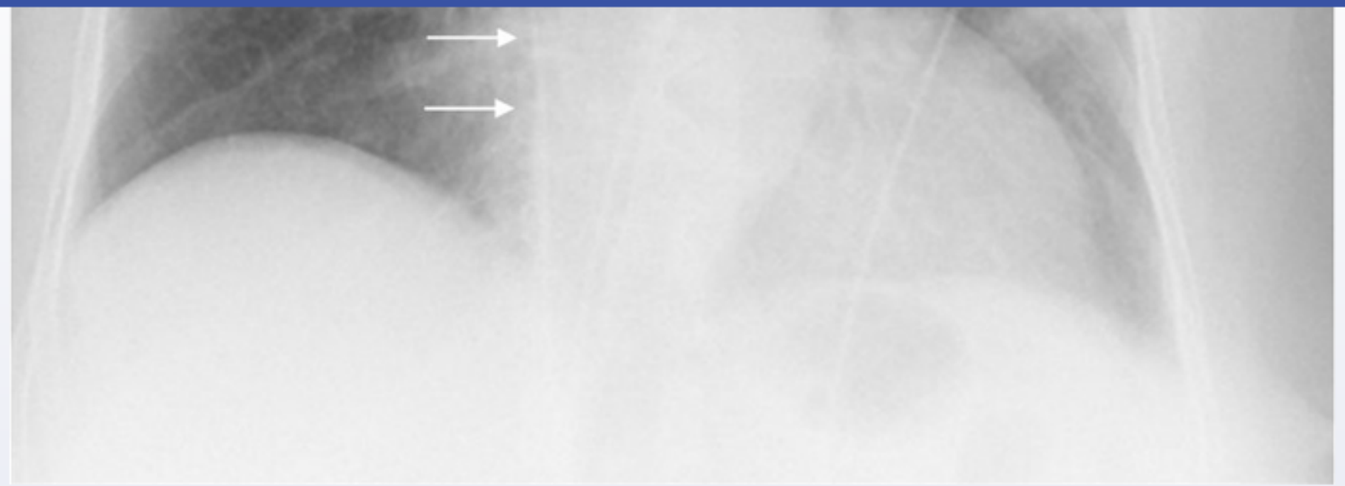

The mediastinal contour obscured by the lung consolidation on this patient's chest x-ray is primarily formed by which of the following structures?

- A. Coronary sinus
- B. Inferior vena cava
- C. Pulmonary artery
- D. Right atrium
- E. Right ventricle
- F. Superior vena cava

Submit

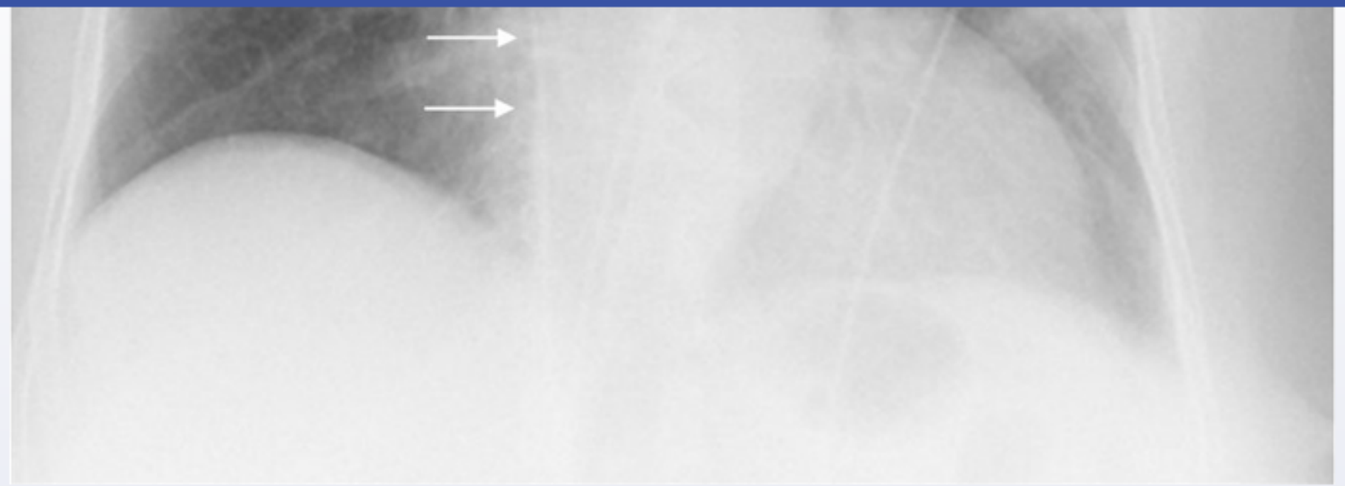

The mediastinal contour obscured by the lung consolidation on this patient's chest x-ray is primarily formed by which of the following structures?

A. Coronary sinus (0%)
B. Inferior vena cava (16%)
C. Pulmonary artery (4%)
✓ D. Right atrium (56%)
E. Right ventricle (16%)
F. Superior vena cava (5%)

Omitted
Correct answer

56%
Answered correctly

09 secs
Time Spent

05/30/2020
Last Updated

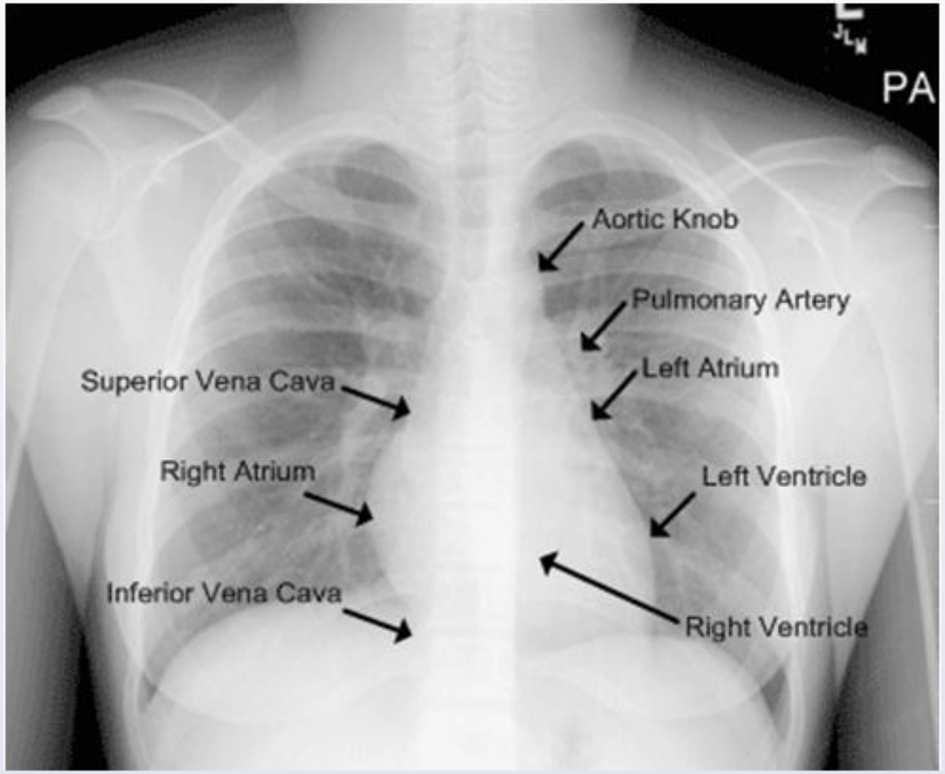

This patient has acute **lobar pneumonia** with consolidation involving the right middle lobe. The **right middle lobe** of the lung lies immediately adjacent to the **right border of the heart**, and any condition that increases radiographic density in the right middle lobe will obscure the adjacent cardiac silhouette. On posteroanterior (PA) chest x-ray projections, the **right atrium** composes most of the right side of the cardiac silhouette.

(Choice A) The coronary sinus receives most of the venous drainage from the cardiac circulation. It courses posteriorly around the heart in the coronary sulcus to empty directly into the right atrium. It is difficult to visualize on standard chest x-ray.

(Choice B) The inferior vena cava empties into the right atrium in the thorax. It composes only the most inferior edge of the right border of the

This patient has acute **lobar pneumonia** with consolidation involving the right middle lobe. The **right middle lobe** of the lung lies immediately adjacent to the **right border of the heart**, and any condition that increases radiographic density in the right middle lobe will obscure the adjacent cardiac silhouette. On posteroanterior (PA) chest x-ray projections, the **right atrium** composes most of the right side of the cardiac silhouette.

(Choice A) The coronary sinus receives most of the venous drainage from the cardiac circulation. It courses posteriorly around the heart in the coronary sulcus to empty directly into the right atrium. It is difficult to visualize on standard chest x-ray.

(Choice B) The inferior vena cava empties into the right atrium in the thorax. It composes only the most inferior edge of the right border of the cardiac silhouette.

(Choice C) The pulmonary artery can be seen on PA chest x-ray on the left side of the cardiomediastinal silhouette just below the aortic arch.

(Choice E) The right ventricle forms the anterior wall of the heart and is best seen on lateral chest x-ray.

(Choice F) The superior vena cava is formed behind the first costal cartilage by the confluence of the right and left brachiocephalic veins. On PA chest x-ray, it is the flattened opacity parallel to the vertebral column that terminates inferiorly at the right atrium.

Educational objective:
On posteroanterior chest x-ray, the right middle lobe is seen adjacent to the right border of the heart, which is primarily formed by the right atrium. Consolidation in the right middle lobe can obscure the x-ray silhouette of the right heart border.

Anatomy	Cardiovascular System	Community acquired pneumonia
Subject	System	Topic

Copyright © UWorld. All rights reserved.

A 23-year-old previously healthy man is brought to the emergency department after a stab injury. His friends report that they were "walking down the street minding our own business when a guy jumped out in front of us from behind a dumpster and stabbed him in the chest." They were able to disarm the man after this single attack, and the man then ran off into an alley. The patient is conscious but in distress. Physical examination shows a laterally directed anterior chest wall stab wound at the fifth intercostal space along the left midclavicular line. Which of the following structures is most likely to have been injured in this patient?

A. Azygos vein

B. Inferior vena cava

C. Left atrium

D. Left lung

E. Right ventricle

Submit

A 23-year-old previously healthy man is brought to the emergency department after a stab injury. His friends report that they were "walking down the street minding our own business when a guy jumped out in front of us from behind a dumpster and stabbed him in the chest." They were able to disarm the man after this single attack, and the man then ran off into an alley. The patient is conscious but in distress. Physical examination shows a laterally directed anterior chest wall stab wound at the fifth intercostal space along the left midclavicular line. Which of the following structures is most likely to have been injured in this patient?

A. Azygos vein (1%)

B. Inferior vena cava (0%)

C. Left atrium (8%)

✓ D. Left lung (52%)

E. Right ventricle (36%)

Omitted
Correct answer
D

52%
Answered correctly

01 sec
Time Spent

04/02/2020
Last Updated

Explanation

Chest anatomy & stab wound

Chest anatomy & stab wound

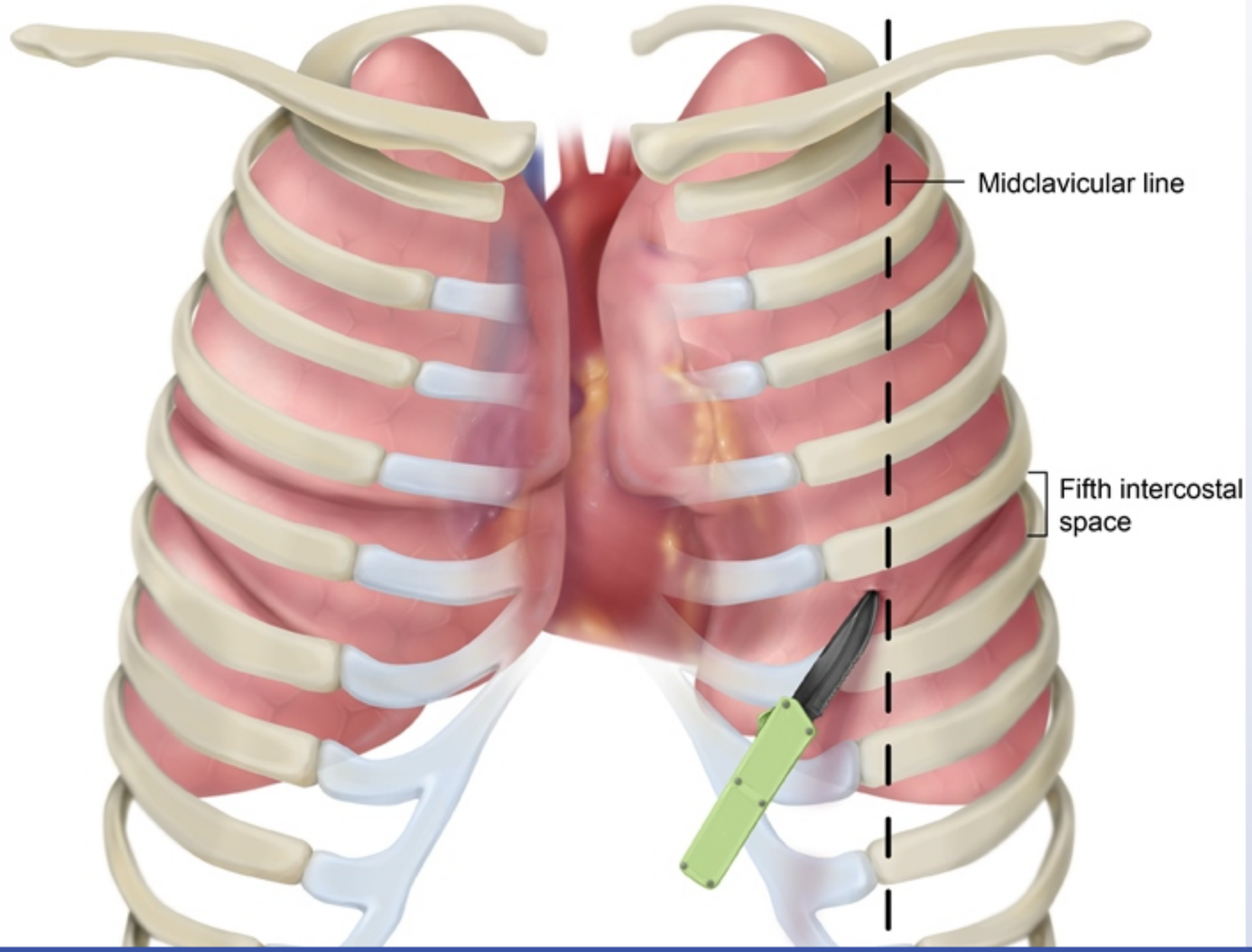

A penetrating, laterally directed stab wound (possibly from a left-handed assaulter) that involves the fifth intercostal space (ICS) at the left anterior midclavicular line (MCL) would most likely injure the **left lung**. The lungs occupy most of the volume of the thoracic cavity. The apex of each lung extends into the neck (3-4 cm above the first rib). The lung bases are in direct contact with the diaphragm, which separates the right lung from the right lobe of the liver and the left lung from the stomach, spleen, and (occasionally) left lobe of the liver. The mediastinal surface of each lung has a cardiac impression that accommodates the heart.

A deeper (and more medially directed) wound could have injured the left (not the right) ventricle. The heart is located behind the sternum, and its anterior surface is partially **covered** by the lungs. The cardiac apex is formed by the left ventricle. Depending on heart size, the point of **maximal** apical impulse can be felt at the fifth left ICS (between the fifth and sixth ribs) at the left MCL. All other heart chambers, including the right ventricle, lie **medial** to the left MCL and are unlikely to have been affected by the injury. The right ventricle forms the sternocostal (anterior) surface of the heart **(Choice E)**. The diaphragmatic (inferior) surface is formed by the left and right ventricles and is in contact with the central tendon of the diaphragm. The posterior surface of the heart is formed mainly by the left atrium **(Choice C)**.

(Choice A) The azygos vein lies in the posterior mediastinum immediately to the right of the midline. It drains blood from the posterior intercostal veins into the superior vena cava.

(Choice B) The inferior vena cava is located in the mediastinum, lies to the right of midline, and drains into the right atrium.

Educational objective:
The left ventricle forms the apex of the heart and can reach as far as the fifth intercostal space at the left midclavicular line (MCL). All other chambers of the heart lie medial to the left MCL. The lungs overlap much of the anterior surface of the heart.

Anatomy	Cardiovascular System	Penetrating thoracic trauma
Subject	System	Topic

Copyright © UWorld. All rights reserved.

A 56-year-old woman is evaluated for fatigue and dyspnea on exertion. Past medical history includes hypertension and systemic sclerosis. Blood pressure is 135/80 mm Hg and pulse is 68/min. Cardiac examination reveals loud second heart sounds with no murmurs. Lungs are clear to auscultation. Further evaluation with a catheterization procedure is performed, during which a balloon-tipped catheter is advanced into the pulmonary artery. A branch of the pulmonary artery is occluded by the balloon, and the pressure beyond the point of occlusion is measured. The pressure reading from the procedure most likely corresponds to which of the following pressures?

- A. Intrapleural pressure
- B. Left atrial pressure
- C. Mean airway pressure
- D. Mean arterial pressure
- E. Pulse pressure
- F. Right atrial pressure
- G. Right ventricular systolic pressure

Submit

A 56-year-old woman is evaluated for fatigue and dyspnea on exertion. Past medical history includes hypertension and systemic sclerosis. Blood pressure is 135/80 mm Hg and pulse is 68/min. Cardiac examination reveals loud second heart sounds with no murmurs. Lungs are clear to auscultation. Further evaluation with a catheterization procedure is performed, during which a balloon-tipped catheter is advanced into the pulmonary artery. A branch of the pulmonary artery is occluded by the balloon, and the pressure beyond the point of occlusion is measured. The pressure reading from the procedure most likely corresponds to which of the following pressures?

- A. Intrapleural pressure (2%)
- ✓ B. Left atrial pressure (78%)
- C. Mean airway pressure (1%)
- D. Mean arterial pressure (2%)
- E. Pulse pressure (0%)
- F. Right atrial pressure (6%)
- G. Right ventricular systolic pressure (8%)

Omitted
Correct answer
B

78%
Answered correctly

02 secs
Time Spent

05/11/2020
Last Updated

Explanation

Pulmonary artery catheters (PACs; also called Swan-Ganz or right heart catheters) are used to diagnose pulmonary hypertension and

Pulmonary artery catheters (PACs; also called Swan-Ganz or right heart catheters) are used to diagnose pulmonary hypertension and occasionally for management of critically ill patients. During pulmonary artery catheterization, the balloon at the distal tip of the catheter is inflated, and the catheter is advanced forward through the right atrium, right ventricle, and pulmonary artery and finally into a branch of the pulmonary artery. Once lodged in a pulmonary artery branch, the inflated balloon obstructs forward blood flow, creating a continuous static column of blood between the catheter tip and left atrium. The pressure measured at the catheter tip at this time is called the **pulmonary artery occlusion pressure** (PAOP; or pulmonary capillary wedge pressure [PCWP]) and closely reflects left atrial and left ventricular end-diastolic pressures.

(Choices A and C) Direct measurement of intrapleural pressure (pleural manometry) can be obtained by placing a catheter in the pleural space during thoracentesis, whereas mean airway pressure is measured during mechanical ventilation. PACs do not measure intrapleural or mean airway pressure.

(Choice D) Mean arterial pressure is measured by placing an arterial catheter directly in central arterial circulation (common femoral or radial artery) and reflects the average aortic pressure (perfusion pressure).

(Choice E) Pulse pressure refers to the difference between systemic arterial systolic and diastolic blood pressure.

(Choices F and G) Right atrial and right ventricular systolic pressures can be measured directly by PACs by placing the catheter in the respective chambers.

Educational objective:
Pulmonary artery occlusion pressure is measured at the distal tip of the pulmonary artery catheter after an inflated balloon occludes blood flow through a pulmonary artery branch. It closely corresponds to left atrial and left ventricular end-diastolic pressure.

References

- Catheterization of the heart in man with use of a flow-directed balloon-tipped catheter.

Anatomy	Cardiovascular System	Pulmonary blood flow
Subject	System	Topic

1
2
3
4
5
6
7
8
9
10
11
12
13
14
15
16
17
18
19
20
21
22
23
24
25
26
27
28
29

Exhibit Display

Pulmonary artery catheter waveforms

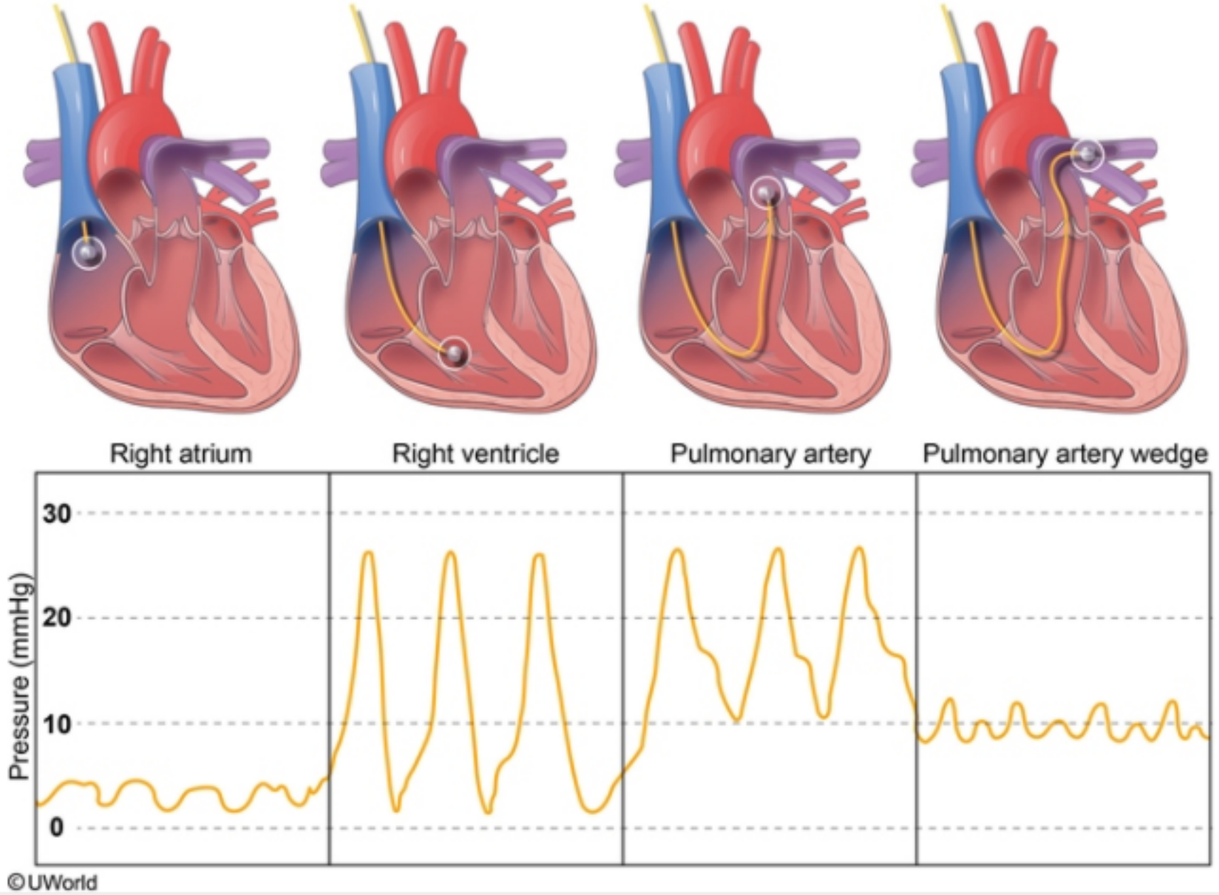

Zoom In | Zoom Out | Reset | Add To New Card | Existing Card

A 65-year-old man with a history of coronary artery disease comes to the physician complaining of progressive exertional shortness of breath, fatigue, and lower extremity swelling. His medical history is significant for a myocardial infarction 5 years ago and an electronic pacemaker implanted 2 years ago. His chest x-ray is shown below. A segment of one of the leads is highlighted (arrow).

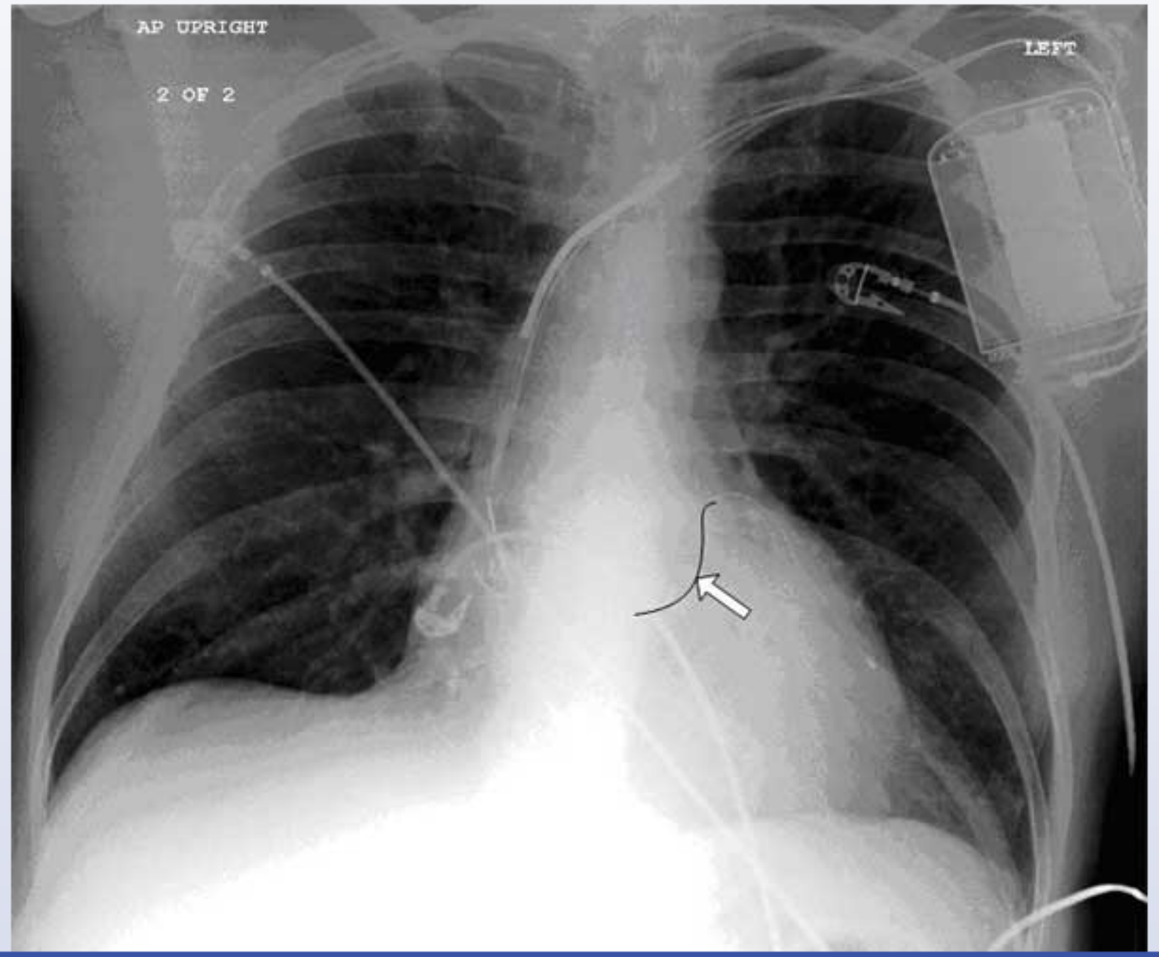

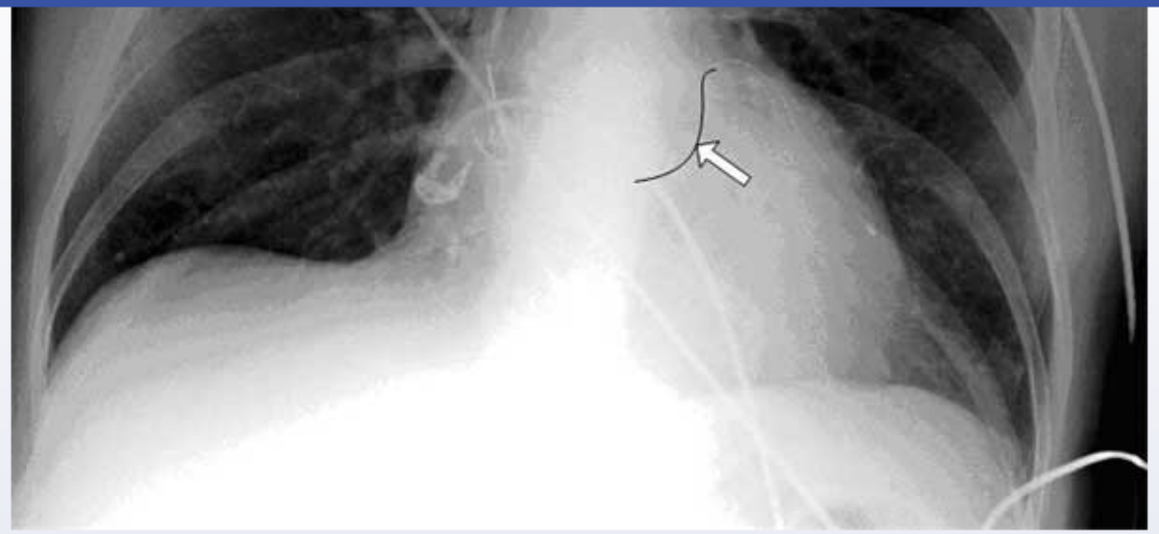

The highlighted segment most likely lies within which of the following structures?

- A. Anterior interventricular sulcus
- B. Atrioventricular groove
- C. Pulmonary artery
- D. Right atrium
- E. Right ventricle

Submit

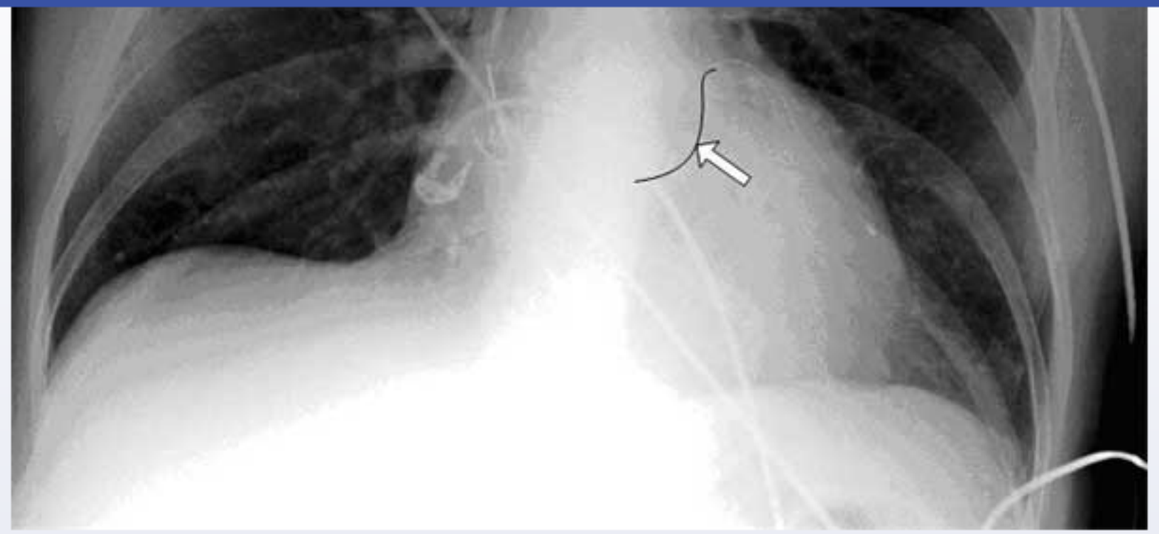

The highlighted segment most likely lies within which of the following structures?

- A. Anterior interventricular sulcus (7%)
- ✓ B. Atrioventricular groove (53%)
- C. Pulmonary artery (7%)
- D. Right atrium (20%)
- E. Right ventricle (10%)

Omitted
Correct answer

53%
Answered correctly

04 secs
Time Spent

01/21/2020
Last Updated

Biventricular pacemaker

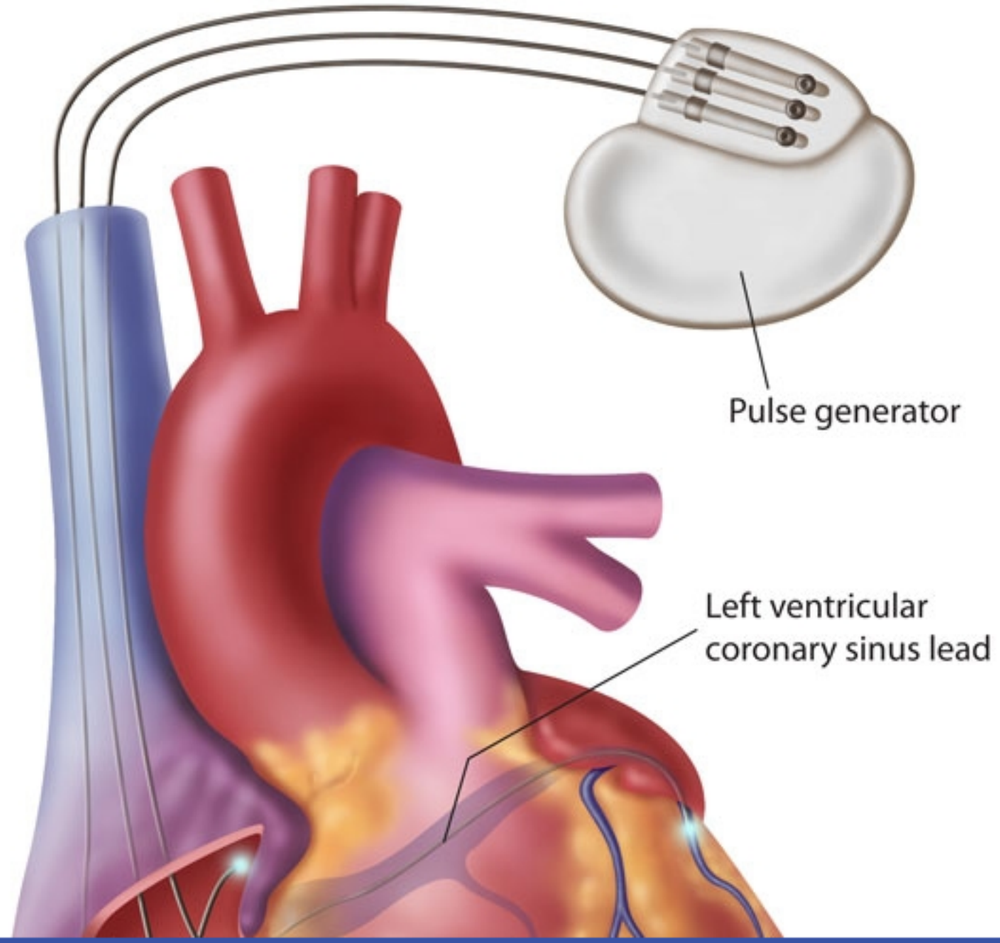

1
2
3
4
5
6
7
8
9
10
11
12
13
14
15
16
17
18
19
20
21
22
23
24
25
26
27
28
29

Exhibit Display

Biventricular pacemaker

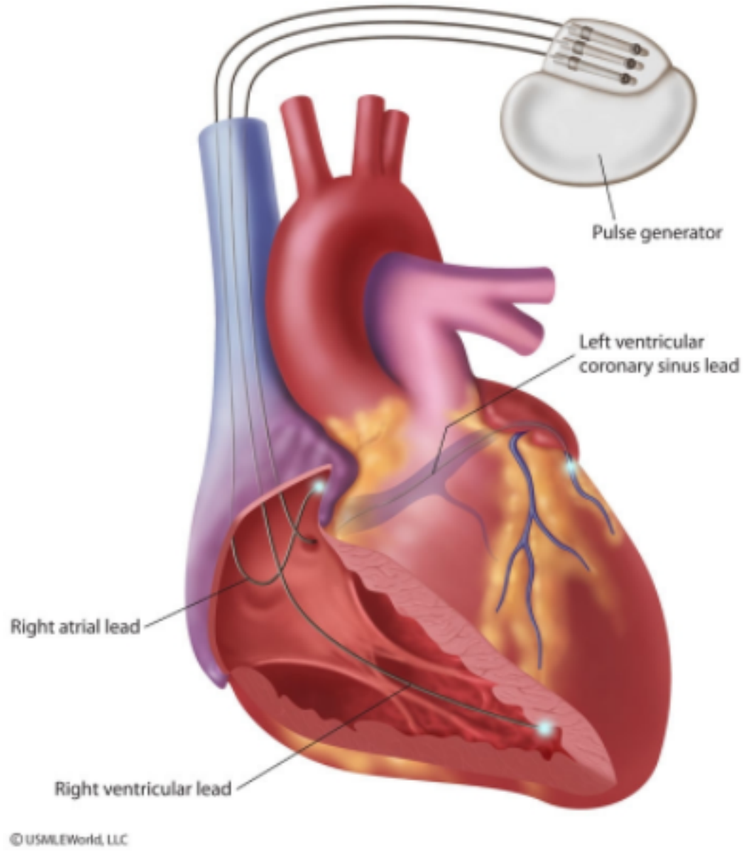

Zoom In | Zoom Out | Reset | Add To New Card | Existing Card

This patient has a biventricular pacemaker, a device that requires 2 or 3 leads. If 3 leads are used, the first 2 are placed in the right atrium and right ventricle. The third lead is used to pace the left ventricle. Right atrial and ventricular leads are easy to place as they only need to traverse the left subclavian vein and superior vena cava to reach these cardiac chambers. In contrast, the lead that paces the left ventricle is more difficult to position. The preferred transvenous approach involves passing the left ventricular pacing lead from the right atrium into the coronary sinus, which resides in the atrioventricular groove on the posterior aspect of the heart. It is then advanced into one of the lateral venous tributaries in order to optimize left ventricular pacing.

(Choice A) The anterior interventricular sulcus courses toward the apex of the heart on its anterior surface. The anterior descending vessels lie in this sulcus.

(Choice C) The pulmonary artery lies just to the left of center on the anterior surface of the heart. It courses from the right ventricle toward the aortic arch. Swan-Ganz catheters traverse the pulmonary artery.

(Choices D & E) The right atrium and ventricle are visible on the rightmost section of the cardiac silhouette.

Educational objective:
Left ventricular leads in biventricular pacemakers course through the coronary sinus, which resides in the atrioventricular groove on the posterior aspect of the heart.

Anatomy	Cardiovascular System	Implantable cardioverter defibrillator
Subject	System	Topic

Copyright © UWorld. All rights reserved.

An 82-year-old woman is sent to the hospital from a nursing home after 2 days of fever, confusion, and lethargy. The patient has a history of mild dementia, hypertension, and osteoarthritis. Her temperature is 38.8 C (102 F), blood pressure is 90/60 mm Hg, and pulse is 116/min. She has mild suprapubic and right costovertebral angle tenderness. Her leukocyte count is 18,000/mm^3, and urinalysis is consistent with acute cystitis. A femoral venous access is planned for administration of intravenous fluids and antibiotics. The femoral artery pulsation is palpable immediately below the inguinal ligament. Which of the following describes the optimal cannulation site for the femoral vein?

- A. Immediately lateral to the femoral artery
- B. Immediately medial to the femoral artery
- C. Midway between the iliac crest and the femoral artery
- D. Superior and medial to the pubic tubercle
- E. Superior to the inguinal ligament

Submit

An 82-year-old woman is sent to the hospital from a nursing home after 2 days of fever, confusion, and lethargy. The patient has a history of mild dementia, hypertension, and osteoarthritis. Her temperature is 38.8 C (102 F), blood pressure is 90/60 mm Hg, and pulse is 116/min. She has mild suprapubic and right costovertebral angle tenderness. Her leukocyte count is 18,000/mm^3, and urinalysis is consistent with acute cystitis. A femoral venous access is planned for administration of intravenous fluids and antibiotics. The femoral artery pulsation is palpable immediately below the inguinal ligament. Which of the following describes the optimal cannulation site for the femoral vein?

A. Immediately lateral to the femoral artery (16%)

✓ B. Immediately medial to the femoral artery (77%)

C. Midway between the iliac crest and the femoral artery (2%)

D. Superior and medial to the pubic tubercle (1%)

E. Superior to the inguinal ligament (1%)

Omitted
Correct answer
B

77%
Answered correctly

02 secs
Time Spent

04/28/2020
Last Updated

Explanation

Femoral triangle

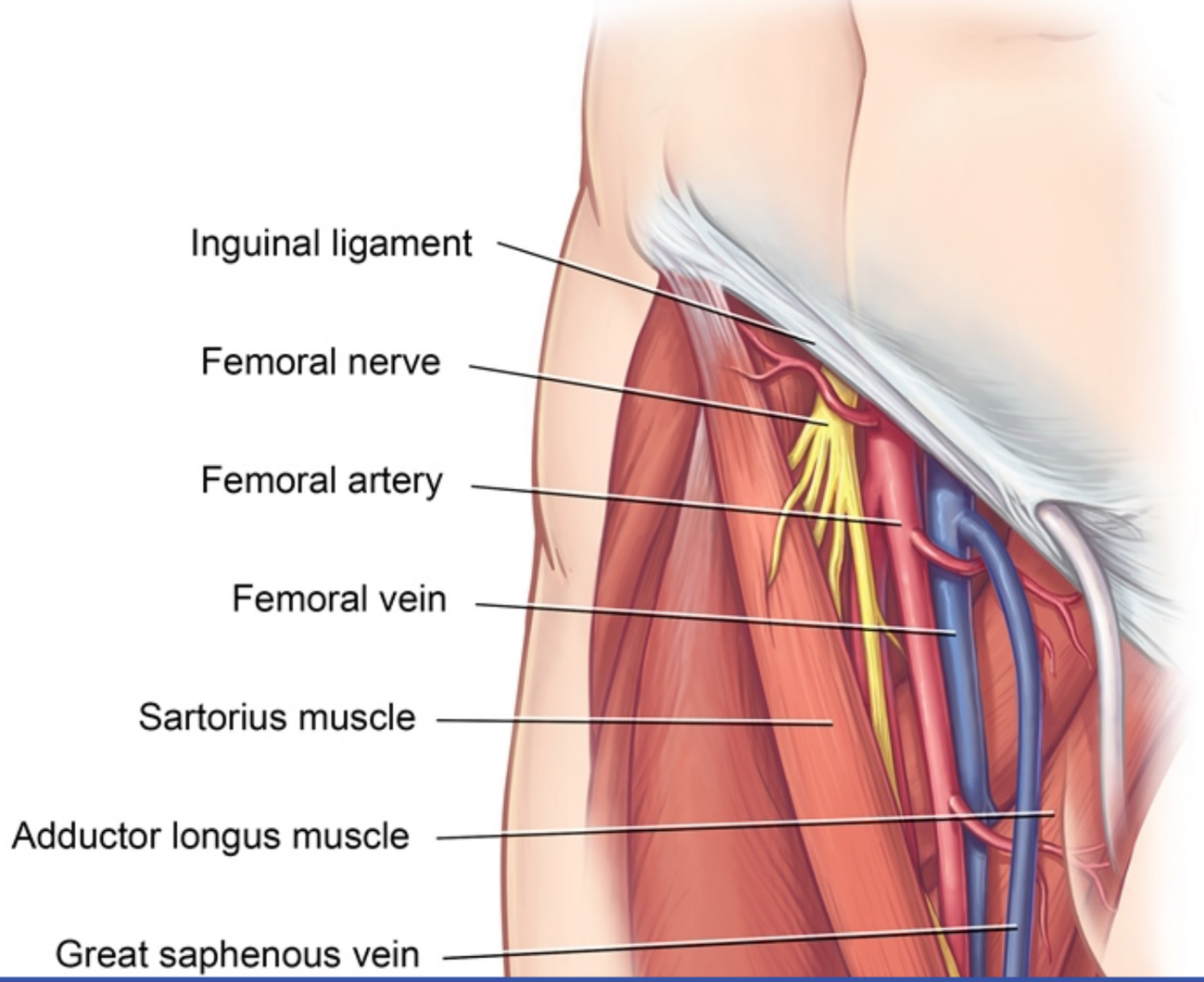

1
2
3
4
5
6
7
8
9
10
11
12
13
14
15
16
17
18
19
20
21
22
23
24
25
26
27
28
29

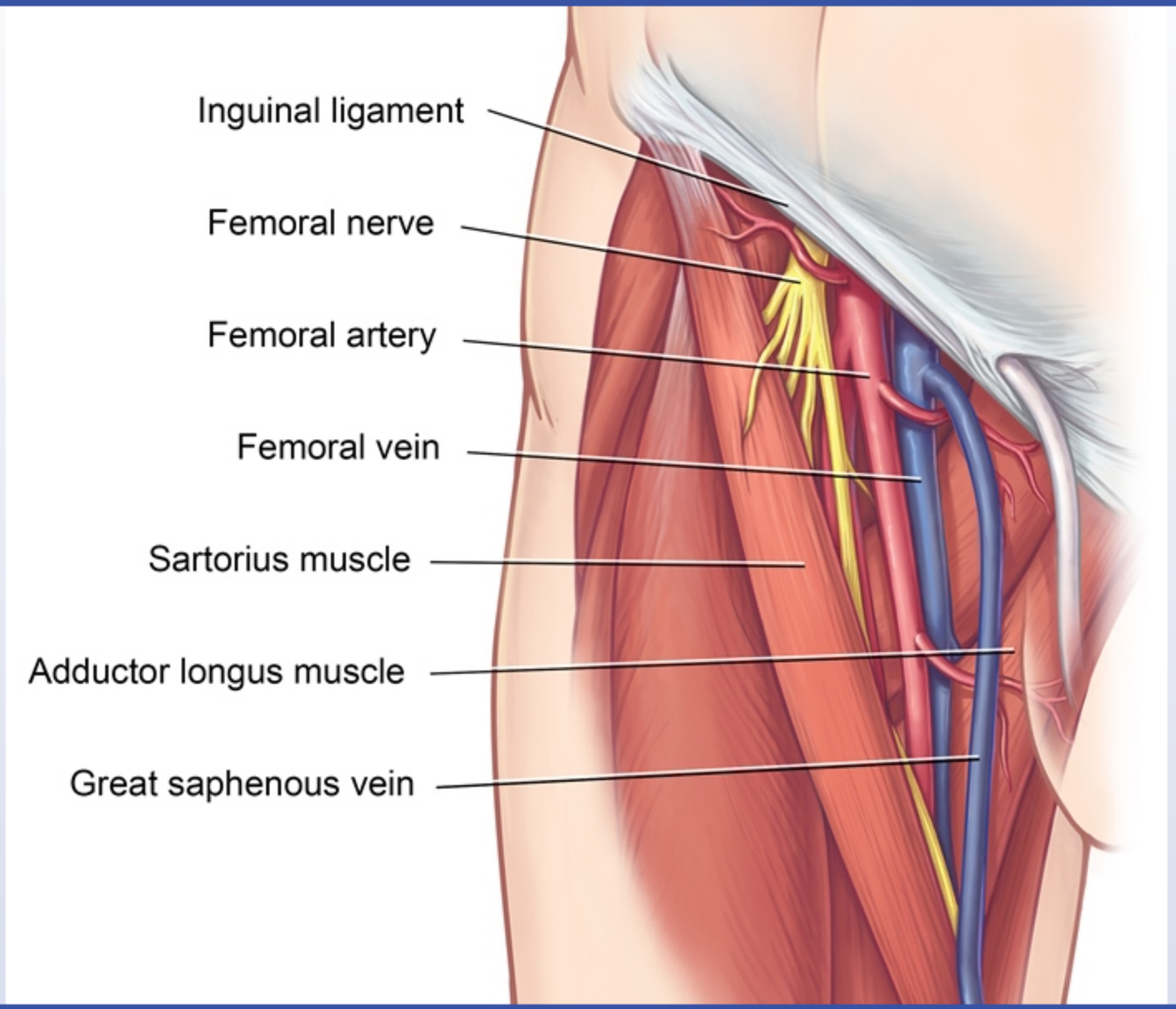

©UWorld

Femoral vein catheter placement is usually done in patients with unavailable preferred access sites (eg, subclavian, jugular vein) or those at increased risk of complications (eg, emergency access, uncooperative patient). The femoral vein is the major deep vein of the lower extremity and passes through the femoral triangle beneath the inguinal ligament before entering the pelvis as the external iliac vein. The femoral triangle is a subfascial space in the upper thigh that is bordered by the inguinal ligament (superiorly), adductor longus muscle (medially), and sartorius muscle (laterally).

Within the femoral triangle lies (lateral to medial) the femoral nerve, femoral artery, femoral vein, and deep inguinal nodes/lymphatic vessels. The femoral artery is located at the midinguinal point (midway between the pubic symphysis and anterior superior iliac spine), and the **femoral vein** lies **immediately medial** to the artery. Cannulation of the femoral vein should occur approximately 1 cm below the inguinal ligament and 0.5-1.0 cm medial to the femoral artery pulsation **(Choices C, D, and E).**

(Choice A) The femoral nerve is approximately 1 cm lateral to the femoral artery pulsation and could be damaged by needle insertion at this site.

Educational objective:
The femoral triangle (lateral to medial) consists of the femoral nerve, femoral artery, femoral vein, and deep inguinal nodes/lymphatic vessels. Cannulation of the femoral vein should occur approximately 1 cm below the inguinal ligament and just medial to the femoral artery pulsation.

Anatomy	Cardiovascular System	Central venous catheter
Subject	System	Topic

Copyright © UWorld. All rights reserved.

A 45-year-old man comes to clinic due to frequent episodes of palpitations accompanied by dizziness, fatigue, and shortness of breath. Prolonged ECG monitoring identifies episodes of atrial fibrillation associated with a rapid ventricular response rate. A radiofrequency ablation procedure is planned. The access site is the right femoral vein. The ablation catheter is advanced to the left atrium where radiofrequency energy is used to eliminate an ectopic focus of abnormal electrical activity. During the procedure, the catheter most likely passes through which of the following structures?

- A. Aortic valve
- B. Interatrial septum
- C. Interventricular septum
- D. Pulmonic valve
- E. Tricuspid valve

Submit

A 45-year-old man comes to clinic due to frequent episodes of palpitations accompanied by dizziness, fatigue, and shortness of breath. Prolonged ECG monitoring identifies episodes of atrial fibrillation associated with a rapid ventricular response rate. A radiofrequency ablation procedure is planned. The access site is the right femoral vein. The ablation catheter is advanced to the left atrium where radiofrequency energy is used to eliminate an ectopic focus of abnormal electrical activity. During the procedure, the catheter most likely passes through which of the following structures?

- A. Aortic valve (6%)
- ✓ B. Interatrial septum (62%)
- C. Interventricular septum (2%)
- D. Pulmonic valve (11%)
- E. Tricuspid valve (16%)

Omitted
Correct answer
B

62%
Answered correctly

02 secs
Time Spent

03/18/2020
Last Updated

Explanation

Trans-septal left atrial catheterization

1
2
3
4
5
6
7
8
9
10
11
12
13
14
15
16
17
18
19
20
21
22
23
24
25
26
27
28
29

Trans-septal left atrial catheterization

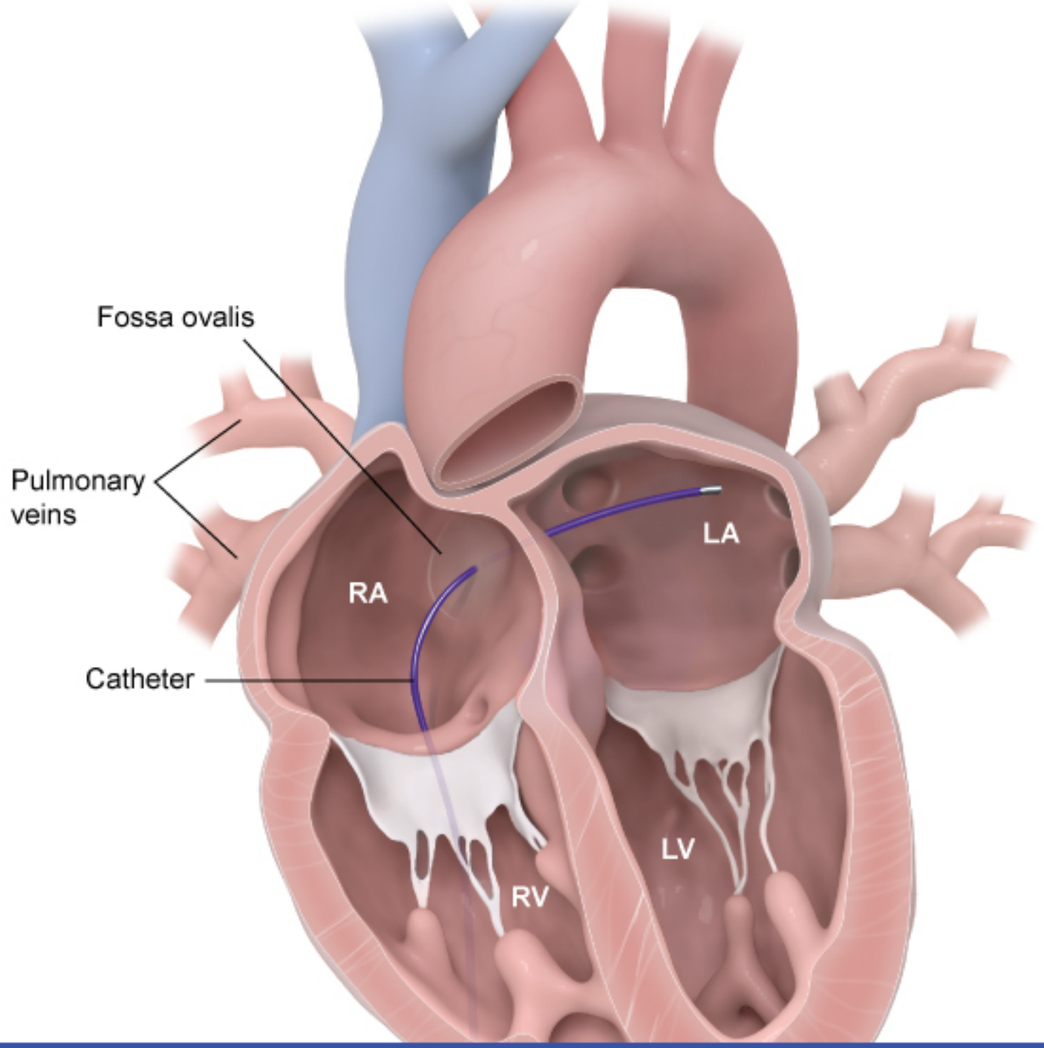

©UWorld

A **venous catheter** traveling from the femoral vein to the heart passes through the iliac vein and inferior vena cava to reach the **right atrium**. Once in the right atrium, structures within the right side of the heart and the pulmonary arteries are readily accessible. However, because the pulmonary capillaries are far too small to pass through, the left side of the heart must be accessed by **traversing the interatrial septum**. The interatrial septum is traversed at the site of the **foramen ovale**, which in adults is typically covered by a thin membrane of fibrous tissue that can be easily punctured.

Entry into the **left atrium** allows for direct measurement of left atrial pressure (rather than an estimate via pulmonary capillary wedge pressure) and for access to arrhythmogenic foci that may be located on the left atrial myocardium or the pulmonary veins. Following the procedure, the small atrial septal defect created by the catheter typically closes spontaneously.

(Choice A) Arterial catheterization of the left side of the heart typically starts in the femoral or radial artery and proceeds to the ascending aorta where pressure can be measured or dye can be placed into the coronary arteries to visualize atherosclerotic obstruction (ie, coronary angiography). In addition, the aortic valve may be crossed to measure left ventricular pressure. However, retrograde crossing of the structurally complex mitral valve is highly difficult, and the left atrium is not accessed via this route.

(Choice C) The interventricular septum is not traversed during heart catheterization because the myocardium is thick and difficult to puncture, and high left ventricular pressure would likely prevent spontaneous closure of the ventricular septal defect that is created.

(Choices D and E) The tricuspid valve is crossed during venous catherization to access the right ventricle, and the pulmonic valve is subsequently crossed to access the pulmonary arteries. However, because the catheter cannot pass through the pulmonary capillaries, the left atrium cannot be accessed via this route.

Educational objective:
To access the left side of the heart, cardiac venous catheters must cross the interatrial septum at the site of the foramen ovale. Entry into the left atrium allows for direct measurement of left atrial pressure and for access to arrhythmogenic foci on the left atrial myocardium or pulmonary veins.

References

- Emerging applications for transseptal left heart catheterization old techniques for new procedures.

©UWorld

Exhibit Display

Right heart catheterization

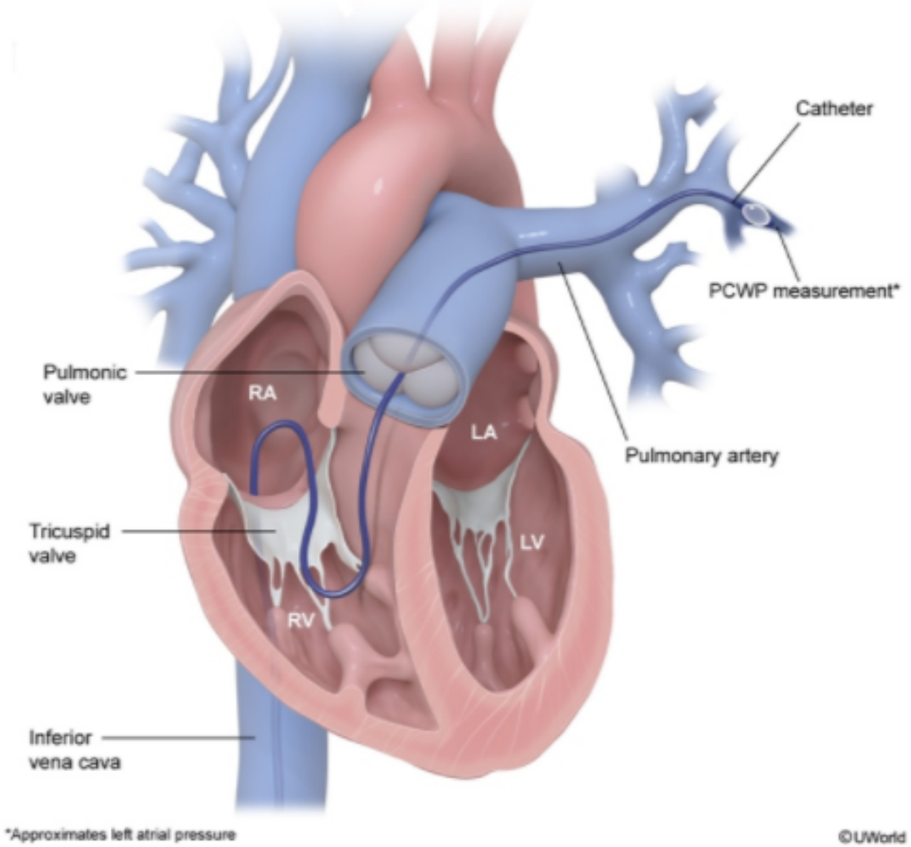

Zoom In | Zoom Out | Reset | Add To New Card | Existing Card

• Emerging applications for transseptal left heart catheterization old techniques for new procedures.

A 68-year-old man with a history of permanent atrial fibrillation comes to the office for follow-up. He has been having symptoms due to ineffective ventricular rate control despite aggressive medical therapy. On examination, the patient's heart rate is 125/min and irregular. ECG shows atrial fibrillation with rapid ventricular response. A catheter-based radiofrequency ablation of the atrioventricular node with placement of a permanent ventricular pacemaker is planned. The ablation tip should be positioned at which of the following locations?

A. Between the tricuspid valve and the inferior vena cava opening

B. Interatrial septum near the opening of the coronary sinus

C. Left atrium near the opening of the pulmonary veins

D. The posterior border of the fossa ovalis

E. Upper part of crista terminalis near the superior vena cava opening

Submit

A 68-year-old man with a history of permanent atrial fibrillation comes to the office for follow-up. He has been having symptoms due to ineffective ventricular rate control despite aggressive medical therapy. On examination, the patient's heart rate is 125/min and irregular. ECG shows atrial fibrillation with rapid ventricular response. A catheter-based radiofrequency ablation of the atrioventricular node with placement of a permanent ventricular pacemaker is planned. The ablation tip should be positioned at which of the following locations?

- A. Between the tricuspid valve and the inferior vena cava opening (17%)
- ✓ B. Interatrial septum near the opening of the coronary sinus (45%)
- C. Left atrium near the opening of the pulmonary veins (20%)
- D. The posterior border of the fossa ovalis (7%)
- E. Upper part of crista terminalis near the superior vena cava opening (9%)

Omitted
Correct answer
B

45%
Answered correctly

02 secs
Time Spent

02/25/2020
Last Updated

Explanation

Right atrial anatomy

1
2
3
4
5
6
7
8
9
10
11
12
13
14
15
16
17
18
19
20
21
22
23
24
25
26
27
28
29

Right atrial anatomy

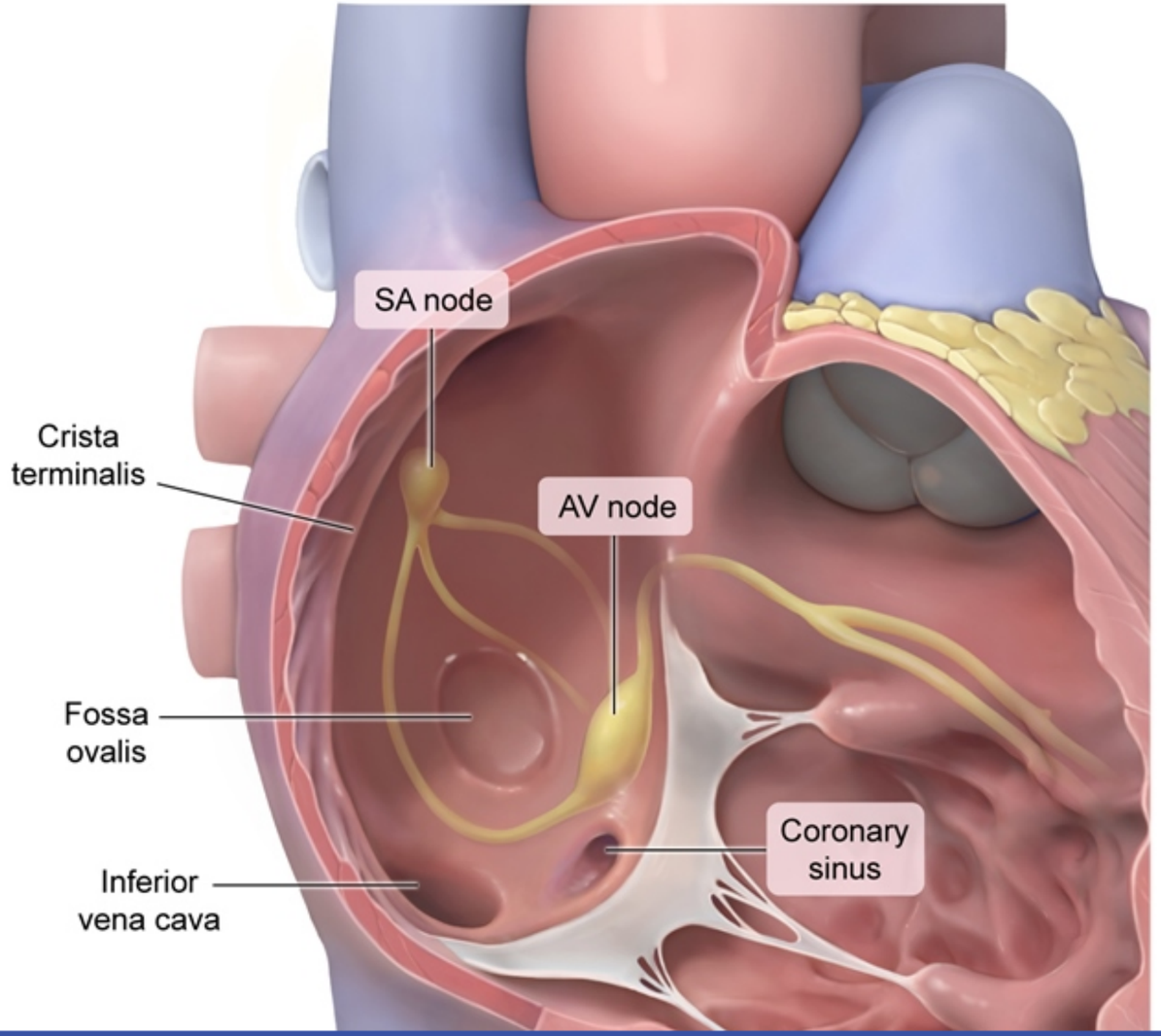

©UWorld

The **atrioventricular (AV) node** controls the rate at which atrial impulses are conducted to the ventricles. In patients with atrial fibrillation, continuous stimulation of the AV node can sometimes lead to a **rapid ventricular rate**, which can cause hemodynamic instability and (if persistent) tachycardia-induced cardiomyopathy. In order to prevent these complications, patients with a rapid ventricular response sometimes undergo **radiofrequency ablation** of the AV node. The AV node is located on the endocardial surface of the right atrium, **near** the insertion of the septal leaflet of the **tricuspid valve** and the orifice of the **coronary sinus**.

(Choices A and D) The isthmus between the inferior vena cava and the tricuspid annulus is the site of radiofrequency ablation for atrial flutter. The fossa ovalis is the name given to the foramen ovale (fetal opening between the right and left atria) once it is closed. However, neither option refers to the location of the AV node.

(Choice C) The pulmonary vein ostia are often the origination site of the aberrant electrical activity that triggers atrial fibrillation, and catheter ablation of these trigger sites (pulmonary vein isolation) can be used to prevent recurrent atrial fibrillation. However, this patient has already developed permanent atrial fibrillation and is undergoing an ablation procedure involving the AV node.

(Choice E) The sinoatrial node is located in the upper anterior right atrium at the opening of the superior vena cava.

Educational objective:
The atrioventricular node is located on the endocardial surface of the right atrium, near the insertion of the septal leaflet of the tricuspid valve and the orifice of the coronary sinus.

References

- Anatomy and electrophysiology of the human AV node.
- The anatomy of the cardiac conduction system.

Anatomy	Cardiovascular System	Av node
Subject	System	Topic

Copyright © UWorld. All rights reserved.

A 55-year-old man is brought to the emergency department due to shortness of breath, productive cough, and confusion. His wife mentions that last week he was diagnosed with the flu and his symptoms have progressively worsened. Temperature is 39.4 C (103 F), blood pressure is 80/50 mm Hg, pulse is 120/min, and respiratory rate is 22/min. Pulse oximetry shows 86% on room air. On physical examination, the patient is obtunded and in respiratory distress. He is intubated, given a 2-L bolus of normal saline, and started on broad spectrum antibiotics after blood cultures are obtained. A central line is placed to access a structure embryonically derived from the common cardinal veins. This structure is represented by which of the following labels shown in the chest CT scan below?

A. A
B. B
C. C
D. D
E. E

Submit

1
2
3
4
5
6
7
8
9
10
11
12
13
14
15
16
17
18
19
20
21
22
23
24
25
26
27
28
29

Exhibit Display

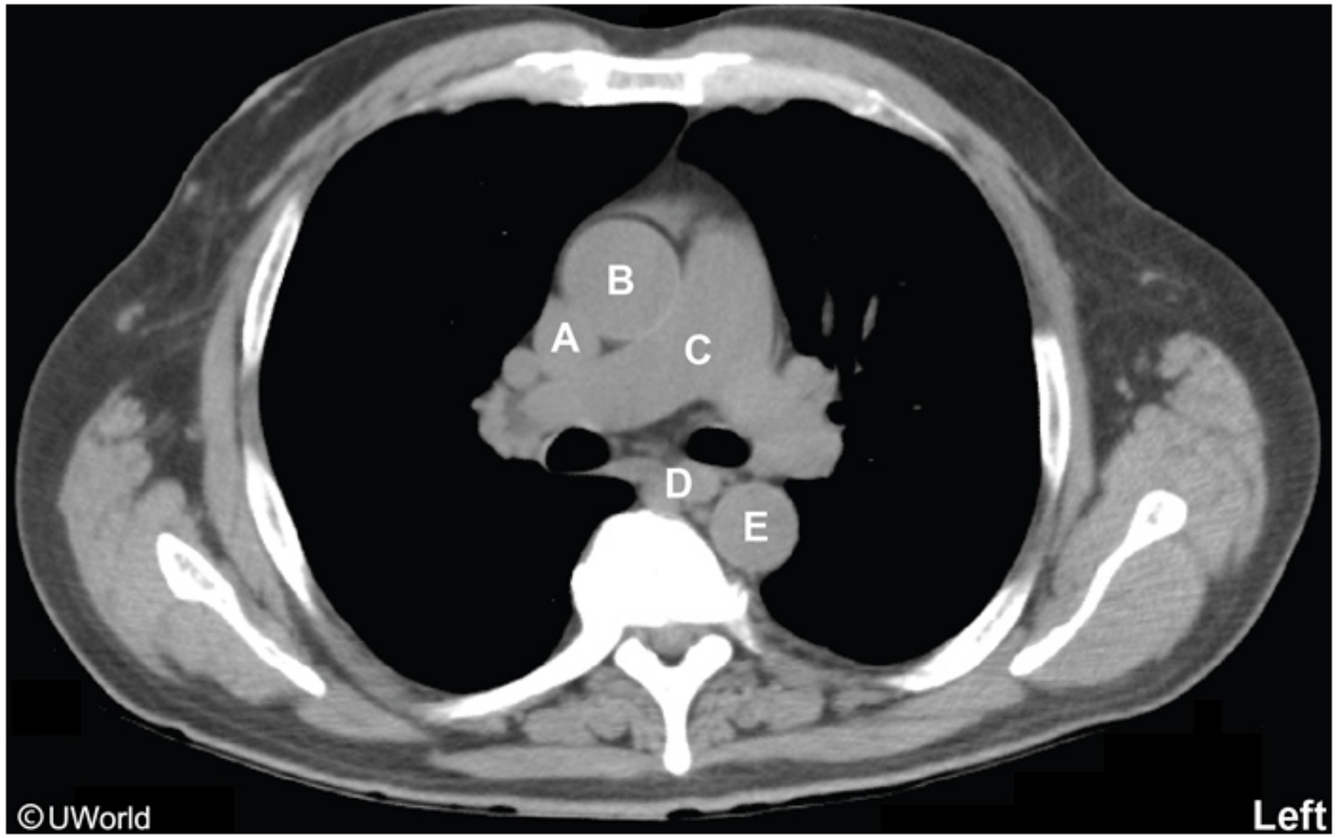

Zoom In | Zoom Out | Reset | Add To New Card | Existing Card

1
2
3
4
5
6
7
8
9
10
11
12
13
14
15
16
17
18
19
20
21
22
23
24
25
26
27
28
29

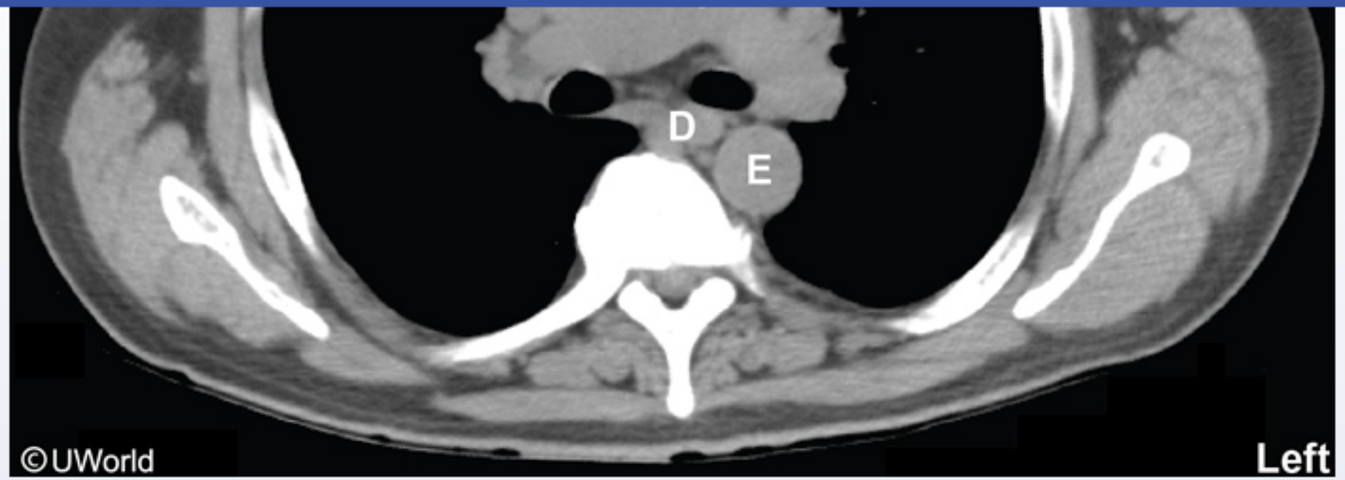

- ✓ A. A (51%)
- B. B (8%)
- C. C (12%)
- D. D (13%)
- E. E (13%)

Omitted
Correct answer
A

51%
Answered correctly

02 secs
Time Spent

03/31/2020
Last Updated

Explanation

Explanation

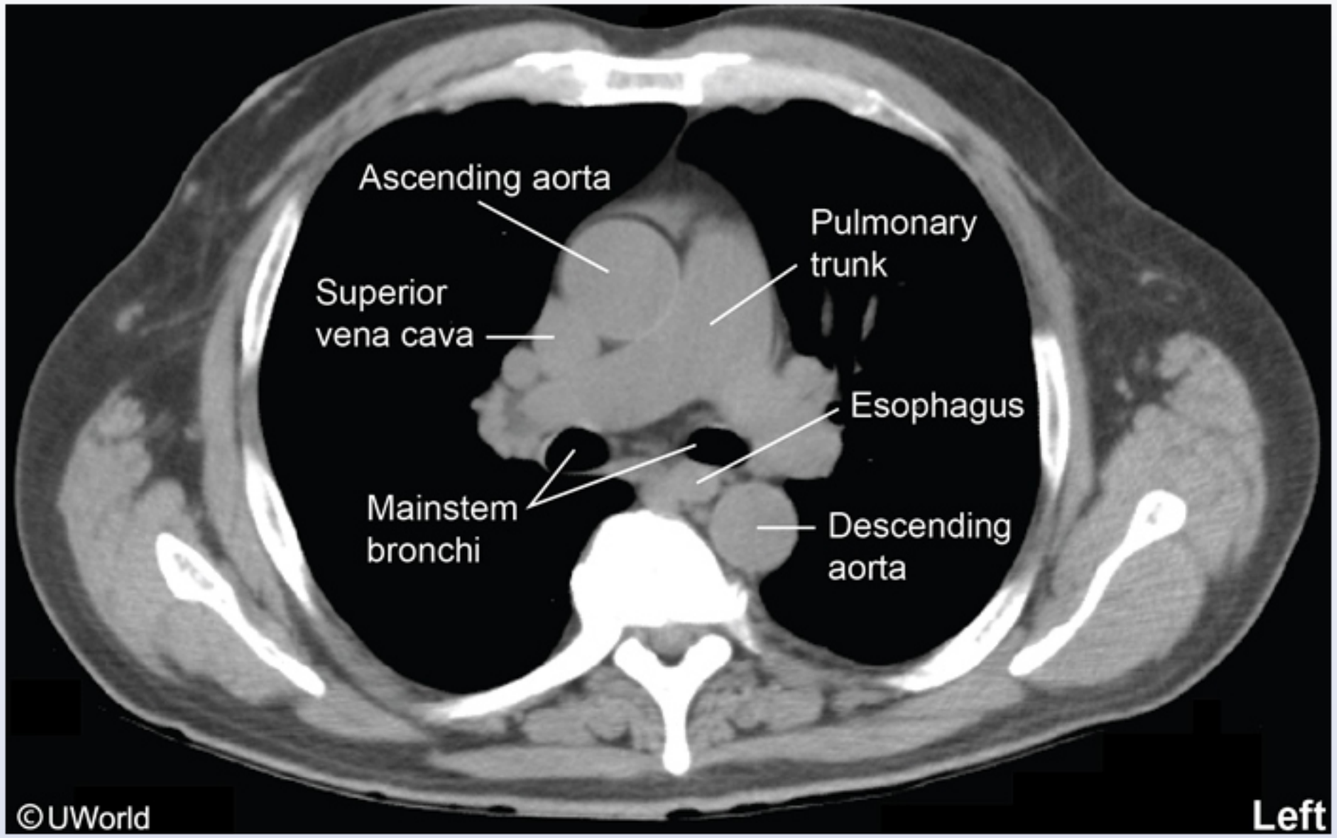

Patients with hemodynamic instability or shock often have **central lines** placed into the central venous system to allow rapid infusion of intravenous fluids, blood, and vasopressors. The catheter is usually inserted into the neck (internal jugular vein) or chest (subclavian vein), and is advanced until the catheter tip enters the **superior vena cava** (SVC). The SVC is derived from the common cardinal veins. On CT scan imaging of the upper thorax, the SVC can be identified to the right of the heart, posterolateral to the ascending aorta, anterior to the right pulmonary artery



Patients with hemodynamic instability or shock often have **central lines** placed into the central venous system to allow rapid infusion of intravenous fluids, blood, and vasopressors. The catheter is usually inserted into the neck (internal jugular vein) or chest (subclavian vein), and is advanced until the catheter tip enters the **superior vena cava** (SVC). The SVC is derived from the common cardinal veins. On CT scan imaging of the upper thorax, the SVC can be identified to the right of the heart, posterolateral to the ascending aorta, anterior to the right pulmonary artery, and just below the level of the carina.

All veins in the developing embryo ultimately drain into the sinus venosus, which drains into the primitive atrium of the developing heart. In early embryonic development, the body's veins fall into 3 main groups: umbilical, vitelline, and **cardinal veins**. The umbilical vein degenerates, the vitelline veins form the portal system, and the cardinal veins form constituents of the **systemic venous circulation**.

(Choice B) The ascending aorta develops from the truncus arteriosus, which also gives rise to the pulmonary trunk. A portion of the aortic arch develops from the fourth branchial (pharyngeal) arch.

(Choice C) The pulmonary trunk is derived from the truncus arteriosus. Neural crest cell migration helps partition the truncus arteriosus into the 2 great arteries (aorta and pulmonary artery) by causing fusion and twisting of the truncal and bulbar ridges. This process results in the normal spiral relation between the aorta and pulmonary artery. Failure of this process results in transposition of the great vessels and tetralogy of Fallot.

(Choice D) The esophagus is embryologically derived from the endodermal foregut. In the thoracic cavity, it descends posterior to the trachea and anterior to the vertebrae.

(Choice E) The descending aorta is derived from fusion of the embryonic right and left dorsal aortas. In the thoracic cavity, it starts left of the vertebral column and approaches the midline as it descends toward the diaphragm.

Educational objective:
The common cardinal veins of the developing embryo drain directly into the sinus venosus. These cardinal veins ultimately give rise to the superior vena cava and other constituents of the systemic venous circulation.

References

Exhibit Display

Embryonic circulation

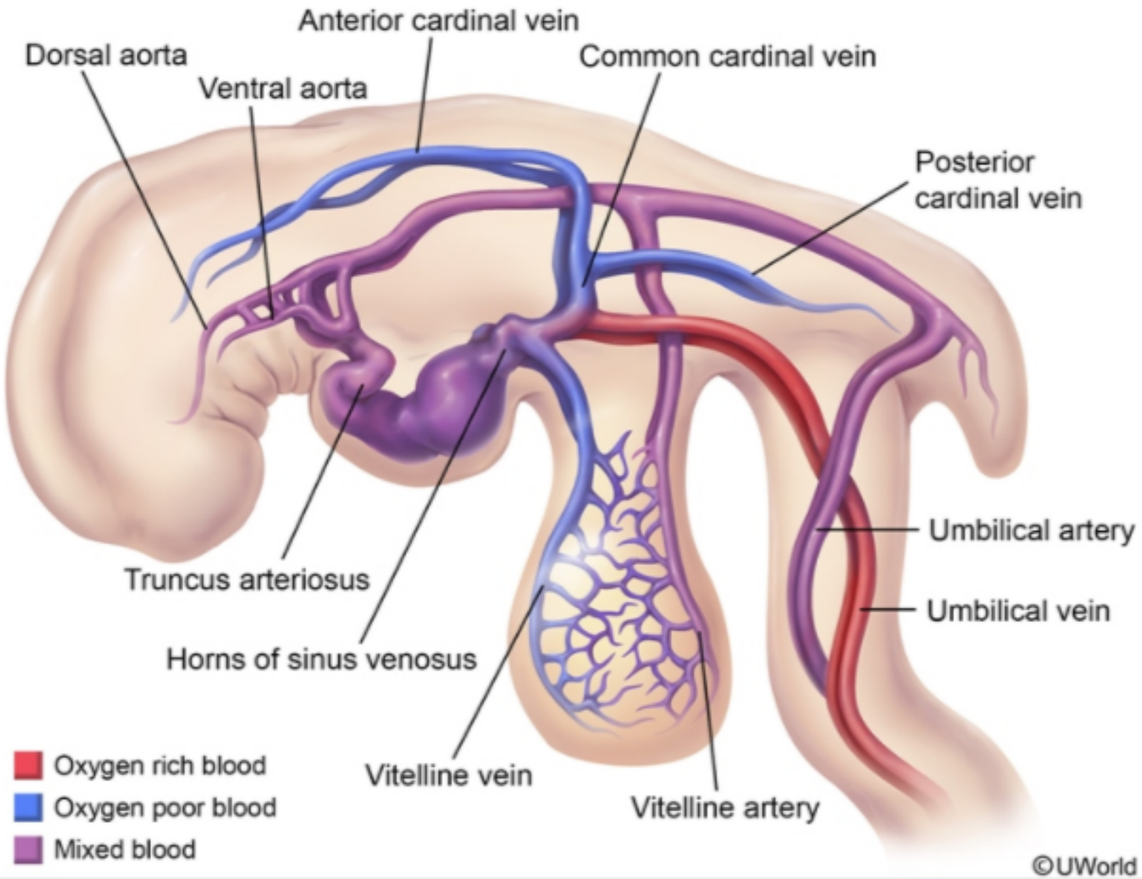

Zoom In | Zoom Out | Reset | Add To New Card | Existing Card

and just below the level of the carina.

All veins in the developing embryo ultimately drain into the sinus venosus, which drains into the primitive atrium of the developing heart. In early embryonic development, the body's veins fall into 3 main groups: umbilical, vitelline, and **cardinal veins**. The umbilical vein degenerates, the vitelline veins form the portal system, and the cardinal veins form constituents of the **systemic venous circulation**.

(Choice B) The ascending aorta develops from the truncus arteriosus, which also gives rise to the pulmonary trunk. A portion of the aortic arch develops from the fourth branchial (pharyngeal) arch.

(Choice C) The pulmonary trunk is derived from the truncus arteriosus. Neural crest cell migration helps partition the truncus arteriosus into the 2 great arteries (aorta and pulmonary artery) by causing fusion and twisting of the truncal and bulbar ridges. This process results in the normal spiral relation between the aorta and pulmonary artery. Failure of this process results in transposition of the great vessels and tetralogy of Fallot.

(Choice D) The esophagus is embryologically derived from the endodermal foregut. In the thoracic cavity, it descends posterior to the trachea and anterior to the vertebrae.

(Choice E) The descending aorta is derived from fusion of the embryonic right and left dorsal aortas. In the thoracic cavity, it starts left of the vertebral column and approaches the midline as it descends toward the diaphragm.

Educational objective:
The common cardinal veins of the developing embryo drain directly into the sinus venosus. These cardinal veins ultimately give rise to the superior vena cava and other constituents of the systemic venous circulation.

References

- Misplaced central venous catheters: Applied anatomy and practical management.

Anatomy	Cardiovascular System	Central venous catheter
Subject	System	Topic

Copyright © UWorld. All rights reserved.

An 18-year-old man comes to the clinic due to hematuria and intermittent left flank pain of several months duration. He has no history of trauma or sexually transmitted diseases and no associated fever or dysuria. Examination reveals a soft abdomen with normal bowel sounds and no localized tenderness. Urinalysis confirms 3+ blood but no white blood cells, crystals, or organisms. Contrast-enhanced CT scan shows no abnormalities in the ureters or kidneys but does reveal compression of the left renal vein between the superior mesenteric artery and the aorta. Which of the following is most likely to develop due to the vascular abnormality seen in this patient?

A. Esophageal varices

B. Left-sided ankle swelling

C. Periumbilical venous distension

D. Rectal varices

E. Varicocele

Submit

An 18-year-old man comes to the clinic due to hematuria and intermittent left flank pain of several months duration. He has no history of trauma or sexually transmitted diseases and no associated fever or dysuria. Examination reveals a soft abdomen with normal bowel sounds and no localized tenderness. Urinalysis confirms 3+ blood but no white blood cells, crystals, or organisms. Contrast-enhanced CT scan shows no abnormalities in the ureters or kidneys but does reveal compression of the left renal vein between the superior mesenteric artery and the aorta. Which of the following is most likely to develop due to the vascular abnormality seen in this patient?

- A. Esophageal varices (2%)
- B. Left-sided ankle swelling (3%)
- C. Periumbilical venous distension (6%)
- D. Rectal varices (2%)
- ✓ E. Varicocele (84%)

Omitted
Correct answer
E

84%
Answered correctly

02 secs
Time Spent

04/01/2020
Last Updated

Explanation

Varicocele pathophysiology

1
2
3
4
5
6
7
8
9
10
11
12
13
14
15
16
17
18
19
20
21
22
23
24
25
26
27
28
29

Varicocele pathophysiology

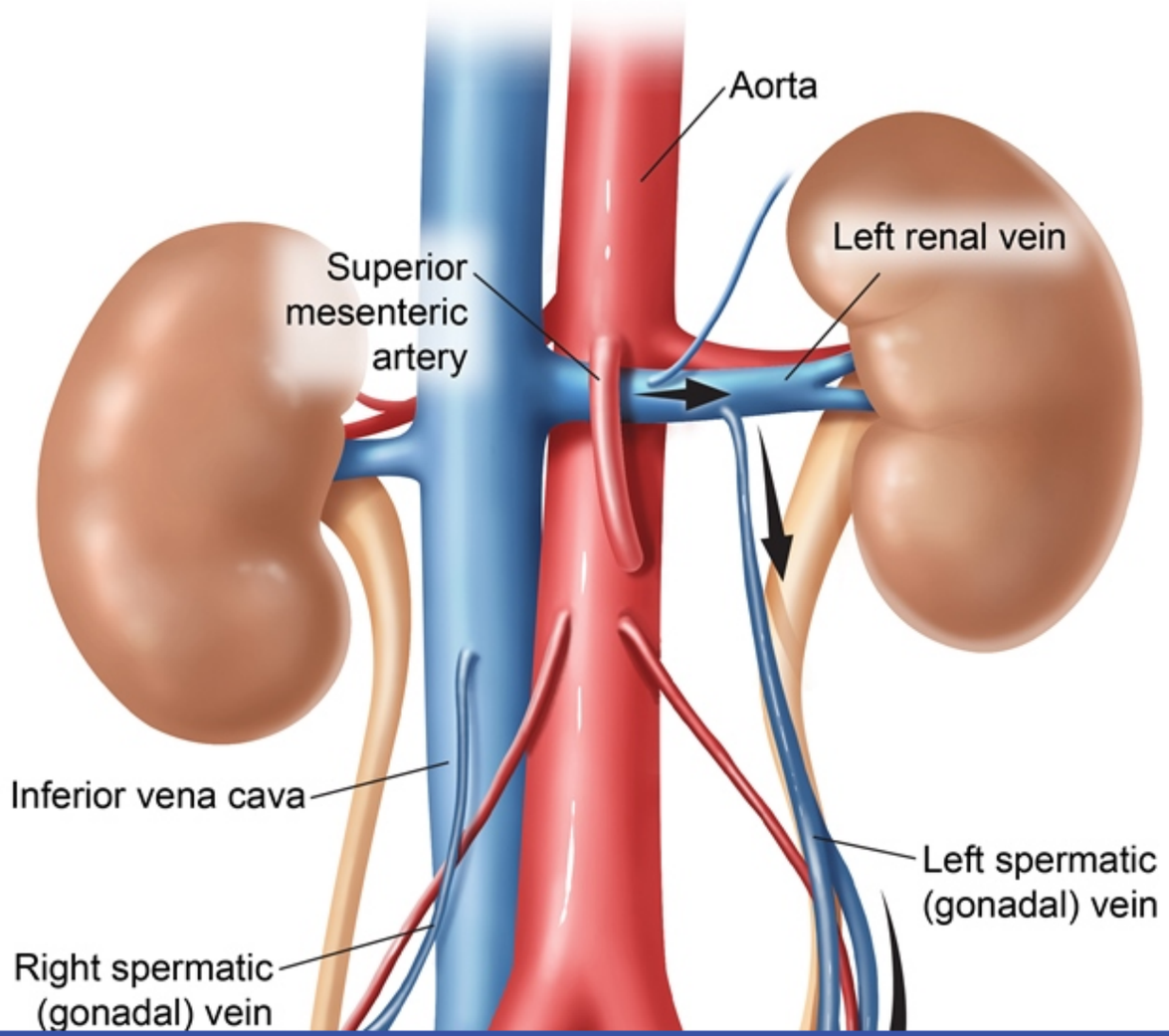

1
2
3
4
5
6
7
8
9
10
11
12
13
14
15
16
17
18
19
20
21
22
23
24
25
26
27
28
29

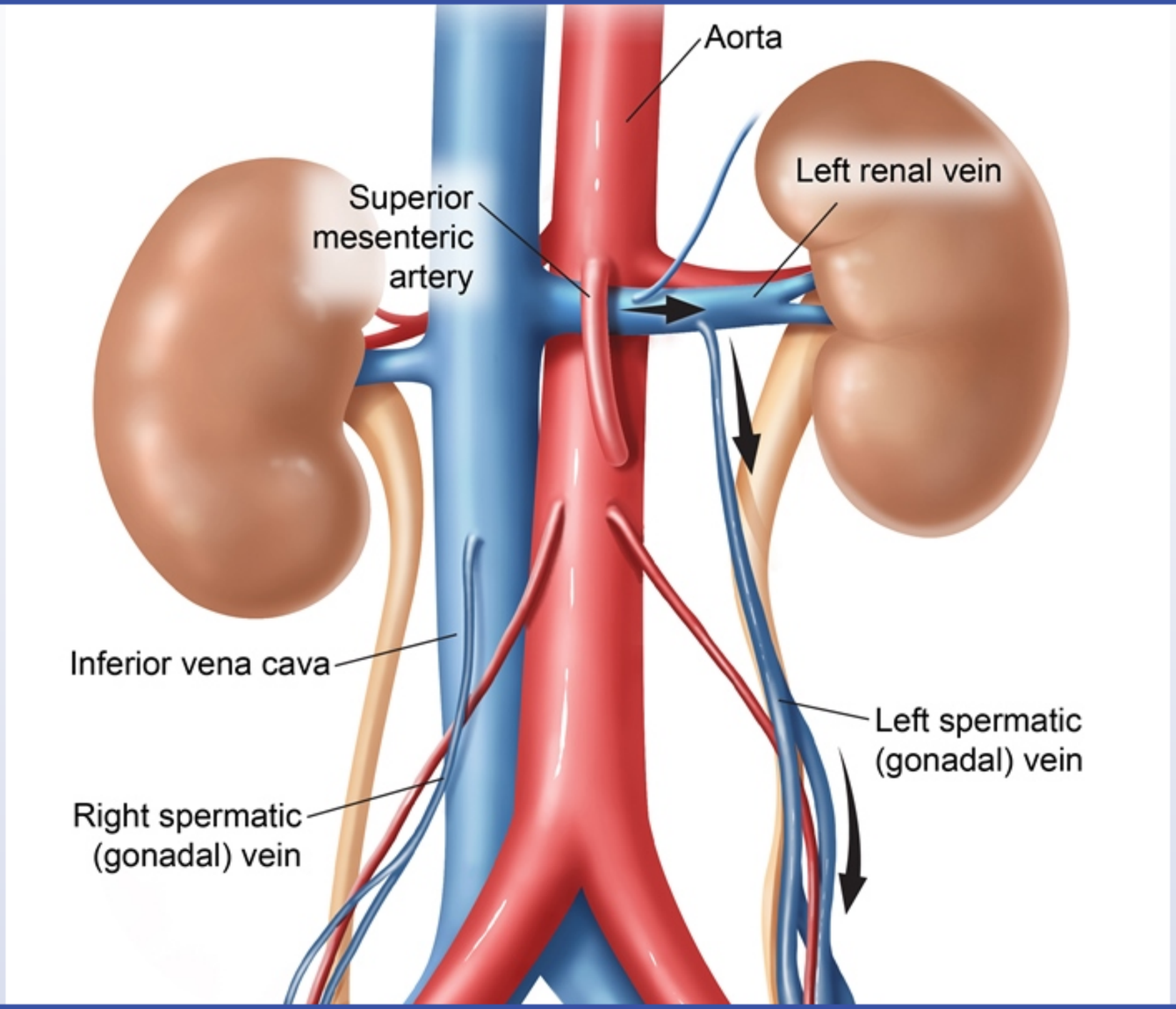

1
2
3
4
5
6
7
8
9
10
11
12
13
14
15
16
17
18
19
20
21
22
23
24
25
26
27
28
29

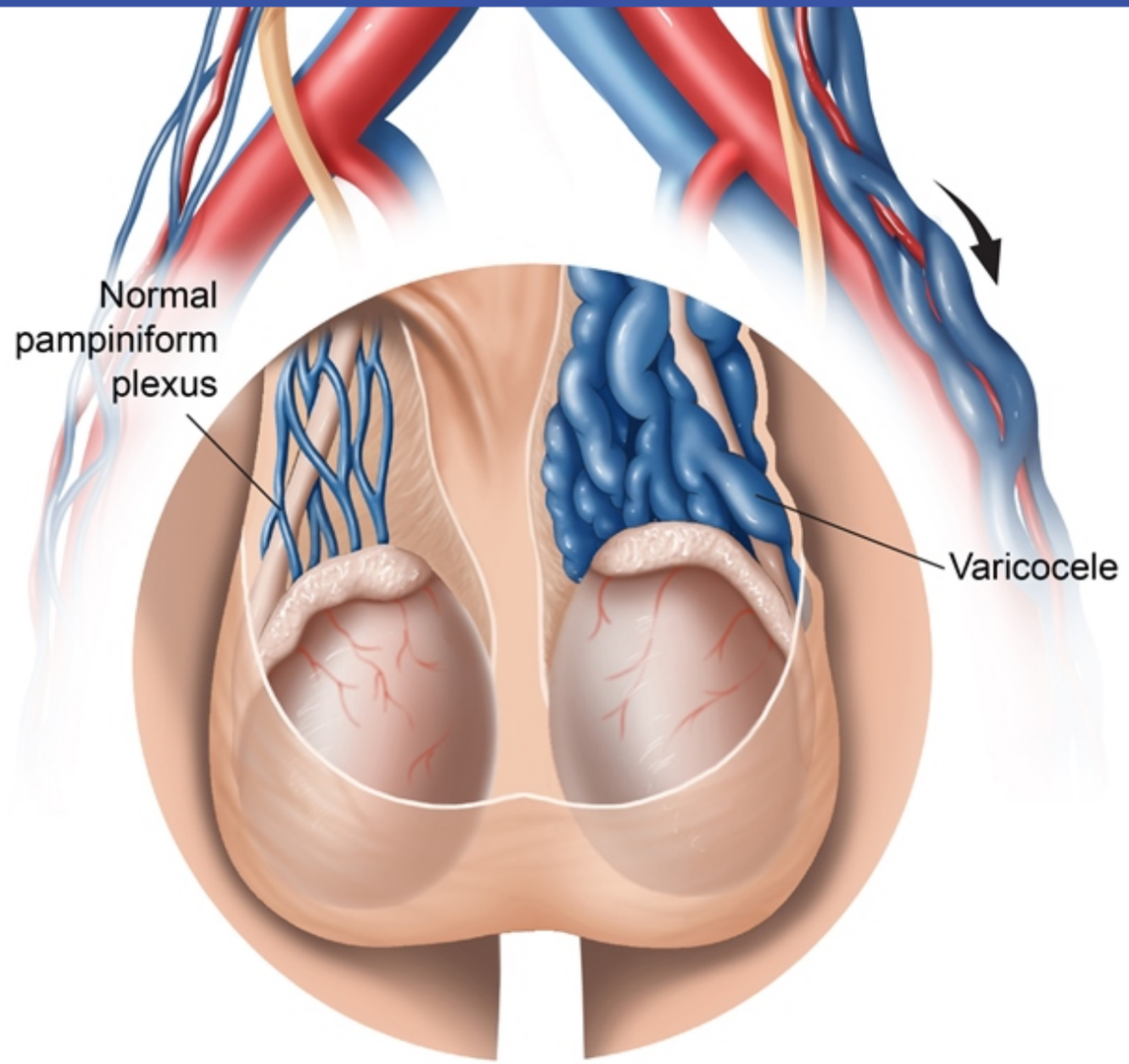

The aorta & superior mesenteric artery compress the left renal vein.

1
2
3
4
5
6
7
8
9
10
11
12
13
14
15
16
17
18
19
20
21
22
23
24
25
26
27
28
29

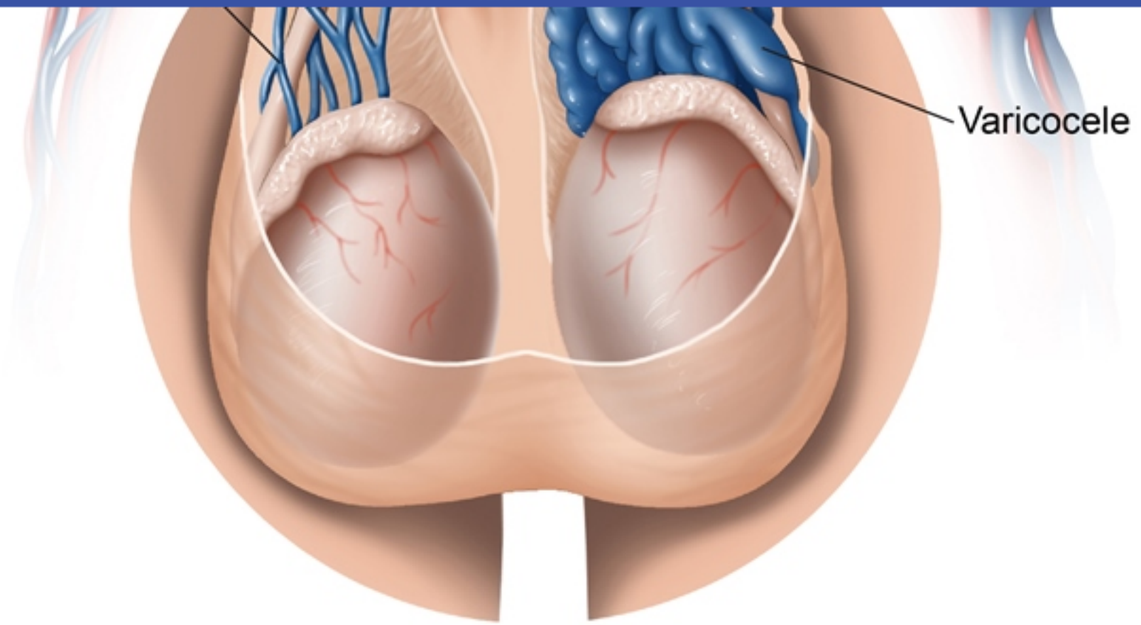

The aorta & superior mesenteric artery compress the left renal vein. The increased pressure in the left renal vein causes retrograde blood flow to testes & dilation of the pampiniform plexus.

©UWorld

The right renal vein is a relatively short structure and runs anterior to the right renal artery before joining the inferior vena cava (IVC). The right gonadal vein also drains directly to the IVC. In contrast, the **left renal vein** is significantly longer and runs posterior to the splenic vein before crossing the aorta beneath the superior mesenteric artery. The left gonadal vein joins the left renal vein upstream of where it crosses the aorta and does not enter the IVC directly.

The pressure within the left renal vein is often higher than on the right due to compression between the aorta and the superior mesenteric artery ("**nutcracker effect**"). Pressure in the left renal vein can also be elevated due to compression from a left-sided abdominal or retroperitoneal

The right renal vein is a relatively short structure and runs anterior to the right renal artery before joining the inferior vena cava (IVC). The right gonadal vein also drains directly to the IVC. In contrast, the **left renal vein** is significantly longer and runs posterior to the splenic vein before crossing the aorta beneath the superior mesenteric artery. The left gonadal vein joins the left renal vein upstream of where it crosses the aorta and does not enter the IVC directly.

The pressure within the left renal vein is often higher than on the right due to compression between the aorta and the superior mesenteric artery ("**nutcracker effect**"). Pressure in the left renal vein can also be elevated due to compression from a left-sided abdominal or retroperitoneal mass. Persistently elevated pressure in the left renal vein can cause flank or abdominal pain, along with gross or microscopic hematuria (left renal vein entrapment syndrome). Increased pressure in the left gonadal vein results in valve leaflet failure and varices of the testicular pampiniform plexus (**varicocele**).

(Choices A, C, and D) Esophageal varices, rectal varices, and periumbilical venous distension are signs of portal venous hypertension. The renal veins are not part of the portal system.

(Choice B) Unilateral left-sided ankle swelling can result from many causes, including obstruction of the left common iliac vein, left external iliac vein, left femoral vein, or any of the other major veins of the left leg.

Educational objective:
Pressure in the left renal vein may become elevated due to compression where the vein crosses the aorta beneath the superior mesenteric artery. This "nutcracker effect" can cause hematuria and flank pain. Pressure can also be elevated in the left gonadal vein, leading to formation of a varicocele.

References

- Nutcracker syndrome.

Anatomy	Cardiovascular System	Varicocele
Subject	System	Topic

Copyright © UWorld. All rights reserved.

1
2
3
4
5
6
7
8
9
10
11
12
13
14
15
16
17
18
19
20
21
22
23
24
25
26
27
28
29

A 47-year-old man is brought to the emergency department after being involved in a high-speed motor vehicle collision. He was a restrained driver and rear-ended a slow-moving car on the highway. He complains of chest pain, abdominal pain, and difficulty breathing. The patient has a past medical history of hypertension, asthma, and type 2 diabetes mellitus. On arrival, his blood pressure is 98/54 mm Hg and pulse is 121/min. Thirty minutes later, he becomes unresponsive and his pulse is no longer detectable. Electrocardiogram demonstrates sinus tachycardia. Despite extensive resuscitation efforts, the patient dies. An autopsy would most likely show an injury involving which of the following areas of the thoracic aorta?

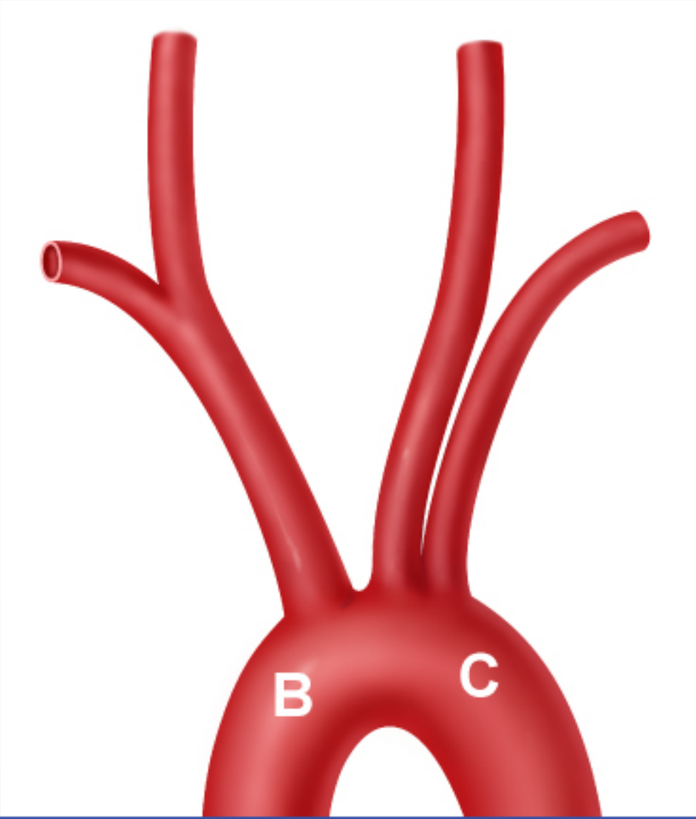

1
2
3
4
5
6
7
8
9
10
11
12
13
14
15
16
17
18
19
20
21
22
23
24
25
26
27
28
29

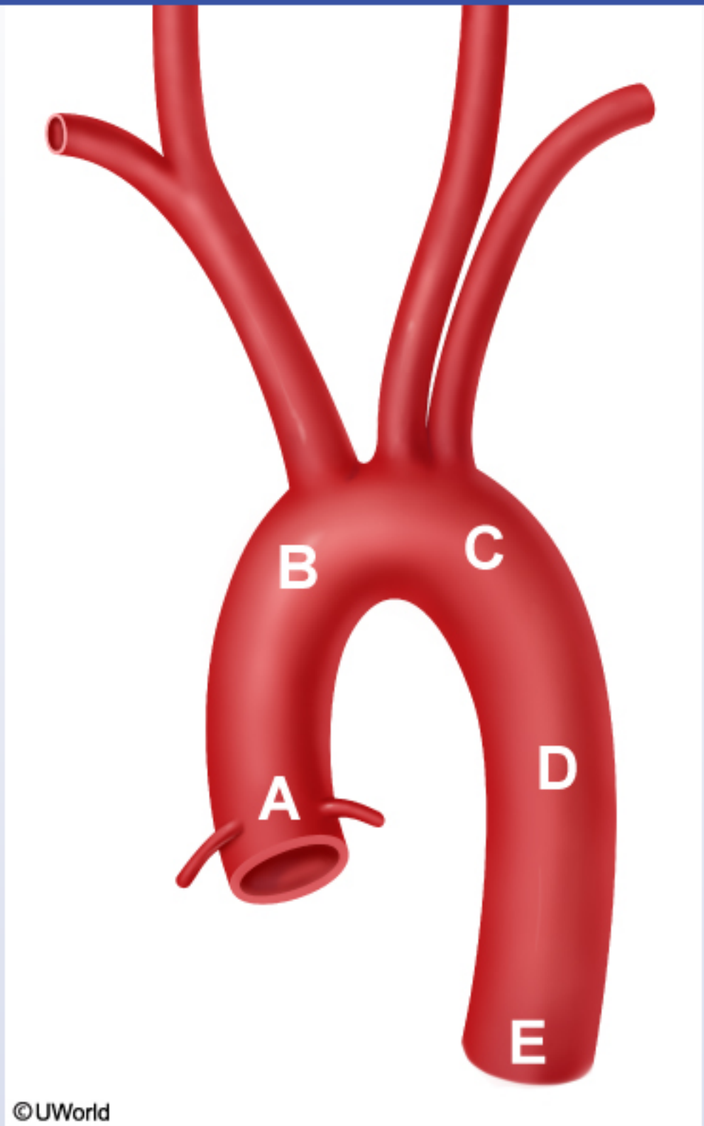

1
2
3
4
5
6
7
8
9
10
11
12
13
14
15
16
17
18
19
20
21
22
23
24
25
26
27
28
29

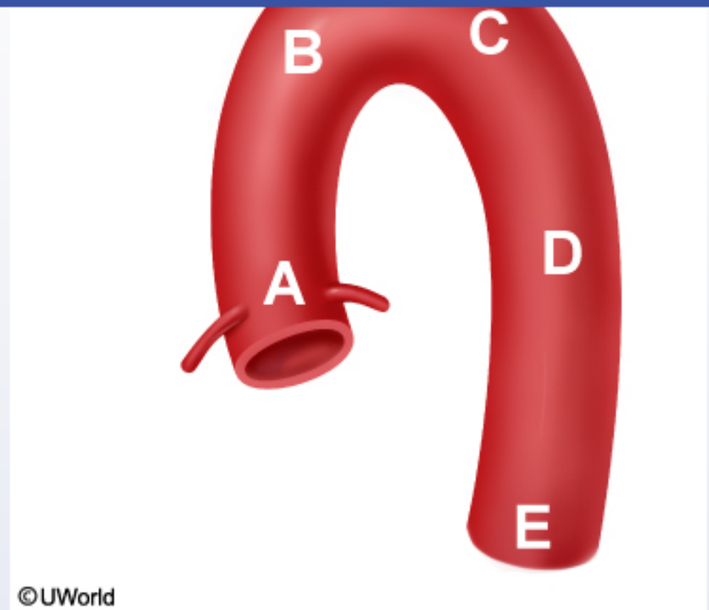

- A. A
- B. B
- C. C
- D. D
- E. E

Submit

1
2
3
4
5
6
7
8
9
10
11
12
13
14
15
16
17
18
19
20
21
22
23
24
25
26
27
28
29

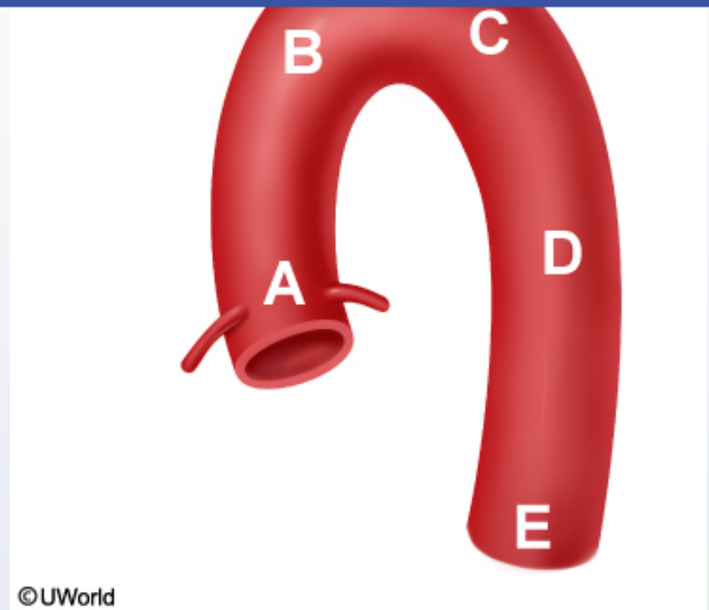

A. A (18%)

B. B (22%)

✓ C. C (32%)

D. D (11%)

E. E (13%)

Omitted
Correct answer

32%
Answered correctly

09 secs
Time Spent

03/13/2020
Last Updated

1
2
3
4
5
6
7
8
9
10
11
12
13
14
15
16
17
18
19
20
21
22
23
24
25
26
27
28
29

Aorta

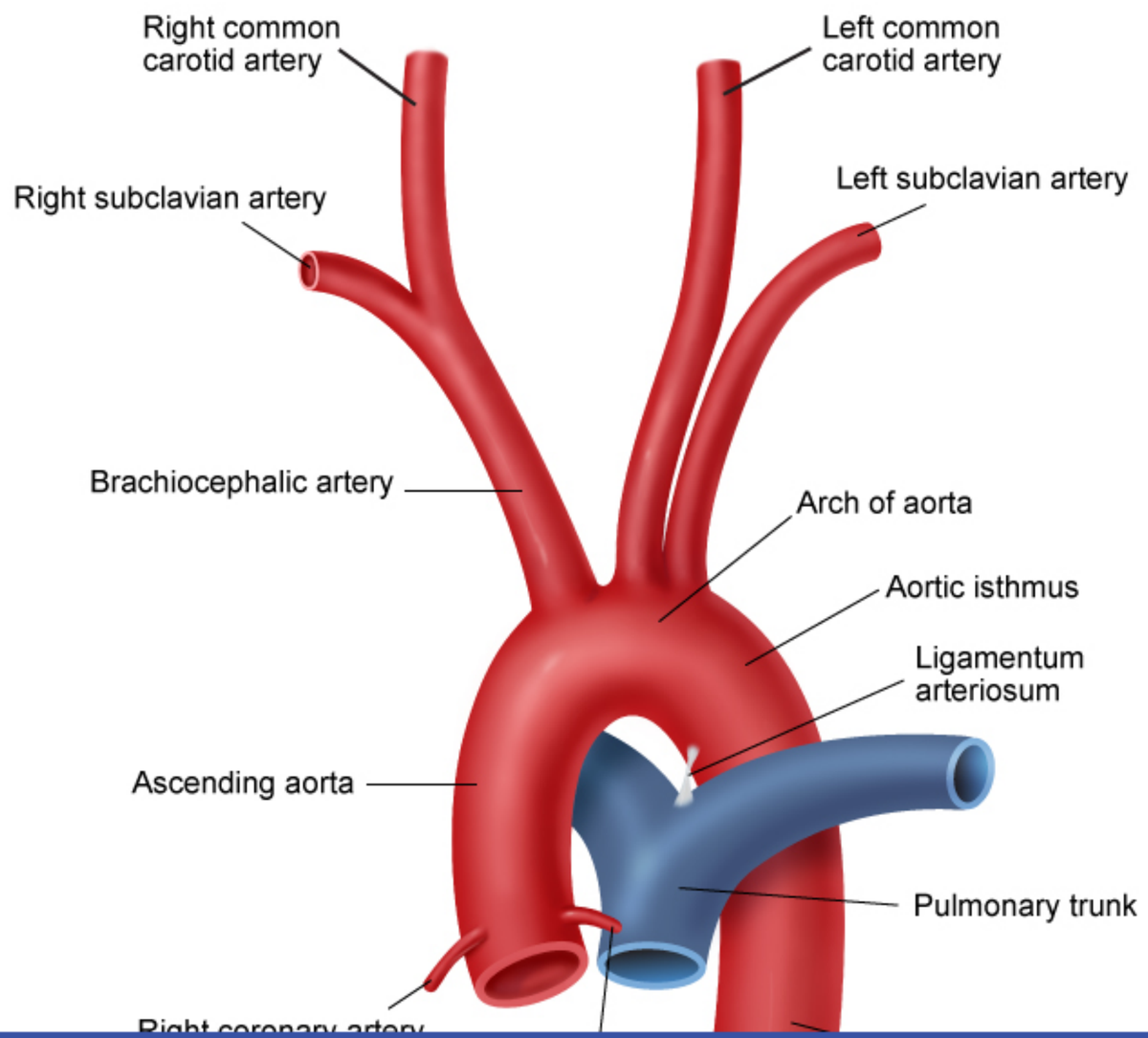

1
2
3
4
5
6
7
8
9
10
11
12
13
14
15
16
17
18
19
20
21
22
23
24
25
26
27
28
29

Aorta

Exhibit Display

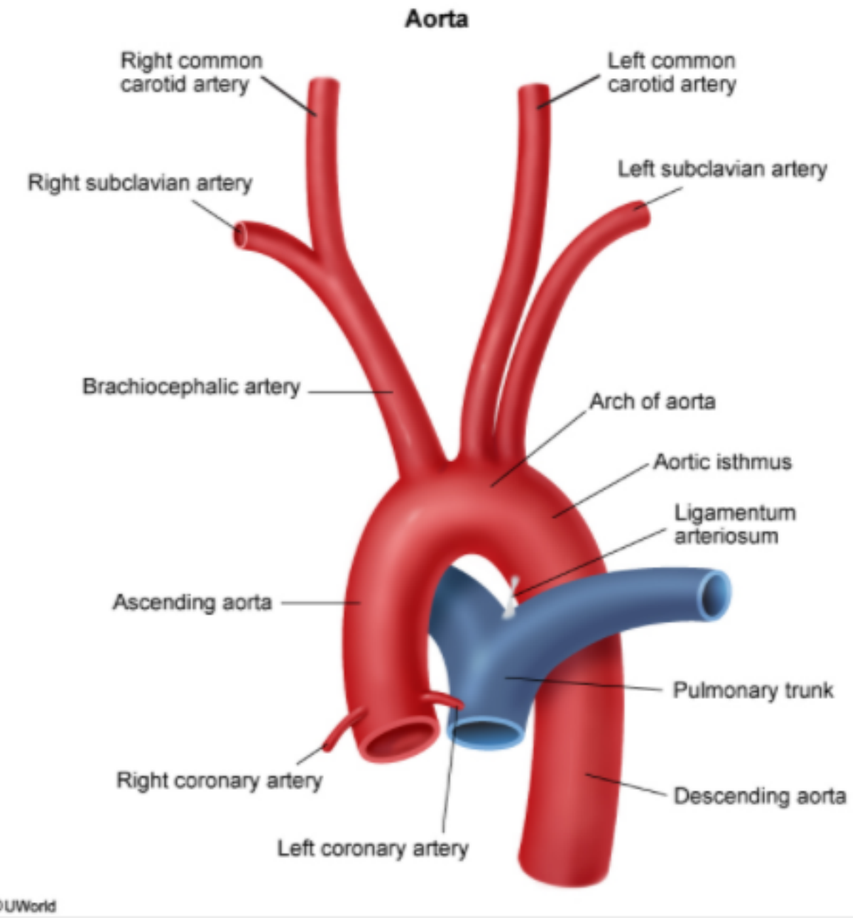

Zoom In | Zoom Out | Reset | Add To New Card | Existing Card

©UWorld

This patient's presentation is consistent with **blunt aortic injury** (ie, traumatic aortic rupture), which is most commonly caused by motor vehicle collisions. The mechanism of injury involves a **sudden deceleration** that results in extreme stretching and torsional forces affecting the heart and aorta. Injury occurs most often at the **aortic isthmus**, which is tethered by the ligamentum arteriosum and is relatively fixed and immobile compared to the adjacent descending aorta.

The majority (>80%) of patients die from aortic rupture before reaching the hospital. Those who survive the initial injury have nonspecific findings such as chest pain, back pain, or shortness of breath. A **widened mediastinum** may also be seen on chest x-ray.

(Choices A and B) Traumatic aortic ruptures can also affect the ascending aorta and are associated with especially high mortality due to associated complications (eg, hemopericardium, coronary artery dissection, aortic valve disruption). However, the aortic isthmus is by far the most common site of blunt aortic injury.

(Choices D and E) The distal descending aorta is a less common site for rupture than the more proximal portions of the aorta.

Educational objective:
Traumatic aortic rupture is most often caused by the rapid deceleration that occurs in motor vehicle collisions. The most common site of injury is the aortic isthmus, which is tethered by the ligamentum arteriosum and is relatively fixed and immobile compared to the adjacent descending aorta.

References

- Blunt thoracic aortic injuries: an autopsy study
- Fatal aortic rupture from nonpenetrating chest trauma.

Anatomy	Cardiovascular System	Blunt thoracic trauma
Subject	System	Topic

Copyright © UWorld. All rights reserved.

A 54-year-old man comes to the physician for evaluation of exertional chest pain. He first noticed the pain a couple months ago when he was shoveling snow off his driveway and has since experienced several episodes while doing other strenuous tasks. He describes the pain as a heavy, crushing sensation and says it is relieved with rest. The patient undergoes coronary angiography and is found to have severe stenosis of the right coronary artery and left anterior descending and circumflex arteries. He is referred to a surgeon for coronary artery bypass grafting. During the procedure, a portion of his great saphenous vein is removed and grafted to one of the diseased coronary arteries to bypass its atherosclerotic narrowing. The vein used as a graft during this patient's procedure can be accessed at which of the following sites?

- A. At the midline of the popliteal fossa
- B. Just inferior to the anterior superior iliac spine
- C. Just inferolateral to the pubic tubercle
- D. Just superior to the inguinal ligament
- E. Over the lateral aspect of the foot

Submit

A 54-year-old man comes to the physician for evaluation of exertional chest pain. He first noticed the pain a couple months ago when he was shoveling snow off his driveway and has since experienced several episodes while doing other strenuous tasks. He describes the pain as a heavy, crushing sensation and says it is relieved with rest. The patient undergoes coronary angiography and is found to have severe stenosis of the right coronary artery and left anterior descending and circumflex arteries. He is referred to a surgeon for coronary artery bypass grafting. During the procedure, a portion of his great saphenous vein is removed and grafted to one of the diseased coronary arteries to bypass its atherosclerotic narrowing. The vein used as a graft during this patient's procedure can be accessed at which of the following sites?

- A. At the midline of the popliteal fossa (31%)
- B. Just inferior to the anterior superior iliac spine (7%)
- ✓ C. Just inferolateral to the pubic tubercle (39%)
- D. Just superior to the inguinal ligament (3%)
- E. Over the lateral aspect of the foot (17%)

Omitted
Correct answer
C

39%
Answered correctly

02 secs
Time Spent

04/12/2020
Last Updated

Explanation

Superficial & deep veins of leg

1
2
3
4
5
6
7
8
9
10
11
12
13
14
15
16
17
18
19
20
21
22
23
24
25
26
27
28
29

Superficial & deep veins of leg

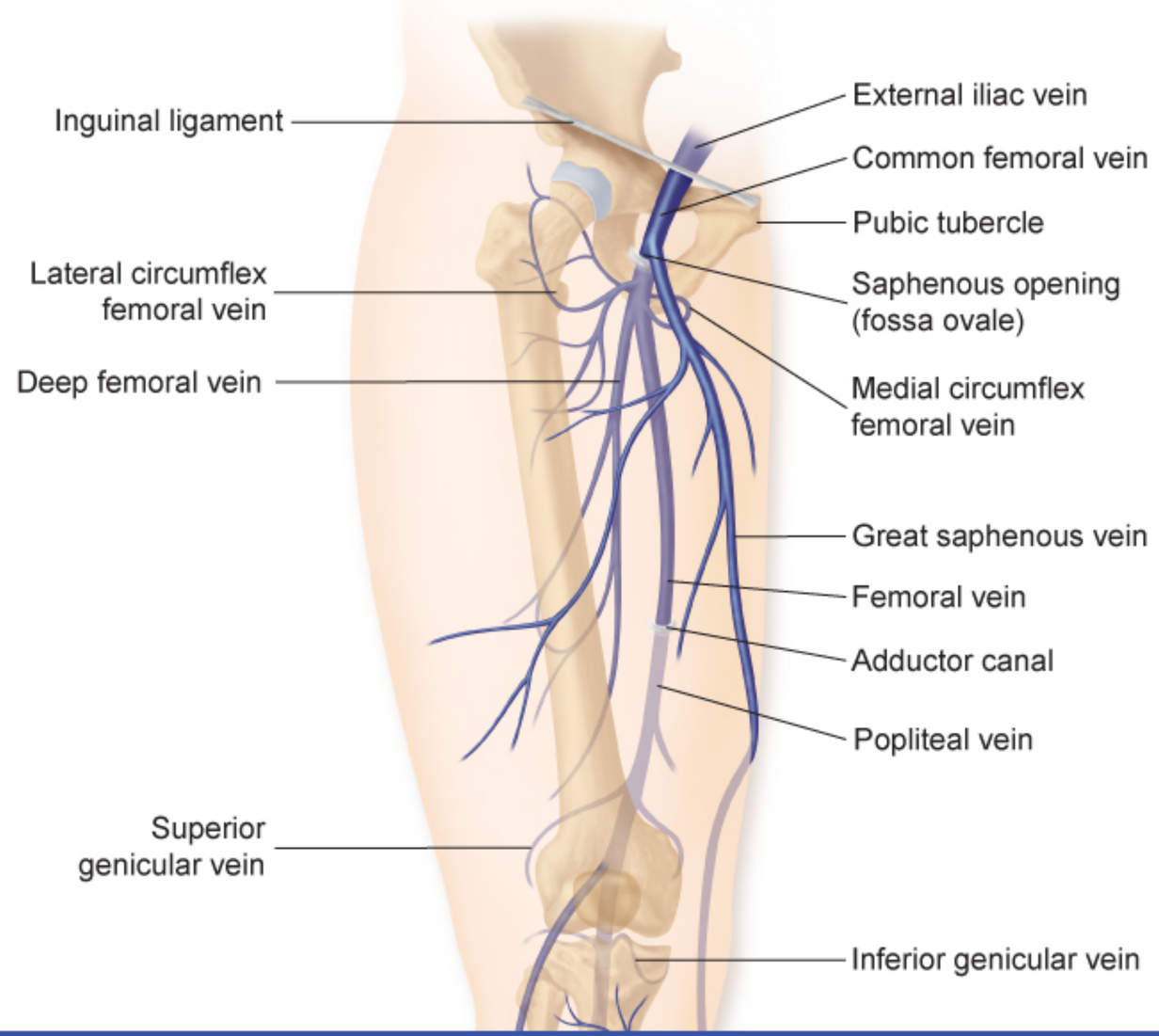

Superficial & deep veins of leg

Exhibit Display

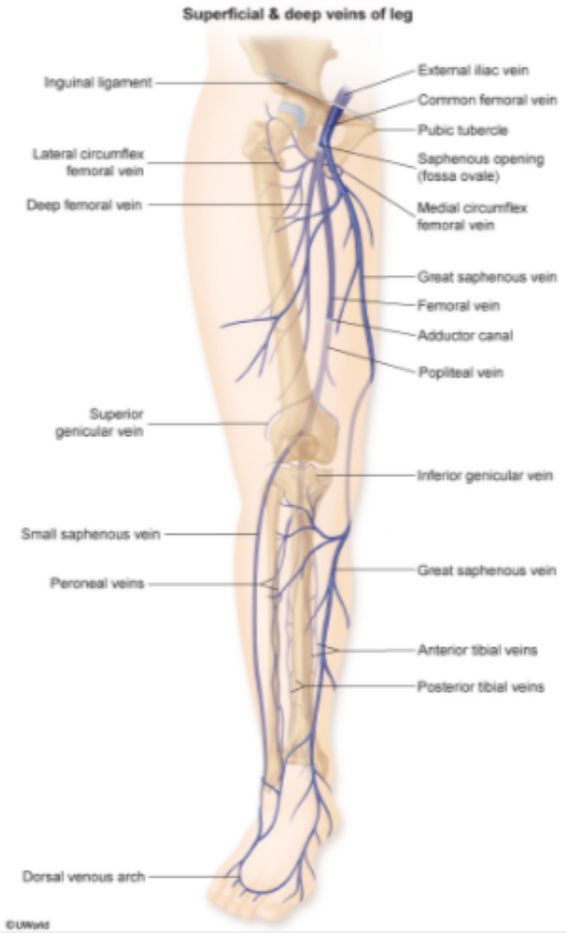

Zoom In | Zoom Out | Reset | Add To New Card | Existing Card

1
2
3
4
5
6
7
8
9
10
11
12
13
14
15
16
17
18
19
20
21
22
23
24
25
26
27
28
29

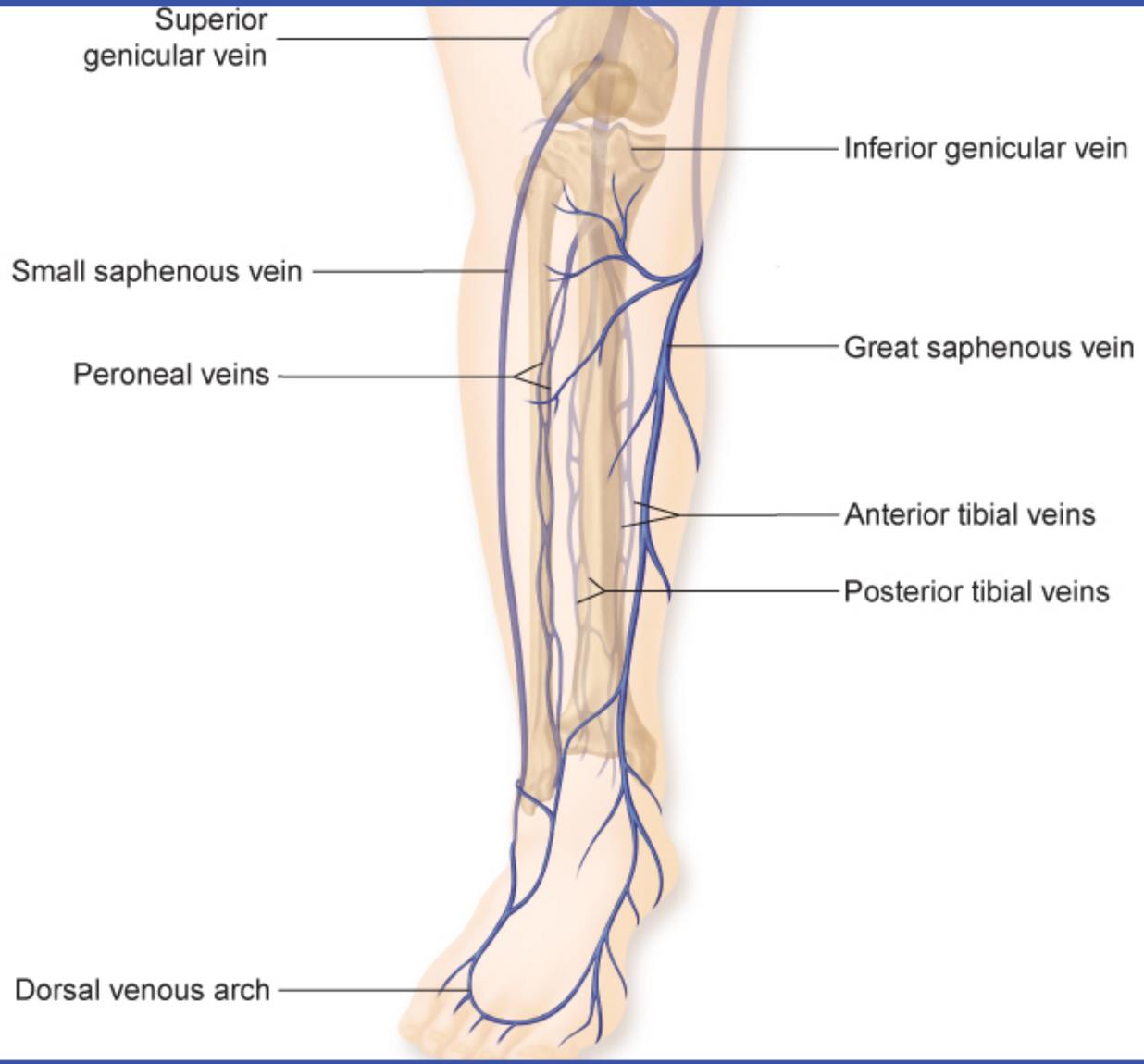

©UWorld

When the left anterior descending artery (LAD) alone is occluded by an atherosclerotic plaque, the left internal mammary (thoracic) artery is the preferred vessel for bypass grafting due to superior patency rates. However, when multiple coronary arteries or vessels other than the LAD require revascularization, great saphenous vein grafts are routinely used.

The **great saphenous vein** is located superficially in the leg and is the longest vein in the body. It courses superiorly from the medial foot, anterior to the medial malleolus, and up the medial aspect of the leg and thigh. In the proximal anterior thigh, 3-4 centimeters inferolateral to the pubic tubercle, the great saphenous vein dives deep through the cribriform fascia of the saphenous opening to join the femoral vein. Surgeons access the great saphenous vein in the medial leg or, less commonly, near its point of termination in the femoral triangle of the upper thigh. The femoral triangle is bordered by the inguinal ligament superiorly, sartorius muscle laterally, and adductor longus muscle medially.

(Choice A) The popliteal artery and vein course centrally through the popliteal fossa together with the tibial nerve. Common medical problems that occur in the popliteal fossa include popliteal artery aneurysms, which account for the majority of peripheral artery aneurysms, and synovial (Baker's) cysts, which are commonly associated with arthritis.

(Choice B) No major vessels are located immediately inferior to the anterior superior iliac spine (ASIS). The ASIS serves as the superior attachment of the inguinal ligament, and a penetrating injury to the region below the ASIS could damage the lateral cutaneous nerve of the thigh.

(Choice D) The deep circumflex iliac vessels course parallel and just superior to the inguinal ligament. The superficial and inferior epigastric veins course above the midportion of the inguinal ligament.

(Choice E) The small saphenous vein can be found at the lateral aspect of the foot. This vein courses posteriorly to drain into the popliteal vein.

Educational objective:
The great saphenous vein is a superficial vein of the leg that originates on the medial side of the foot, courses anterior to the medial malleolus, and then travels up the medial aspect of the leg and thigh. It drains into the femoral vein within the region of the femoral triangle, a few centimeters inferolateral to the pubic tubercle.

Anatomy Cardiovascular System CABG

When the left anterior descending artery (LAD) alone is occluded by an atherosclerotic plaque, the left internal mammary (thoracic) artery is the

Exhibit Display

Femoral triangle

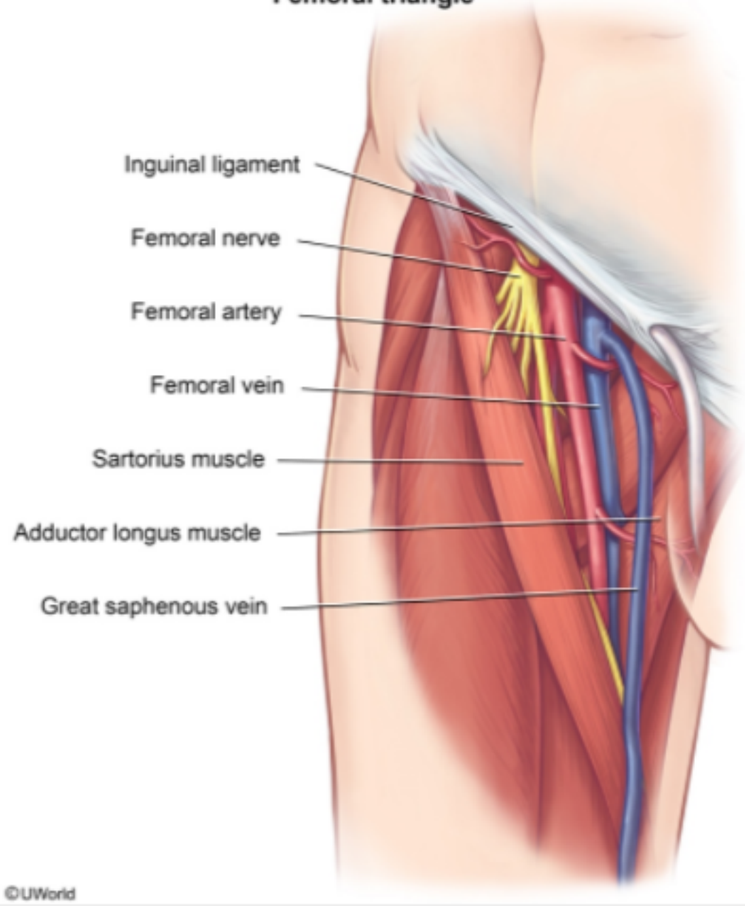

Zoom In | Zoom Out | Reset | Add To New Card | Existing Card

A 35-year-old woman comes to the office due to solid food dysphagia for the past several months. The patient has a sensation of food getting stuck in the mid-thorax, but has no pain or reflux. She also has palpitations and dyspnea on exertion. The patient immigrated to the United States from India 1 year ago, and was treated in her home country for rheumatic heart disease. Barium esophagram demonstrates extrinsic compression on the mid-esophagus. Enlargement of which of the following is most likely causing this patient's dysphagia?

A. Left atrium

B. Left ventricle

C. Pulmonary artery

D. Right atrium

E. Right ventricle

Submit

A 35-year-old woman comes to the office due to solid food dysphagia for the past several months. The patient has a sensation of food getting stuck in the mid-thorax, but has no pain or reflux. She also has palpitations and dyspnea on exertion. The patient immigrated to the United States from India 1 year ago, and was treated in her home country for rheumatic heart disease. Barium esophagram demonstrates extrinsic compression on the mid-esophagus. Enlargement of which of the following is most likely causing this patient's dysphagia?

- ✓ A. Left atrium (86%)
- B. Left ventricle (3%)
- C. Pulmonary artery (1%)
- D. Right atrium (7%)
- E. Right ventricle (1%)

Omitted
Correct answer
A

86%
Answered correctly

02 secs
Time Spent

04/13/2020
Last Updated

Explanation

1
2
3
4
5
6
7
8
9
10
11
12
13
14
15
16
17
18
19
20
21
22
23
24
25
26
27
28
29

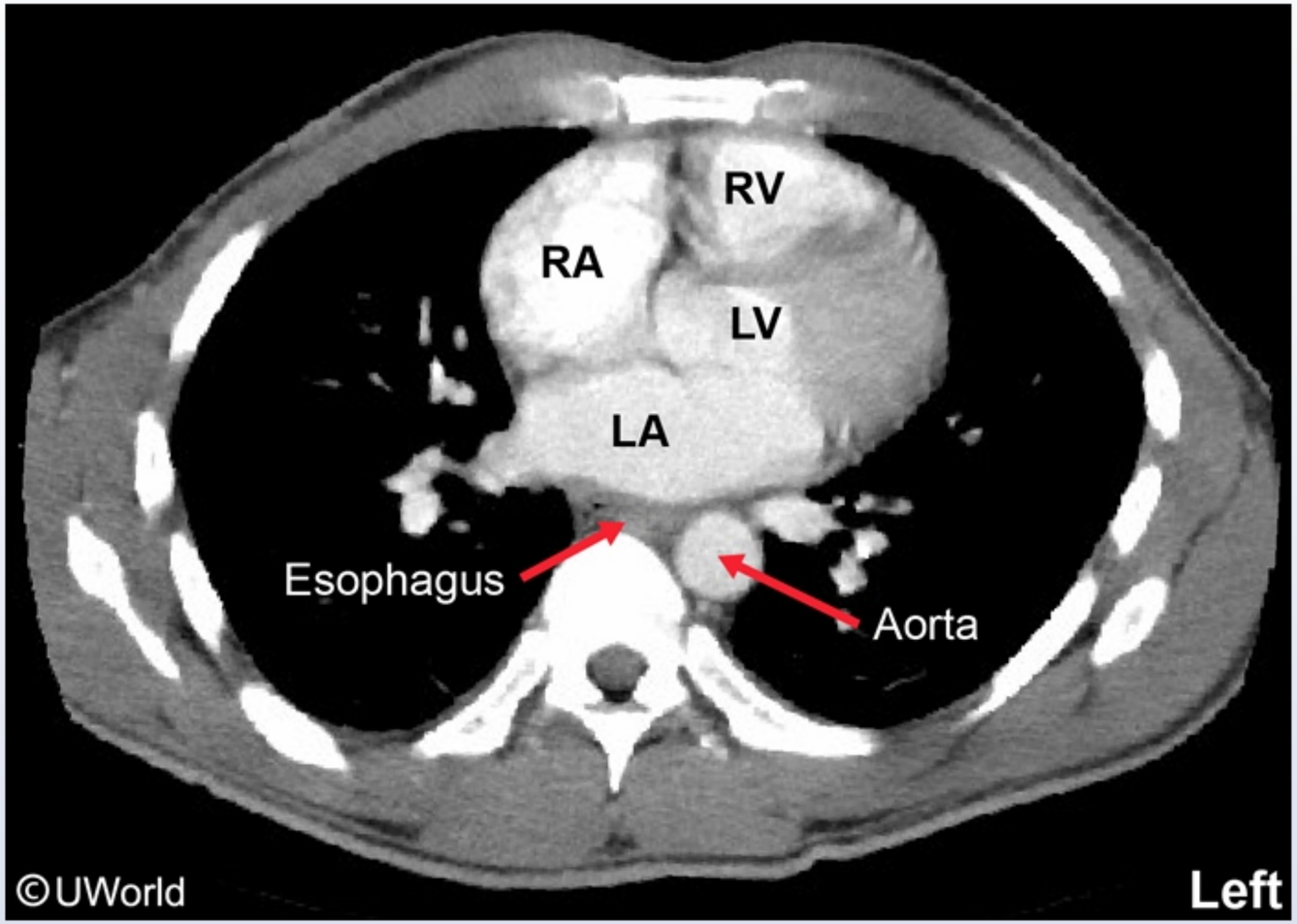

This patient with a history of **rheumatic heart disease** has likely developed mitral stenosis/regurgitation (eg, palpitations, exertional dyspnea), leading to left atrial enlargement and extrinsic compression of the esophagus (eg, solid food dysphagia).

The **posterior surface** of the heart is mostly formed by the left atrium, which lies directly over the **esophagus**. Longstanding **mitral**

This patient with a history of **rheumatic heart disease** has likely developed mitral stenosis/regurgitation (eg, palpitations, exertional dyspnea), leading to left atrial enlargement and extrinsic compression of the esophagus (eg, solid food dysphagia).

The **posterior surface** of the heart is mostly formed by the left atrium, which lies directly over the **esophagus**. Longstanding **mitral stenosis/regurgitation** can lead to progressive **left atrial enlargement**, further displacing the left atrium posteriorly and causing external compression of the mid-esophagus with dysphagia (**cardiovascular dysphagia**). On rare occasions, left atrial enlargement can also cause compression of the left recurrent laryngeal nerve, leading to voice hoarseness and chronic cough.

(Choice B) The left ventricle makes up most of the left surface of the heart, which abuts the left lung.

(Choice C) The pulmonary artery emerges from the right ventricle and branches into the right and left pulmonary arteries below the aortic arch.

(Choices D and E) The anterior (sternocostal) surface of the heart is mostly formed by the right atrium superiorly and right ventricle inferiorly. Blood from the coronary sinus and inferior and superior venae cavae drain into the right atrium, which then drains blood into the right ventricle through the tricuspid valve.

Educational objective:
Cardiovascular dysphagia can result from external compression of the esophagus by a dilated and posteriorly displaced left atrium in patients with rheumatic heart disease and mitral stenosis/regurgitation.

References

- An unusual case of dysphonia and dysphagia.

Anatomy	Cardiovascular System	Left atrial enlargement
Subject	System	Topic

Copyright © UWorld. All rights reserved.

A 78-year-old woman is hospitalized due to acute myocardial infarction. The patient had been having intermittent chest pain for 3 days and came to the hospital when the pain became unremitting. She has type 2 diabetes mellitus, but her medical follow-up has been poor. On the third day of hospitalization, the patient has sudden-onset shortness of breath due to pulmonary edema. Echocardiography confirms severe mitral regurgitation. She is taken immediately to surgery, which reveals rupture of the posteromedial papillary muscle. This patient's finding typically suggests compromised blood flow through which of the following coronary arteries?

A. Conus branch

B. Diagonal branch

C. Left anterior descending

D. Obtuse marginal

E. Posterior descending

Submit

A 78-year-old woman is hospitalized due to acute myocardial infarction. The patient had been having intermittent chest pain for 3 days and came to the hospital when the pain became unremitting. She has type 2 diabetes mellitus, but her medical follow-up has been poor. On the third day of hospitalization, the patient has sudden-onset shortness of breath due to pulmonary edema. Echocardiography confirms severe mitral regurgitation. She is taken immediately to surgery, which reveals rupture of the posteromedial papillary muscle. This patient's finding typically suggests compromised blood flow through which of the following coronary arteries?

- A. Conus branch (1%)
- B. Diagonal branch (3%)
- C. Left anterior descending (25%)
- D. Obtuse marginal (3%)
- ✓ E. Posterior descending (67%)

Omitted
Correct answer
E

67%
Answered correctly

02 secs
Time Spent

01/15/2020
Last Updated

Explanation

Right dominant coronary artery circulation

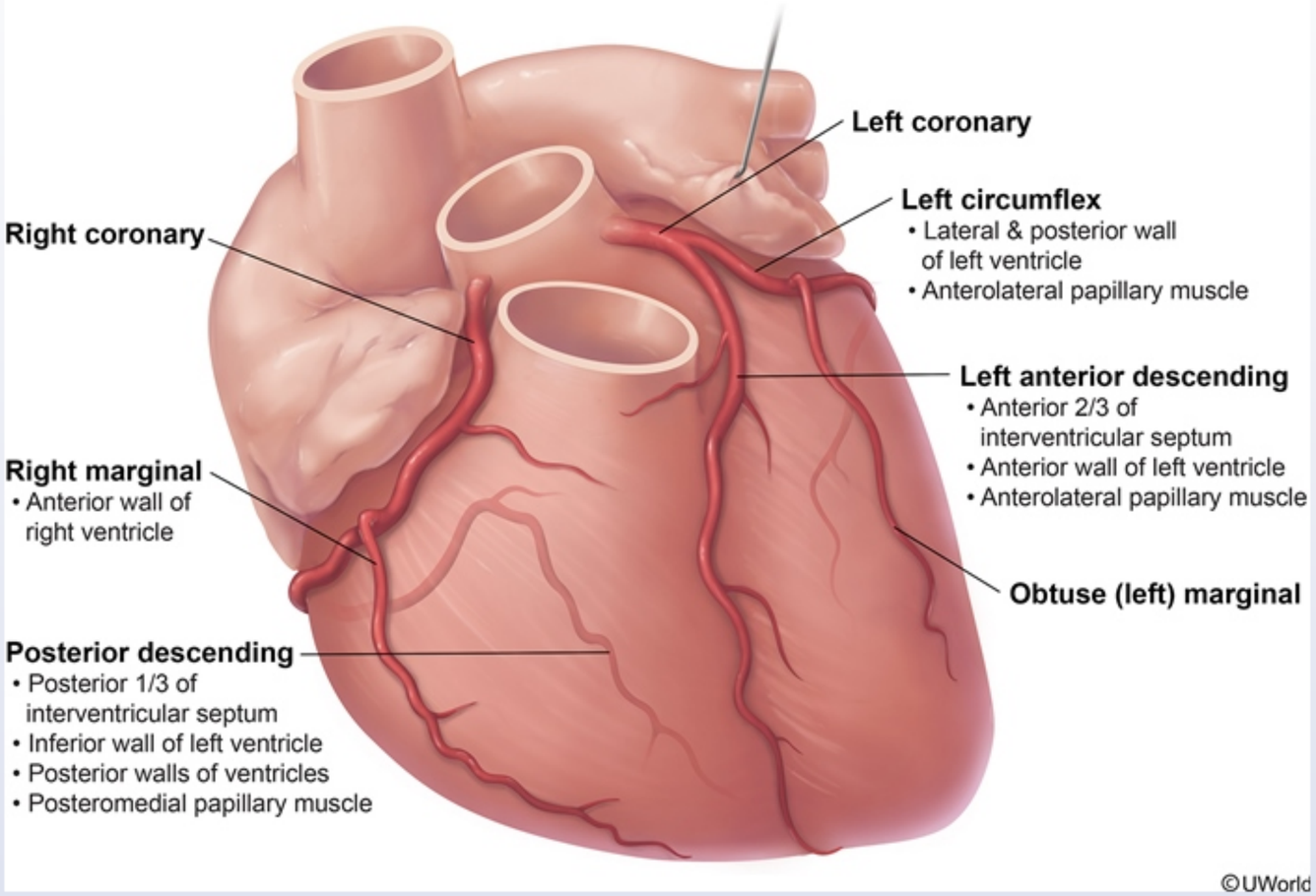

The mitral valve apparatus consists of the mitral valve annulus, anterior and posterior mitral leaflets, and chordae tendineae, which are tethered to the left ventricular wall via the anterolateral and posteromedial papillary muscles. Pathologic processes that disrupt any of these structures can lead to improper alignment of the mitral leaflets, resulting in **mitral regurgitation** and pulmonary edema.

The mitral valve apparatus consists of the mitral valve annulus, anterior and posterior mitral leaflets, and chordae tendineae, which are tethered to the left ventricular wall via the anterolateral and posteromedial papillary muscles. Pathologic processes that disrupt any of these structures can lead to improper alignment of the mitral leaflets, resulting in **mitral regurgitation** and pulmonary edema.

The patient's mitral regurgitation is the result of **papillary muscle rupture**, a life-threatening mechanical complication typically occurring **3-5 days** following acute **myocardial infarction**. The anterolateral papillary muscle has a dual blood supply from the left anterior descending (LAD) and left circumflex arteries. In contrast, the **posteromedial** papillary muscle is supplied solely by the **posterior descending artery**, a branch of the right coronary artery (right dominant circulation) or left circumflex artery (left dominant circulation). Because blood flow to the posteromedial papillary muscle depends on a single artery, it is more likely to become ischemic and rupture following myocardial infarction.

(Choice A) The conus artery is an early branch of the proximal right coronary artery; it supplies the anterior area of the interventricular septum and conus of the pulmonary artery.

(Choice B) Diagonal arteries branch from the LAD artery and supply blood to the anterolateral walls of the left ventricle.

(Choice C) The LAD artery supplies the anterior two thirds of the interventricular septum, anterior wall of the left ventricle, and anterolateral papillary muscle. Abrupt occlusion of the LAD rarely results in ischemic rupture of the anterolateral papillary muscle as this muscle also receives blood supply from the left circumflex artery.

(Choice D) The obtuse (left) marginal artery is a branch of the left circumflex artery and supplies the lateral wall of the left ventricle.

Educational objective:
Papillary muscle rupture is a life-threatening complication that typically occurs 3-5 days after myocardial infarction and presents with acute mitral regurgitation and pulmonary edema. The posteromedial papillary muscle is supplied solely by the posterior descending artery, making it susceptible to ischemic rupture.

References

- A forgotten devil; rupture of mitral valve papillary muscle.

Anatomy Cardiovascular System Myocardial infarction

The mitral valve apparatus consists of the mitral valve annulus, anterior and posterior mitral leaflets, and chordae tendineae, which are tethered to the left ventricular wall via
lead to improper alignmen

The patient's mitral regurg
following acute **myocardi**
circumflex arteries. In cor
coronary artery (right dom
muscle depends on a sing

(Choice A) The conus ar
and conus of the pulmona

(Choice B) Diagonal arte

(Choice C) The LAD arte
papillary muscle. Abrupt
blood supply from the left

(Choice D) The obtuse (l

Educational objective:
Papillary muscle rupture is
regurgitation and pulmona
susceptible to ischemic ru

References

- A forgotten devil; ruptu

Anatomy Cardiovascular System Myocardial infarction

Exhibit Display

Mechanical complications of acute myocardial infarction

Complication	Time frame	Clinical findings
Right ventricular failure	Acute	• Hypotension • Clear lungs • Kussmaul sign
Papillary muscle rupture	Acute or within 3-5 days	• Severe MR with flail leaflet • New holosystolic murmur • Severe pulmonary edema
Interventricular septal rupture	Acute or within 3-5 days	• Chest pain • New holosystolic murmur • Biventricular failure, shock • Step up in O_2 level from RA to RV
Ventricular free-wall rupture	Within 5 days or up to 2 weeks	• Chest pain • Tamponade, shock • Distant heart sounds
Left ventricular aneurysm	Within several months	• Subacute heart failure • Stable angina

MR = mitral regurgitation; **RA** = right atrium; **RV** = right ventricle.

Add To New Card | Existing Card

A 35-year-old previously healthy man is evaluated for several episodes of syncope in the past 6 weeks. Physical examination is unremarkable. Echocardiogram shows no structural heart defect. An electrophysiologic study is performed during which catheters are passed into the patient's right and left atrium to record atrial electric potentials. Cardiac monitor currently shows normal sinus rhythm. Which of the following is the most likely earliest site of electric activation?

A. Junction of left atrium and atrial appendage

B. Left atrium near the opening of pulmonary veins

C. Right atrium near the opening of inferior vena cava

D. Right atrium near the opening of superior vena cava

E. Right atrium near the septal cusp of tricuspid valve

Submit

A 35-year-old previously healthy man is evaluated for several episodes of syncope in the past 6 weeks. Physical examination is unremarkable. Echocardiogram shows no structural heart defect. An electrophysiologic study is performed during which catheters are passed into the patient's right and left atrium to record atrial electric potentials. Cardiac monitor currently shows normal sinus rhythm. Which of the following is the most likely earliest site of electric activation?

- A. Junction of left atrium and atrial appendage (2%)
- B. Left atrium near the opening of pulmonary veins (2%)
- C. Right atrium near the opening of inferior vena cava (6%)
- ✓ D. Right atrium near the opening of superior vena cava (80%)
- E. Right atrium near the septal cusp of tricuspid valve (7%)

Omitted
Correct answer
D

80%
Answered correctly

02 secs
Time Spent

04/08/2020
Last Updated

Explanation

Normal cardiac conduction system

1
2
3
4
5
6
7
8
9
10
11
12
13
14
15
16
17
18
19
20
21
22
23
24
25
26
27
28
29

Normal cardiac conduction system

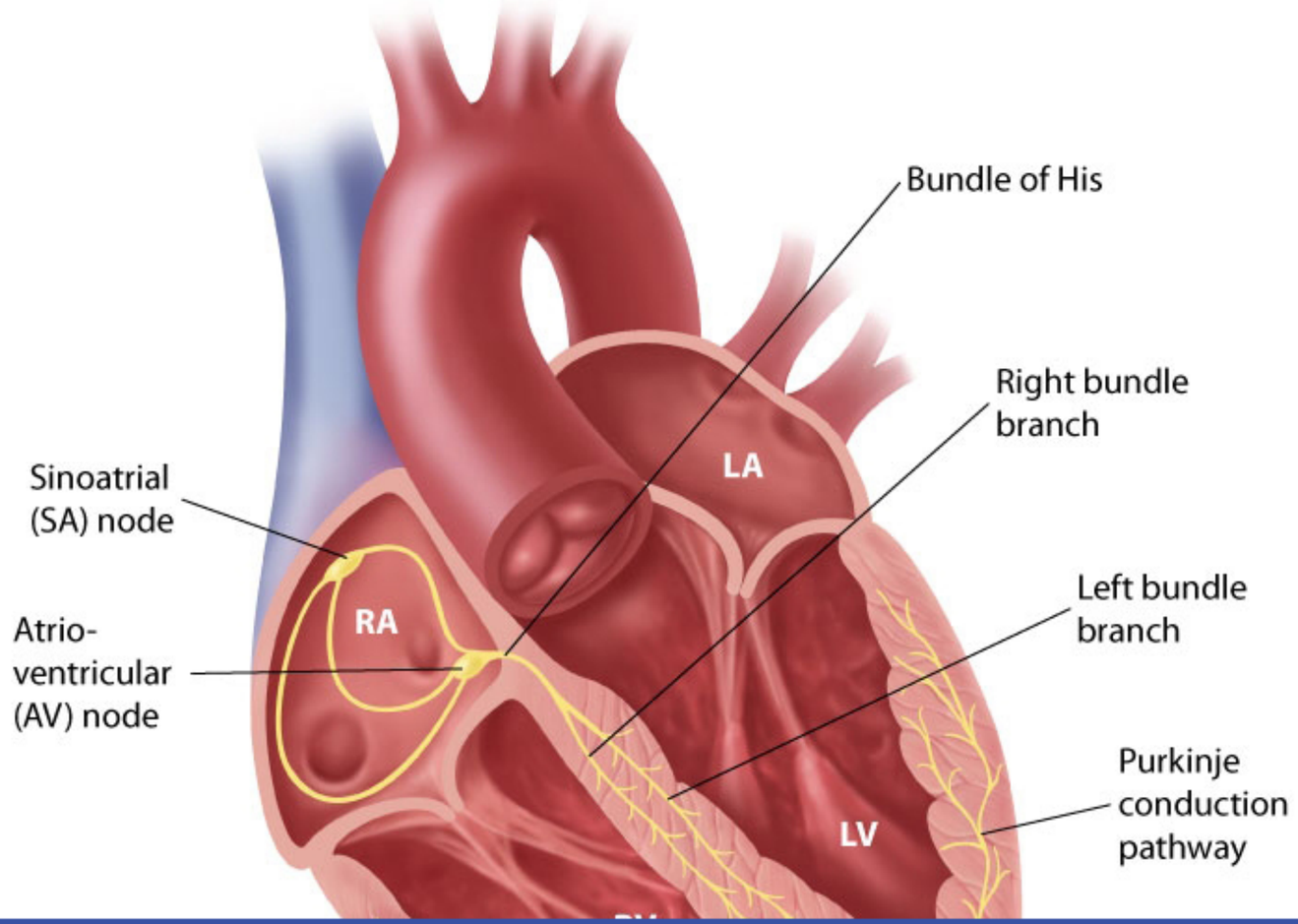

1
2
3
4
5
6
7
8
9
10
11
12
13
14
15
16
17
18
19
20
21
22
23
24
25
26
27
28
29

Exhibit Display

Normal cardiac conduction system

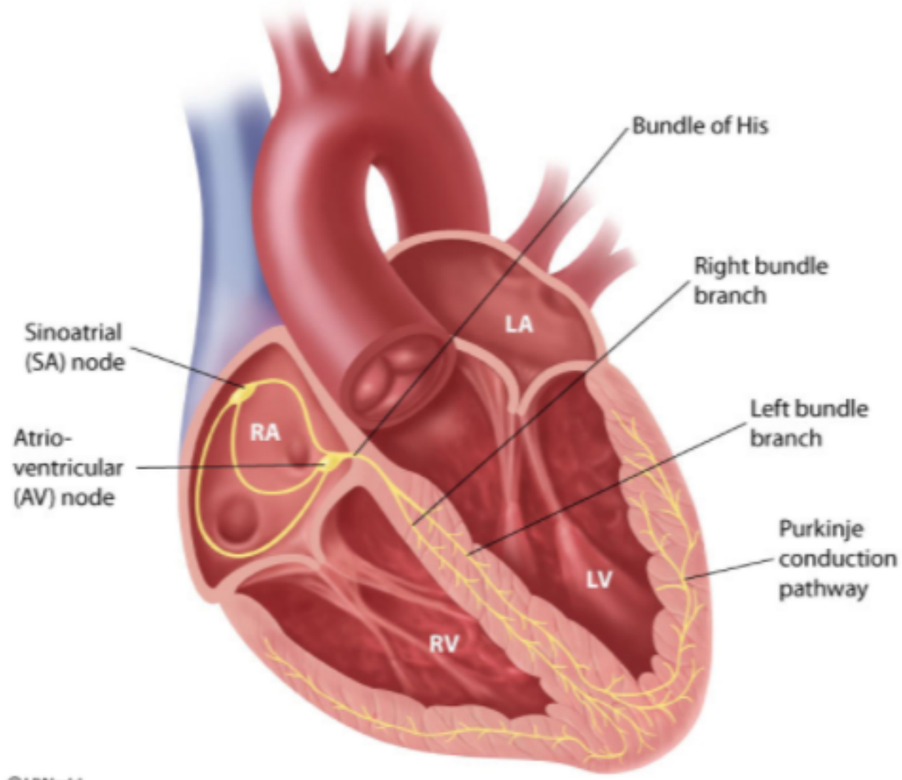

©UWorld

Zoom In | Zoom Out | Reset | Add To New Card | Existing Card

Sin
(SA

Atric
vent
(AV)

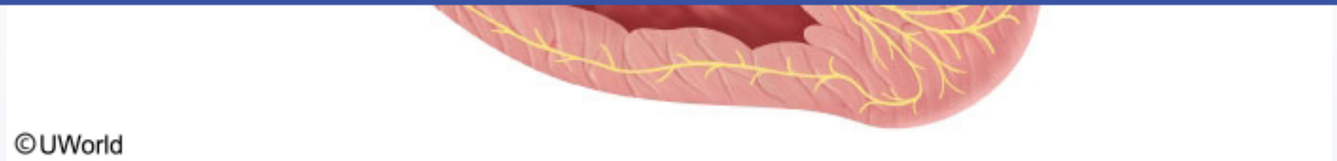

The cardiac conduction system consists of the sinoatrial (SA) node, atrioventricular (AV) node, bundle of His, right and left bundle branches, and the Purkinje system (which directly activates the ventricular myocardium). In patients **with normal sinus rhythm** (as in this patient), the **SA node** acts as the dominant pacemaker site and is the site of earliest electrical activation. The SA node is a compact subepicardial structure that consists of specialized pacemaker cells located at the **junction of the right atrium and superior vena cava**.

(Choices A and B) The SA node is located in the right, not the left, atrium. The area around the opening of the pulmonary veins in the left atrium is frequently involved in the pathogenesis of atrial fibrillation.

(Choice C) The junction of the right atrium and inferior vena cava is not a major site of electrical activity.

(Choice E) The AV node is located in the right atrium near the septal cusp of the tricuspid valve.

Educational objective:
The sinoatrial node consists of specialized pacemaker cells located at the junction of the right atrium and superior vena cava. It is the site of earliest electrical activation in patients with sinus rhythm.

References

- The sinoatrial node, a heterogeneous pacemaker structure.
- The anatomy of the cardiac conduction system.

Anatomy	Cardiovascular System	Sinoatrial node
Subject	System	Topic

Copyright © UWorld. All rights reserved.

A 72-year-old man comes to the emergency department due to left-sided weakness and speech difficulty on awakening this morning. Past medical history includes hypertension and persistent atrial fibrillation. His anticoagulant medication was stopped 6 months ago after an episode of gastrointestinal bleeding. Blood pressure is 160/90 mm Hg and pulse is 88/min and irregular. Examination shows mild dysarthria, left lower facial weakness, and left hemiparesis. CT scan of the head shows no evidence of intracranial bleeding. Transthoracic echocardiogram shows left atrial enlargement, normal left ventricular systolic function, and mild mitral regurgitation. The patient's symptoms are determined to be caused by a thromboembolic event. Which of the following is the most likely source of the thrombus?

A. Crista terminalis
B. Left atrial appendage
C. Left ventricular apex
D. Mitral valve
E. Pulmonary veins
F. Right atrial appendage
G. Sinus of Valsalva

Submit

A 72-year-old man comes to the emergency department due to left-sided weakness and speech difficulty on awakening this morning. Past medical history includes hypertension and persistent atrial fibrillation. His anticoagulant medication was stopped 6 months ago after an episode of gastrointestinal bleeding. Blood pressure is 160/90 mm Hg and pulse is 88/min and irregular. Examination shows mild dysarthria, left lower facial weakness, and left hemiparesis. CT scan of the head shows no evidence of intracranial bleeding. Transthoracic echocardiogram shows left atrial enlargement, normal left ventricular systolic function, and mild mitral regurgitation. The patient's symptoms are determined to be caused by a thromboembolic event. Which of the following is the most likely source of the thrombus?

A. Crista terminalis (1%)
✓ B. Left atrial appendage (69%)
C. Left ventricular apex (2%)
D. Mitral valve (18%)
E. Pulmonary veins (3%)
F. Right atrial appendage (3%)
G. Sinus of Valsalva (0%)

Omitted
Correct answer
B

69%
Answered correctly

01 sec
Time Spent

06/23/2020
Last Updated

Explanation

1
2
3
4
5
6
7
8
9
10
11
12
13
14
15
16
17
18
19
20
21
22
23
24
25
26
27
28
29

Atrial fibrillation with thrombus formation

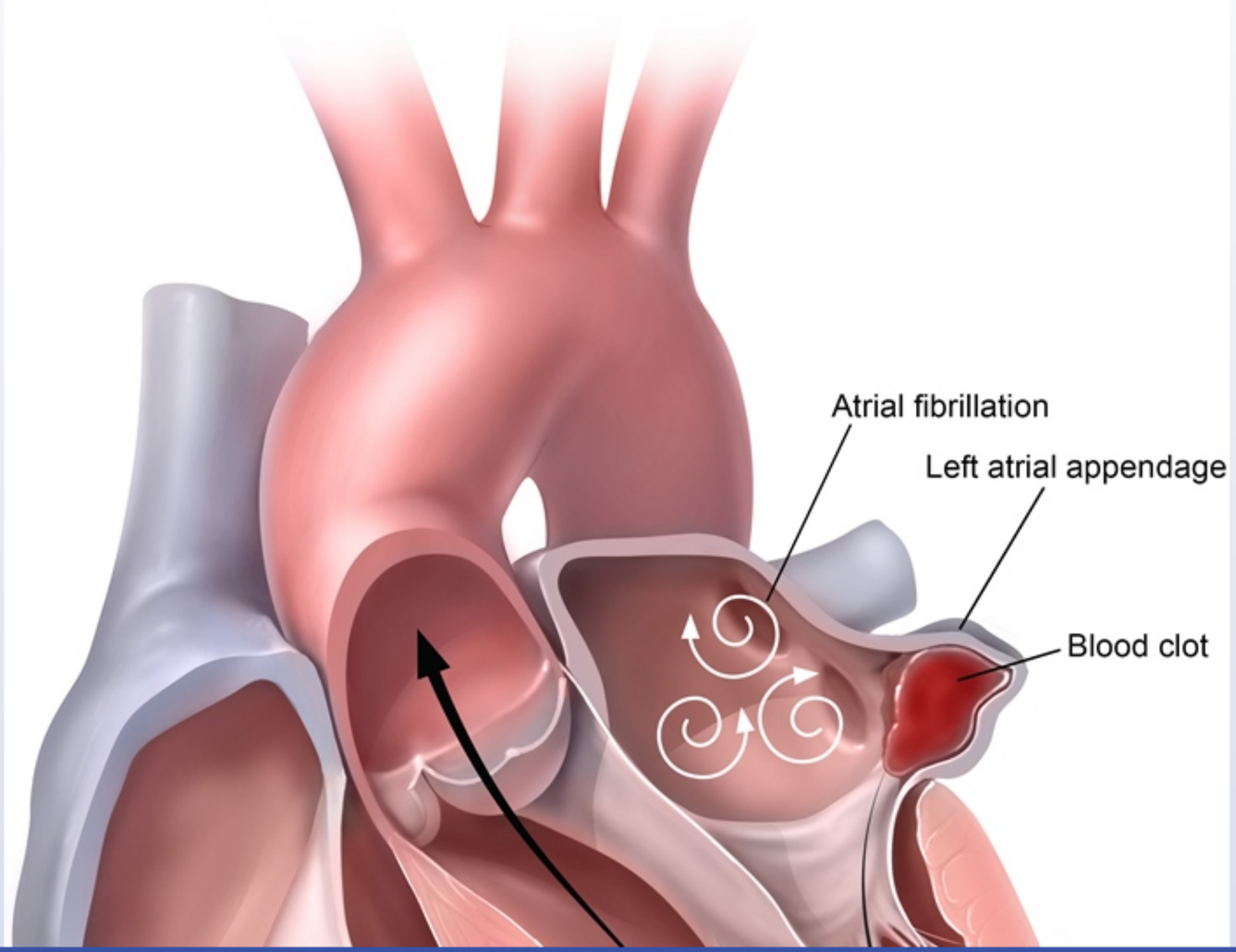

1
2
3
4
5
6
7
8
9
10
11
12
13
14
15
16
17
18
19
20
21
22
23
24
25
26
27
28
29

Exhibit Display

Atrial fibrillation with thrombus formation

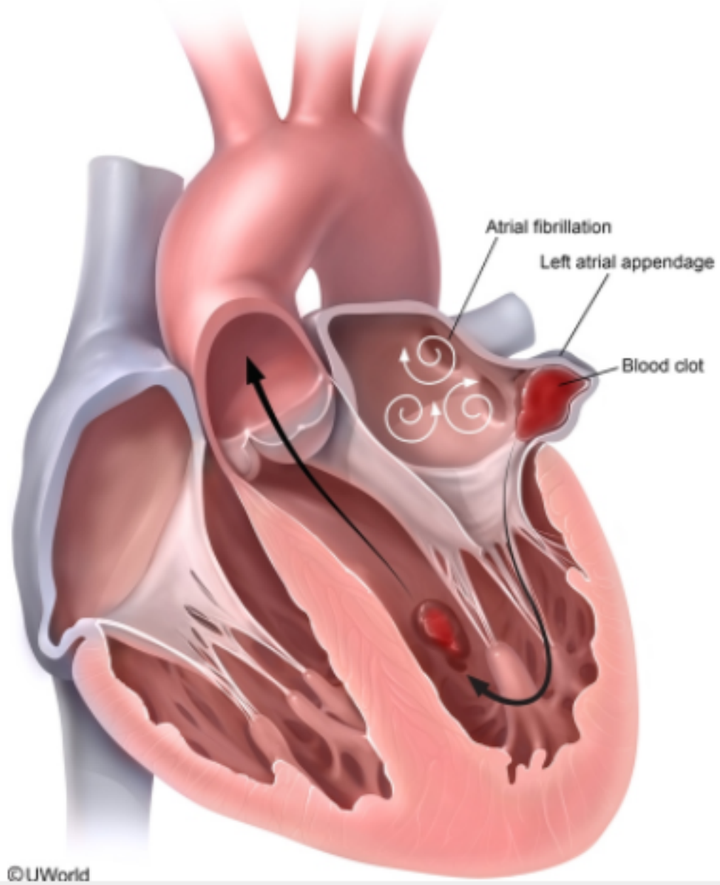

Zoom In | Zoom Out | Reset | Add To New Card | Existing Card

©UWorld

Atrial fibrillation is associated with significant risk of **systemic thromboembolism**, and long-term anticoagulation is recommended in patients at increased risk without any confounding contraindications. Several factors contribute to thrombus development in atrial fibrillation, including left atrial enlargement, stasis of blood due to ineffective atrial contraction, and atrial inflammation and fibrosis (exerts a procoagulant effect).

The **left atrial appendage** (LAA) is a small saclike structure in the left atrium that is particularly susceptible to thrombus formation. Approximately 90% of left atrial thrombi are found within the LAA in patients with nonvalvular atrial fibrillation. These clots can then systemically embolize and lead to stroke, as in this patient.

(Choice A) The crista terminalis refers to a thick band of atrial muscle that separates the smooth sinus venosus from the right atrial appendage and atrium proper. It is the site of origin of the atrial pectinate muscles and is not a significant region of thrombus formation in atrial fibrillation.

(Choice C) Left ventricular apical thrombus can develop in patients with severe generalized left ventricular systolic dysfunction or impaired regional apical wall motion in patients with prior myocardial infarction.

(Choice D) Prosthetic valve thrombosis can occur with bioprosthetic or mechanical mitral valves in patients without adequate anticoagulation. It is not seen in patients with normal mitral valves.

(Choices E and G) Thrombosis of the pulmonary veins or sinus of Valsalva (aortic sinus) is rare and not associated with atrial fibrillation.

(Choice F) Thrombus formation is theoretically possible in the right atrial appendage in patients with atrial fibrillation; however, it most likely would embolize to the pulmonary vasculature.

Educational objective:
Atrial fibrillation is associated with increased risk of systemic thromboembolism. The left atrial appendage is the most common site of thrombus formation.

References

- Left atrial appendage exclusion for stroke prevention in patients with nonrheumatic atrial fibrillation.

1
2
3
4
5
6
7
8
9
10
11
12
13
14
15
16
17
18
19
20
21
22
23
24
25
26
27
28
29

A 71-year-old man comes to the emergency department due to sudden-onset vision loss in his left eye for one hour. He has a history of coronary artery disease, hypertension, and type 2 diabetes mellitus. Blood pressure is 145/80 mm Hg and pulse is 72/min. On examination, the patient can see only hand motions through the left eye. Funduscopic evaluation of the eye shows a cherry-red spot in the macula with surrounding retinal whitening. Cranial nerve examination is otherwise unremarkable. There is a left-sided neck bruit on cardiovascular examination. Which of the following is the most likely path of the embolus causing this patient's symptoms?

A. External carotid artery, facial artery, ophthalmic artery, retinal artery

B. External carotid artery, ophthalmic artery, retinal artery

C. External carotid artery, temporal artery, retinal artery

D. Internal carotid artery, anterior cerebral artery, retinal artery

E. Internal carotid artery, ophthalmic artery, retinal artery

Submit

A 71-year-old man comes to the emergency department due to sudden-onset vision loss in his left eye for one hour. He has a history of coronary artery disease, hypertension, and type 2 diabetes mellitus. Blood pressure is 145/80 mm Hg and pulse is 72/min. On examination, the patient can see only hand motions through the left eye. Funduscopic evaluation of the eye shows a cherry-red spot in the macula with surrounding retinal whitening. Cranial nerve examination is otherwise unremarkable. There is a left-sided neck bruit on cardiovascular examination. Which of the following is the most likely path of the embolus causing this patient's symptoms?

- A. External carotid artery, facial artery, ophthalmic artery, retinal artery (7%)
- B. External carotid artery, ophthalmic artery, retinal artery (19%)
- C. External carotid artery, temporal artery, retinal artery (6%)
- D. Internal carotid artery, anterior cerebral artery, retinal artery (8%)
- ✓ E. Internal carotid artery, ophthalmic artery, retinal artery (57%)

Omitted
Correct answer
E

57%
Answered correctly

02 secs
Time Spent

06/20/2020
Last Updated

Explanation

Retinal artery occlusion (RAO) is an important cause of acute, painless, monocular vision loss. Thromboembolic complications of atherosclerosis in the **internal carotid** are the most common cause of RAO. The retinal artery is one of the first branches of the **ophthalmic artery**, which receives its supply from the internal carotid **(Choice B)**. The retinal artery then travels within the retinal nerve to supply the inner

1
2
3
4
5
6
7
8
9
10
11
12
13
14
15
16
17
18
19
20
21
22
23
24
25
26
27
28
29

Explanation

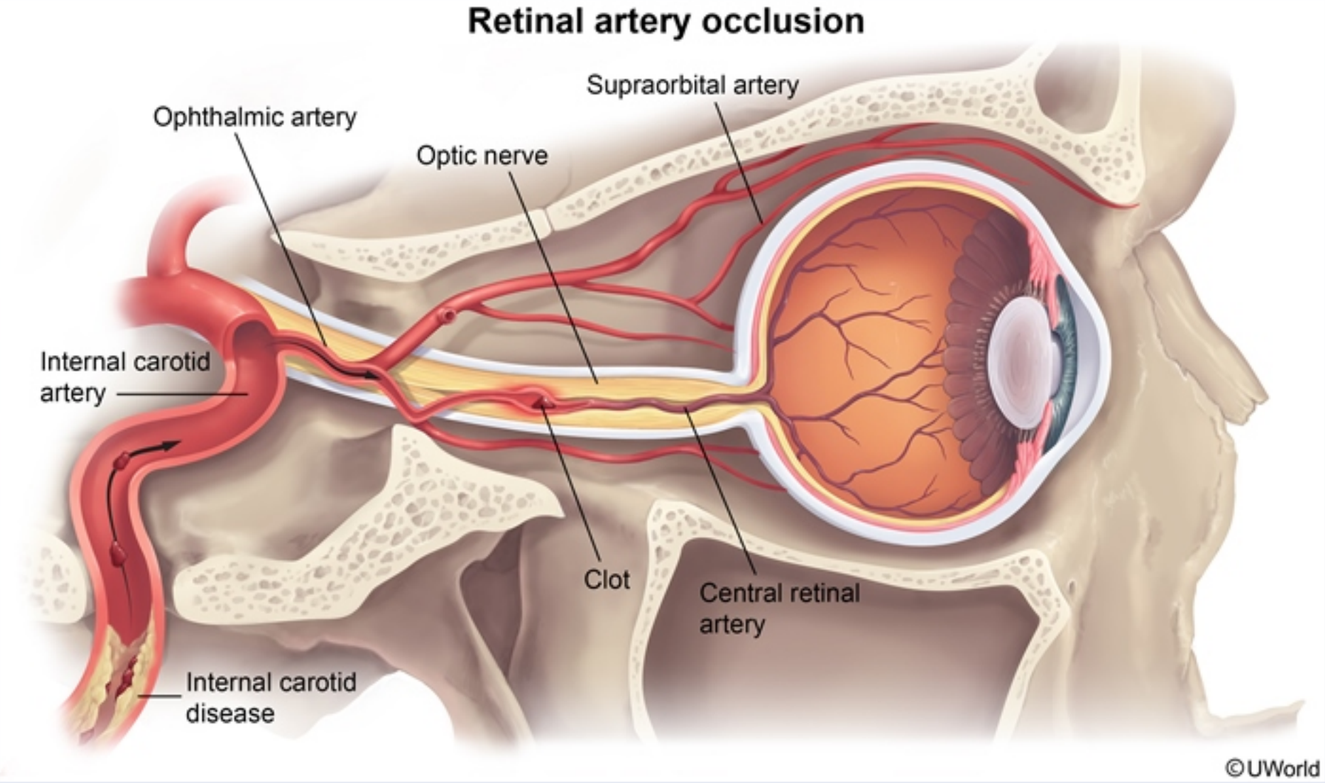

Retinal artery occlusion (RAO) is an important cause of acute, painless, monocular vision loss. Thromboembolic complications of atherosclerosis in the **internal carotid** are the most common cause of RAO. The retinal artery is one of the first branches of the **ophthalmic artery**, which receives its supply from the internal carotid **(Choice B)**. The retinal artery then travels within the retinal nerve to supply the inner retina and the surface of the optic nerve.

(Choices A and C) There are a number of anastomoses between branches of the ophthalmic artery and branches of the external carotid, including the facial artery and temporal artery, but neither branch anastomoses with the retinal artery or supplies the retina.

Retinal artery occlusion (RAO) is an important cause of acute, painless, monocular vision loss. Thromboembolic complications of atherosclerosis in the **internal carotid** are the most common cause of RAO. The retinal artery is one of the first branches of the **ophthalmic artery**, which receives its supply from the internal carotid **(Choice B)**. The retinal artery then travels within the retinal nerve to supply the inner retina and the surface of the optic nerve.

(Choices A and C) There are a number of anastomoses between branches of the ophthalmic artery and branches of the external carotid, including the facial artery and temporal artery, but neither branch anastomoses with the retinal artery or supplies the retina.

(Choice D) The anterior cerebral artery is a branch off the circle of Willis that supplies blood to the midline portions of the frontal and superior medial parietal lobes. Its occlusion can lead to loss of strength and sensation in the contralateral lower extremity, incontinence, and transcortical motor aphasia.

Educational objective:
Retinal artery occlusion is a cause of acute, painless, monocular vision loss. It is usually caused by thromboembolic complications of atherosclerosis traveling from the internal carotid artery and through the ophthalmic artery.

References

- Orbital vascular anatomy.
- Ocular ischemic syndrome - a systematic review.

Anatomy	Cardiovascular System	Retinal artery occlusion
Subject	System	Topic

Copyright © UWorld. All rights reserved.

1
2
3
4
5
6
7
8
9
10
11
12
13
14
15
16
17
18
19
20
21
22
23
24
25
26
27
28
29

Internal carotid

Exhibit Display

Zoom In | Zoom Out | Reset | Add To New Card | Existing Card

1
2
3
4
5
6
7
8
9
10
11
12
13
14
15
16
17
18
19
20
21
22
23
24
25
26
27
28
29

Exhibit Display

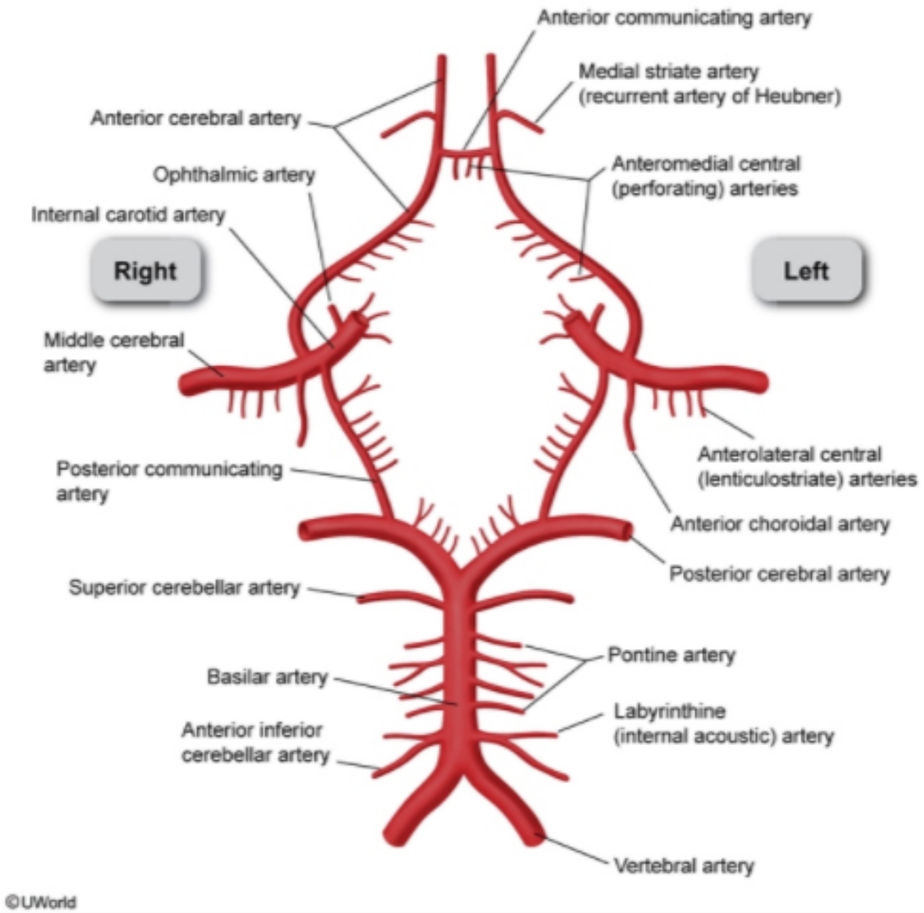

Zoom In | Zoom Out | Reset | Add To New Card | Existing Card

1
2
3
4
5
6
7
8
9
10
11
12
13
14
15
16
17
18
19
20
21
22
23
24
25
26
27
28
29

A 64-year-old man with type 2 diabetes mellitus is evaluated in the clinic due to occasional dizziness. His symptoms usually occur while playing table tennis. The patient has not had any falls or loss of consciousness. He has no known history of coronary artery disease or stroke. The patient has smoked a pack of cigarettes daily for the past 40 years and occasionally drinks alcohol. Orthostatic vital signs are normal. ECG shows normal sinus rhythm. Doppler ultrasound evaluation of the left vertebral artery reveals retrograde (caudal) flow instead of normal antegrade flow. Which of the following arteries is most likely to be occluded based on these ultrasound findings?

A. Innominate artery
B. Left internal carotid
C. Left internal mammary
D. Left subclavian
E. Right vertebral

Submit

A 64-year-old man with type 2 diabetes mellitus is evaluated in the clinic due to occasional dizziness. His symptoms usually occur while playing table tennis. The patient has not had any falls or loss of consciousness. He has no known history of coronary artery disease or stroke. The patient has smoked a pack of cigarettes daily for the past 40 years and occasionally drinks alcohol. Orthostatic vital signs are normal. ECG shows normal sinus rhythm. Doppler ultrasound evaluation of the left vertebral artery reveals retrograde (caudal) flow instead of normal antegrade flow. Which of the following arteries is most likely to be occluded based on these ultrasound findings?

- A. Innominate artery (10%)
- B. Left internal carotid (33%)
- C. Left internal mammary (6%)
- ✓ D. Left subclavian (40%)
- E. Right vertebral (8%)

Omitted
Correct answer
D

40%
Answered correctly

02 secs
Time Spent

05/20/2020
Last Updated

Explanation

Subclavian steal

1
2
3
4
5
6
7
8
9
10
11
12
13
14
15
16
17
18
19
20
21
22
23
24
25
26
27
28
29

Subclavian steal

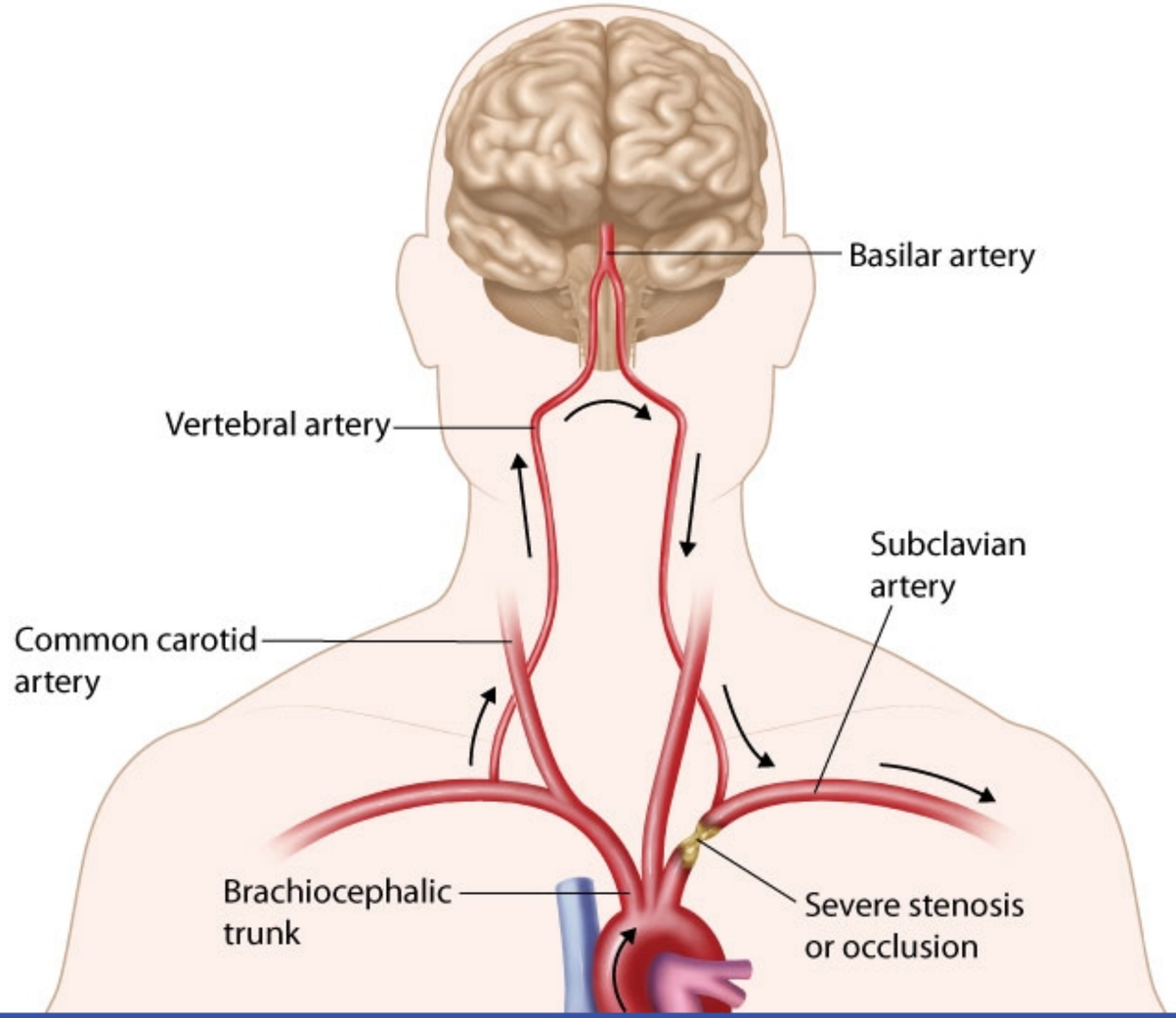

1
2
3
4
5
6
7
8
9
10
11
12
13
14
15
16
17
18
19
20
21
22
23
24
25
26
27
28
29

Exhibit Display

Subclavian steal

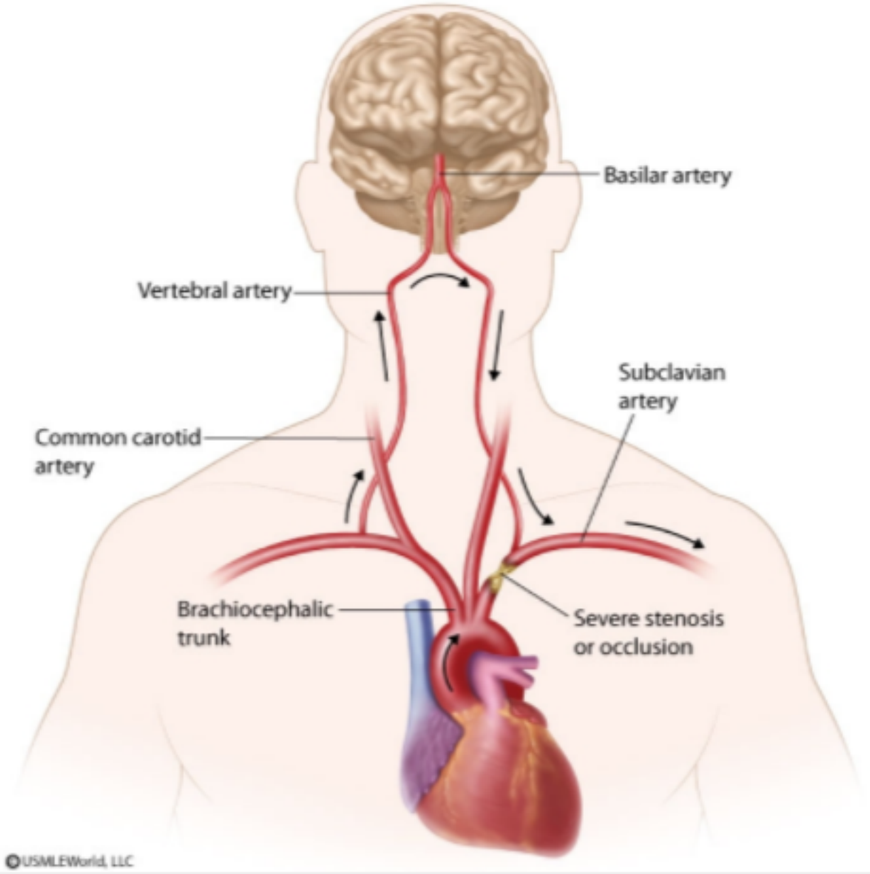

Zoom In | Zoom Out | Reset | Add To New Card | Existing Card

This patient's presentation is consistent with **subclavian steal syndrome**, which typically occurs due to hemodynamically significant stenosis of the subclavian artery proximal to the origin of the vertebral artery. **Subclavian stenosis** is typically caused by atherosclerosis, although less common etiologies include Takayasu arteritis and complications from heart surgery (eg, aortic coarctation repair). The lowered distal subclavian arterial pressure leads to reversal in blood flow ("steal") from the contralateral vertebral artery to the ipsilateral vertebral artery, away from the brainstem.

Most patients with subclavian artery stenosis are asymptomatic. When symptoms occur, they are typically related to **arm ischemia** in the affected extremity (eg, exercise-induced fatigue, pain, paresthesias) or **vertebrobasilar insufficiency** (eg, dizziness, vertigo, drop attacks). Physical examination can show a significant difference (>15 mm Hg) in brachial systolic blood pressure between the affected arm and normal arm. Doppler ultrasound of the cerebrovascular and upper extremity arterial circulation establishes the diagnosis in most patients.

(Choice A) Although innominate (brachiocephalic) artery stenosis or occlusion can cause subclavian steal syndrome, patients with significant occlusion would develop retrograde flow through the right vertebral artery rather than the left.

(Choice B) Internal carotid artery occlusion may occur due to thrombosis or embolism, leading to a transient ischemic attack (TIA) or ischemic stroke. Patients typically have profound neurologic deficits (eg, contralateral homonymous hemianopsia, hemiparesis, hemisensory loss), including cortical signs (eg, aphasia, agnosia, neglect). Blood flow reversal in the vertebral artery is not characteristic.

(Choice C) Coronary-subclavian steal phenomenon occurs in patients with prior coronary artery bypass surgery using the internal mammary artery (IMA). Similar to that of subclavian steal syndrome, blood flow through the IMA can reverse and steal flow from the coronary circulation during increased demand (eg, upper extremity exercise). However, symptoms are typically related to coronary ischemia (eg, angina pectoris).

(Choice E) Right vertebral artery occlusion usually leads to ischemic stroke or TIA and can cause similar symptoms as seen in this patient. However, occlusion of the right vertebral artery would cause retrograde flow on the right versus the left, and symptoms are not typically precipitated by arm exertion.

Educational objective:
Subclavian steal syndrome occurs due to severe stenosis of the proximal subclavian artery, which leads to reversal in blood flow from the contralateral vertebral artery to the ipsilateral vertebral artery. Patients may have symptoms related to arm ischemia in the affected extremity (eg, exercise-induced fatigue, pain, paresthesias) or vertebrobasilar insufficiency (eg, dizziness, vertigo).

ultrasound of the cerebrovascular and upper extremity arterial circulation establishes the diagnosis in most patients.

(Choice A) Although innominate (brachiocephalic) artery stenosis or occlusion can cause subclavian steal syndrome, patients with significant occlusion would develop retrograde flow through the right vertebral artery rather than the left.

(Choice B) Internal carotid artery occlusion may occur due to thrombosis or embolism, leading to a transient ischemic attack (TIA) or ischemic stroke. Patients typically have profound neurologic deficits (eg, contralateral homonymous hemianopsia, hemiparesis, hemisensory loss), including cortical signs (eg, aphasia, agnosia, neglect). Blood flow reversal in the vertebral artery is not characteristic.

(Choice C) Coronary-subclavian steal phenomenon occurs in patients with prior coronary artery bypass surgery using the internal mammary artery (IMA). Similar to that of subclavian steal syndrome, blood flow through the IMA can reverse and steal flow from the coronary circulation during increased demand (eg, upper extremity exercise). However, symptoms are typically related to coronary ischemia (eg, angina pectoris).

(Choice E) Right vertebral artery occlusion usually leads to ischemic stroke or TIA and can cause similar symptoms as seen in this patient. However, occlusion of the right vertebral artery would cause retrograde flow on the right versus the left, and symptoms are not typically precipitated by arm exertion.

Educational objective:
Subclavian steal syndrome occurs due to severe stenosis of the proximal subclavian artery, which leads to reversal in blood flow from the contralateral vertebral artery to the ipsilateral vertebral artery. Patients may have symptoms related to arm ischemia in the affected extremity (eg, exercise-induced fatigue, pain, paresthesias) or vertebrobasilar insufficiency (eg, dizziness, vertigo).

References

- A review of subclavian steal syndrome with clinical correlation.

Anatomy	Cardiovascular System	Subclavian steal syndrome
Subject	System	Topic

Copyright © UWorld. All rights reserved.

1
2
3
4
5
6
7
8
9
10
11
12
13
14
15
16
17
18
19
20
21
22
23
24
25
26
27
28
29

A 4-year-old boy is being evaluated for failure to thrive, shortness of breath, and exercise intolerance. The parents first became aware of his symptoms after the patient started preschool a few weeks ago. His teacher mentioned that the patient seemed to tire faster than the other children when playing outside. Cardiac examination shows bounding peripheral pulses and a palpable thrill below the clavicle near the left upper sternal border. On auscultation, a continuous murmur is best heard over the same region. After discussion with the parents, a thoracotomy is scheduled to correct the patient's condition. During the procedure, the surgeon should plan on ligating a derivative of which of the following embryologic structures?

A. Bulbus cordis
B. Fourth aortic arch
C. Primitive atria
D. Sinus venosus
E. Sixth aortic arch

Submit

A 4-year-old boy is being evaluated for failure to thrive, shortness of breath, and exercise intolerance. The parents first became aware of his symptoms after the patient started preschool a few weeks ago. His teacher mentioned that the patient seemed to tire faster than the other children when playing outside. Cardiac examination shows bounding peripheral pulses and a palpable thrill below the clavicle near the left upper sternal border. On auscultation, a continuous murmur is best heard over the same region. After discussion with the parents, a thoracotomy is scheduled to correct the patient's condition. During the procedure, the surgeon should plan on ligating a derivative of which of the following embryologic structures?

A. Bulbus cordis (10%)

B. Fourth aortic arch (28%)

C. Primitive atria (5%)

D. Sinus venosus (10%)

✓ E. Sixth aortic arch (45%)

Omitted
Correct answer
E

45%
Answered correctly

02 secs
Time Spent

06/13/2020
Last Updated

Explanation

Aortic arch vascular derivatives	
Aortic arch	Adult derivative

Aortic arch vascular derivatives	
Aortic arch	**Adult derivative**
First	• Part of maxillary artery
Second	• Hyoid artery • Stapedial artery
Third	• Common carotid artery • Proximal internal carotid artery
Fourth	• On left → aortic arch • On right → proximal right subclavian artery
Sixth	• Proximal pulmonary arteries • On left → ductus arteriosus

This patient most likely has a **patent ductus arteriosus (PDA)**. The ductus arteriosus is an embryonic derivative of the **sixth aortic arch** that allows fetal blood to pass directly from the pulmonary artery to the proximal descending aorta (bypassing the pulmonary circulation). This vessel usually closes shortly after birth, secondary to decreased prostaglandin E_2 (PGE_2) levels and increased oxygen concentration. Patency of the ductus after birth results in a **left-to-right shunt** that can cause left ventricular volume overload and symptoms of **heart failure** (eg, failure to thrive, respiratory distress). Physical examination will show a **continuous "machinery-like" murmur** and palpable thrill over the **left infraclavicular region** due to turbulent blood flow through the PDA.

Pharmacologic closure of a PDA can be achieved by **PGE_2 synthesis inhibitors** (eg, indomethacin) in premature infants. However, older patients usually require **surgical ligation** or percutaneous PDA occlusion.

(Choice A) The bulbus cordis forms the beginning of the ventricular outflow tract in the embryonic heart. This structure forms the smooth portions

This patient most likely has a **patent ductus arteriosus (PDA)**. The ductus arteriosus is an embryonic derivative of the **sixth aortic arch** that allows fetal blood to pass directly from the pulmonary artery to the proximal descending aorta (bypassing the pulmonary circulation). This vessel usually closes shortly after birth, secondary to decreased prostaglandin E_2 (PGE_2) levels and increased oxygen concentration. Patency of the ductus after birth results in a **left-to-right shunt** that can cause left ventricular volume overload and symptoms of **heart failure** (eg, failure to thrive, respiratory distress). Physical examination will show a **continuous "machinery-like" murmur** and palpable thrill over the **left infraclavicular region** due to turbulent blood flow through the PDA.

Pharmacologic closure of a PDA can be achieved by **PGE_2 synthesis inhibitors** (eg, indomethacin) in premature infants. However, older patients usually require **surgical ligation** or percutaneous PDA occlusion.

(Choice A) The bulbus cordis forms the beginning of the ventricular outflow tract in the embryonic heart. This structure forms the smooth portions of the left and right ventricles adjacent to the aorta and pulmonary artery, respectively.

(Choice B) The fourth aortic arch on the left forms the arch of the aorta between the left carotid artery and ductus arteriosus. Abnormalities during development can result in coarctation (narrowing) of the aorta, which can present with continuous murmurs over the back due to collateral formation.

(Choice C) The primitive atrium receives blood from the sinus venosus in the embryonic heart and transmits it to the primitive ventricle. The primitive atrium forms the rough portions of the left and right atria.

(Choice D) The sinus venosus is an embryologic structure within the heart that receives blood from the vena cava. In adults, this structure forms the smooth portion of the right atrium, known as the sinus venarum.

Educational objective:
The ductus arteriosus is derived from the sixth embryonic aortic arch. A patent ductus arteriosus (PDA) causes left-to-right shunting of blood that can be heard as a continuous murmur over the left infraclavicular region. Indomethacin (a PGE_2 synthesis inhibitor) can be used to close a PDA in premature infants, but surgical ligation is often necessary in older patients.

Anatomy Cardiovascular System Patent ductus arteriosus

ductus after birth results in a **left-to-right shunt** that can cause left ventricular volume overload and symptoms of **heart failure** (eg, failure to thrive, respiratory distress). Physical examination will show a **continuous "machinery-like" murmur** and palpable thrill over the **left infraclavicular region** due to turbulent blood flow through the PDA.

Pharmacologic closure of a PDA can be achieved by **PGE_2 synthesis inhibitors** (eg, indomethacin) in premature infants. However, older patients usually require **surgical ligation** or percutaneous PDA occlusion.

(Choice A) The bulbus cordis forms the beginning of the ventricular outflow tract in the embryonic heart. This structure forms the smooth portions of the left and right ventricles adjacent to the aorta and pulmonary artery, respectively.

(Choice B) The fourth aortic arch on the left forms the arch of the aorta between the left carotid artery and ductus arteriosus. Abnormalities during development can result in coarctation (narrowing) of the aorta, which can present with continuous murmurs over the back due to collateral formation.

(Choice C) The primitive atrium receives blood from the sinus venosus in the embryonic heart and transmits it to the primitive ventricle. The primitive atrium forms the rough portions of the left and right atria.

(Choice D) The sinus venosus is an embryologic structure within the heart that receives blood from the vena cava. In adults, this structure forms the smooth portion of the right atrium, known as the sinus venarum.

Educational objective:
The ductus arteriosus is derived from the sixth embryonic aortic arch. A patent ductus arteriosus (PDA) causes left-to-right shunting of blood that can be heard as a continuous murmur over the left infraclavicular region. Indomethacin (a PGE_2 synthesis inhibitor) can be used to close a PDA in premature infants, but surgical ligation is often necessary in older patients.

Anatomy	Cardiovascular System	Patent ductus arteriosus
Subject	System	Topic

Copyright © UWorld. All rights reserved.

A 66-year-old man comes to the hospital due to sudden-onset chest pain and dyspnea. The patient has a history of asthma and gastroesophageal reflux disease but says his current symptoms feel different than what he usually experiences. An ECG is consistent with ST-elevation myocardial infarction, and an emergent cardiac catheterization is performed. Evaluation of the left and right coronary arteries reveals left-dominant circulation. A stenotic region is identified in one of the coronary vessels just before the origin of the artery supplying the atrioventricular node. Which of the following arteries is most likely affected?

A. Anterior interventricular artery
B. Left circumflex artery
C. Left diagonal artery
D. Right coronary artery
E. Right marginal artery

Submit

A 66-year-old man comes to the hospital due to sudden-onset chest pain and dyspnea. The patient has a history of asthma and gastroesophageal reflux disease but says his current symptoms feel different than what he usually experiences. An ECG is consistent with ST-elevation myocardial infarction, and an emergent cardiac catheterization is performed. Evaluation of the left and right coronary arteries reveals left-dominant circulation. A stenotic region is identified in one of the coronary vessels just before the origin of the artery supplying the atrioventricular node. Which of the following arteries is most likely affected?

- A. Anterior interventricular artery (6%)
- ✓ B. Left circumflex artery (55%)
- C. Left diagonal artery (2%)
- D. Right coronary artery (30%)
- E. Right marginal artery (4%)

Omitted
Correct answer
B

55%
Answered correctly

01 sec
Time Spent

02/10/2020
Last Updated

Explanation

Left dominant circulation: posterior view

Sinoatrial (SA)
nodal branch

Left dominant circulation: posterior view

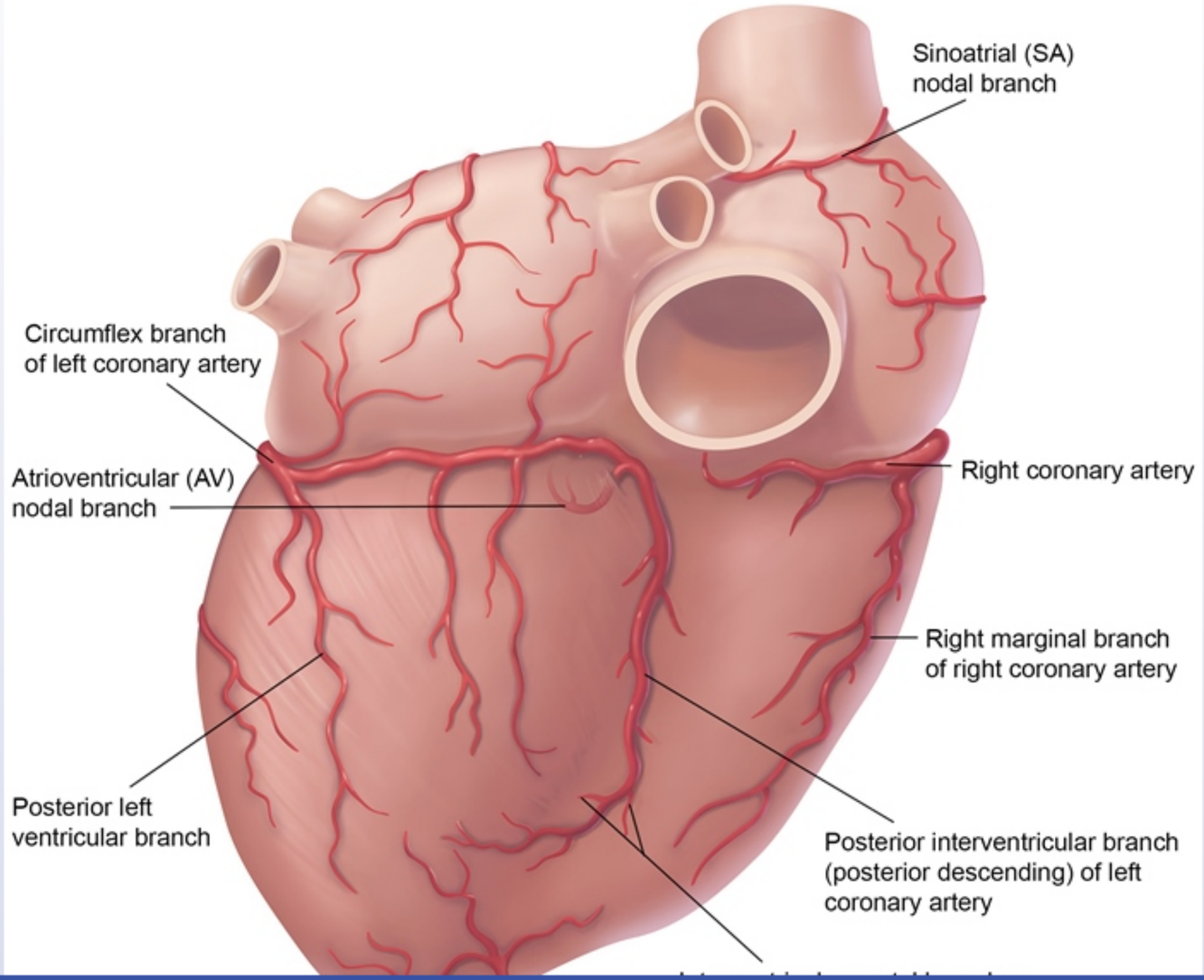

Coronary dominance is determined by the coronary artery that supplies blood to the **posterior descending artery** (PDA [or posterior interventricular artery]). The PDA originates from one of the following:

- Right coronary artery in approximately 70%-80% of the population (right dominant)
- Left circumflex artery in approximately 5%-10% of the population (**left dominant**)
- Both right coronary and left circumflex artery in 10%-20% of the population (codominant)

The atrioventricular **(AV) nodal artery** most often **arises** from the **dominant coronary artery**. This patient has left-dominant coronary circulation; therefore, his atherosclerotic lesion is most likely in the **left circumflex artery**. Involvement of the AV nodal artery during myocardial infarction can cause varying degrees of AV block.

(Choice A) The left anterior descending artery travels in the anterior interventricular groove and supplies the anterior part of the septum and the anterior wall of the left ventricle. It does not supply the AV node.

(Choice C) The diagonal arteries arise from the left anterior descending artery and supply the anterolateral wall of the left ventricle.

(Choice D) The right coronary artery gives rise to the AV nodal artery in patients with right-dominant or codominant circulation. This patient has left-dominant circulation, so the AV node is most likely supplied by the left circumflex artery.

(Choice E) The right marginal arteries arise from the right coronary artery and supply blood to the free wall of the right ventricle.

Educational objective:
Coronary dominance is determined by the coronary artery supplying the posterior descending artery. The posterior descending artery originates from the right coronary artery in approximately 70%-80% of patients (right dominant), both the right coronary and left circumflex artery in 10%-20% (codominant), and the left circumflex artery in 5%-10% (left dominant). The dominant coronary artery supplies blood to the atrioventricular (AV) node via the AV nodal artery.

References

- Anatomical aspects of the arterial blood supply to the sinoatrial and atrioventricular nodes of the human heart.

interventricular artery]). The PDA originates from one of the following:

- Right coronary artery in approximately 70%-80% of the population (right dominant)
- Left circumflex artery in approximately 5%-10% of the population (**left dominant**)
- Both right coronary and left circumflex artery in 10%-20% of the population (codominant)

The atrioventricular **(AV) nodal artery** most often **arises** from the **dominant coronary artery**. This patient has left-dominant coronary circulation; therefore, his atherosclerotic lesion is most likely in the **left circumflex artery**. Involvement of the AV nodal artery during myocardial infarction can cause varying degrees of AV block.

(Choice A) The left anterior descending artery travels in the anterior interventricular groove and supplies the anterior part of the septum and the anterior wall of the left ventricle. It does not supply the AV node.

(Choice C) The diagonal arteries arise from the left anterior descending artery and supply the anterolateral wall of the left ventricle.

(Choice D) The right coronary artery gives rise to the AV nodal artery in patients with right-dominant or codominant circulation. This patient has left-dominant circulation, so the AV node is most likely supplied by the left circumflex artery.

(Choice E) The right marginal arteries arise from the right coronary artery and supply blood to the free wall of the right ventricle.

Educational objective:
Coronary dominance is determined by the coronary artery supplying the posterior descending artery. The posterior descending artery originates from the right coronary artery in approximately 70%-80% of patients (right dominant), both the right coronary and left circumflex artery in 10%-20% (codominant), and the left circumflex artery in 5%-10% (left dominant). The dominant coronary artery supplies blood to the atrioventricular (AV) node via the AV nodal artery.

References

- Anatomical aspects of the arterial blood supply to the sinoatrial and atrioventricular nodes of the human heart.

Anatomy	Cardiovascular System	Coronary blood flow
Subject	System	Topic

interventricular artery]). The PDA originates from one of the following:

Exhibit Display

Right dominant circulation: posterior view

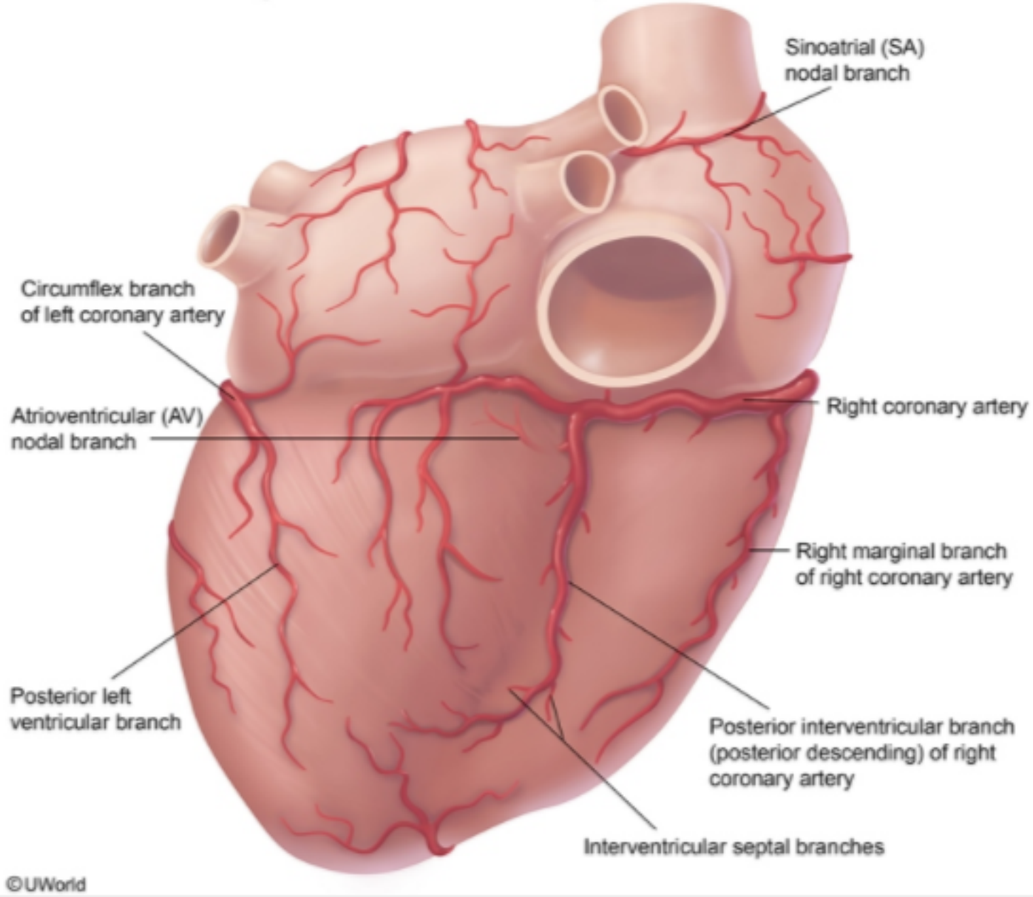

Zoom In | Zoom Out | Reset | Add To New Card | Existing Card

Subject System Topic

interventricular artery]). The PDA originates from one of the following:

Exhibit Display

Coronary arteries: anterior view

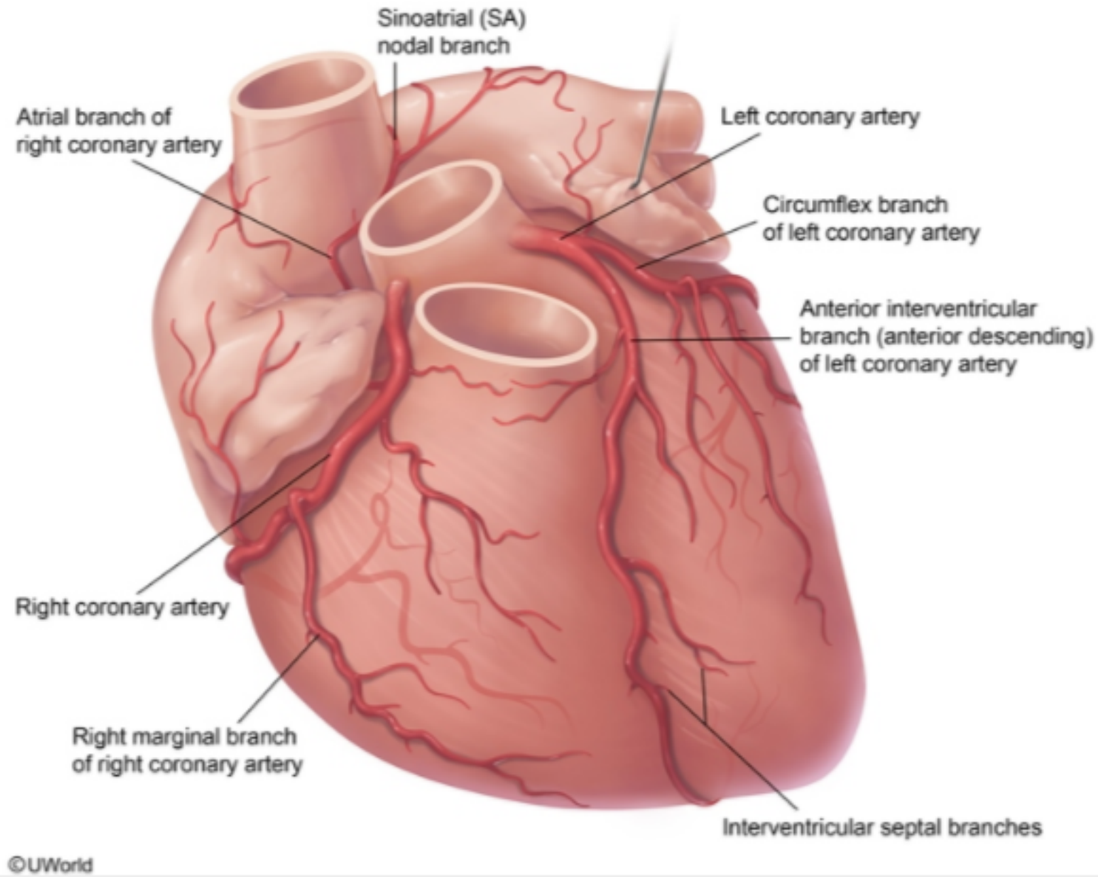

Zoom In | Zoom Out | Reset | Add To New Card | Existing Card

Subject System Topic

A 63-year-old man comes to the emergency department due to pain and swelling of the right calf. He has a history of recurrent gastrointestinal hemorrhage and was discharged from the hospital 4 days ago following a prolonged admission for diverticular bleeding requiring multiple blood transfusions. Temperature is 36.7 C (98 F), blood pressure is 110/60 mm Hg, pulse is 92/min, and respirations are 18/min. Compression ultrasonography with Doppler reveals deep venous thrombosis in the right popliteal vein. A filter placement is planned to prevent embolization. A section of the patient's abdominal CT at the level of L2 is shown in the image below. The filter will most likely be placed in which of the following structures?

- A. A
- B. B
- C. C
- D. D
- E. E

Submit

1
2
3
4
5
6
7
8
9
10
11
12
13
14
15
16
17
18
19
20
21
22
23
24
25
26
27
28
29

section of the patient's abdominal CT at the level of L2 is shown in the image below. The filter will most likely be placed in which of the following structures?

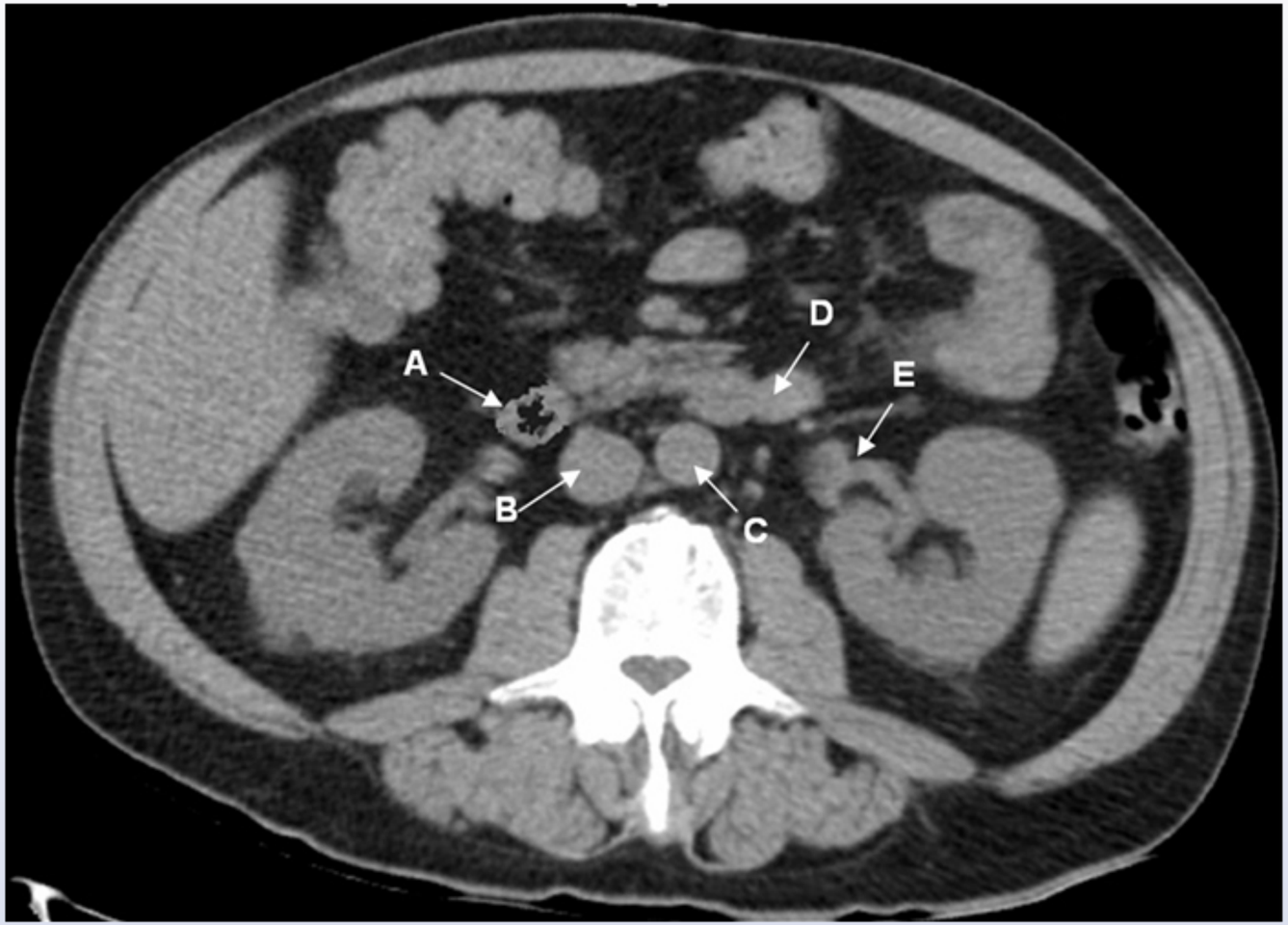

A. A

1
2
3
4
5
6
7
8
9
10
11
12
13
14
15
16
17
18
19
20
21
22
23
24
25
26
27
28
29

A. A

B. B

C. C

D. D

E. E

Submit

1
2
3
4
5
6
7
8
9
10
11
12
13
14
15
16
17
18
19
20
21
22
23
24
25
26
27
28
29

A. A (9%)

✓ B. B (77%)

C. C (9%)

D. D (3%)

E. E (0%)

Omitted
Correct answer

77%
Answered correctly

07 secs
Time Spent

04/25/2020
Last Updated

1
2
3
4
5
6
7
8
9
10
11
12
13
14
15
16
17
18
19
20
21
22
23
24
25
26
27
28
29

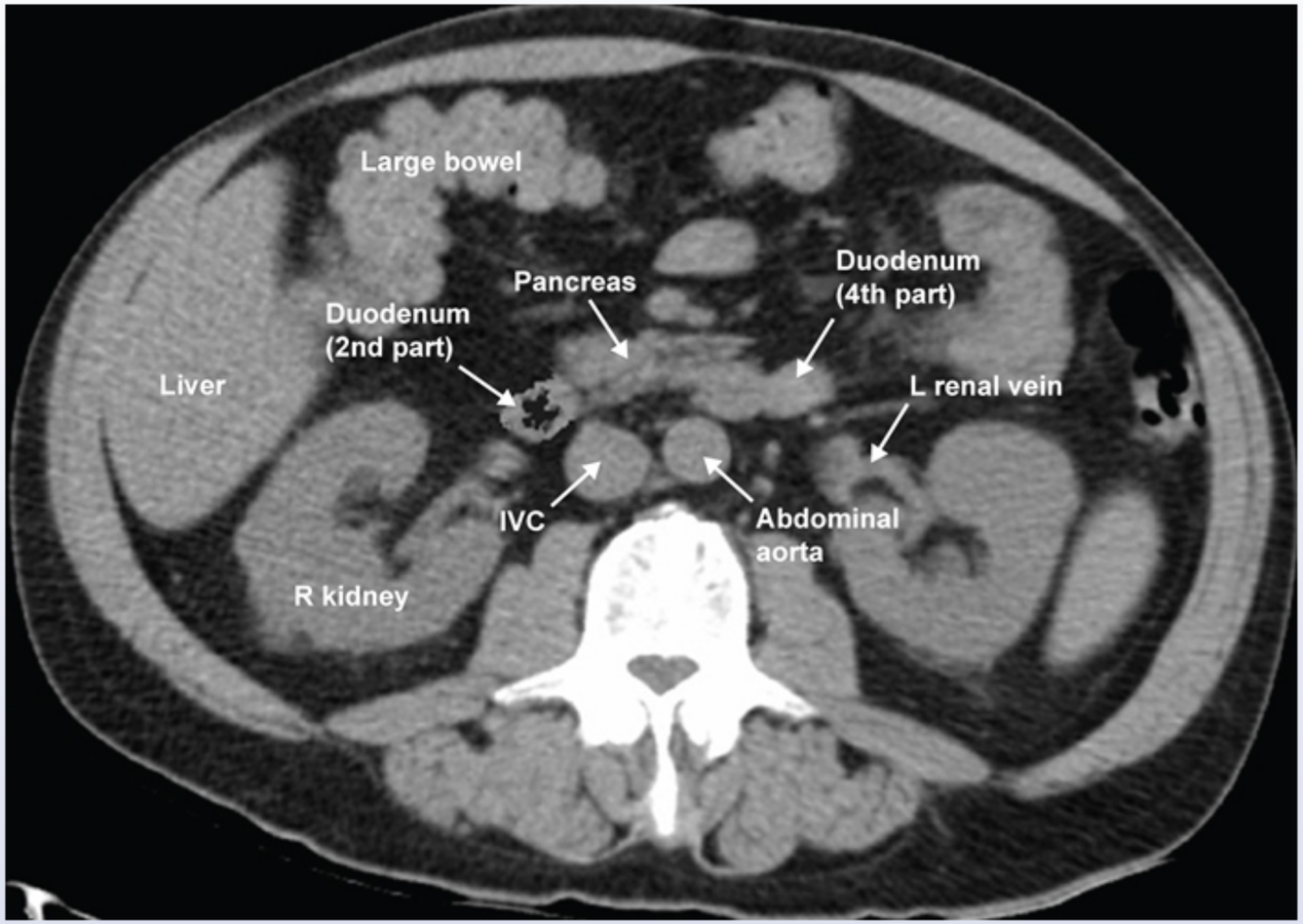

This patient with **deep venous thrombosis** (DVT) has had recurrent episodes of gastrointestinal hemorrhage, including a recent one requiring prolonged hospitalization. Given the risk of bleeding associated with anticoagulation therapy in this patient, **inferior vena cava (IVC) filter** placement is planned. IVC filters are designed to prevent the embolization of DVT from the legs to the lung vasculature (ie, pulmonary embolism),

This patient with **deep venous thrombosis** (DVT) has had recurrent episodes of gastrointestinal hemorrhage, including a recent one requiring prolonged hospitalization. Given the risk of bleeding associated with anticoagulation therapy in this patient, **inferior vena cava (IVC) filter** placement is planned. IVC filters are designed to prevent the embolization of DVT from the legs to the lung vasculature (ie, pulmonary embolism), and are used in patients who have **contraindications to anticoagulation**.

CT images are always visualized as though standing at the patient's feet and looking through the patient's body toward the head; therefore, the left side of the image corresponds to the patient's right side. Both kidneys are viewed in this section, and the inferior pole of the right lobe of the liver is noted anterior to the right kidney and posterolateral to the large bowel. The filter will be placed in the IVC, which lies medial to the descending part of the duodenum and anterior to the right side of the vertebral body. The common iliac veins merge to become the IVC inferior to this plane of section at the L5 level.

(Choice A) With its dark center, representing an air-filled lumen, and mucosal folds, this structure is likely the second (descending) part of the duodenum, which typically lies at the level of L2.

(Choice C) This structure represents the abdominal aorta, which bifurcates at the level of L4. The structure is on the patient's left, so it is unlikely to be the IVC.

(Choice D) This structure likely represents the fourth (ascending) part of the duodenum. This CT section likely captures only the wall of the fourth part of the duodenum as it briefly courses transversely across the abdomen (before descending as the jejunum), so the lumen is not visible.

(Choice E) This structure is likely the left renal vein. The left renal vein receives drainage from the left gonadal vein and courses anterior to the aorta, but posterior to the superior mesenteric artery, before draining into the IVC.

Educational objective:
The inferior vena cava (IVC) courses through the abdomen and inferior thorax in a location anterior to the right half of the vertebral bodies. The renal veins join the IVC at the level of L1/L2, and the common iliac veins merge to become the IVC at the level of L5. IVC filters are placed in patients with deep venous thrombosis who have contraindications to anticoagulation therapy.

Anatomy Cardiovascular System Pulmonary embolism

and are used in patients who have **contraindications to anticoagulation**.

CT images are always visualized as though standing at the patient's feet and looking through the patient's body toward the head; therefore, the left side of the image corresponds to the patient's right side. Both kidneys are viewed in this section, and the inferior pole of the right lobe of the liver is noted anterior to the right kidney and posterolateral to the large bowel. The filter will be placed in the IVC, which lies medial to the descending part of the duodenum and anterior to the right side of the vertebral body. The common iliac veins merge to become the IVC inferior to this plane of section at the L5 level.

(Choice A) With its dark center, representing an air-filled lumen, and mucosal folds, this structure is likely the second (descending) part of the duodenum, which typically lies at the level of L2.

(Choice C) This structure represents the abdominal aorta, which bifurcates at the level of L4. The structure is on the patient's left, so it is unlikely to be the IVC.

(Choice D) This structure likely represents the fourth (ascending) part of the duodenum. This CT section likely captures only the wall of the fourth part of the duodenum as it briefly courses transversely across the abdomen (before descending as the jejunum), so the lumen is not visible.

(Choice E) This structure is likely the left renal vein. The left renal vein receives drainage from the left gonadal vein and courses anterior to the aorta, but posterior to the superior mesenteric artery, before draining into the IVC.

Educational objective:
The inferior vena cava (IVC) courses through the abdomen and inferior thorax in a location anterior to the right half of the vertebral bodies. The renal veins join the IVC at the level of L1/L2, and the common iliac veins merge to become the IVC at the level of L5. IVC filters are placed in patients with deep venous thrombosis who have contraindications to anticoagulation therapy.

Anatomy	Cardiovascular System	Pulmonary embolism
Subject	System	Topic

Copyright © UWorld. All rights reserved.

A 52-year-old man is being evaluated for nonspecific, chronic abdominal pain. As part of the workup, he undergoes an abdominal CT scan with intravenous contrast, which reveals no significant findings. An axial image from the scan is shown below.

Which of the following statements best describes the structure indicated by the arrow?

1
2
3
4
5
6
7
8
9
10
11
12
13
14
15
16
17
18
19
20
21
22
23
24
25
26
27
28
29

Which of the following statements best describes the structure indicated by the arrow?

A. It drains into the left subclavian vein in the thorax.

B. It drains through the cystic duct into the common bile duct.

C. It gives rise to the right and left renal arteries.

D. It is formed by the union of the common iliac veins.

E. It joins the splenic vein to form the portal vein.

Submit

1
2
3
4
5
6
7
8
9
10
11
12
13
14
15
16
17
18
19
20
21
22
23
24
25
26
27
28
29

Which of the following statements best describes the structure indicated by the arrow?

A. It drains into the left subclavian vein in the thorax. (3%)

B. It drains through the cystic duct into the common bile duct. (10%)

C. It gives rise to the right and left renal arteries. (5%)

✓ D. It is formed by the union of the common iliac veins. (70%)

E. It joins the splenic vein to form the portal vein. (10%)

Omitted
Correct answer

70%
Answered correctly

06 secs
Time Spent

02/29/2020
Last Updated

1
2
3
4
5
6
7
8
9
10
11
12
13
14
15
16
17
18
19
20
21
22
23
24
25
26
27
28
29

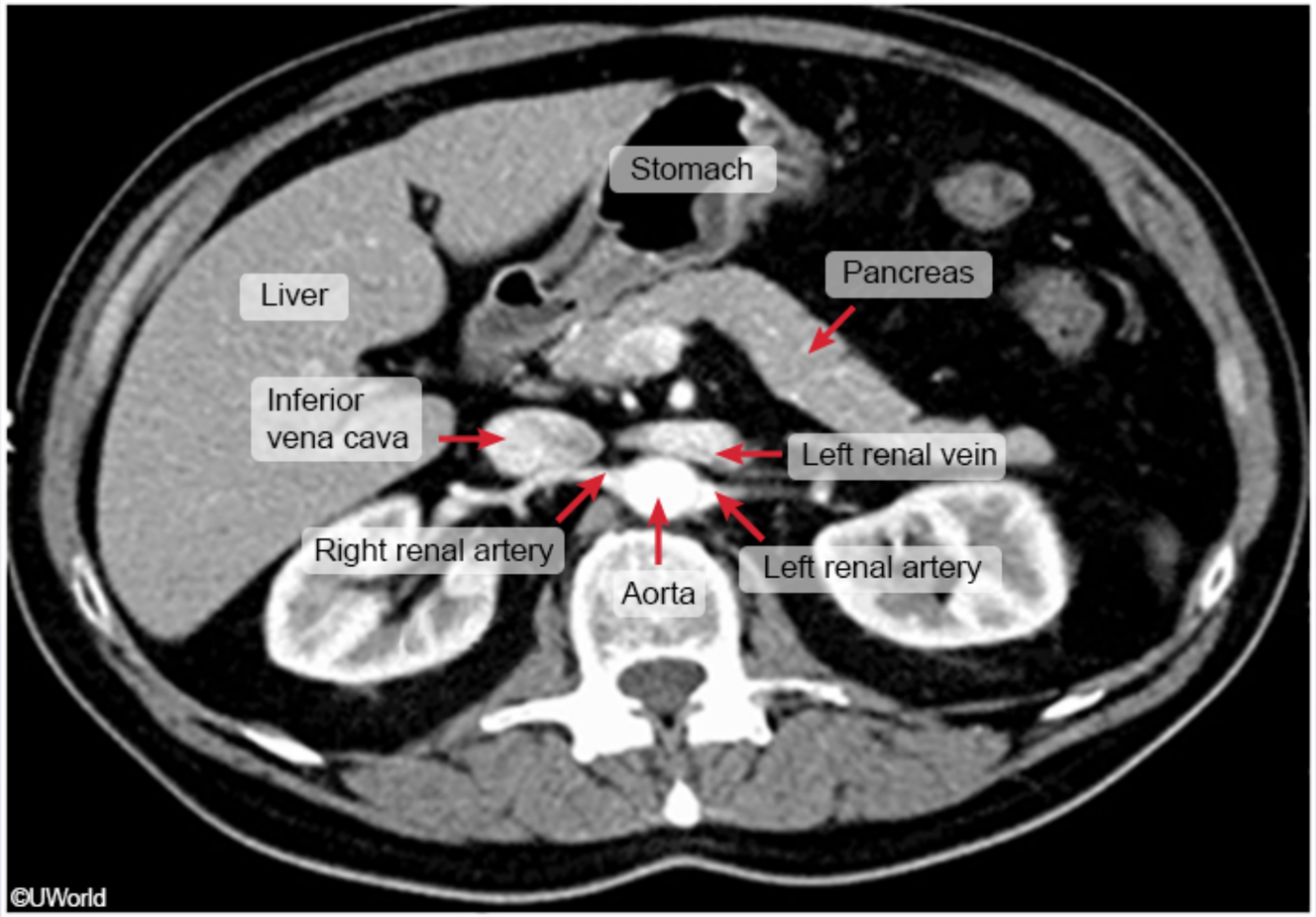

This axial CT image reveals the abdomen near the L1 vertebral level. At this level, the **inferior vena cava (IVC)** lies just anterior to the right renal artery and to the right of the aorta. The IVC is formed by the **union of the right and left common iliac veins** at the level of L4-L5 and drains into the right atrium just above the level of the diaphragm at T8. The IVC returns venous blood to the right atrium from the lower extremities, portal

This axial CT image reveals the abdomen near the L1 vertebral level. At this level, the **inferior vena cava (IVC)** lies just anterior to the right renal artery and to the right of the aorta. The IVC is formed by the **union of the right and left common iliac veins** at the level of L4-L5 and drains into the right atrium just above the level of the diaphragm at T8. The IVC returns venous blood to the right atrium from the lower extremities, portal system, and abdominal and pelvic viscera.

(Choice A) The thoracic duct drains lymph from the entire left side of the body and all regions inferior to the umbilicus (including the entire gastrointestinal tract). It enters the thorax through the aortic hiatus and empties into the left subclavian vein near its junction with the internal jugular vein.

(Choice B) The cystic duct drains bile from the gallbladder into the common bile duct. The gallbladder is typically visualized just below the liver in the anterior right abdomen but is not well seen in this image.

(Choice C) The image reveals the abdominal aorta giving rise to the right and left renal arteries at the L1 vertebral level. The abdominal aorta lies posteromedial to the IVC within the abdomen.

(Choice E) The superior mesenteric vein joins the splenic vein to form the portal vein. The portal vein can be seen vaguely near the head of the pancreas in this cross-sectional image.

Educational objective:
The inferior vena cava is formed by the union of the right and left common iliac veins at the level of L4-L5. The renal arteries and veins lie at the level of L1. The inferior vena cava returns venous blood to the heart from the lower extremities, portal system, and abdominal and pelvic viscera.

Anatomy	Cardiovascular System	Ct abdomen
Subject	System	Topic

Copyright © UWorld. All rights reserved.

A 70-year-old man comes to the emergency department due to severe midback pain that started several hours ago. He describes the pain as excruciating and wants immediate relief. The patient also has nausea, diaphoresis, and lightheadedness. He has a history of hypertension and chronic kidney disease. His medication compliance has been poor. He is an active smoker with a 40-pack-year history. His blood pressure on the right arm is 220/105 mm Hg. ECG shows sinus tachycardia and voltage criteria for left ventricular hypertrophy with secondary ST-segment and T wave changes. After initial evaluation, a transesophageal echocardiogram shows a dissection flap in the descending aorta but no evidence of dissection in the ascending aorta. The dissection flap in this patient most likely originates near which of the following points?

- A. Brachiocephalic trunk
- B. Celiac trunk
- C. Intercostal arteries
- D. Left subclavian artery
- E. Renal arteries

Submit

A 70-year-old man comes to the emergency department due to severe midback pain that started several hours ago. He describes the pain as excruciating and wants immediate relief. The patient also has nausea, diaphoresis, and lightheadedness. He has a history of hypertension and chronic kidney disease. His medication compliance has been poor. He is an active smoker with a 40-pack-year history. His blood pressure on the right arm is 220/105 mm Hg. ECG shows sinus tachycardia and voltage criteria for left ventricular hypertrophy with secondary ST-segment and T wave changes. After initial evaluation, a transesophageal echocardiogram shows a dissection flap in the descending aorta but no evidence of dissection in the ascending aorta. The dissection flap in this patient most likely originates near which of the following points?

- A. Brachiocephalic trunk (12%)
- B. Celiac trunk (14%)
- C. Intercostal arteries (5%)
- ✓ D. Left subclavian artery (46%)
- E. Renal arteries (21%)

Omitted
Correct answer
D

46%
Answered correctly

06 secs
Time Spent

01/20/2020
Last Updated

Explanation

DISSECTING AORTIC HEMATOMAS

1
2
3
4
5
6
7
8
9
10
11
12
13
14
15
16
17
18
19
20
21
22
23
24
25
26
27
28
29

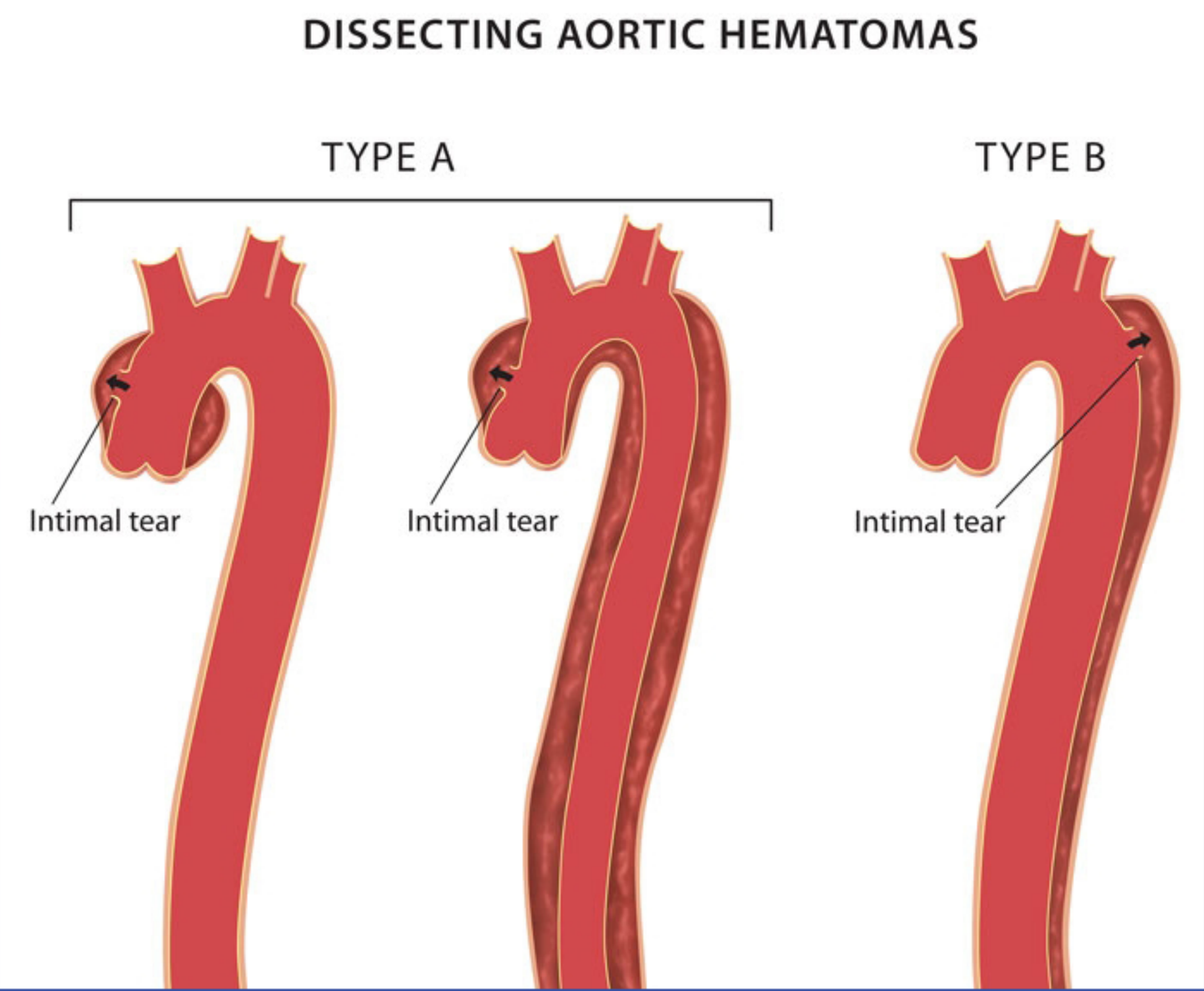

1
2
3
4
5
6
7
8
9
10
11
12
13
14
15
16
17
18
19
20
21
22
23
24
25
26
27
28
29

Exhibit Display

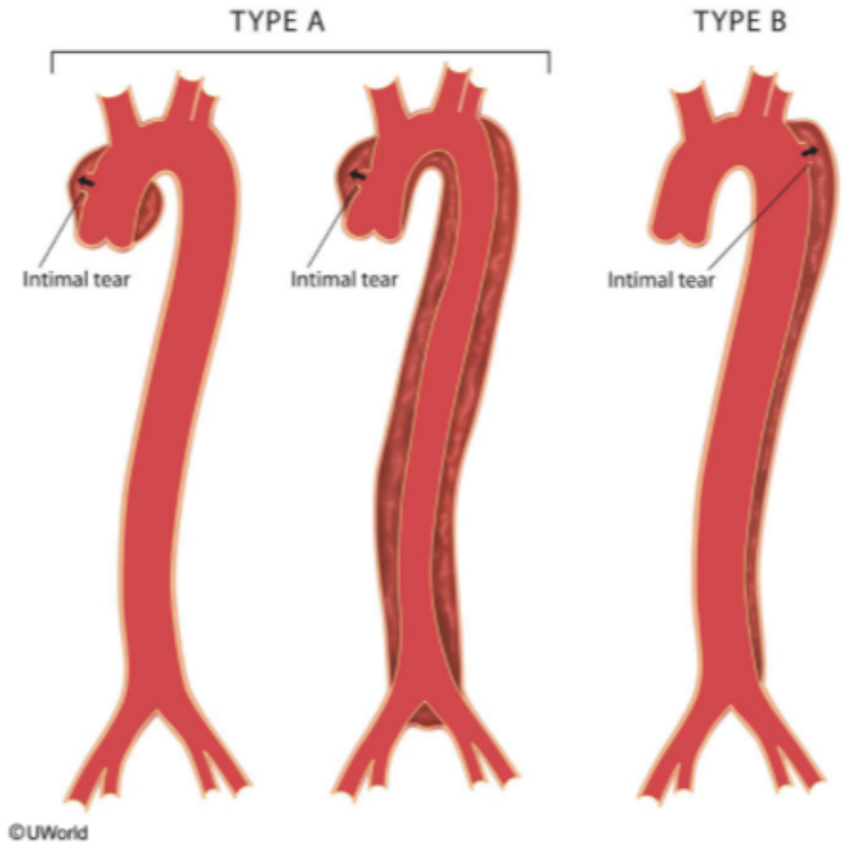

Zoom In | Zoom Out | Reset | Add To New Card | Existing Card

This patient's clinical presentation with severe back pain, hypertension, ECG abnormalities, and transesophageal echocardiogram finding of a dissection flap in the descending aorta is consistent with Stanford type B **aortic dissection**. The Stanford system uses the anatomic localization of the dissection plane for classification of aortic dissections:

- **Stanford type A** refers to aortic dissections that involve any part of the **ascending aorta**.
- **Stanford type B** refers to all other dissections involving the **descending aorta**.

Type B dissections involving the descending aorta typically originate close to the origin of the **left subclavian artery**. Type A aortic dissections usually originate in the sinotubular junction. The areas are thought to be predominantly affected due to increases in the rate of rise of pressure (dP/dT) and in shearing forces at these sites in patients with severe hypertension.

(Choices A, B, C, and E) Distal propagation of a type A dissection or proximal propagation of a type B dissection can affect the aortic arch (eg, brachiocephalic artery, left common carotid artery, left subclavian artery). Either type of dissection can propagate distally into the thoracoabdominal aorta, involving the origins of the celiac trunk, intercostal arteries, and renal arteries.

Educational objective:
The intimal tear in Stanford type A aortic dissection (involving the ascending aorta) usually originates in the sinotubular junction whereas the intimal flap in Stanford type B aortic dissection usually starts near the origin of the left subclavian artery. Dissections can propagate distally to the thoracoabdominal aorta.

Anatomy	Cardiovascular System	Aortic dissection
Subject	System	Topic

Copyright © UWorld. All rights reserved.

1
2
3
4
5
6
7
8
9
10
11
12
13
14
15
16
17
18
19
20
21
22
23
24
25
26
27
28
29

A 33-year-old man comes to the emergency department due to fever, chills, cough, and shortness of breath over the last week. He smokes a pack of cigarettes a day, consumes 2 or 3 alcoholic beverages daily, and uses intravenous heroin 2 or 3 times per week. He is febrile and tachycardic. Blood cultures grow *Staphylococcus aureus*. Chest x-ray shows bilateral nodular lesions with areas of cavitation. The valve most likely affected in this patient can be best evaluated by auscultation at which of the following sites?

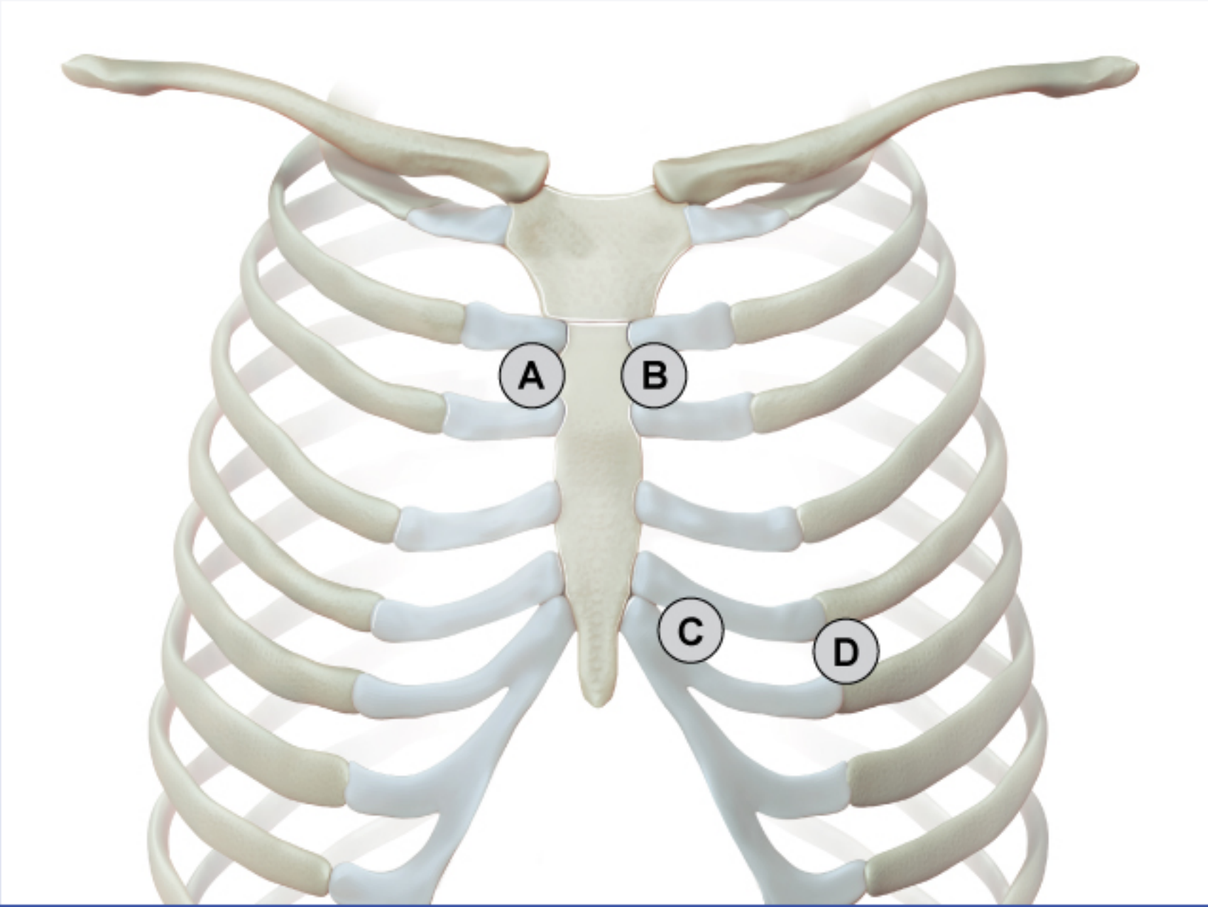

1
2
3
4
5
6
7
8
9
10
11
12
13
14
15
16
17
18
19
20
21
22
23
24
25
26
27
28
29

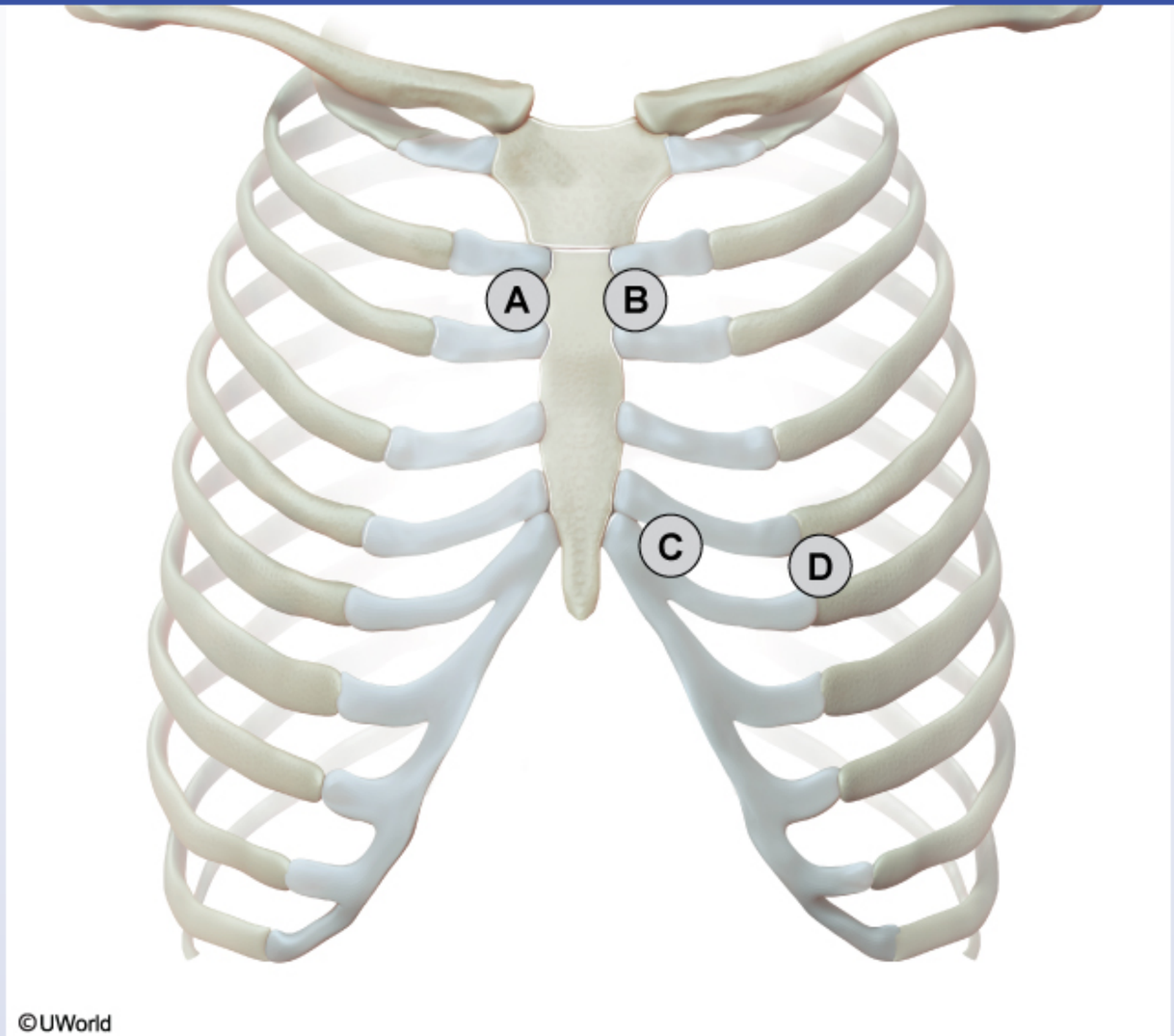

A. A

1
2
3
4
5
6
7
8
9
10
11
12
13
14
15
16
17
18
19
20
21
22
23
24
25
26
27
28
29

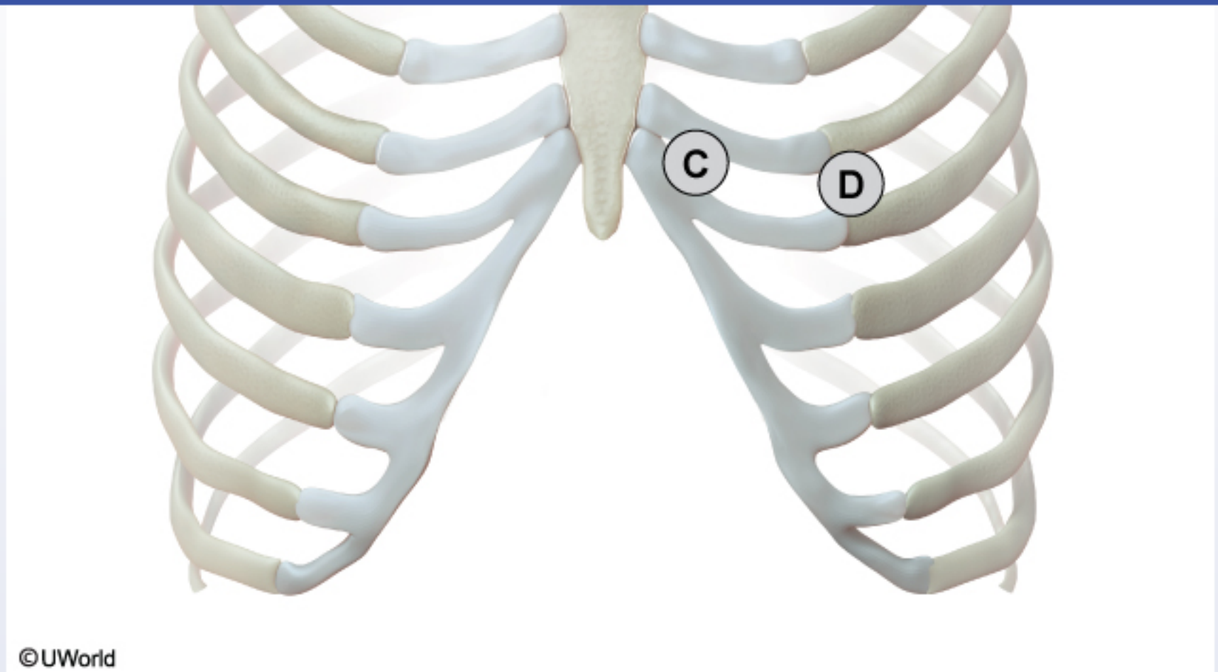

A. A

B. B

C. C

D. D

Submit

1
2
3
4
5
6
7
8
9
10
11
12
13
14
15
16
17
18
19
20
21
22
23
24
25
26
27
28
29

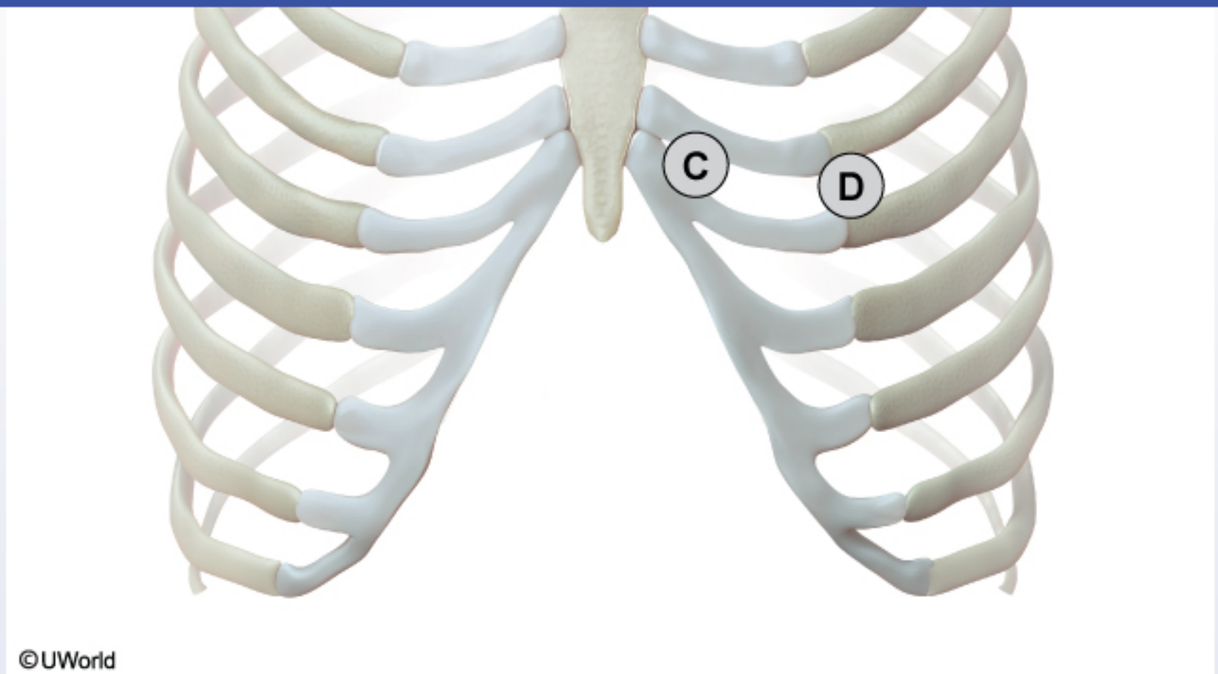

A. A (2%)

B. B (1%)

✓ C. C (88%)

D. D (7%)

Omitted
Correct answer

88%
Answered correctly

09 secs
Time Spent

03/21/2020
Last Updated

1
2
3
4
5
6
7
8
9
10
11
12
13
14
15
16
17
18
19
20
21
22
23
24
25
26
27
28
29

Cardiac auscultatory locations

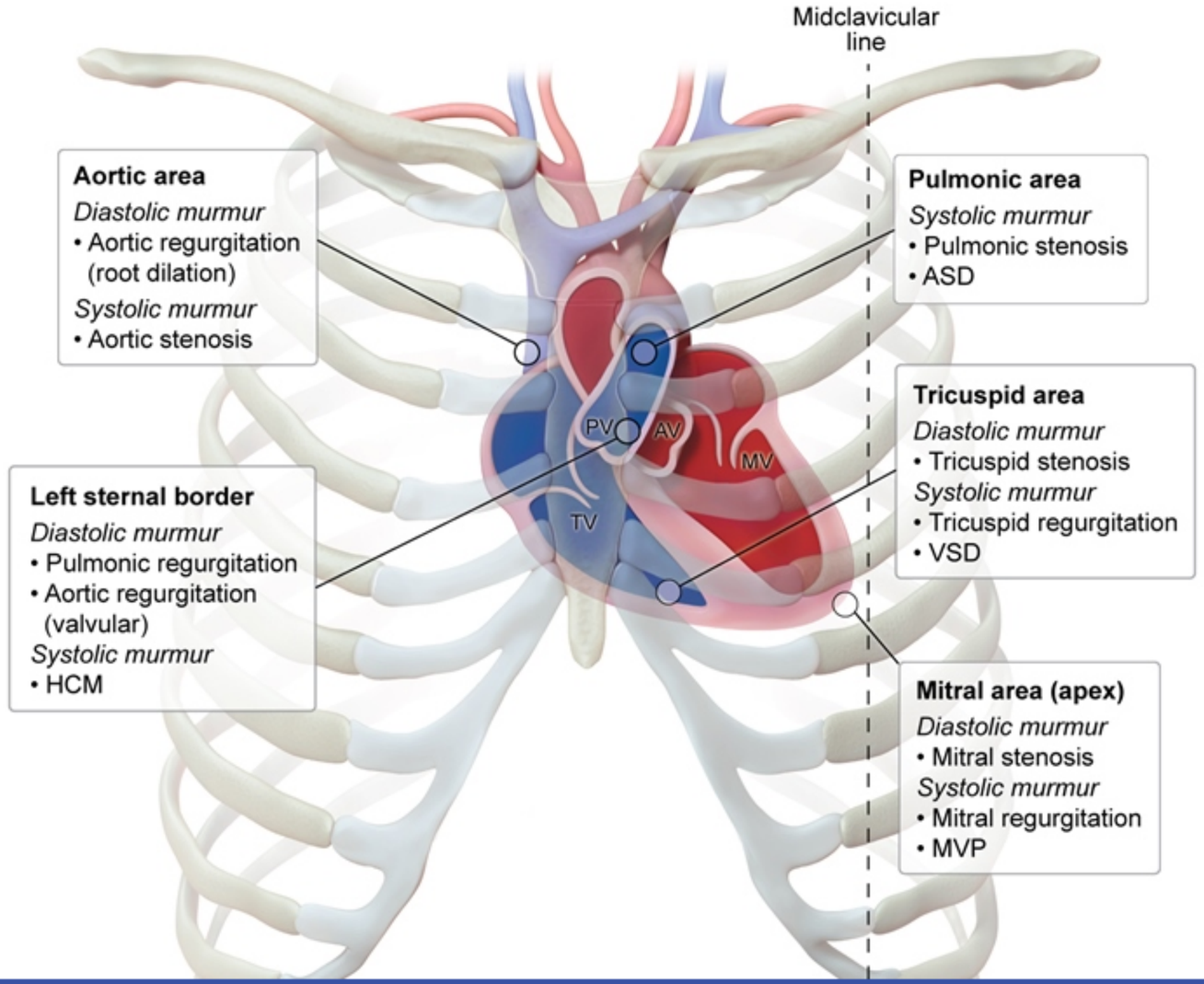

1
2
3
4
5
6
7
8
9
10
11
12
13
14
15
16
17
18
19
20
21
22
23
24
25
26
27
28
29

prolapse; **PV** = pulmonic valve; **TV** = tricuspid valve; **VSD** = ventricular septal defect.
©UWorld

The cavitary pulmonary nodules on this patient's chest x-ray are consistent with **septic emboli**, which are a common complication of **right-sided infective endocarditis** (IE). The **tricuspid valve** is frequently affected in intravenous drug users; bacterial adherence may be encouraged by the inadvertent injection of particulate matter that damages the tricuspid valve endothelium. *Staphylococcus aureus* is the most common organism responsible for IE in intravenous drug users.

A murmur of IE typically results from regurgitation of blood due to impaired closure of the affected valve. Although tricuspid valve endocarditis does not always cause a murmur, an early- or holo-systolic murmur of **tricuspid regurgitation** is sometimes appreciated. This murmur is best auscultated in the 4th or 5th intercostal space at the **left lower sternal border** (the tricuspid auscultation area), and it increases in intensity with maneuvers that increase right ventricular blood volume (eg, inspiration, supine leg raise).

(Choices A and D) Most aortic valve murmurs are best auscultated in the 2nd intercostal space at the right upper sternal border. Mitral valve murmurs are best auscultated at the cardiac apex, which is usually located near the midclavicular line in the left 5th intercostal space. IE affecting these left-sided heart valves may cause septic embolization to the kidneys, brain, or other systemic organs but not to the pulmonary circulation.

(Choice B) Pulmonic valve murmurs are best auscultated in the 2nd intercostal space at the left upper sternal border. IE affecting the pulmonic valve can occur in intravenous drug users and lead to septic pulmonary emboli, but it is far less common than tricuspid valve endocarditis.

Educational objective:
Infective endocarditis in intravenous drug users commonly affects the tricuspid valve, often leading to septic pulmonary emboli. Patients can have an early- or holo-systolic murmur of tricuspid regurgitation, which is best auscultated in the 4th or 5th intercostal space at the left lower sternal border.

Anatomy	Cardiovascular System	Tricuspid regurgitation
Subject	System	Topic

Copyright © UWorld. All rights reserved.

A 71-year-old man comes to the hospital due to 3 hours of persistent retrosternal chest pain and dyspnea. After prompt evaluation, he is diagnosed with acute myocardial infarction and undergoes cardiac catheterization. During cannulation of the right common femoral artery, the arterial wall is penetrated superior to the right inguinal ligament. Percutaneous coronary intervention is then performed, after which firm pressure is applied to achieve hemostasis. Soon after the procedure, the patient becomes cold, clammy, and hypotensive. Physical examination shows a 5cm region of ecchymosis surrounding the femoral puncture site. Internal bleeding is suspected. Which of the following is the most likely location of the blood collection?

A. Pelvic cavity

B. Retroperitoneal space

C. Right paracolic gutter

D. Subcutaneous tissue

E. Thigh muscles

Submit

A 71-year-old man comes to the hospital due to 3 hours of persistent retrosternal chest pain and dyspnea. After prompt evaluation, he is diagnosed with acute myocardial infarction and undergoes cardiac catheterization. During cannulation of the right common femoral artery, the arterial wall is penetrated superior to the right inguinal ligament. Percutaneous coronary intervention is then performed, after which firm pressure is applied to achieve hemostasis. Soon after the procedure, the patient becomes cold, clammy, and hypotensive. Physical examination shows a 5cm region of ecchymosis surrounding the femoral puncture site. Internal bleeding is suspected. Which of the following is the most likely location of the blood collection?

A. Pelvic cavity (36%)
✓ B. Retroperitoneal space (27%)
C. Right paracolic gutter (16%)
D. Subcutaneous tissue (10%)
E. Thigh muscles (8%)

Omitted
Correct answer
B

27%
Answered correctly

02 secs
Time Spent

06/12/2020
Last Updated

Explanation

Retroperitoneal hematoma

1
2
3
4
5
6
7
8
9
10
11
12
13
14
15
16
17
18
19
20
21
22
23
24
25
26
27
28
29

Retroperitoneal hematoma

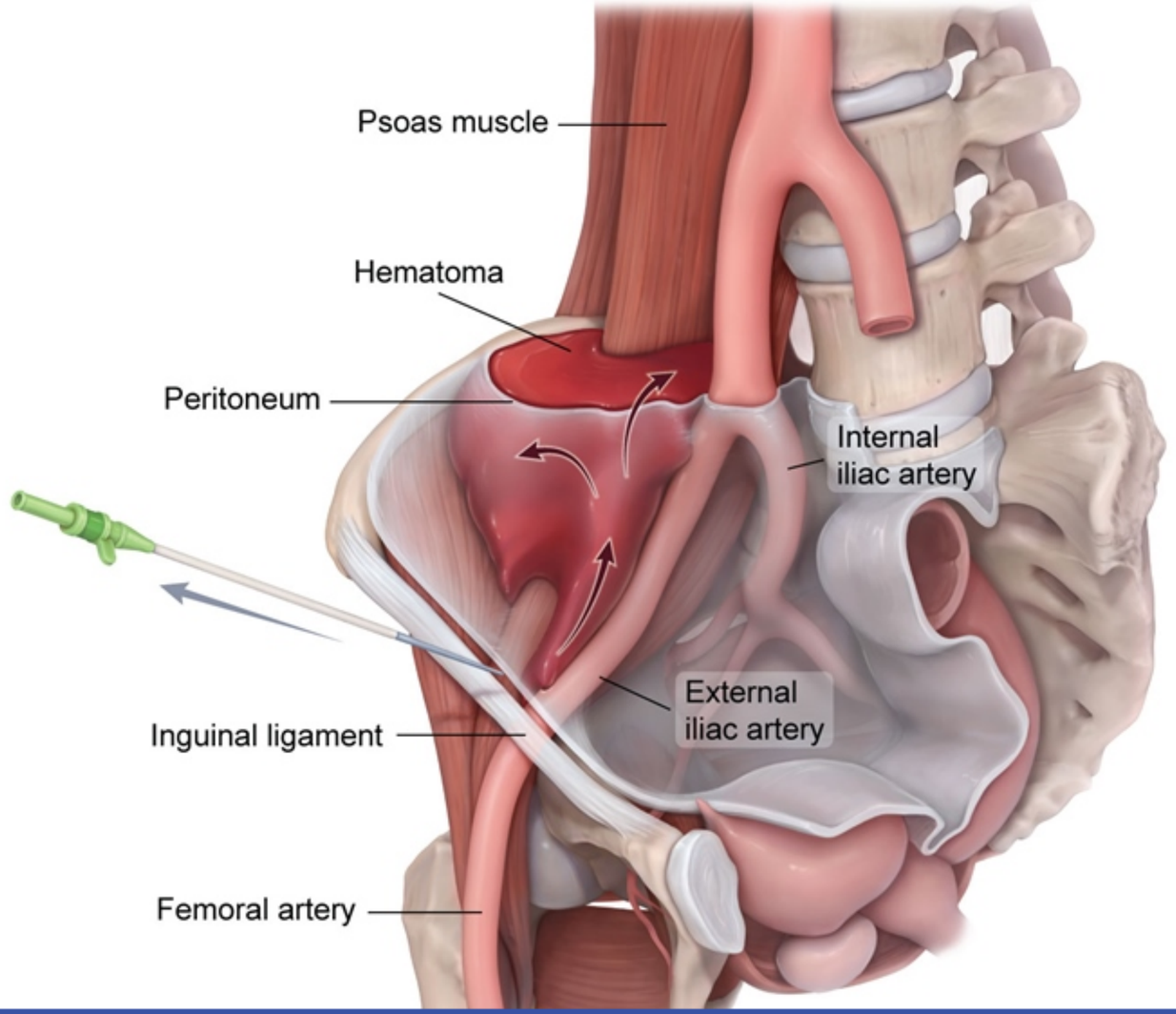

1
2
3
4
5
6
7
8
9
10
11
12
13
14
15
16
17
18
19
20
21
22
23
24
25
26
27
28
29

Exhibit Display

Retroperitoneal hematoma

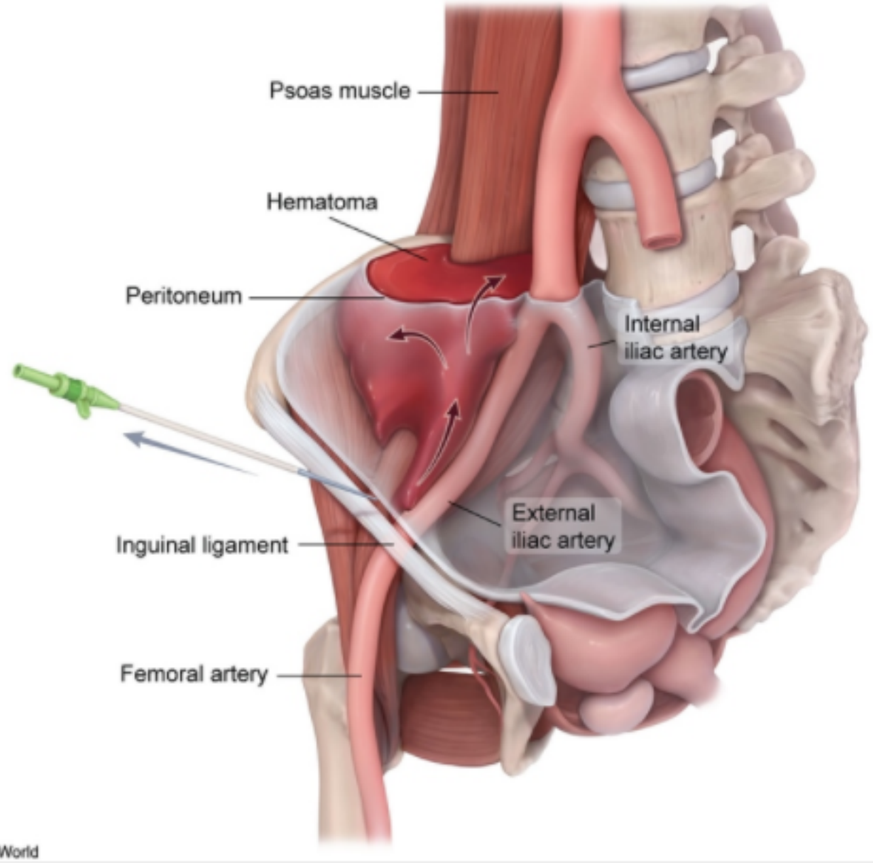

Zoom In | Zoom Out | Reset | Add To New Card | Existing Card

Vascular access during **cardiac catheterization** is typically obtained through either the **common femoral artery** or radial artery. The common femoral artery is the continuation of the external iliac artery as it crosses the inguinal ligament. Arterial **puncture above the inguinal ligament** increases the risk of **retroperitoneal hemorrhage**, as this portion of the vessel lies directly inferior to the peritoneum. Accidental puncture of the posterior wall can cause blood to track along the loose connective tissue surrounding the vessel and accumulate within the interfascial planes of the retroperitoneum.

Bleeding in the retroperitoneal space **cannot be controlled** with external compression and can lead to life-threatening hemorrhage. Affected patients typically develop **hemodynamic instability** with significant hypotension, a drop in hemoglobin, and ipsilateral flank pain.

(Choice A) Bleeding into the pelvic cavity is frequently due to trauma (eg, pelvic fracture) or gynecologic hemorrhage (eg, ruptured ectopic pregnancy). Injury to the common femoral artery is less likely to cause intraperitoneal bleeding as the external iliac artery courses underneath the peritoneum.

(Choice C) The right paracolic gutter is a peritoneal recess found between the ascending colon and abdominal wall. Fluid (bile, pus, or blood) typically accumulates there from pathology involving the gastrointestinal organs, particularly the appendix and gall bladder.

(Choice D) Subcutaneous tissue hemorrhage from an arterial source typically presents with a large area of ecchymosis and a palpable hematoma. Development of significant hypotension is less likely with subcutaneous bleeding, as the potential space for blood accumulation is smaller than with peritoneal or retroperitoneal bleeding.

(Choice E) Hemorrhage into the thigh muscles would present with significant pain and edema in the thigh and possibly lead to compartment syndrome (severe pain, absent distal pulses).

Educational objective:
The optimal site for obtaining vascular access in the lower extremity during cardiac catheterization is the common femoral artery below the inguinal ligament. Cannulation above the inguinal ligament can significantly increase the risk of retroperitoneal hemorrhage.

References

- Retroperitoneal hematoma in patients undergoing cardiac catheterization.

The following vignette applies to the next **2** items.

A 52-year-old man is brought to the emergency department for evaluation of fever, chills, and malaise. Cardiopulmonary examination reveals a new holosystolic heart murmur that radiates toward the axilla. Blood cultures are obtained, and the patient undergoes transesophageal echocardiography. The ultrasound probe is placed in the midesophagus facing anteriorly, and the cardiac chambers are interrogated.

Item 1 of 2

Which of the following chambers is closest to the probe?

A. Left atrium

B. Left ventricle

C. Right atrium

D. Right ventricle

Submit

The following vignette applies to the next **2** items.

A 52-year-old man is brought to the emergency department for evaluation of fever, chills, and malaise. Cardiopulmonary examination reveals a new holosystolic heart murmur that radiates toward the axilla. Blood cultures are obtained, and the patient undergoes transesophageal echocardiography. The ultrasound probe is placed in the midesophagus facing anteriorly, and the cardiac chambers are interrogated.

Item 1 of 2

Which of the following chambers is closest to the probe?

- ✓ A. Left atrium (79%)
- B. Left ventricle (4%)
- C. Right atrium (11%)
- D. Right ventricle (4%)

Omitted
Correct answer
A

79%
Answered correctly

03 secs
Time Spent

05/04/2020
Last Updated

Explanation

Transesophageal echocardiography (TEE)

1
2
3
4
5
6
7
8
9
10
11
12
13
14
15
16
17
18
19
20
21
22
23
24
25
26
27
28
29

Exhibit Display

Transesophageal echocardiography (TEE)

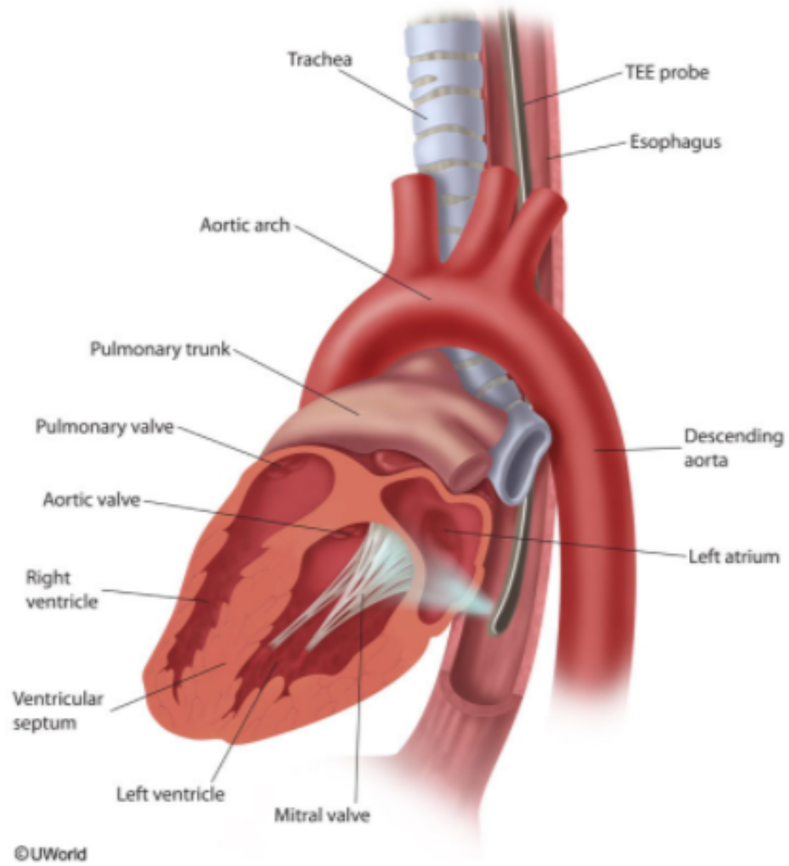

Zoom In | Zoom Out | Reset | Add To New Card | Existing Card

This patient's presentation suggests acute endocarditis, with confirmation pending the results of the blood cultures and cardiac imaging. **Transesophageal echocardiography** (TEE) uses ultrasound waves generated from within the **esophagus** to produce clear images of the neighboring cardiac structures. The left atrium makes up the majority of the heart's posterior surface, with the esophagus passing immediately posterior to the heart. Therefore, the esophagus lies within closest proximity to the **left atrium**. This allows the left atrium, atrial septum, and mitral valve to be particularly well visualized on TEE.

Due to its proximity, conditions that result in left atrial enlargement (eg, mitral stenosis or regurgitation) can cause dysphagia through external compression of the esophagus.

(Choice B) The left ventricle forms the majority of the inferior (diaphragmatic) surface of the heart and the left border of the heart on frontal chest x-ray.

(Choice C) The right atrium, along with the superior vena cava, forms the right lateral cardiac border on frontal chest x-ray.

(Choice D) The right ventricle forms the anterior (sternal) surface of the heart and the majority of its inferior border on frontal chest x-ray.

Educational objective:
The left atrium forms the majority of the posterior surface of the heart and resides adjacent to the esophagus. Enlargement of the left atrium can compress the esophagus and cause dysphagia.

Anatomy	Cardiovascular System	Cardiovascular anatomy
Subject	System	Topic

Copyright © UWorld. All rights reserved.

1
2
3
4
5
6
7
8
9
10
11
12
13
14
15
16
17
18
19
20
21
22
23
24
25
26
27
28
29

Exhibit Display

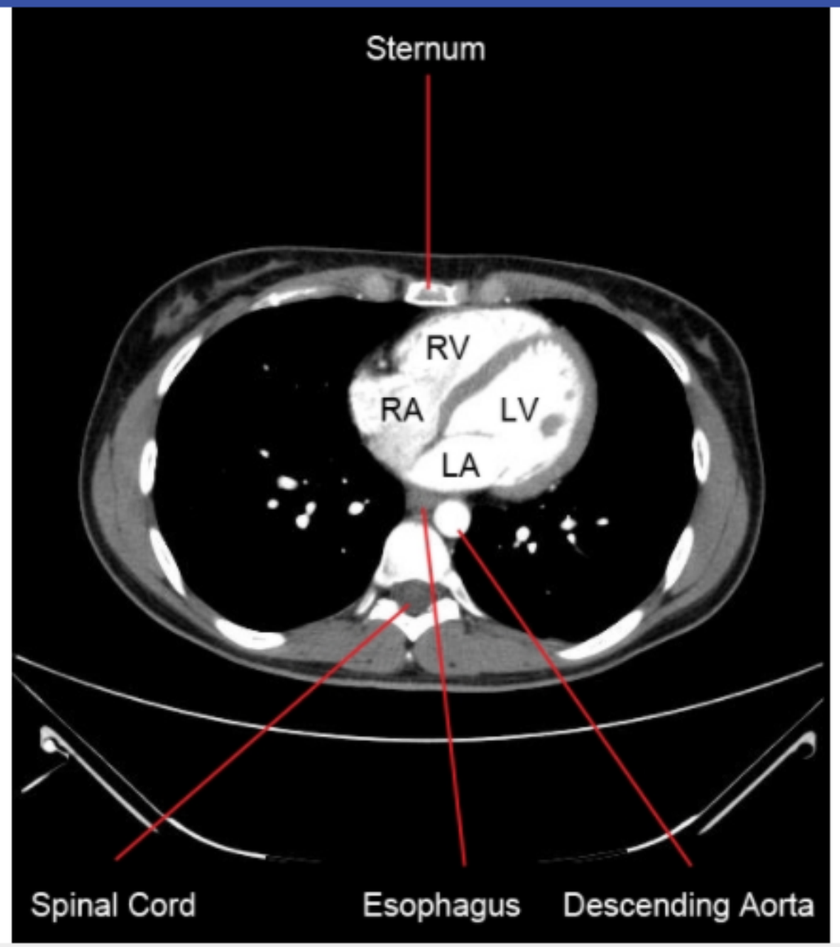

Zoom In | Zoom Out | Reset | Add To New Card | Existing Card

Item 2 of 2

In the same midesophageal position, the probe is rotated so that it now faces posteriorly. Which of the following structures will be best visualized with the probe's new orientation?

- A. Descending aorta
- B. Pulmonary artery
- C. Pulmonary veins
- D. Superior vena cava
- E. Tricuspid valve

Submit

Item 2 of 2

In the same midesophageal position, the probe is rotated so that it now faces posteriorly. Which of the following structures will be best visualized with the probe's new orientation?

- ✓ A. Descending aorta (74%)
- B. Pulmonary artery (4%)
- C. Pulmonary veins (8%)
- D. Superior vena cava (11%)
- E. Tricuspid valve (1%)

Omitted
Correct answer
A

74%
Answered correctly

02 secs
Time Spent

05/04/2020
Last Updated

Explanation

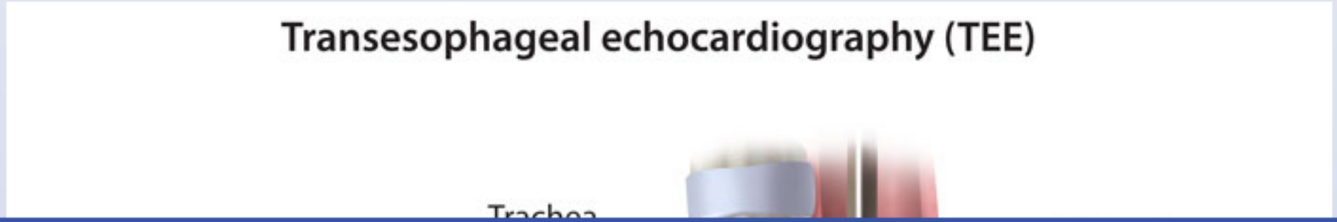

1
2
3
4
5
6
7
8
9
10
11
12
13
14
15
16
17
18
19
20
21
22
23
24
25
26
27
28
29

Exhibit Display

Transesophageal echocardiography (TEE)

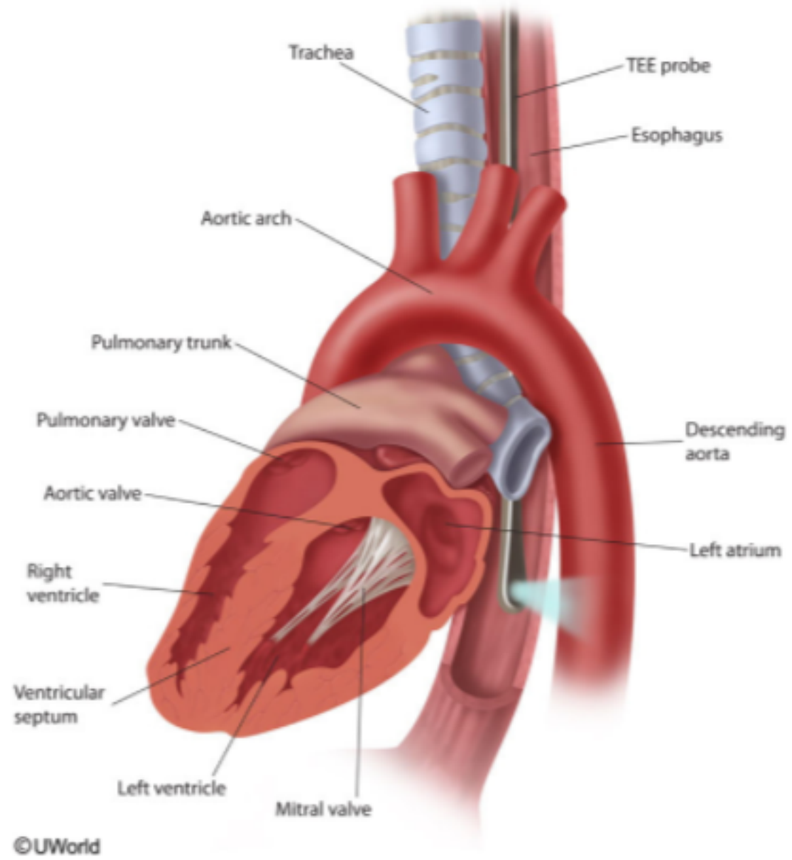

Zoom In | Zoom Out | Reset | Add To New Card | Existing Card

The aorta has 4 major divisions: the ascending aorta, the aortic arch, the descending thoracic aorta, and the abdominal aorta. The ascending aorta lies posterior and to the right of the main pulmonary artery. The aortic arch travels above the right pulmonary artery and the left bronchus. The brachiocephalic, left common carotid, and left subclavian arteries (in that order) originate from its superior aspect.

The **descending thoracic aorta** travels down the anterior surface of the vertebral column, becoming the abdominal aorta as it crosses the diaphragm. As it descends, the aorta moves from the left side of the vertebral column toward the midline; at the level of the cardiac chambers, the descending aorta lies posterior to the esophagus and the left atrium. This permits clear visualization of the descending aorta during transesophageal echocardiography (TEE), allowing for the detection of abnormalities such as dissection or aneurysm.

The other answer choices describe structures located anterior to the esophagus.

(Choice B) The main pulmonary artery ascends anteriorly and to the left of the ascending aorta and is directed toward the left shoulder. After the pulmonary artery bifurcates, the right pulmonary artery travels horizontally under the aortic arch posterior to the superior vena cava, and the left pulmonary artery courses superiorly over the left main bronchus.

(Choice C) The superior and inferior pulmonary veins arise bilaterally from each lung and enter the left atrium. The proximal 2-3 cm of the pulmonary veins contain cardiac muscle within the media and function like sphincters during atrial systole.

(Choice D) The superior vena cava (SVC) is formed behind the right first costal cartilage by the merger of the right and left brachiocephalic veins. It returns blood from the head, neck, and upper extremities to the right atrium of the heart. Mediastinal neoplasms can compress the SVC and result in SVC syndrome.

(Choice E) The tricuspid valve is located between the right atrium and right ventricle and is composed of 3 valve leaflets, the annulus, supporting chordae tendineae, and the papillary muscles. It is commonly infected (endocarditis) in intravenous drug users.

Educational objective:
The descending thoracic aorta lies posterior to the esophagus and the left atrium. This position permits clear visualization of the descending aorta by transesophageal echocardiography, allowing for the detection of abnormalities such as dissection or aneurysm.

1
2
3
4
5
6
7
8
9
10
11
12
13
14
15
16
17
18
19
20
21
22
23
24
25
26
27
28
29

Exhibit Display

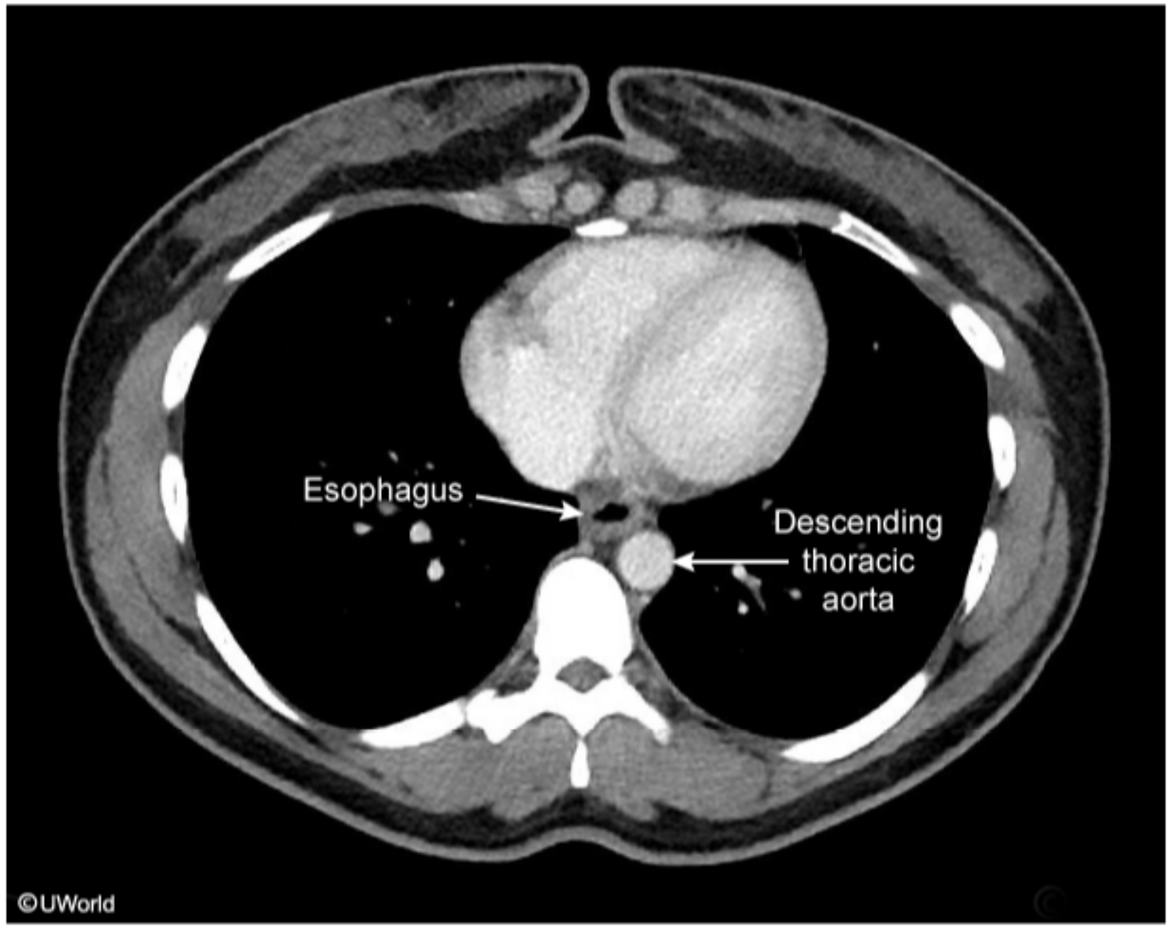

Zoom In | Zoom Out | Reset | Add To New Card | Existing Card

aorta lies posterior and to the right of the main pulmonary artery. The aortic arch travels above the right pulmonary artery and the left bronchus.

Exhibit Display

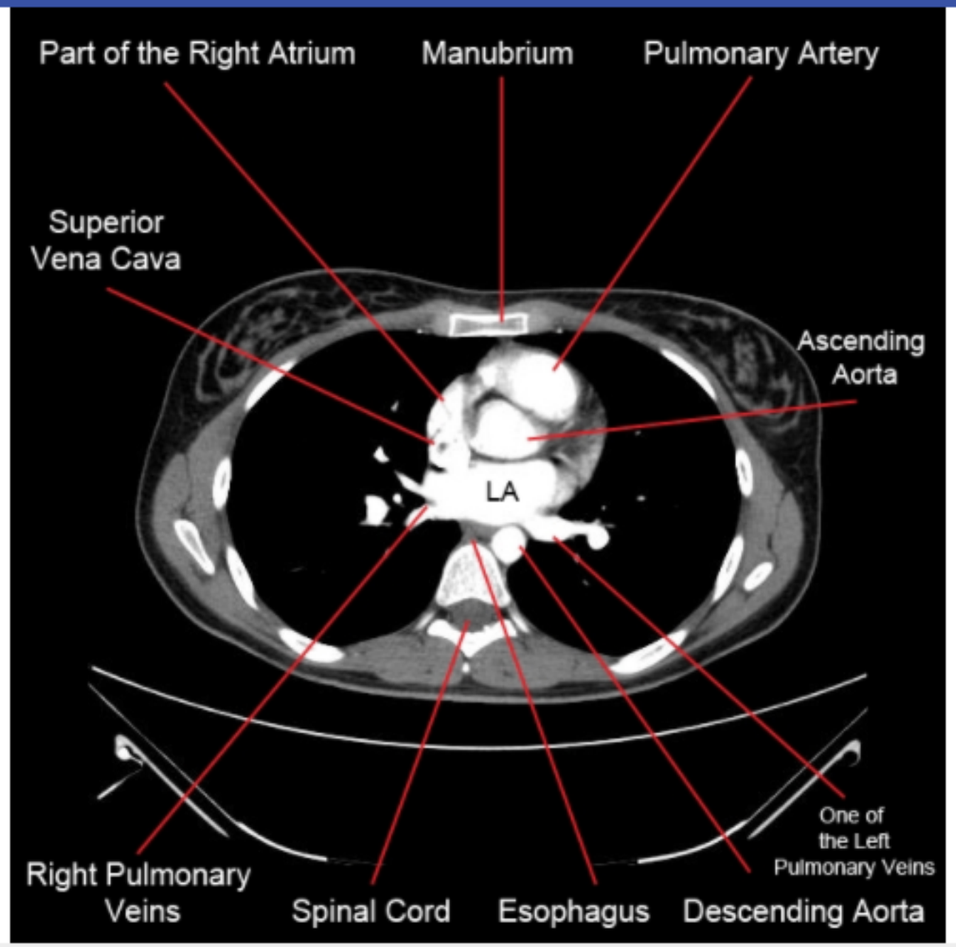

Zoom In | Zoom Out | Reset | Add To New Card | Existing Card

Subject System Topic

A 51-year-old man is brought to the emergency department due to chest tightness that started 30 minutes prior to arrival. His chest discomfort is associated with shortness of breath and nausea. The patient was shoveling snow off his driveway when his symptoms began. He has a history of hypertension and type 2 diabetes mellitus. Initial ECG shows ST elevation in leads I and aVL. Cardiac enzymes are elevated. Emergent cardiac catheterization in this patient will most likely show occlusion of which of the following arteries?

A. Distal left anterior descending artery

B. Left circumflex artery

C. Left main coronary artery

D. Proximal left anterior descending artery

E. Right coronary artery

Submit

A 51-year-old man is brought to the emergency department due to chest tightness that started 30 minutes prior to arrival. His chest discomfort is associated with shortness of breath and nausea. The patient was shoveling snow off his driveway when his symptoms began. He has a history of hypertension and type 2 diabetes mellitus. Initial ECG shows ST elevation in leads I and aVL. Cardiac enzymes are elevated. Emergent cardiac catheterization in this patient will most likely show occlusion of which of the following arteries?

A. Distal left anterior descending artery (13%)
✓ B. Left circumflex artery (55%)
C. Left main coronary artery (5%)
D. Proximal left anterior descending artery (14%)
E. Right coronary artery (11%)

Omitted
Correct answer
B

55%
Answered correctly

02 secs
Time Spent

03/25/2020
Last Updated

Explanation

ECG/anatomy correlation

Exhibit Display

ECG/anatomy correlation

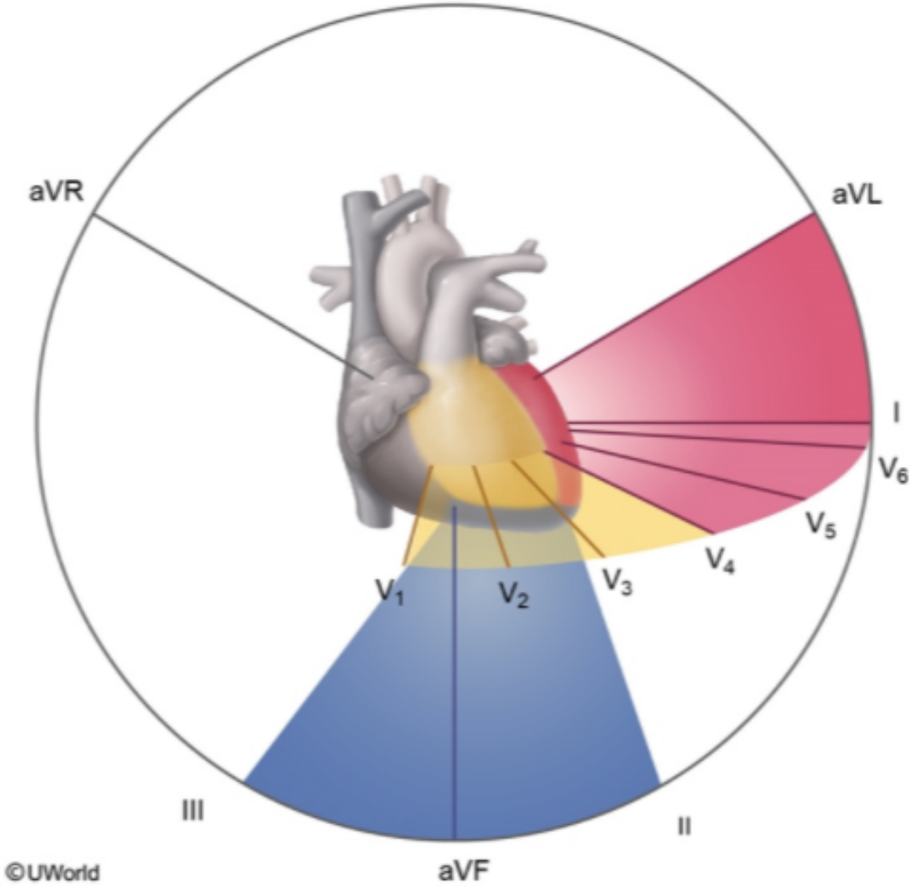

Zoom In | Zoom Out | Reset | Add To New Card | Existing Card

©UWorld

aVF

This patient with **ST elevations** in leads I and aVL most likely has an acute lateral **myocardial infarction** (MI) due to occlusion of the left circumflex artery. ECGs are useful in the diagnosis of MI and may help localize the area of infarction. ST elevations typically represent acute MI, whereas prominent Q waves are suggestive of old MI.

Leads **I and aVL** correspond to the **lateral limb leads** on ECG; therefore, ST elevation or Q waves in these leads are indicative of infarction involving the lateral aspect of the left ventricle. Because the chest leads V5-V6 are also laterally placed, they may also show ST elevation during a lateral infarction. The lateral aspect of the left ventricle is supplied by the **left circumflex artery**, which originates from the left main coronary artery.

(Choices A and D) The left anterior descending artery (LAD) primarily supplies the anterior aspect of the left ventricle and interventricular septum (septal branches), which corresponds to the anterior chest leads (V1-V4). Proximal occlusion of the LAD may involve all of these leads; however, distal LAD occlusion typically spares the septal leads (V1-V2).

(Choice C) The left main coronary artery gives rise to the LAD and left circumflex arteries. Therefore, left main coronary artery occlusion typically results in anterolateral infarction, which corresponds to ST elevation in the anterior (eg, V1-V4) and lateral (V5-V6, I, and aVL) leads.

(Choice E) The right coronary artery typically supplies the right ventricle and inferior aspect of the left ventricle. Occlusion of this vessel therefore results in inferior MI, which corresponds to ST elevation in the inferior leads (II, III, and aVF).

Educational objective:
Leads I and aVL correspond to the lateral limb leads on ECG. Therefore, ST elevation or Q waves in these leads are indicative of infarction involving the lateral aspect of the left ventricle, which is supplied by the left circumflex artery.

References

- The electrocardiogram in ST elevation acute myocardial infarction: correlation with coronary anatomy and prognosis.
- Electrocardiographic localization of coronary artery narrowings: studies during myocardial ischemia and infarction in patients with one-vessel disease.

©UWorld

aVF

Exhibit Display

Coronary arteries, anterior view Coronary Arteries

Coronary arteries: anterior view

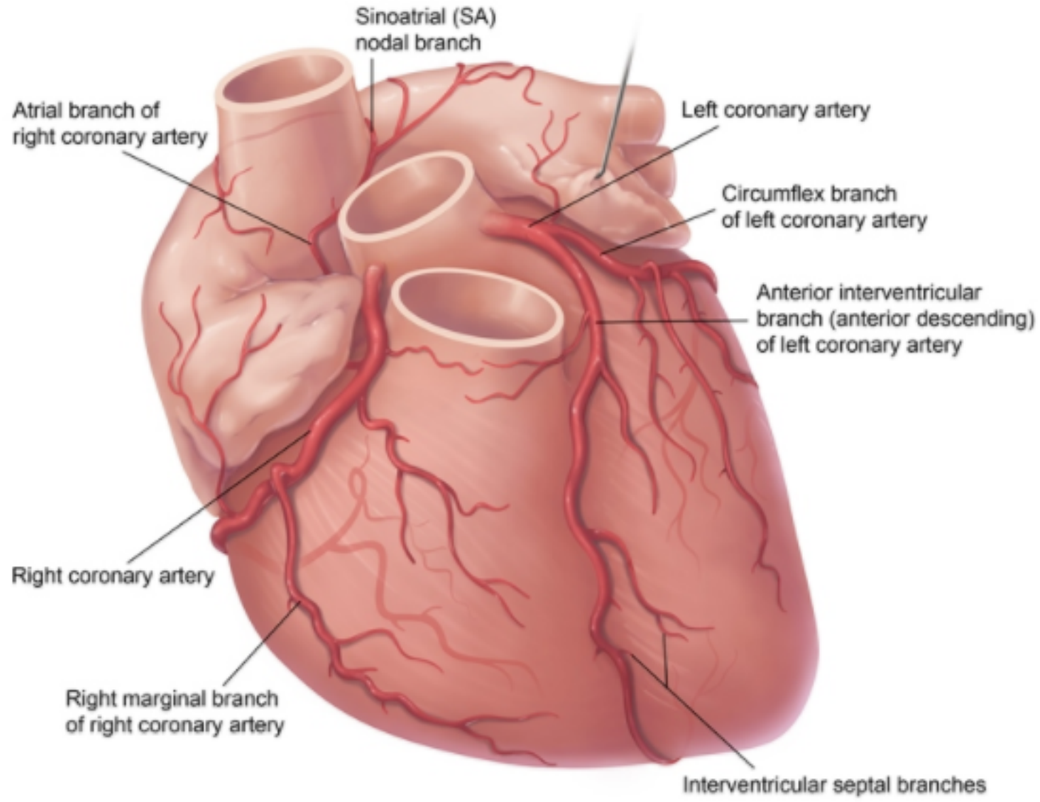

©UWorld

Zoom In Zoom Out Reset Add To New Card | Existing Card

©UWorld

aVF

Exhibit Display

Coronary arteries, anterior view Coronary Arteries

Right dominant circulation: posterior view

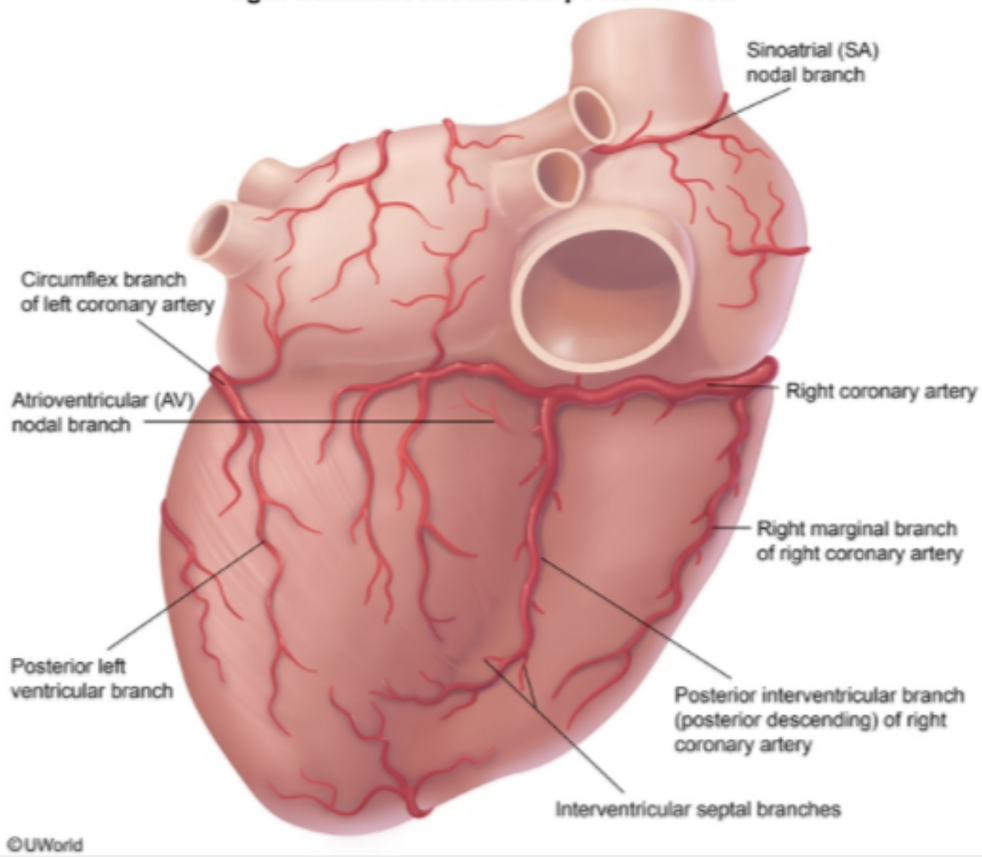

Zoom In Zoom Out Reset Add To New Card | Existing Card

A 53-year-old man is hospitalized due to chest pain and palpitations. Cardiac catheterization is planned to evaluate for coronary artery disease. The femoral artery is palpated in the right groin, and a catheter is introduced into the common femoral artery. The associated vasculature is visualized after injecting a contrast agent into the catheter.

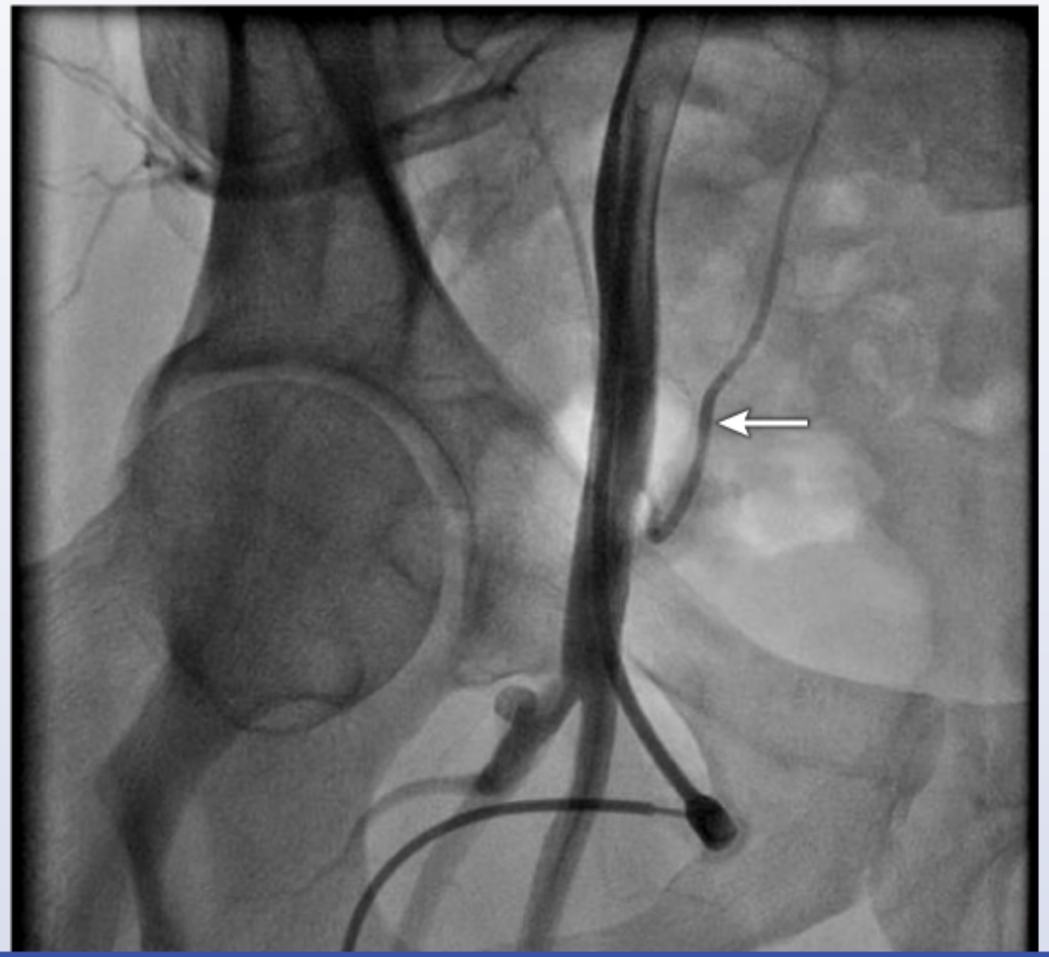

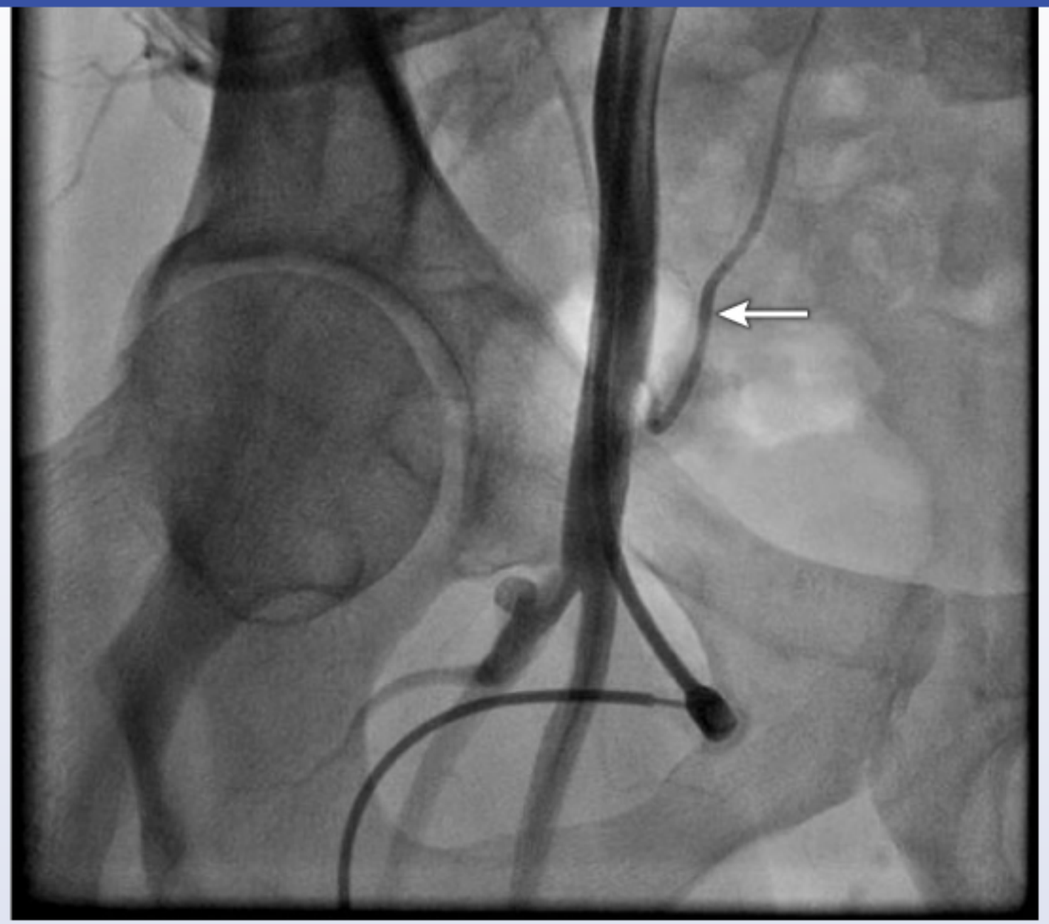

Which of the following is most likely the artery indicated by the arrow in the image above?

A. Inferior epigastric

B. Internal iliac

Which of the following is most likely the artery indicated by the arrow in the image above?

- A. Inferior epigastric
- B. Internal iliac
- C. Medial circumflex femoral
- D. Obturator
- E. Superior gluteal

Submit

Which of the following is most likely the artery indicated by the arrow in the image above?

- ✓ A. Inferior epigastric (57%)
- B. Internal iliac (7%)
- C. Medial circumflex femoral (13%)
- D. Obturator (9%)
- E. Superior gluteal (11%)

Omitted
Correct answer

57%
Answered correctly

08 secs
Time Spent

01/07/2020
Last Updated

1
2
3
4
5
6
7
8
9
10
11
12
13
14
15
16
17
18
19
20
21
22
23
24
25
26
27
28
29

Inferior epigastric artery

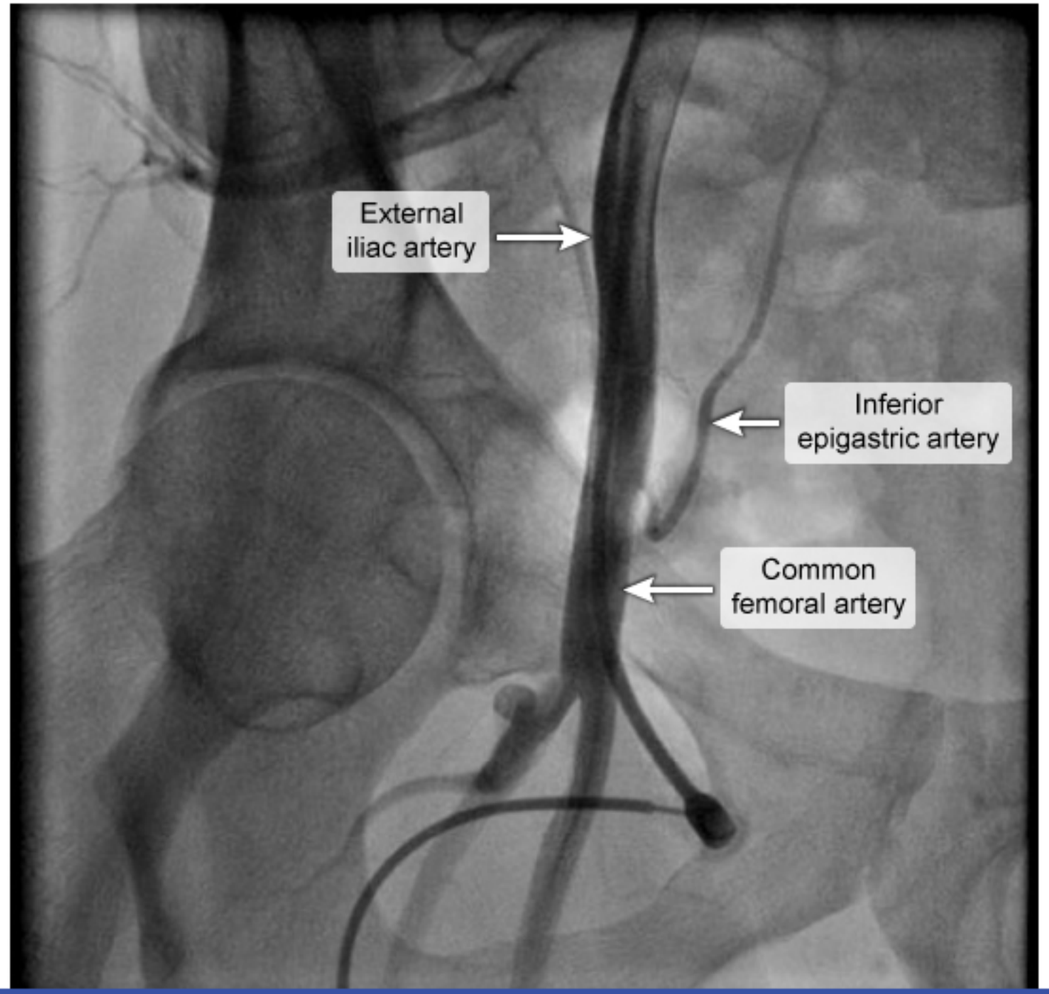

©UWorld

As the aorta courses through the lower abdomen, it divides into the common iliac arteries, which subsequently branch into the internal and external iliac arteries. The **inferior epigastric artery** branches off from the external iliac artery immediately proximal to the inguinal ligament before the external iliac artery becomes the common femoral artery. As the inferior epigastric artery runs **superiorly** and **medially** up the abdomen, it provides blood supply to the lower anterior abdominal wall. The other main branch off the external iliac artery is the deep circumflex iliac artery, which branches more laterally but also supplies blood to the lower abdominal wall.

(Choices B, D, and E) The internal iliac artery supplies most of the structures of the pelvis, gluteal region, and medial thigh. The obturator artery is a branch of the internal iliac artery that runs inferiorly to supply blood to the bladder and medial compartment of the thigh. The superior gluteal artery is the continuation of the internal iliac artery and runs inferiorly to supply blood to the gluteal muscles and a portion of the hip.

(Choice C) The medial circumflex femoral artery branches off the deep femoral artery to supply blood to the femoral neck.

Educational objective:
The inferior epigastric artery branches off the external iliac artery immediately proximal to the inguinal ligament. It provides blood supply to the lower anterior abdominal wall as it runs superiorly and medially up the abdomen.

References

- Percutaneous management of inferior epigastric artery injury after cardiac catheterization.
- Transcatheter coil embolization of the inferior epigastric artery in a huge abdominal wall hematoma caused by paracentesis in a patient with liver cirrhosis.
- Retroperitoneal hemorrhage caused by inferior epigastric artery injury.

Anatomy	Cardiovascular System	Cardiovascular anatomy
Subject	System	Topic

Copyright © UWorld. All rights reserved.

©UWorld

Exhibit Display

Branches of common iliac artery

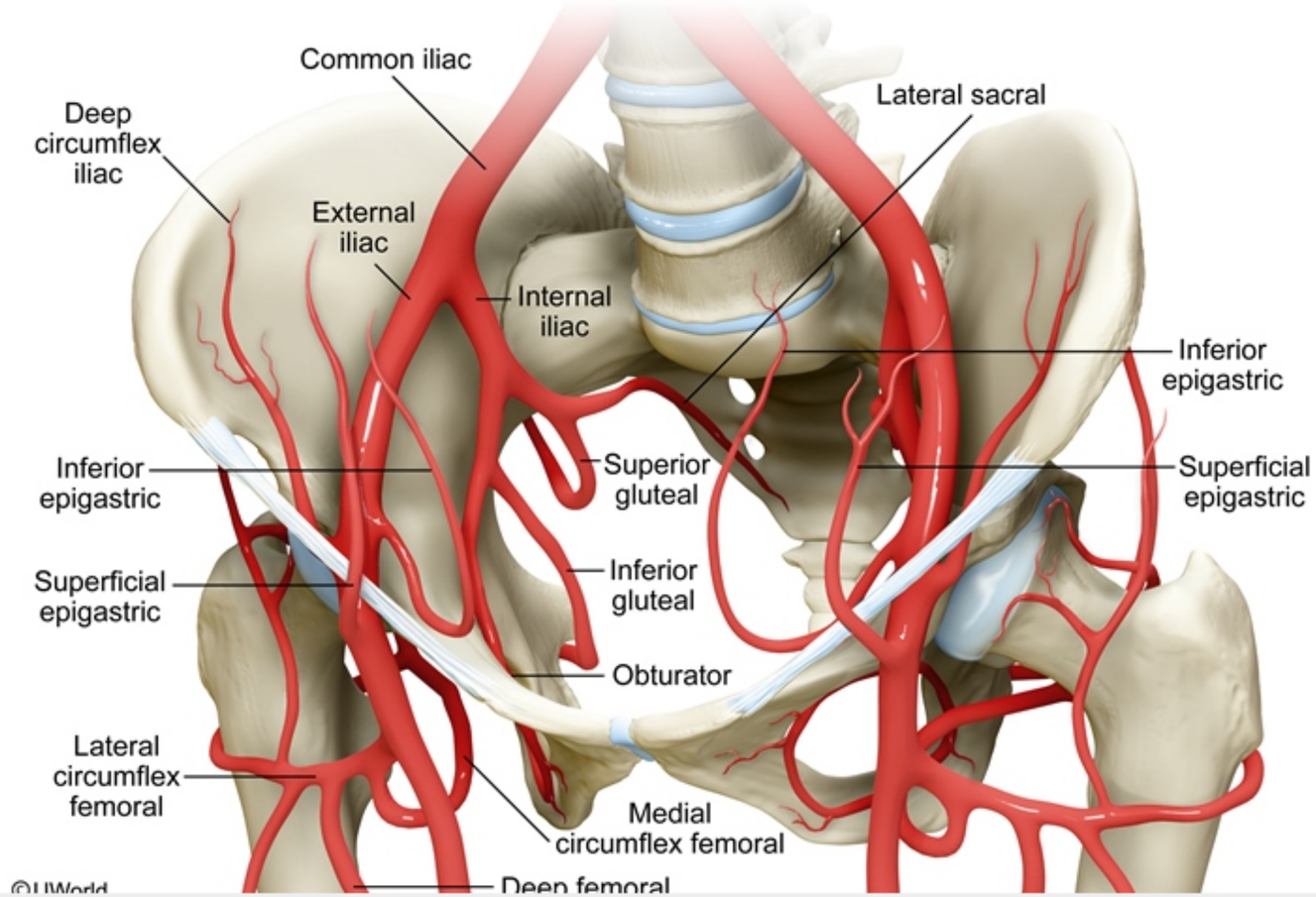

©UWorld

Zoom In | Zoom Out | Reset | Add To New Card | Existing Card

A 5-year-old boy is brought to the office by his parents for evaluation of cyanosis with minimal exertion. The boy has had occasional episodes of "turning blue" that first began during infancy and are now occurring more frequently. During the episodes, the boy assumes a squatting position as it makes him "feel better." The family recently immigrated to the United States; the boy has never had a medical checkup prior to this visit. Physical examination reveals a prominent right ventricular impulse and a harsh systolic murmur. Which of the following embryological events is the most likely mechanism that caused this patient's condition?

- A. Anomalous pulmonary venous return
- B. Aortic arch constriction
- C. Deviation of the infundibular septum
- D. Endocardial cushion defect
- E. Linear development of the aorticopulmonary septum

Submit

A 5-year-old boy is brought to the office by his parents for evaluation of cyanosis with minimal exertion. The boy has had occasional episodes of "turning blue" that first began during infancy and are now occurring more frequently. During the episodes, the boy assumes a squatting position as it makes him "feel better." The family recently immigrated to the United States; the boy has never had a medical checkup prior to this visit. Physical examination reveals a prominent right ventricular impulse and a harsh systolic murmur. Which of the following embryological events is the most likely mechanism that caused this patient's condition?

- A. Anomalous pulmonary venous return (5%)
- B. Aortic arch constriction (4%)
- ✓ C. Deviation of the infundibular septum (42%)
- D. Endocardial cushion defect (34%)
- E. Linear development of the aorticopulmonary septum (12%)

Omitted
Correct answer
C

42%
Answered correctly

03 secs
Time Spent

01/22/2020
Last Updated

Explanation

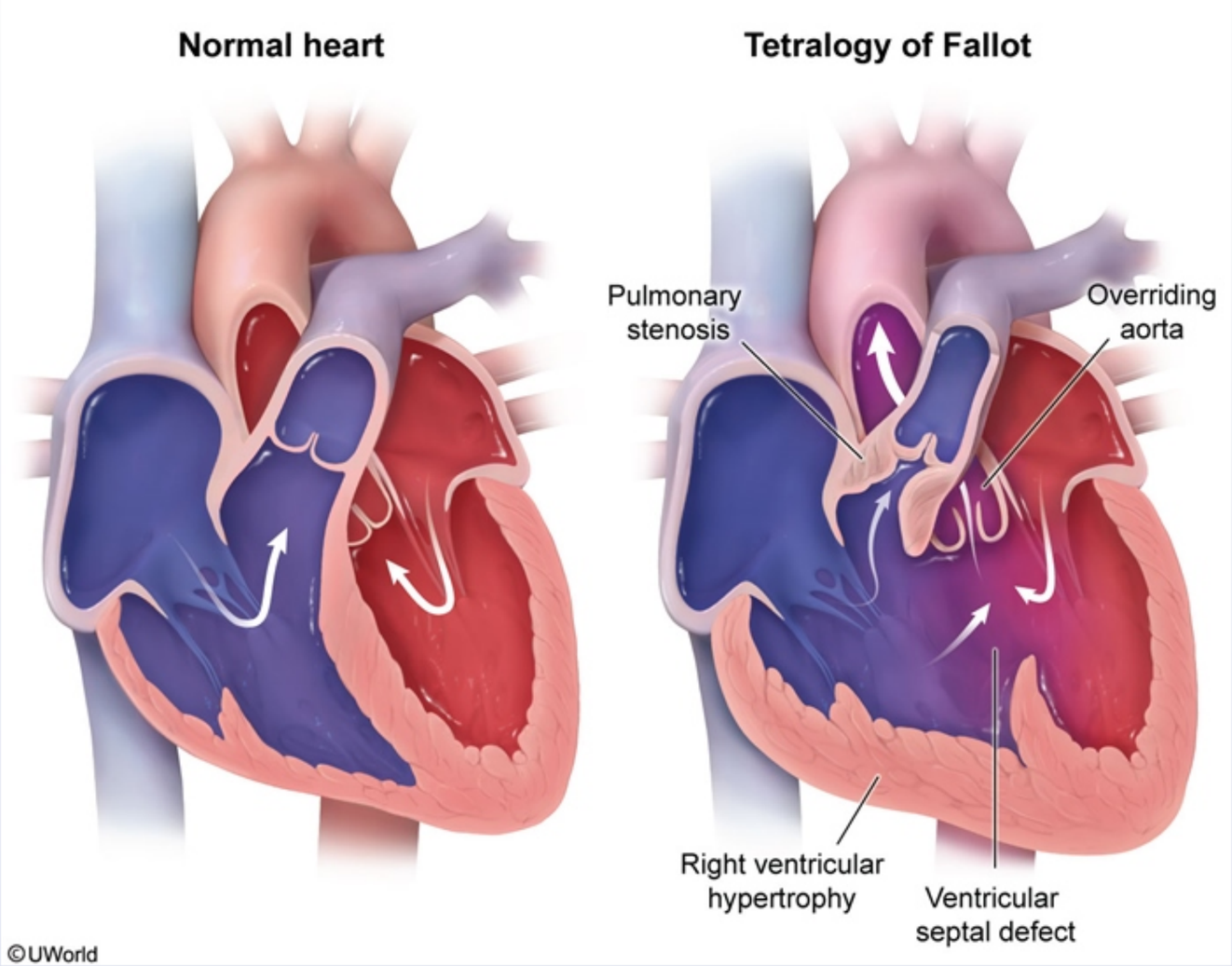

This patient's clinical presentation (**cyanotic spells** that improve with **squatting**, prominent right ventricular impulse, **systolic murmur**) is consistent with tetralogy of Fallot (TOF). Abnormal neural crest cell migration leads to anterior and cephalad deviation of the infundibular septum

This patient's clinical presentation (**cyanotic spells** that improve with **squatting**, prominent right ventricular impulse, **systolic murmur**) is consistent with tetralogy of Fallot (TOF). Abnormal neural crest cell migration leads to anterior and cephalad deviation of the infundibular septum during embryologic development, resulting in a malaligned VSD and an overriding aorta. TOF is characterized by 4 distinct anatomic abnormalities:

- Ventricular septal defect (VSD)
- Overriding aorta over the right and left ventricles
- Right ventricular outflow tract (RVOT) obstruction
- Right ventricular hypertrophy

Cyanosis occurs due to the presence of right-to-left shunt in patients with severe or worsening **RVOT obstruction**. The typical harsh, systolic ejection murmur over the mid-to-left upper sternal border is due to the presence of RVOT obstruction (subvalvular, pulmonary valve stenosis or supravalvular narrowing in the main pulmonary artery). Squatting increases the peripheral systemic vascular resistance (afterload) and decreases the degree of right-to-left shunting across the VSD, thereby improving cyanosis.

(Choice A) In anomalous pulmonary venous return, blood from both the pulmonary (oxygenated) and systemic (deoxygenated) venous systems flow into the right atrium, leading to right atrial and ventricular dilation. Patients also have obligatory right-to-left atrial shunting.

(Choice B) Aortic arch constriction results in coarctation of the aorta and is most commonly located just distal to the left subclavian artery (juxtaductal). Common manifestations include brachial-femoral pulse delay and blood pressure discrepancy between the upper and lower extremities.

(Choice D) Failed fusion of the superior and inferior endocardial cushions (eg, endocardial cushion defect) results in defects of the atrioventricular septum and valves (mitral and tricuspid valves). These typically manifest initially as atrial defects and/or VSDs with left-to-right shunting of blood. Over time, the increased right-sided blood flow leads to pulmonary hypertension with reversal of blood flow through the shunt and development of cyanosis (Eisenmenger syndrome). This patient has had cyanotic symptoms since birth that would not be expected with an isolated endocardial cushion defect.

(Choice E) Transposition of the great arteries results from linear, rather than spiral, development of the aorticopulmonary septum in utero.

- Right ventricular outflow tract (RVOT) obstruction
- Right ventricular hypertrophy

Cyanosis occurs due to the presence of right-to-left shunt in patients with severe or worsening **RVOT obstruction**. The typical harsh, systolic ejection murmur over the mid-to-left upper sternal border is due to the presence of RVOT obstruction (subvalvular, pulmonary valve stenosis or supravalvular narrowing in the main pulmonary artery). Squatting increases the peripheral systemic vascular resistance (afterload) and decreases the degree of right-to-left shunting across the VSD, thereby improving cyanosis.

(Choice A) In anomalous pulmonary venous return, blood from both the pulmonary (oxygenated) and systemic (deoxygenated) venous systems flow into the right atrium, leading to right atrial and ventricular dilation. Patients also have obligatory right-to-left atrial shunting.

(Choice B) Aortic arch constriction results in coarctation of the aorta and is most commonly located just distal to the left subclavian artery (juxtaductal). Common manifestations include brachial-femoral pulse delay and blood pressure discrepancy between the upper and lower extremities.

(Choice D) Failed fusion of the superior and inferior endocardial cushions (eg, endocardial cushion defect) results in defects of the atrioventricular septum and valves (mitral and tricuspid valves). These typically manifest initially as atrial defects and/or VSDs with left-to-right shunting of blood. Over time, the increased right-sided blood flow leads to pulmonary hypertension with reversal of blood flow through the shunt and development of cyanosis (Eisenmenger syndrome). This patient has had cyanotic symptoms since birth that would not be expected with an isolated endocardial cushion defect.

(Choice E) Transposition of the great arteries results from linear, rather than spiral, development of the aorticopulmonary septum in utero.

Educational objective:
Tetralogy of Fallot results from anterior and cephalad deviation of the infundibular septum during embryologic development, resulting in a malaligned ventricular septal defect (VSD) with an overriding aorta. As a result, the patient has right ventricular outflow obstruction (resulting in a systolic murmur) and squats to increase the peripheral systemic vascular resistance (afterload) and decrease right-to-left shunting across the VSD.

References

Evaluation and management of heart murmurs in children

- Right ventricular outflow tract (RVOT) obstruction

Exhibit Display

Supracardiac total anomalous pulmonary venous return

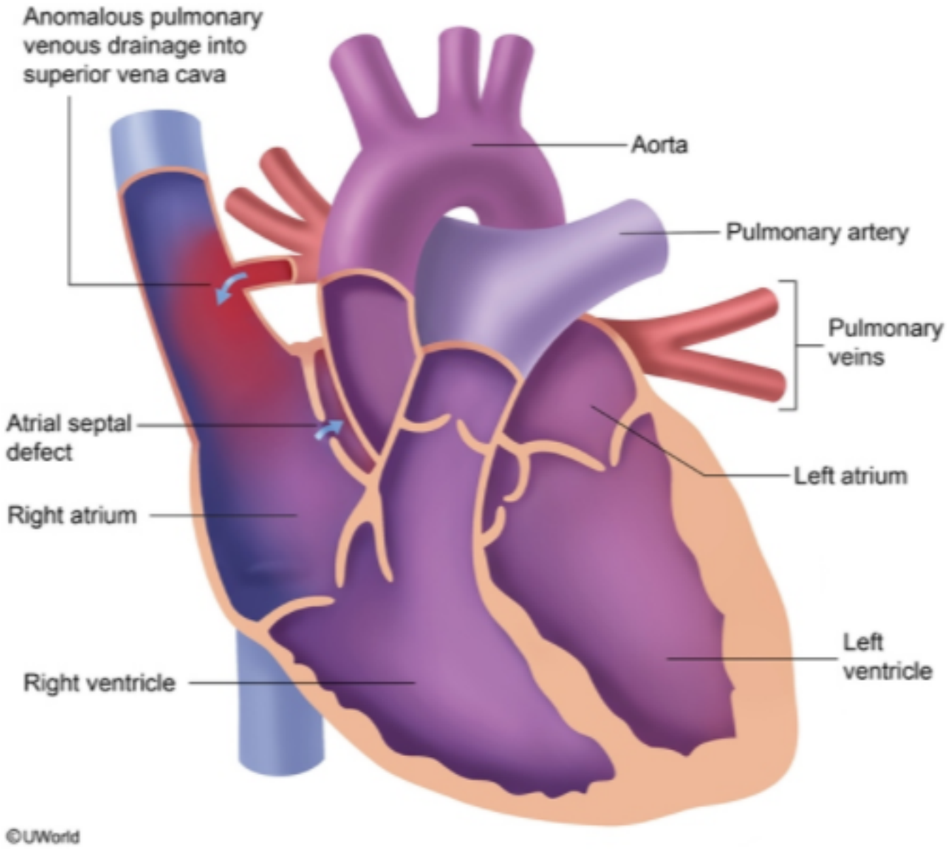

Zoom In | Zoom Out | Reset | Add To New Card | Existing Card

- Right ventricular outflow tract (RVOT) obstruction

Exhibit Display

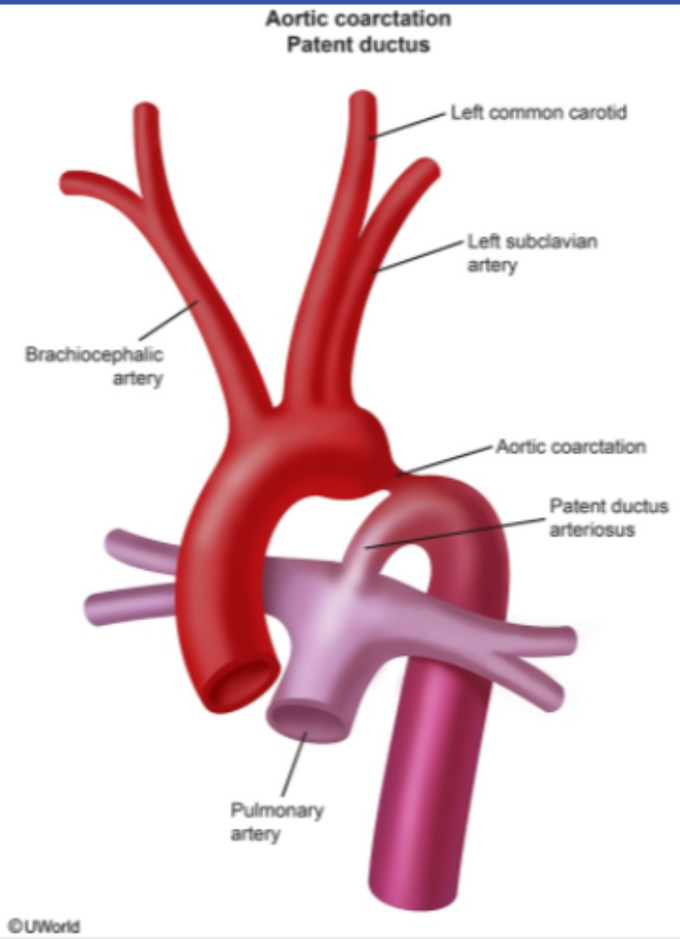

Zoom In | Zoom Out | Reset | Add To New Card | Existing Card

- Right ventricular outflow tract (RVOT) obstruction

Exhibit Display

Eisenmenger syndrome

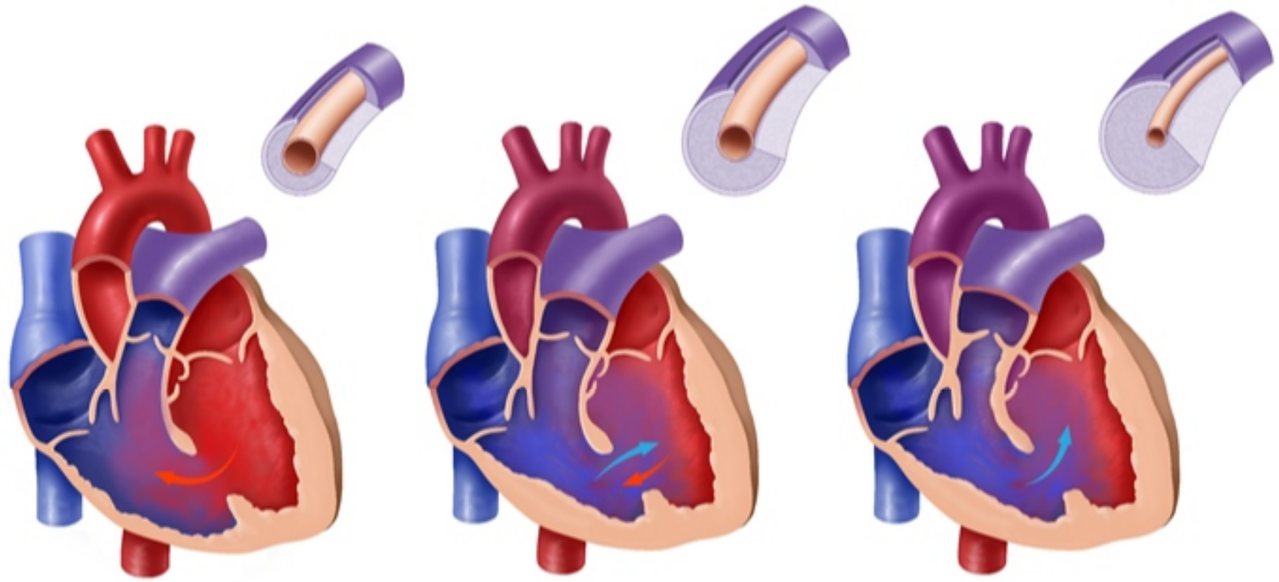

Atrial septal defect, ventricular septal defect, patent ductus arteriosus causes left-to-right shunt

Over time, pulmonary vascular resistance increases leading to bidirectional flow

Pulmonary vascular resistance continues to increase with eventual right-to-left shunt = **Eisenmenger syndrome**

©UWorld

Zoom In | Zoom Out | Reset | Add To New Card | Existing Card

- Right ventricular outflow tract (RVOT) obstruction

Exhibit Display

Transposition of the great vessels

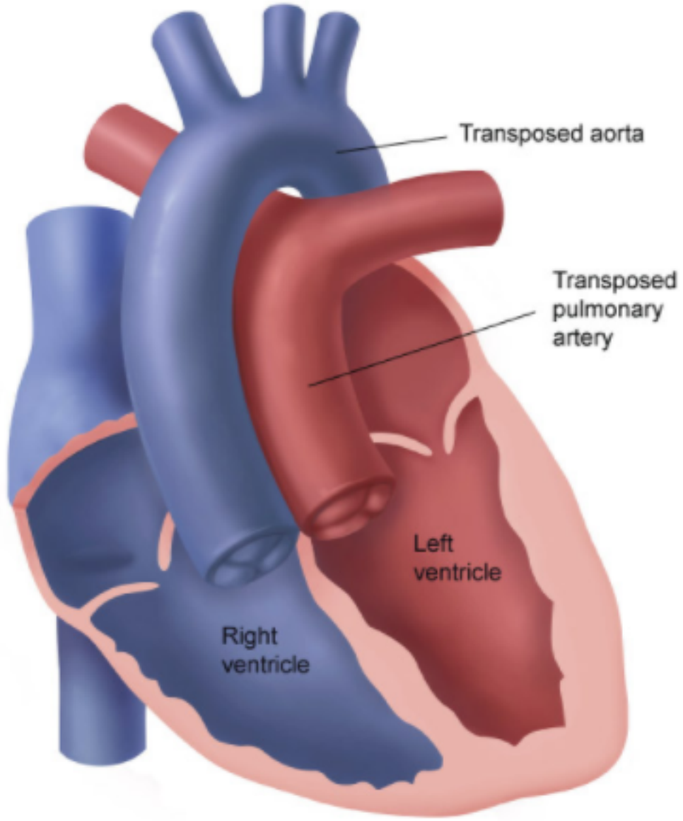

©UWorld

Zoom In | Zoom Out | Reset | Add To New Card | Existing Card

A 2-day-old infant is dusky and irritable. He was born to a 22-year-old primigravida with sporadic prenatal care. Delivery was uncomplicated, and Apgar scores were 7 and 8 at 1 and 5 minutes, respectively. His temperature is 36.7 C (98 F), blood pressure is 70/30 mm Hg, pulse is 148/min, and respiratory rate is 68/min. Physical examination shows a cyanotic and irritable newborn with mild-to-moderate respiratory distress. Auscultation reveals a continuous, machine-like murmur appreciated between the scapulae. Serum lactate is elevated. Echocardiogram shows the aorta lying anterior, inferior, and to the right of the pulmonary artery. Failure of which of the following embryologic processes is most likely responsible for this patient's condition?

- A. Apoptosis
- B. Fusion
- C. Obliteration
- D. Proliferation
- E. Septation
- F. Spiraling

Submit

A 2-day-old infant is dusky and irritable. He was born to a 22-year-old primigravida with sporadic prenatal care. Delivery was uncomplicated, and Apgar scores were 7 and 8 at 1 and 5 minutes, respectively. His temperature is 36.7 C (98 F), blood pressure is 70/30 mm Hg, pulse is 148/min, and respiratory rate is 68/min. Physical examination shows a cyanotic and irritable newborn with mild-to-moderate respiratory distress. Auscultation reveals a continuous, machine-like murmur appreciated between the scapulae. Serum lactate is elevated. Echocardiogram shows the aorta lying anterior, inferior, and to the right of the pulmonary artery. Failure of which of the following embryologic processes is most likely responsible for this patient's condition?

- A. Apoptosis (2%)
- B. Fusion (4%)
- C. Obliteration (12%)
- D. Proliferation (0%)
- E. Septation (10%)
- ✓ F. Spiraling (68%)

Omitted
Correct answer
F

68%
Answered correctly

02 secs
Time Spent

04/06/2020
Last Updated

Explanation

Formation of aorta, pulmonary

Formation of aorta, pulmonary trunk, & interventricular septum

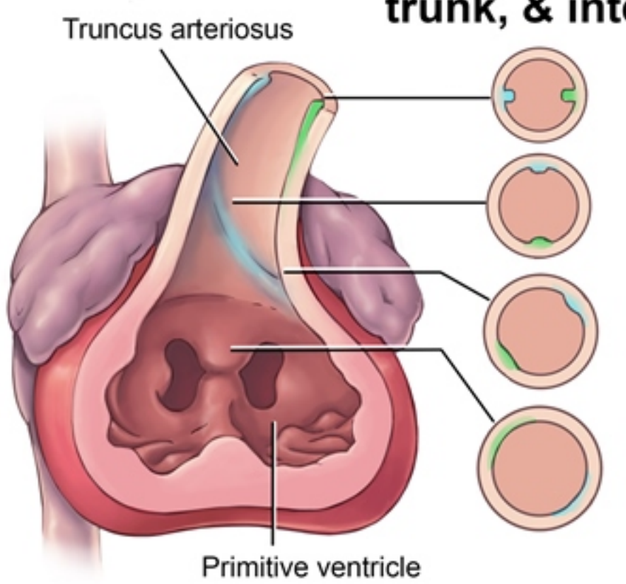

1. Ridges appear at opposite sides of truncal lumen

2. Truncal ridges grow toward each other

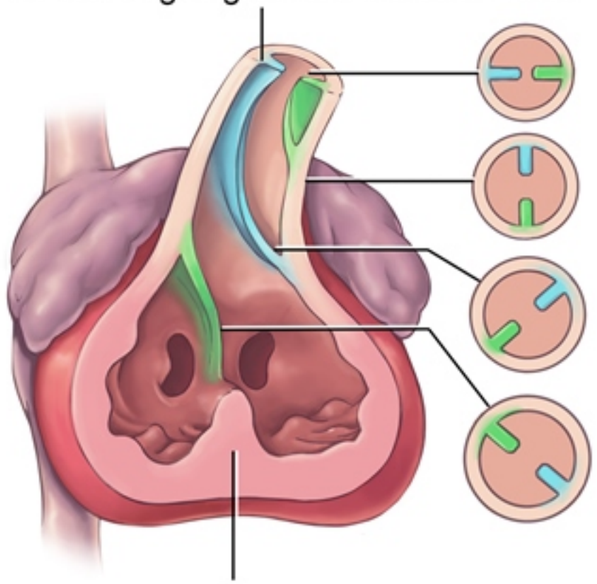

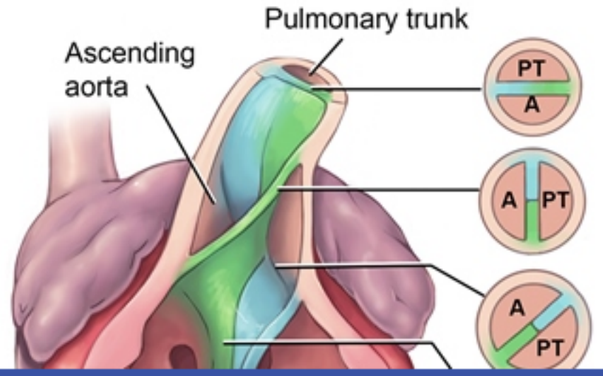

3. Cells at ventricle base grow toward endocardial cushions, and form the muscular part of the interventricular septum

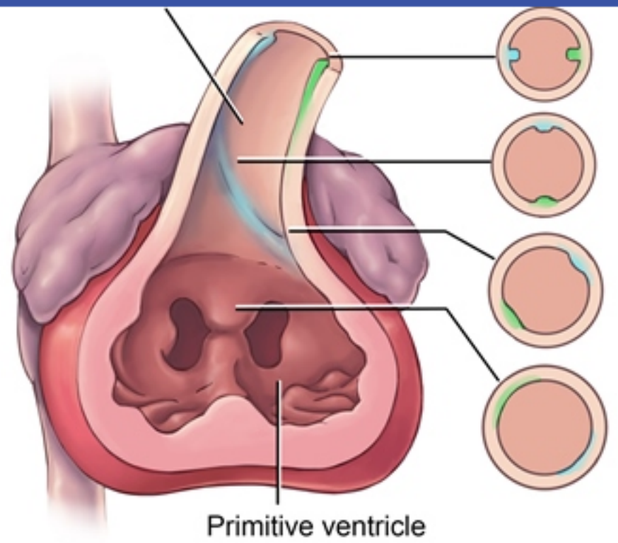

1. Ridges appear at opposite sides of truncal lumen

2. Truncal ridges grow toward each other

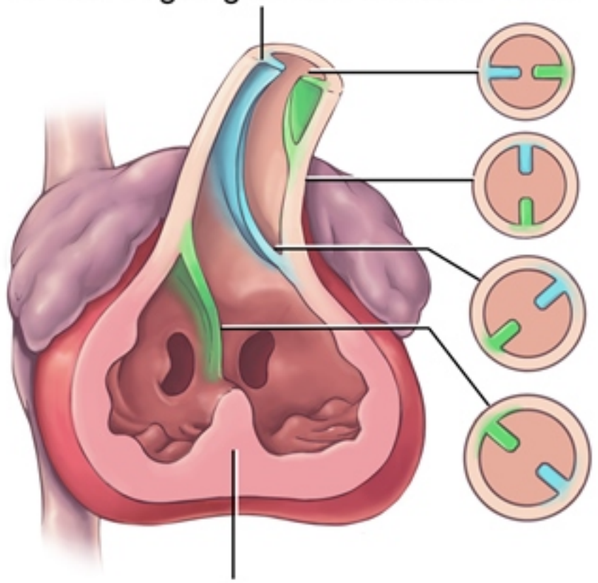

3. Cells at ventricle base grow toward endocardial cushions, and form the muscular part of the interventricular septum

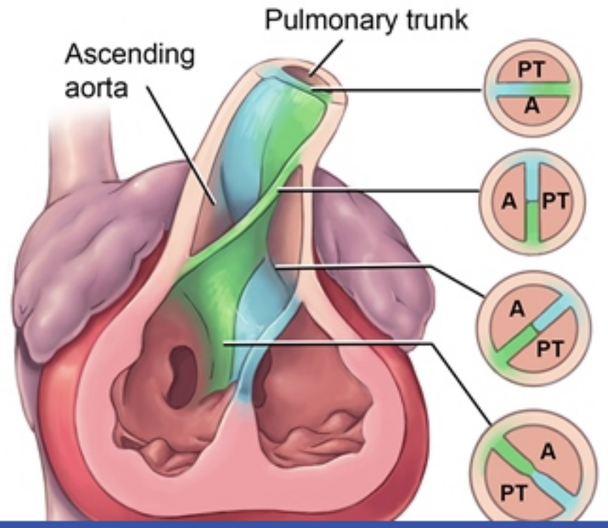

4. Spiraling of aorticopulmonary septum results in pulmonary trunk anterior to aorta

Exhibit Display

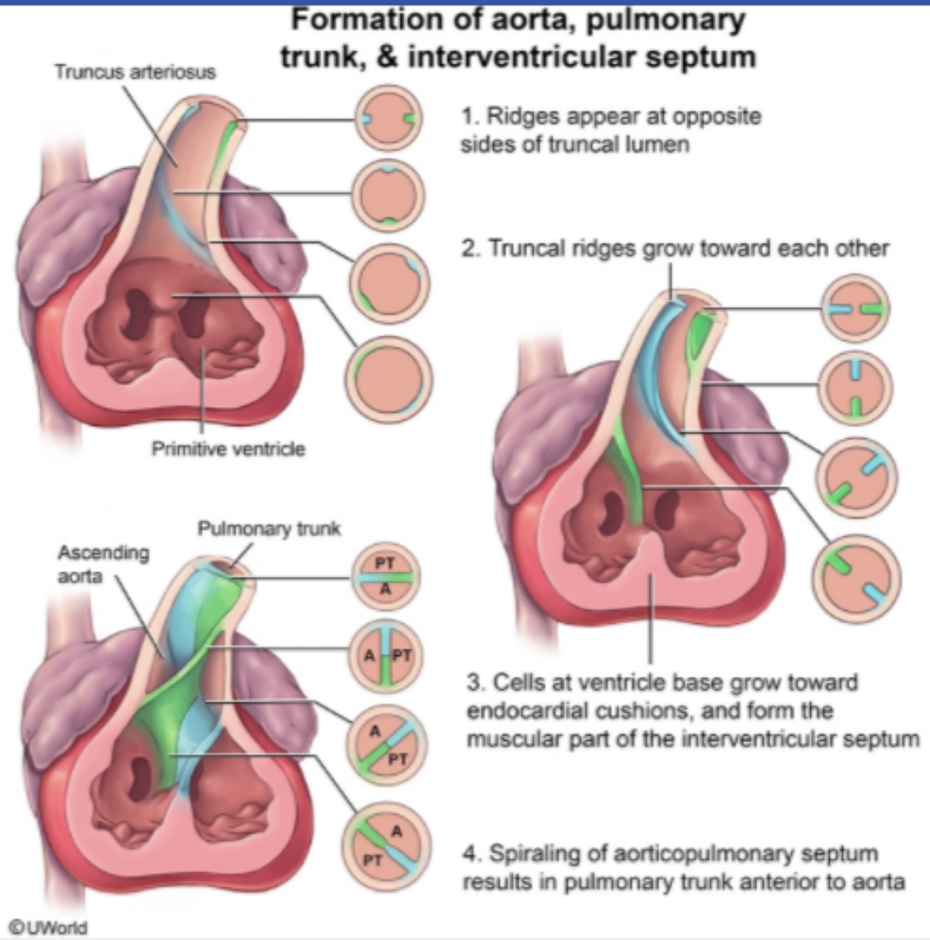

Zoom In | Zoom Out | Reset | Add To New Card | Existing Card

The clinical and echocardiographic findings in this cyanotic neonate are consistent with transposition of the great arteries (TGA). The etiology of TGA is due to linear (rather than spiral) **development of the aorticopulmonary septum** in utero, resulting in an anteriorly positioned aorta connected to the right ventricle and a posteriorly positioned pulmonary artery connected to the left ventricle. Therefore, pulmonary and systemic circulations are abnormally separated and exist as 2 **parallel circulations**.

TGA is incompatible with life unless there is another coexisting connection, such as a patent foramen ovale, septal defect, or **patent ductus arteriosus** (PDA), to allow **mixing** of oxygenated pulmonary circulation blood with the systemic circulation. Patients may be normal on initial presentation but will become cyanotic, tachypneic, and tachycardic as the PDA (machine-like murmur) begins to close, which typically occurs at age 1-3 days. Elevated lactate in this patient signifies anaerobic metabolism in the presence of poorly oxygenated blood.

(Choice A) Failure of apoptosis of the tissue between the digits can result in syndactyly.

(Choice B) Failure of fusion is seen in hypospadias (failure of urethral folds to fuse).

(Choice C) A branchial cleft cyst results from failure of obliteration of the second branchial cleft. The cysts usually present as a draining sinus at the angle of the mandible.

(Choice D) The membranous portion of the interventricular septum results from proliferation of endocardial cushions. Failure of this proliferation leads to a membranous ventricular septal defect (VSD) that can present as a holosystolic murmur if small, or cyanosis if large. However, the aorta should lie posterior to the pulmonary artery (the normal configuration).

(Choice E) Failure of conotruncal septation results in persistent truncus arteriosus, which can present with cyanosis and respiratory distress, although an echocardiogram will show a single arterial trunk overriding a large VSD.

Educational objective:
An echocardiogram showing an aorta lying anterior to the pulmonary artery is diagnostic of transposition of the great arteries (TGA). This life-threatening cyanotic condition results from failure of the fetal aorticopulmonary septum to spiral normally during septation of the truncus arteriosus.

References

- Clinical presentations of critical cardiac defects in the newborn: Decision making and initial management.

Exhibit Display

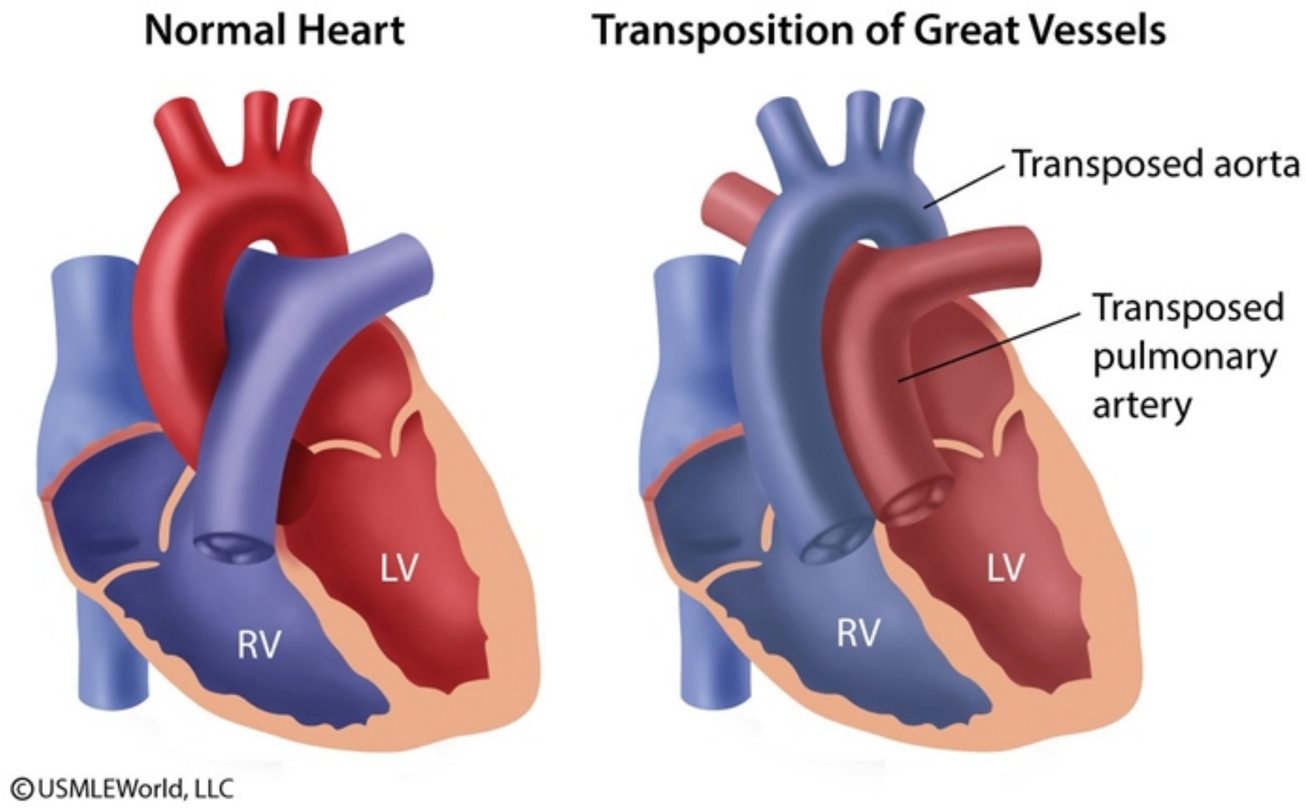

Zoom In | Zoom Out | Reset | Add To New Card | Existing Card

- Clinical presentations of critical cardiac defects in the newborn. Decision making and initial management.

Exhibit Display

Zoom In Zoom Out Reset Add To New Card | Existing Card

- Clinical presentations of critical cardiac defects in the newborn: Decision making and initial management.

Exhibit Display

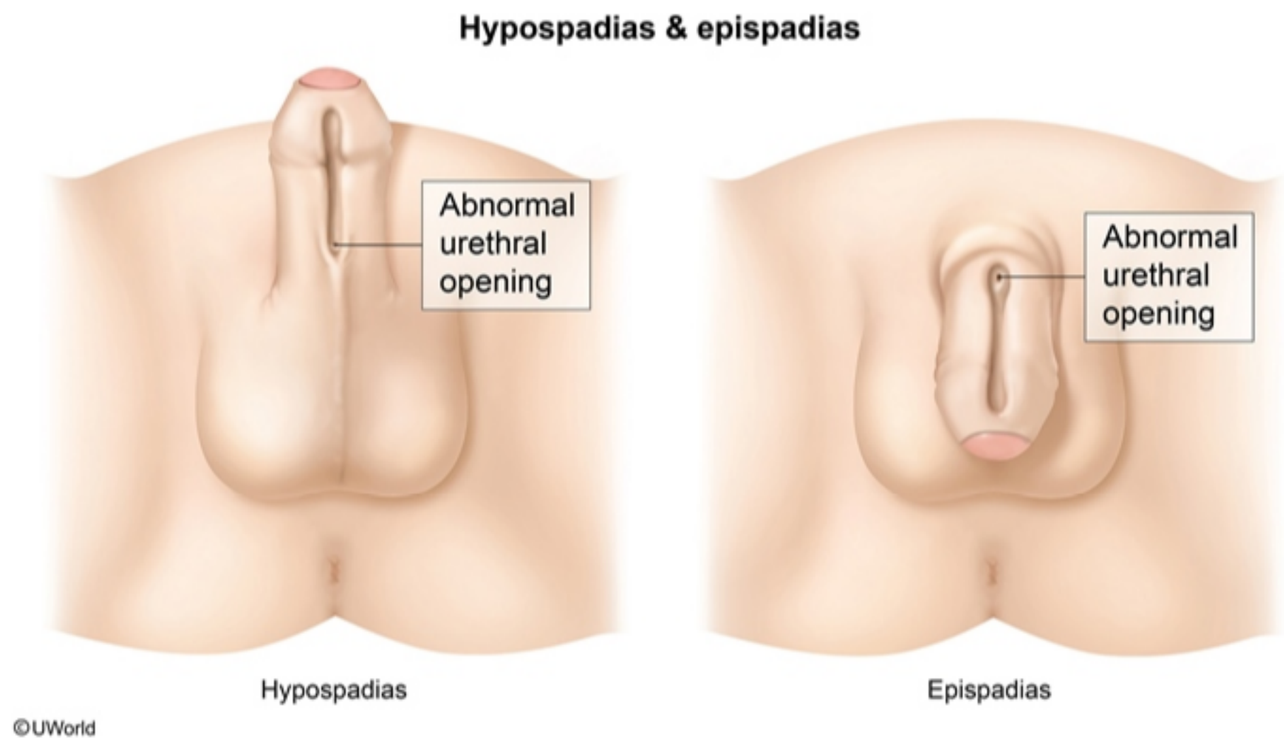

Zoom In | Zoom Out | Reset | Add To New Card | Existing Card

- Clinical presentations of critical cardiac defects in the newborn: Decision making and initial management.

Exhibit Display

Truncus arteriosus

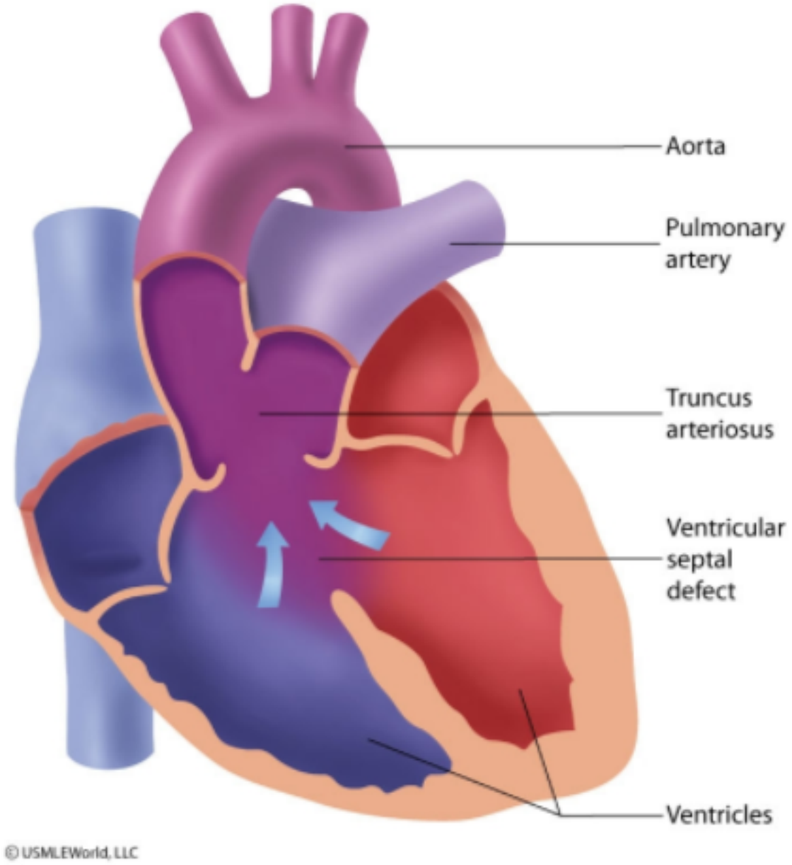

Zoom In | Zoom Out | Reset | Add To New Card | Existing Card

- Clinical presentations of critical cardiac defects in the newborn. Decision making and initial management.

A 64-year-old man loses consciousness near the entrance to an emergency room. A physician rushes to the patient and palpates a strong pulse along the inner side of the left sternocleidomastoid muscle. The vessel palpated by the doctor is a derivative of which of the following aortic arches?

A. First

B. Second

C. Third

D. Fourth

E. Sixth

Submit

A 64-year-old man loses consciousness near the entrance to an emergency room. A physician rushes to the patient and palpates a strong pulse along the inner side of the left sternocleidomastoid muscle. The vessel palpated by the doctor is a derivative of which of the following aortic arches?

- A. First (7%)
- B. Second (23%)
- ✓ C. Third (51%)
- D. Fourth (12%)
- E. Sixth (5%)

Omitted
Correct answer
C

51%
Answered correctly

02 secs
Time Spent

04/15/2020
Last Updated

Explanation

Arches & associated cranial nerves		
Pharyngeal and aortic arch	**Cranial nerve**	**Key aortic arch derivatives**
1	Trigeminal (CN V)	Maxillary artery (portion)

Arches & associated cranial nerves		
Pharyngeal and aortic arch	**Cranial nerve**	**Key aortic arch derivatives**
1	Trigeminal (CN V)	Maxillary artery (portion)
2	Facial (CN VII)	Stapedial artery (regresses)
3	Glossopharyngeal (CN IX)	Common carotid artery, proximal internal carotid artery
4	Superior laryngeal branch of vagus (CN X)	True aortic arch, subclavian arteries
5	Obliterated	Obliterated
6	Recurrent laryngeal branch of CN X	Pulmonary arteries, ductus arteriosus

During embryonic development, the head, neck, and upper thorax region develop from a set of arches known as **pharyngeal arches**. Each arch is associated with a cranial nerve and an aortic arch derivative. The vessel palpated in this patient is the **common carotid artery**, which (along with the proximal portion of the internal carotid artery) is derived from the **third aortic arch** (ie, third pharyngeal arch). The third pharyngeal arch also gives rise to the glossopharyngeal nerve (CN IX), parts of the hyoid bone, and the stylopharyngeus muscle.

(Choice A) The first pharyngeal arch is associated with the trigeminal nerve (CN V). This pharyngeal arch gives rise to the tensor tympani, muscles of mastication, maxilla, and inner ear bones (eg, incus, malleus). The associated first aortic arch regresses almost completely, although it does give rise to a portion of the maxillary artery.

During embryonic development, the head, neck, and upper thorax region develop from a set of arches known as **pharyngeal arches**. Each arch is associated with a cranial nerve and an aortic arch derivative. The vessel palpated in this patient is the **common carotid artery**, which (along with the proximal portion of the internal carotid artery) is derived from the **third aortic arch** (ie, third pharyngeal arch). The third pharyngeal arch also gives rise to the glossopharyngeal nerve (CN IX), parts of the hyoid bone, and the stylopharyngeus muscle.

(Choice A) The first pharyngeal arch is associated with the trigeminal nerve (CN V). This pharyngeal arch gives rise to the tensor tympani, muscles of mastication, maxilla, and inner ear bones (eg, incus, malleus). The associated first aortic arch regresses almost completely, although it does give rise to a portion of the maxillary artery.

(Choice B) The second pharyngeal arch is associated with the facial nerve (CN VII). This pharyngeal arch gives rise to the muscles of facial expression as well as some ear and hyoid structures. The stapedial artery is a derivative of the associated second aortic arch, but this vessel typically regresses.

(Choice D) The fourth pharyngeal arch is associated with the superior laryngeal branch of the vagus nerve (CN X). This pharyngeal arch gives rise to many of the muscles of the pharynx and soft palate as well as a few of the laryngeal muscles. The associated fourth aortic arch gives rise to part of the true aortic arch and subclavian arteries.

(Choice E) The sixth pharyngeal arch is associated with the recurrent laryngeal branches of CN X. This pharyngeal arch gives rise to most of the muscles of the larynx, and the associated aortic arch gives rise to the pulmonary arteries and the ductus arteriosus.

Educational objective:
The common carotid artery and the proximal portion of the internal carotid artery are derived from the third aortic arch. The third aortic arch is associated with the third pharyngeal arch, which gives rise to the glossopharyngeal nerve (CN IX), parts of the hyoid bone, and the stylopharyngeus muscle.

Embryology	Cardiovascular System	Embryologic derivatives
Subject	System	Topic

Exhibit Display

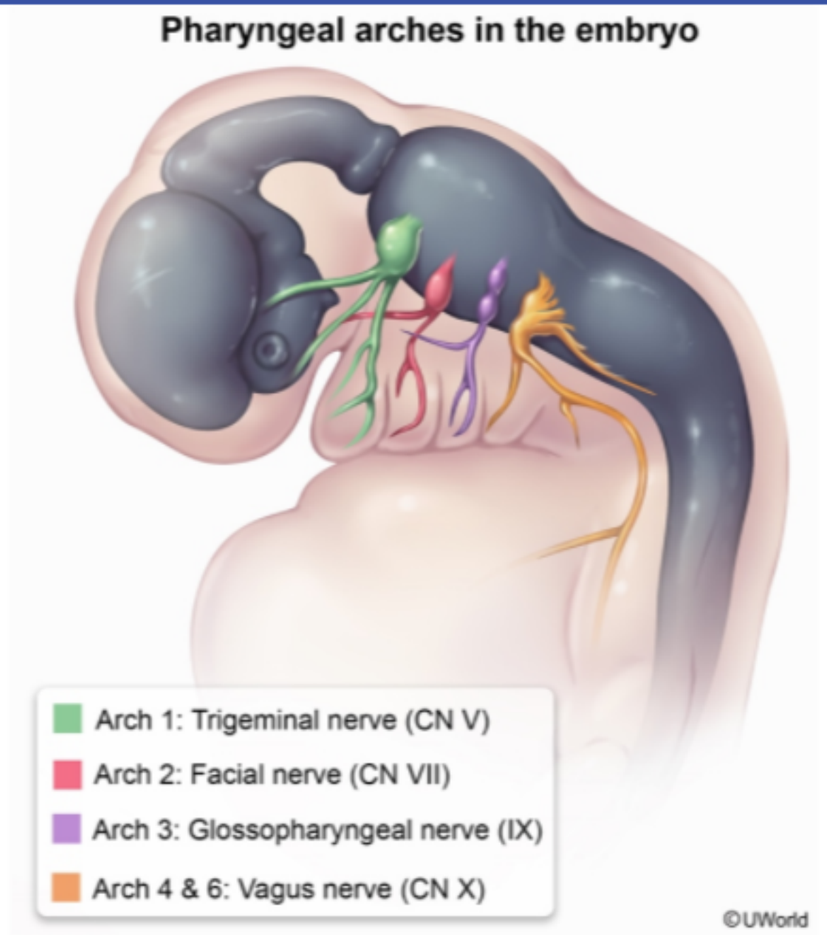

Zoom In | Zoom Out | Reset | Add To New Card | Existing Card

A 37-year-old woman is brought to the emergency department after developing sudden-onset right arm weakness and difficulty speaking. She has no significant medical history but takes oral contraceptives. Examination shows decreased right upper extremity strength and expressive aphasia. Cardiac auscultation is normal. MRI of the brain reveals acute infarction in the left frontal lobe. Further evaluation to determine an etiology is performed. During echocardiogram, agitated normal saline is injected into a peripheral vein and bubbles are seen passing into the left side of the heart. Which of the following is the most likely cause of the observed finding in this patient?

A. Aplasia of the atrial septum secundum

B. Failure of the aorticopulmonary septum to develop

C. Incomplete closure of the interventricular foramen

D. Incomplete fusion of atrial septum primum and secundum

E. Persistent channel between aorta and pulmonary artery

Submit

A 37-year-old woman is brought to the emergency department after developing sudden-onset right arm weakness and difficulty speaking. She has no significant medical history but takes oral contraceptives. Examination shows decreased right upper extremity strength and expressive aphasia. Cardiac auscultation is normal. MRI of the brain reveals acute infarction in the left frontal lobe. Further evaluation to determine an etiology is performed. During echocardiogram, agitated normal saline is injected into a peripheral vein and bubbles are seen passing into the left side of the heart. Which of the following is the most likely cause of the observed finding in this patient?

- A. Aplasia of the atrial septum secundum (9%)
- B. Failure of the aorticopulmonary septum to develop (3%)
- C. Incomplete closure of the interventricular foramen (16%)
- ✓ D. Incomplete fusion of atrial septum primum and secundum (66%)
- E. Persistent channel between aorta and pulmonary artery (4%)

Omitted
Correct answer
D

66%
Answered correctly

02 secs
Time Spent

03/19/2020
Last Updated

Explanation

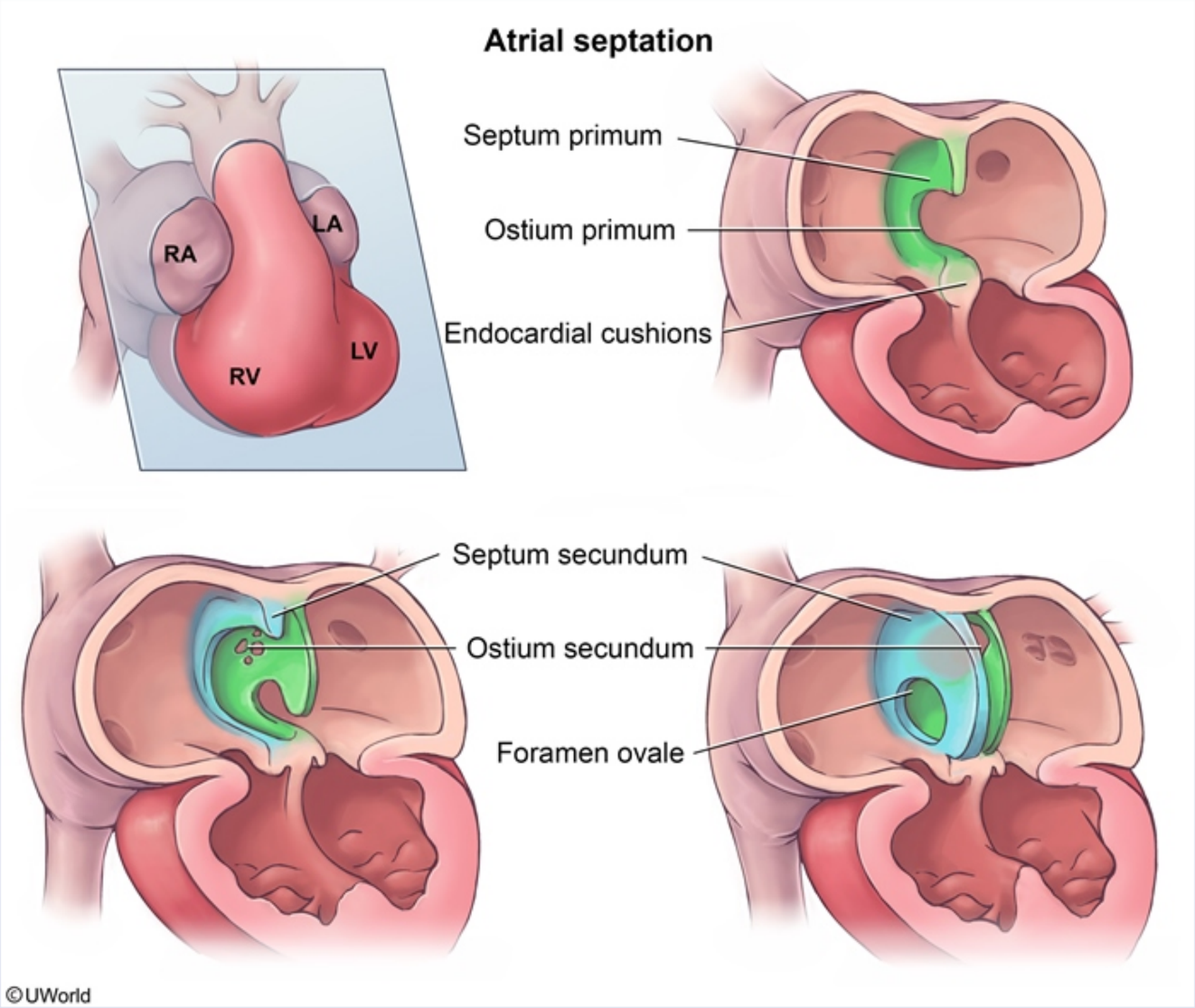
Atrial septation
RA
LA
RV
LV
Septum primum
Ostium primum
Endocardial cushions
Septum secundum
Ostium secundum
Foramen ovale
©UWorld

This young patient had a **cryptogenic stroke**, which is evaluated with echocardiography with a "bubble study" to identify right-to-left intracardiac shunts. This study is performed by injecting agitated normal saline intravenously and observing for microbubbles in the left heart. Shunt detection is improved by having the patient release a sustained Valsalva maneuver, which increases right atrial pressure. Cryptogenic stroke is frequently associated with atrial septal abnormalities such as **patent foramen ovale** (PFO) and atrial septal defect (ASD).

During fetal development, the foramen ovale shunts oxygenated fetal blood across from the right to the left atrium. After delivery, umbilical cord clamping and decreased pulmonary vascular resistance lower right atrial pressure and raise left atrial pressure. This pushes the **septum primum** against the **septum secundum**, closing the foramen ovale. Over time, fibrosis and tissue remodeling fuse the flap closed. **Incomplete fusion** occurs in approximately 25% of normal adults, resulting in a PFO.

PFO usually remains functionally closed and asymptomatic after birth as left atrial pressure is greater than right atrial pressure. However, conditions that raise right atrial pressure above left atrial pressure (eg, Valsalva release) produce a transient right-to-left shunt across the PFO. This is particularly concerning in patients with hypercoagulability (eg, oral contraceptive use) as they are at increased risk for venous thrombosis and **paradoxical brain embolism**. Chronically elevated right heart pressure (eg, Eisenmenger syndrome) is not necessary for paradoxical embolism.

(Choice A) ASD results from aplasia of the septum primum or septum secundum during development. Although ASD may lead to paradoxical embolism, it is much less common than PFO and characterized by fixed splitting of S2. Unrepaired ASDs may lead to heart failure, pulmonary hypertension, or Eisenmenger syndrome.

(Choice B) Incomplete development of the aorticopulmonary septum results in truncus arteriosus, which causes cyanosis in newborns and requires early surgical repair.

(Choice C) Incomplete closure of the interventricular foramen results in ventricular septal defect (VSD), which causes a holosystolic murmur at the lower left sternal border. Large VSDs can cause significant left-to-right shunting, leading to heart failure in infancy; however, VSDs infrequently lead to paradoxical embolism.

(Choice E) The ductus arteriosus functionally closes within 24 hours after delivery. Persistent patent ductus arteriosus causes a continuous murmur and may eventually result in heart failure, pulmonary hypertension, or Eisenmenger syndrome.

conditions that raise right atrial pressure above left atrial pressure (eg, Valsalva release) produce a transient right-to-left shunt across the PFO. This is particularly concerning in patients with hypercoagulability (eg, oral contraceptive use) as they are at increased risk for venous thrombosis and **paradoxical brain embolism**. Chronically elevated right heart pressure (eg, Eisenmenger syndrome) is not necessary for paradoxical embolism.

(Choice A) ASD results from aplasia of the septum primum or septum secundum during development. Although ASD may lead to paradoxical embolism, it is much less common than PFO and characterized by fixed splitting of S2. Unrepaired ASDs may lead to heart failure, pulmonary hypertension, or Eisenmenger syndrome.

(Choice B) Incomplete development of the aorticopulmonary septum results in truncus arteriosus, which causes cyanosis in newborns and requires early surgical repair.

(Choice C) Incomplete closure of the interventricular foramen results in ventricular septal defect (VSD), which causes a holosystolic murmur at the lower left sternal border. Large VSDs can cause significant left-to-right shunting, leading to heart failure in infancy; however, VSDs infrequently lead to paradoxical embolism.

(Choice E) The ductus arteriosus functionally closes within 24 hours after delivery. Persistent patent ductus arteriosus causes a continuous murmur and may eventually result in heart failure, pulmonary hypertension, or Eisenmenger syndrome.

Educational objective:
The foramen ovale is patent in approximately 25% of normal adults. Although the foramen ovale usually remains functionally closed, transient increases of right atrial pressure above left atrial pressure can produce a right-to-left shunt, leading to paradoxical embolism of venous clots into the arterial circulation.

References

- Contemporary approach to paradoxical embolism.
- Patent foramen ovale.

Embryology Cardiovascular System Atrial septal defect

conditions that raise right atrial pressure above left atrial pressure (eg, Valsalva release) produce a transient right-to-left shunt across the PFO.

Exhibit Display

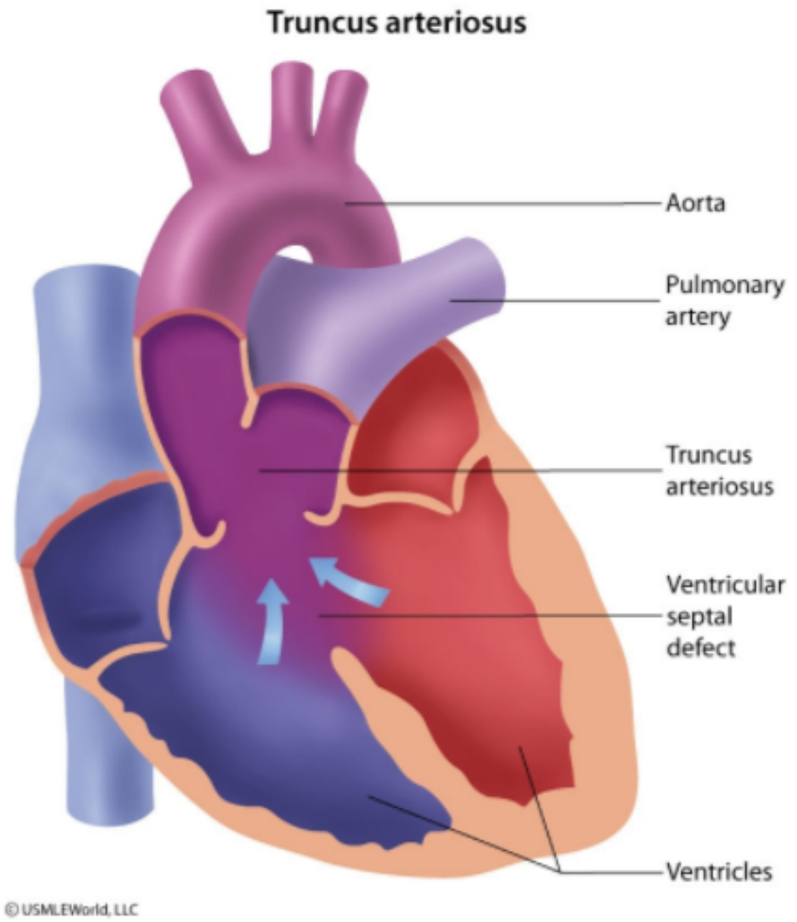

Zoom In | Zoom Out | Reset | Add To New Card | Existing Card

conditions that raise right atrial pressure above left atrial pressure (eg, Valsalva release) produce a transient right-to-left shunt across the PFO.

Exhibit Display

Ventricular septal defect

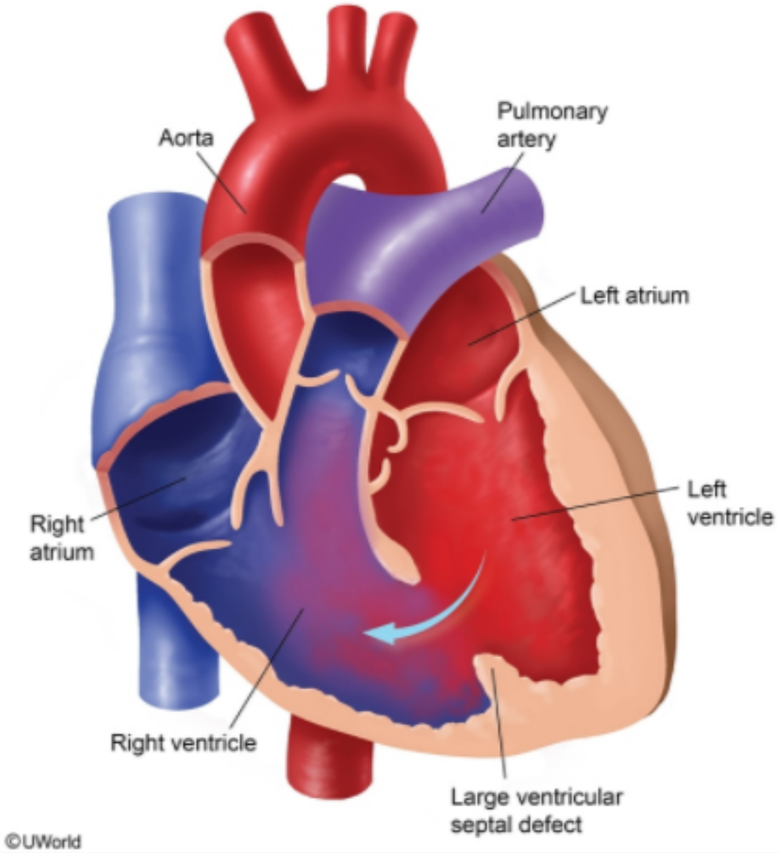

Zoom In | Zoom Out | Reset | Add To New Card | Existing Card

conditions that raise right atrial pressure above left atrial pressure (eg, Valsalva release) produce a transient right-to-left shunt across the PFO.

Exhibit Display

Patent ductus arteriosus

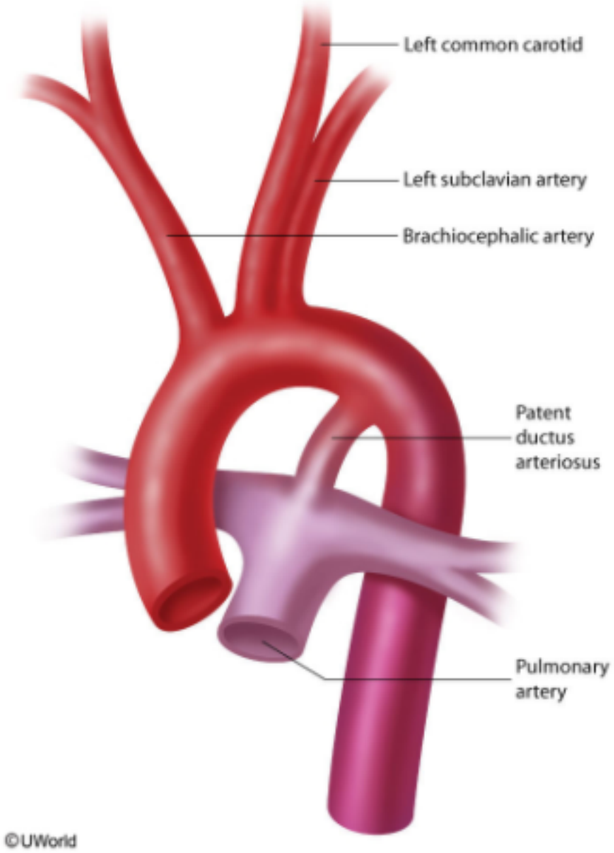

Zoom In | Zoom Out | Reset | Add To New Card | Existing Card

Embryology | Cardiovascular system | Atrial septal defect

Researchers conduct an experiment to determine hemodynamic changes during exercise. Invasive monitoring of various parameters is performed to obtain a left ventricular pressure-volume loop. Compared to at rest, which of the following changes is most likely to be observed during moderate to heavy exercise?

(solid line: at rest; dashed line: during exercise)

A.

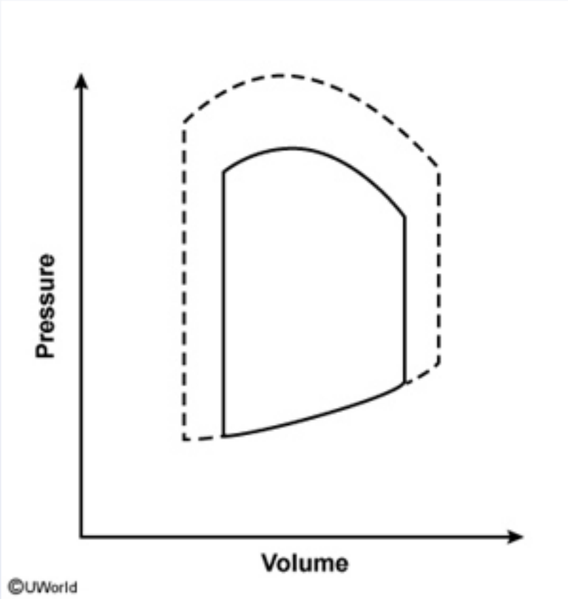

B.

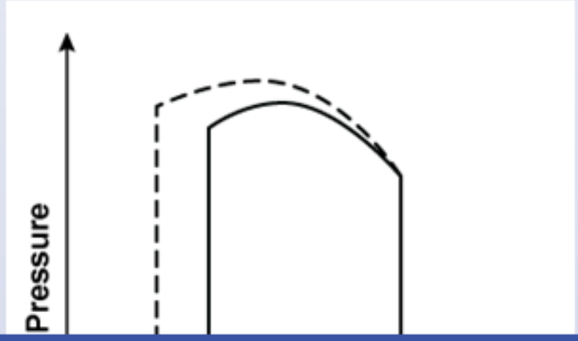

©UWorld

B.

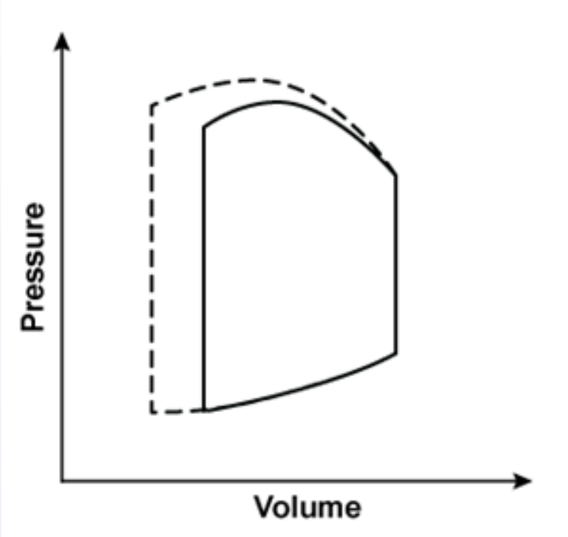

C.

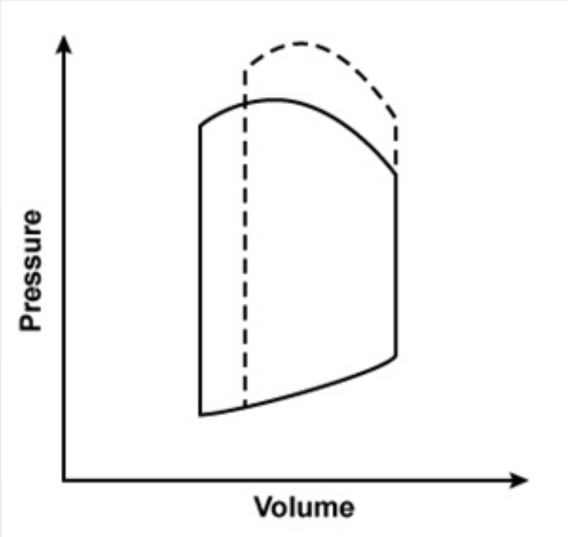

D.

D.

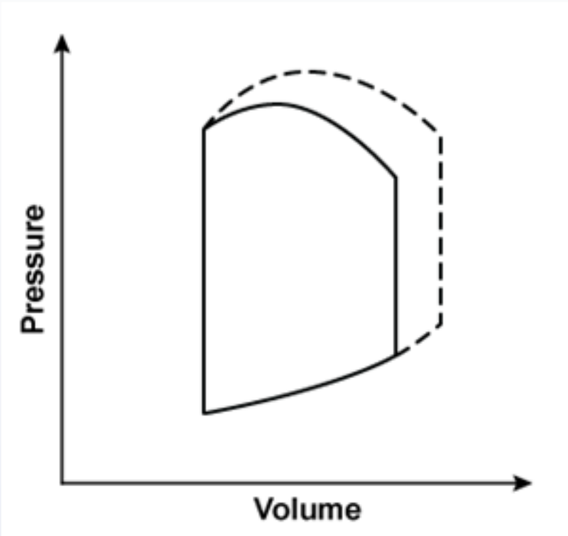

E.

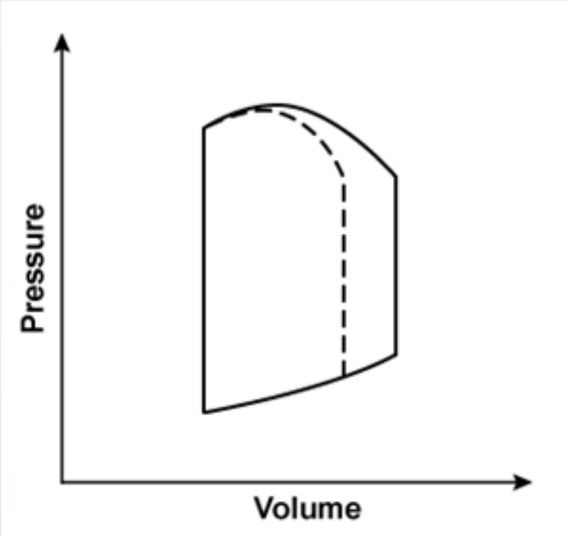

Submit

A. (34%)

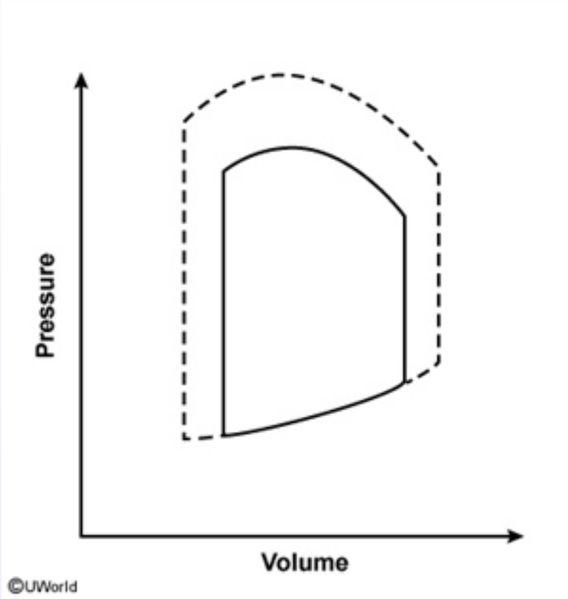

B. (28%)

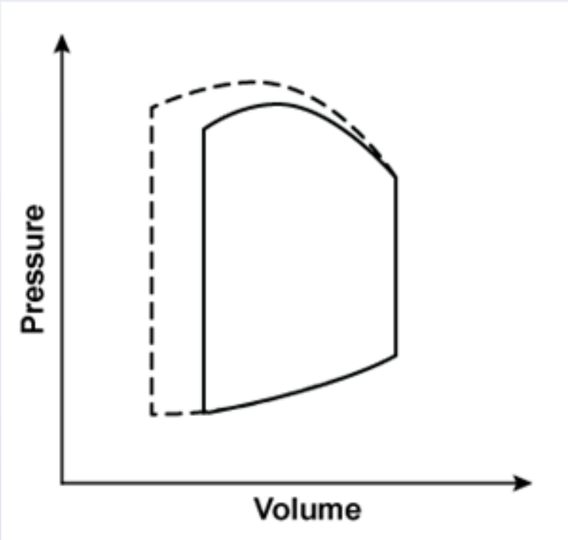

Volume

C. (10%)

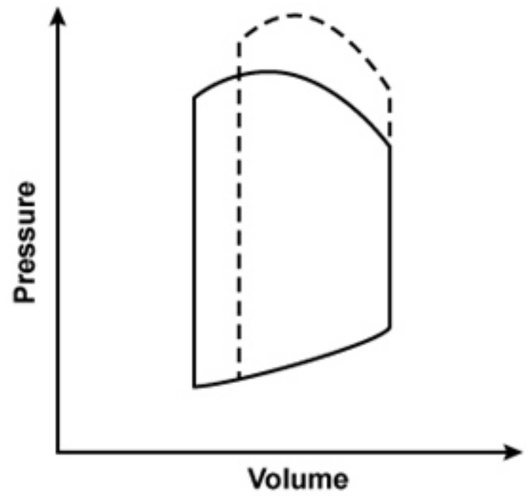

D. (21%)

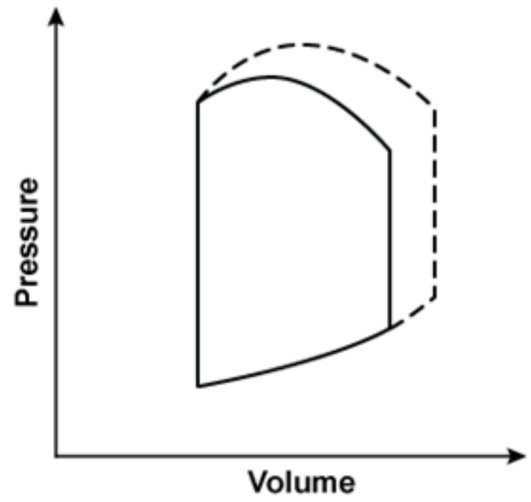

E. (4%)

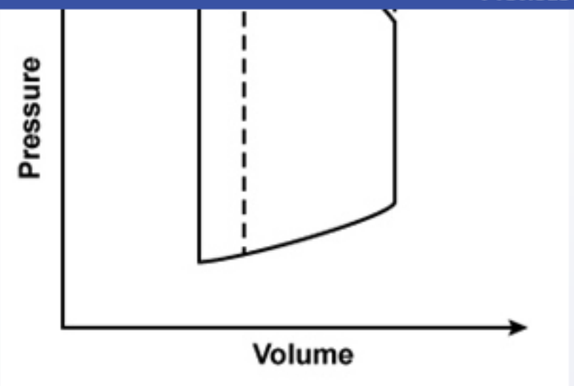

D. (21%)

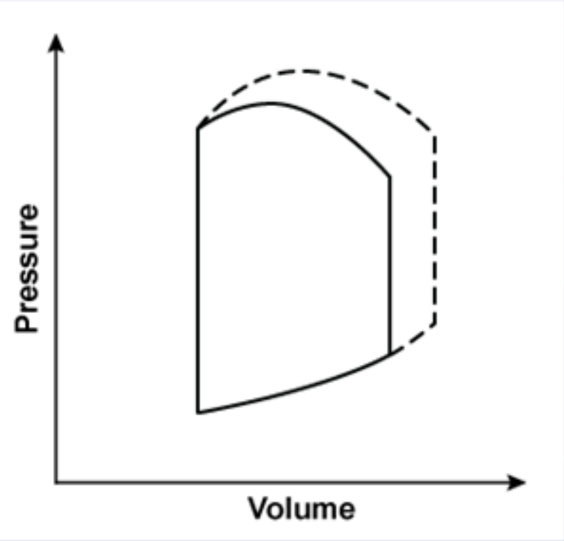

E. (4%)

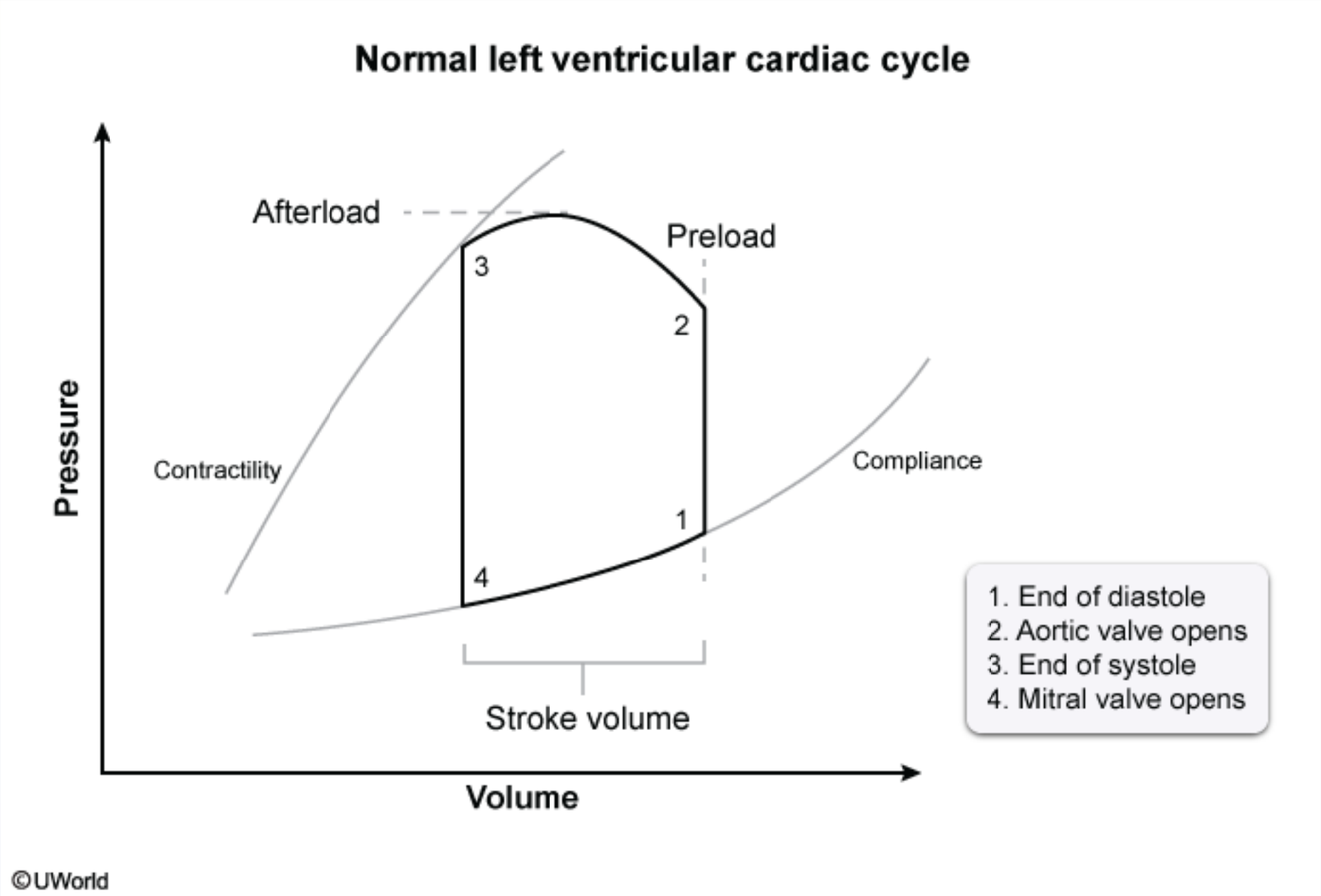

During moderate to heavy **exercise**, several **cardiovascular changes** occur to facilitate adequate oxygen delivery to skeletal muscle. These changes and their effects on the left ventricular (LV) pressure-volume loop are as follows:

- Vasoconstriction of capacitance veins mobilizes blood from the legs and increases venous return (ie, **increased preload**), which shifts LV end-diastolic volume to the right. There is also vasoconstriction of the splanchnic circulation and a higher degree of vasodilation in skeletal muscle, which shunts blood away from the gastrointestinal tract toward skeletal muscle and causes overall **reduced systemic vascular**

©UWorld

During moderate to heavy **exercise**, several **cardiovascular changes** occur to facilitate adequate oxygen delivery to skeletal muscle. These changes and their effects on the left ventricular (LV) pressure-volume loop are as follows:

- Vasoconstriction of capacitance veins mobilizes blood from the legs and increases venous return (ie, **increased preload**), which shifts LV end-diastolic volume to the right. There is also vasoconstriction of the splanchnic circulation and a higher degree of vasodilation in skeletal muscle, which shunts blood away from the gastrointestinal tract toward skeletal muscle and causes overall **reduced systemic vascular resistance** (SVR). The reduced SVR also contributes to increased preload by allowing cardiac output to return to the right atrium more quickly and easily.
- **Myocardial contractility** is markedly **increased**, shifting point 3 up and to the left. Both the increased contractility and the increased preload contribute to **increased stroke volume** (ie, the horizontal distance between points 1 and 3 is increased).
- Although reduced SVR typically leads to a slight decrease in diastolic pressure during exercise, the increase in myocardial contractility and stroke volume causes systolic pressure to rise. This results in an overall **increase in afterload** due to increased peak LV and aortic pressure during LV contraction.

The increase in stroke volume, combined with an increase in heart rate, **increases cardiac output** to meet the metabolic demands of exercise.

(Choice B) This graph shows an increase in contractility that leads to increased stroke volume and a slight increase in afterload. Such changes are expected with a positive inotropic agent such as digoxin.

(Choice C) This graph shows an increase in afterload with a consequent reduction in stroke volume (end-systolic volume is increased). Such changes are expected with the obstruction to LV outflow that occurs with aortic stenosis.

(Choice D) This graph shows an increase in preload (end-diastolic volume) with a consequent increase in stroke volume and slight increase in afterload. Such changes are expected with the increase in intravascular volume that occurs with the infusion of normal saline.

(Choice E) This graph shows decreased preload with a consequent decrease in stroke volume and slight reduction in afterload. Such changes are expected with the selective venous vasodilation that occurs with nitroglycerin.

Educational objective:
With moderate to heavy exercise, the changes to the left ventricular pressure-volume loop include increased preload and increased contractility

quickly and easily.

- **Myocardial contractility** is markedly **increased**, shifting point 3 up and to the left. Both the increased contractility and the increased preload contribute to **increased stroke volume** (ie, the horizontal distance between points 1 and 3 is increased).
- Although reduced SVR typically leads to a slight decrease in diastolic pressure during exercise, the increase in myocardial contractility and stroke volume causes systolic pressure to rise. This results in an overall **increase in afterload** due to increased peak LV and aortic pressure during LV contraction.

The increase in stroke volume, combined with an increase in heart rate, **increases cardiac output** to meet the metabolic demands of exercise.

(Choice B) This graph shows an increase in contractility that leads to increased stroke volume and a slight increase in afterload. Such changes are expected with a positive inotropic agent such as digoxin.

(Choice C) This graph shows an increase in afterload with a consequent reduction in stroke volume (end-systolic volume is increased). Such changes are expected with the obstruction to LV outflow that occurs with aortic stenosis.

(Choice D) This graph shows an increase in preload (end-diastolic volume) with a consequent increase in stroke volume and slight increase in afterload. Such changes are expected with the increase in intravascular volume that occurs with the infusion of normal saline.

(Choice E) This graph shows decreased preload with a consequent decrease in stroke volume and slight reduction in afterload. Such changes are expected with the selective venous vasodilation that occurs with nitroglycerin.

Educational objective:
With moderate to heavy exercise, the changes to the left ventricular pressure-volume loop include increased preload and increased contractility that both contribute to increased stroke volume. Although reduced systemic vascular resistance decreases afterload, the increase in systolic pressure caused by increased preload and contractility override the decrease, resulting in overall increased afterload.

Physiology	Cardiovascular System	Physical exercise
Subject	System	Topic

Copyright © UWorld. All rights reserved.

Preload

Exhibit Display

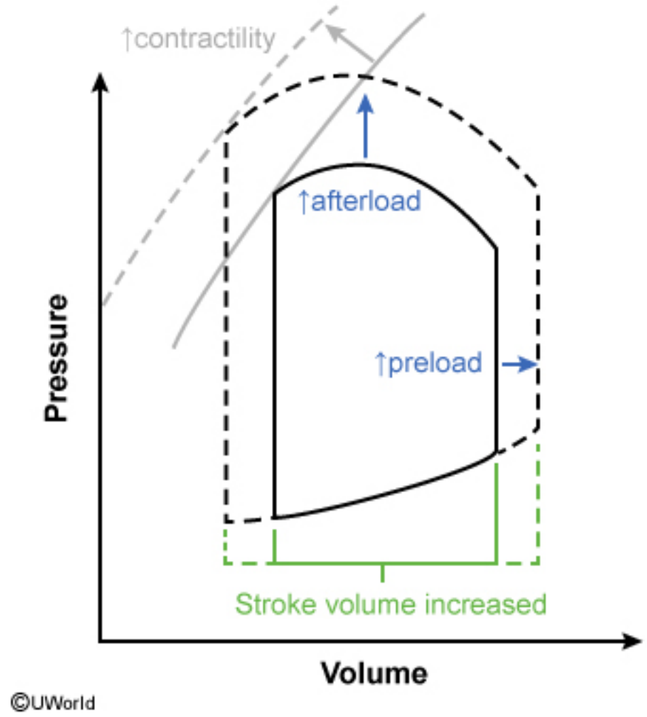

Zoom In
Zoom Out
Reset
Add To Flash Card

stroke volume causes systolic pressure to rise. This results in an overall **increase in afterload** due to increased peak LV and aortic

Exhibit Display

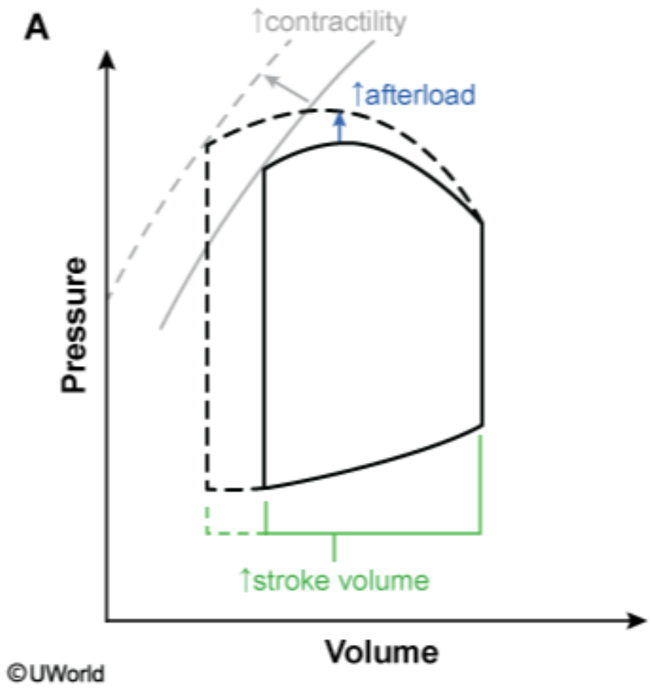

Zoom In Zoom Out Reset Add To Flash Card

Educational objective:

Exhibit Display

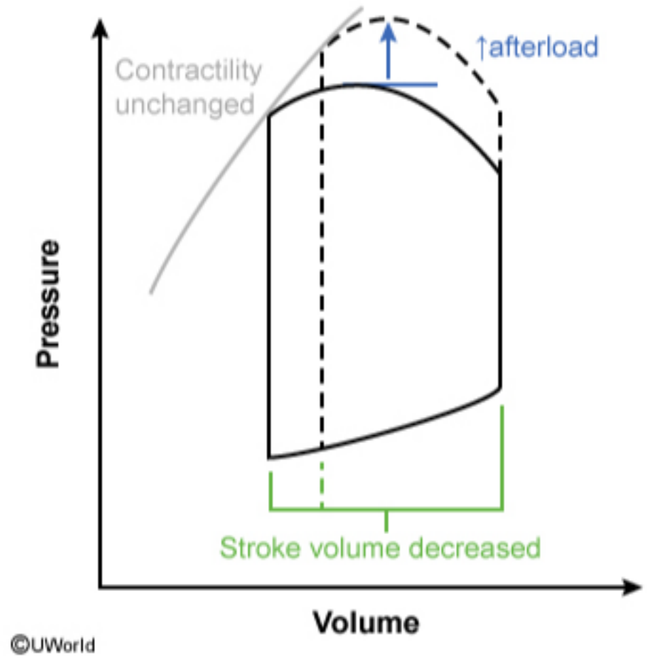

Zoom In Zoom Out Reset Add To Flash Card

Educational objective:

Exhibit Display

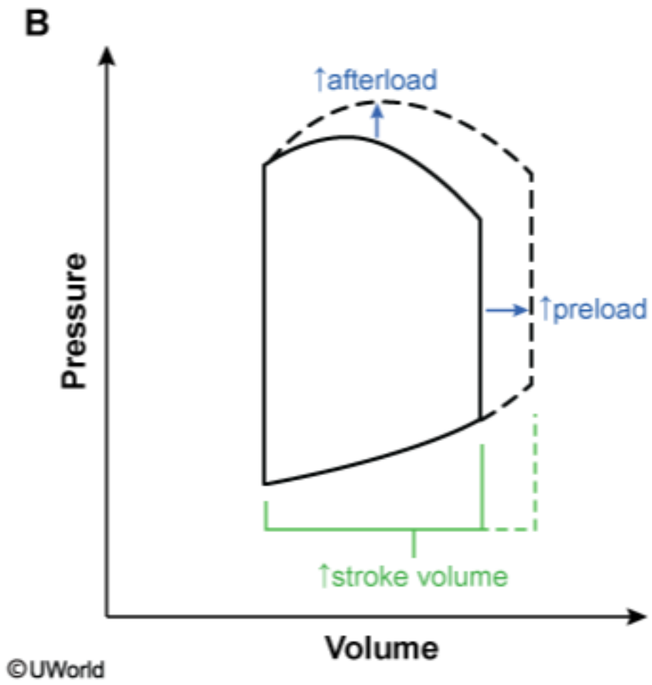

Zoom In Zoom Out Reset Add To Flash Card

Educational objective:

quickly and easily.

Exhibit Display

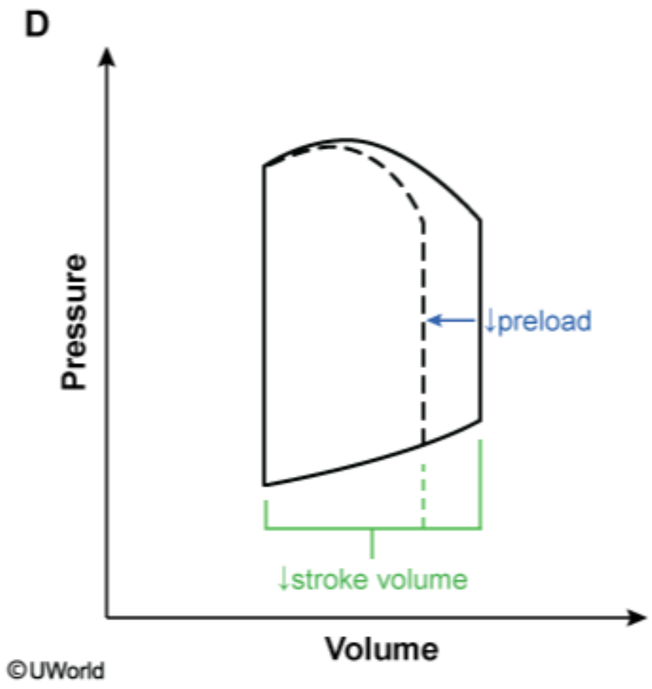

Zoom In Zoom Out Reset Add To Flash Card

A 67-year-old man is brought to the emergency department by his son after a syncopal episode. The son was helping his father clean out his garage when his father complained of dizziness. As his son was helping him into a chair, the patient lost consciousness. He woke up spontaneously about a minute later without any disorientation or confusion. An electrocardiogram demonstrates bradycardia with regular rhythm and narrow QRS complexes. However, there is complete desynchronization between the P waves and QRS complexes. Which of the following locations is most likely responsible for pacing this patient's ventricles?

- A. Sinoatrial node
- B. Atrioventricular node
- C. Left bundle branch
- D. Purkinje system
- E. Left ventricular muscle

Submit

A 67-year-old man is brought to the emergency department by his son after a syncopal episode. The son was helping his father clean out his garage when his father complained of dizziness. As his son was helping him into a chair, the patient lost consciousness. He woke up spontaneously about a minute later without any disorientation or confusion. An electrocardiogram demonstrates bradycardia with regular rhythm and narrow QRS complexes. However, there is complete desynchronization between the P waves and QRS complexes. Which of the following locations is most likely responsible for pacing this patient's ventricles?

- A. Sinoatrial node (3%)
- ✓ B. Atrioventricular node (65%)
- C. Left bundle branch (5%)
- D. Purkinje system (18%)
- E. Left ventricular muscle (5%)

Omitted
Correct answer
B

65%
Answered correctly

02 secs
Time Spent

03/24/2020
Last Updated

Explanation

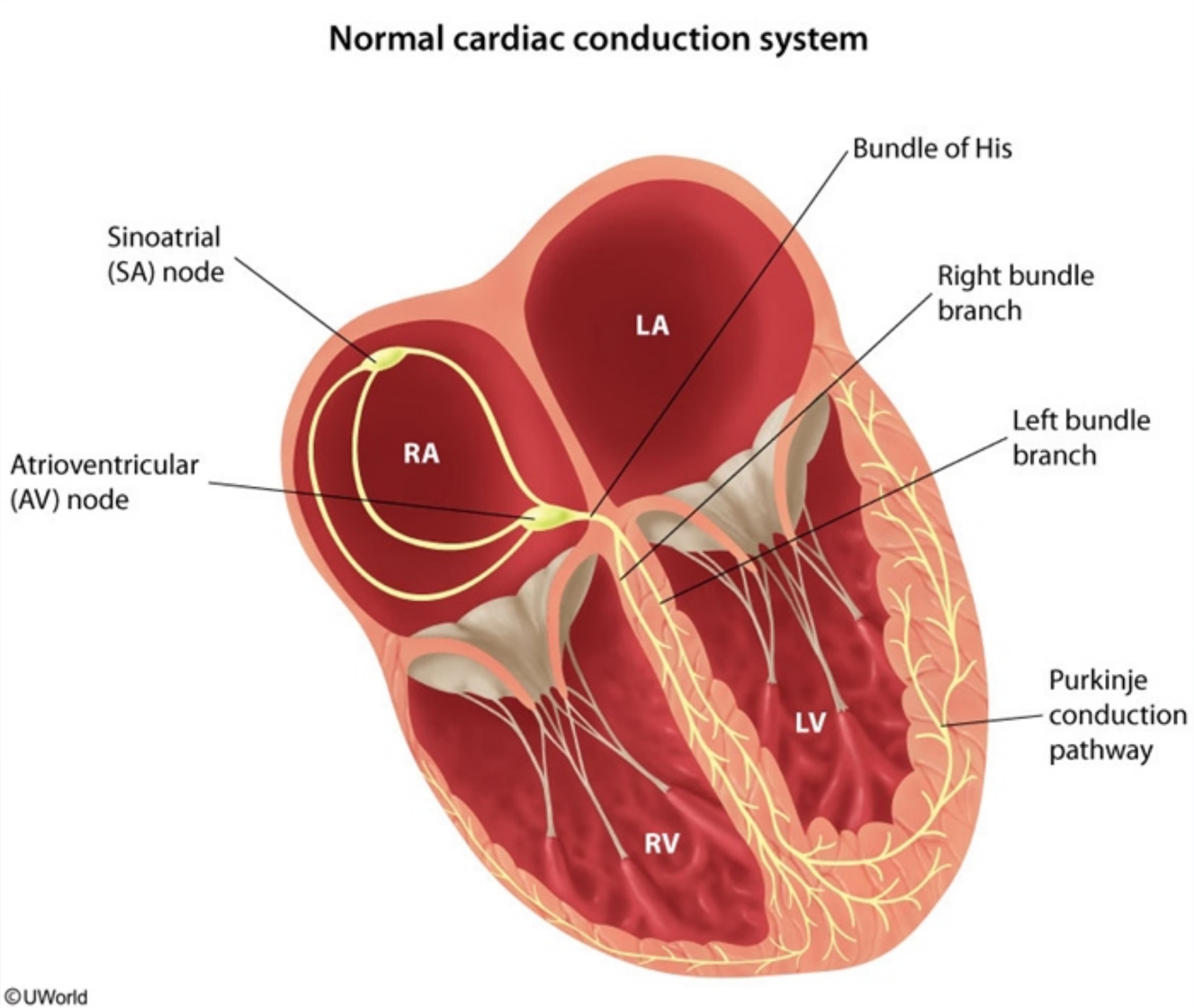

The electrical impulses in the myocardium are normally generated by the sinoatrial (SA) node at a rate of 60-100 beats per minute. These impulses are then transmitted through the conduction system to the ventricles, which depolarize from apex to base and from endocardium to

The electrical impulses in the myocardium are normally generated by the sinoatrial (SA) node at a rate of 60-100 beats per minute. These impulses are then transmitted through the conduction system to the ventricles, which depolarize from apex to base and from endocardium to epicardium.

Cells throughout the conduction system possess pacemaker ability. The SA node, however, normally stifles impulse generation by other cells in the conduction system as it is able to fire more rapidly. Should impulse conduction from the SA node be interrupted, the pacemaker activity of cells in other regions of the conduction system will be unmasked. The location of the pacemaker can be identified on ECG, which reflects the sequence of cardiac depolarization: atrial depolarization (P wave), followed by ventricular depolarization (QRS complex), followed by ventricular repolarization (T wave).

AV nodal cells can become pacemakers when conduction between the SA and AV nodes is impaired. This can occur in complete (third-degree) atrioventricular (AV) block, in which SA node impulses cause atrial contraction while impulses generated by the AV node cause ventricular contraction. On ECG, the atria and ventricles depolarize independently of each other (AV dissociation). QRS complexes are narrow since ventricular depolarization proceeds normally. The AV node produces a heart rate of 45-55 beats per minute.

(Choice A) When electrical impulses are generated by the SA node, the heart rate is normal. The ECG shows P waves synchronized with each QRS complex and normal ventricular depolarization.

(Choices C, D, and E) When electrical impulses are generated below the AV node and His bundle, the heart rate can slow to as few as 20 beats per minute. The ECG also shows prolonged, abnormally shaped QRS complexes due to aberrant impulse conduction through the ventricles.

Educational objective:
Cardiac pacemaker impulse generation normally occurs in the SA node, which has the fastest firing rate of all conductive cells. The cells in other areas of the conduction system (eg, AV node, bundle of His, and Purkinje fibers) may serve as pacemakers if normal impulse conduction is impaired.

Physiology	Cardiovascular System	Heart block
Subject	System	Topic

Copyright © UWorld. All rights reserved.

A 22-year-old man comes to the clinic for a routine physical. The patient has no medical problems and takes no medication. He does not use tobacco, alcohol, or illicit drugs. He plays on his college football team and participates in intense training sessions and weekly games. Review of systems is unremarkable. Blood pressure is 120/76 mm Hg, pulse is 68/min, and respirations are 15/min. BMI is 28 kg/m^2. Blood pressures in the upper and lower extremities are equal. There is no jugular venous distension. Carotid upstrokes are brisk. There is a grade 2/6 early systolic murmur along the left lower sternal border. The murmur decreases in intensity with hand grip and passive leg elevation. Lung sounds are normal without crackles or wheezes. Echocardiogram is most likely to demonstrate which of the following findings?

	Left ventricular mass	Left ventricular cavity size	Left ventricular ejection fraction	Left ventricular relaxation
A.	Increased	Dilated	Decreased	Normal
B.	Increased	Normal	Preserved	Normal
C.	Increased	Small	Decreased	Impaired
D.	Increased	Small	Preserved	Impaired
E.	Normal	Normal	Preserved	Impaired

Submit

A 22-year-old man comes to the clinic for a routine physical. The patient has no medical problems and takes no medication. He does not use tobacco, alcohol, or illicit drugs. He plays on his college football team and participates in intense training sessions and weekly games. Review of systems is unremarkable. Blood pressure is 120/76 mm Hg, pulse is 68/min, and respirations are 15/min. BMI is 28 kg/m^2. Blood pressures in the upper and lower extremities are equal. There is no jugular venous distension. Carotid upstrokes are brisk. There is a grade 2/6 early systolic murmur along the left lower sternal border. The murmur decreases in intensity with hand grip and passive leg elevation. Lung sounds are normal without crackles or wheezes. Echocardiogram is most likely to demonstrate which of the following findings?

	Left ventricular mass	Left ventricular cavity size	Left ventricular ejection fraction	Left ventricular relaxation
A. (8%)	Increased	Dilated	Decreased	Normal
B. (18%)	Increased	Normal	Preserved	Normal
C. (21%)	Increased	Small	Decreased	Impaired
✓ D. (48%)	Increased	Small	Preserved	Impaired
E. (2%)	Normal	Normal	Preserved	Impaired

Omitted
Correct answer
D

48%
Answered correctly

02 secs
Time Spent

04/07/2020
Last Updated

This patient with a systolic murmur along the left sternal border that **decreases in intensity** with **maneuvers that increase left ventricular (LV) blood volume** likely has **hypertrophic cardiomyopathy** (HCM). HCM typically involves hypertrophy of the interventricular septum that can partially obstruct LV outflow and cause a murmur. Increases in LV blood volume, caused by maneuvers that increase preload (eg, passive leg elevation) or increase afterload (eg, handgrip), alleviate the LV outflow obstruction of HCM and decrease the intensity of the murmur.

HCM is characterized by **increased LV muscle mass** and a **small LV cavity**. Because LV contractility is typically intact and outflow obstruction is dynamic and commonly only present with exercise, there is usually **preserved ejection fraction**. However, **impaired relaxation** of the hypertrophied LV wall typically leads to diastolic dysfunction.

(Choices A and E) Increased LV mass with a dilated LV cavity, decreased LV ejection fraction, and normal LV relaxation are consistent with dilated cardiomyopathy. Normal LV mass and cavity size with preserved ejection fraction and impaired LV relaxation describe restrictive cardiomyopathy; the LV walls are stiffened but are not typically thickened. Both conditions are likely to lead to symptomatic heart failure with jugular venous distension and pulmonary edema (evidenced by crackles on lung auscultation).

(Choice B) Increased LV mass with normal LV relaxation and normal (or somewhat increased) LV cavity size and ejection fraction are consistent with athlete's heart, which describes physiologic cardiac changes (eg, LV cavity enlargement and wall thickening) that improve cardiac function in response to intense endurance training. A murmur consistent with HCM is not expected in athlete's heart.

(Choice C) Increased LV mass with small LV cavity size, decreased ejection fraction, and impaired ventricular relaxation occurs in severe aortic stenosis. The fixed obstruction created by the stenotic valve leads to pressure overload and concentric LV hypertrophy, and also restricts stroke volume to decrease ejection fraction. The murmur of aortic stenosis is similar to that of HCM but is differentiated by a decrease in intensity with maneuvers that decrease (rather than increase) LV preload (eg, abrupt standing, Valsalva strain phase).

Educational objective:
Hypertrophic cardiomyopathy (HCM) typically involves interventricular septal hypertrophy that obstructs left ventricular (LV) outflow and creates a systolic murmur that decreases in intensity with maneuvers that increase LV blood volume (eg, hand grip, passive leg elevation). HCM is characterized by increased LV muscle mass with a small LV cavity, preserved ejection fraction, and impaired LV relaxation leading to diastolic dysfunction.

Physiology Cardiovascular System Hypertrophic cardiomyopathy

This patient with a systolic murmur along the left sternal border that **decreases in intensity** with **maneuvers that increase left ventricular (LV) blood volume** likely has h
partially obstruct LV outflo
elevation) or increase afte

HCM is characterized by i
dynamic and commonly o
hypertrophied LV wall typi

(Choices A and E) Increa
dilated cardiomyopathy. N
cardiomyopathy; the LV w
jugular venous distension

(Choice B) Increased LV
with athlete's heart, which
response to intense endur

(Choice C) Increased LV
stenosis. The fixed obstru
volume to decrease ejecti
maneuvers that decrease

Educational objective:
Hypertrophic cardiomyopa
systolic murmur that decre
characterized by increase
dysfunction.

Physiology Cardiovascular System Hypertrophic cardiomyopathy

Exhibit Display

Effect of maneuvers on hypertrophic cardiomyopathy			
	Physiologic effect	**Left ventricular blood volume**	**Murmur intensity**
Valsalva (strain phase)	↓ Preload	↓	↑
Abrupt standing			
Nitroglycerin administration			
Sustained hand grip	↑ Afterload	↑	↓
Squatting	↑ Afterload & preload		
Passive leg raise	↑ Preload		

Add To New Card | Existing Card

This patient with a systolic murmur along the left sternal border that **decreases in intensity** with **maneuvers that increase left ventricular (LV) blood volume** likely has h
partially obstruct LV outflo
elevation) or increase afte

HCM is characterized by i n is
dynamic and commonly o
hypertrophied LV wall typi

(Choices A and E) Increa
dilated cardiomyopathy. N
cardiomyopathy; the LV w
jugular venous distension

(Choice B) Increased LV ent
with athlete's heart, which in
response to intense endur

(Choice C) Increased LV ic
stenosis. The fixed obstru e
volume to decrease ejecti n
maneuvers that decrease

Educational objective:
Hypertrophic cardiomyopa s a
systolic murmur that decre
characterized by increase
dysfunction.

Exhibit Display

UWorld

Hypertrophic cardiomyopathy

0:00 / 1:22

Physiology Cardiovascular System Hypertrophic cardiomyopathy

A 56-year-old man comes to the emergency department due to palpitations that started several hours ago. He has not had similar symptoms before. The patient has had no chest pain, shortness of breath, lightheadedness, or syncope. He drinks alcohol on weekends and does not use illicit drugs. He has no family history of heart disease. Blood pressure is 145/78 mm Hg. BMI is 40 kg/m^2. ECG is shown in the exhibit. The patient is treated medically in the emergency department. He is then taken to the electrophysiology laboratory for radiofrequency catheter ablation to terminate his arrhythmia. The ablation procedure should create a conduction block through which of the following areas?

- A. Accessory pathway bypassing the atrioventricular node
- B. Area between the tricuspid valve and inferior vena cava in the right atrium
- C. Area in the right ventricular outflow tract
- D. Ostia of the pulmonary veins in the left atrium
- E. Slow pathway of the atrioventricular node

Submit

A 56-year-old man comes to the emergency department due to palpitations that started several hours ago. He has not had similar symptoms before. The patient has had no chest pain, shortness of breath, lightheadedness, or syncope. He drinks alcohol on weekends and does not use illicit drugs. He has no family history of heart disease. Blood pressure is 145/78 mm Hg. BMI is 40 kg/m^2. ECG is shown in the exhibit. The patient is treated medically in the emergency department. He is then taken to the electrophysiology laboratory for radiofrequency catheter ablation to terminate his arrhythmia. The ablation procedure should create a conduction block through which of the following areas?

- A. Accessory pathway bypassing the atrioventricular node (23%)
- ✓ B. Area between the tricuspid valve and inferior vena cava in the right atrium (45%)
- C. Area in the right ventricular outflow tract (3%)
- D. Ostia of the pulmonary veins in the left atrium (17%)
- E. Slow pathway of the atrioventricular node (11%)

Omitted
Correct answer
B

45%
Answered correctly

02 secs
Time Spent

01/28/2020
Last Updated

Explanation

Reentrant circuit in atrial flutter

1
2
3
4
5
6
7
8
9
10
11
12
13
14
15
16
17
18
19
20
21
22
23
24
25
26
27
28
29
30
31

Reentrant circuit in atrial flutter

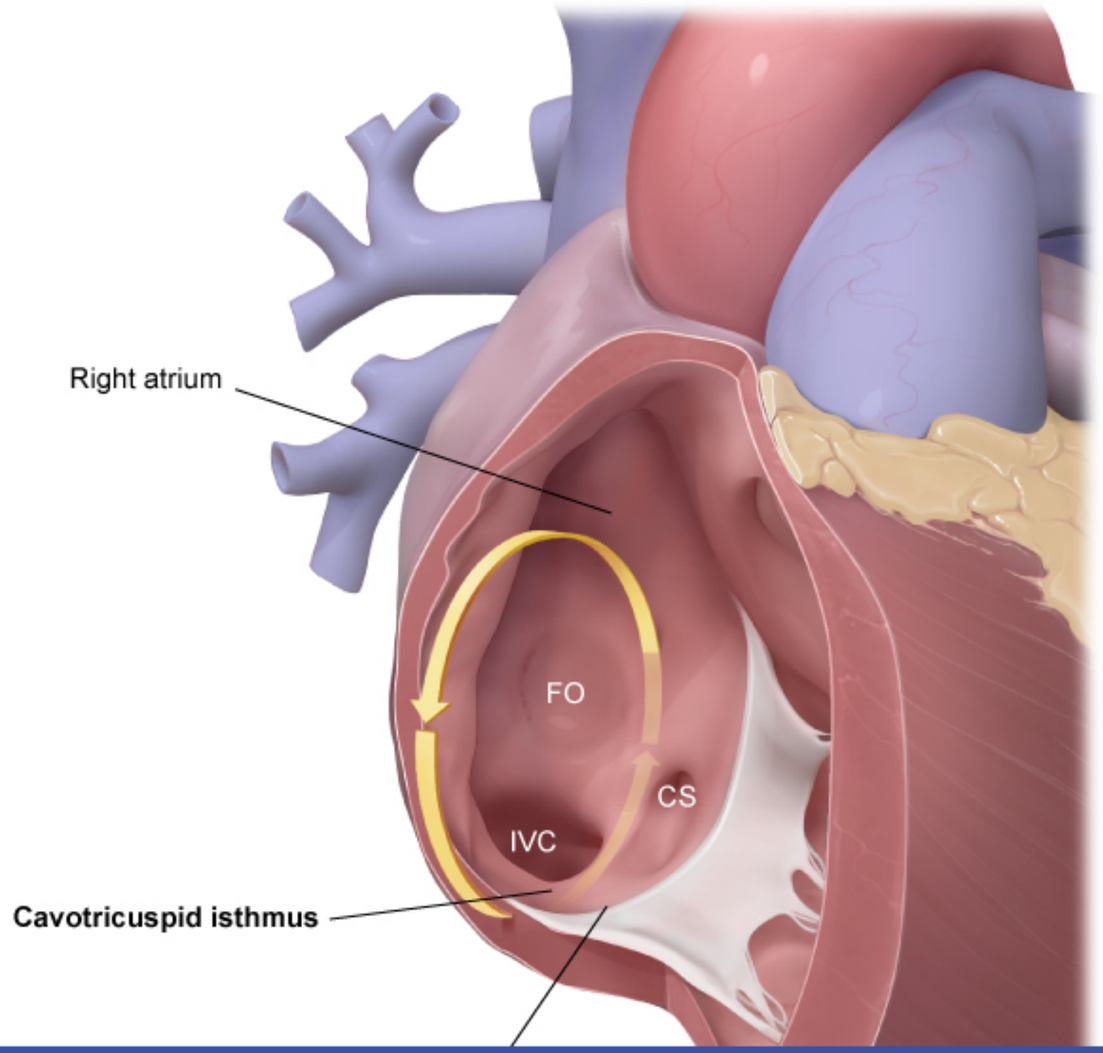

1
2
3
4
5
6
7
8
9
10
11
12
13
14
15
16
17
18
19
20
21
22
23
24
25
26
27
28
29
30
31

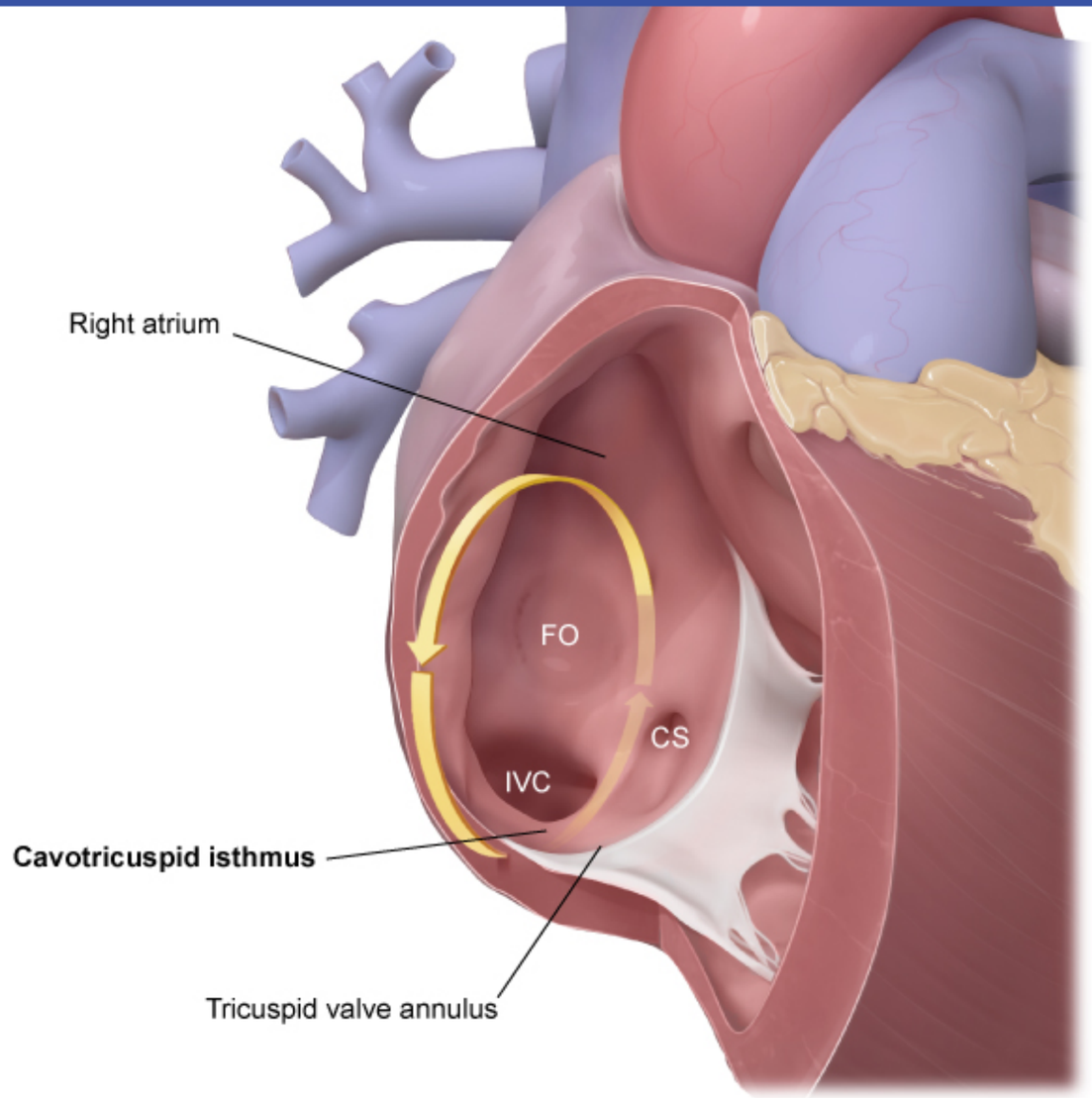

CS = coronary sinus; **FO** = fossa ovalis; **IVC** = inferior vena cava.
©UWorld

This patient's ECG strip shows rapid and regular atrial activity in a **saw-toothed** pattern (flutter or F waves), consistent with **atrial flutter**. Narrow

©UWorld

This patient's ECG strip shows rapid and regular atrial activity in a **saw-toothed** pattern (flutter or F waves), consistent with **atrial flutter**. Narrow QRS complexes are typically present and the ventricular rhythm appears regular. Because the **atrial rate** is approximately **300/min**, typical ventricular rates in atrial flutter are 150/min, 100/min, or 75/min due to 2:1, 3:1, or 4:1 conduction through the atrioventricular node, respectively.

Atrial flutter shares many of the same triggers as atrial fibrillation; underlying comorbidities that cause atrial dilation (eg, heart failure) are often present and alcohol intake may contribute. Typical atrial flutter is caused by a **large reentrant circuit** that traverses the **cavotricuspid isthmus**, the region of right atrial tissue between the inferior vena cava and the tricuspid valve annulus. This region is identified during electrophysiologic study and is the target for radiofrequency ablation to interrupt the reentrant circuit and abolish atrial flutter.

(Choice A) An accessory pathway that bypasses the atrioventricular node is present in atrioventricular reentrant tachycardia, also known as Wolff-Parkinson-White syndrome. ECG shows the triad of short PR interval, wide QRS complex, and slurred upstroke of the QRS complex (delta wave).

(Choice C) The right ventricular outflow tract is the most common origination site of idiopathic ventricular tachycardia, a repetitive monomorphic ventricular tachycardia that occurs in the absence of structural heart disease. ECG shows a wide QRS complex with uniform QRS morphology and a regular rhythm.

(Choice D) The pulmonary vein ostia are often the origination site of atrial fibrillation, and catheter ablation of pulmonary vein trigger sites (pulmonary vein isolation) may be used to treat symptomatic patients. ECG reveals an irregularly irregular rhythm with varying R-R intervals and absence of P waves.

(Choice E) Dual electrical pathways (a slow and fast pathway) within or near the atrioventricular node are implicated in atrioventricular nodal reentrant tachycardia; the slow pathway is targeted for radiofrequency ablation. ECG shows narrow QRS complexes with a rapid rate and regular rhythm, and sometimes retrograde P waves.

Educational objective:
Atrial flutter demonstrates rapid and regular atrial activity in a saw-toothed pattern (flutter or F waves) on ECG. Typical atrial flutter is caused by a large reentrant circuit that traverses the cavotricuspid isthmus of the right atrium, which is the target site for radiofrequency ablation.

References

- Electrophysiologic studies in atrial flutter

©UWorld

This patient's ECG strip shows rapid and regular atrial activity in a **saw-toothed** pattern (flutter or F waves), consistent with **atrial flutter**. Narrow QRS complexes are typica
ventricular rates in atrial fl

Atrial flutter shares many
present and alcohol intake
the region of right atrial tis
study and is the target for

(Choice A) An accessory
Wolff-Parkinson-White syn
wave).

(Choice C) The right ven
ventricular tachycardia tha
and a regular rhythm.

(Choice D) The pulmona
(pulmonary vein isolation)
absence of P waves.

(Choice E) Dual electrica
reentrant tachycardia; the
rhythm, and sometimes re

Educational objective:
Atrial flutter demonstrates
large reentrant circuit that

References

- Electrophysiologic studies in atrial flutter

Exhibit Display

Zoom In | Zoom Out | Reset | Add To New Card | Existing Card

©UWorld

Exhibit Display

Wolff-Parkinson-White ventricular preexcitation

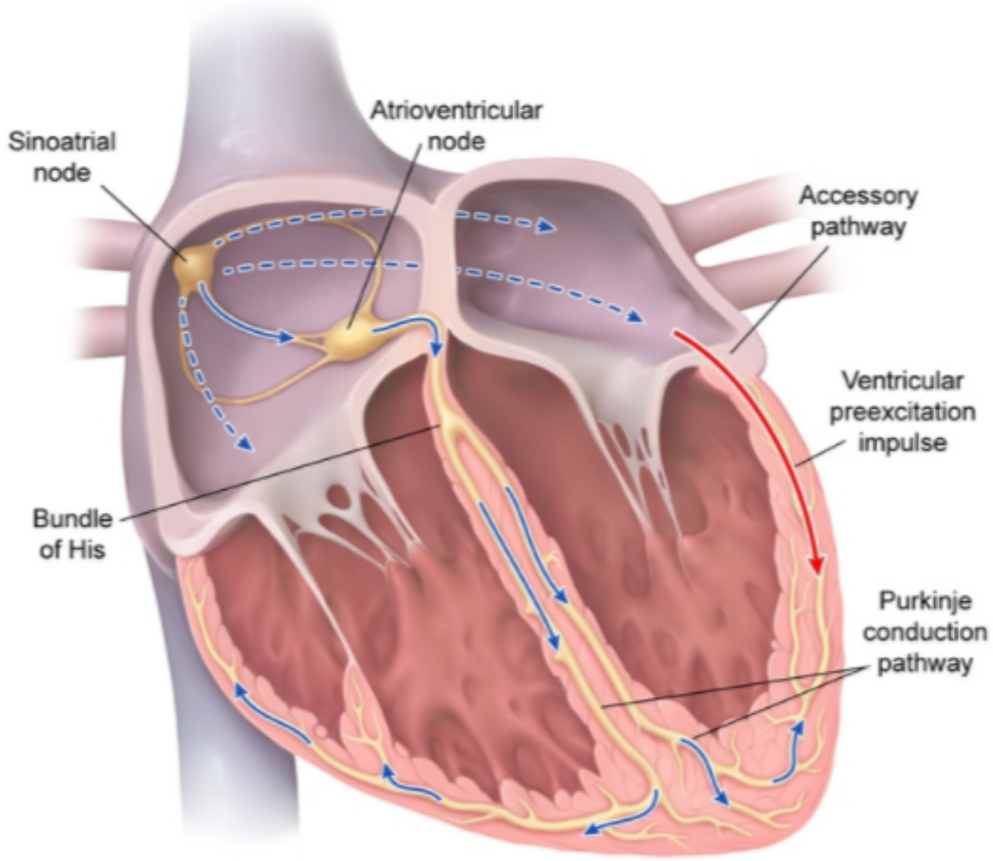

©UWorld

Zoom In | Zoom Out | Reset | Add To New Card | Existing Card

- Electrophysiologic studies in atrial flutter

©UWorld

Exhibit Display

Wolff-Parkinson-White pattern

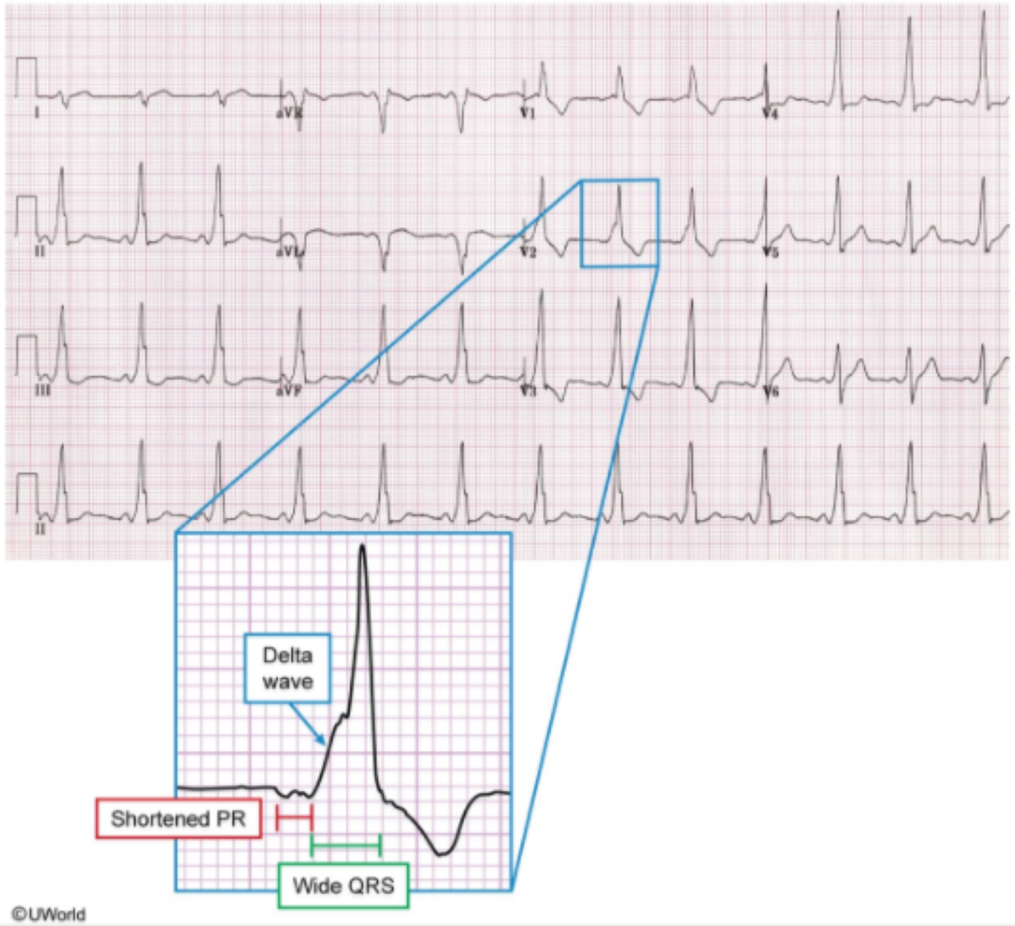

Zoom In | Zoom Out | Reset | Add To New Card | Existing Card

- Electrophysiologic studies in atrial flutter

©UWorld

Exhibit Display

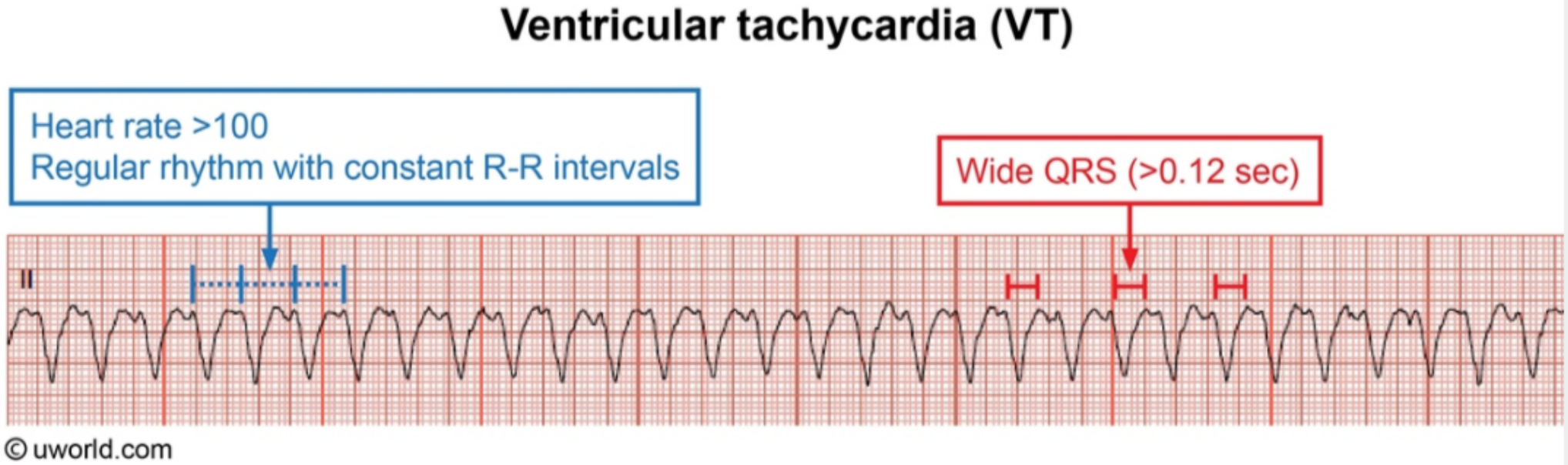

Zoom In | Zoom Out | Reset | Add To New Card | Existing Card

- Electrophysiologic studies in atrial flutter

©UWorld

Exhibit Display

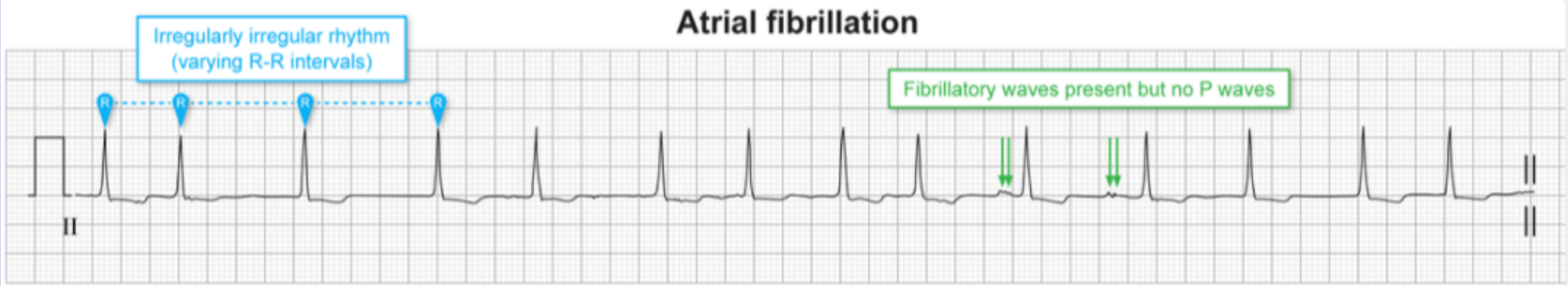

©UWorld

Zoom In | Zoom Out | Reset | Add To New Card | Existing Card

- Electrophysiologic studies in atrial flutter

©UWorld

Exhibit Display

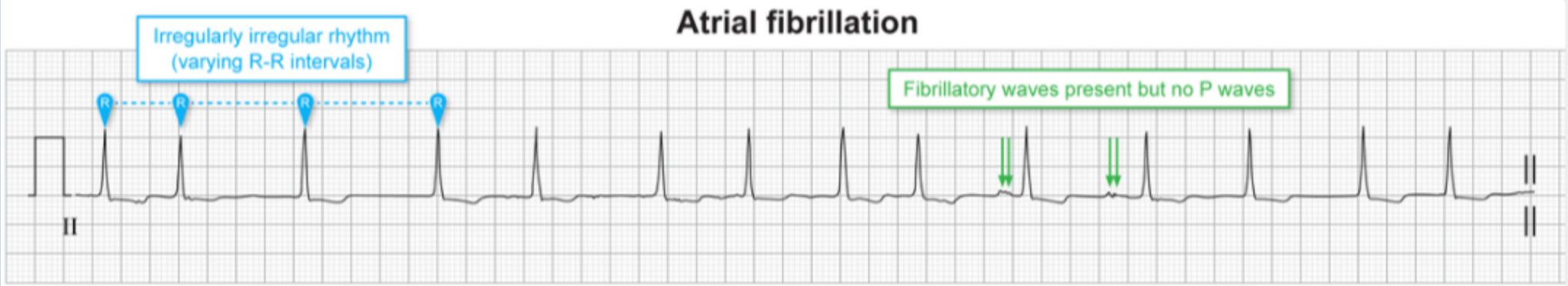

©UWorld

Zoom In | Zoom Out | Reset | Add To New Card | Existing Card

- Electrophysiologic studies in atrial flutter

©UWorld

Exhibit Display

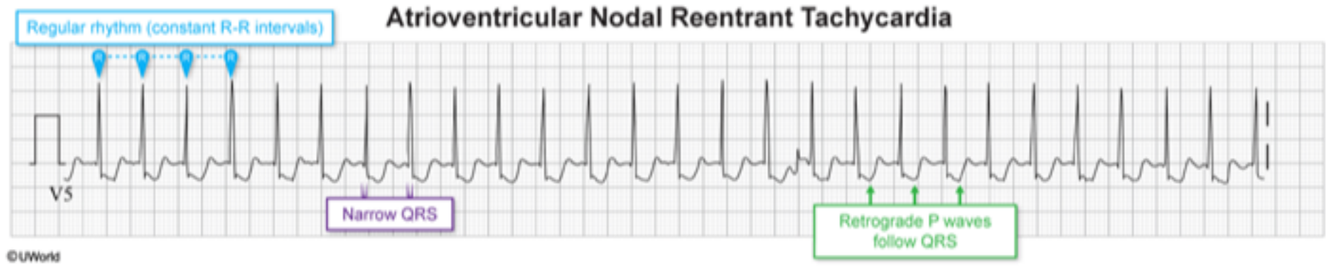

Zoom In | Zoom Out | Reset | Add To New Card | Existing Card

- Electrophysiologic studies in atrial flutter

A 35-year-old woman comes to the office for a follow-up appointment after recent hospitalization. The patient presented to the emergency department with fever and malaise and was diagnosed with infective endocarditis. She underwent a prolonged course of antibiotic therapy and her last dose was 5 days ago. She has no fever or shortness of breath and has resumed her daily activities. The patient has no other medical problems. Blood pressure is 128/72 mm Hg and pulse is 78/min. Auscultatory findings recorded at the left sternal border are shown in the phonocardiogram below.

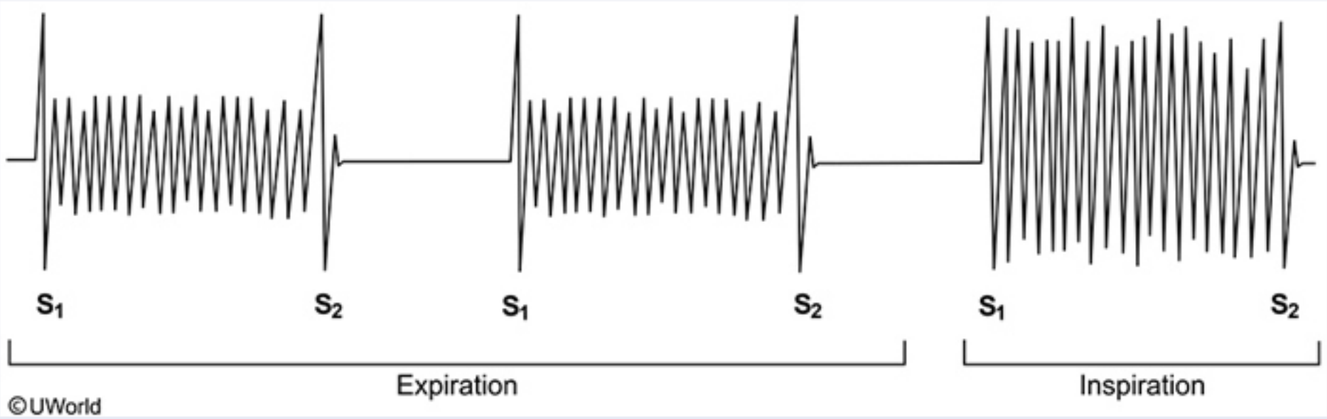

Which of the following is the most likely cause of the murmur depicted above?

A. Aortic stenosis
B. Mitral regurgitation
C. Mitral stenosis
D. Pulmonary regurgitation
E. Tricuspid regurgitation

Submit

A 35-year-old woman comes to the office for a follow-up appointment after recent hospitalization. The patient presented to the emergency department with fever and malaise and was diagnosed with infective endocarditis. She underwent a prolonged course of antibiotic therapy and her last dose was 5 days ago. She has no fever or shortness of breath and has resumed her daily activities. The patient has no other medical problems. Blood pressure is 128/72 mm Hg and pulse is 78/min. Auscultatory findings recorded at the left sternal border are shown in the phonocardiogram below.

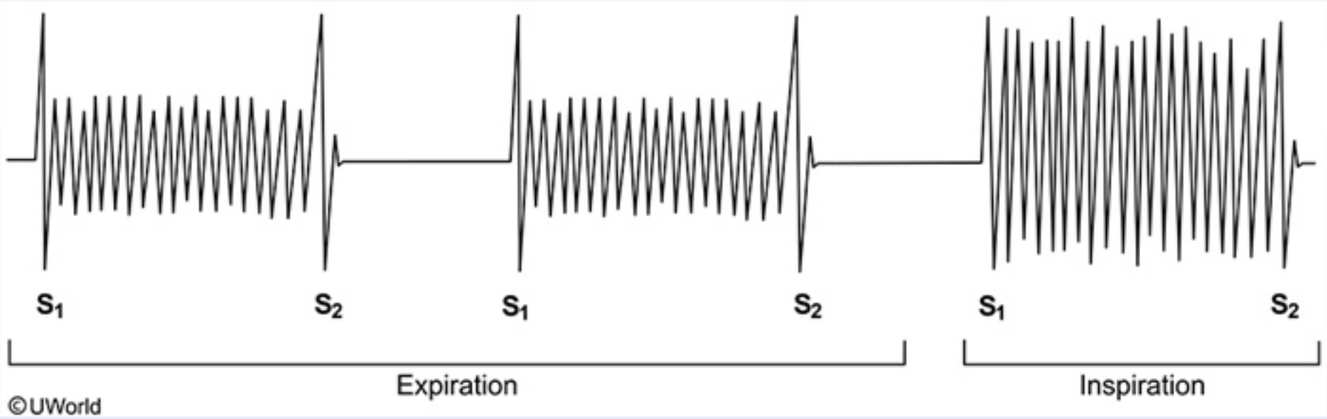

Which of the following is the most likely cause of the murmur depicted above?

A. Aortic stenosis (5%)
B. Mitral regurgitation (25%)
C. Mitral stenosis (4%)
D. Pulmonary regurgitation (6%)
✓ E. Tricuspid regurgitation (57%)

Auscultation of holosystolic murmurs	
Mitral regurgitation	• Best heard at the apex • Radiates to the axilla
Tricuspid regurgitation	• Best heard at the left 2nd & 3rd intercostal spaces • Murmur increases with inspiration
Ventricular septal defect	• Best heard at the left 3rd & 4th intercostal spaces • Murmur is usually loud & accompanied by a thrill

©UWorld

This patient's phonocardiogram shows a **holosystolic murmur** that increases in intensity during inspiration. Holosystolic murmurs are associated with **tricuspid regurgitation** (TR), mitral regurgitation (MR), and ventricular septal defects (VSDs).

Intrathoracic pressure drops during inspiration, allowing more blood to return to the right heart. Right ventricular stroke volume rises due to increased venous return. However, the drop in intrathoracic pressure also increases pulmonary vessel capacity, leading to a transient decrease in left ventricular venous return. As a result, a TR murmur would be expected to increase in intensity during inspiration (Carvallo sign), whereas murmurs associated with MR or VSD would either decrease or not change. TR is further favored over MR as TR is loudest near the left sternal border at the second and third intercostal spaces. MR is heard most prominently over the cardiac apex. A VSD produces a holosystolic murmur that is typically loudest over the left sternal border in the third or fourth intercostal spaces.

(Choice A) Aortic stenosis is characterized by a mid-systolic ejection murmur that starts after S1 and ends before S2 and is heard best at the right second interspace. This murmur has a crescendo-decrescendo (diamond-shaped) configuration.

(Choice B) MR causes a high-pitched holosystolic murmur most prominent over the cardiac apex, which is best heard with the patient in the left lateral decubitus position. The murmur of MR displays little respiratory variation.

This patient's phonocardiogram shows a **holosystolic murmur** that increases in intensity during inspiration. Holosystolic murmurs are associated with **tricuspid regurgitation** (TR), mitral regurgitation (MR), and ventricular septal defects (VSDs).

Intrathoracic pressure drops during inspiration, allowing more blood to return to the right heart. Right ventricular stroke volume rises due to increased venous return. However, the drop in intrathoracic pressure also increases pulmonary vessel capacity, leading to a transient decrease in left ventricular venous return. As a result, a TR murmur would be expected to increase in intensity during inspiration (Carvallo sign), whereas murmurs associated with MR or VSD would either decrease or not change. TR is further favored over MR as TR is loudest near the left sternal border at the second and third intercostal spaces. MR is heard most prominently over the cardiac apex. A VSD produces a holosystolic murmur that is typically loudest over the left sternal border in the third or fourth intercostal spaces.

(Choice A) Aortic stenosis is characterized by a mid-systolic ejection murmur that starts after S1 and ends before S2 and is heard best at the right second interspace. This murmur has a crescendo-decrescendo (diamond-shaped) configuration.

(Choice B) MR causes a high-pitched holosystolic murmur most prominent over the cardiac apex, which is best heard with the patient in the left lateral decubitus position. The murmur of MR displays little respiratory variation.

(Choice C) Mitral stenosis is associated with an opening snap of the mitral valve and a low-pitched rumbling murmur heard throughout diastole.

(Choice D) Pulmonic regurgitation yields an early diastolic murmur that starts with S2 and ends before S1. The murmur has a decrescendo configuration and may increase in intensity during inspiration. It has a high-pitched, blowing sound that is best heard over the left second and third intercostal spaces.

Educational objective:
A holosystolic murmur that increases in intensity on inspiration most likely represents tricuspid regurgitation. The other holosystolic murmurs (which are secondary to mitral regurgitation or a ventricular septal defect) do not typically increase in intensity during inspiration.

Physiology	Cardiovascular System	Tricuspid regurgitation
Subject	System	Topic

Copyright © UWorld. All rights reserved.

septal defect

- Murmur is usually loud & accompanied by a thrill

Exhibit Display

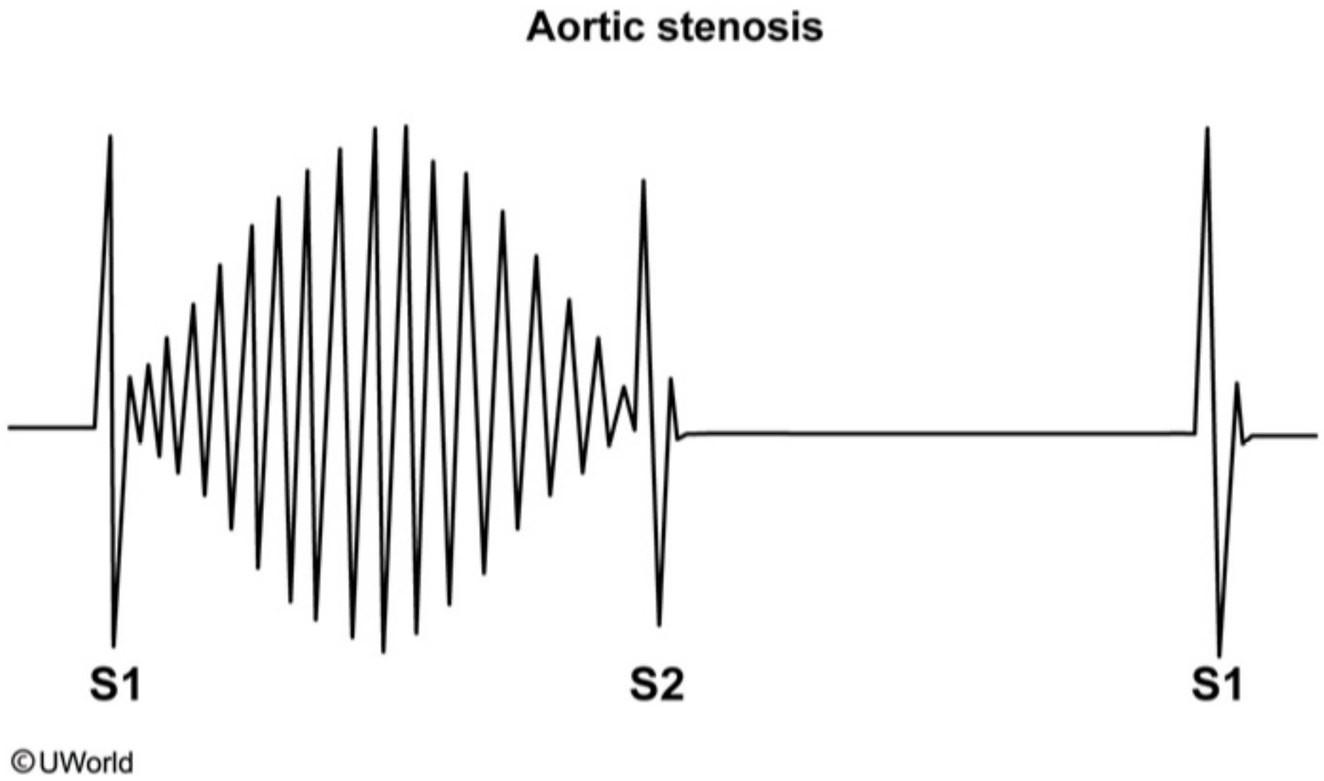

Zoom In | Zoom Out | Reset | Add To New Card | Existing Card

septal defect	• Murmur is usually loud & accompanied by a thrill

Exhibit Display

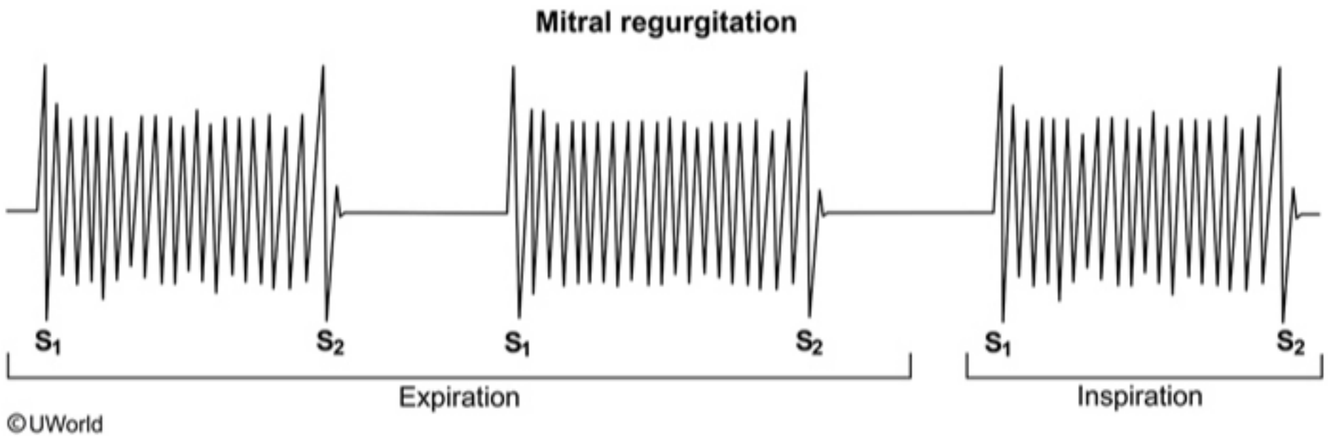

Zoom In | Zoom Out | Reset | Add To New Card | Existing Card

septal defect

- Murmur is usually loud & accompanied by a thrill

Exhibit Display

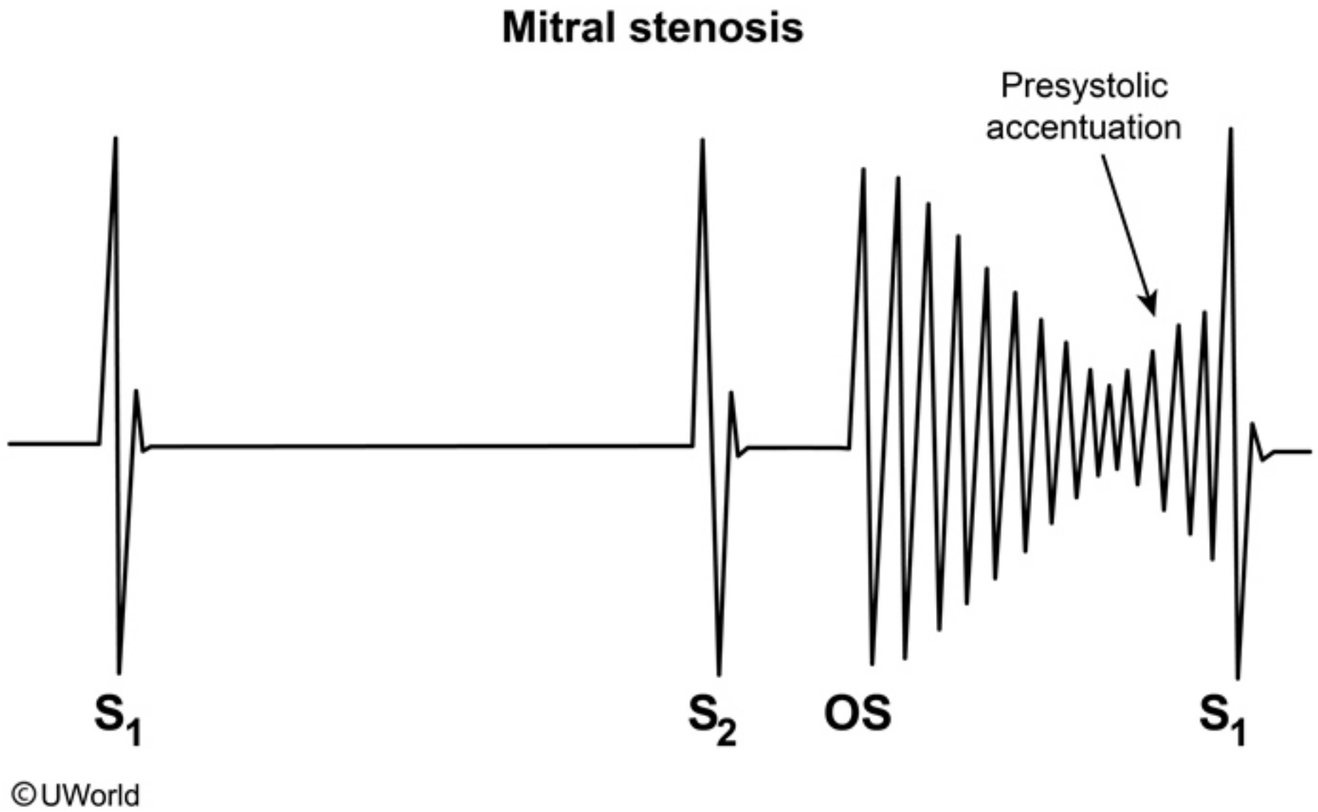

Zoom In | Zoom Out | Reset | Add To New Card | Existing Card

septal defect

- Murmur is usually loud & accompanied by a thrill

Exhibit Display

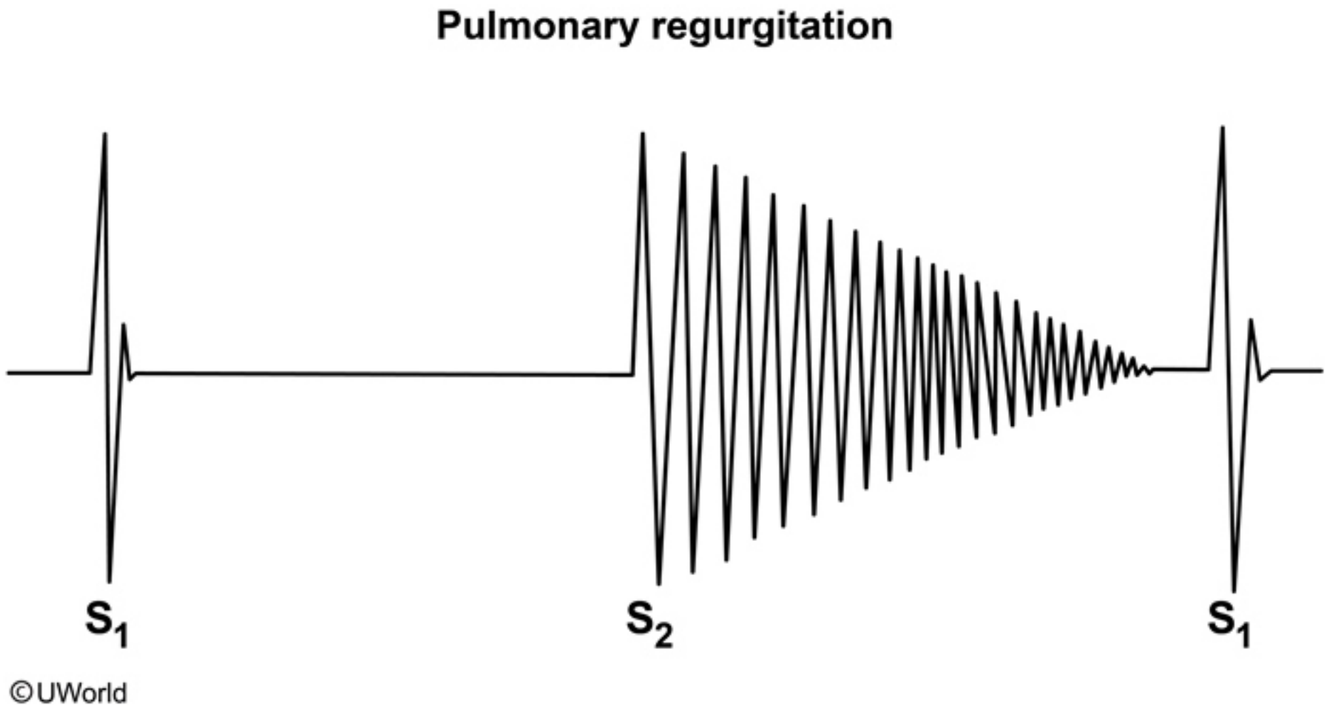

Zoom In | Zoom Out | Reset | Add To New Card | Existing Card

1 2 3 4 5 6 7 8 9 10 11 12 13 14 15 16 17 18 19 20 21 22 23 24 25 26 27 28 29 30 31

A 43-year-old man is evaluated for occasional palpitations provoked by anxiety. The patient describes a sudden-onset pounding sensation in the chest followed by lightheadedness and shortness of breath. He has never had syncope. The patient has no history of heart disease, and family history is unremarkable. After initial evaluation, he is treated with verapamil and reports marked improvement in the frequency of palpitation episodes. The tracing below shows the electrical activity of a specific type of cardiac cell in the patient's heart.

Which of the following effects would verapamil administration most likely have on these cells?

- A. Decreased excitation and contraction coupling
- B. Increased action potential amplitude
- C. Lowered threshold potential
- D. Reduced refractory period
- E. Slowed spontaneous depolarization

Submit

A 43-year-old man is evaluated for occasional palpitations provoked by anxiety. The patient describes a sudden-onset pounding sensation in the chest followed by lightheadedness and shortness of breath. He has never had syncope. The patient has no history of heart disease, and family history is unremarkable. After initial evaluation, he is treated with verapamil and reports marked improvement in the frequency of palpitation episodes. The tracing below shows the electrical activity of a specific type of cardiac cell in the patient's heart.

Which of the following effects would verapamil administration most likely have on these cells?

- A. Decreased excitation and contraction coupling (38%)
- B. Increased action potential amplitude (3%)
- C. Lowered threshold potential (2%)
- D. Reduced refractory period (2%)
- ✓ E. Slowed spontaneous depolarization (53%)

Omitted

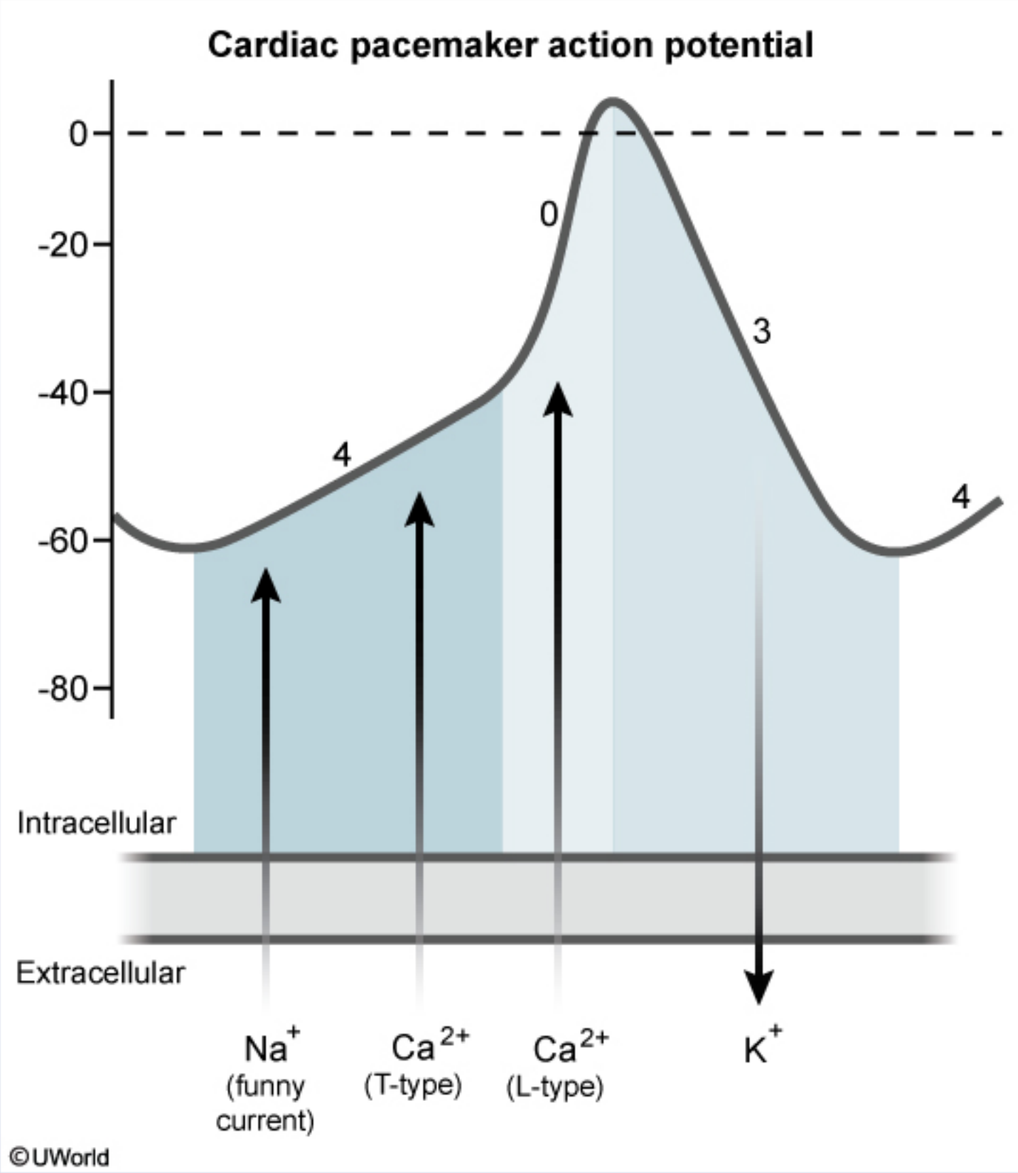
Cardiac pacemaker action potential
0
-20
-40
-60
-80
0
3
4
4
Intracellular
Extracellular
Na+
(funny
current)
Ca2+
(T-type)
Ca2+
(L-type)
K+
©UWorld

The above tracing demonstrates the action potential of cardiac pacemaker cells in cardiac **slow-response tissues** such as the **sinoatrial** (SA) and **atrioventricular** (AV) nodes. The pacemaker action potential includes the following phases:

- Phase 4 (spontaneous depolarization) begins after hyperpolarization triggers the opening of HCN channels that allow slow influx of Na^+ ("funny current"). T-type (transient) Ca^{2+} channels then open once the membrane potential becomes more positive, allowing Ca^{2+} influx to contribute to depolarization. As the pacemaker cell approaches threshold, **L-type** (long-lasting) **Ca^{2+} channels begin to open**, which further increases Ca^{2+} influx and significantly decreases the time until threshold is reached.
- Phase 0 (upstroke) is characterized by continued opening of L-type Ca^{2+} channels. In cardiac slow-response tissues, the action potential upstroke is much slower and transitions gradually from phase 4 due to the relatively slow influx of Ca^{2+} into the cell.
- Phase 3 (repolarization) is characterized by the opening of K^+ channels and efflux of K^+ from the cell in conjunction with the closure of L-type Ca^{2+} channels.

This patient's anxiety-provoked episodes of sudden-onset palpitations associated with lightheadedness and shortness of breath are consistent with **paroxysmal supraventricular tachycardia**. Class IV antiarrhythmics (eg, **verapamil**, diltiazem) are commonly used to prevent recurrent nodal tachyarrhythmias such as PSVT. They work by **blocking L-type calcium channels** in cardiac slow-response tissues, which causes **slowing of phase 4 depolarization** and reduced conduction velocity in the SA and AV nodes.

(Choice A) Verapamil decreases the amount of intracellular calcium available for excitation-contraction coupling within cardiac myocytes. This reduces myocardial contractility, which can be harmful in patients with impaired ventricular function. However, the tracing shown in the question stem corresponds to pacemaker action potentials, not cardiac myocyte action potentials.

(Choices B and C) The threshold potential refers to the amount of depolarization required to initiate an action potential. Class I (sodium channel blockers) and class IV (calcium channel blockers) antiarrhythmics raise the threshold potential of cardiac fast- and slow-response tissues, respectively, by blocking the channels that trigger an action potential. This effect also results in reduced action potential amplitude, decreased upslope, and reduced impulse conduction speed within the respective tissues.

(Choice D) Verapamil's calcium blocking activity reduces the action potential duration in nodal tissues, but it also increases the refractory period by slowing the recovery of inactivated calcium channels. Class IA (eg, quinidine) and class III (eg, amiodarone) antiarrhythmics also increase the refractory period by blocking potassium channels and prolonging repolarization.

This patient's anxiety-provoked episodes of sudden-onset palpitations associated with lightheadedness and shortness of breath are consistent with **paroxysmal supraventricular tachycardia**. Class IV antiarrhythmics (eg, **verapamil**, diltiazem) are commonly used to prevent recurrent nodal tachyarrhythmias such as PSVT. They work by **blocking L-type calcium channels** in cardiac slow-response tissues, which causes **slowing of phase 4 depolarization** and reduced conduction velocity in the SA and AV nodes.

(Choice A) Verapamil decreases the amount of intracellular calcium available for excitation-contraction coupling within cardiac myocytes. This reduces myocardial contractility, which can be harmful in patients with impaired ventricular function. However, the tracing shown in the question stem corresponds to pacemaker action potentials, not cardiac myocyte action potentials.

(Choices B and C) The threshold potential refers to the amount of depolarization required to initiate an action potential. Class I (sodium channel blockers) and class IV (calcium channel blockers) antiarrhythmics raise the threshold potential of cardiac fast- and slow-response tissues, respectively, by blocking the channels that trigger an action potential. This effect also results in reduced action potential amplitude, decreased upslope, and reduced impulse conduction speed within the respective tissues.

(Choice D) Verapamil's calcium blocking activity reduces the action potential duration in nodal tissues, but it also increases the refractory period by slowing the recovery of inactivated calcium channels. Class IA (eg, quinidine) and class III (eg, amiodarone) antiarrhythmics also increase the refractory period by blocking potassium channels and prolonging repolarization.

Educational objective:
Class IV antiarrhythmics (eg, verapamil, diltiazem) are commonly used to prevent recurrent nodal arrhythmias (eg, paroxysmal supraventricular tachycardia). They work by blocking calcium channels in slow-response cardiac tissues, slowing phase 4 (spontaneous depolarization) and phase 0 (upstroke). This reduces impulse conduction velocity in the sinoatrial and atrioventricular nodes.

References

- Class IV antiarrhythmic agents: new compounds using an old strategy.
- Antiarrhythmic and anti-ischemic properties of calcium-channel antagonists.

Physiology	Cardiovascular System	Antiarrhythmic drugs
Subject	System	Topic

Copyright © UWorld. All rights reserved.

A 39-year-old man comes to the office due to increasing fatigue for the past 2 weeks. The patient reports no prior medical conditions, although he recently had a self-limiting upper respiratory illness. He does not use tobacco, alcohol, or illicit drugs and has not traveled recently. Temperature is 37.2 C (99 F), blood pressure is 116/66 mm Hg, pulse is 100/min, and respirations are 20/min. Physical examination reveals lung crackles. Echocardiography shows no valvular abnormalities and the following parameters:

Left ventricular end-diastolic volume	125 mL
Left ventricular end-systolic volume	75 mL

Based on the observed findings, which of the following is most accurate about this patient?

- A. Cardiac output is 4 L/min
- B. Cardiac output is 6 L/min
- C. Left ventricular ejection fraction is 40%
- D. Left ventricular ejection fraction is 60%
- E. Stroke volume is 40 mL
- F. Stroke volume is 60 mL

Submit

A 39-year-old man comes to the office due to increasing fatigue for the past 2 weeks. The patient reports no prior medical conditions, although he recently had a self-limiting upper respiratory illness. He does not use tobacco, alcohol, or illicit drugs and has not traveled recently. Temperature is 37.2 C (99 F), blood pressure is 116/66 mm Hg, pulse is 100/min, and respirations are 20/min. Physical examination reveals lung crackles. Echocardiography shows no valvular abnormalities and the following parameters:

Left ventricular end-diastolic volume	125 mL
Left ventricular end-systolic volume	75 mL

Based on the observed findings, which of the following is most accurate about this patient?

- A. Cardiac output is 4 L/min (1%)
- B. Cardiac output is 6 L/min (1%)
- ✓ C. Left ventricular ejection fraction is 40% (77%)
- D. Left ventricular ejection fraction is 60% (16%)
- E. Stroke volume is 40 mL (2%)
- F. Stroke volume is 60 mL (0%)

Omitted
Correct answer
C

77%
Answered correctly

02 secs
Time Spent

01/28/2020
Last Updated

Explanation

Explanation

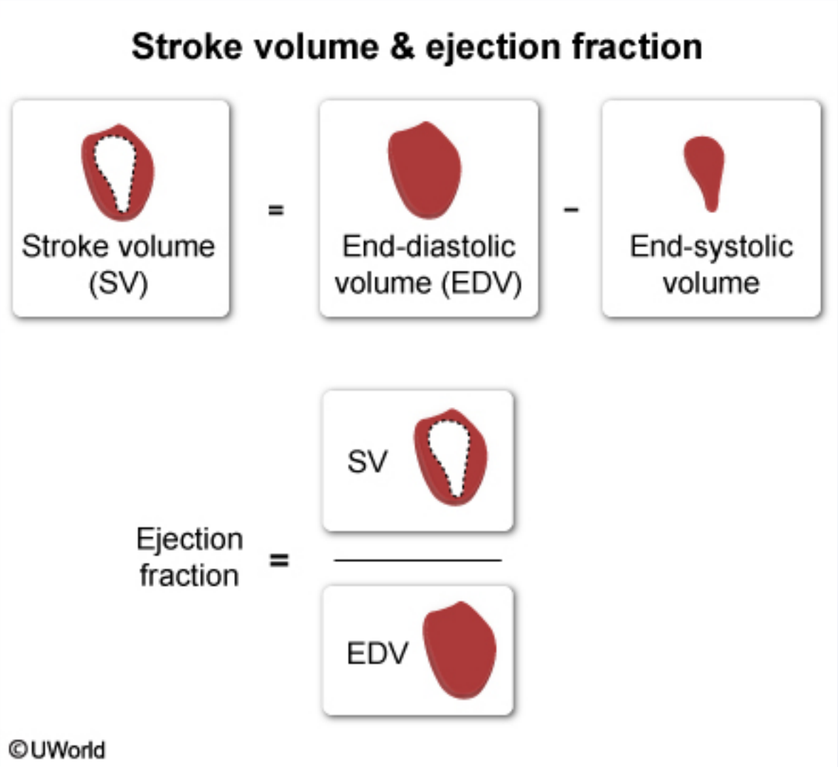

Left ventricular **stroke volume** is the absolute volume of blood ejected from the left ventricle with each contraction. It is calculated by subtracting the volume of blood in the left ventricle at the end of contraction, the **left ventricular end-systolic volume**, from the volume of blood in the left ventricle at the beginning of contraction, the **left ventricular end-diastolic volume** (LVEDV). This patient's stroke volume is 50 mL (125 mL − 75 mL), which is lower than the expected normal value of approximately 70 mL.

Ejection fraction, the relative volume of blood ejected from the left ventricle with each contraction, is calculated by dividing stroke volume by LVEDV. In this patient, the ejection fraction is 0.4 (50 mL / 125 mL). The fraction is typically multiplied by 100 and expressed as a percentage; therefore, this patient's left ventricular ejection fraction is **40%** (0.4 × 100), which is lower than the expected normal value of ≥50%.

©UWorld

Left ventricular **stroke volume** is the absolute volume of blood ejected from the left ventricle with each contraction. It is calculated by subtracting the volume of blood in the left ventricle at the end of contraction, the **left ventricular end-systolic volume**, from the volume of blood in the left ventricle at the beginning of contraction, the **left ventricular end-diastolic volume** (LVEDV). This patient's stroke volume is 50 mL (125 mL − 75 mL), which is lower than the expected normal value of approximately 70 mL.

Ejection fraction, the relative volume of blood ejected from the left ventricle with each contraction, is calculated by dividing stroke volume by LVEDV. In this patient, the ejection fraction is 0.4 (50 mL / 125 mL). The fraction is typically multiplied by 100 and expressed as a percentage; therefore, this patient's left ventricular ejection fraction is **40%** (0.4 × 100), which is lower than the expected normal value of ≥50%.

Cardiac output, the volume of blood ejected into the aorta per unit time, is estimated by multiplying stroke volume by heart rate. This patient's cardiac output is 5 L/min (50 mL × 100/min), which is normal. Although it is not pertinent to this patient, this equation overestimates cardiac output in the setting of mitral regurgitation because a portion of the stroke volume flows backward into the left atrium with each contraction.

This patient's presentation is consistent with left ventricular **systolic dysfunction** leading to **heart failure with reduced ejection fraction**. He has only mild symptoms at present because the low stroke volume is being compensated by an elevated heart rate to maintain cardiac output; however, further decompensation with reduced cardiac output is likely over time.

Educational objective:
Stroke volume is the absolute volume of blood ejected from the left ventricle with each contraction and is calculated by subtracting left ventricular end-systolic volume from left ventricular end-diastolic volume (LVEDV). Ejection fraction is the relative volume of blood ejected from the left ventricle with each contraction; it is calculated by dividing stroke volume by LVEDV. Cardiac output, the volume of blood ejected into the aorta per unit time, is estimated by multiplying stroke volume by heart rate.

Physiology	Cardiovascular System	Acute heart failure
Subject	System	Topic

Copyright © UWorld. All rights reserved.

A 54-year-old man is being evaluated for exertional dyspnea that started 6 months ago. The patient has no associated cough or wheezing. There is no known history of heart disease in his family. ECG, chest x-ray, exercise stress test, and echocardiogram are obtained to evaluate his symptoms. He subsequently undergoes right and left cardiac catheterization, and the results are as follows:

Arterial blood oxygen content	20 mL O_2/100 mL blood
Pulmonary artery diastolic pressure	12 mm Hg
Left ventricular diastolic pressure	10 mm Hg
Mean right atrial pressure	4 mm Hg
Venous blood oxygen content	15 mL O_2/100 mL blood

What additional information is necessary to calculate cardiac output in this patient?

A. Arteriovenous difference in oxygen content
B. Oxygen-binding capacity of hemoglobin
C. Percentage of hemoglobin saturation
D. Rate of oxygen consumption
E. Respiratory quotient

Submit

A 54-year-old man is being evaluated for exertional dyspnea that started 6 months ago. The patient has no associated cough or wheezing. There is no known history of heart disease in his family. ECG, chest x-ray, exercise stress test, and echocardiogram are obtained to evaluate his symptoms. He subsequently undergoes right and left cardiac catheterization, and the results are as follows:

Arterial blood oxygen content	20 mL O_2/100 mL blood
Pulmonary artery diastolic pressure	12 mm Hg
Left ventricular diastolic pressure	10 mm Hg
Mean right atrial pressure	4 mm Hg
Venous blood oxygen content	15 mL O_2/100 mL blood

What additional information is necessary to calculate cardiac output in this patient?

A. Arteriovenous difference in oxygen content (10%)
B. Oxygen-binding capacity of hemoglobin (2%)
C. Percentage of hemoglobin saturation (6%)
✓ D. Rate of oxygen consumption (73%)
E. Respiratory quotient (6%)

Omitted
Correct answer
D

73%
Answered correctly

02 secs
Time Spent

04/06/2020
Last Updated

Cardiac output, expressed in liters per minute, is commonly calculated using the following formula:

Cardiac output = stroke volume x heart rate

Cardiac output can also be determined with a pulmonary artery (Swan-Ganz) catheter by applying the **Fick principle**, which uses the rate of oxygen consumption and the arteriovenous oxygen difference:

Cardiac output = rate of O_2 consumption / arteriovenous O_2 content difference

Arterial oxygen content is measured directly from arterial blood, and mixed venous oxygen content is measured from pulmonary arterial blood. The rate of oxygen consumption can be determined with an oxygen meter by measuring the rate of disappearance of oxygen in exhaled air.

(Choice A) The arteriovenous difference in oxygen content can be calculated using the information provided in the question stem (eg, arterial blood O_2 content - venous blood O_2 content).

(Choices B and C) The oxygen-binding capacity of hemoglobin and percentage of hemoglobin saturation can be used to calculate blood oxygen content using the following equation:

Blood O_2 content = (O_2-binding capacity x % saturation) + dissolved O_2

Dissolved oxygen is the amount of oxygen unbound to hemoglobin and typically makes up a small fraction of the total blood oxygen content.

(Choice E) The respiratory quotient is the ratio of CO_2 to O_2 across the alveolar membrane, and is used to estimate the metabolic rate. The normal value is typically 0.8.

Educational objective:
The Fick principle can be applied to calculate cardiac output using the rate of oxygen consumption and the arteriovenous oxygen content difference:

Cardiac output = rate of O_2 consumption / arteriovenous O_2 content difference

References

- Cardiac output monitoring: Basic science and clinical application.

1 2 3 4 5 6 7 8 9 10 11 12 13 14 15 16 17 18 19 20 21 22 23 24 25 26 27 28 29 30 31

Special electrodes are used to detect the change in membrane potential of a specific type of cardiac cell. These changes are recorded on the graph below.

©UWorld

The deflection indicated by the arrow is most likely caused by movement of which of the following ions?

- A. Sodium
- B. Potassium
- C. Calcium
- D. Chloride
- E. Sodium and potassium
- F. Calcium and potassium

Submit

1 2 3 4 5 6 7 8 9 10 11 12 13 14 15 16 17 18 19 20 21 22 23 24 25 26 27 28 29 30 31

Special electrodes are used to detect the change in membrane potential of a specific type of cardiac cell. These changes are recorded on the graph below.

©UWorld

The deflection indicated by the arrow is most likely caused by movement of which of the following ions?

- A. Sodium (20%)
- B. Potassium (2%)
- ✓ C. Calcium (71%)
- D. Chloride (0%)
- E. Sodium and potassium (2%)
- F. Calcium and potassium (2%)

Omitted
Correct answer
C

71%
Answered correctly

03 secs
Time Spent

04/07/2020
Last Updated

1
2
3
4
5
6
7
8
9
10
11
12
13
14
15
16
17
18
19
20
21
22
23
24
25
26
27
28
29
30
31

Cardiac action potentials

Pacemaker action potential

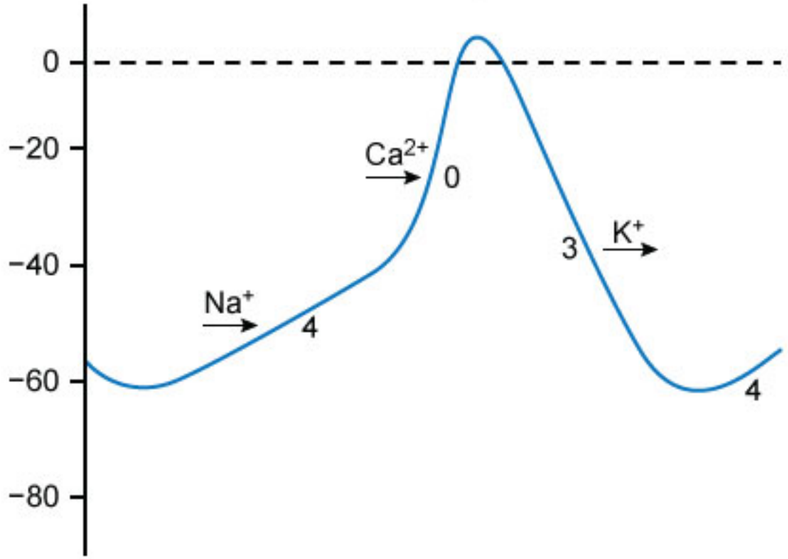

Nonpacemaker action potential

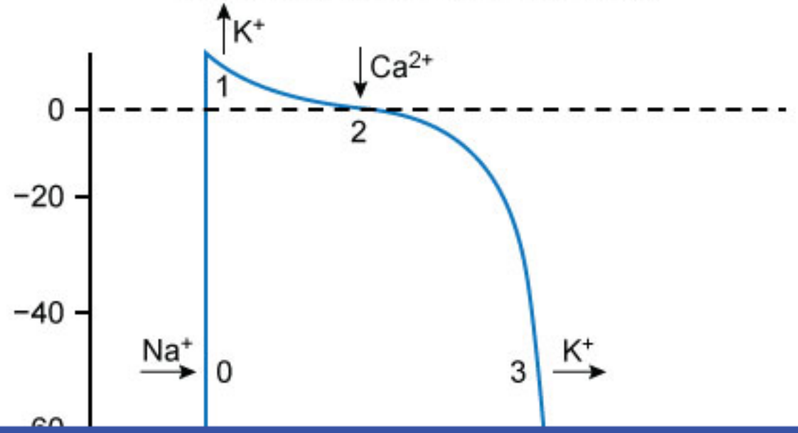

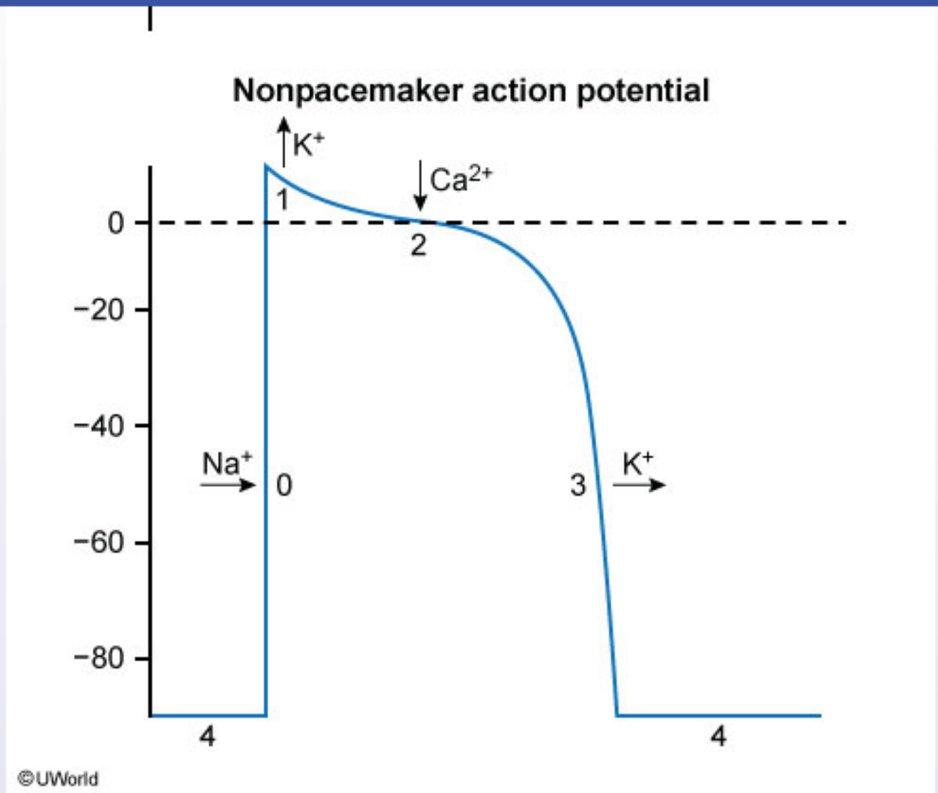

The graph in the question stem illustrates an action potential typical of cardiac **pacemaker cells**, such as those found in the sinoatrial node. These action potentials are different from non-pacemaker cardiac action potentials in that phases 1 and 2 are absent and phase 4 represents a slow depolarization phase.

Pacemaker cells are unique in that they exhibit automaticity (an inherent ability to depolarize without any external influences). Automaticity is made possible by a inward, mixed sodium-potassium current (the **funny current**) that occurs during phase 4 of the action potential **(Choice E)**. This current gradually brings the membrane potential closer to threshold, at which point phase 0 depolarization occurs due to a **large increase in calcium influx (arrow)**. Pacemaker cell depolarization is then followed by phase 3 (repolarization), which is caused by an outward potassium current **(Choice B)**.

1
2
3
4
5
6
7
8
9
10
11
12
13
14
15
16
17
18
19
20
21
22
23
24
25
26
27
28
29
30
31

The graph in the question stem illustrates an action potential typical of cardiac **pacemaker cells**, such as those found in the sinoatrial node. These action potentials are different from non-pacemaker cardiac action potentials in that phases 1 and 2 are absent and phase 4 represents a slow depolarization phase.

Pacemaker cells are unique in that they exhibit automaticity (an inherent ability to depolarize without any external influences). Automaticity is made possible by a inward, mixed sodium-potassium current (the **funny current**) that occurs during phase 4 of the action potential **(Choice E)**. This current gradually brings the membrane potential closer to threshold, at which point phase 0 depolarization occurs due to a **large increase in calcium influx (arrow)**. Pacemaker cell depolarization is then followed by phase 3 (repolarization), which is caused by an outward potassium current **(Choice B)**.

In cardiomyocytes and Purkinje cells (**non-pacemaker cells**), phase 4 corresponds to the resting membrane potential and is typically stable at approximately -90 mV (near the equilibrium potential of potassium). Phase 0 of the non-pacemaker action potential is mediated by rapid sodium influx **(Choice A)**, in contrast to the slower calcium-mediated depolarization of pacemaker cells. Phase 1 is an early short repolarization occurring immediately after depolarization that is caused by increased outflow of potassium and decreased sodium conductance. Phase 2 is the plateau phase of the action potential, during which an inward calcium current counteracts the outward movement of potassium ions that started in phase 1 **(Choice F)**. Phase 3 (repolarization) occurs as the inward calcium current ceases while potassium continues to rush out of the cell.

Educational objective:
In cardiac pacemaker cells, phase 0 depolarization is mediated by an inward flux of calcium. This differs from phase 0 of cardiomyocytes and Purkinje cells, which results from an inward sodium current.

Physiology	Cardiovascular System	Cardiac physiology
Subject	System	Topic

Copyright © UWorld. All rights reserved.

1
2
3
4
5
6
7
8
9
10
11
12
13
14
15
16
17
18
19
20
21
22
23
24
25
26
27
28
29
30
31

A 54-year-old man is admitted to the hospital due to cough, shortness of breath, and chest discomfort. He has a known history of coronary artery disease and underwent coronary artery bypass graft surgery 3 years ago. As a result of drug therapy, the left ventricular pressure-volume loop changes from a solid to a dashed line as shown on the graph below.

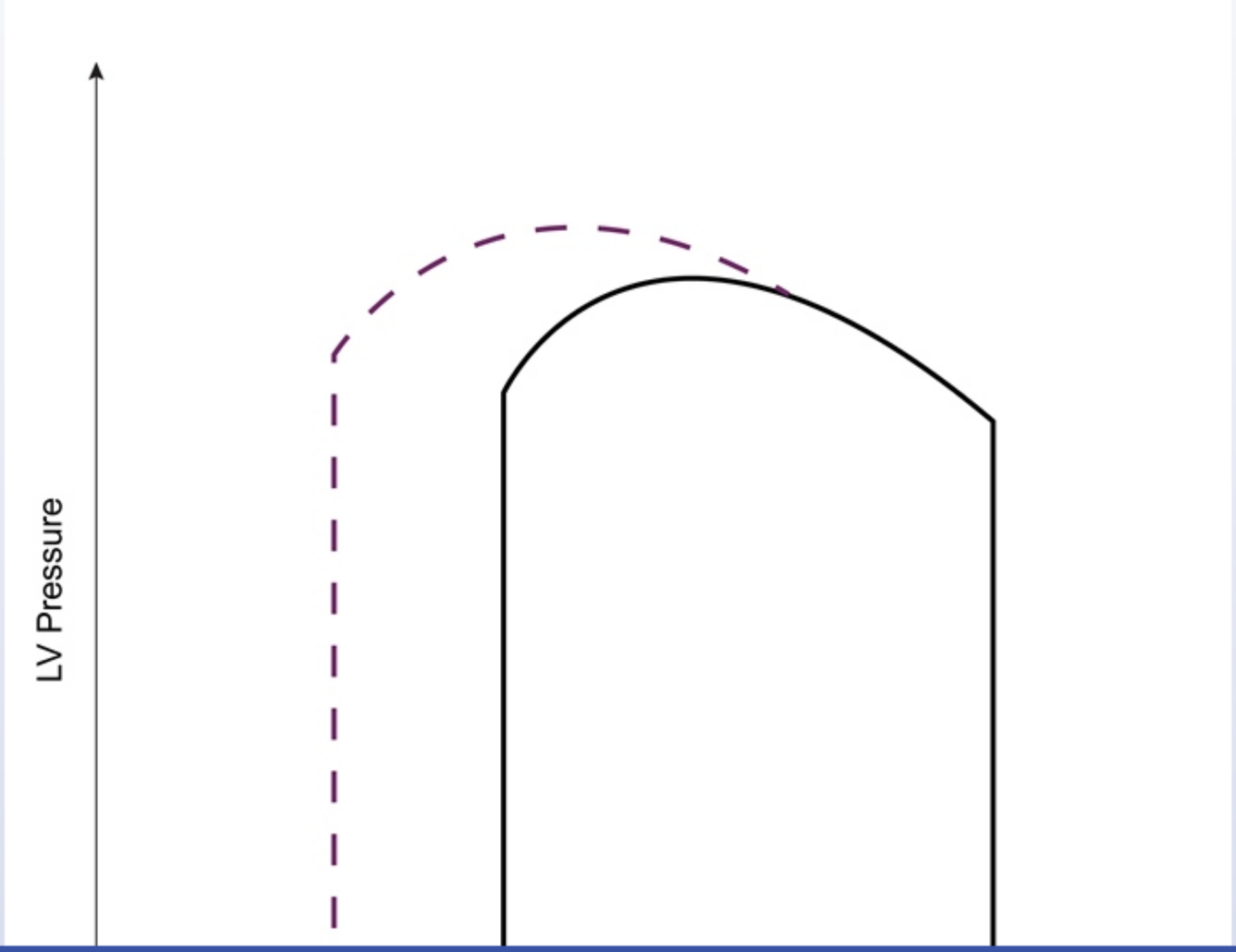

4
5
6
7
8
9
10
11
12
13
14
15
16
17
18
19
20
21
22
23
24
25
26
27
28
29
30
31
32
33
34

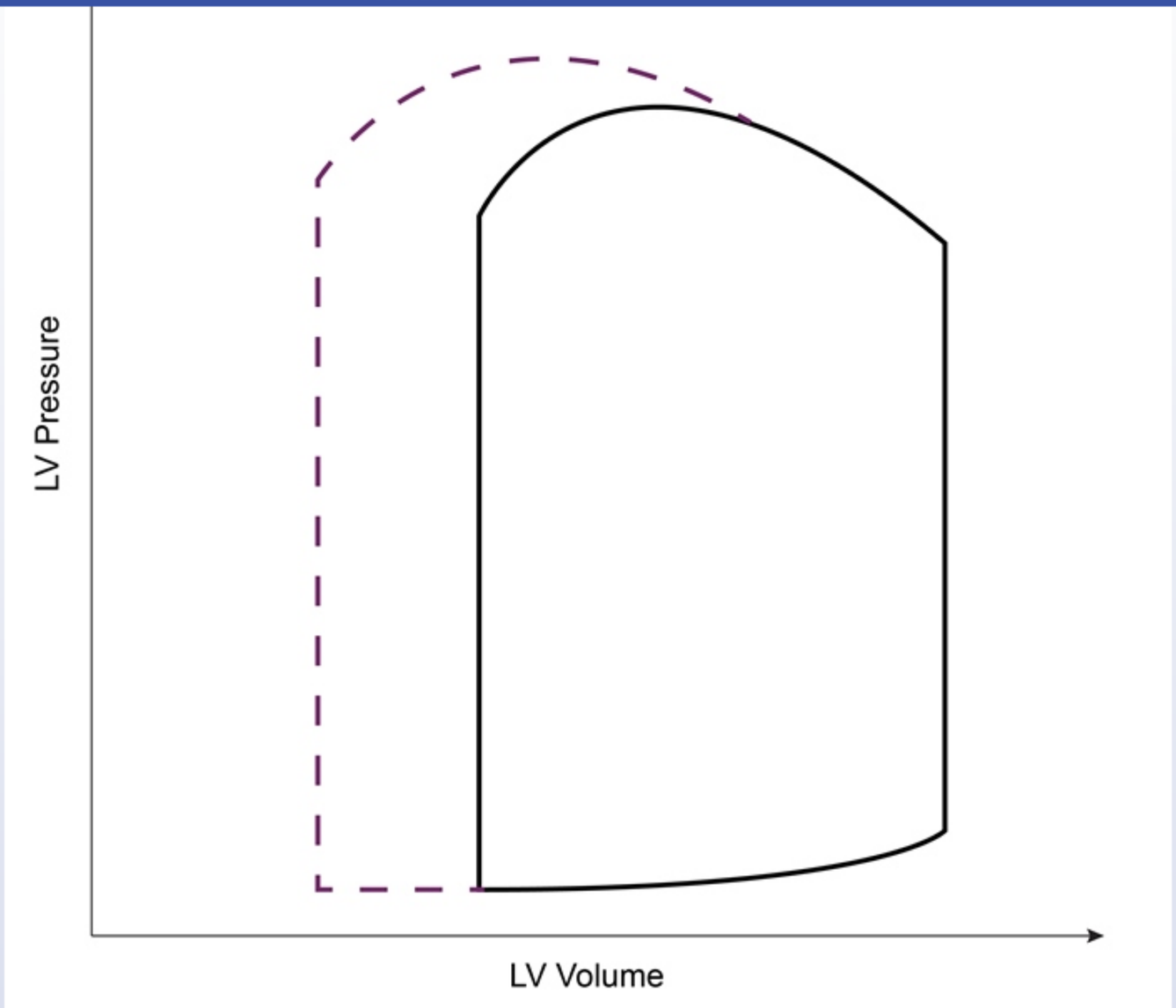

Which of the following parameters is most likely to increase as a result of this change?

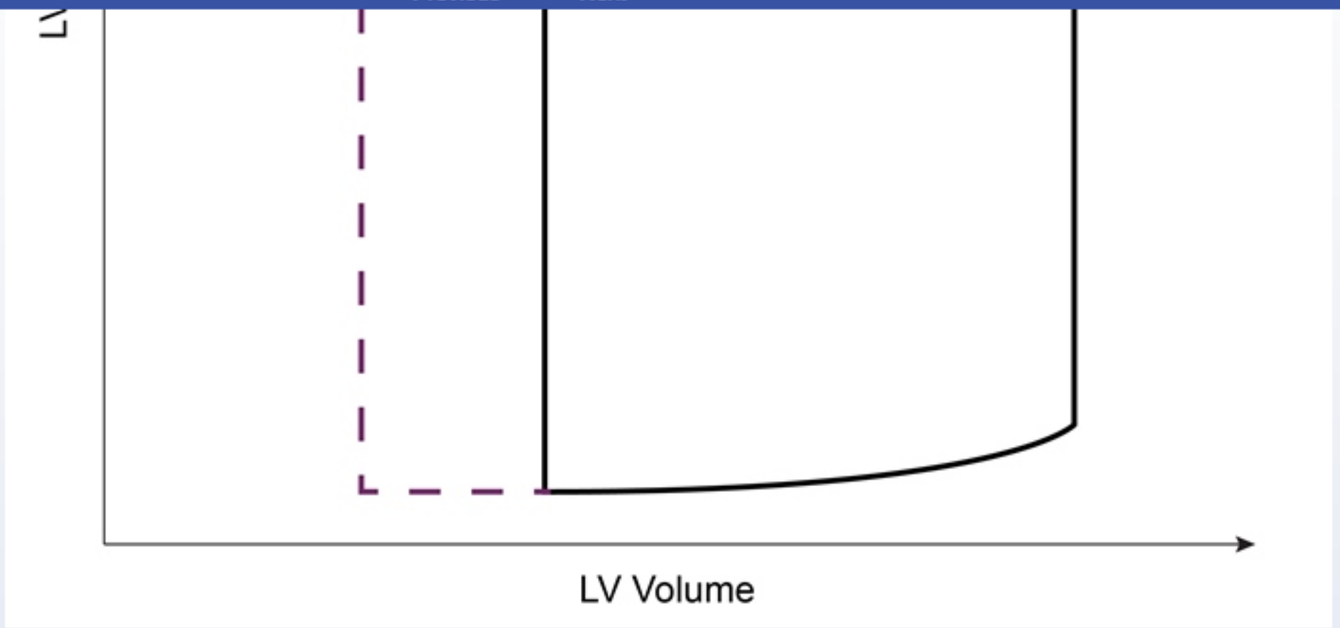

Which of the following parameters is most likely to increase as a result of this change?

- A. End-diastolic pressure
- B. End-systolic volume
- C. Stroke volume
- D. Ventricular afterload
- E. Ventricular preload

Submit

4
5
6
7
8
9
10
11
12
13
14
15
16
17
18
19
20
21
22
23
24
25
26
27
28
29
30
31
32
33
34

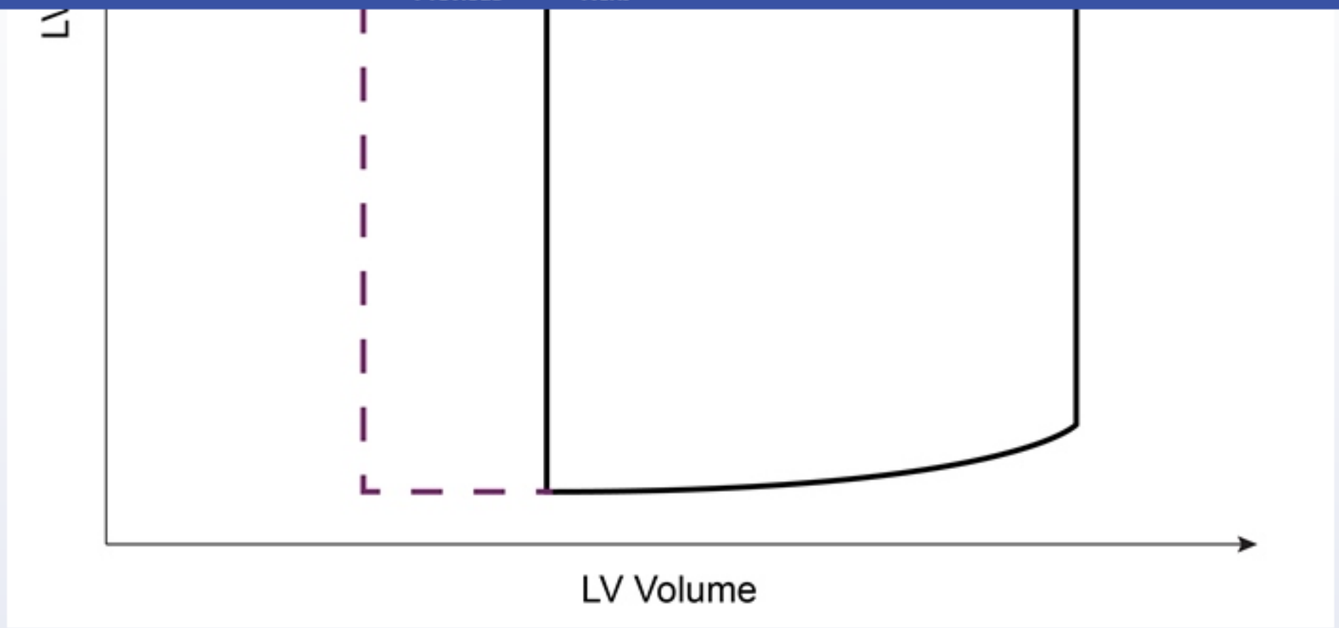

Which of the following parameters is most likely to increase as a result of this change?

- A. End-diastolic pressure (4%)
- B. End-systolic volume (5%)
- ✓ C. Stroke volume (79%)
- D. Ventricular afterload (4%)
- E. Ventricular preload (6%)

Omitted
Correct answer

79%
Answered correctly

08 secs
Time Spent

05/06/2020
Last Updated

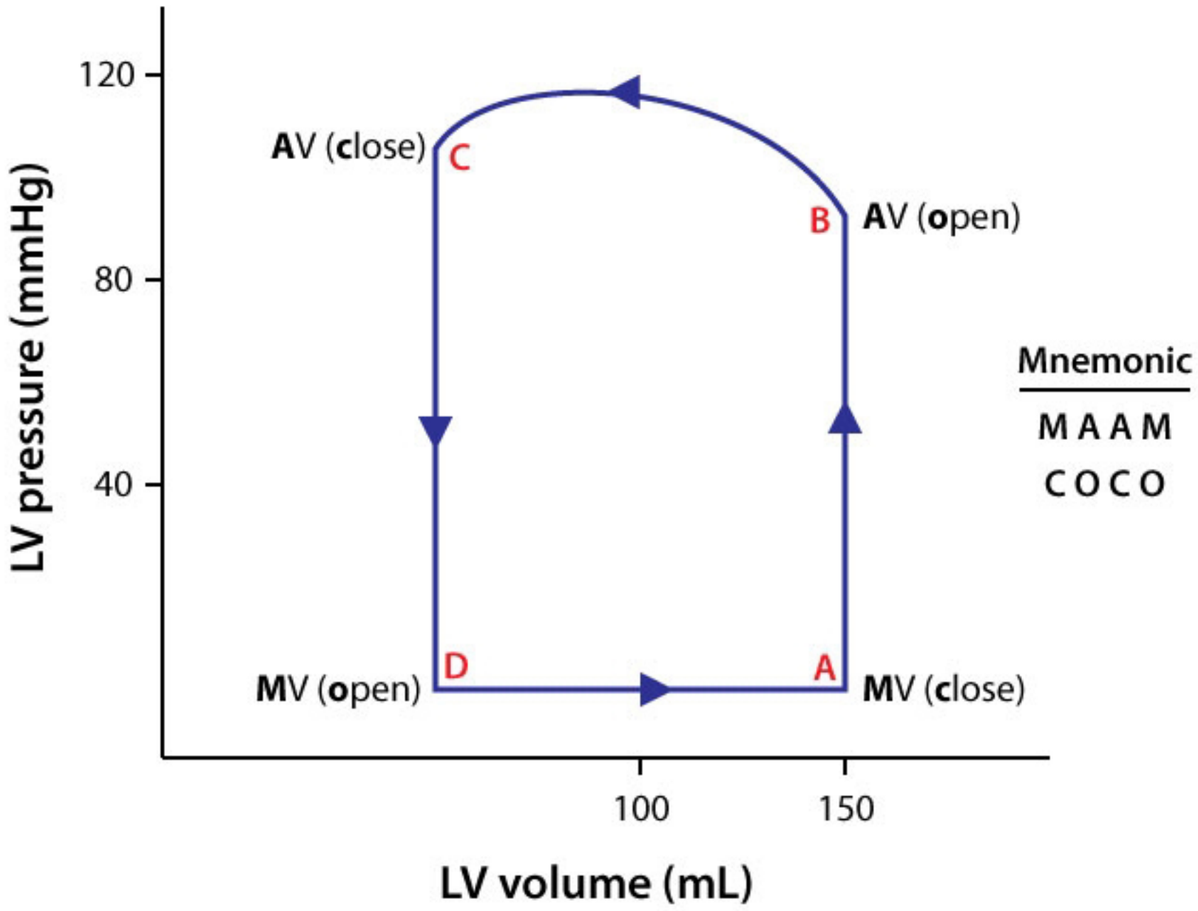

Mnemonic

M A A M
C O C O

A → B = Isovolumetric contraction
B → C = Ventricular ejection
} Ventricular systole

4
5
6
7
8
9
10
11
12
13
14
15
16
17
18
19
20
21
22
23
24
25
26
27
28
29
30
31
32
33
34

Exhibit Display

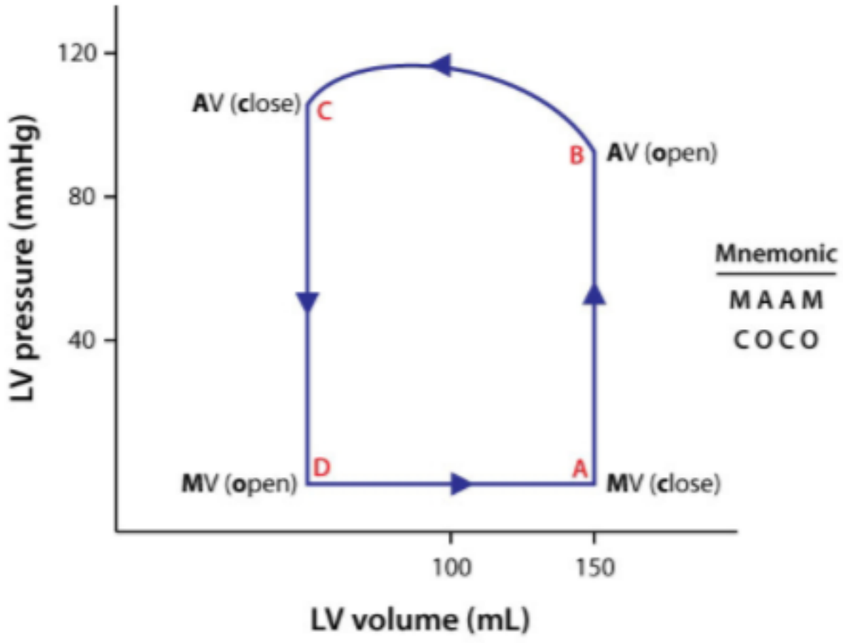

Mnemonic

M A A M
C O C O

A → B = Isovolumetric contraction
B → C = Ventricular ejection
} Ventricular systole

C → D = Isovolumetric relaxation
D → A = Ventricular filling
} Ventricular diastole

©UWorld

Zoom In | Zoom Out | Reset | Add To New Card | Existing Card

D → A = Ventricular filling

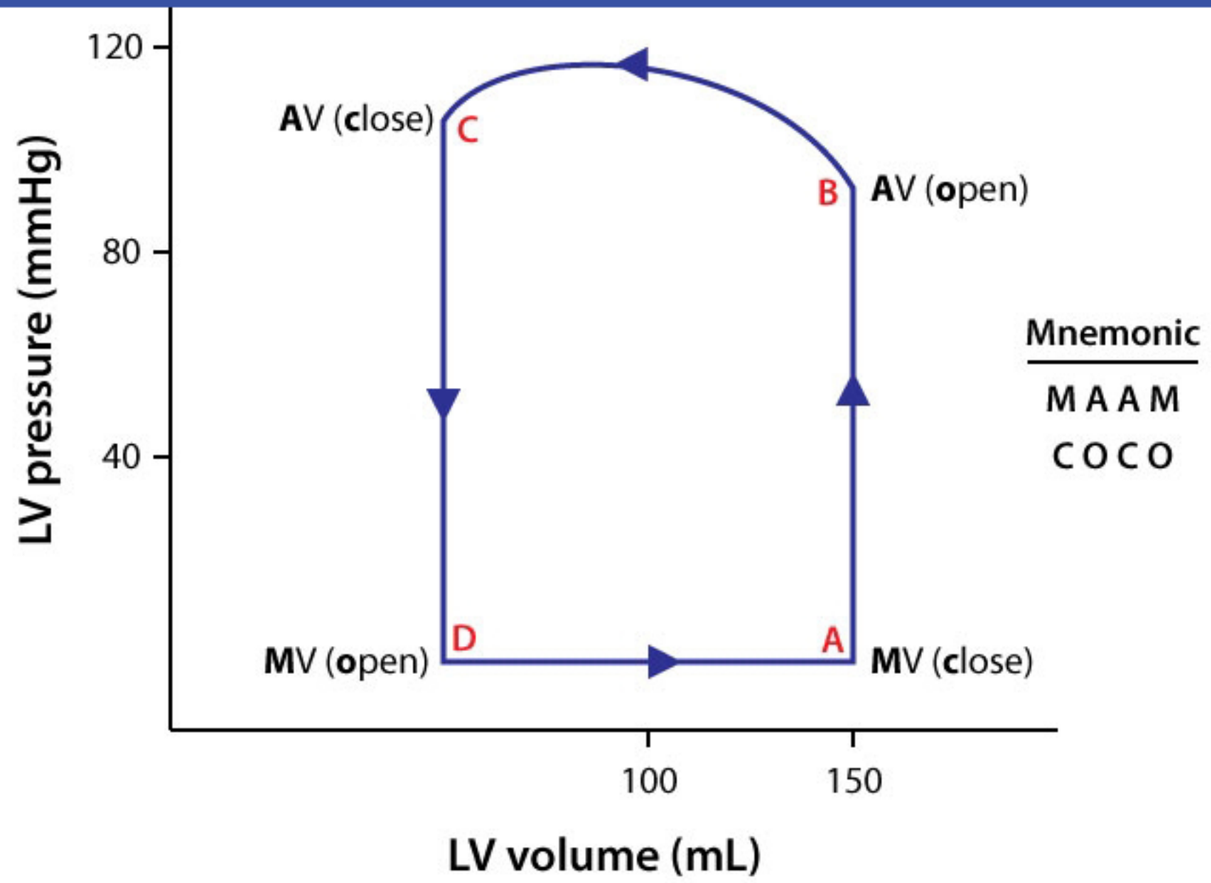

Mnemonic

M A A M
C O C O

A → B = Isovolumetric contraction
B → C = Ventricular ejection
} Ventricular systole

C → D = Isovolumetric relaxation
D → A = Ventricular filling
} Ventricular diastole

D ⟶ A = Ventricular filling

©UWorld

The ventricular pressure-volume loop depicts the relationship between the pressure and volume of blood ejected from the left ventricle (stroke volume or ejection fraction). The difference between points B and C on the x axis represents the volume of blood ejected or forward effective stroke volume during contraction. The changes noted in the pressure-volume loop as a result of this patient's drug therapy (dashed line) indicate **increased contractility** with a larger volume of blood ejected. As a result, there will be an **increase in effective stroke volume** or ejection fraction.

(Choices A and E) Left ventricular (LV) end-diastolic volume and pressure occur at point A, which represents the volume of blood in the left ventricle after closure of the mitral valve. LV end-diastolic volume determines the stretch of myocardial fibers at end-diastole and corresponds to LV preload. The diagram does not indicate increased preload.

(Choice B) LV end-systolic volume refers to the volume of blood remaining in the ventricular cavity after myocardial contraction (point C). It would be increased in states of decreased cardiac contractility; the ventricular pressure-volume loop would be narrow with a shift in the isovolumetric relaxation line to the right.

(Choice D) Ventricular afterload is increased when there is increased systemic blood pressure against which the ventricle has to generate force during isovolumic contraction to open the aortic valve (point B). The ventricular pressure-volume loop would show elevated pressures during the isovolumetric ventricular contraction phase before the aortic valve opens.

Educational objective:
An increase in effective stroke volume or ejection fraction is depicted on the left ventricular pressure-volume relationship by widening of the loop with a shift in the isovolumic relaxation line to the left (indicating less residual blood volume in the ventricle at end-systole).

Physiology	Cardiovascular System	Cardiac physiology
Subject	System	Topic

Copyright © UWorld. All rights reserved.

D ⟶ A = Ventricular filling

Exhibit Display

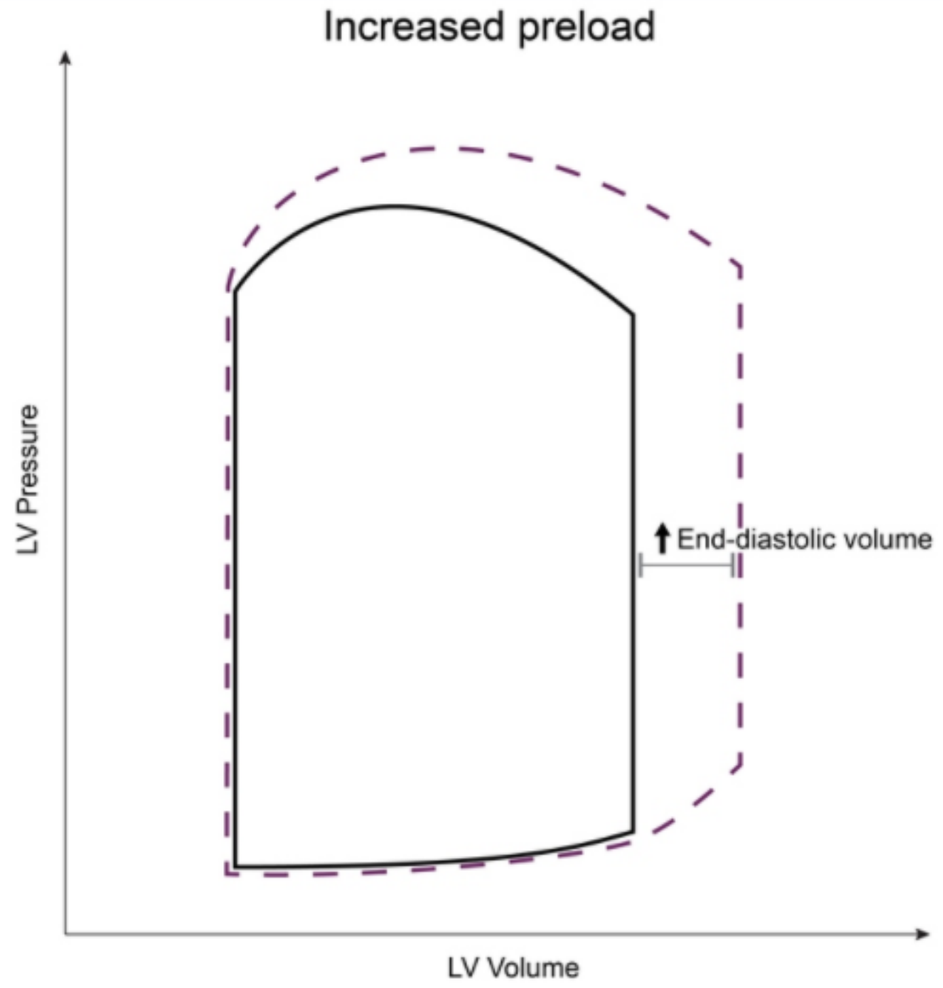

Zoom In Zoom Out Reset Add To New Card | Existing Card

D ⟶ A = Ventricular filling

Exhibit Display

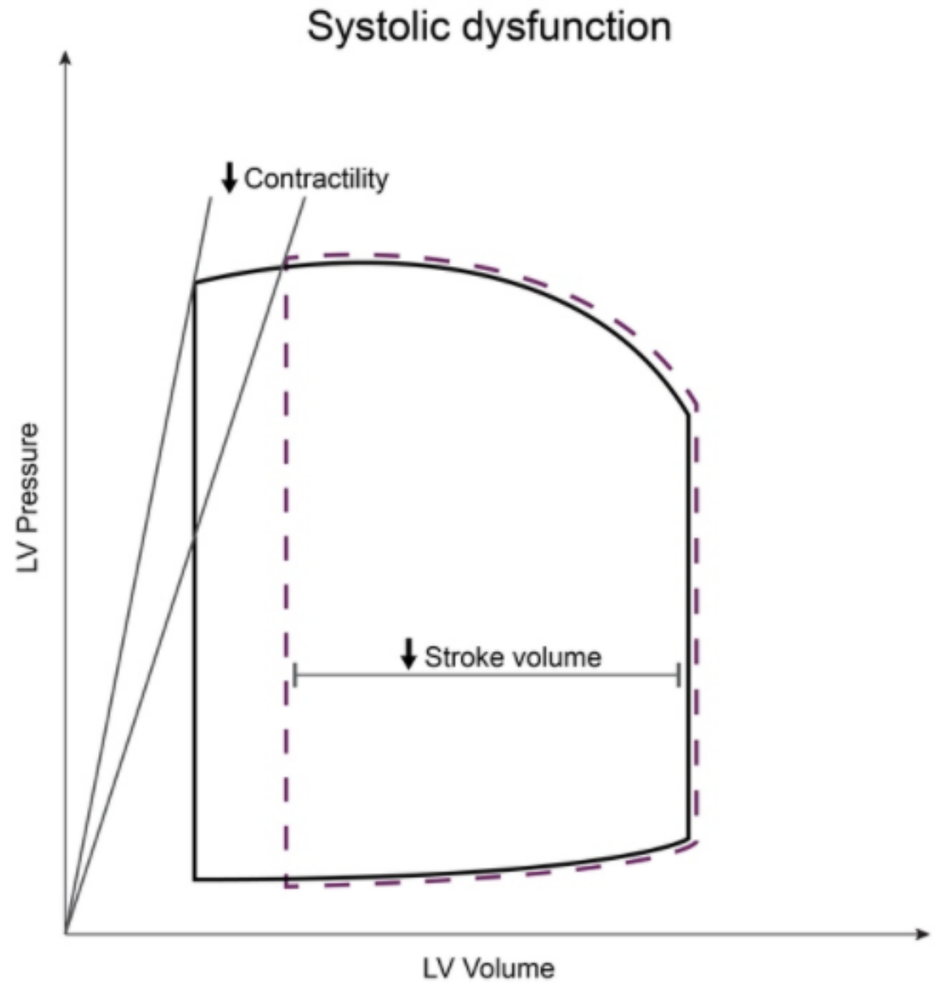

Zoom In | Zoom Out | Reset | Add To New Card | Existing Card

D ⟶ A = Ventricular filling

Exhibit Display

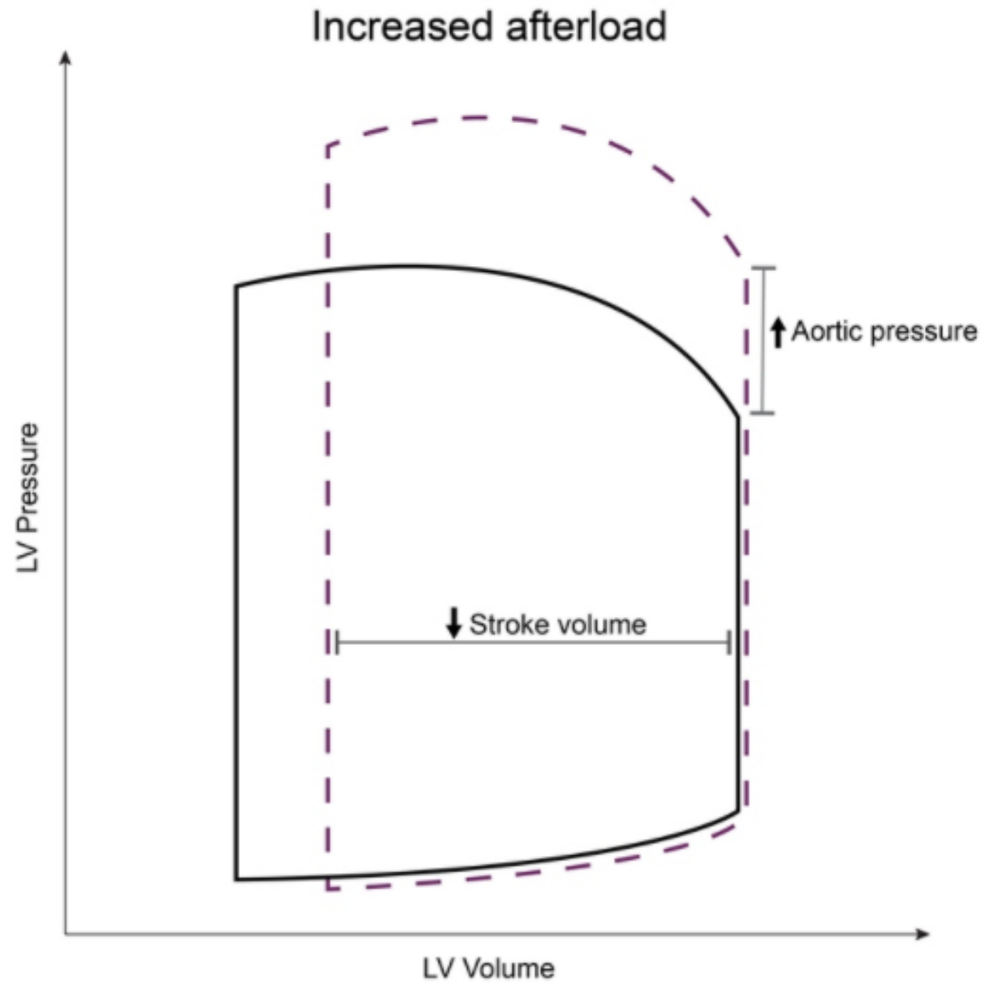

Zoom In | Zoom Out | Reset | Add To New Card | Existing Card

4
5
6
7
8
9
10
11
12
13
14
15
16
17
18
19
20
21
22
23
24
25
26
27
28
29
30
31
32
33
34

Membrane potential changes in an isolated cardiac muscle cell are recorded along with ion movements across the cell membrane (see graph below).

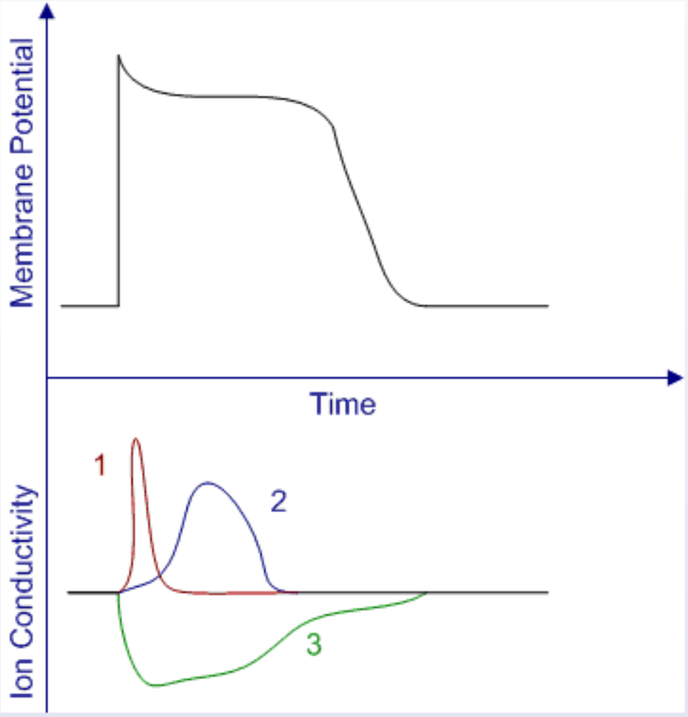

Which of the following ion sequences corresponds to regions 1-2-3 on the graph, respectively?

A. Potassium, sodium, calcium

B. Sodium, calcium, potassium

C. Calcium, sodium, chloride

D. Calcium, sodium, potassium

4
5
6
7
8
9
10
11
12
13
14
15
16
17
18
19
20
21
22
23
24
25
26
27
28
29
30
31
32
33
34

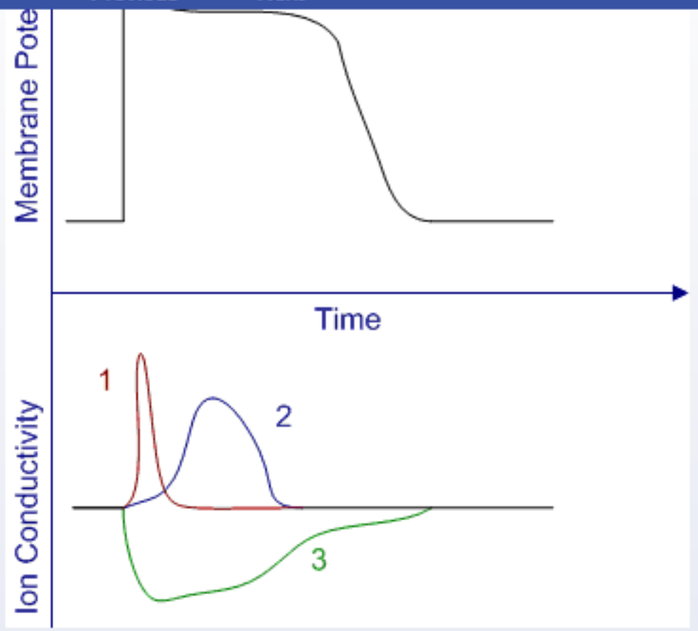

Which of the following ion sequences corresponds to regions 1-2-3 on the graph, respectively?

A. Potassium, sodium, calcium

B. Sodium, calcium, potassium

C. Calcium, sodium, chloride

D. Calcium, sodium, potassium

E. Sodium, potassium, calcium

Submit

4
5
6
7
8
9
10
11
12
13
14
15
16
17
18
19
20
21
22
23
24
25
26
27
28
29
30
31
32
33
34

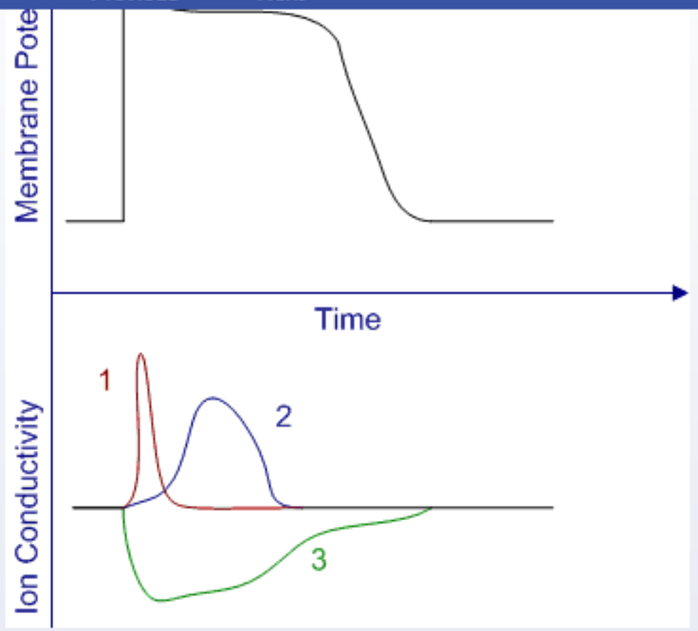

Which of the following ion sequences corresponds to regions 1-2-3 on the graph, respectively?

A. Potassium, sodium, calcium (1%)
B. Sodium, calcium, potassium (87%)
C. Calcium, sodium, chloride (0%)
D. Calcium, sodium, potassium (3%)
E. Sodium, potassium, calcium (7%)

Omitted
Correct answer

87%
Answered correctly

05 secs
Time Spent

02/03/2020
Last Updated

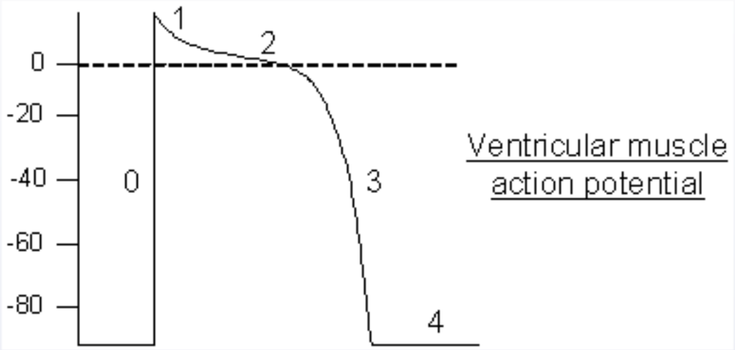

The action potential of ventricular and non-nodal conduction cells within the heart consists of four phases.

1. **Phase 4: Resting potential (diastole).** Resting potential is determined largely by membrane permeability to K^+ ions when in the resting state. The resting potential of cardiac myocytes is approximately -90mV, while the resting potential of skeletal myocytes is approximately -75mV. The highly negative resting potential of cardiac myocytes reduces the risk of arrhythmias, as a larger stimulus is needed to excite the cells.
2. **Phase 0: Rapid depolarization.** As in skeletal myocytes, the action potential onset occurs when voltage-gated Na^+ channels open and Na^+ ions rush into the cell.
3. **Phase 1: Initial rapid repolarization.** This phase is associated with the rapid closure of Na^+ channels.
4. **Phase 2: Plateau.** This phase is a distinctive feature of the cardiac action potential not seen in other tissues. It is characterized by the opening of L-type dihydropyridine-sensitive Ca^{++} channels and the closure of some K^+ channels. Consequently, the membrane becomes highly permeable to Ca^{++} ions and minimally permeable to K^+ ions.
5. **Phase 3: Late rapid repolarization.** This phase features closure of Ca^{++} channels and the opening of K^+ channels. Efflux of K^+ from the cell restores the membrane resting potential.

In sum, the cardiac myocyte action potential includes the following three key events: Na^+ ion influx (corresponding to the red curve on the ion conductivity graph); Ca^{++} ion influx (corresponding to the blue curve on the ion conductivity graph); and decreased K^+ permeability during the action potential upstroke (corresponding to the green curve on the ion conductivity graph).

(Choices A, C, D, and E) The other ion sequences listed do not correlate with the action potential phases observed in cardiac myocytes.

The action potential of ventricular and non-nodal conduction cells within the heart consists of four phases.

1. **Phase 4: Resting potential (diastole).** Resting potential is determined largely by membrane permeability to K^+ ions when in the resting state. The resting potential of cardiac myocytes is approximately -90mV, while the resting potential of skeletal myocytes is approximately -75mV. The highly negative resting potential of cardiac myocytes reduces the risk of arrhythmias, as a larger stimulus is needed to excite the cells.
2. **Phase 0: Rapid depolarization.** As in skeletal myocytes, the action potential onset occurs when voltage-gated Na^+ channels open and Na^+ ions rush into the cell.
3. **Phase 1: Initial rapid repolarization.** This phase is associated with the rapid closure of Na^+ channels.
4. **Phase 2: Plateau.** This phase is a distinctive feature of the cardiac action potential not seen in other tissues. It is characterized by the opening of L-type dihydropyridine-sensitive Ca^{++} channels and the closure of some K^+ channels. Consequently, the membrane becomes highly permeable to Ca^{++} ions and minimally permeable to K^+ ions.
5. **Phase 3: Late rapid repolarization.** This phase features closure of Ca^{++} channels and the opening of K^+ channels. Efflux of K^+ from the cell restores the membrane resting potential.

In sum, the cardiac myocyte action potential includes the following three key events: Na^+ ion influx (corresponding to the red curve on the ion conductivity graph); Ca^{++} ion influx (corresponding to the blue curve on the ion conductivity graph); and decreased K^+ permeability during the action potential upstroke (corresponding to the green curve on the ion conductivity graph).

(Choices A, C, D, and E) The other ion sequences listed do not correlate with the action potential phases observed in cardiac myocytes.

Educational Objective:
The cardiac myocyte action potential consists of rapid depolarization (phase 0), initial rapid repolarization (phase 1), plateau (phase 2), late rapid repolarization (phase 3), and resting potential (phase 4). The action potential is associated with increased membrane permeability to Na^+ and Ca^{++} and decreased permeability to K^+.

Physiology	Cardiovascular System	Resting membrane potential and action potential
Subject	System	Topic

4
5
6
7
8
9
10
11
12
13
14
15
16
17
18
19
20
21
22
23
24
25
26
27
28
29
30
31
32
33
34

A 34-year-old woman who recently emigrated from Russia comes to the physician complaining of weakness, exertional dyspnea, and orthopnea. On cardiac auscultation, a snap followed by a rumbling diastolic murmur is heard over the cardiac apex. The snap most likely occurs nearest to which of the following points on the cardiac pressure-volume loop?

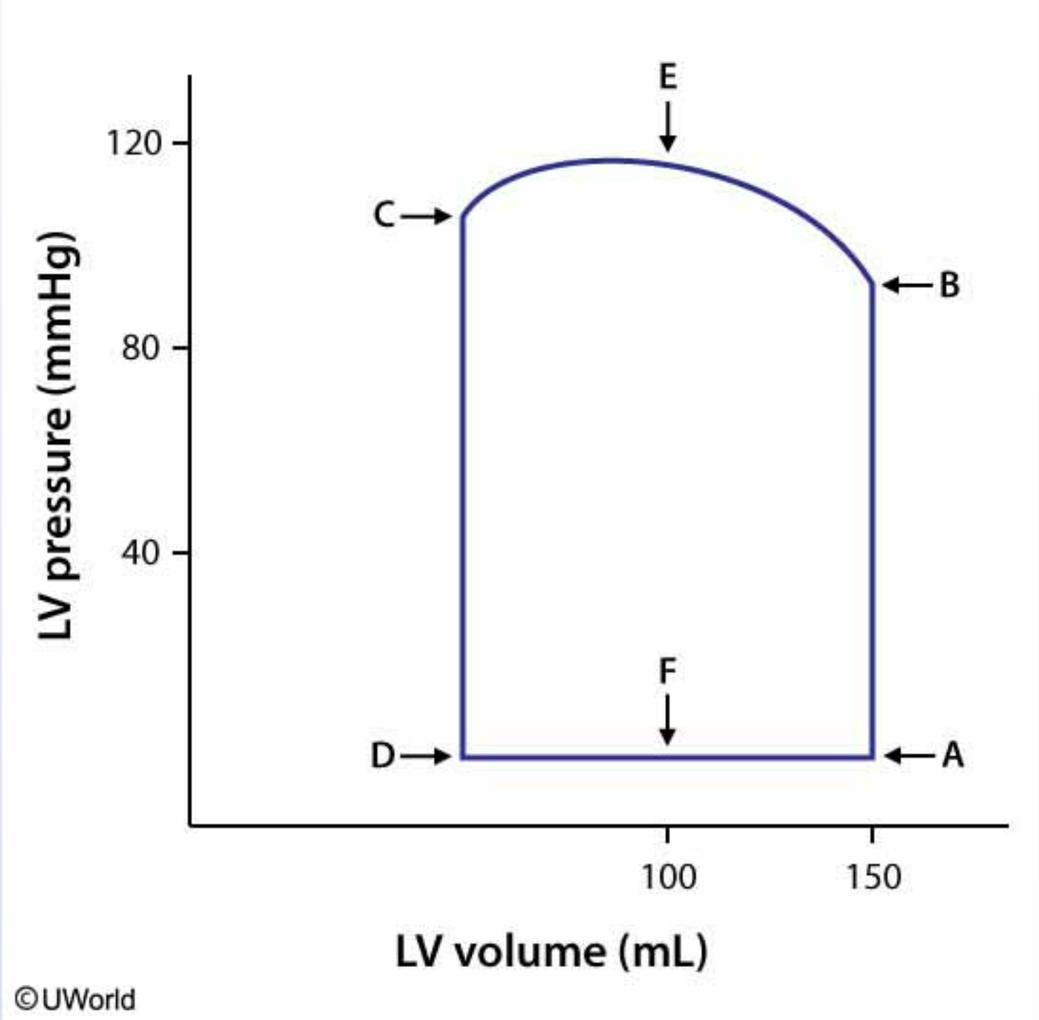

On cardiac auscultation, a snap followed by a rumbling diastolic murmur is heard over the cardiac apex. The snap most likely occurs nearest to

Exhibit Display

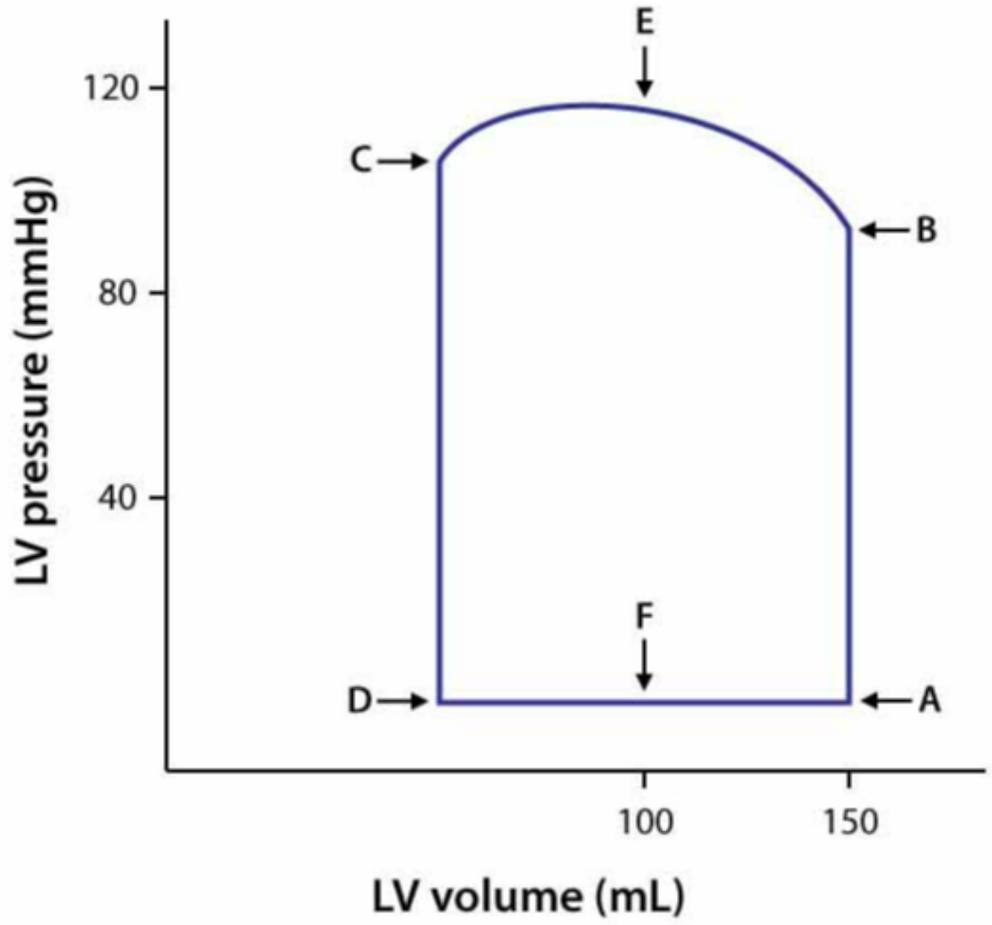

©UWorld

Zoom In | Zoom Out | Reset | Add To New Card | Existing Card

A. A

4
5
6
7
8
9
10
11
12
13
14
15
16
17
18
19
20
21
22
23
24
25
26
27
28
29
30
31
32
33
34

Which of the following points on the cardiac pressure-volume loop?

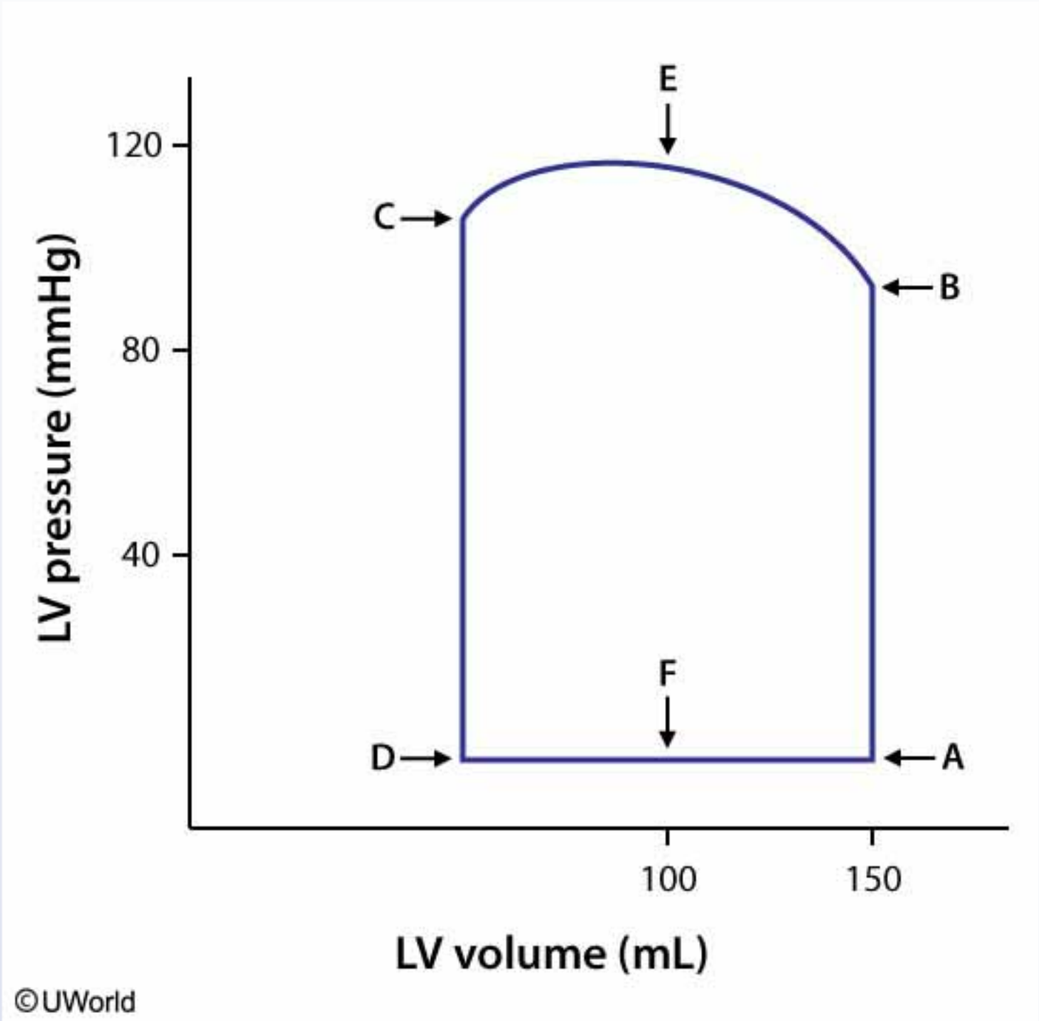

A. A

B. B

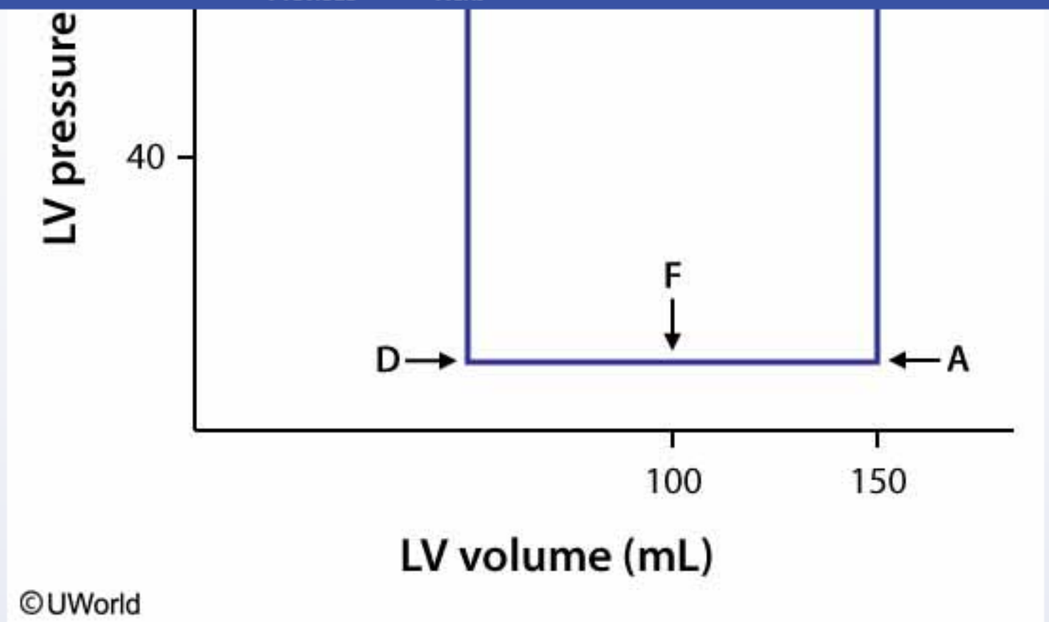

A. A
B. B
C. C
D. D
E. E
F. F

Submit

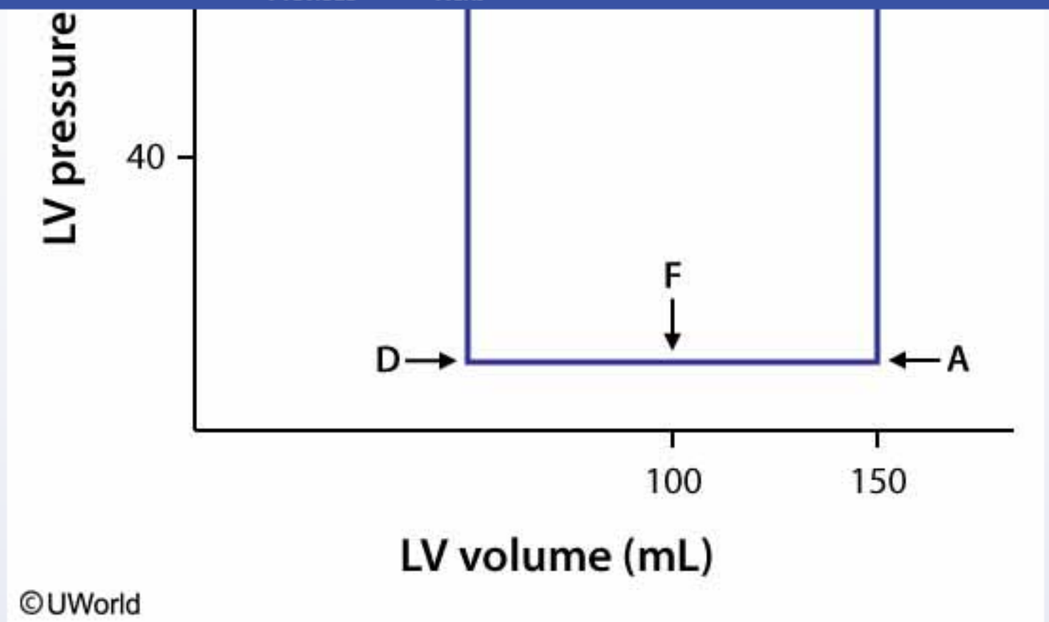

- A. A (7%)
- B. B (5%)
- C. C (9%)
- ✓ D. D (56%)
- E. E (3%)
- F. F (17%)

Omitted
Correct answer

56%
Answered correctly

11 secs
Time Spent

05/01/2020
Last Updated

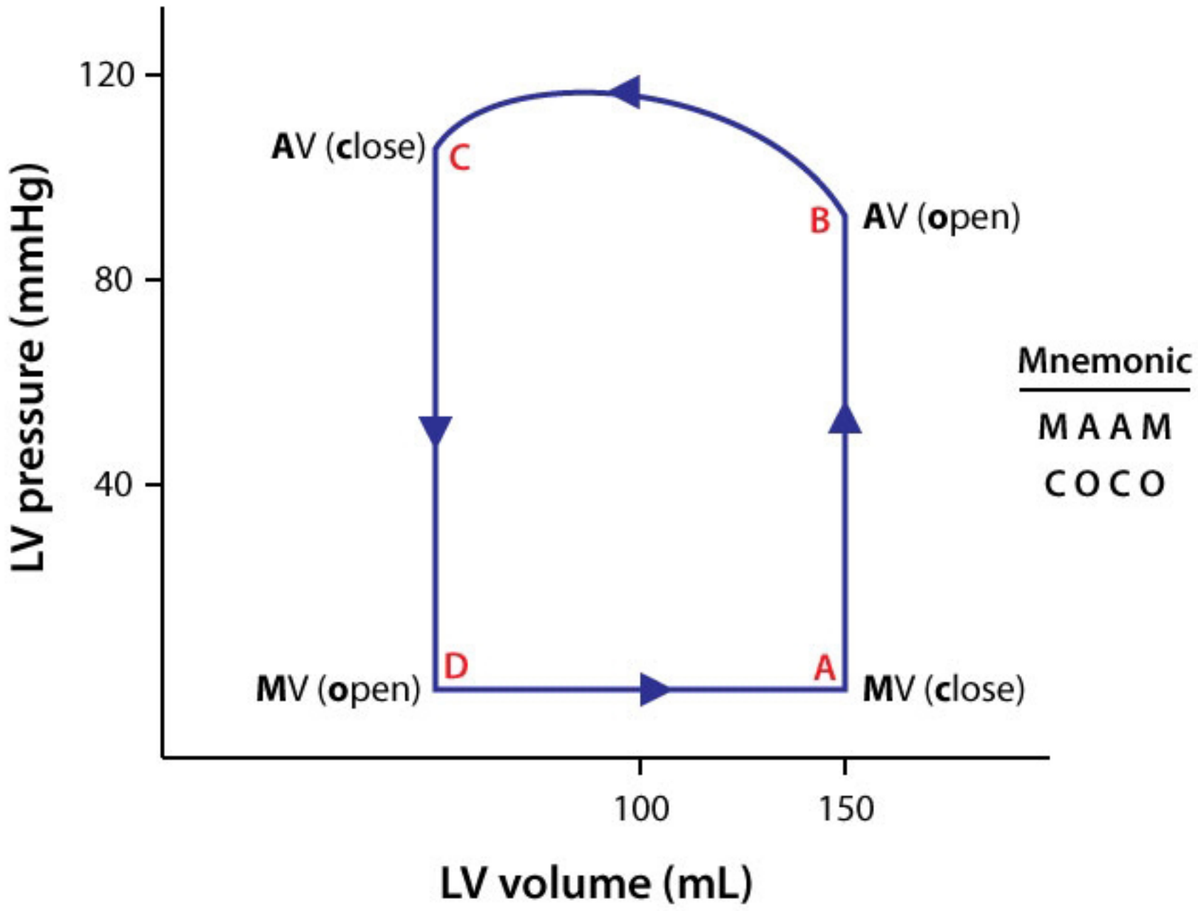

Mnemonic

M A A M
C O C O

A → B = Isovolumetric contraction
B → C = Ventricular ejection
} Ventricular systole

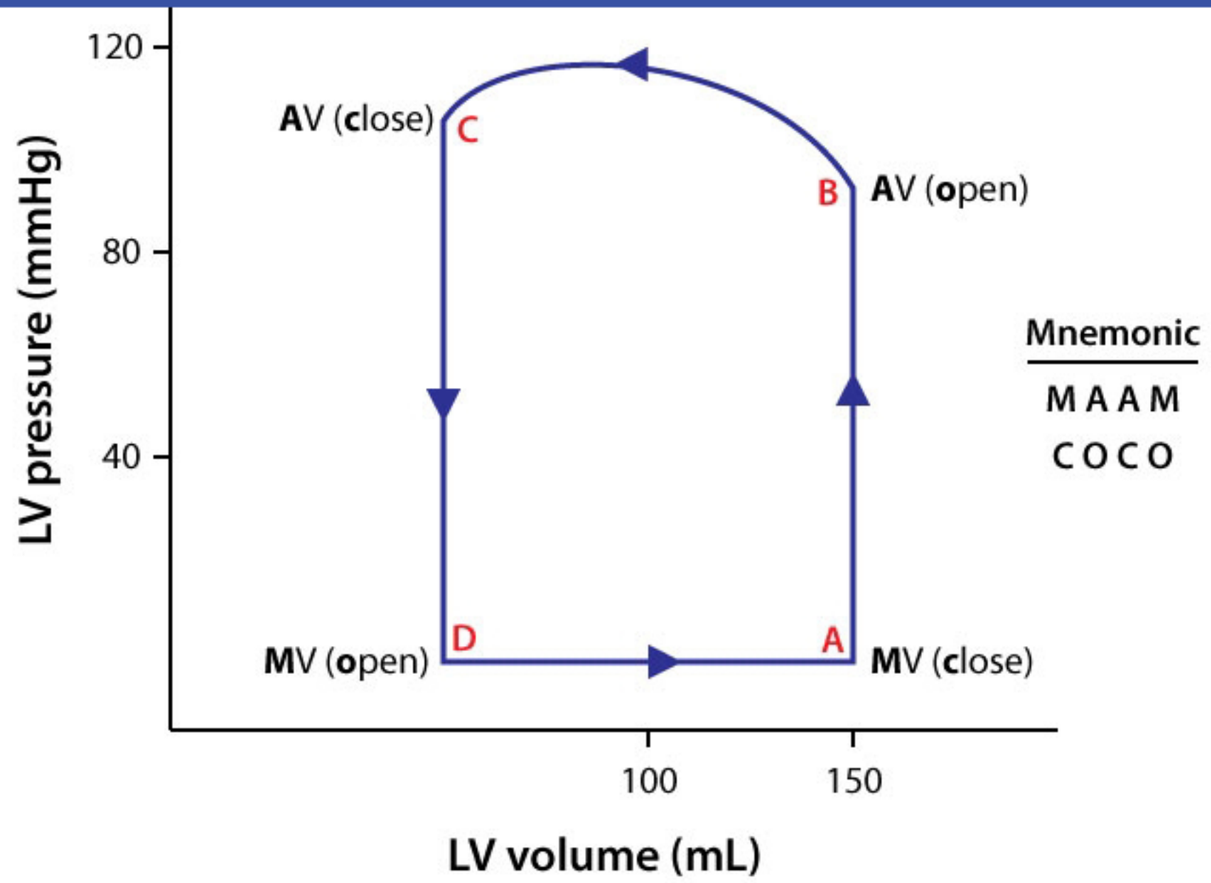

Mnemonic

M A A M
C O C O

A → B = Isovolumetric contraction
B → C = Ventricular ejection
} Ventricular systole

C → D = Isovolumetric relaxation
D → A = Ventricular filling
} Ventricular diastole

Ventricular pressure-volume loops depict the relationship between pressure and volume in the left ventricle during systole and diastole. Left ventricular contraction, ejection, relaxation, and refilling occur as follows:

1. **Isovolumetric contraction:** This phase of the cardiac cycle begins with closure of the mitral valve at point A (S1 sound). During this period, the left ventricle is contracting and intraventricular pressure is increasing, but no blood is leaving the ventricle because both the aortic and mitral valves are closed. The pressure in the left ventricle continues to increase and, at point B, the systemic diastolic blood pressure is reached and the aortic valve opens.
2. **Ventricular ejection:** This phase of the cardiac cycle is represented by the curved line between points B and C. It begins with the opening of the aortic valve at point B and corresponds to the period during which blood is actively squeezed out of the ventricle into the systemic circulation.
3. **Isovolumetric relaxation:** This phase of the cardiac cycle is represented by the line between points C and D. It begins with closure of the aortic valve at point C (S2 sound). The pressure in the ventricle decreases during this time, but no blood enters the ventricle because both the aortic and mitral valves are closed.
4. **Ventricular filling:** This phase is represented by the line between points D and A. It begins with the opening of the mitral valve at point D as ventricular pressure drops below atrial pressure. Blood fills the ventricles during this time.

This patient most likely has mitral stenosis, which often results in an extra heart sound (termed an opening snap) being heard shortly after the S2 heart sound (point C). The opening snap results from the abrupt halting of leaflet motion during mitral valve opening due to fusion of the mitral valve leaflet tips. It occurs just after point D (the atrial/ventricular pressure crossover point) as the mitral valve reaches its maximum opening size. A diastolic rumbling murmur is heard after the opening snap as a result of turbulent blood flow through the stenotic mitral valve during left ventricular filling (point F). Prior rheumatic carditis is the most common cause of mitral stenosis.

(Choice F) The mitral opening snap is heard just after the atrial/ventricular pressure crossover before significant ventricular filling has occurred. Thus, it will be heard much closer to point D than point F, since at point F, the ventricle has already filled to half of its end-diastolic volume.

Educational objective:
The classic cardiac auscultation findings in mitral valve stenosis include an opening snap followed by a diastolic rumbling murmur that is heard best over the apex of the heart. On the ventricular pressure-volume loop, mitral valve opening occurs at the point between isovolumetric relaxation and diastolic filling.

1. **Isovolumetric contraction:** This phase of the cardiac cycle begins with closure of the mitral valve at point A (S1 sound). During this period, the left ventricle is contracting and intraventricular pressure is increasing, but no blood is leaving the ventricle because both the aortic and mitral valves are closed. The pressure in the left ventricle continues to increase and, at point B, the systemic diastolic blood pressure is reached and the aortic valve opens.
2. **Ventricular ejection:** This phase of the cardiac cycle is represented by the curved line between points B and C. It begins with the opening of the aortic valve at point B and corresponds to the period during which blood is actively squeezed out of the ventricle into the systemic circulation.
3. **Isovolumetric relaxation:** This phase of the cardiac cycle is represented by the line between points C and D. It begins with closure of the aortic valve at point C (S2 sound). The pressure in the ventricle decreases during this time, but no blood enters the ventricle because both the aortic and mitral valves are closed.
4. **Ventricular filling:** This phase is represented by the line between points D and A. It begins with the opening of the mitral valve at point D as ventricular pressure drops below atrial pressure. Blood fills the ventricles during this time.

This patient most likely has mitral stenosis, which often results in an extra heart sound (termed an opening snap) being heard shortly after the S2 heart sound (point C). The opening snap results from the abrupt halting of leaflet motion during mitral valve opening due to fusion of the mitral valve leaflet tips. It occurs just after point D (the atrial/ventricular pressure crossover point) as the mitral valve reaches its maximum opening size. A diastolic rumbling murmur is heard after the opening snap as a result of turbulent blood flow through the stenotic mitral valve during left ventricular filling (point F). Prior rheumatic carditis is the most common cause of mitral stenosis.

(Choice F) The mitral opening snap is heard just after the atrial/ventricular pressure crossover before significant ventricular filling has occurred. Thus, it will be heard much closer to point D than point F, since at point F, the ventricle has already filled to half of its end-diastolic volume.

Educational objective:
The classic cardiac auscultation findings in mitral valve stenosis include an opening snap followed by a diastolic rumbling murmur that is heard best over the apex of the heart. On the ventricular pressure-volume loop, mitral valve opening occurs at the point between isovolumetric relaxation and diastolic filling.

Physiology	Cardiovascular System	Mitral stenosis
Subject	System	Topic

4
5
6
7
8
9
10
11
12
13
14
15
16
17
18
19
20
21
22
23
24
25
26
27
28
29
30
31
32
33
34

A 43-year-old man is being evaluated for occasional retrosternal chest pressure that develops with moderate exertion and sometimes occurs when resting. He does not use alcohol, tobacco, or illicit drugs. The patient has an extensive family history of coronary artery disease. His temperature is 36.7 C (98 F), blood pressure is 124/72 mm Hg, pulse is 81/min, and respirations are 14/min. Physical examination shows no abnormalities. Coronary angiography shows mild luminal irregularities but no significant obstructive lesions. Acetylcholine infusion during the procedure results in dilation of epicardial coronary vessels. A reaction involving which of the following amino acids is most likely responsible for the observed dilation?

A. Arginine
B. Aspartate
C. Glutamate
D. Tryptophan
E. Tyrosine

Submit

4
5
6
7
8
9
10
11
12
13
14
15
16
17
18
19
20
21
22
23
24
25
26
27
28
29
30
31
32
33
34

A 43-year-old man is being evaluated for occasional retrosternal chest pressure that develops with moderate exertion and sometimes occurs when resting. He does not use alcohol, tobacco, or illicit drugs. The patient has an extensive family history of coronary artery disease. His temperature is 36.7 C (98 F), blood pressure is 124/72 mm Hg, pulse is 81/min, and respirations are 14/min. Physical examination shows no abnormalities. Coronary angiography shows mild luminal irregularities but no significant obstructive lesions. Acetylcholine infusion during the procedure results in dilation of epicardial coronary vessels. A reaction involving which of the following amino acids is most likely responsible for the observed dilation?

- ✓ A. Arginine (55%)
- B. Aspartate (4%)
- C. Glutamate (17%)
- D. Tryptophan (7%)
- E. Tyrosine (15%)

Omitted
Correct answer
A

55%
Answered correctly

02 secs
Time Spent

03/10/2020
Last Updated

Explanation

Endothelium-dependent vasodilation

4
5
6
7
8
9
10
11
12
13
14
15
16
17
18
19
20
21
22
23
24
25
26
27
28
29
30
31
32
33
34

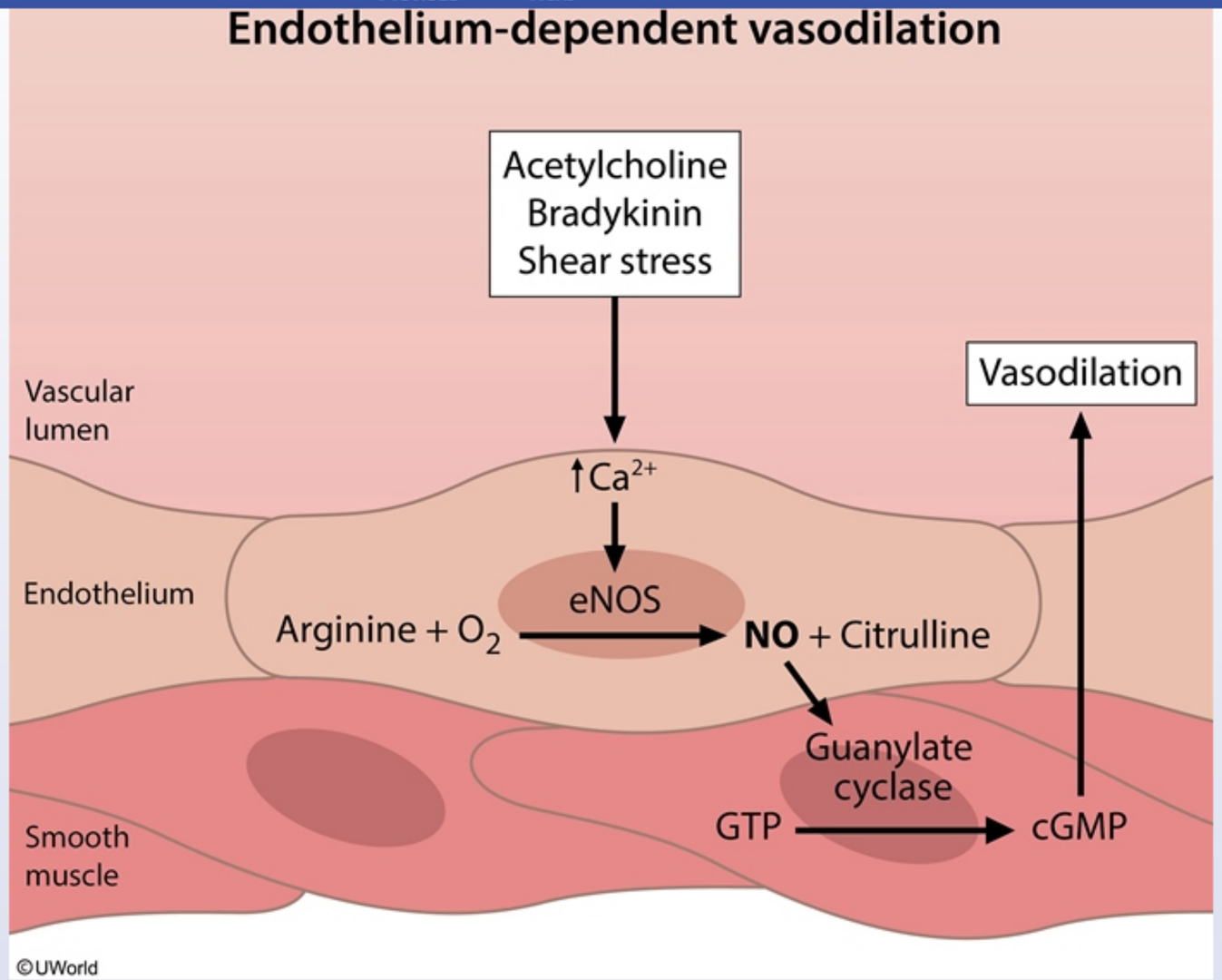

The **vascular endothelium** plays an important role in vasodilation mediated by acetylcholine, bradykinin, serotonin, substance P, and shear forces. These stimuli activate specific membrane receptors present on endothelial cells, leading to an increase in cytosolic calcium levels. This causes activation of **endothelial nitric oxide synthase** (eNOS), which synthesizes **nitric oxide** from arginine, NADPH, and O_2. Nitric oxide then

4
5
6
7
8
9
10
11
12
13
14
15
16
17
18
19
20
21
22
23
24
25
26
27
28
29
30
31
32
33
34

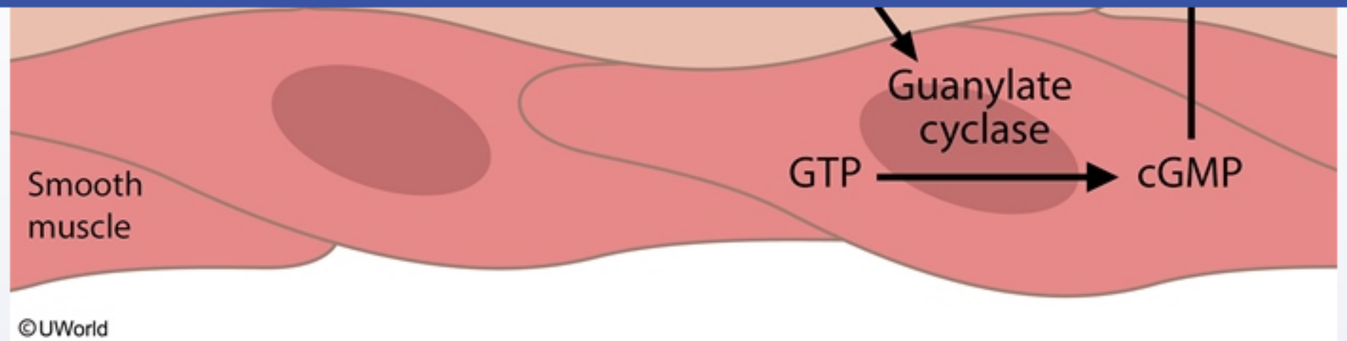

The **vascular endothelium** plays an important role in vasodilation mediated by acetylcholine, bradykinin, serotonin, substance P, and shear forces. These stimuli activate specific membrane receptors present on endothelial cells, leading to an increase in cytosolic calcium levels. This causes activation of **endothelial nitric oxide synthase** (eNOS), which synthesizes **nitric oxide** from arginine, NADPH, and O_2. Nitric oxide then diffuses into the adjacent smooth muscle cells, where it activates guanylyl cyclase and increases formation of **cyclic GMP**. High levels of cyclic GMP activate protein kinase G, which causes a reduction in cytosolic calcium levels and **relaxation** of vascular smooth muscle cells.

The availability of arginine for synthesizing nitric oxide depends on several factors, including exogenous food intake, endogenous synthesis, intracellular storage and degradation, and the presence of asymmetrical dimethylarginine (an endogenous analog of arginine that works as a competitive inhibitor of eNOS).

Educational objective:

Nitric oxide is synthesized from arginine by nitric oxide synthase. As a precursor of nitric oxide, arginine supplementation may play an adjunct role in the treatment of conditions that improve with vasodilation, such as stable angina.

References

- Randomized trial of a medical food for the dietary management of chronic, stable angina.

Physiology	Cardiovascular System	Nitric oxide
Subject	System	Topic

Copyright © UWorld. All rights reserved.

4
5
6
7
8
9
10
11
12
13
14
15
16
17
18
19
20
21
22
23
24
25
26
27
28
29
30
31
32
33
34

Exhibit Display

Important amino acid derivatives

Precursor amino acids	Substance
Arginine	• Nitric oxide
Arginine + Aspartate	• Urea
Glycine + Succinyl CoA	• Heme
Glycine + Arginine + SAM	• Creatine
Glutamate	• GABA • Glutathione
Glutamine + Aspartate	• Pyrimidines
Glutamine + Aspartate + Glycine	• Purines
Histidine	• Histamine
Tyrosine	• Dopamine • Epinephrine • Norepinephrine • Thyroxine • Melanin
Tryptophan	• Serotonin • Melatonin • Niacin

©UWorld

Zoom In | Zoom Out | Reset | Add To New Card | Existing Card

4
5
6
7
8
9
10
11
12
13
14
15
16
17
18
19
20
21
22
23
24
25
26
27
28
29
30
31
32
33
34

A 24-year-old primigravid woman at 36 weeks gestation comes to the physician complaining of lightheadedness and nausea at bedtime. Her pregnancy has been uncomplicated and her past medical history is unremarkable. She takes one multivitamin and one iron tablet daily. Her blood pressure is 115/75 mm Hg when sitting, 110/70 mm Hg when standing, and 80/60 mm Hg when supine. Physical examination shows a uterus consistent in size with 36 weeks gestation. Which of the following is the most likely explanation for this patient's hypotension while supine?

A. Autonomic neuropathy

B. Decreased venous return

C. Reduced peripheral arterial resistance

D. Volume depletion

E. Withdrawal of sympathetic activity

Submit

4
5
6
7
8
9
10
11
12
13
14
15
16
17
18
19
20
21
22
23
24
25
26
27
28
29
30
31
32
33
34

A 24-year-old primigravid woman at 36 weeks gestation comes to the physician complaining of lightheadedness and nausea at bedtime. Her pregnancy has been uncomplicated and her past medical history is unremarkable. She takes one multivitamin and one iron tablet daily. Her blood pressure is 115/75 mm Hg when sitting, 110/70 mm Hg when standing, and 80/60 mm Hg when supine. Physical examination shows a uterus consistent in size with 36 weeks gestation. Which of the following is the most likely explanation for this patient's hypotension while supine?

A. Autonomic neuropathy (1%)
✓ B. Decreased venous return (75%)
C. Reduced peripheral arterial resistance (12%)
D. Volume depletion (2%)
E. Withdrawal of sympathetic activity (8%)

Omitted
Correct answer
B

75%
Answered correctly

02 secs
Time Spent

05/24/2020
Last Updated

Explanation

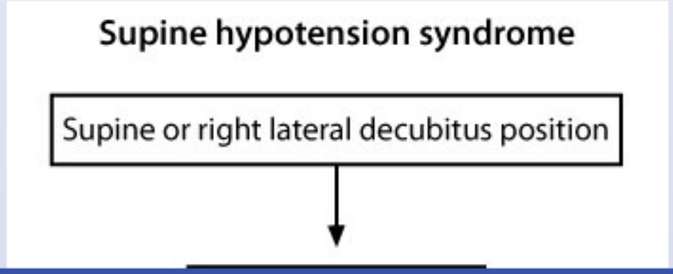

4
5
6
7
8
9
10
11
12
13
14
15
16
17
18
19
20
21
22
23
24
25
26
27
28
29
30
31
32
33
34

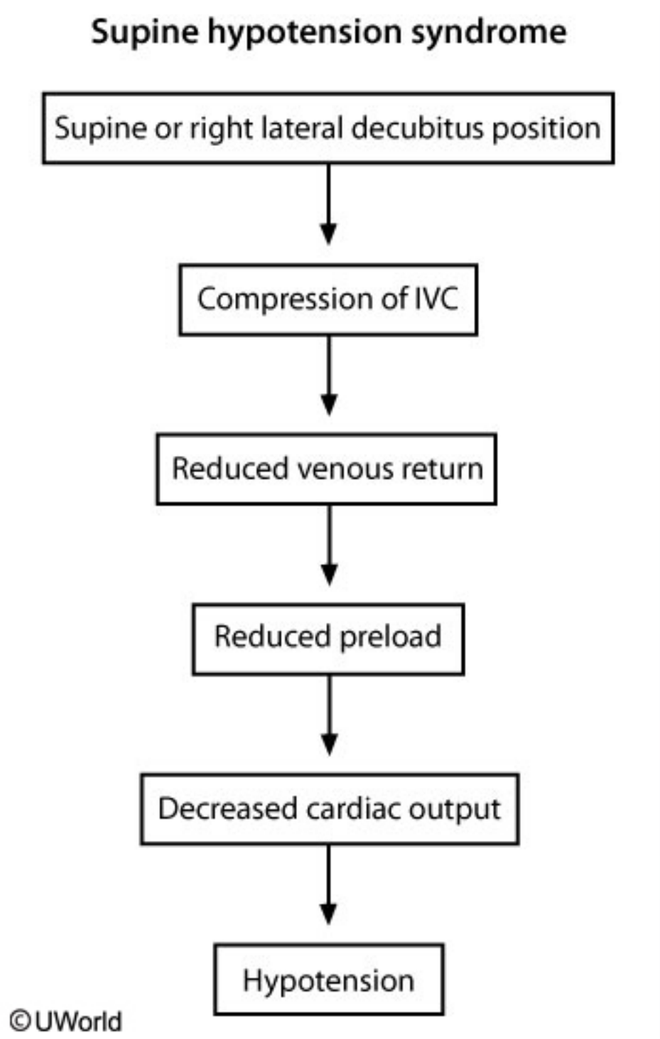

Supine hypotension syndrome (or aortocaval compression syndrome) is characterized by hypotension, pallor, sweating, nausea, and dizziness that occur when a pregnant woman lies supine (on her back). Symptoms resolve with sitting, standing up, or when assuming a left lateral

©UWorld

Supine hypotension syndrome (or aortocaval compression syndrome) is characterized by hypotension, pallor, sweating, nausea, and dizziness that occur when a pregnant woman lies supine (on her back). Symptoms resolve with sitting, standing up, or when assuming a left lateral decubitus position. It occurs predominantly in women > 20 weeks gestation, and is due to the gravid uterus compressing and obstructing the inferior vena cava. This reduces the venous return (preload), which subsequently lowers the cardiac output leading to hypotension. In severe cases, it can result in loss of consciousness and even fetal demise.

(Choice A) Peripheral neuropathies that affect postganglionic autonomic nerves can result in orthostatic hypotension. Diabetes mellitus is the most common cause of autonomic neuropathy in developed countries.

(Choice C) The blood pressure falls early in gestation, secondary to a reduction in systemic vascular resistance. However, this would not result in isolated supine hypotension.

(Choice D) During pregnancy, there is expansion of the plasma volume and an increase in red blood cell mass. In addition, volume depletion is more likely to cause orthostatic hypotension than supine hypotension.

(Choice E) Vasovagal syncope occurs due to concomitant withdrawal of sympathetic efferent activity and enhanced parasympathetic (vagal) activity, which results in bradycardia, vasodilation, and orthostatic hypotension.

Educational objective:
Pregnant women > 20 weeks gestation can experience compression of the inferior cava by the gravid uterus while in the supine position. This reduces venous return and cardiac output, which can result in hypotension and syncope.

References

- Supine hypotensive syndrome.

Physiology	Cardiovascular System	Supine hypotension
Subject	System	Topic

Copyright © UWorld. All rights reserved.

4
5
6
7
8
9
10
11
12
13
14
15
16
17
18
19
20
21
22
23
24
25
26
27
28
29
30
31
32
33
34

Electrophysiologists conduct a study in which they record the membrane potential changes of cardiac cells while exposing them to various agents. A tracing from one of the experiments is shown below.

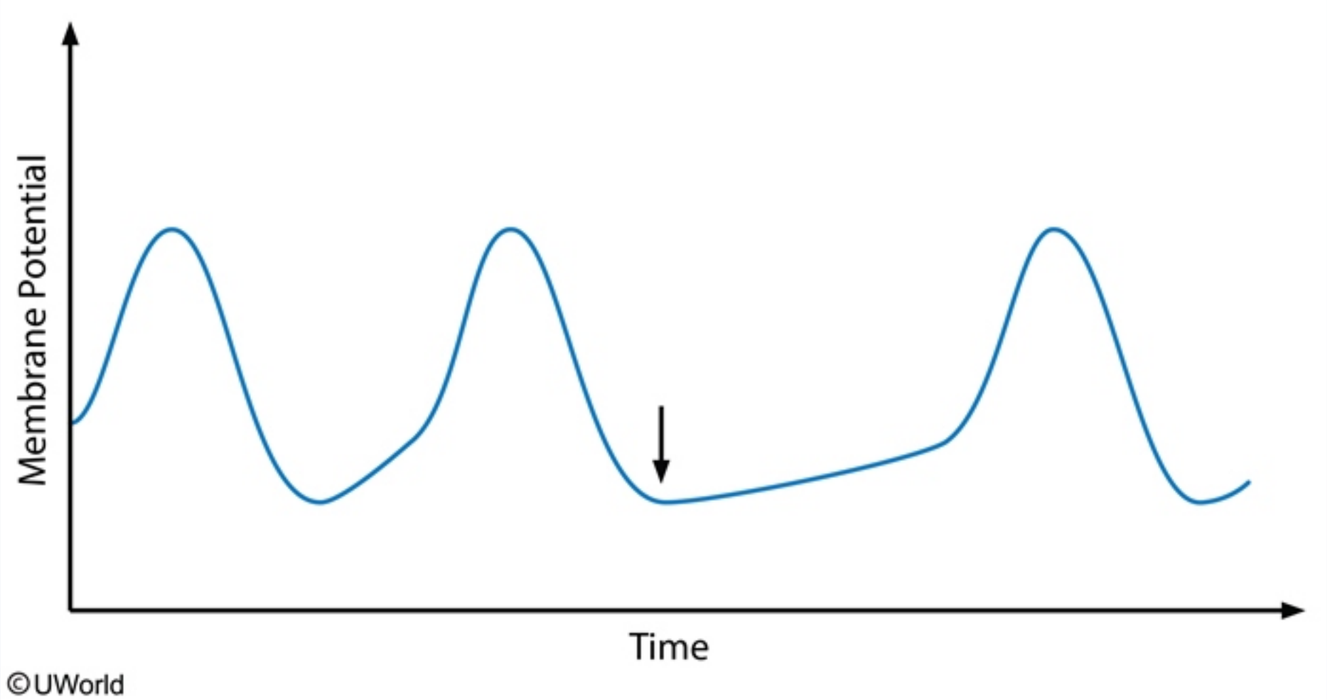

Which of the following substances was most likely applied to the cells at the point indicated by the arrow?

- A. Adenosine
- B. Aldosterone
- C. Angiotensin II
- D. Glucagon

4
5
6
7
8
9
10
11
12
13
14
15
16
17
18
19
20
21
22
23
24
25
26
27
28
29
30
31
32
33
34

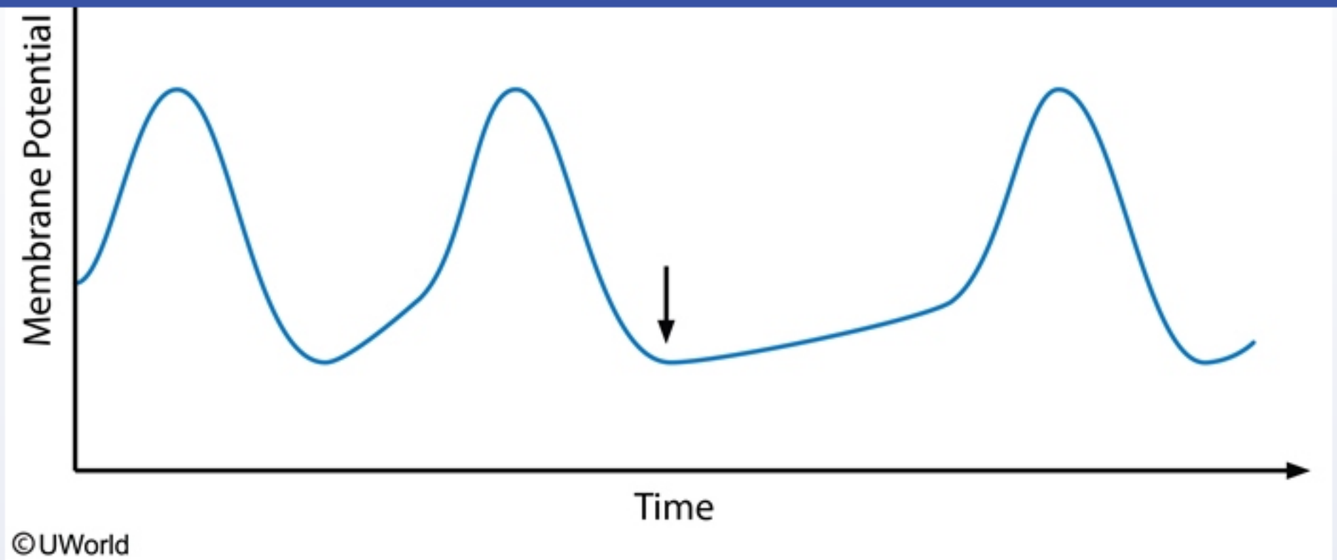

Which of the following substances was most likely applied to the cells at the point indicated by the arrow?

- ✓ A. Adenosine (82%)
- B. Aldosterone (3%)
- C. Angiotensin II (1%)
- D. Glucagon (3%)
- E. Glycine (6%)
- F. Norepinephrine (3%)

Omitted
Correct answer

82%
Answered correctly

04 secs
Time Spent

03/01/2020
Last Updated

4
5
6
7
8
9
10
11
12
13
14
15
16
17
18
19
20
21
22
23
24
25
26
27
28
29
30
31
32
33
34

SA node action potential

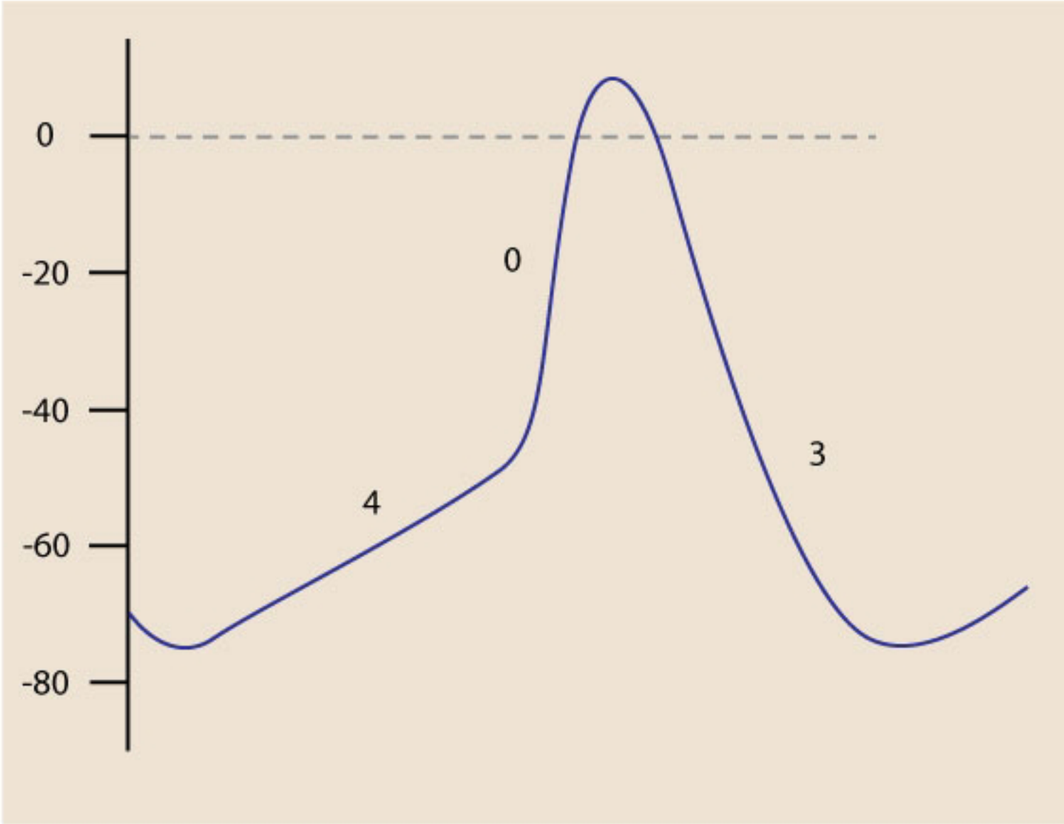

Ventricular muscle action potential

4
5
6
7
8
9
10
11
12
13
14
15
16
17
18
19
20
21
22
23
24
25
26
27
28
29
30
31
32
33
34

Ventricular muscle action potential

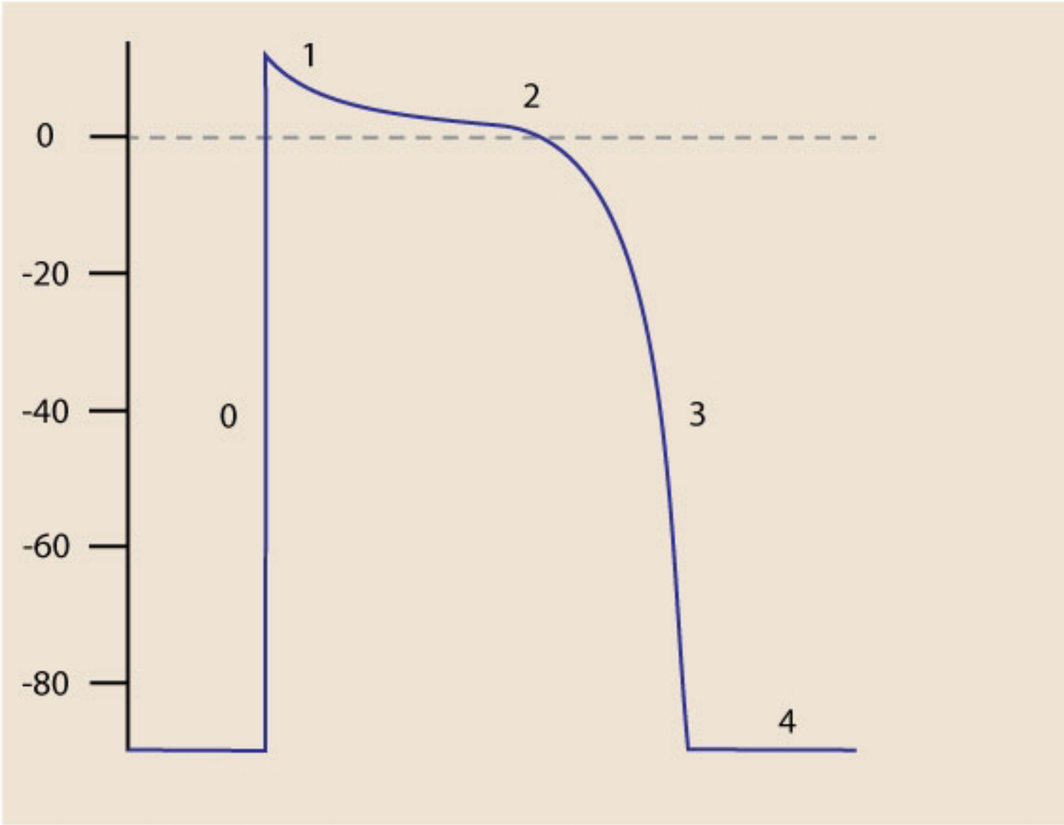

©UWorld

The membrane potential changes shown above are typical of **cardiac pacemaker cells**, which are primarily located in the sinoatrial node on the wall of the right atrium. These specialized cells demonstrate slow spontaneous depolarization at regular intervals (**automaticity**) and have an action potential that differs from that of cardiomyocytes. The action potential of pacemaker cells proceeds as follows:

1. **Phase 0 (upstroke)** begins once the cell crosses the depolarization threshold (about -40 mV). It is characterized by the opening of voltage-gated L-type (long-lasting) Ca^{2+} channels with a large influx of Ca^{2+} into the cell.

©UWorld

The membrane potential changes shown above are typical of **cardiac pacemaker cells**, which are primarily located in the sinoatrial node on the wall of the right atrium. These specialized cells demonstrate slow spontaneous depolarization at regular intervals (**automaticity**) and have an action potential that differs from that of cardiomyocytes. The action potential of pacemaker cells proceeds as follows:

1. **Phase 0 (upstroke)** begins once the cell crosses the depolarization threshold (about -40 mV). It is characterized by the opening of voltage-gated L-type (long-lasting) Ca^{2+} channels with a large influx of Ca^{2+} into the cell.
2. **Phase 3 (repolarization)** begins with closure of L-type Ca^{2+} channels in conjunction with the opening of K^+ channels and the efflux of K^+ ions from the cell.
3. **Phase 4 (pacemaker potential)** is characterized by the slow influx of Na^+ that begins at the end of repolarization. During this time, there is also a slow decrease in K^+ efflux as the K^+ channels continue to close. Once the membrane potential reaches approximately -50 mV, the T-type (transient) Ca^{2+} channels open and allow Ca^{2+} to enter the cell and contribute to depolarization. As the action potential approaches -40 mV, the L-type (long-lasting) Ca^{2+} channels open and trigger an action potential.

Adenosine and acetylcholine affect phase 4 of the action potential, reducing the rate of spontaneous depolarization in cardiac pacemaker cells. Adenosine interacts with A1 receptors on the surface of cardiac cells, activating potassium channels and **increasing potassium conductance**, causing the membrane potential to remain negative for a longer period. Adenosine also inhibits L-type Ca^{2+} channels, further prolonging the depolarization time. These actions result in a transient **slowing of the sinus rate** and an increase in **atrioventricular (AV) nodal conduction delay**. Adenosine is useful in the termination of paroxysmal supraventricular tachycardia. Acetylcholine behaves similarly by increasing outward K^+ conductance while decreasing inward Ca^{2+} and Na^+ currents during phase 4.

(Choices B and C) Angiotensin II is a potent vasoconstrictor that increases both systolic and diastolic blood pressure. Aldosterone acts on collecting duct epithelium in the kidneys; this increases Na^+ reabsorption and urinary excretion of K^+ and H^+. However, neither process directly affects phase 4 of pacemaker action potential.

(Choices D and E) Glycine is an inhibitory neurotransmitter, and glucagon is a pancreatic hormone that increases blood sugar levels. Neither affects phase 4 of pacemaker action potential.

(Choice F) Norepinephrine facilitates opening of L-type Ca^{2+} channels and Na^+ channels in phase 4 of the nodal action potential. This leads to

mV, the L-type (long-lasting) Ca^{2+} channels open and trigger an action potential.

Adenosine and acetylcholine affect phase 4 of the action potential, reducing the rate of spontaneous depolarization in cardiac pacemaker cells. Adenosine interacts with A1 receptors on the surface of cardiac cells, activating potassium channels and **increasing potassium conductance**, causing the membrane potential to remain negative for a longer period. Adenosine also inhibits L-type Ca^{2+} channels, further prolonging the depolarization time. These actions result in a transient **slowing of the sinus rate** and an increase in **atrioventricular (AV) nodal conduction delay**. Adenosine is useful in the termination of paroxysmal supraventricular tachycardia. Acetylcholine behaves similarly by increasing outward K^+ conductance while decreasing inward Ca^{2+} and Na^+ currents during phase 4.

(Choices B and C) Angiotensin II is a potent vasoconstrictor that increases both systolic and diastolic blood pressure. Aldosterone acts on collecting duct epithelium in the kidneys; this increases Na^+ reabsorption and urinary excretion of K^+ and H^+. However, neither process directly affects phase 4 of pacemaker action potential.

(Choices D and E) Glycine is an inhibitory neurotransmitter, and glucagon is a pancreatic hormone that increases blood sugar levels. Neither affects phase 4 of pacemaker action potential.

(Choice F) Norepinephrine facilitates opening of L-type Ca^{2+} channels and Na^+ channels in phase 4 of the nodal action potential. This leads to more rapid depolarization.

Educational objective:
The phase 4 slow depolarization in cardiac pacemaker cells occurs due to the closure of repolarizing K^+ channels, the slow influx of Na^+ through funny channels, and the opening of T-type Ca^{2+} channels. Acetylcholine and adenosine reduce the rate of spontaneous depolarization in cardiac pacemaker cells by prolonging phase 4.

References

- Sophisticated architecture is required for the sinoatrial node to perform its normal pacemaker function.

Physiology	Cardiovascular System	Cardiac physiology
Subject	System	Topic

Copyright © UWorld. All rights reserved.

4
5
6
7
8
9
10
11
12
13
14
15
16
17
18
19
20
21
22
23
24
25
26
27
28
29
30
31
32
33
34

A 48-year-old man with diet-controlled type 2 diabetes mellitus is being evaluated for occasional retrosternal chest pain. He has no history of hypertension, and his blood pressure measurements during office visits were always within normal limits. There is no family history of cardiovascular disease. The patient undergoes exercise treadmill stress testing. He walks for 7 minutes on the treadmill and stops due to fatigue but does not experience chest pain. His ECG does not show any abnormal changes. Heart rate ranges from 70/min at rest to 132/min at peak and mean blood pressure ranges from 95 mm Hg at rest to 112 mm Hg at peak. Which of the following parameters was most likely decreased during peak stress compared to the resting state in this patient?

A. Cardiac output

B. Left ventricular end-diastolic pressure

C. Pulmonary artery systolic pressure

D. Systemic systolic blood pressure

E. Total systemic vascular resistance

Submit

4
5
6
7
8
9
10
11
12
13
14
15
16
17
18
19
20
21
22
23
24
25
26
27
28
29
30
31
32
33
34

A 48-year-old man with diet-controlled type 2 diabetes mellitus is being evaluated for occasional retrosternal chest pain. He has no history of hypertension, and his blood pressure measurements during office visits were always within normal limits. There is no family history of cardiovascular disease. The patient undergoes exercise treadmill stress testing. He walks for 7 minutes on the treadmill and stops due to fatigue but does not experience chest pain. His ECG does not show any abnormal changes. Heart rate ranges from 70/min at rest to 132/min at peak and mean blood pressure ranges from 95 mm Hg at rest to 112 mm Hg at peak. Which of the following parameters was most likely decreased during peak stress compared to the resting state in this patient?

A. Cardiac output (8%)

B. Left ventricular end-diastolic pressure (28%)

C. Pulmonary artery systolic pressure (8%)

D. Systemic systolic blood pressure (1%)

✓ E. Total systemic vascular resistance (51%)

Omitted
Correct answer
E

51%
Answered correctly

02 secs
Time Spent

02/23/2020
Last Updated

Explanation

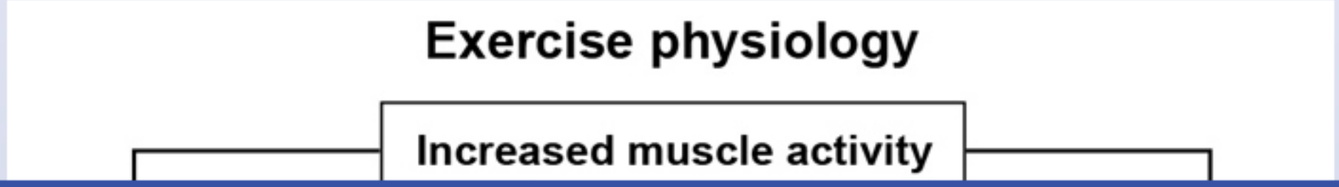

4
5
6
7
8
9
10
11
12
13
14
15
16
17
18
19
20
21
22
23
24
25
26
27
28
29
30
31
32
33
34

Exercise physiology

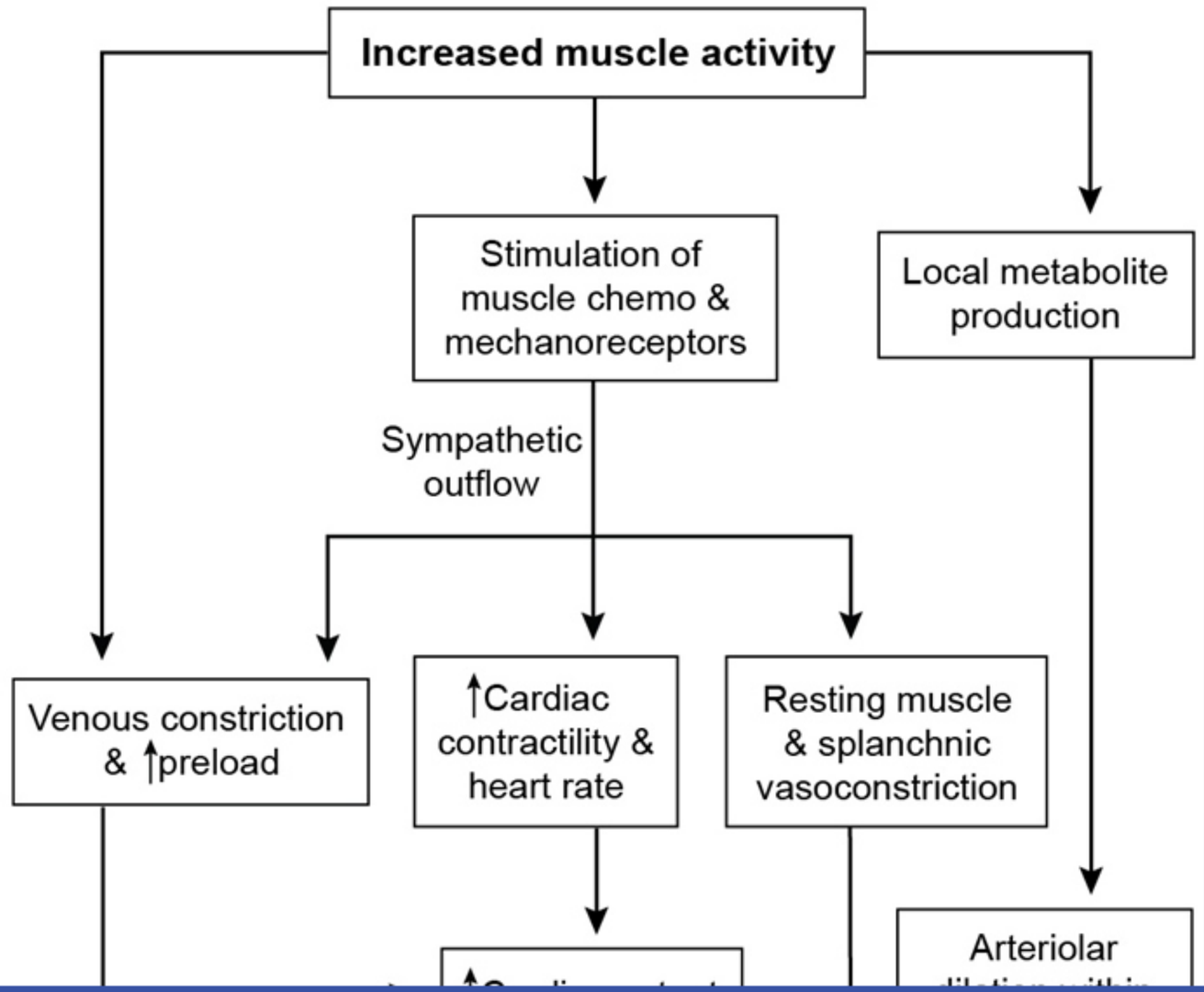

4
5
6
7
8
9
10
11
12
13
14
15
16
17
18
19
20
21
22
23
24
25
26
27
28
29
30
31
32
33
34

Exhibit Display

Exercise physiology

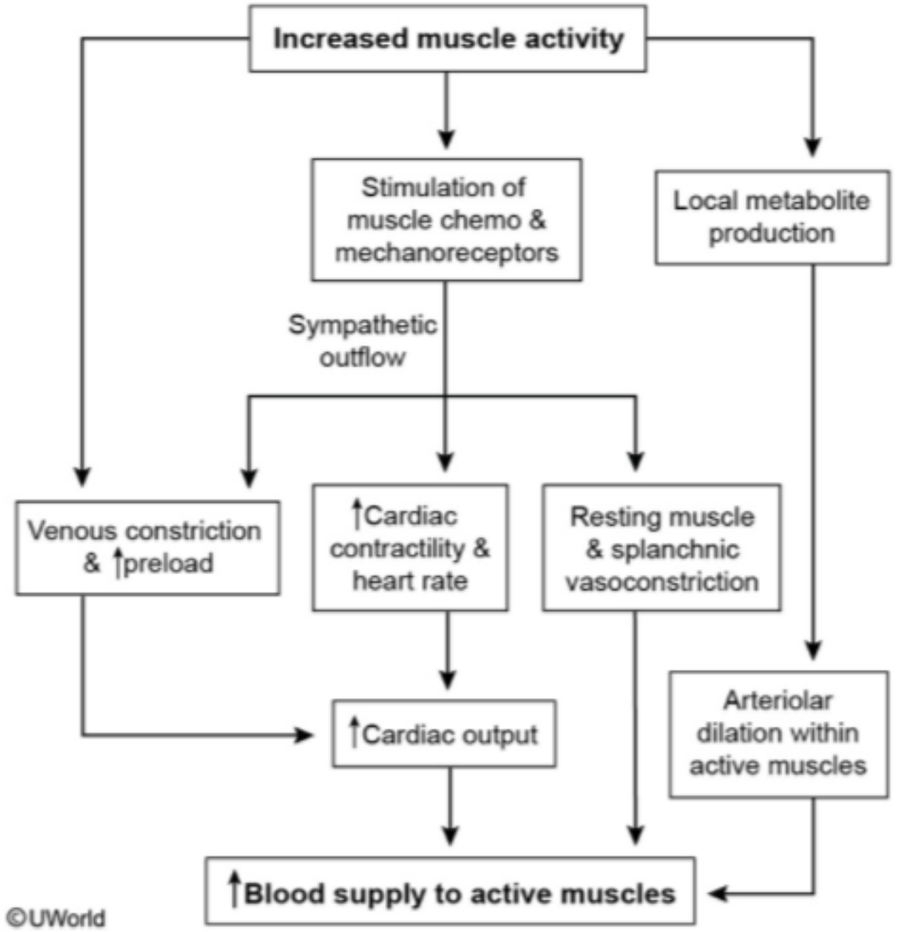

Zoom In | Zoom Out | Reset | Add To New Card | Existing Card

4
5
6
7
8
9
10
11
12
13
14
15
16
17
18
19
20
21
22
23
24
25
26
27
28
29
30
31
32
33
34

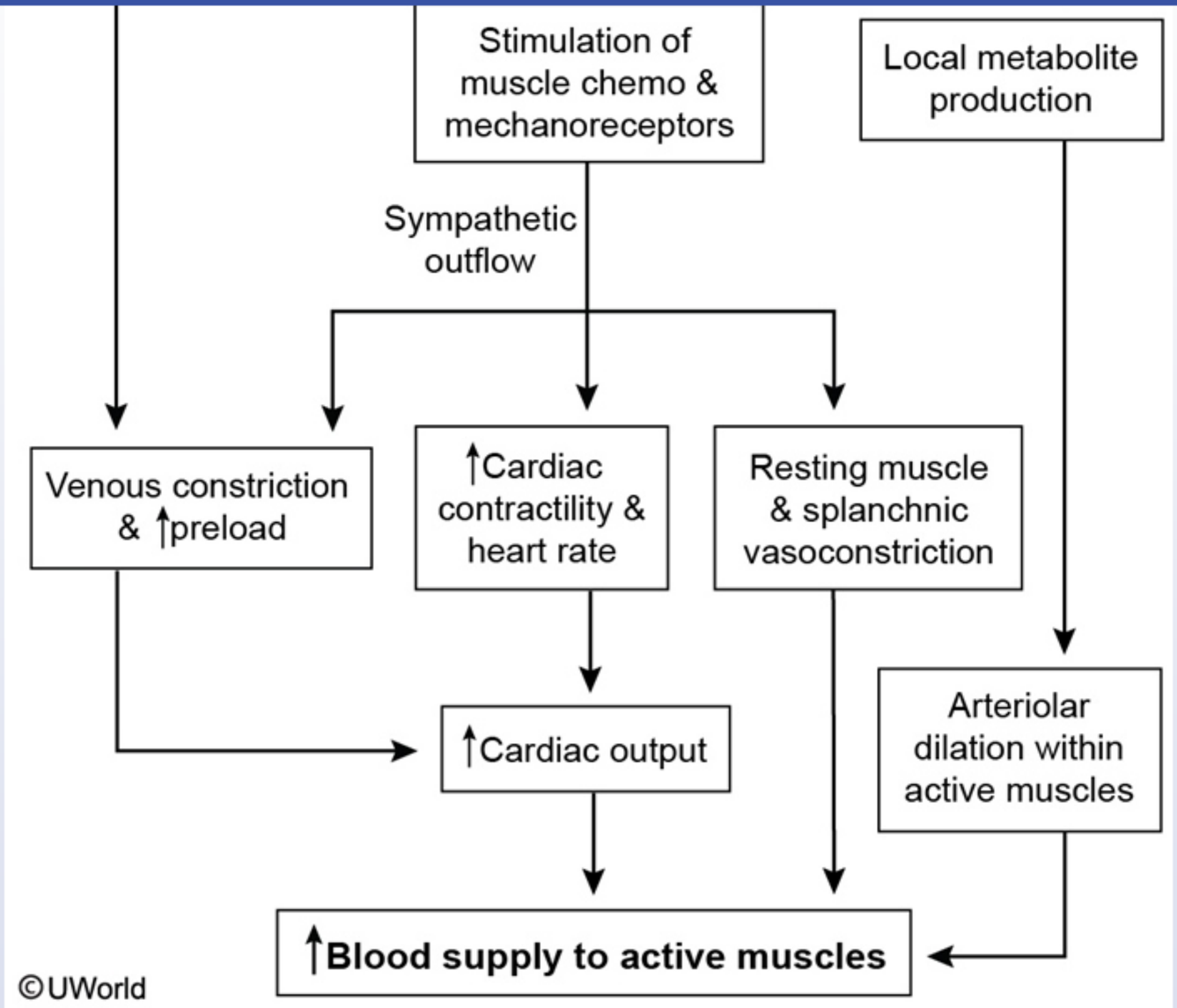

Exercise is associated with several hemodynamic and vasoregulatory adjustments to provide maximal blood flow to the active muscles.

4
5
6
7
8
9
10
11
12
13
14
15
16
17
18
19
20
21
22
23
24
25
26
27
28
29
30
31
32
33
34

Exercise is associated with several hemodynamic and vasoregulatory adjustments to provide maximal blood flow to the active muscles. Stimulation of mechano- and chemoreceptors in the exercising muscle causes sympathetic activation and withdrawal of vagal tone, resulting in increased heart rate (HR), stroke volume, and overall cardiac output **(Choice A)**. At higher levels of exercise, HR is predominantly responsible for most of the increase in CO.

Sympathetic discharge causes contraction of the arterioles in all tissues except the actively working muscles, effectively shunting blood toward the exercising muscle. This also results in an increase in systolic blood pressure, which helps improve perfusion of actively contracting skeletal muscle **(Choice D)**. However, the rise in the mean arterial pressure is much lower due to an **overall decrease in systemic vascular resistance**. This occurs due to the substantial arteriolar vasodilation in active skeletal muscles, which is mediated by local release of adenosine, potassium ions, ATP, CO_2, and lactate.

(Choice B) Left ventricular (LV) end-diastolic volume and pressure both rise during exercise due to an increase in LV filling (increased venous return) by peripheral vasoconstriction and the pumping actions of actively contracting muscles.

(Choice C) Pulmonary artery systolic pressure typically rises during exercise; however, similar to systemic circulation, the rise in pulmonary pressure is much smaller than the increase in blood flow across the pulmonary circulation due to a fall in pulmonary vascular resistance.

Educational objective:
Exercising muscles can receive up to 85% of the total cardiac output during periods of strenuous activity. Although sympathetic discharge during exercise causes increased cardiac output and splanchnic vasoconstriction, there is only a modest increase in mean blood pressure as vasodilation within active skeletal muscles significantly decreases the total systemic vascular resistance.

References

- Reflex control of the circulation during exercise: chemoreflexes and mechanoreflexes.
- Hemodynamic and neurohumoral responses to dynamic exercise: normal subjects versus patients with heart disease.

Physiology	Cardiovascular System	Physical exercise
Subject	System	Topic

Copyright © UWorld. All rights reserved.

4
5
6
7
8
9
10
11
12
13
14
15
16
17
18
19
20
21
22
23
24
25
26
27
28
29
30
31
32
33
34

A 44-year-old previously healthy woman comes to the emergency department due to a 2-day history of left flank pain, dysuria, fever, and chills. Temperature is 38.9 C (102 F), blood pressure is 80/40 mm Hg, and pulse is 140/min and regular. Physical examination shows left costovertebral angle tenderness. Laboratory studies reveal leukocytosis, pyuria, and bacteriuria. Empiric broad-spectrum antibiotics and intravenous fluids are administered. The patient remains persistently hypotensive, and an intravenous phenylephrine infusion is begun. Several minutes later, her heart rate decreases to 100/min. Compared to just prior to the infusion, which of the following intracellular changes are expected in this patient?

	Cyclic AMP level in ventricular myocytes	Inositol trisphosphate level in vascular smooth muscle	Inward calcium current in sinoatrial nodal cells
A.	Decreased	Increased	Decreased
B.	Decreased	Decreased	No change
C.	Increased	Increased	Increased
D.	Increased	No change	Increased
E.	No change	Decreased	Decreased

Submit

4
5
6
7
8
9
10
11
12
13
14
15
16
17
18
19
20
21
22
23
24
25
26
27
28
29
30
31
32
33
34

A 44-year-old previously healthy woman comes to the emergency department due to a 2-day history of left flank pain, dysuria, fever, and chills. Temperature is 38.9 C (102 F), blood pressure is 80/40 mm Hg, and pulse is 140/min and regular. Physical examination shows left costovertebral angle tenderness. Laboratory studies reveal leukocytosis, pyuria, and bacteriuria. Empiric broad-spectrum antibiotics and intravenous fluids are administered. The patient remains persistently hypotensive, and an intravenous phenylephrine infusion is begun. Several minutes later, her heart rate decreases to 100/min. Compared to just prior to the infusion, which of the following intracellular changes are expected in this patient?

	Cyclic AMP level in ventricular myocytes	Inositol trisphosphate level in vascular smooth muscle	Inward calcium current in sinoatrial nodal cells
✓ A. (59%)	Decreased	Increased	Decreased
B. (5%)	Decreased	Decreased	No change
C. (18%)	Increased	Increased	Increased
D. (8%)	Increased	No change	Increased
E. (8%)	No change	Decreased	Decreased

Omitted
Correct answer
A

59%
Answered correctly

02 secs
Time Spent

05/07/2020
Last Updated

Receptor stimulated	Change in second messenger	Primary effects
Alpha-1	↑ IP_3	• Peripheral vasoconstriction • Urethral constriction • Pupillary dilation
Alpha-2	↓ cAMP	• CNS sympatholytic • ↓ insulin release & intestinal motility
Beta-1	↑ cAMP	• ↑ Cardiac contractility & heart rate • ↑ Renin release by JG cells of kidney
Beta-2	↑ cAMP	• Peripheral vasodilation • Bronchodilation
Muscarinic-2	↓ cAMP	• ↓ Cardiac contractility & heart rate
Muscarinic-3	↑ IP_3	• Bronchoconstriction • ↑ insulin release & intestinal motility • Bladder contraction • Pupillary constriction • Peripheral vasodilation*

*Via release of nitric oxide.

cAMP = cyclic AMP; **IP_3** = inositol 1,4,5-triphosphate; **JG** = juxtaglomerular.

Phenylephrine is a selective alpha-1 adrenergic receptor agonist that causes vasoconstriction and increased blood pressure by **increasing inositol triphosphate** (IP_3) levels in **vascular smooth muscle cells**. The abrupt increase in blood pressure triggers a **baroreceptor reflex**, resulting in increased parasympathetic and decreased sympathetic outflow to the heart and vasculature.

The baroreceptor reflex–driven changes in the **heart** are mediated by **beta-1 adrenergic receptors** and **muscarinic-2 receptors**. Both reduced sympathetic stimulation of beta-1 receptors and increased parasympathetic stimulation of muscarinic-2 receptors trigger a **decrease in cyclic**

		• Pupillary constriction • Peripheral vasodilation*

*Via release of nitric oxide.

cAMP = cyclic AMP; **IP_3** = inositol 1,4,5-triphosphate; **JG** = juxtaglomerular.

Phenylephrine is a selective alpha-1 adrenergic receptor agonist that causes vasoconstriction and increased blood pressure by **increasing inositol triphosphate** (IP_3) levels in **vascular smooth muscle cells**. The abrupt increase in blood pressure triggers a **baroreceptor reflex**, resulting in increased parasympathetic and decreased sympathetic outflow to the heart and vasculature.

The baroreceptor reflex–driven changes in the **heart** are mediated by **beta-1 adrenergic receptors** and **muscarinic-2 receptors**. Both reduced sympathetic stimulation of beta-1 receptors and increased parasympathetic stimulation of muscarinic-2 receptors trigger a **decrease in cyclic AMP** (cAMP) levels, which leads to a decrease in heart rate and contractility to reduce cardiac output and lessen the increase in blood pressure. The reduction in heart rate is driven in part by **decreased inward calcium current** during phases 4 and 0 of the sinoatrial node action potential.

The above baroreceptor response also affects vascular smooth muscle, which is mostly under sympathetic control. Although this response causes reduced sympathetic stimulation of vascular alpha-1 receptors, the infusion of phenylephrine still maintains IP_3 activity above baseline, resulting in a persistent vasoconstrictive effect.

In contrast, an abrupt decrease in blood pressure triggers the opposite regulatory response via the baroreceptor reflex.

Educational objective:
Phenylephrine increases blood pressure via an alpha-1 receptor-mediated increase in inositol triphosphate in vascular smooth muscle cells. The abrupt increase in blood pressure triggers a reflexive increase in parasympathetic activity while decreasing sympathetic outflow. This leads to decreased cyclic AMP activity in the heart (mediated by beta-1 adrenergic and muscarinic-2 receptors), which decreases heart rate and myocardial contractility. The reduction in heart rate is driven in part by decreased inward calcium current in sinoatrial cells.

Physiology	Cardiovascular System	Sympathomimetic agents
Subject	System	Topic

Copyright © UWorld. All rights reserved.

4
5
6
7
8
9
10
11
12
13
14
15
16
17
18
19
20
21
22
23
24
25
26
27
28
29
30
31
32
33
34

Exhibit Display

Phosphatidylinositol 2nd messenger system

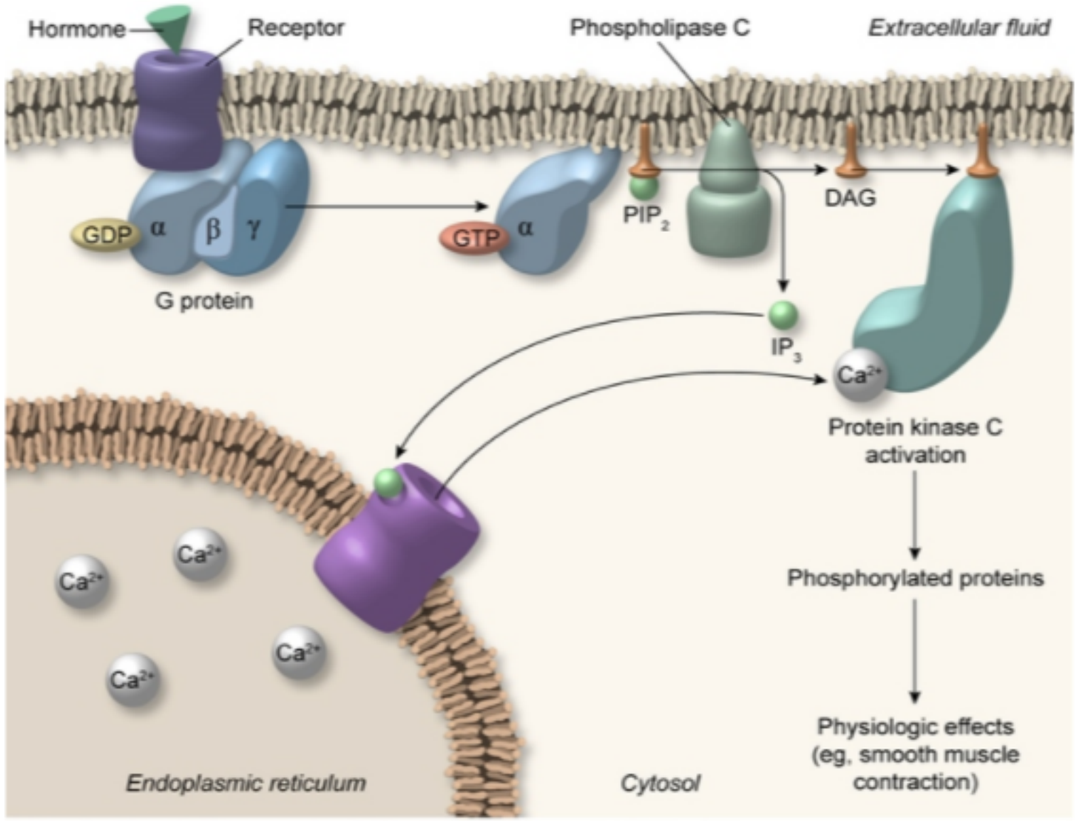

DAG = diacylglycerol; **GDP** = guanosine 5'-diphosphate; **GTP** = guanosine 5'-triphosphate; **IP_3** = inositol 1,4,5-trisphosphate; **PIP_2** = phosphatidylinositol 4,5-bisphosphate.

©UWorld

Zoom In Zoom Out Reset Add To Flash Card

4
5
6
7
8
9
10
11
12
13
14
15
16
17
18
19
20
21
22
23
24
25
26
27
28
29
30
31
32
33
34

Exhibit Display

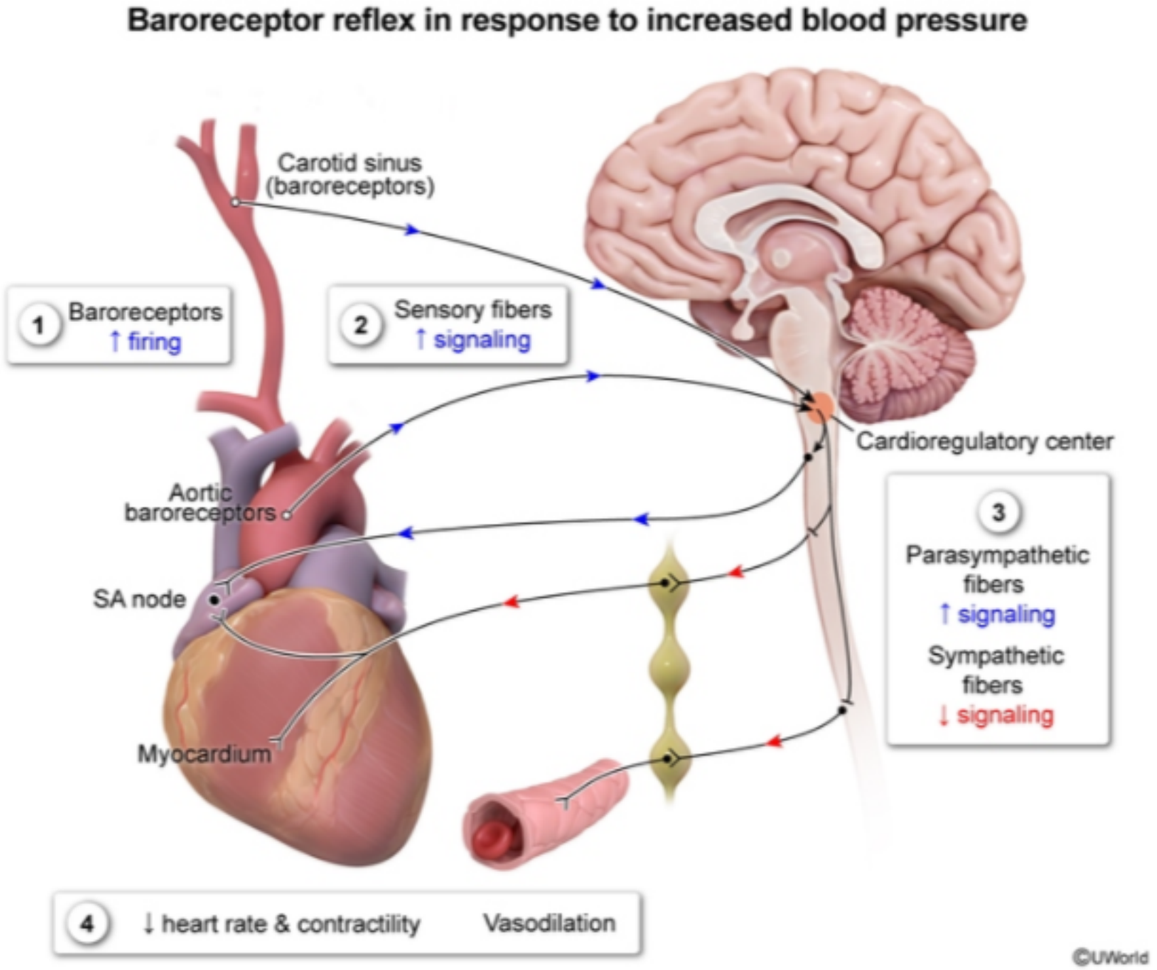

Zoom In Zoom Out Reset Add To Flash Card

4
5
6
7
8
9
10
11
12
13
14
15
16
17
18
19
20
21
22
23
24
25
26
27
28
29
30
31
32
33
34

Exhibit Display

G protein activation of adenylate cyclase

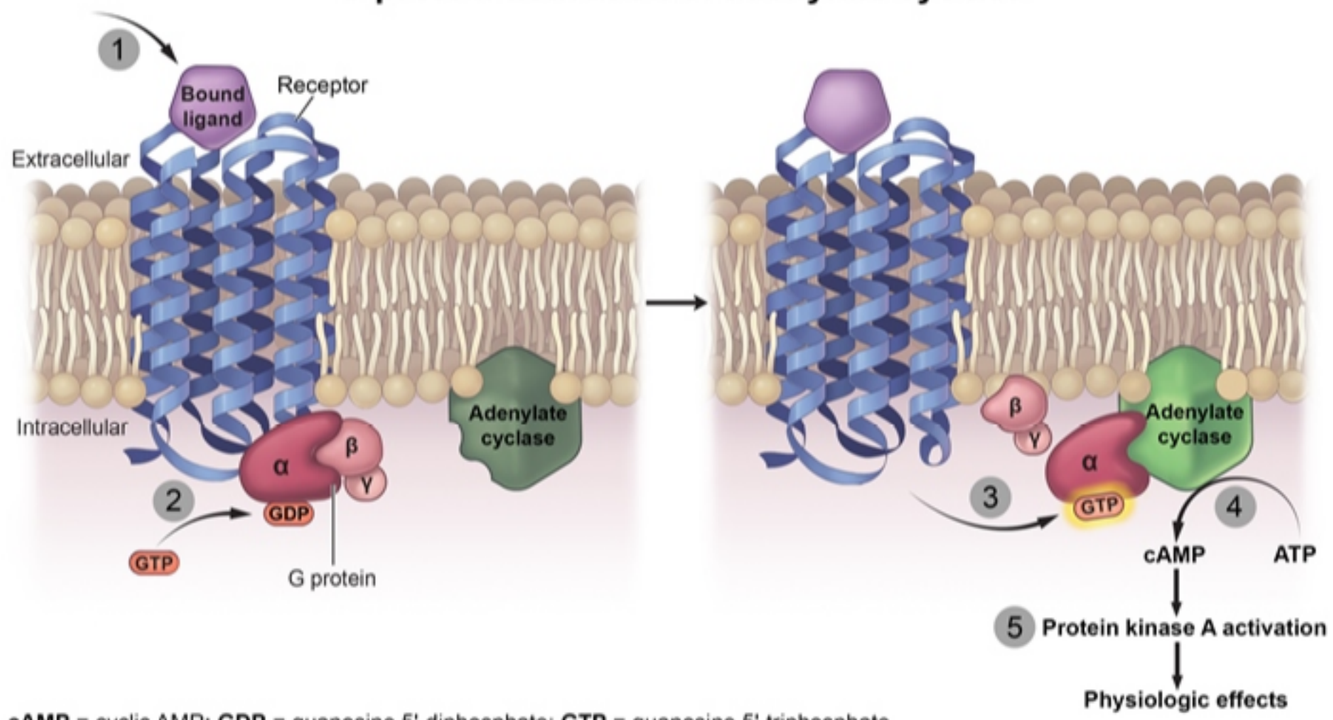

cAMP = cyclic AMP; **GDP** = guanosine 5'-diphosphate; **GTP** = guanosine 5'-triphosphate.

©UWorld

Zoom In Zoom Out Reset Add To Flash Card

4
5
6
7
8
9
10
11
12
13
14
15
16
17
18
19
20
21
22
23
24
25
26
27
28
29
30
31
32
33
34

Exhibit Display

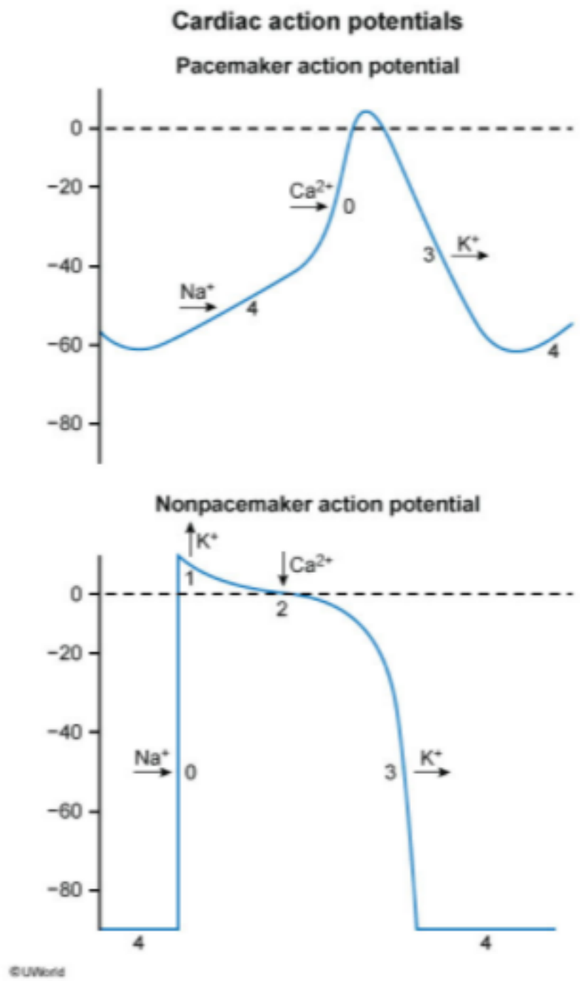

Zoom In Zoom Out Reset Add To Flash Card

4
5
6
7
8
9
10
11
12
13
14
15
16
17
18
19
20
21
22
23
24
25
26
27
28
29
30
31
32
33
34

Exhibit Display

Baroreceptor reflex in response to decreased blood pressure

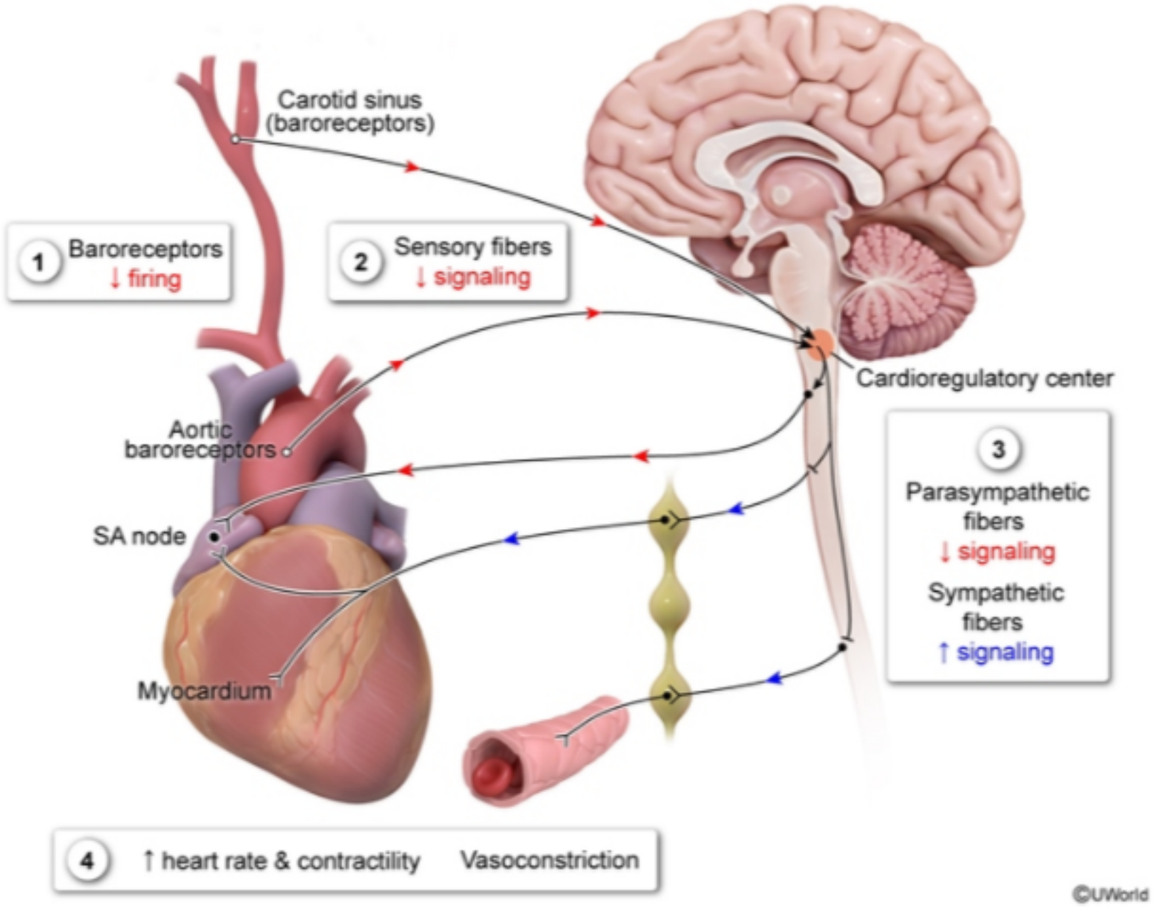

Zoom In Zoom Out Reset Add To Flash Card

4
5
6
7
8
9
10
11
12
13
14
15
16
17
18
19
20
21
22
23
24
25
26
27
28
29
30
31
32
33
34

A 32-year-old woman is recruited for a research study. She is evaluated in the hospital as part of the study protocol. Her medical history includes an uncomplicated appendectomy, and medications include oral contraceptive pills and a multivitamin. During the evaluation, increases in heart rate and cardiac output are observed, and an arterial blood gas study taken at the same time shows normal partial pressures of arterial oxygen (PaO_2) and carbon dioxide ($PaCO_2$). These changes are most likely part of an integrated response to which of the following?

A. Carotid sinus massage

B. Exercise

C. High altitude exposure

D. Panic attack

E. Pulmonary artery occlusion

Submit

4
5
6
7
8
9
10
11
12
13
14
15
16
17
18
19
20
21
22
23
24
25
26
27
28
29
30
31
32
33
34

A 32-year-old woman is recruited for a research study. She is evaluated in the hospital as part of the study protocol. Her medical history includes an uncomplicated appendectomy, and medications include oral contraceptive pills and a multivitamin. During the evaluation, increases in heart rate and cardiac output are observed, and an arterial blood gas study taken at the same time shows normal partial pressures of arterial oxygen (PaO_2) and carbon dioxide ($PaCO_2$). These changes are most likely part of an integrated response to which of the following?

A. Carotid sinus massage (9%)
✓ B. Exercise (76%)
C. High altitude exposure (2%)
D. Panic attack (9%)
E. Pulmonary artery occlusion (1%)

Omitted
Correct answer
B

76%
Answered correctly

02 secs
Time Spent

02/03/2020
Last Updated

Explanation

This patient with increased heart rate, cardiac output, and unchanged partial pressures of arterial oxygen (PaO_2) and carbon dioxide ($PaCO_2$) is likely undergoing an **exercise** test. **Heart rate** and **cardiac output increase** to meet increased tissue oxygen demands, and the respiratory rate increases to eliminate the additional carbon dioxide produced. Changes in the partial pressures of oxygen and carbon dioxide during exercise occur predominantly in the venous blood as muscle tissue extracts a higher portion of oxygen and produces greater amounts of carbon dioxide. The **PaO_2** and **$PaCO_2$** remain relatively close to **resting values** at most levels of exercise due to a number of adaptations in the lungs and pulmonary circulation, such as hyperventilation and improved ventilation-perfusion (V/Q) matching.

4
5
6
7
8
9
10
11
12
13
14
15
16
17
18
19
20
21
22
23
24
25
26
27
28
29
30
31
32
33
34

Explanation

This patient with increased heart rate, cardiac output, and unchanged partial pressures of arterial oxygen (PaO_2) and carbon dioxide ($PaCO_2$) is likely undergoing an **exercise** test. **Heart rate** and **cardiac output increase** to meet increased tissue oxygen demands, and the respiratory rate increases to eliminate the additional carbon dioxide produced. Changes in the partial pressures of oxygen and carbon dioxide during exercise occur predominantly in the venous blood as muscle tissue extracts a higher portion of oxygen and produces greater amounts of carbon dioxide. The **PaO_2** and **$PaCO_2$** remain relatively close to **resting values** at most levels of exercise due to a number of adaptations in the lungs and pulmonary circulation, such as hyperventilation and improved ventilation-perfusion (V/Q) matching.

(Choice A) Carotid sinus massage causes reflex parasympathetic stimulation of the sinoatrial node, atrial myocytes, and atrioventricular node, resulting in a transient decrease in heart rate and cardiac output.

(Choice C) High altitude simulation is associated with lower ambient oxygen pressures; consequently, heart rate and cardiac output increase in order to improve oxygen delivery to tissues. The lower oxygen pressures cause hypoxemia and result in hypoxic stimulation of respiration, causing hyperventilation and decreased $PaCO_2$.

(Choice D) A panic attack can increase heart rate and cardiac output via sympathetic stimulation of the heart; however, there is usually associated hyperventilation without a significant increase in muscle activity and therefore a fall in the $PaCO_2$.

(Choice E) Pulmonary artery occlusion as seen in pulmonary embolism (PE) results in increased pulmonary vascular resistance, right ventricular strain, and frequently decreased left ventricular stroke volume. Reflex tachycardia can result to maintain (not increase) cardiac output. Additionally, PE often causes hypoxemia (low PaO_2) due to acute V/Q mismatching in the affected lung.

Educational objective:
The cardiorespiratory response to exercise includes increased heart rate, cardiac output, and respiratory rate in order to balance the increased total tissue oxygen consumption and carbon dioxide production. These coordinated adaptations result in relatively constant arterial blood gas values whereas venous oxygen is decreased and venous carbon dioxide is increased.

References

- Integrative biology of exercise.
- Organ-specific physiological responses to acute physical exercise and long-term training in humans

4
5
6
7
8
9
10
11
12
13
14
15
16
17
18
19
20
21
22
23
24
25
26
27
28
29
30
31
32
33
34

A 43-year-old man comes to the office due to occasional chest discomfort over the last 6 weeks. He thinks he is most likely experiencing musculoskeletal pain but is concerned due to family history of heart disease. The patient has no medical conditions and does not use tobacco. He leads an active lifestyle and exercises every day. He undergoes treadmill exercise stress testing. Baseline blood pressure is 122/75 mm Hg and pulse is 54/min. After 10 minutes of exercise, his blood pressure is 155/80 mm Hg and pulse is 150/min. He has no chest pain and ECG shows no abnormalities. Compared to pretest conditions, which of the following is the single most important limiting factor for left ventricular myocardial blood supply during the test?

A. Contraction force
B. Coronary vasoconstriction
C. Diastolic aortic pressure
D. Duration of diastole
E. Intraventricular pressure
F. Systolic ventricular wall stress

Submit

4
5
6
7
8
9
10
11
12
13
14
15
16
17
18
19
20
21
22
23
24
25
26
27
28
29
30
31
32
33
34

A 43-year-old man comes to the office due to occasional chest discomfort over the last 6 weeks. He thinks he is most likely experiencing musculoskeletal pain but is concerned due to family history of heart disease. The patient has no medical conditions and does not use tobacco. He leads an active lifestyle and exercises every day. He undergoes treadmill exercise stress testing. Baseline blood pressure is 122/75 mm Hg and pulse is 54/min. After 10 minutes of exercise, his blood pressure is 155/80 mm Hg and pulse is 150/min. He has no chest pain and ECG shows no abnormalities. Compared to pretest conditions, which of the following is the single most important limiting factor for left ventricular myocardial blood supply during the test?

- A. Contraction force (6%)
- B. Coronary vasoconstriction (8%)
- C. Diastolic aortic pressure (4%)
- ✓ D. Duration of diastole (74%)
- E. Intraventricular pressure (1%)
- F. Systolic ventricular wall stress (5%)

Omitted
Correct answer
D

74%
Answered correctly

02 secs
Time Spent

02/01/2020
Last Updated

Explanation

Left ventricular myocardial perfusion & heart rate

4
5
6
7
8
9
10
11
12
13
14
15
16
17
18
19
20
21
22
23
24
25
26
27
28
29
30
31
32
33
34

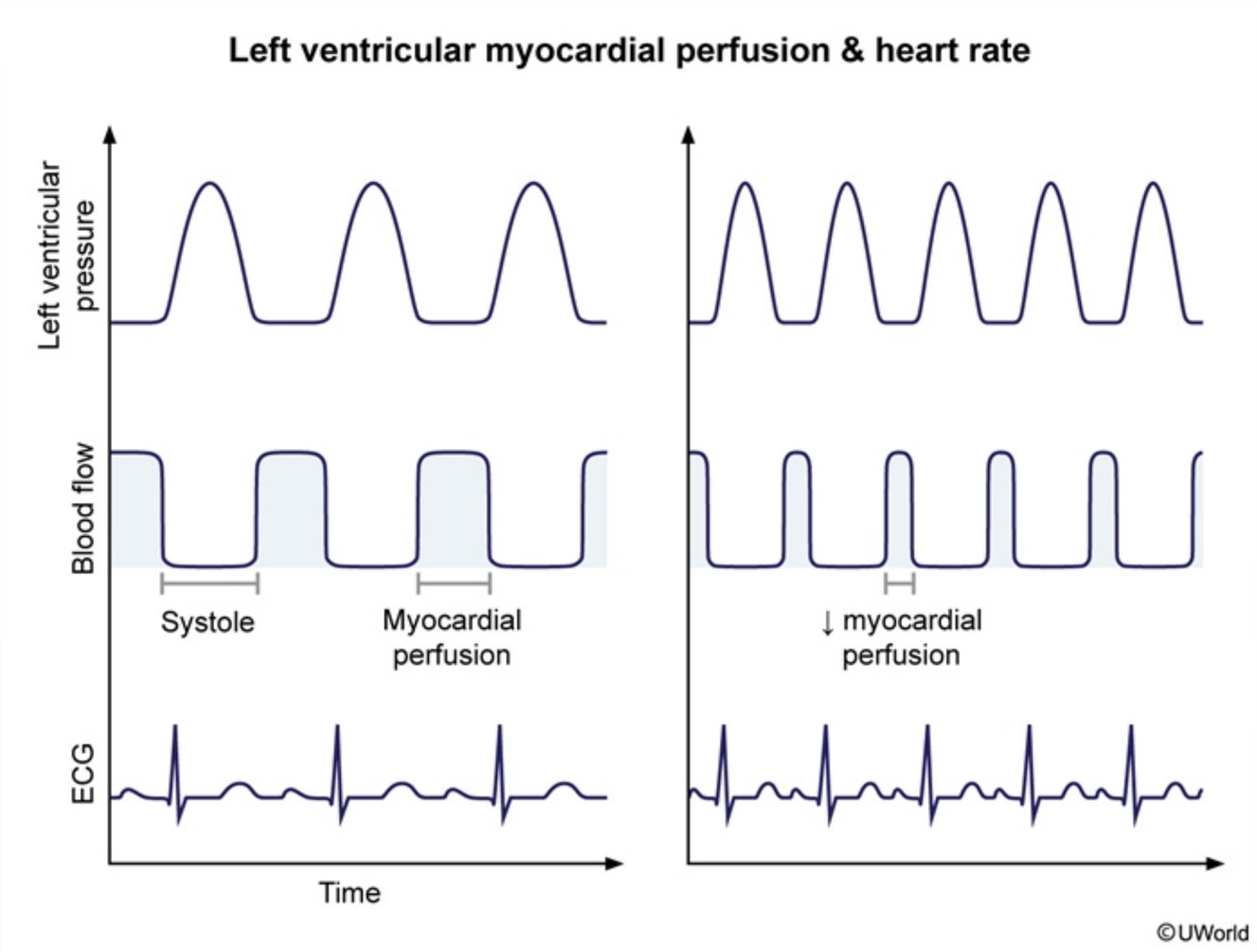

Myocardial perfusion is provided by the right and left coronary arteries arising directly from the aortic root. In contrast to most other vascular beds in the body, **left ventricular myocardial perfusion** occurs mainly during **diastole**. During ventricular systole, intraventricular pressure and wall stress in the left ventricle exceed the aortic perfusion pressure (eg, 120 mm Hg), preventing effective coronary perfusion. Wall tension is highest in the subendocardial region, making this area of the myocardium particularly susceptible to ischemia. Relaxation of the left ventricle during

©UWorld

Myocardial perfusion is provided by the right and left coronary arteries arising directly from the aortic root. In contrast to most other vascular beds in the body, **left ventricular myocardial perfusion** occurs mainly during **diastole**. During ventricular systole, intraventricular pressure and wall stress in the left ventricle exceed the aortic perfusion pressure (eg, 120 mm Hg), preventing effective coronary perfusion. Wall tension is highest in the subendocardial region, making this area of the myocardium particularly susceptible to ischemia. Relaxation of the left ventricle during diastole decreases intraventricular pressure to about 10 mm Hg (which is much lower than aortic diastolic pressure [~80 mm Hg]), providing a driving force that allows for adequate perfusion.

Increased heart rate shortens the time of ventricular relaxation (**duration of diastole**); therefore, the time available for maximal coronary blood flow decreases and consequently becomes the major limiting factor for coronary blood supply to the myocardium.

(Choice B) During exercise, mechanisms such as flow-mediated dilation and release of vasodilators such as adenosine and nitric oxide ensure adequate coronary blood supply.

(Choices A, E, and F) Left ventricular contraction force, intraventricular pressure, and ventricular wall stress all increase during exercise to provide adequate blood flow to actively contracting skeletal muscle. However, because there is already minimal left ventricular perfusion occurring during systole, the increase in these forces does not cause further limitation in left ventricular myocardial perfusion.

(Choice C) Diastolic aortic pressure is the driving force for coronary blood flow during diastole, and coronary blood flow is reduced in patients with low diastolic pressures. This patient's diastolic pressures are similar while at rest and during exercise and would not contribute to decreased coronary blood supply.

Educational objective:
The high systolic intraventricular pressure and wall stress of the left ventricle prevent myocardial perfusion during systole; therefore, the majority of left ventricular myocardial perfusion occurs during diastole. Shorter duration of diastole is the major limiting factor for coronary blood supply to the left ventricular myocardium during periods of tachycardia (eg, exercise).

Physiology	Cardiovascular System	Coronary blood flow
Subject	System	Topic

4
5
6
7
8
9
10
11
12
13
14
15
16
17
18
19
20
21
22
23
24
25
26
27
28
29
30
31
32
33
34

A 44-year-old man with progressive dyspnea is diagnosed with dilated cardiomyopathy. Despite optimal medical therapy, he continues to have symptoms and disease progression is noted. He undergoes cardiac transplantation after a suitable donor becomes available. Permission is obtained from the patient to study his diseased heart for intracellular calcium regulation. Microelectrodes placed into cardiac muscle cells detect a rapid decrease in cytoplasmic calcium level immediately preceding relaxation. Which of the following proteins is most likely responsible for the observed change in electrolyte levels?

A. Calmodulin

B. Na^+/Ca^{2+} exchanger

C. Ryanodine receptors

D. Troponin C

E. Voltage-dependent calcium channels

Submit

4
5
6
7
8
9
10
11
12
13
14
15
16
17
18
19
20
21
22
23
24
25
26
27
28
29
30
31
32
33
34

A 44-year-old man with progressive dyspnea is diagnosed with dilated cardiomyopathy. Despite optimal medical therapy, he continues to have symptoms and disease progression is noted. He undergoes cardiac transplantation after a suitable donor becomes available. Permission is obtained from the patient to study his diseased heart for intracellular calcium regulation. Microelectrodes placed into cardiac muscle cells detect a rapid decrease in cytoplasmic calcium level immediately preceding relaxation. Which of the following proteins is most likely responsible for the observed change in electrolyte levels?

- A. Calmodulin (11%)
- ✓ B. Na^+/Ca^{2+} exchanger (45%)
- C. Ryanodine receptors (21%)
- D. Troponin C (5%)
- E. Voltage-dependent calcium channels (15%)

Omitted
Correct answer
B

45%
Answered correctly

01 sec
Time Spent

02/27/2020
Last Updated

Explanation

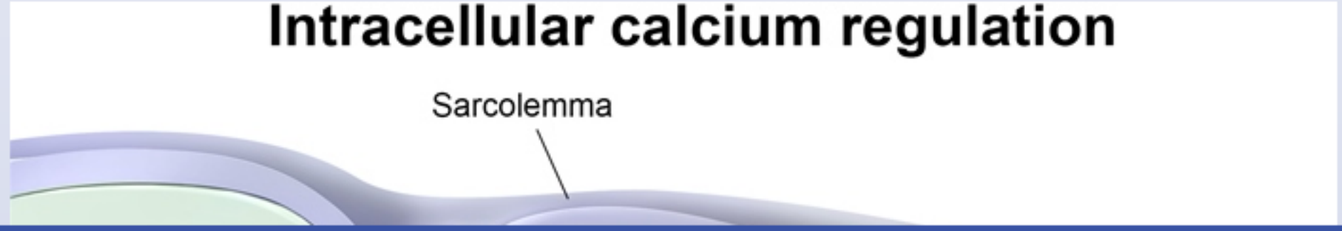

Explanation

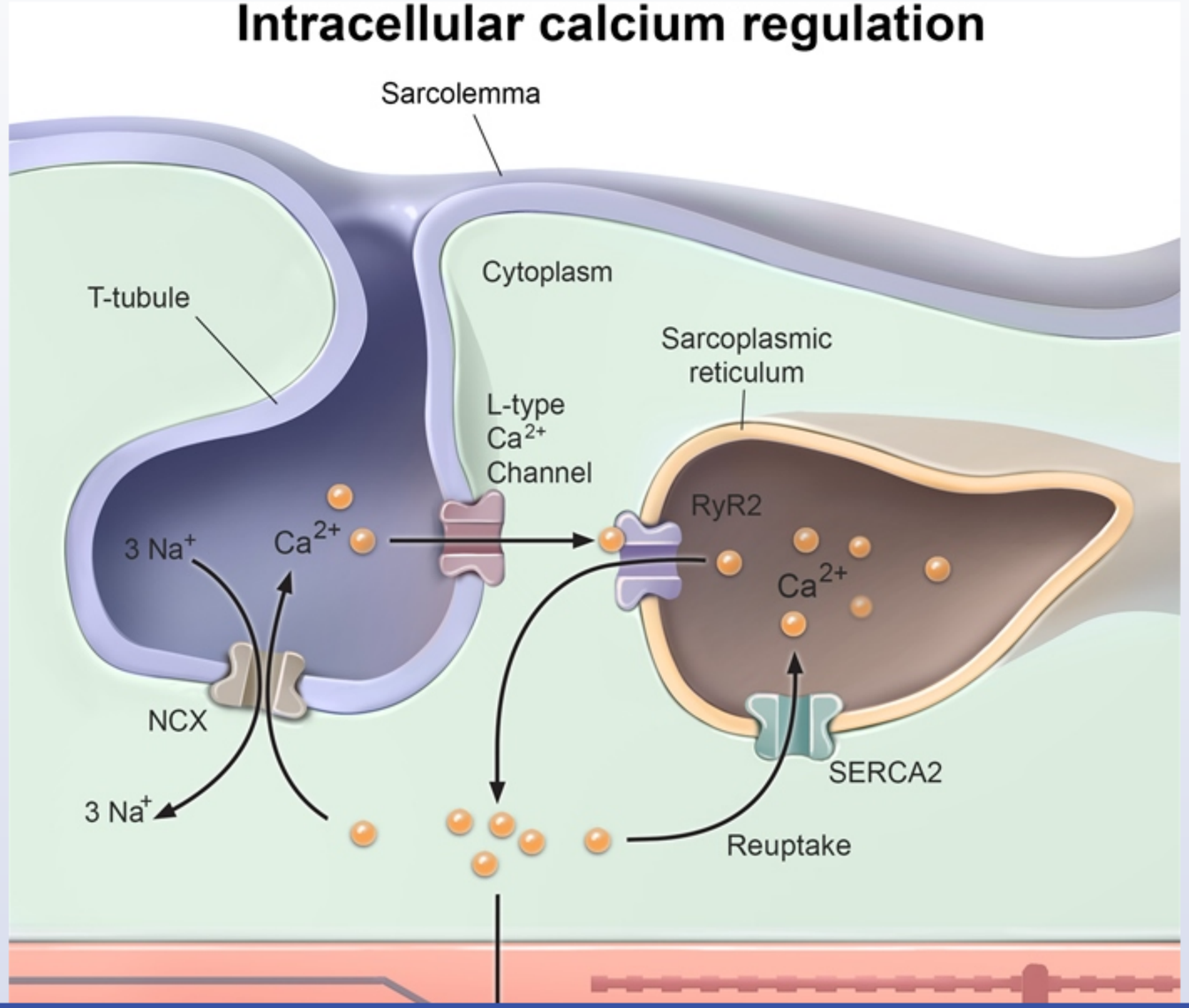

4
5
6
7
8
9
10
11
12
13
14
15
16
17
18
19
20
21
22
23
24
25
26
27
28
29
30
31
32
33
34

Intracellular calcium regulation

Exhibit Display

Intracellular calcium regulation

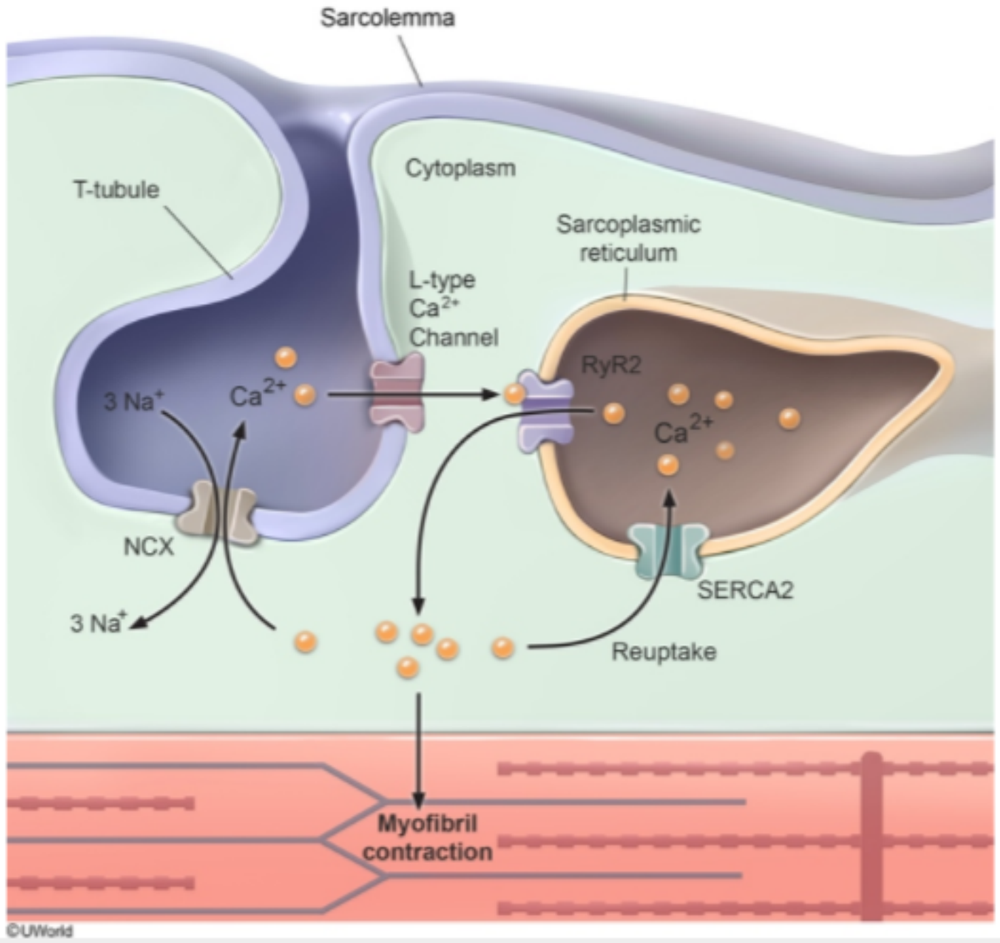

Zoom In | Zoom Out | Reset | Add To New Card | Existing Card

Myofibril

Intracellular calcium regulation plays an important role in **excitation-contraction coupling**. Voltage-dependent calcium channels (L-type) are activated during phase 2 of cardiac action potential (depolarization) and permit influx of calcium into the cardiac myocytes **(Choice E)**. This initial calcium influx is sensed by the ryanodine receptors in the sarcoplasmic reticulum, which triggers further release of Ca^{2+} (calcium-induced calcium release) into the cytoplasm, thereby increasing intracellular calcium concentration 100-fold **(Choice C)**. The calcium released from the sarcoplasmic reticulum diffuses through the myofilament network and binds to troponin C **(Choice D)**. Tropomyosin is then moved out of the way so that actin and myosin can interact, leading to muscle contraction.

The final stage of **excitation**-contraction coupling is **myocyte relaxation**, which occurs subsequent to **calcium efflux** from the cytoplasm. Intracellular calcium is removed primarily via an **Na^+/Ca^{2+} exchange pump** (NCX) and sarcoplasmic reticulum **Ca^{2+}-ATPase pump** (SERCA). NCX uses the large extracellular Na^+ concentration gradient to help pump Ca^{2+} out of the cell and, in the process, removes one intracellular Ca^{2+} in exchange for 3 extracellular Na^+ ions. In contrast, SERCA is a Ca^{2+}-ATPase pump that actively transfers Ca^{2+} from the cytosol to the lumen of sarcoplasmic reticulum at the expense of ATP hydrolysis.

(Choice A) Calmodulin (**cal**cium **modul**ated protein) is a calcium-binding messenger protein that is present in all cells and mediates many of the regulatory effects of Ca^{2+}. Calmodulin is important for excitation-contraction coupling in smooth muscle cells, which lack troponin, unlike cardiac and skeletal muscles. In cardiac muscle, calmodulin is not directly involved in excitation-contraction coupling; rather, it helps regulate intracellular calcium activity and transcription factor signaling.

Educational objective:
Calcium efflux from cardiac cells prior to relaxation is primarily mediated via an Na^+/Ca^{2+} exchange pump and sarcoplasmic reticulum Ca^{2+}-ATPase pump.

References

- The therapeutic potential of new insights into myocardial excitation-contraction coupling.

Physiology	Cardiovascular System	Muscle structure & physiology
Subject	System	Topic

Copyright © UWorld. All rights reserved.

4
5
6
7
8
9
10
11
12
13
14
15
16
17
18
19
20
21
22
23
24
25
26
27
28
29
30
31
32
33
34

Exhibit Display

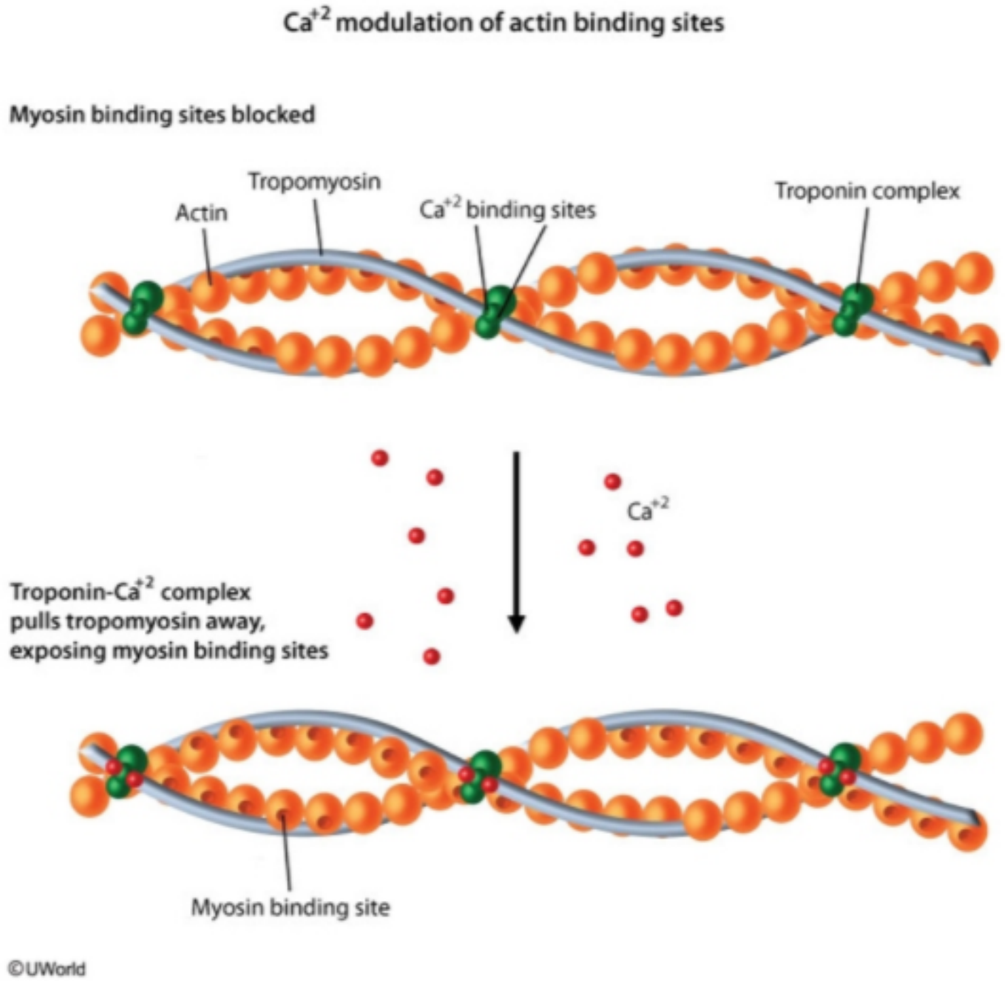

Zoom In | Zoom Out | Reset | Add To New Card | Existing Card

4
5
6
7
8
9
10
11
12
13
14
15
16
17
18
19
20
21
22
23
24
25
26
27
28
29
30
31
32
33
34

Exhibit Display

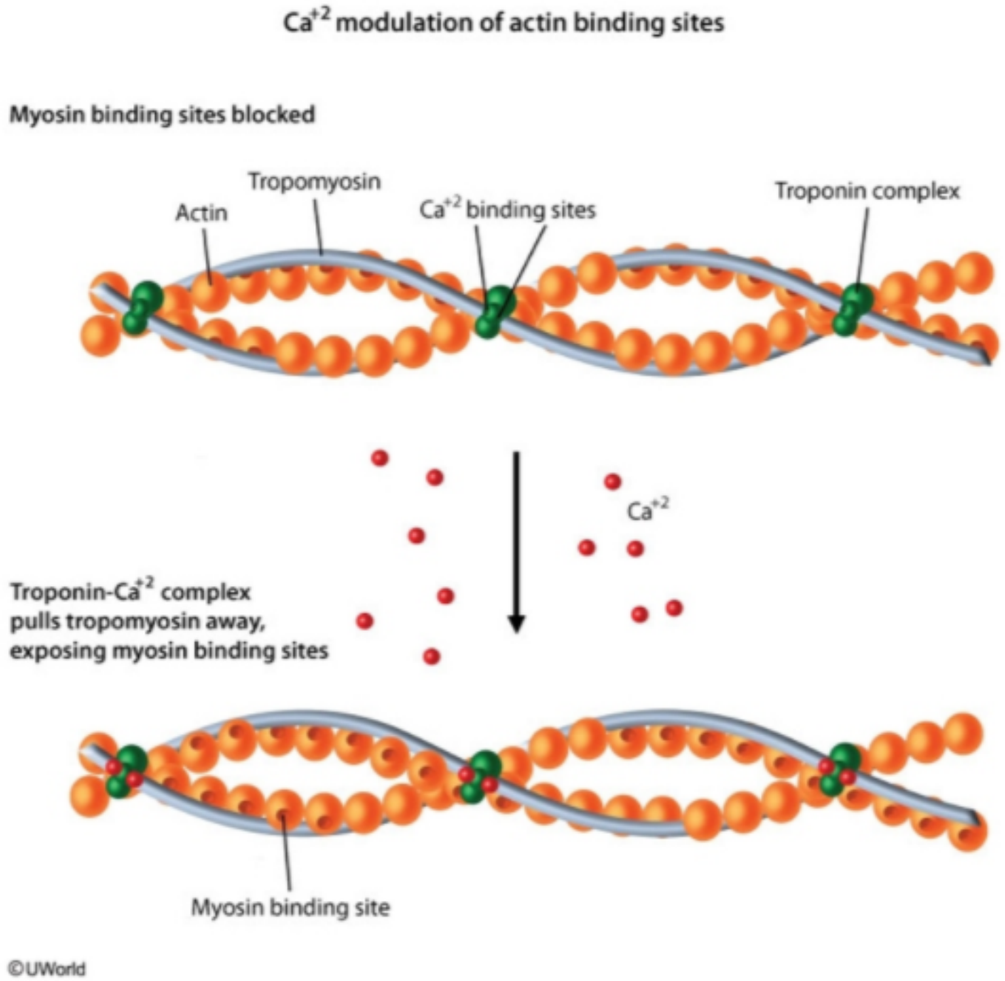

Zoom In | Zoom Out | Reset | Add To New Card | Existing Card

4
5
6
7
8
9
10
11
12
13
14
15
16
17
18
19
20
21
22
23
24
25
26
27
28
29
30
31
32
33
34

A 45-year-old man comes to the emergency department with fever, shortness of breath, and generalized weakness. Two days ago, the patient was diagnosed with a urinary tract infection and treated with oral antibiotics. He has a history of coronary artery disease and underwent coronary artery bypass graft surgery 3 years ago. The patient is admitted to the hospital and started on medical therapy. As a result of his treatment, the left ventricular pressure-volume loop changes from the solid line to the dashed line, as shown on the graph below.

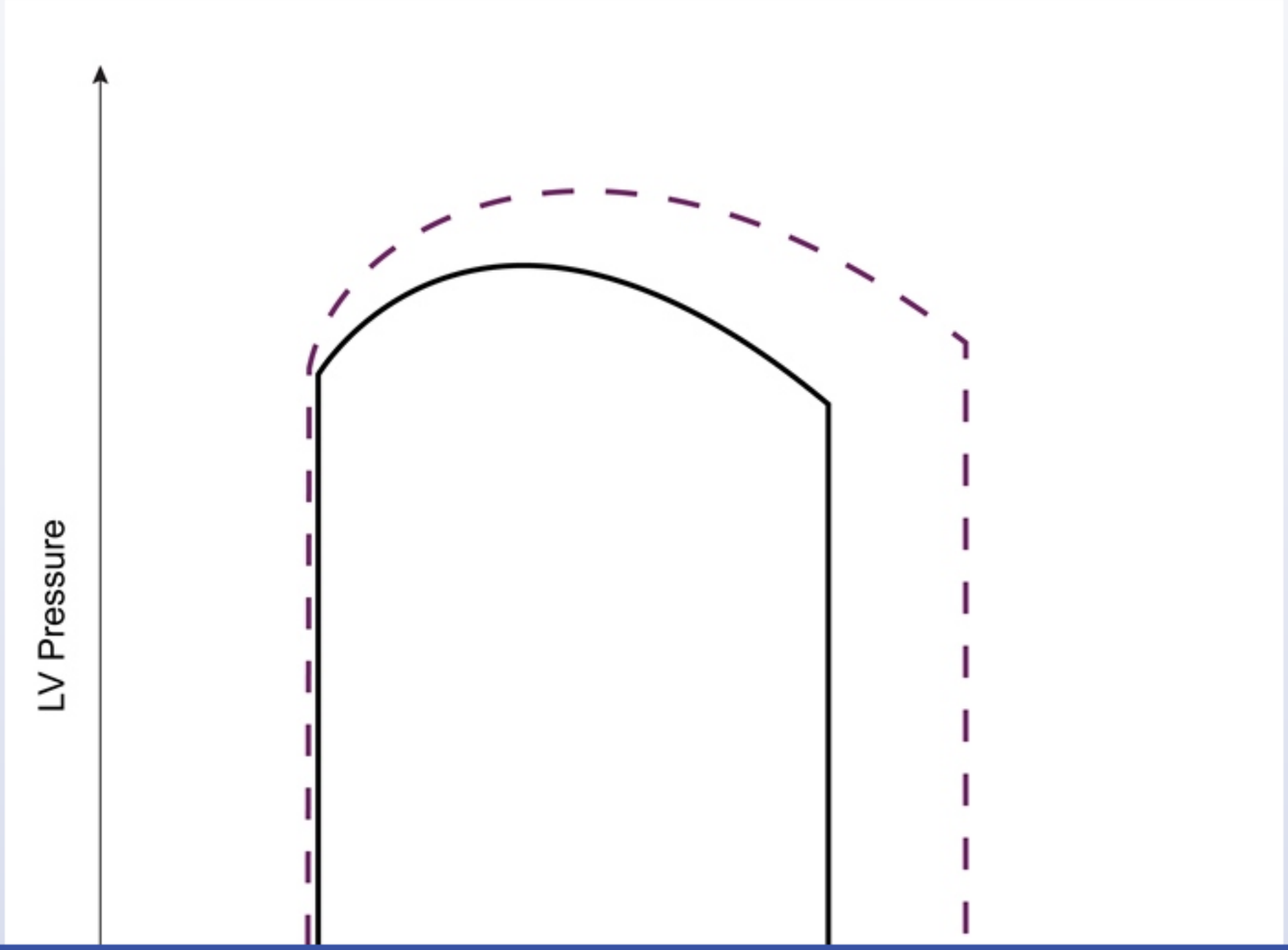

4
5
6
7
8
9
10
11
12
13
14
15
16
17
18
19
20
21
22
23
24
25
26
27
28
29
30
31
32
33
34

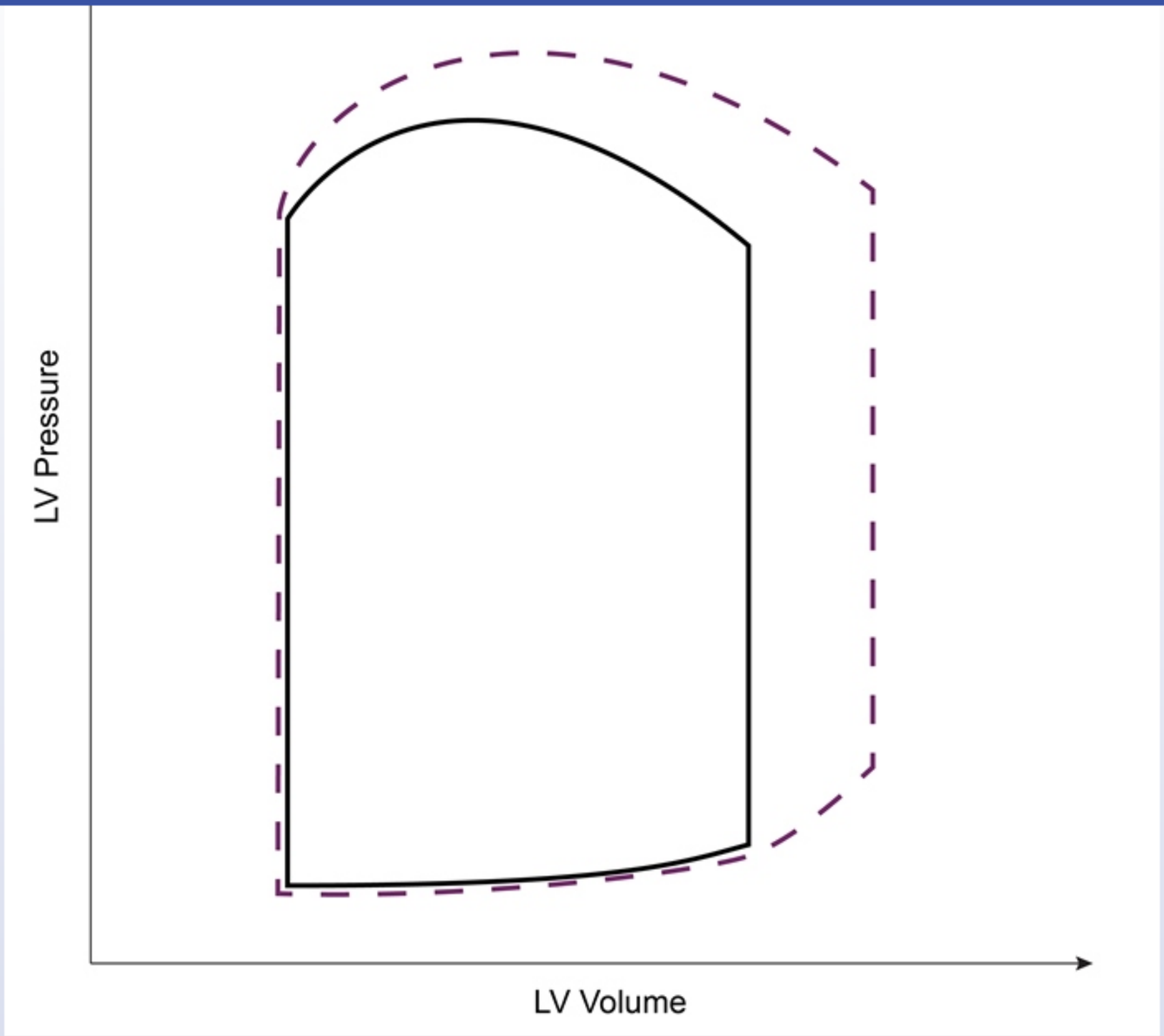

4
5
6
7
8
9
10
11
12
13
14
15
16
17
18
19
20
21
22
23
24
25
26
27
28
29
30
31
32
33
34

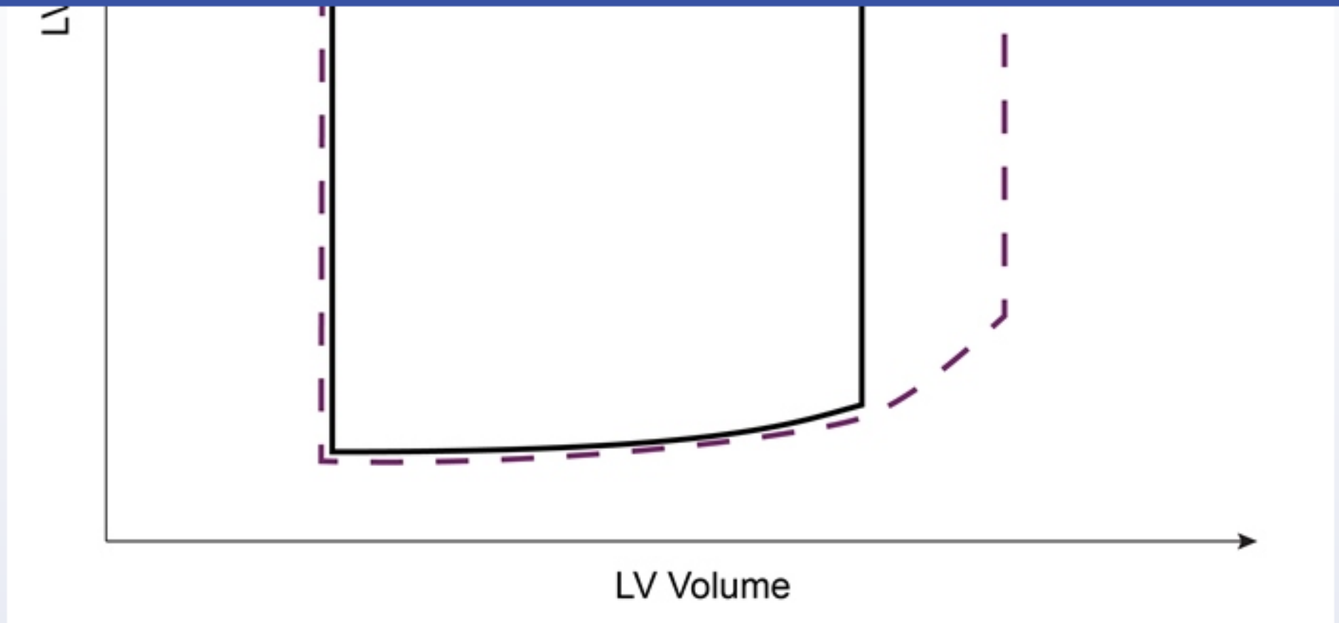

Which of the following therapies is most likely responsible for the hemodynamic change?

- A. Abdominal aorta clamping
- B. Blood volume loss
- C. Dobutamine infusion
- D. Loss of contracting myocardial mass
- E. Normal saline infusion

Submit

4
5
6
7
8
9
10
11
12
13
14
15
16
17
18
19
20
21
22
23
24
25
26
27
28
29
30
31
32
33
34

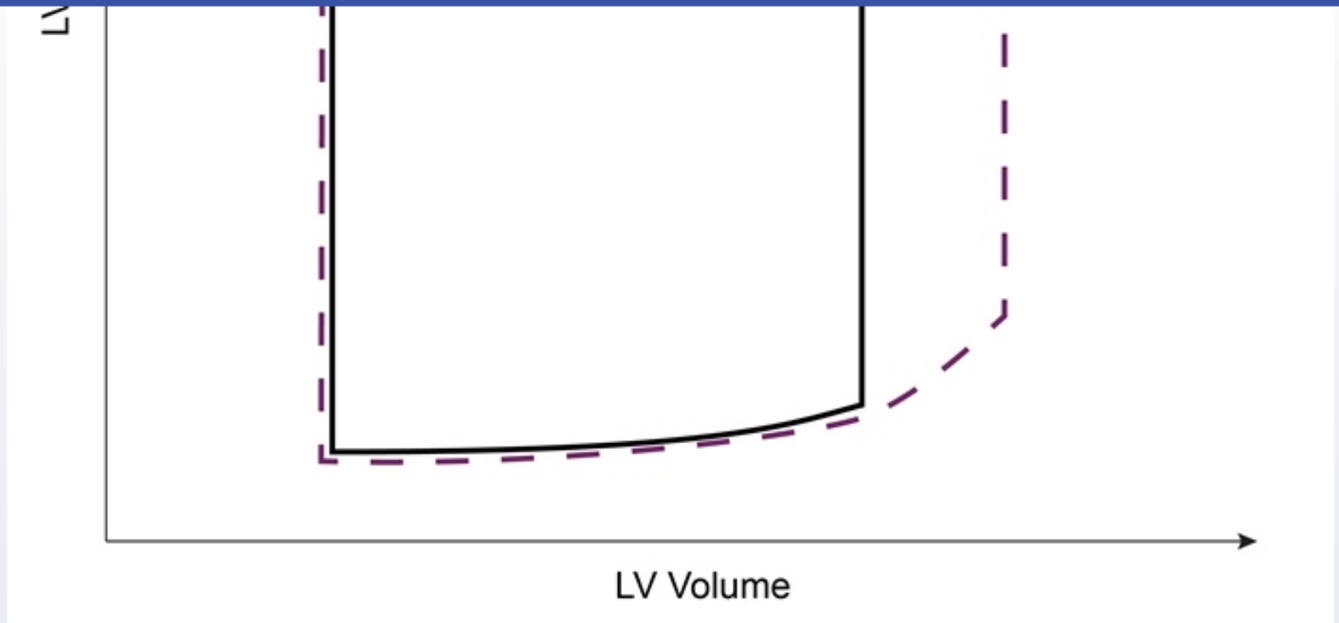

Which of the following therapies is most likely responsible for the hemodynamic change?

A. Abdominal aorta clamping (2%)

B. Blood volume loss (1%)

C. Dobutamine infusion (16%)

D. Loss of contracting myocardial mass (2%)

✓ E. Normal saline infusion (77%)

Omitted
Correct answer

77%
Answered correctly

08 secs
Time Spent

04/28/2020
Last Updated

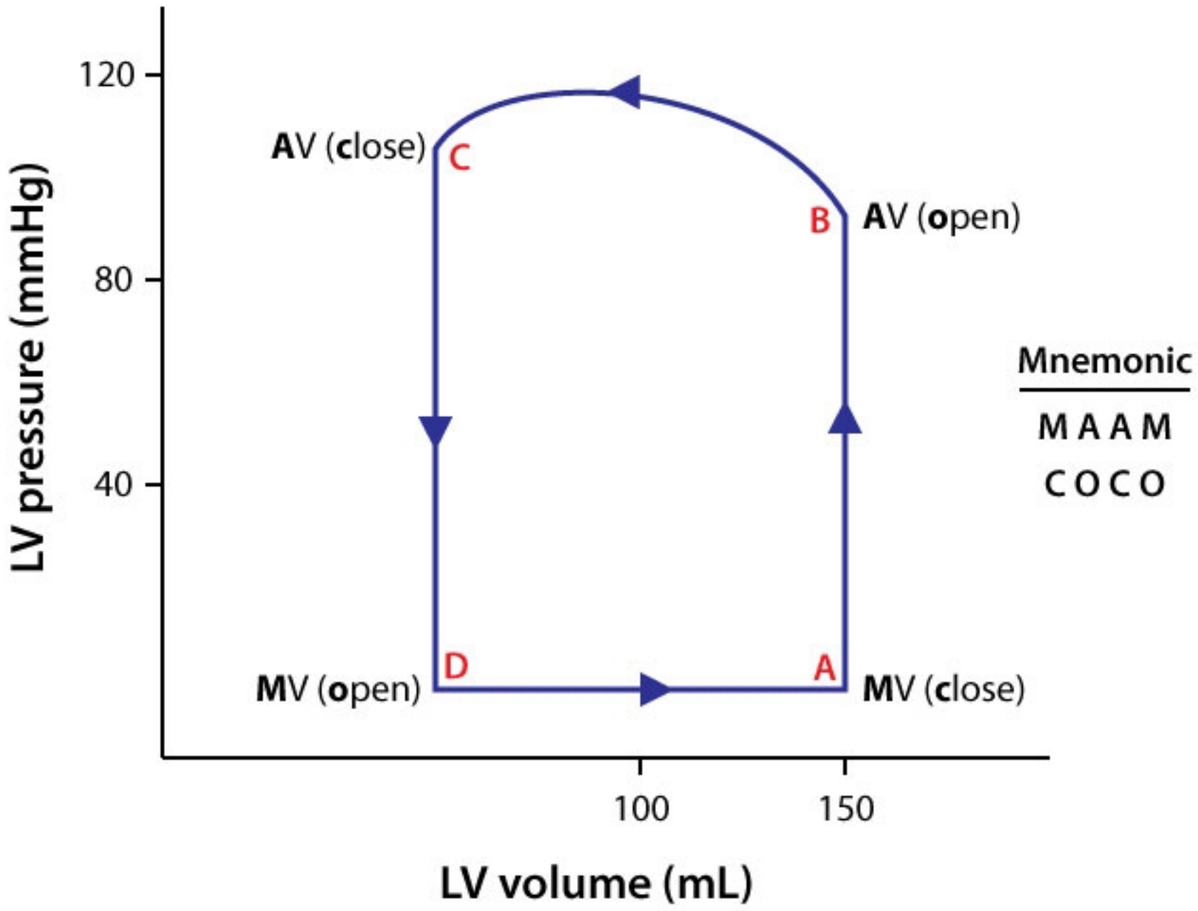

Mnemonic

M A A M
C O C O

A → B = Isovolumetric contraction
B → C = Ventricular ejection
} Ventricular systole

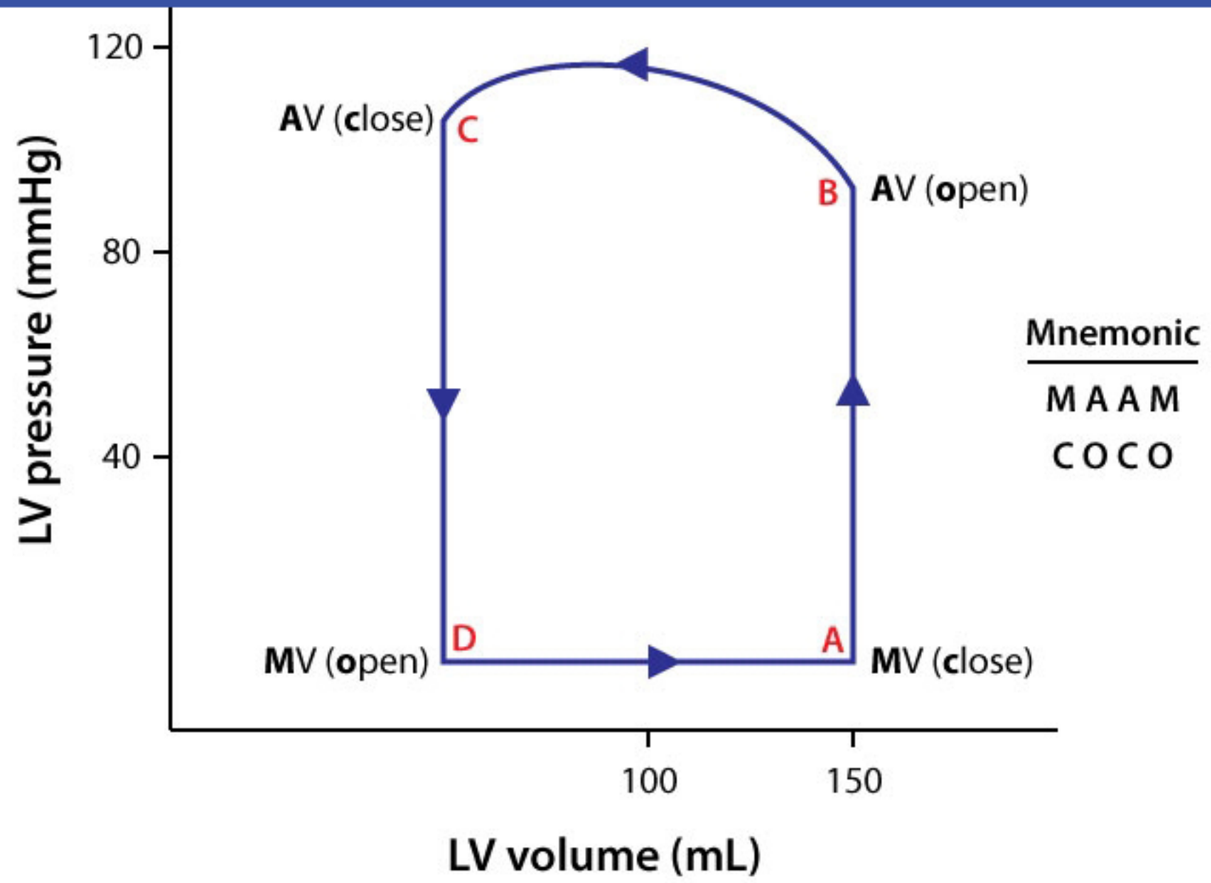

Mnemonic

M A A M
C O C O

A → B = Isovolumetric contraction
B → C = Ventricular ejection
} Ventricular systole

C → D = Isovolumetric relaxation
D → A = Ventricular filling
} Ventricular diastole

©UWorld

Ventricular pressure-volume loops depict the relationship between pressure and volume in the left ventricle during systole and diastole. The **rightward extension** of the ventricular filling portion of the graph (point D to point A) indicates larger than normal left ventricular end-diastolic volume (**increased ventricular preload**). This can occur during any state of **fluid overload** (renal failure, congestive heart failure) or after infusion of intravenous fluids.

(Choice A) Clamping the abdominal aorta would drastically increase afterload, causing narrowing and upward shift of the ventricular ejection phase of the pressure-volume loop (the result of higher than normal pressures at the time of aortic valve opening and closure). The graph narrows as less blood would be ejected during ventricular contraction (due to the increased effort needed to overcome the higher aortic pressures).

(Choice B) Blood volume loss would have an effect opposite of that depicted, causing the ventricular filling phase to be shorter than normal.

(Choice C) Dobutamine infusion would cause an increase in contractility. Higher pressures would be reached during the ventricular ejection phase of the pressure-volume loop, and a greater volume of blood would be ejected during contraction. The result would be widening of the pressure-volume loop due to decreased end-systolic volume.

(Choice D) Loss of contracting myocardial mass results in decreased contractility. This leads to increased end-systolic volume (amount of blood remaining in the left ventricle after contraction). The ventricular pressure-volume loop is narrow with a shift in the isovolumetric relaxation line to the right indicating a smaller ejection fraction with a larger end-systolic volume.

Educational objective:
Pressure-volume loops represent the relationship between pressure and volume in the left ventricle during systole and diastole. An increase in the circulating volume increases preload (left ventricular end-diastolic volume) and causes a rightward widening of the pressure-volume loop.

Physiology	Cardiovascular System	Cardiac physiology
Subject	System	Topic

Copyright © UWorld. All rights reserved.

4
5
6
7
8
9
10
11
12
13
14
15
16
17
18
19
20
21
22
23
24
25
26
27
28
29
30
31
32
33
34

Exhibit Display

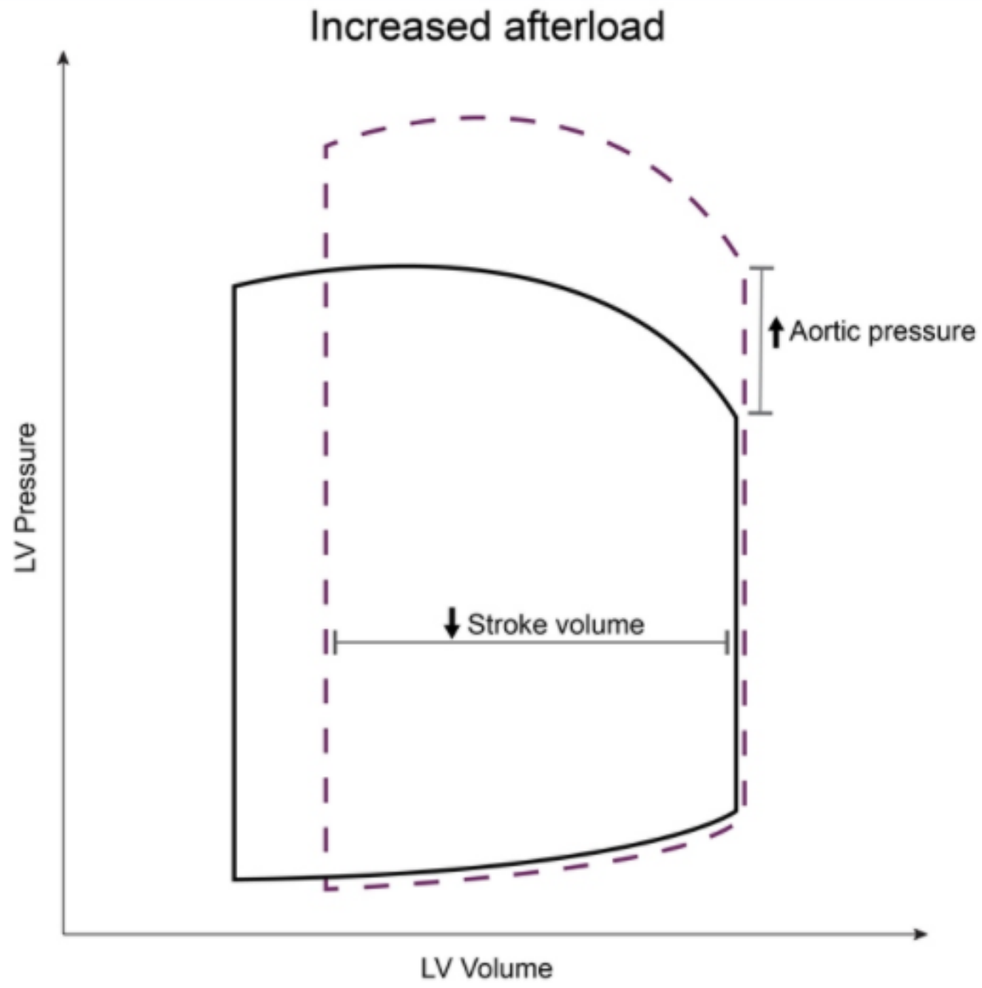

Zoom In | Zoom Out | Reset | Add To New Card | Existing Card

4
5
6
7
8
9
10
11
12
13
14
15
16
17
18
19
20
21
22
23
24
25
26
27
28
29
30
31
32
33
34

Exhibit Display

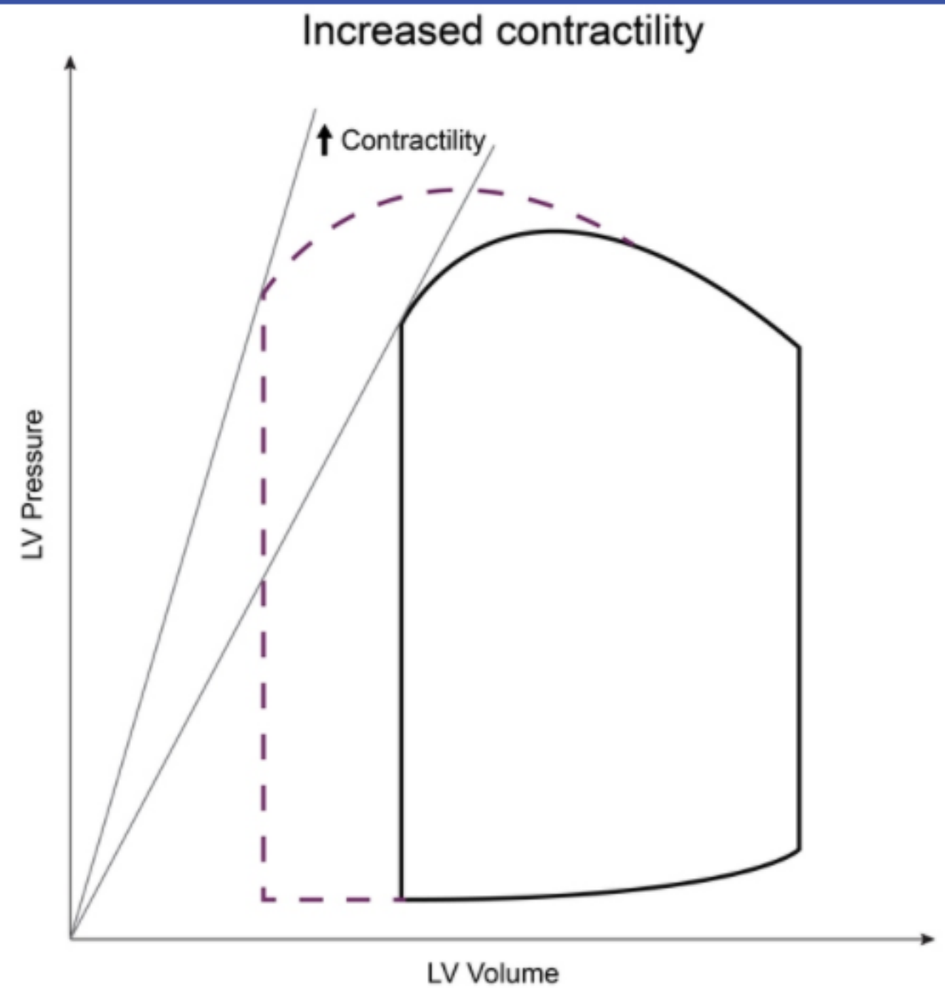

Zoom In Zoom Out Reset Add To New Card | Existing Card

4
5
6
7
8
9
10
11
12
13
14
15
16
17
18
19
20
21
22
23
24
25
26
27
28
29
30
31
32
33
34

Exhibit Display

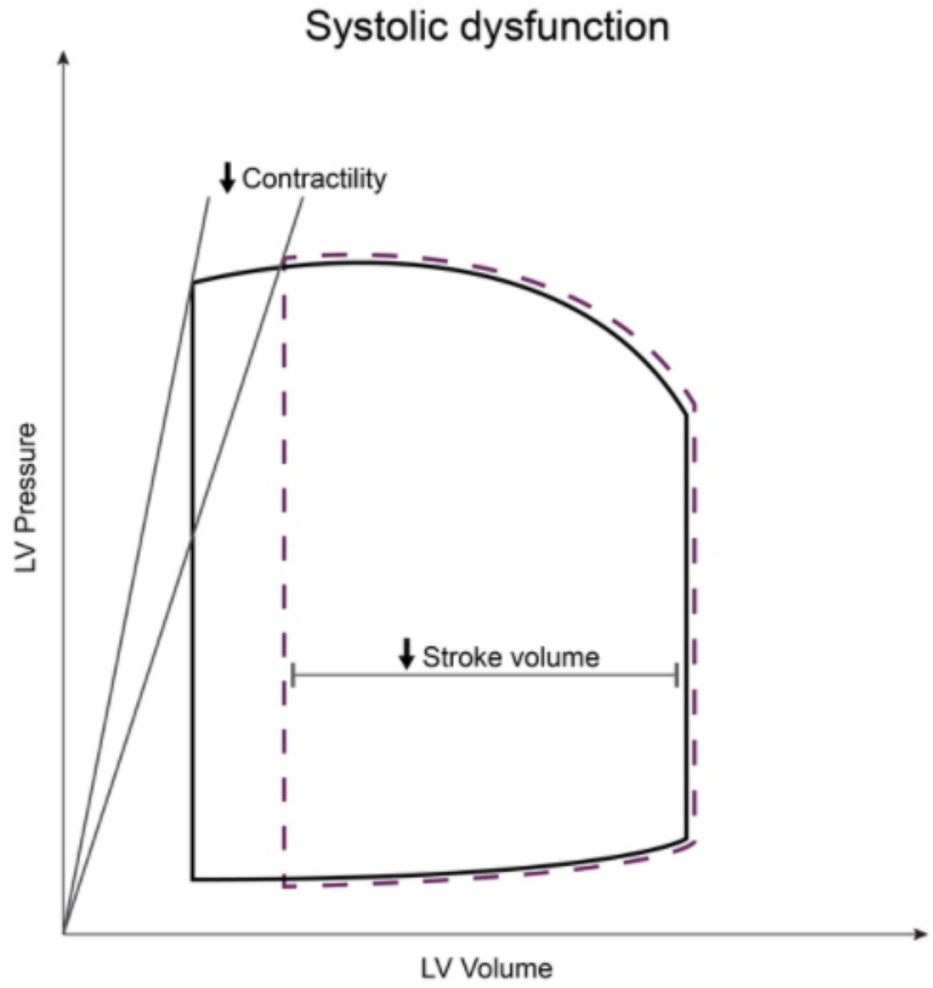

Zoom In Zoom Out Reset Add To New Card | Existing Card

4
5
6
7
8
9
10
11
12
13
14
15
16
17
18
19
20
21
22
23
24
25
26
27
28
29
30
31
32
33
34

An 8-month-old previously healthy infant is brought to the urgent care clinic due to vomiting and watery diarrhea for the past 3 days. He attends a day care where recently several other children had similar symptoms. His mother states that the infant is less active and has no interest in feeding. Physical examination shows a listless infant with tachycardia, dry mucous membranes, and decreased skin turgor. The abdomen is nontender with hyperactive bowel sounds. Compared to pre-illness levels, which of the following sets of laboratory findings are most likely present in this patient?

	Hematocrit	Serum albumin concentration	Serum uric acid concentration
A.	Decreased	Decreased	Decreased
B.	Decreased	Decreased	Normal
C.	Decreased	Increased	Decreased
D.	Increased	Decreased	Normal
E.	Increased	Increased	Increased
F.	Increased	Normal	Normal

Submit

4
5
6
7
8
9
10
11
12
13
14
15
16
17
18
19
20
21
22
23
24
25
26
27
28
29
30
31
32
33
34

An 8-month-old previously healthy infant is brought to the urgent care clinic due to vomiting and watery diarrhea for the past 3 days. He attends a day care where recently several other children had similar symptoms. His mother states that the infant is less active and has no interest in feeding. Physical examination shows a listless infant with tachycardia, dry mucous membranes, and decreased skin turgor. The abdomen is nontender with hyperactive bowel sounds. Compared to pre-illness levels, which of the following sets of laboratory findings are most likely present in this patient?

	Hematocrit	Serum albumin concentration	Serum uric acid concentration
A. (2%)	Decreased	Decreased	Decreased
B. (9%)	Decreased	Decreased	Normal
C. (4%)	Decreased	Increased	Decreased
D. (13%)	Increased	Decreased	Normal
✓ E. (49%)	Increased	Increased	Increased
F. (19%)	Increased	Normal	Normal

Omitted
Correct answer
E

49%
Answered correctly

02 secs
Time Spent

02/04/2020
Last Updated

4
5
6
7
8
9
10
11
12
13
14
15
16
17
18
19
20
21
22
23
24
25
26
27
28
29
30
31
32
33
34

An 8-month-old previously healthy infant is brought to the urgent care clinic due to vomiting and watery diarrhea for the past 3 days. He attends a day care where recently several other children had similar symptoms. His mother states that the infant is less active and has no interest in feeding. Physical examination shows a listless infant with tachycardia, dry mucous membranes, and decreased skin turgor. The abdomen is nontender with hyperactive bowel sounds. Compared to pre-illness levels, which of the following sets of laboratory findings are most likely present in this patient?

	Hematocrit	Serum albumin concentration	Serum uric acid concentration
A. (2%)	Decreased	Decreased	Decreased
B. (9%)	Decreased	Decreased	Normal
C. (4%)	Decreased	Increased	Decreased
D. (13%)	Increased	Decreased	Normal
✓ E. (49%)	Increased	Increased	Increased
F. (19%)	Increased	Normal	Normal

Omitted
Correct answer
E

49%
Answered correctly

02 secs
Time Spent

02/04/2020
Last Updated

4
5
6
7
8
9
10
11
12
13
14
15
16
17
18
19
20
21
22
23
24
25
26
27
28
29
30
31
32
33
34

Explanation

This patient's history of vomiting and diarrhea and physical examination findings of tachycardia, dry mucous membranes, and decreased skin turgor are consistent with moderate to severe **hypovolemia**. Vomiting and diarrhea cause gastrointestinal losses of both sodium and water from the extracellular space with a consequent **decrease in plasma volume**. Because red blood cells and proteins such as albumin are relatively large and trapped intravascularly, these blood components become concentrated, leading to **increased hematocrit** and **increased serum albumin**. Such hemoconcentration can be a clue to hypovolemia caused by salt and/or water depletion; however, it does not occur with hypovolemia due to acute blood loss because red blood cells and albumin are also depleted.

In the setting of hypovolemia, the kidneys respond by increasing sodium reabsorption to increase circulating blood volume. This increased sodium reabsorption occurs in both the distal renal tubule via increased aldosterone activity and the proximal renal tubule through poorly understood mechanisms. Uric acid absorption is closely tied and directly related to sodium absorption in the proximal renal tubule; therefore, there is typically **increased serum uric acid** in the setting of hypovolemia. Although uric acid levels are not typically collected in the management of hypovolemia, the relationship between hypovolemia and serum uric acid level has clinical application in that hypovolemia increases the risk of acute gout flares.

Educational objective:
Hypovolemia due to loss of sodium and/or water causes increased concentration of red blood cells (ie, hematocrit) and albumin as both of these blood components are trapped within the intravascular space. Hypovolemia also triggers increased absorption of uric acid in the proximal renal tubule, resulting in an increased serum uric acid level.

References

- Renal transport of uric acid: evolving concepts and uncertainties.

Physiology	Cardiovascular System	Hypovolemia
Subject	System	Topic

Copyright © UWorld. All rights reserved.

4
5
6
7
8
9
10
11
12
13
14
15
16
17
18
19
20
21
22
23
24
25
26
27
28
29
30
31
32
33
34

A 23-year-old man comes to the emergency department with sudden onset of heart palpitations that started while he was at his desk at work. The patient has no known medical problems and does not use tobacco or illicit drugs. He drinks alcohol occasionally on the weekends. Initial blood pressure is 110/70 mm Hg and pulse is 160/min and regular. Gentle neck massage just below the angle of the right mandible provides immediate improvement of his condition. His blood pressure is now 120/80 mm Hg and pulse is 75/min. Which of the following mechanisms is responsible for improvement of this patient's condition?

A. Decreased baroreceptor firing rate

B. Increased sympathetic output to the sinoatrial node

C. Increased systemic vascular resistance

D. Prolonged atrioventricular node refractory period

E. Prolonged ventricular myocardium refractory period

Submit

4
5
6
7
8
9
10
11
12
13
14
15
16
17
18
19
20
21
22
23
24
25
26
27
28
29
30
31
32
33
34

A 23-year-old man comes to the emergency department with sudden onset of heart palpitations that started while he was at his desk at work. The patient has no known medical problems and does not use tobacco or illicit drugs. He drinks alcohol occasionally on the weekends. Initial blood pressure is 110/70 mm Hg and pulse is 160/min and regular. Gentle neck massage just below the angle of the right mandible provides immediate improvement of his condition. His blood pressure is now 120/80 mm Hg and pulse is 75/min. Which of the following mechanisms is responsible for improvement of this patient's condition?

A. Decreased baroreceptor firing rate (34%)

B. Increased sympathetic output to the sinoatrial node (5%)

C. Increased systemic vascular resistance (4%)

✓ D. Prolonged atrioventricular node refractory period (53%)

E. Prolonged ventricular myocardium refractory period (1%)

Omitted
Correct answer
D

53%
Answered correctly

02 secs
Time Spent

01/16/2020
Last Updated

Explanation

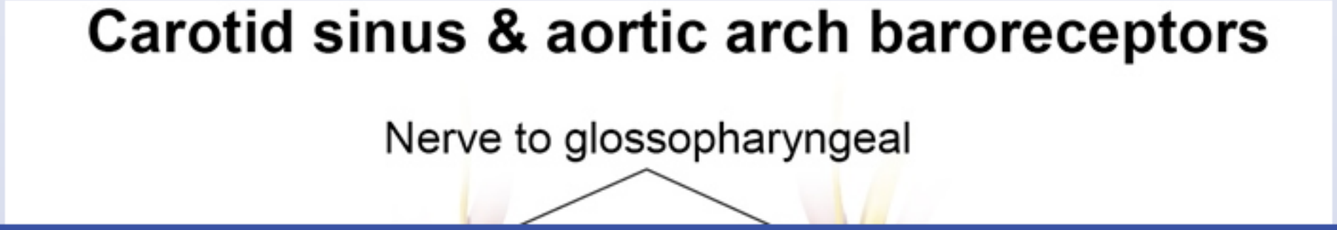

Carotid sinus & aortic arch baroreceptors

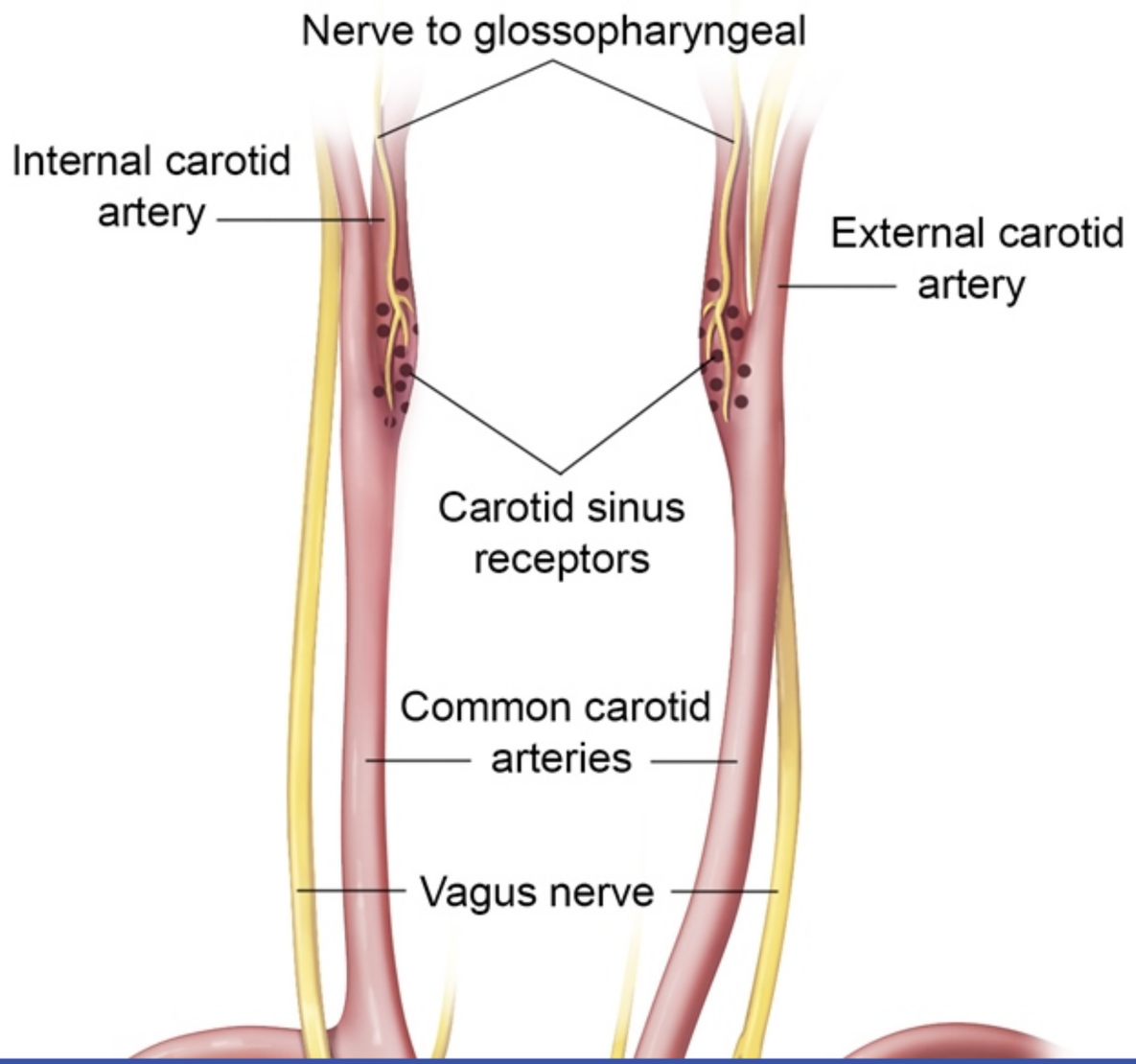

4
5
6
7
8
9
10
11
12
13
14
15
16
17
18
19
20
21
22
23
24
25
26
27
28
29
30
31
32
33
34

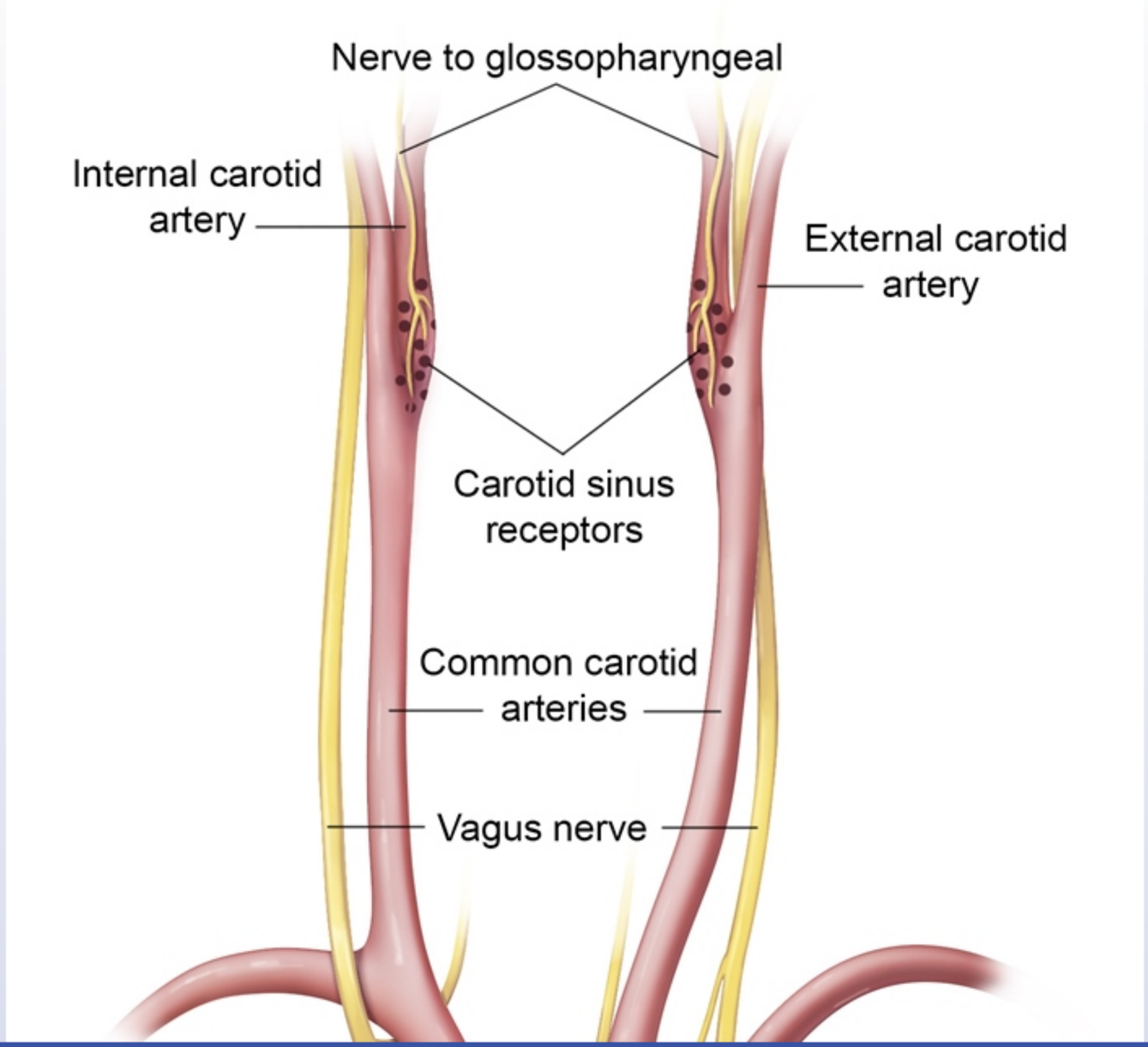

4
5
6
7
8
9
10
11
12
13
14
15
16
17
18
19
20
21
22
23
24
25
26
27
28
29
30
31
32
33
34

Exhibit Display

Carotid sinus & aortic arch baroreceptors

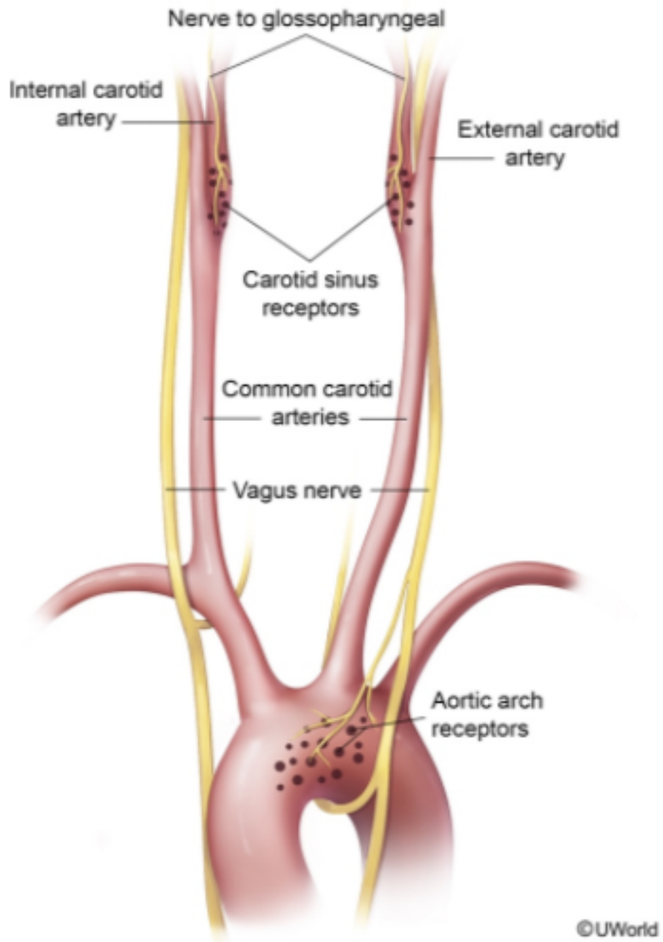

Zoom In | Zoom Out | Reset | Add To New Card | Existing Card

4
5
6
7
8
9
10
11
12
13
14
15
16
17
18
19
20
21
22
23
24
25
26
27
28
29
30
31
32
33
34

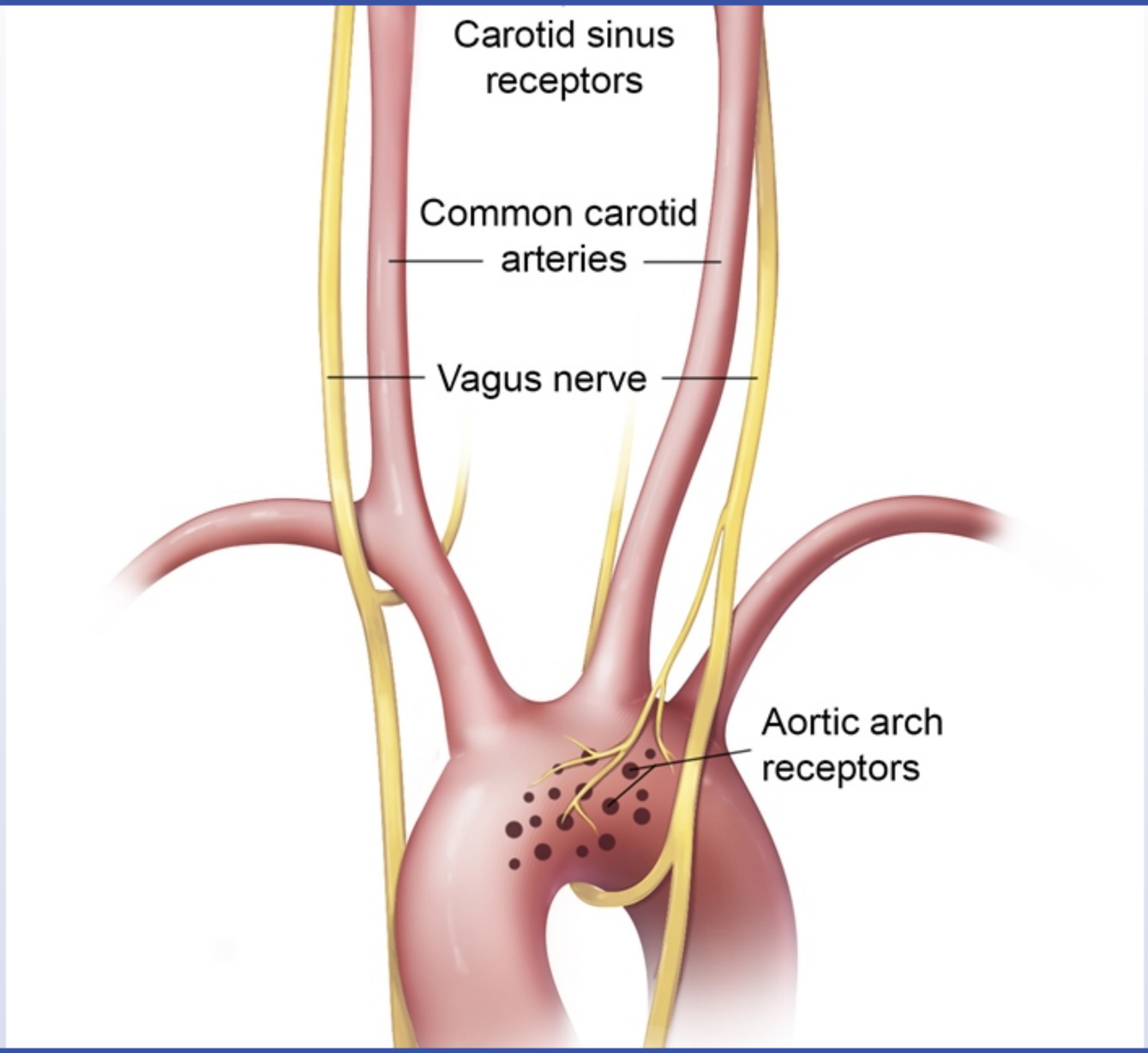

This patient's presentation with sudden onset of palpitations and rapid regular tachycardia is consistent with **paroxysmal supraventricular tachycardia** (PSVT), which is most often due to a reentrant impulse traveling circularly between the slowly and rapidly conducting segments of the atrioventricular (AV) node. **Vagal maneuvers** such as carotid sinus massage, Valsalva, and cold water immersion can be used to acutely terminate PSVT.

The carotid sinuses are bulges in the internal carotid artery with baroreceptors located immediately distal to the bifurcation of the common carotid artery. The carotid sinus reflex has an afferent limb that arises from the baroreceptors in the sinus and travels to the vagal nucleus and medullary centers via the glossopharyngeal nerve (cranial nerve [CN] IX), whereas the efferent limb carries parasympathetic impulses to the sinoatrial (SA) and AV nodes via the vagus nerve (CN X). Carotid sinus massage leads to increased afferent firing from the carotid sinus, which in turn, **increases vagal parasympathetic tone**. This **slows conduction through the AV node** and **prolongs** the AV node **refractory period**, helping to terminate the reentrant tachycardia.

(Choices A, B, and C) Carotid sinus massage stimulates the baroreceptors and increases the firing rate from the carotid sinus, leading to an increase in parasympathetic output and withdrawal of sympathetic output to the heart and peripheral vasculature. This leads to slowing of the heart rate and AV conduction, along with a decrease in systemic vascular resistance.

(Choice E) Vagal efferent nerves only sparsely innervate ventricular myocardium, and carotid sinus massage does not cause any significant change in the ventricular refractory period.

Educational objective:
Carotid sinus massage leads to an increase in parasympathetic tone causing temporary inhibition of sinoatrial node activity, slowing of conduction through the atrioventricular (AV) node, and prolongation of the AV node refractory period. It is a useful vagal maneuver for termination of paroxysmal supraventricular tachycardia.

References

- Vagal techniques for termination of paroxysmal supraventricular tachycardia.

Physiology	Cardiovascular System	Supraventricular tachycardia
Subject	System	Topic

4
5
6
7
8
9
10
11
12
13
14
15
16
17
18
19
20
21
22
23
24
25
26
27
28
29
30
31
32
33
34

The cardiac output and venous return curves of a healthy person are shown below with solid lines.

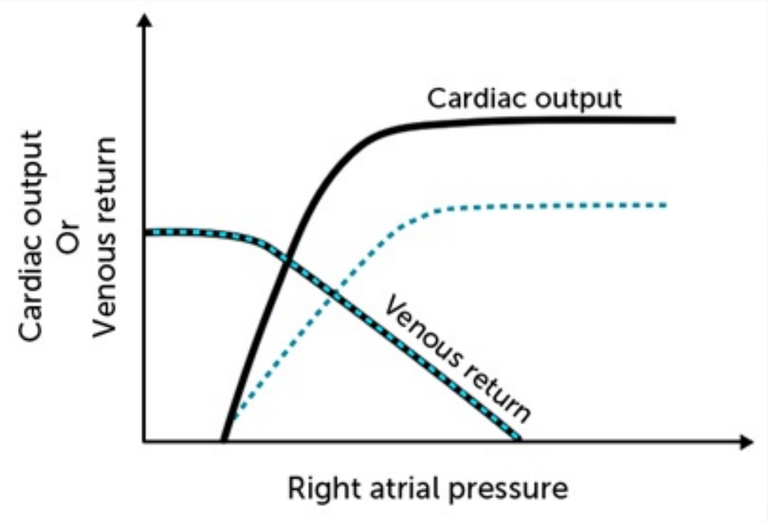

Which of the following is the most likely cause of the change depicted by the dashed lines?

A. Excessive hydration
B. Acute hemorrhage
C. Chronic anemia
D. Myocardial infarction
E. Anaphylaxis

Submit

4
5
6
7
8
9
10
11
12
13
14
15
16
17
18
19
20
21
22
23
24
25
26
27
28
29
30
31
32
33
34

The cardiac output and venous return curves of a healthy person are shown below with solid lines.

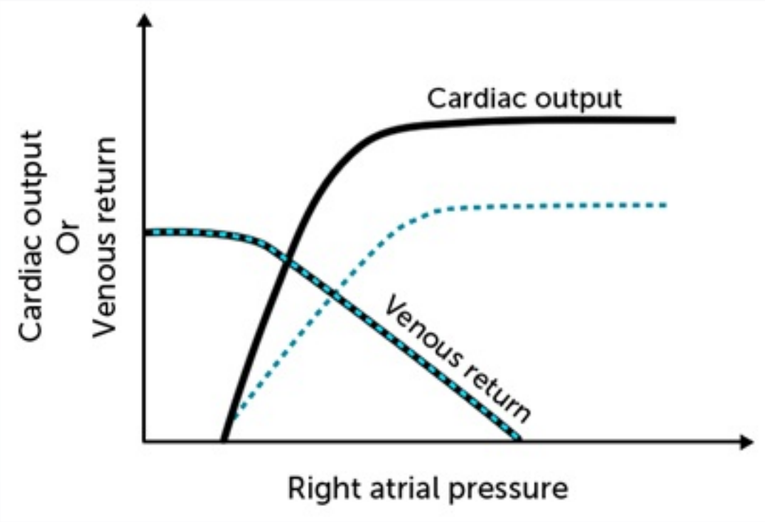

Which of the following is the most likely cause of the change depicted by the dashed lines?

A. Excessive hydration (2%)
B. Acute hemorrhage (13%)
C. Chronic anemia (4%)
✓ D. Myocardial infarction (76%)
E. Anaphylaxis (3%)

Omitted
Correct answer

76%

04 secs

02/03/2020

4
5
6
7
8
9
10
11
12
13
14
15
16
17
18
19
20
21
22
23
24
25
26
27
28
29
30
31
32
33
34

Explanation

The graph above combines cardiac and vascular function curves. The cardiac function curve, labeled as cardiac output, illustrates the Frank-Starling effect. The Frank-Starling effect states that as cardiac muscle is increasingly stretched, the cardiac output increases (up to a limit, as illustrated by the flat portion of the curve). This is essentially the same length-tension relationship that is seen in skeletal muscle.

The venous return curve represents how venous return changes with variations in right atrial pressure. Where the venous return curve intersects with the x-axis, it indicates a venous return of zero. At this point, all circulatory flow ceases, and the pressure throughout the circulatory system equalizes. This average pressure is termed the mean systemic filling pressure, which is a measure of the degree of filling of the circulatory system relative to the circulatory capacity. Increases in blood volume (such as with excessive hydration, dashed line) shift the x-intercept to the right, while decreased blood volume (acute hemorrhage, dashed line) shifts it to the left **(Choices A and B)**. Total peripheral resistance (TPR) affects the slope of both the venous return and cardiac output curves. Increases in the TPR decrease the slope of both curves, as higher vascular resistance restricts venous return and increases afterload.

The dashed lines in the question image depict decreased cardiac output and an unchanged venous return (unchanged blood volume and TPR). An isolated decrease in cardiac output indicates decreased contractility that is not the result of decreased preload (because the venous return line is unchanged). This indicates inhibited contraction either from the action of a negative inotropic drug or an injury to the myocardium, such as a myocardial infarction.

(Choice C) Chronic anemia causes an increase in cardiac output in an effort to meet the metabolic demands of the tissues. This causes an increase in the slope and height of the cardiac output graph. Venous return also increases somewhat due to decreased blood viscosity.

(Choice E) Anaphylaxis causes widespread venous and arteriolar dilation along with increased capillary permeability and third-spacing of fluids. This results in a serious drop in venous return (shifted down and leftward). Cardiac contractility also increase as the body attempts to maintain blood pressure.

Educational objective:
Myocardial infarction causes a sharp decrease in cardiac output due to loss of function of a zone of myocardium. On a cardiac function curve, myocardial infarction would decrease both the slope and the maximal height of the line.

Physiology Cardiovascular System Myocardial infarction

Explanation

Exhibit Display

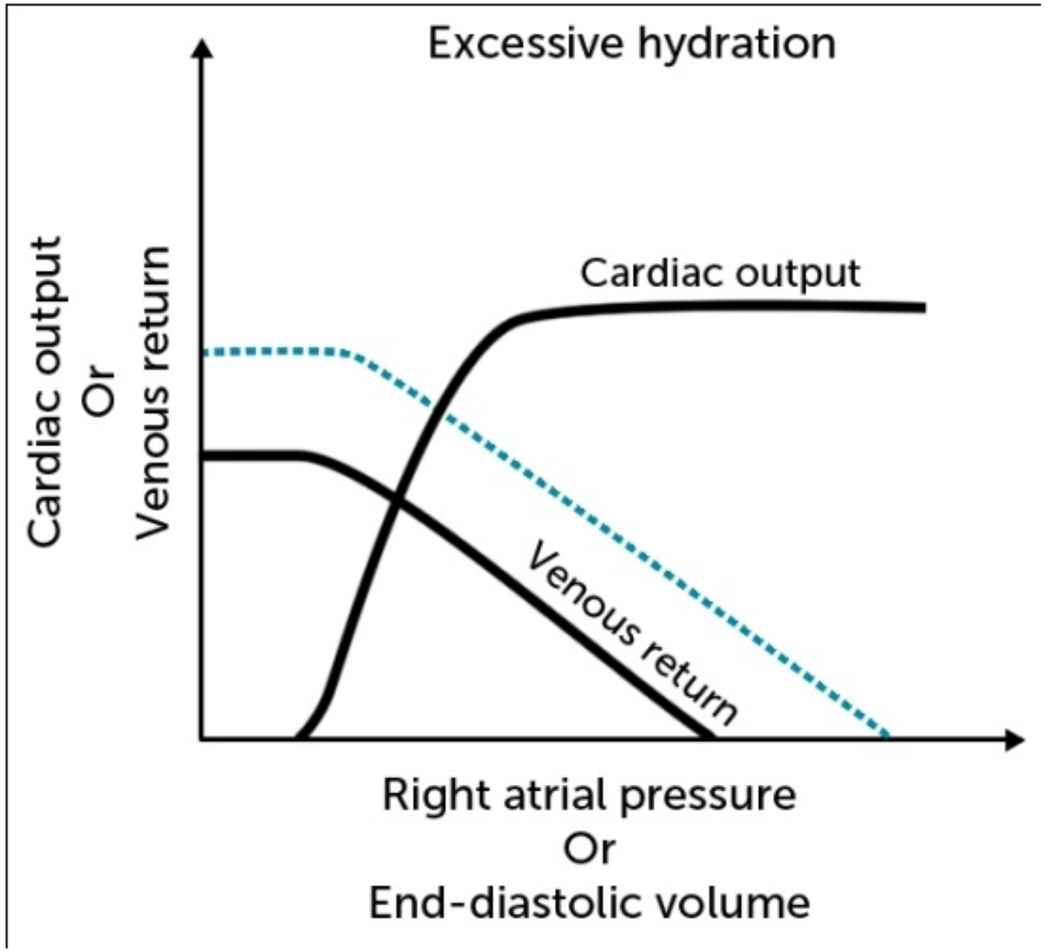

Zoom In | Zoom Out | Reset | Add To New Card | Existing Card

Physiology | Cardiovascular System | Myocardial infarction

Explanation

Exhibit Display

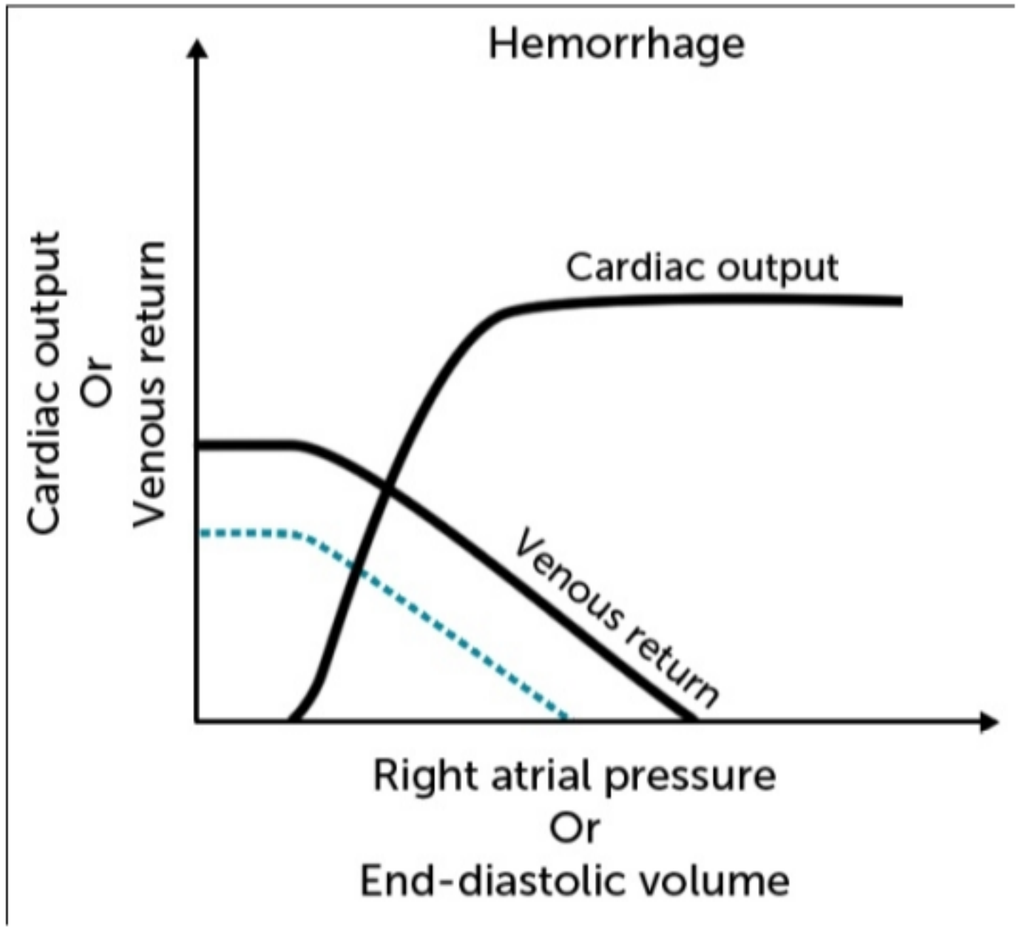

Zoom In | Zoom Out | Reset | Add To New Card | Existing Card

Physiology | Cardiovascular System | Myocardial infarction

Explanation

Exhibit Display

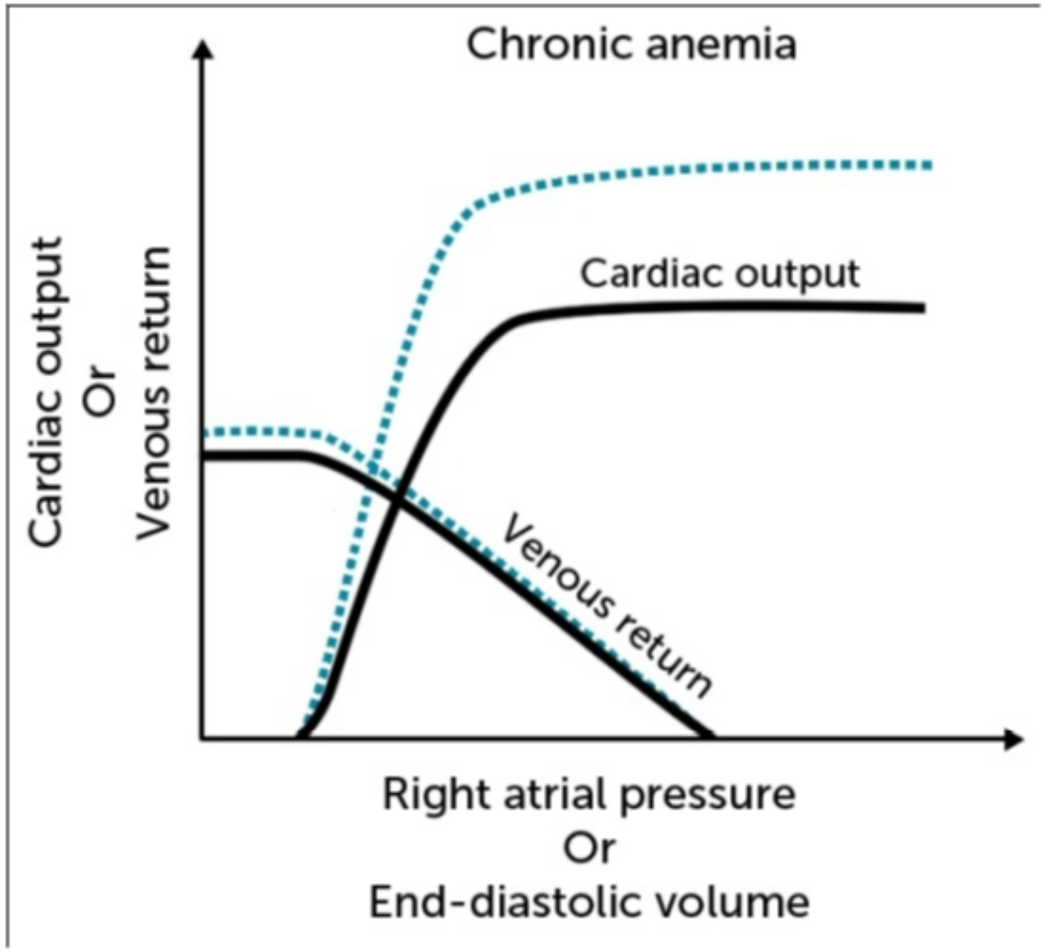

Zoom In Zoom Out Reset Add To New Card | Existing Card

Physiology Cardiovascular System Myocardial infarction

Explanation

Exhibit Display

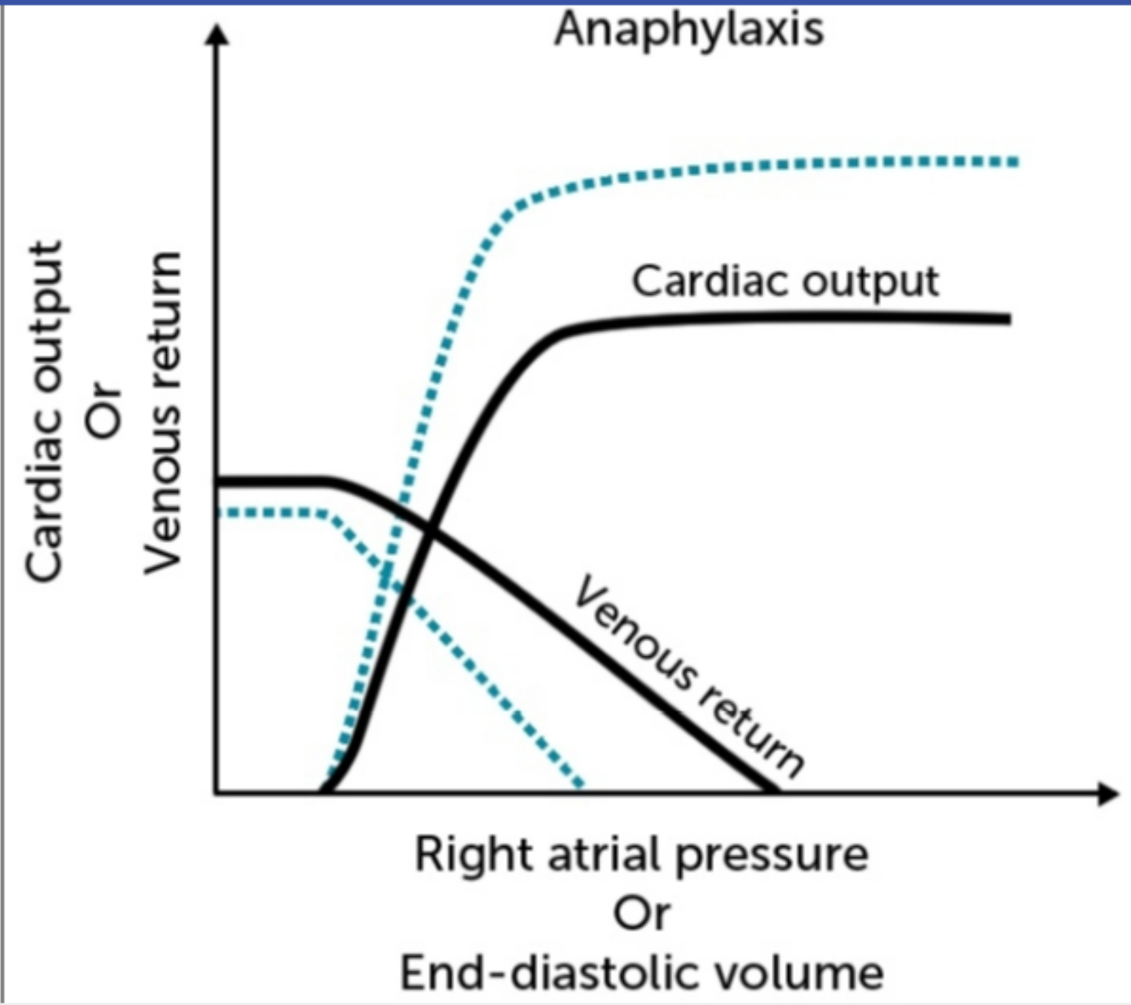

Zoom In | Zoom Out | Reset | Add To New Card | Existing Card

Physiology | Cardiovascular System | Myocardial infarction

4
5
6
7
8
9
10
11
12
13
14
15
16
17
18
19
20
21
22
23
24
25
26
27
28
29
30
31
32
33
34

A 78-year-old man is evaluated for periodic headaches relieved by over-the-counter acetaminophen. He takes no other medications and is a lifelong nonsmoker. The patient's blood pressure is 180/70 mm Hg, and pulse is 75/min and regular. During a prior office visit, his blood pressure was 175/68 mm Hg. Physical examination shows a fourth heart sound but is otherwise unremarkable. CT scan of the head reveals no significant abnormalities. Which of the following age-related changes best explains this patient's blood pressure readings?

A. Aortic stiffening

B. Decrease in cardiac output

C. Decrease in lung residual volume

D. Increase in sympathetic tone

E. Renal artery atherosclerosis

Submit

4
5
6
7
8
9
10
11
12
13
14
15
16
17
18
19
20
21
22
23
24
25
26
27
28
29
30
31
32
33
34

A 78-year-old man is evaluated for periodic headaches relieved by over-the-counter acetaminophen. He takes no other medications and is a lifelong nonsmoker. The patient's blood pressure is 180/70 mm Hg, and pulse is 75/min and regular. During a prior office visit, his blood pressure was 175/68 mm Hg. Physical examination shows a fourth heart sound but is otherwise unremarkable. CT scan of the head reveals no significant abnormalities. Which of the following age-related changes best explains this patient's blood pressure readings?

- ✓ A. Aortic stiffening (71%)
- B. Decrease in cardiac output (6%)
- C. Decrease in lung residual volume (0%)
- D. Increase in sympathetic tone (4%)
- E. Renal artery atherosclerosis (17%)

Omitted
Correct answer
A

71%
Answered correctly

02 secs
Time Spent

03/23/2020
Last Updated

Explanation

The patient's blood pressure readings show a pattern of elevated systolic blood pressure (SBP) with normal (<90 mm Hg) diastolic blood pressure (DBP), consistent with **isolated systolic hypertension** (ISH). ISH is often seen in patients age >60, and is responsible for 60%-80% of hypertension cases in this population. SBP of >140 mm Hg is typically considered an important modifiable risk factor for stroke and heart disease.

Aging is associated with **increased arterial stiffness** caused by endothelial dysfunction and a change in extracellular matrix composition (eg, decreased elastin, increased collagen deposition). Increased arterial stiffness leads to decreased compliance of the aorta and major peripheral arteries, causing elevated pressures during systole. ISH can also result from an increase in cardiac output due to severe aortic regurgitation or

4
5
6
7
8
9
10
11
12
13
14
15
16
17
18
19
20
21
22
23
24
25
26
27
28
29
30
31
32
33
34

The patient's blood pressure readings show a pattern of elevated systolic blood pressure (SBP) with normal (<90 mm Hg) diastolic blood pressure (DBP), consistent with **isolated systolic hypertension** (ISH). ISH is often seen in patients age >60, and is responsible for 60%-80% of hypertension cases in this population. SBP of >140 mm Hg is typically considered an important modifiable risk factor for stroke and heart disease.

Aging is associated with **increased arterial stiffness** caused by endothelial dysfunction and a change in extracellular matrix composition (eg, decreased elastin, increased collagen deposition). Increased arterial stiffness leads to decreased compliance of the aorta and major peripheral arteries, causing elevated pressures during systole. ISH can also result from an increase in cardiac output due to severe aortic regurgitation or systemic causes (eg, anemia, hyperthyroidism).

(Choice B) A primary decrease in cardiac output would lower systolic, diastolic, and mean arterial blood pressures. In the setting of low cardiac output, arterial vasoconstriction and renal fluid retention help maintain arterial blood pressure; however, this compensatory response would not result in hypertension.

(Choice C) A decrease in pulmonary residual volume occurs with age due to destruction of alveolar walls, which may be associated with a minor increase in pulmonary vascular resistance. However, this would not have a significant effect on arterial pressures in the systemic circulation.

(Choice D) An increase in sympathetic tone leads to an increase in peripheral vascular resistance and would be expected to increase SBP and DBP. This plays an important role in the pathogenesis of hypertension in patients age <50; however, this is not the major cause of ISH in individuals age >60.

(Choice E) Renal artery atherosclerosis and renal artery stenosis, in particular, can result in renovascular hypertension due to excess activation of the renin-angiotensin-aldosterone system. The resultant hypervolemia and increased total peripheral vascular resistance would elevate both SBP and DBP.

Educational objective:
Isolated systolic hypertension (systolic blood pressure >140 mm Hg with diastolic blood pressure <90 mm Hg) is due to age-related stiffness and decrease in compliance of the aorta and major peripheral arteries.

Physiology	Cardiovascular System	Primary hypertension
Subject	System	Topic

4
5
6
7
8
9
10
11
12
13
14
15
16
17
18
19
20
21
22
23
24
25
26
27
28
29
30
31
32
33
34

A 63-year-old man with long-standing hypertension has undergone multiple changes in his antihypertensive regimen over the years with only minimal improvement in his blood pressure. A CT study of his thoracolumbar spine is performed for evaluation of chronic back pain, and the study incidentally reveals a small right kidney. Angiography demonstrates atherosclerotic narrowing of the right renal artery. The left renal artery is intact. You conclude that the flow in the right-sided artery is decreased by a factor of 16 compared to the left. By what percentage has the radius of the lumen been reduced?

- A. 25%
- B. 33%
- C. 50%
- D. 75%
- E. 90%

Submit

4
5
6
7
8
9
10
11
12
13
14
15
16
17
18
19
20
21
22
23
24
25
26
27
28
29
30
31
32
33
34

A 63-year-old man with long-standing hypertension has undergone multiple changes in his antihypertensive regimen over the years with only minimal improvement in his blood pressure. A CT study of his thoracolumbar spine is performed for evaluation of chronic back pain, and the study incidentally reveals a small right kidney. Angiography demonstrates atherosclerotic narrowing of the right renal artery. The left renal artery is intact. You conclude that the flow in the right-sided artery is decreased by a factor of 16 compared to the left. By what percentage has the radius of the lumen been reduced?

A. 25% (26%)
B. 33% (3%)
✓ C. 50% (46%)
D. 75% (17%)
E. 90% (5%)

Omitted
Correct answer
C

46%
Answered correctly

02 secs
Time Spent

06/21/2020
Last Updated

Explanation

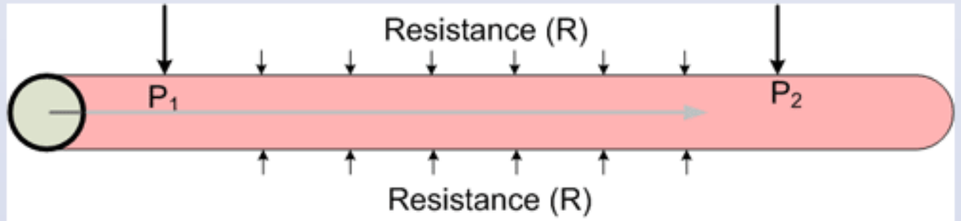

4
5
6
7
8
9
10
11
12
13
14
15
16
17
18
19
20
21
22
23
24
25
26
27
28
29
30
31
32
33
34

Explanation

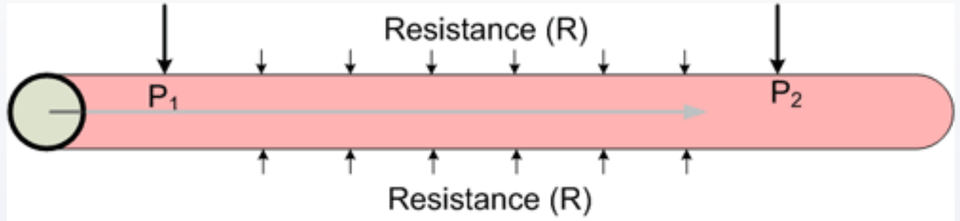

$$\text{Flow (Q)} = \frac{P_1 - P_2}{R}$$

The flow of blood through a vessel can be calculated by dividing the pressure gradient between two points in the vessel by the resistance to flow in that vessel. The resistance in a blood vessel can be calculated using Poiseuille's equation as follows:

Resistance (R) = $\eta L / r^4$

η = viscosity of blood
L = length of the blood vessel
r = radius of the blood vessel (note: raised to the 4th power)

Combining these equations illustrates the profound effect that a small change in blood vessel radius can have on the flow through a vessel. This is due to the fact that the resistance to flow in a blood vessel is inversely proportional to the radius raised to the fourth power.

$$\text{Flow (Q)} = \frac{P_1 - P_2}{\eta L} \times r^4$$

In the patient described above, flow through the right renal artery has been decreased by a factor of 16 compared to the left renal artery. It can be assumed that the pressure gradient, blood viscosity, and blood vessel lengths are equivalent bilaterally, leaving the blood vessel radius as the only variable. Using the above equation, it can be determined that decreasing the radius by a factor of 2 decreases the flow by a factor of 16.

FLOW = $(P_1 - P_2) / \eta L * r^4$ = CONSTANT * r^4, which can be simplified to:

4 5 6 7 8 9 10 11 12 13 14 15 16 17 18 19 20 21 22 23 24 25 26 27 28 29 30 31 32 33 34

The flow of blood through a vessel can be calculated by dividing the pressure gradient between two points in the vessel by the resistance to flow in that vessel. The resistance in a blood vessel can be calculated using Poiseuille's equation as follows:

Resistance (R) = $\eta L / r^4$

η = viscosity of blood
L = length of the blood vessel
r = radius of the blood vessel (note: raised to the 4th power)

Combining these equations illustrates the profound effect that a small change in blood vessel radius can have on the flow through a vessel. This is due to the fact that the resistance to flow in a blood vessel is inversely proportional to the radius raised to the fourth power.

$$\text{Flow (Q)} = \frac{P_1 - P_2}{\eta L} \times r^4$$

In the patient described above, flow through the right renal artery has been decreased by a factor of 16 compared to the left renal artery. It can be assumed that the pressure gradient, blood viscosity, and blood vessel lengths are equivalent bilaterally, leaving the blood vessel radius as the only variable. Using the above equation, it can be determined that decreasing the radius by a factor of 2 decreases the flow by a factor of 16.

FLOW = $(P_1 - P_2) / \eta L * r^4$ = CONSTANT * r^4, which can be simplified to:
FLOW = r^4, and:
(FLOW / 16) = $(r^4 / 16) = (r/2)^4$

Thus, when flow is reduced by a factor of 16, the radius of the lumen is decreased to r/2 (50% of the original radius).

Educational objective:
Blood flow is directly proportional to the vessel radius raised to the fourth power. Resistance to blood flow is inversely proportional to the vessel radius raised to the fourth power.

Physiology	Cardiovascular System	Renal artery stenosis
Subject	System	Topic

that vessel. The resistance in a blood vessel can be calculated using Poiseuille's equation as follows:

Resistance (R) = $\eta L / r^4$

η = viscosity of blood
L = length of the blood vessel
r = radius of the blood vessel (note: raised to the 4th power)

Combining these equations illustrates the profound effect that a small change in blood vessel radius can have on the flow through a vessel. This is due to the fact that the resistance to flow in a blood vessel is inversely proportional to the radius raised to the fourth power.

$$\text{Flow (Q)} = \frac{P_1 - P_2}{\eta L} \times r^4$$

In the patient described above, flow through the right renal artery has been decreased by a factor of 16 compared to the left renal artery. It can be assumed that the pressure gradient, blood viscosity, and blood vessel lengths are equivalent bilaterally, leaving the blood vessel radius as the only variable. Using the above equation, it can be determined that decreasing the radius by a factor of 2 decreases the flow by a factor of 16.

FLOW = $(P_1 - P_2) / \eta L * r^4$ = CONSTANT * r^4, which can be simplified to:
FLOW = r^4, and:
(FLOW / 16) = $(r^4 / 16) = (r/2)^4$

Thus, when flow is reduced by a factor of 16, the radius of the lumen is decreased to r/2 (50% of the original radius).

Educational objective:
Blood flow is directly proportional to the vessel radius raised to the fourth power. Resistance to blood flow is inversely proportional to the vessel radius raised to the fourth power.

Physiology	Cardiovascular System	Renal artery stenosis
Subject	System	Topic

Copyright © UWorld. All rights reserved.

4
5
6
7
8
9
10
11
12
13
14
15
16
17
18
19
20
21
22
23
24
25
26
27
28
29
30
31
32
33
34

A 65-year-old man reports multiple episodes of lightheadedness while buttoning a tight shirt collar. During 2 episodes, he passed out briefly but sustained no injuries. His blood pressure was 70/40 mm Hg and pulse was 45/min during one of the episodes. Past medical history is significant for hypertension and diet-controlled diabetes mellitus. The patient is a lifetime nonsmoker and drinks alcohol on social occasions. On physical examination, his blood pressure is 125/72 mm Hg and pulse is 76/min without orthostatic changes. Stimulation of afferent sensory fibers in which of the following nerves is most likely responsible for this patient's symptoms?

A. Accessory
B. Glossopharyngeal
C. Hypoglossal
D. Trigeminal
E. Vagus

Submit

4
5
6
7
8
9
10
11
12
13
14
15
16
17
18
19
20
21
22
23
24
25
26
27
28
29
30
31
32
33
34

A 65-year-old man reports multiple episodes of lightheadedness while buttoning a tight shirt collar. During 2 episodes, he passed out briefly but sustained no injuries. His blood pressure was 70/40 mm Hg and pulse was 45/min during one of the episodes. Past medical history is significant for hypertension and diet-controlled diabetes mellitus. The patient is a lifetime nonsmoker and drinks alcohol on social occasions. On physical examination, his blood pressure is 125/72 mm Hg and pulse is 76/min without orthostatic changes. Stimulation of afferent sensory fibers in which of the following nerves is most likely responsible for this patient's symptoms?

- A. Accessory (0%)
- ✓ B. Glossopharyngeal (52%)
- C. Hypoglossal (1%)
- D. Trigeminal (0%)
- E. Vagus (45%)

Omitted
Correct answer
B

52%
Answered correctly

02 secs
Time Spent

01/16/2020
Last Updated

Explanation

The patient's history is suggestive of **carotid sinus hypersensitivity**, triggered by pressure on the carotid sinus by a tight shirt collar. The carotid sinus baroreceptors are important in blood pressure control and use arterial wall stretch as an indicator of systemic blood pressure.

The carotid sinus is a dilation of the internal carotid artery located just above the bifurcation of the common carotid artery. The carotid sinus reflex has an **afferent limb** that arises from the baroreceptors in the carotid sinus and travels to the medullary centers via the Hering nerve, a branch of

4
5
6
7
8
9
10
11
12
13
14
15
16
17
18
19
20
21
22
23
24
25
26
27
28
29
30
31
32
33
34

Baroreceptors & peripheral chemoreceptors

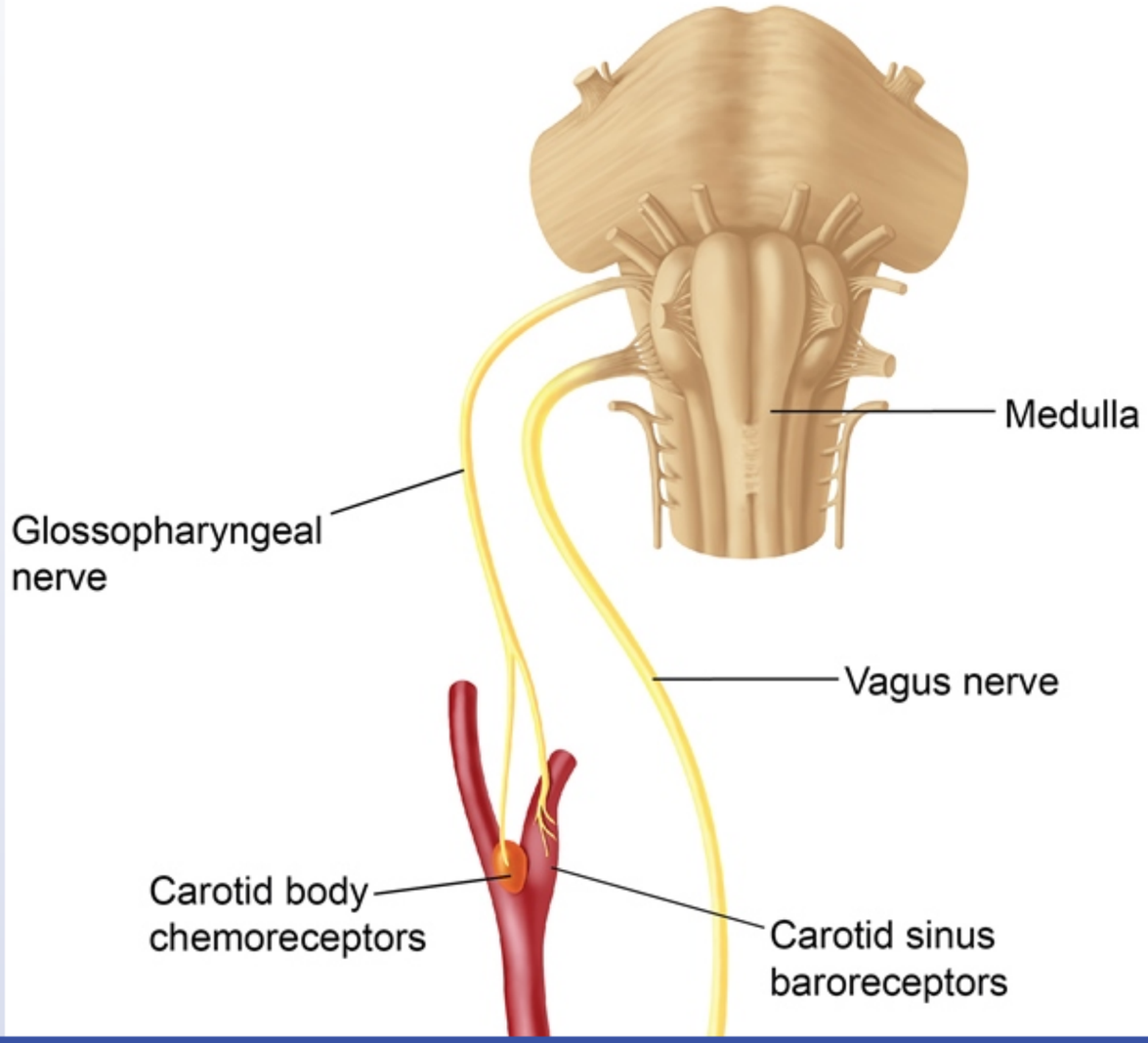

4
5
6
7
8
9
10
11
12
13
14
15
16
17
18
19
20
21
22
23
24
25
26
27
28
29
30
31
32
33
34

Exhibit Display

Baroreceptors & peripheral chemoreceptors

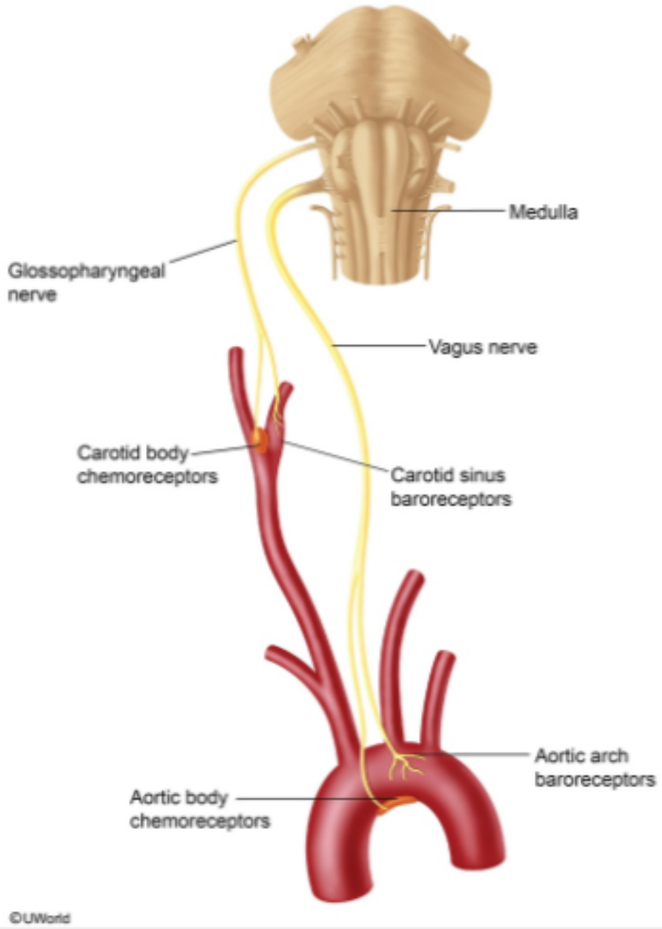

Zoom In | Zoom Out | Reset | Add To New Card | Existing Card

4
5
6
7
8
9
10
11
12
13
14
15
16
17
18
19
20
21
22
23
24
25
26
27
28
29
30
31
32
33
34

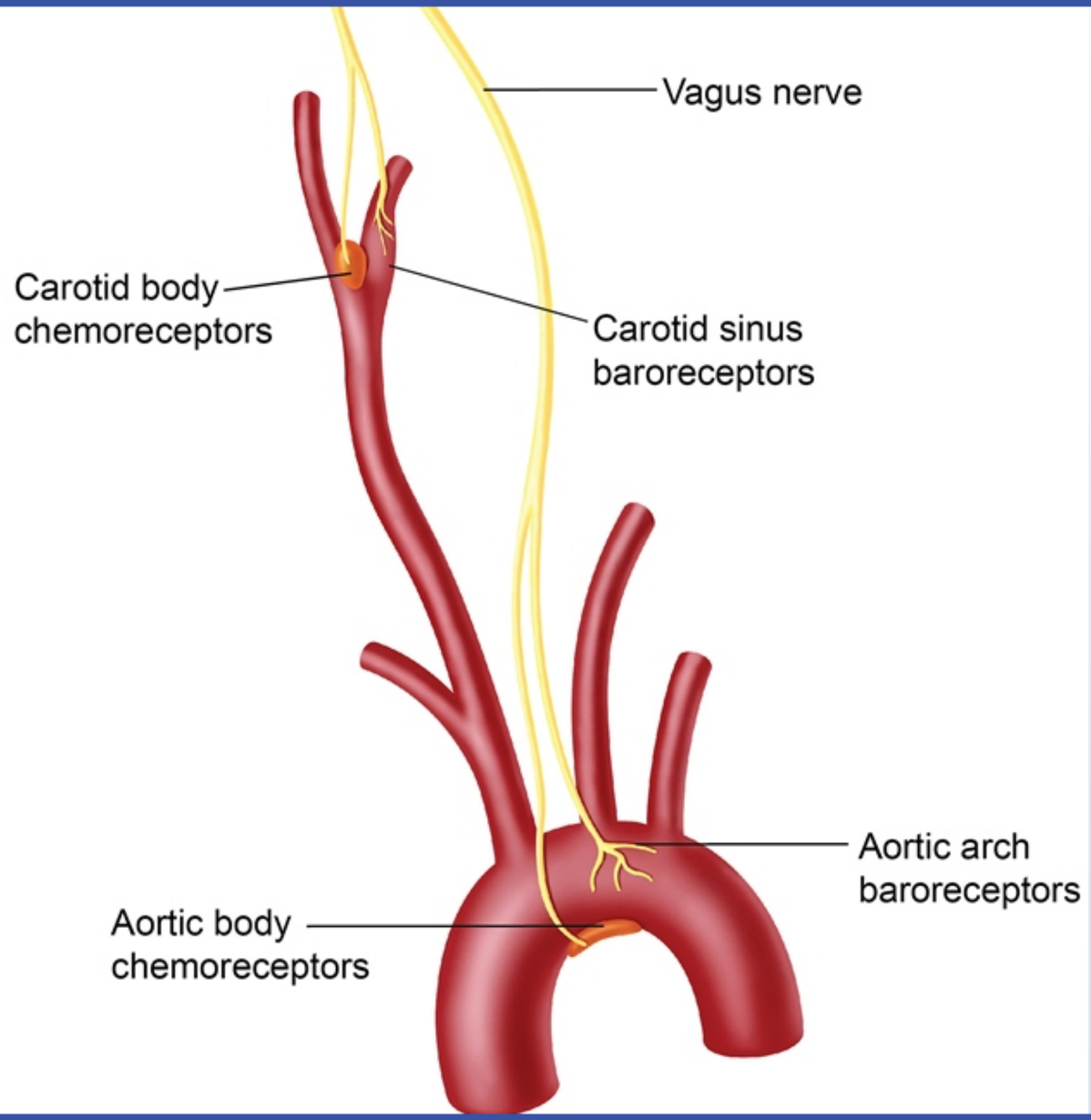

©UWorld

The patient's history is suggestive of **carotid sinus hypersensitivity**, triggered by pressure on the carotid sinus by a tight shirt collar. The carotid sinus baroreceptors are important in blood pressure control and use arterial wall stretch as an indicator of systemic blood pressure.

The carotid sinus is a dilation of the internal carotid artery located just above the bifurcation of the common carotid artery. The carotid sinus reflex has an **afferent limb** that arises from the baroreceptors in the carotid sinus and travels to the medullary centers via the Hering nerve, a branch of the **glossopharyngeal nerve** (CN IX). The **efferent limb** of the carotid sinus carries parasympathetic impulses via the **vagus nerve** (CN X). Carotid sinus pressure or massage stimulates the baroreceptors and increases the firing rate from the carotid sinus, leading to an increase in parasympathetic output and withdrawal of sympathetic output to the heart and peripheral vasculature. The result is decreased blood pressure (via peripheral vasodilation) and decreased cardiac output (decreased contractility/stroke volume and heart rate). In sensitive individuals, this response can cause severe bradycardia, hypotension, and sometimes syncope.

(Choices A, C, and D) The accessory (CN XI), hypoglossal (CN XII), and trigeminal (CN V) nerves do not transmit baroreceptor signals. The accessory nerve controls the sternocleidomastoid and trapezius muscles, the hypoglossal nerve primarily controls the muscles of the tongue, and the trigeminal nerve mediates facial sensation and also controls the muscles of mastication (chewing).

(Choice E) The vagus nerve (CN X) acts as the afferent limb for the nerve fibers originating from the aortic arch baroreceptors and as an efferent limb for the carotid sinus reflex. However, a tight collar would stimulate carotid sinus (not aortic arch) baroreceptor afferents carried by the glossopharyngeal nerve.

Educational objective:
The carotid sinus is a dilation of the internal carotid artery located just above the bifurcation of the common carotid artery. The carotid sinus reflex has an afferent limb that arises from the baroreceptors in the carotid sinus and travels to the vagal nucleus and medullary centers via the glossopharyngeal nerve (CN IX); the efferent limb carries parasympathetic impulses via the vagus nerve (CN X).

Physiology	Cardiovascular System	Carotid sinus hypersensitivity
Subject	System	Topic

Copyright © UWorld. All rights reserved.

4
5
6
7
8
9
10
11
12
13
14
15
16
17
18
19
20
21
22
23
24
25
26
27
28
29
30
31
32
33
34

A 46-year-old man comes to the office for an annual examination. He has an uncomfortable heartbeat sensation at night that he tries to decrease by sleeping on his right side. The patient has had mild shortness of breath with exertion over the last 6 months, but he has no chest pain. He was told during a wellness check approximately 2 years ago that he had a heart murmur. The patient has no other medical problems. Physical examination reveals bounding femoral pulses and carotid pulsations that are accompanied by head bobbing. Which of the following is the most likely diagnosis?

- A. Aortic regurgitation
- B. Aortic stenosis
- C. Atrial septal defect
- D. Coarctation of the aorta
- E. Mitral regurgitation
- F. Mitral stenosis
- G. Pulmonary stenosis
- H. Tricuspid regurgitation

Submit

4
5
6
7
8
9
10
11
12
13
14
15
16
17
18
19
20
21
22
23
24
25
26
27
28
29
30
31
32
33
34

A 46-year-old man comes to the office for an annual examination. He has an uncomfortable heartbeat sensation at night that he tries to decrease by sleeping on his right side. The patient has had mild shortness of breath with exertion over the last 6 months, but he has no chest pain. He was told during a wellness check approximately 2 years ago that he had a heart murmur. The patient has no other medical problems. Physical examination reveals bounding femoral pulses and carotid pulsations that are accompanied by head bobbing. Which of the following is the most likely diagnosis?

- ✓ A. Aortic regurgitation (75%)
- B. Aortic stenosis (12%)
- C. Atrial septal defect (0%)
- D. Coarctation of the aorta (5%)
- E. Mitral regurgitation (2%)
- F. Mitral stenosis (0%)
- G. Pulmonary stenosis (0%)
- H. Tricuspid regurgitation (1%)

Omitted
Correct answer
A

75%
Answered correctly

02 secs
Time Spent

03/10/2020
Last Updated

Explanation

This presentation is most suggestive of **aortic regurgitation**. The inability of aortic valve leaflets to effectively close during diastole leads to

4
5
6
7
8
9
10
11
12
13
14
15
16
17
18
19
20
21
22
23
24
25
26
27
28
29
30
31
32
33
34

This presentation is most suggestive of **aortic regurgitation**. The inability of aortic valve leaflets to effectively close during diastole leads to regurgitation of blood back into the left ventricular (LV) cavity with an increase in LV end-diastolic volume and wall stress. The resultant chamber enlargement and eccentric hypertrophy increase total stroke volume, which is often felt as a sense of pounding or an uncomfortable feeling of heartbeat (especially when lying on the left side).

Physical examination reveals an early "blowing" **diastolic decrescendo murmur** best heard at the left sternal border in the third or fourth intercostal space. The precordial impulse is hyperdynamic and displaced laterally and downward. **Bounding femoral and carotid pulses**, marked by abrupt distension and quick collapse ("water-hammer" pulses), are the result of the wide pulse pressure. Some patients exhibit **head bobbing** with carotid pulsations (de Musset sign) due to transfer of momentum from the large LV stroke volume to the head and neck. Significant systolic pulsations may also be noticed in other organs (eg, liver, spleen, retina) and the fingertips.

(Choice B) Patients with severe aortic stenosis have a characteristic arterial pulse – small pulse amplitude (pulsus parvus) with a delayed peak and slower upstroke of the arterial pulse (pulsus tardus) due to diminished stroke volume and prolonged ejection time.

(Choice C) The presence of atrial septal defect leads to left-to-right intracardiac shunting, which can cause a hyperdynamic right ventricular impulse. It does not cause any significant change in arterial pulse character.

(Choice D) Coarctation of the aorta causes systolic hypertension in the upper extremities along with characteristic diminished and/or delayed femoral pulses (brachial-femoral delay).

(Choice E) Arterial pulse, pulse pressure, and forward stroke volume remain normal in patients with chronic (compensated) mitral regurgitation.

(Choice F) Arterial pulses are reduced in volume and amplitude in patients with mitral stenosis due to decreased LV end-diastolic volume and stroke volume.

(Choices G and H) Tricuspid regurgitation and/or pulmonary stenosis are right-sided valvular lesions and do not cause any specific arterial pulse pattern on physical examination.

Educational objective:
Aortic regurgitation causes an increase in total stroke volume with abrupt distension and rapid falloff of peripheral arterial pulses, resulting in a wide pulse pressure. This leads to bounding peripheral pulses and head bobbing with each heartbeat.

4
5
6
7
8
9
10
11
12
13
14
15
16
17
18
19
20
21
22
23
24
25
26
27
28
29
30
31
32
33
34

regurgitation of blood back into the left ventricular (LV) cavity with an increase in LV end-diastolic volume and wall stress. The resultant chamber enlargement and eccentric hypertrophy increase total stroke volume, which is often felt as a sense of pounding or an uncomfortable feeling of heartbeat (especially when lying on the left side).

Physical examination reveals an early "blowing" **diastolic decrescendo murmur** best heard at the left sternal border in the third or fourth intercostal space. The precordial impulse is hyperdynamic and displaced laterally and downward. **Bounding femoral and carotid pulses**, marked by abrupt distension and quick collapse ("water-hammer" pulses), are the result of the wide pulse pressure. Some patients exhibit **head bobbing** with carotid pulsations (de Musset sign) due to transfer of momentum from the large LV stroke volume to the head and neck. Significant systolic pulsations may also be noticed in other organs (eg, liver, spleen, retina) and the fingertips.

(Choice B) Patients with severe aortic stenosis have a characteristic arterial pulse – small pulse amplitude (pulsus parvus) with a delayed peak and slower upstroke of the arterial pulse (pulsus tardus) due to diminished stroke volume and prolonged ejection time.

(Choice C) The presence of atrial septal defect leads to left-to-right intracardiac shunting, which can cause a hyperdynamic right ventricular impulse. It does not cause any significant change in arterial pulse character.

(Choice D) Coarctation of the aorta causes systolic hypertension in the upper extremities along with characteristic diminished and/or delayed femoral pulses (brachial-femoral delay).

(Choice E) Arterial pulse, pulse pressure, and forward stroke volume remain normal in patients with chronic (compensated) mitral regurgitation.

(Choice F) Arterial pulses are reduced in volume and amplitude in patients with mitral stenosis due to decreased LV end-diastolic volume and stroke volume.

(Choices G and H) Tricuspid regurgitation and/or pulmonary stenosis are right-sided valvular lesions and do not cause any specific arterial pulse pattern on physical examination.

Educational objective:
Aortic regurgitation causes an increase in total stroke volume with abrupt distension and rapid falloff of peripheral arterial pulses, resulting in a wide pulse pressure. This leads to bounding peripheral pulses and head bobbing with each heartbeat.

References

- Valvular heart disease: aortic regurgitation.

4
5
6
7
8
9
10
11
12
13
14
15
16
17
18
19
20
21
22
23
24
25
26
27
28
29
30
31
32
33
34

A 34-year-old woman comes to the office due to exertional dyspnea. The patient has a history of IgA nephropathy; she received hemodialysis for 2 years before undergoing kidney transplantation last month. Chest x-ray reveals cardiomegaly and pulmonary congestion. Further evaluation determines that her symptoms are likely due to persistence of the arteriovenous fistula that was used for hemodialysis. Which of the following physiologic changes are most likely present in this patient due to the fistula?

	Cardiac output	Systemic vascular resistance	Venous return
A.	↓	↑	↓
B.	↓	↑	↑
C.	↑	↓	↓
D.	↑	↓	↑
E.	↑	↑	↑

Submit

4
5
6
7
8
9
10
11
12
13
14
15
16
17
18
19
20
21
22
23
24
25
26
27
28
29
30
31
32
33
34

A 34-year-old woman comes to the office due to exertional dyspnea. The patient has a history of IgA nephropathy; she received hemodialysis for 2 years before undergoing kidney transplantation last month. Chest x-ray reveals cardiomegaly and pulmonary congestion. Further evaluation determines that her symptoms are likely due to persistence of the arteriovenous fistula that was used for hemodialysis. Which of the following physiologic changes are most likely present in this patient due to the fistula?

	Cardiac output	Systemic vascular resistance	Venous return
A. (11%)	↓	↑	↓
B. (11%)	↓	↑	↑
C. (7%)	↑	↓	↓
✓ D. (57%)	↑	↓	↑
E. (12%)	↑	↑	↑

Omitted
Correct answer
D

57%
Answered correctly

01 sec
Time Spent

06/24/2020
Last Updated

Explanation

4
5
6
7
8
9
10
11
12
13
14
15
16
17
18
19
20
21
22
23
24
25
26
27
28
29
30
31
32
33
34

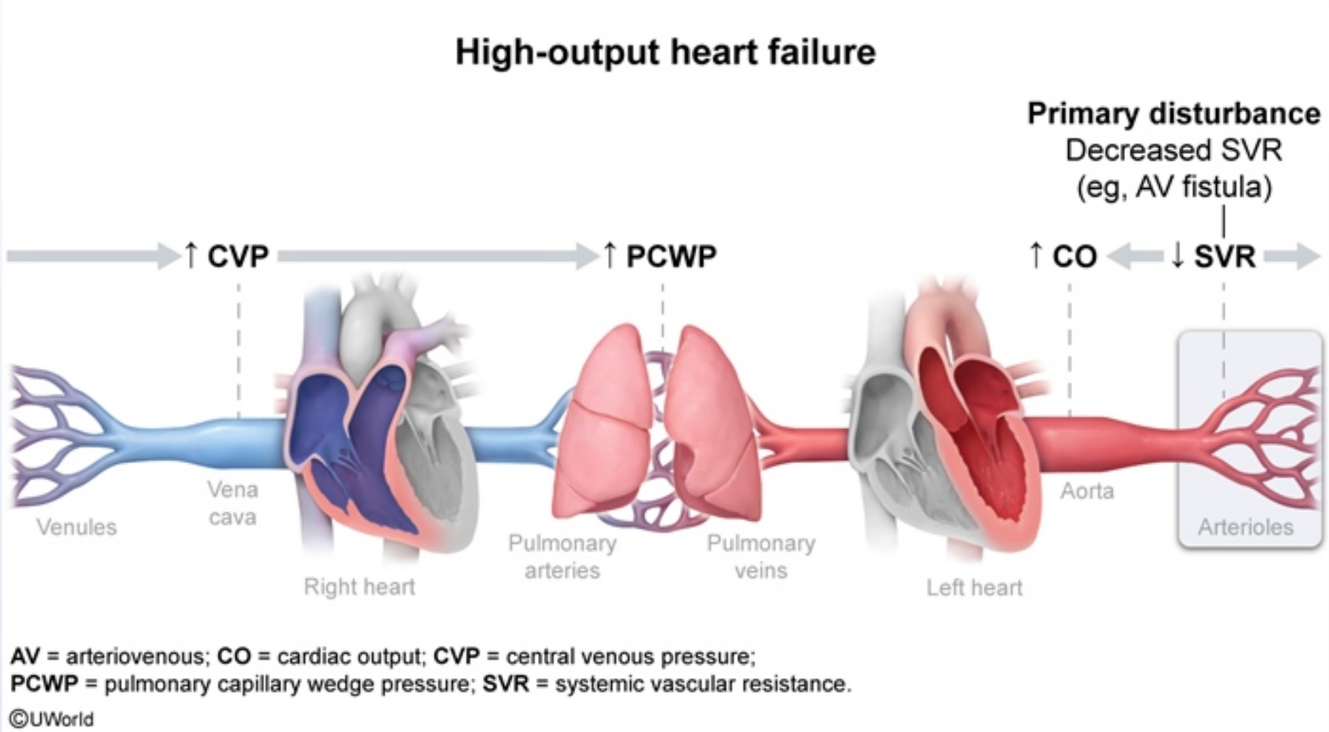

This patient with dyspnea and chest x-ray showing an enlarged heart and pulmonary edema likely has **high-output heart failure** due to excessive flow through her **arteriovenous fistula**. A surgically created arteriovenous fistula forms an enlarged vein that serves as an access point for hemodialysis (which requires a vessel with high blood flow rates); however, if the fistula becomes too large, it can lead to hemodynamic complications.

A large arteriovenous fistula allows a high proportion of blood flow to bypass the resistance of the systemic arterioles, causing markedly **decreased systemic vascular resistance** (SVR) (ie, reduced afterload). Blood passing through the low peripheral resistance returns to the right atrium quickly and easily, resulting in **increased venous return** (ie, increased preload). Both the reduced afterload and increased preload facilitate increased stroke volume (ie, **increased cardiac output**). A baroreceptor reflex-mediated increase in contractility and heart rate in response to hypotension may also contribute to increased cardiac output.

4
5
6
7
8
9
10
11
12
13
14
15
16
17
18
19
20
21
22
23
24
25
26
27
28
29
30
31
32
33
34

This patient with dyspnea and chest x-ray showing an enlarged heart and pulmonary edema likely has **high-output heart failure** due to excessive flow through her **arteriovenous fistula**. A surgically created arteriovenous fistula forms an enlarged vein that serves as an access point for hemodialysis (which requires a vessel with high blood flow rates); however, if the fistula becomes too large, it can lead to hemodynamic complications.

A large arteriovenous fistula allows a high proportion of blood flow to bypass the resistance of the systemic arterioles, causing markedly **decreased systemic vascular resistance** (SVR) (ie, reduced afterload). Blood passing through the low peripheral resistance returns to the right atrium quickly and easily, resulting in **increased venous return** (ie, increased preload). Both the reduced afterload and increased preload facilitate increased stroke volume (ie, **increased cardiac output**). A baroreceptor reflex-mediated increase in contractility and heart rate in response to hypotension may also contribute to increased cardiac output.

With excessively large fistulas, the left ventricle becomes unable to keep up with the increased venous return despite a persistent increase in cardiac output; left ventricular diastolic pressure gradually increases, and decompensated heart failure develops. Other common causes of high-output heart failure also involve decreased SVR as the initial disturbance.

(Choice A) Hypovolemia (eg, severe dehydration) involves a marked reduction in blood volume. Venous return is decreased, leading to reduced cardiac output and a compensatory increase in SVR.

(Choice B) Low-output heart failure (the typical cause of cardiogenic shock) involves left ventricular dysfunction as the initial disturbance, which leads to decreased cardiac output and a compensatory increase in SVR. Increased pressure is transmitted backward from the left ventricle, causing elevated central venous pressure (ie, increased venous return [preload]).

(Choice C) The pathophysiology of sepsis is similar to high-output heart failure in that reduced SVR is the initial disturbance and is followed by a compensatory increase in cardiac output. However, in sepsis the leaky vasculature reduces intravascular volume to decrease venous return, preventing volume overload of the left ventricle.

(Choice E) Stimulation of both alpha-1 and beta-1 adrenergic receptors (eg, with norepinephrine) causes arteriolar constriction to increase SVR, venoconstriction to increase venous return, and increased heart rate and contractility to increase cardiac output.

Educational objective:
High-output heart failure results from markedly decreased systemic vascular resistance (eg, large arteriovenous fistula) that leads to increased

4
5
6
7
8
9
10
11
12
13
14
15
16
17
18
19
20
21
22
23
24
25
26
27
28
29
30
31
32
33
34

This patient with dyspnea and chest x-ray showing an enlarged heart and pulmonary edema likely has **high-output heart failure** due to excessive

Exhibit Display

©UWorld

Zoom In | Zoom Out | Reset | Add To New Card | Existing Card

High-output heart failure results from markedly decreased systemic vascular resistance (eg, large arteriovenous fistula) that leads to increased

4
5
6
7
8
9
10
11
12
13
14
15
16
17
18
19
20
21
22
23
24
25
26
27
28
29
30
31
32
33
34

This patient with dyspnea and chest x-ray showing an enlarged heart and pulmonary edema likely has **high-output heart failure** due to excessive

Exhibit Display

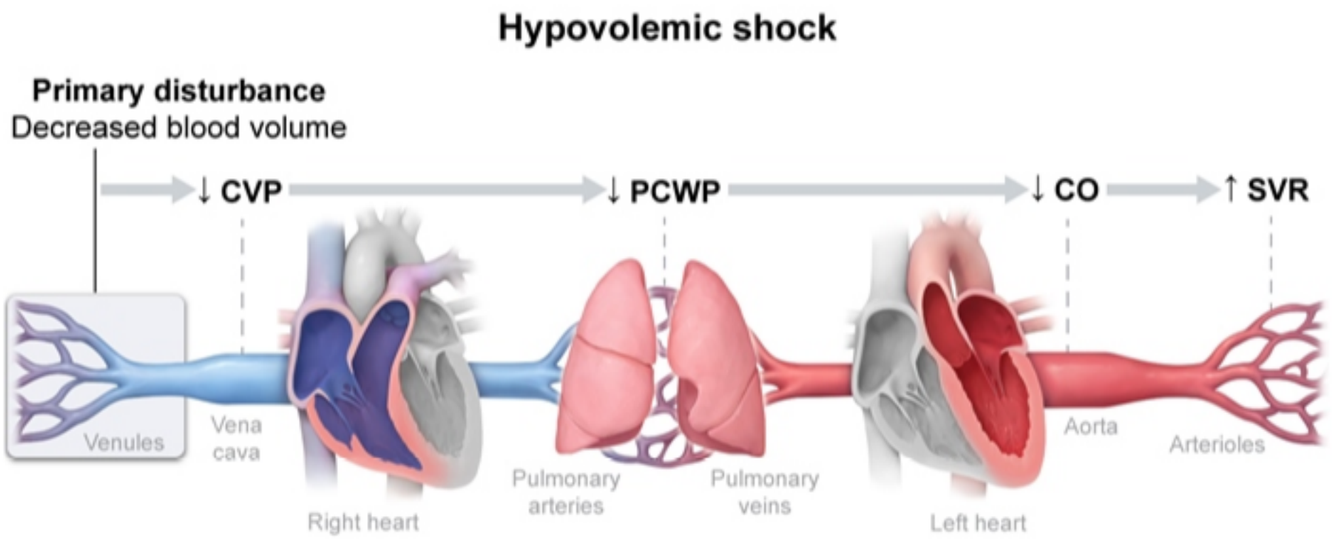

CO = cardiac output; **CVP** = central venous pressure;
PCWP = pulmonary capillary wedge pressure; **SVR** = systemic vascular resistance.

©UWorld

Zoom In | Zoom Out | Reset | Add To New Card | Existing Card

High-output heart failure results from markedly decreased systemic vascular resistance (eg, large arteriovenous fistula) that leads to increased

4
5
6
7
8
9
10
11
12
13
14
15
16
17
18
19
20
21
22
23
24
25
26
27
28
29
30
31
32
33
34

This patient with dyspnea and chest x-ray showing an enlarged heart and pulmonary edema likely has **high-output heart failure** due to excessive

Exhibit Display

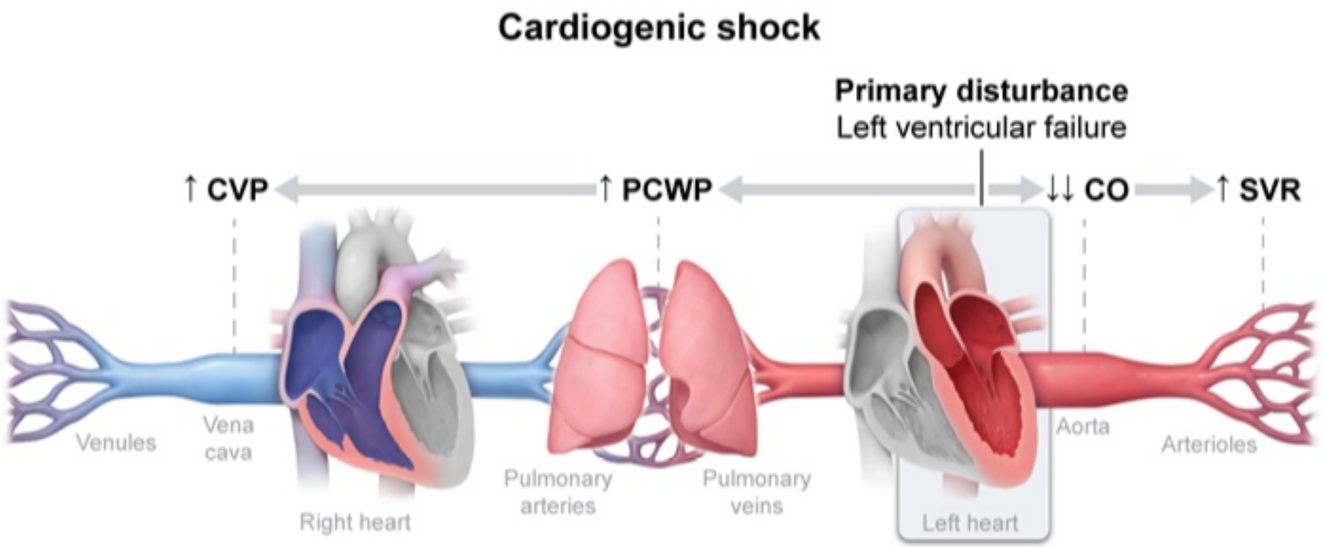

CO = cardiac output; **CVP** = central venous pressure;
PCWP = pulmonary capillary wedge pressure; **SVR** = systemic vascular resistance.

©UWorld

Zoom In | Zoom Out | Reset | Add To New Card | Existing Card

High-output heart failure results from markedly decreased systemic vascular resistance (eg, large arteriovenous fistula) that leads to increased

4
5
6
7
8
9
10
11
12
13
14
15
16
17
18
19
20
21
22
23
24
25
26
27
28
29
30
31
32
33
34

This patient with dyspnea and chest x-ray showing an enlarged heart and pulmonary edema likely has **high-output heart failure** due to excessive

Exhibit Display

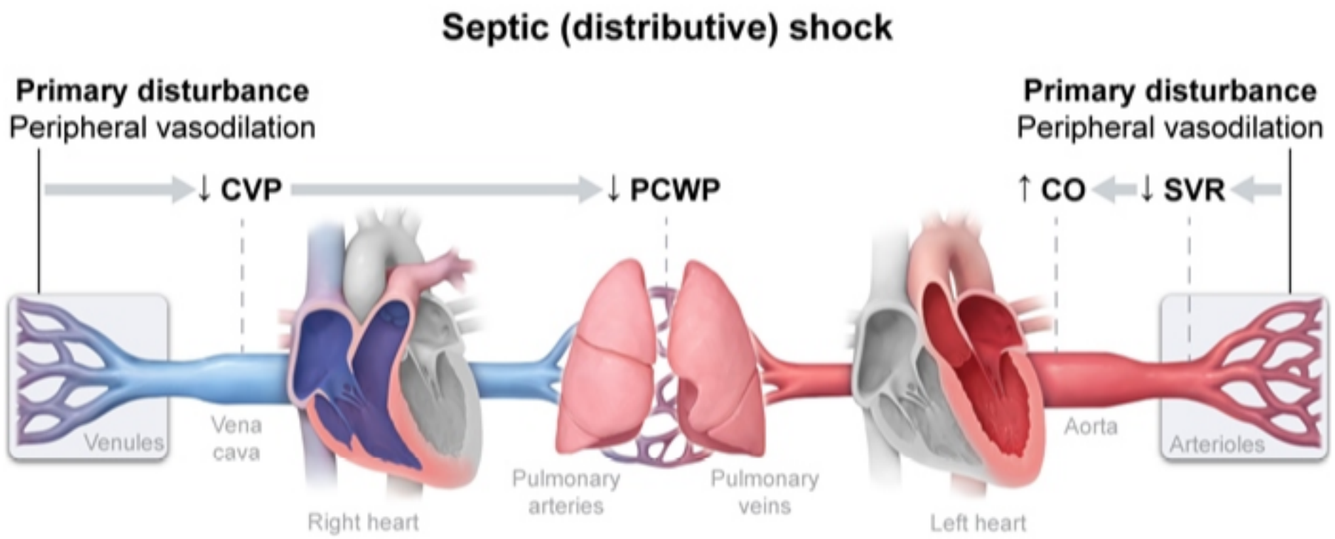

Zoom In | Zoom Out | Reset | Add To New Card | Existing Card

High-output heart failure results from markedly decreased systemic vascular resistance (eg, large arteriovenous fistula) that leads to increased

flow through her **arteriovenous fistula**. A surgically created arteriovenous fistula forms an enlarged vein that serves as an access point for hemodialysis (which requires a vessel with high blood flow rates); however, if the fistula becomes too large, it can lead to hemodynamic complications.

A large arteriovenous fistu
decreased systemic vas ght
atrium quickly and easily,
facilitate increased stroke
response to hypotension r

With excessively large fist
cardiac output; left ventric gh-
output heart failure also in

(Choice A) Hypovolemia ced
cardiac output and a comp

(Choice B) Low-output h ch
leads to decreased cardia
causing elevated central v

(Choice C) The pathophy y a
compensatory increase in
preventing volume overloa

(Choice E) Stimulation of R,
venoconstriction to increa

Educational objective:
High-output heart failure r
venous return and increased cardiac output. Despite a sustained increase in cardiac output, the left ventricle is unable to keep up with the increased venous return, and decompensated heart failure develops.

Exhibit Display

Common mechanisms of high-output heart failure	
Increased quantity of peripheral vessels	• Morbid obesity • Paget disease
Bypass of systemic arteriolar resistance	• Acquired AV fistula (eg, trauma, HD) • Congenital AV malformation
Vasodilation due to unmet metabolic demand in tissues	• Hyperthyroidism • Severe anemia • Thiamine deficiency (wet beriberi)

AV = arteriovenous; HD = hemodialysis.

Add To New Card | Existing Card

With excessively large fistulas, the left ventricle becomes unable to keep up with the increased venous return despite a persistent increase in cardiac output; left ventricular diastolic pressure gradually increases, and decompensated heart failure develops. Other common causes of high-output heart failure also involve decreased SVR as the initial disturbance.

(Choice A) Hypovolemia (eg, severe dehydration) involves a marked reduction in blood volume. Venous return is decreased, leading to reduced cardiac output and a compensatory increase in SVR.

(Choice B) Low-output heart failure (the typical cause of cardiogenic shock) involves left ventricular dysfunction as the initial disturbance, which leads to decreased cardiac output and a compensatory increase in SVR. Increased pressure is transmitted backward from the left ventricle, causing elevated central venous pressure (ie, increased venous return [preload]).

(Choice C) The pathophysiology of sepsis is similar to high-output heart failure in that reduced SVR is the initial disturbance and is followed by a compensatory increase in cardiac output. However, in sepsis the leaky vasculature reduces intravascular volume to decrease venous return, preventing volume overload of the left ventricle.

(Choice E) Stimulation of both alpha-1 and beta-1 adrenergic receptors (eg, with norepinephrine) causes arteriolar constriction to increase SVR, venoconstriction to increase venous return, and increased heart rate and contractility to increase cardiac output.

Educational objective:
High-output heart failure results from markedly decreased systemic vascular resistance (eg, large arteriovenous fistula) that leads to increased venous return and increased cardiac output. Despite a sustained increase in cardiac output, the left ventricle is unable to keep up with the increased venous return, and decompensated heart failure develops.

References

- High-output cardiac failure.

Physiology	Cardiovascular System	Av fistula
Subject	System	Topic

Copyright © UWorld. All rights reserved.

4
5
6
7
8
9
10
11
12
13
14
15
16
17
18
19
20
21
22
23
24
25
26
27
28
29
30
31
32
33
34

A large pharmaceutical company is conducting research on an experimental drug that affects blood flow in diseased tissue. A healthy 30-year-old man is enrolled in the trial, and patterns of normal blood flow through various tissues are studied. One of the patterns is shown in the image below:

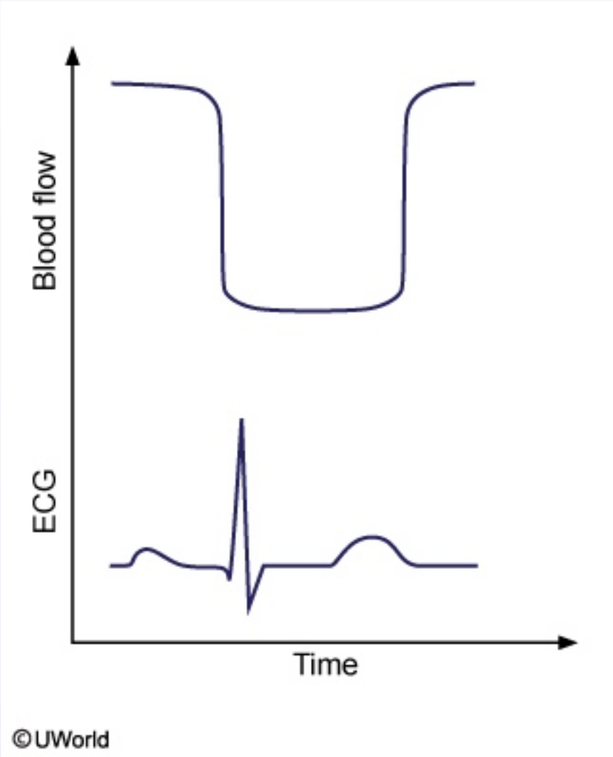

The blood flow curve was most likely obtained from tissue of which of the following?

A. Adrenal medulla

B. Brain cortex

C. Left ventricular myocardium

4
5
6
7
8
9
10
11
12
13
14
15
16
17
18
19
20
21
22
23
24
25
26
27
28
29
30
31
32
33
34

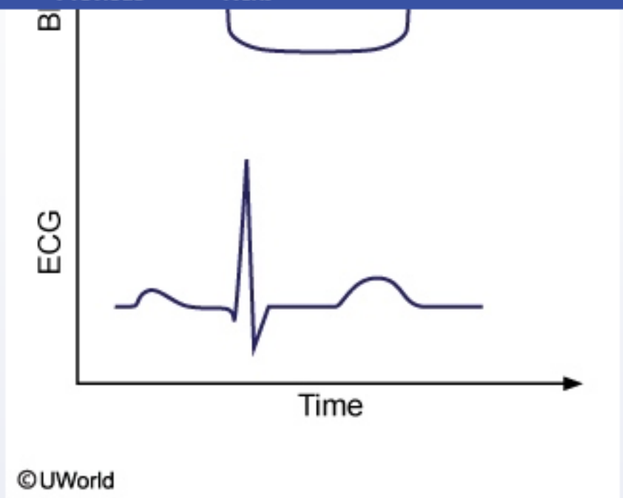

The blood flow curve was most likely obtained from tissue of which of the following?

- A. Adrenal medulla
- B. Brain cortex
- C. Left ventricular myocardium
- D. Renal cortex
- E. Renal medulla
- F. Right ventricular myocardium
- G. Subcortical nuclei

Submit

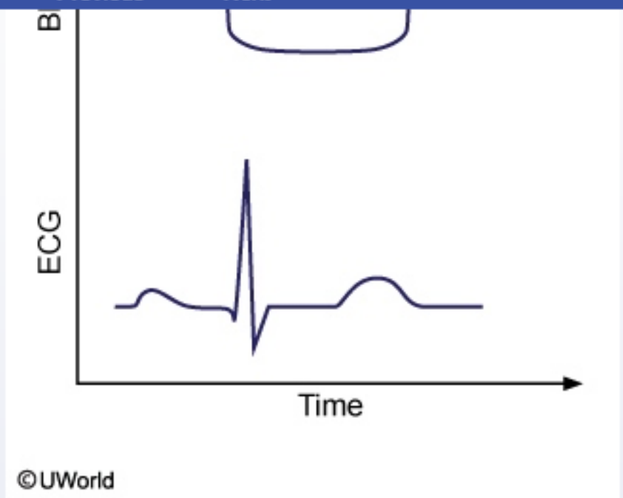

The blood flow curve was most likely obtained from tissue of which of the following?

- A. Adrenal medulla (1%)
- B. Brain cortex (1%)
- ✓ C. Left ventricular myocardium (84%)
- D. Renal cortex (1%)
- E. Renal medulla (1%)
- F. Right ventricular myocardium (9%)
- G. Subcortical nuclei (0%)

Omitted
Correct answer

84%
Answered correctly

06 secs
Time Spent

02/02/2020
Last Updated

4
5
6
7
8
9
10
11
12
13
14
15
16
17
18
19
20
21
22
23
24
25
26
27
28
29
30
31
32
33
34

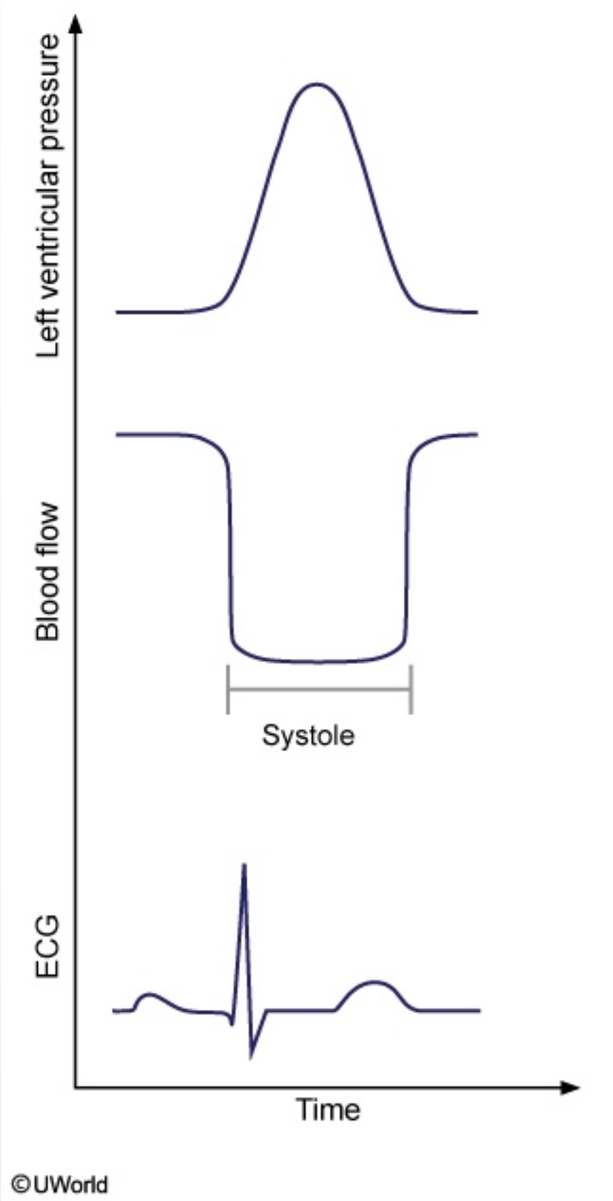

4
5
6
7
8
9
10
11
12
13
14
15
16
17
18
19
20
21
22
23
24
25
26
27
28
29
30
31
32
33
34

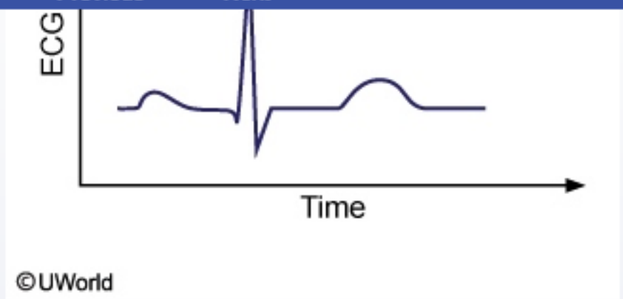

The blood flow curve shows a cyclical variation in flow during the cardiac cycle, with **maximum flow** occurring during **diastole** and minimal flow occurring during ventricular systole. This pattern is unique for the **left ventricular myocardium**. The great majority of blood flows through the vascular beds of the left ventricle during diastole, when the coronary vessels are not compressed by the high ventricular wall pressures created by myocardial contraction. This systolic reduction in blood flow is greatest in the subendocardial myocardium (where wall pressures are the highest), making it the region most prone to ischemia and myocardial infarction.

(Choices A, B, D, E, and G) In all other organs, blood flows continuously throughout the cardiac cycle down the pressure gradient from the arterial source into the venous circulation.

(Choice F) During systole, pressures in the right ventricle are much lower than in the left ventricle (only ~25 mm Hg compared to ~120 mm Hg). As a result, coronary perfusion pressure is able to overcome right ventricular wall pressure throughout the cardiac cycle, leading to relatively constant blood flow to the right ventricular myocardium.

Educational objective:
During ventricular systole, the coronary vessels supplying the left ventricle are compressed by the surrounding muscle. As a result, the majority of left ventricular blood flow occurs during diastole. The systolic reduction in coronary blood flow is greatest in the subendocardial region, making this portion of the left ventricle most prone to ischemia and infarction.

Physiology	Cardiovascular System	Coronary blood flow
Subject	System	Topic

Copyright © UWorld. All rights reserved.

4
5
6
7
8
9
10
11
12
13
14
15
16
17
18
19
20
21
22
23
24
25
26
27
28
29
30
31
32
33
34

In an experiment, 3 L of isotonic saline are infused intravenously into a healthy volunteer after multiple baseline physiologic parameters are recorded. Serial blood pressure measurements show an increase in the systolic and diastolic blood pressure. Ultrasonography reveals an increase in the left ventricular volume and engorgement of the inferior vena cava. Blood levels of a peptide hormone have also increased compared to baseline. This hormone is most likely to increase which of the following in this test subject?

A. Acid content of the urine

B. Glomerular filtration rate

C. Renal sodium reabsorption

D. Renal water reabsorption

E. Vascular resistance

Submit

4
5
6
7
8
9
10
11
12
13
14
15
16
17
18
19
20
21
22
23
24
25
26
27
28
29
30
31
32
33
34

In an experiment, 3 L of isotonic saline are infused intravenously into a healthy volunteer after multiple baseline physiologic parameters are recorded. Serial blood pressure measurements show an increase in the systolic and diastolic blood pressure. Ultrasonography reveals an increase in the left ventricular volume and engorgement of the inferior vena cava. Blood levels of a peptide hormone have also increased compared to baseline. This hormone is most likely to increase which of the following in this test subject?

- A. Acid content of the urine (3%)
- ✓ B. Glomerular filtration rate (73%)
- C. Renal sodium reabsorption (9%)
- D. Renal water reabsorption (5%)
- E. Vascular resistance (7%)

Omitted
Correct answer
B

73%
Answered correctly

01 sec
Time Spent

02/12/2020
Last Updated

Explanation

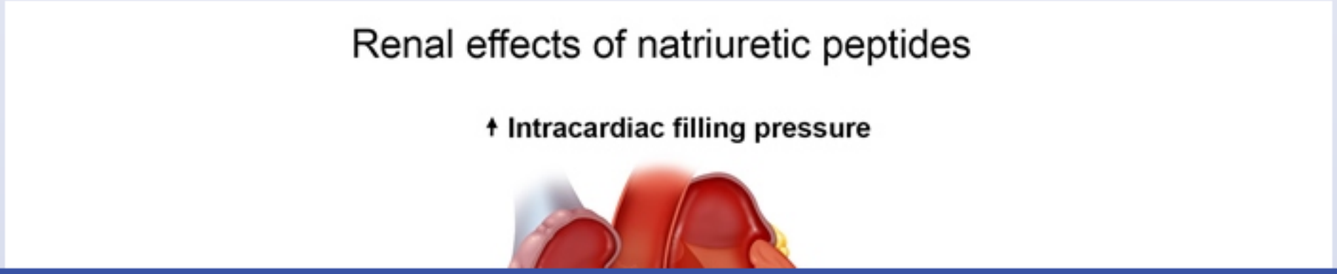

4
5
6
7
8
9
10
11
12
13
14
15
16
17
18
19
20
21
22
23
24
25
26
27
28
29
30
31
32
33
34

Renal effects of natriuretic peptides

↑ Intracardiac filling pressure

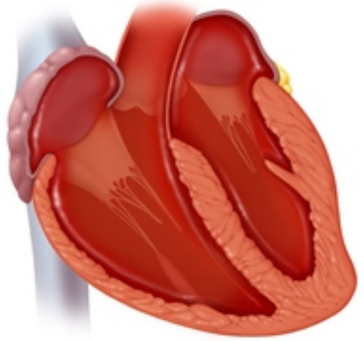

↓

Release of ANP (atria) & BNP (ventricles)

↑ GFR

↓ Proximal Na^+ reabsorption

↓ Renin secretion

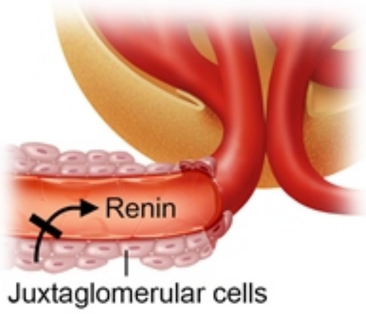

4
5
6
7
8
9
10
11
12
13
14
15
16
17
18
19
20
21
22
23
24
25
26
27
28
29
30
31
32
33
34

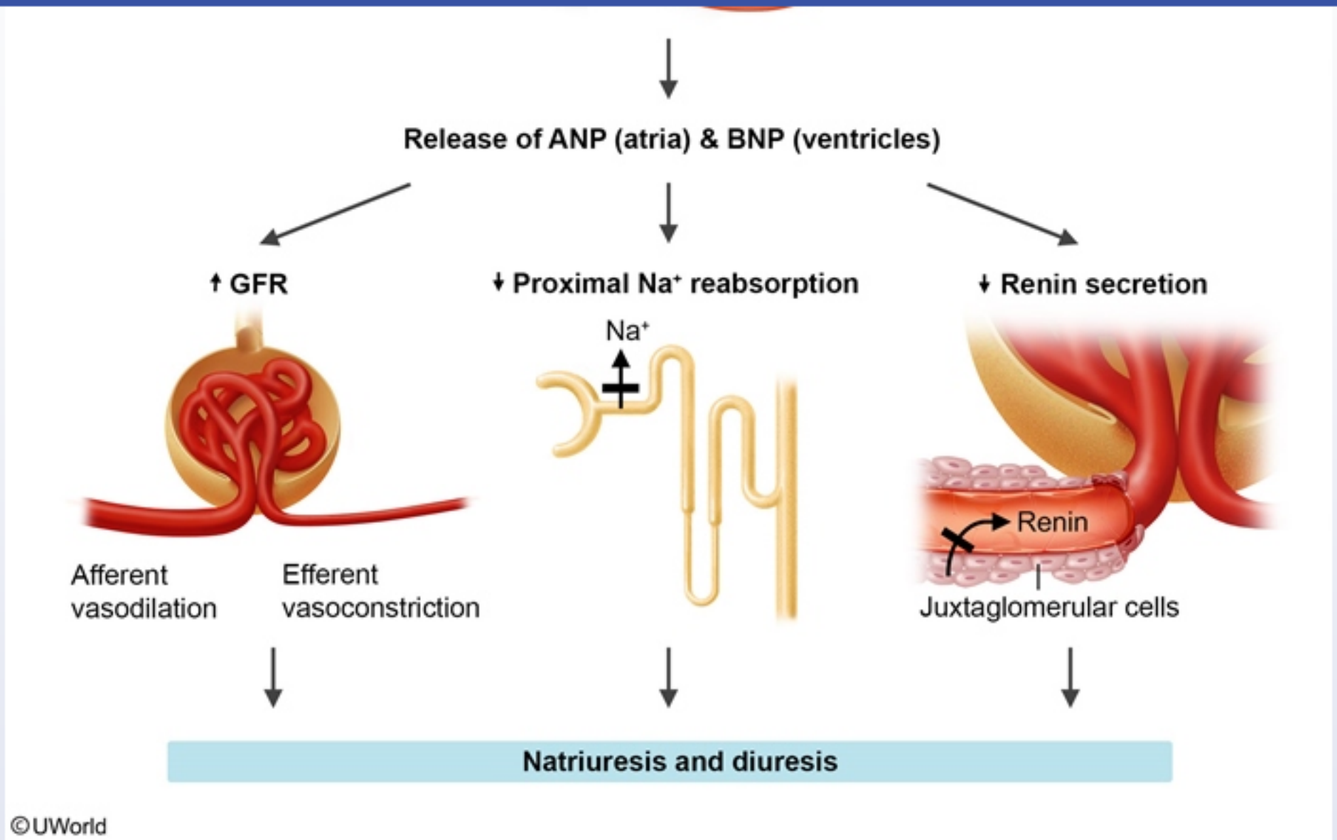

Intravenous infusion of isotonic saline leads to **intravascular volume expansion** with an increase in intracardiac volume and filling pressures. The resultant increase in myocardial wall stretch leads to the release of endogenous natriuretic peptide hormones, including **atrial natriuretic peptide** (ANP) and **brain natriuretic peptide** (BNP) from the atria and ventricles, respectively.

Both ANP and BNP activate guanylate cyclase, which increases intracellular cyclic GMP, and leads to downstream physiologic effects in various tissues. In the kidney, natriuretic peptides promote afferent glomerular arteriolar vasodilation and efferent arteriolar constriction, causing **increased glomerular filtration rate**; this leads to increased **natriuresis** (sodium excretion) and **diuresis** (fluid excretion). Natriuretic peptides also directly inhibit proximal tubular sodium reabsorption and renin secretion. Decreased renin secretion results in reduced angiotensin II and aldosterone levels, further promoting natriuresis and diuresis.

4
5
6
7
8
9
10
11
12
13
14
15
16
17
18
19
20
21
22
23
24
25
26
27
28
29
30
31
32
33
34

Intravenous infusion of isotonic saline leads to **intravascular volume expansion** with an increase in intracardiac volume and filling pressures. The resultant increase in myocardial wall stretch leads to the release of endogenous natriuretic peptide hormones, including **atrial natriuretic peptide** (ANP) and **brain natriuretic peptide** (BNP) from the atria and ventricles, respectively.

Both ANP and BNP activate guanylate cyclase, which increases intracellular cyclic GMP, and leads to downstream physiologic effects in various tissues. In the kidney, natriuretic peptides promote afferent glomerular arteriolar vasodilation and efferent arteriolar constriction, causing **increased glomerular filtration rate**; this leads to increased **natriuresis** (sodium excretion) and **diuresis** (fluid excretion). Natriuretic peptides also directly inhibit proximal tubular sodium reabsorption and renin secretion. Decreased renin secretion results in reduced angiotensin II and aldosterone levels, further promoting natriuresis and diuresis.

(Choice A) An increase in aldosterone levels causes sodium and water retention, hypokalemia, and metabolic alkalosis due to increased urinary hydrogen excretion. Infusion of isotonic saline inhibits aldosterone release and causes a decrease in urinary hydrogen excretion and acid content of the urine.

(Choice C) Activation of the renin-angiotensin-aldosterone system (eg, hypotension, hypovolemia, increased sympathetic activity) leads to an increase in renin secretion, which in turn leads to increased production of angiotensin II and aldosterone. Angiotensin II increases sodium reabsorption in the proximal tubules and stimulates aldosterone secretion from the adrenal cortex, which in turn promotes sodium and water reabsorption in the distal tubule. An increase in intravascular volume by isotonic saline inhibits renin release and causes a decrease in sodium and water reabsorption.

(Choice D) Infusion of isotonic saline inhibits the release of antidiuretic hormone (vasopressin), reducing renal water reabsorption in the collecting duct.

(Choice E) Angiotensin II causes arteriolar vasoconstriction via direct actions on AT1 receptors on the cell membrane. Infusion of isotonic saline decreases renin release with a reduction in angiotensin II production, resulting in decreased systemic vascular resistance.

Educational objective:
Atrial natriuretic peptide and brain natriuretic peptide are released from the atria and ventricles, respectively, in response to myocardial wall stretch due to intravascular volume expansion. These endogenous hormones promote increased glomerular filtration rate, natriuresis, and diuresis.

References

Natriuretic peptides: their structures, receptors, physiologic functions and therapeutic applications

increased glomerular filtration rate; this leads to increased **natriuresis** (sodium excretion) and **diuresis** (fluid excretion). Natriuretic peptides also directly inhibit proximal tubular sodium reabsorption and renin secretion. Decreased renin secretion results in reduced angiotensin II and aldosterone levels, further promoting natriuresis and diuresis.

(Choice A) An increase in aldosterone levels causes sodium and water retention, hypokalemia, and metabolic alkalosis due to increased urinary hydrogen excretion. Infusion of isotonic saline inhibits aldosterone release and causes a decrease in urinary hydrogen excretion and acid content of the urine.

(Choice C) Activation of the renin-angiotensin-aldosterone system (eg, hypotension, hypovolemia, increased sympathetic activity) leads to an increase in renin secretion, which in turn leads to increased production of angiotensin II and aldosterone. Angiotensin II increases sodium reabsorption in the proximal tubules and stimulates aldosterone secretion from the adrenal cortex, which in turn promotes sodium and water reabsorption in the distal tubule. An increase in intravascular volume by isotonic saline inhibits renin release and causes a decrease in sodium and water reabsorption.

(Choice D) Infusion of isotonic saline inhibits the release of antidiuretic hormone (vasopressin), reducing renal water reabsorption in the collecting duct.

(Choice E) Angiotensin II causes arteriolar vasoconstriction via direct actions on AT1 receptors on the cell membrane. Infusion of isotonic saline decreases renin release with a reduction in angiotensin II production, resulting in decreased systemic vascular resistance.

Educational objective:
Atrial natriuretic peptide and brain natriuretic peptide are released from the atria and ventricles, respectively, in response to myocardial wall stretch due to intravascular volume expansion. These endogenous hormones promote increased glomerular filtration rate, natriuresis, and diuresis.

References

- Natriuretic peptides: their structures, receptors, physiologic functions and therapeutic applications.

Physiology	Cardiovascular System	Natriuretic peptides
Subject	System	Topic

Copyright © UWorld. All rights reserved.

©UWorld

Exhibit Display

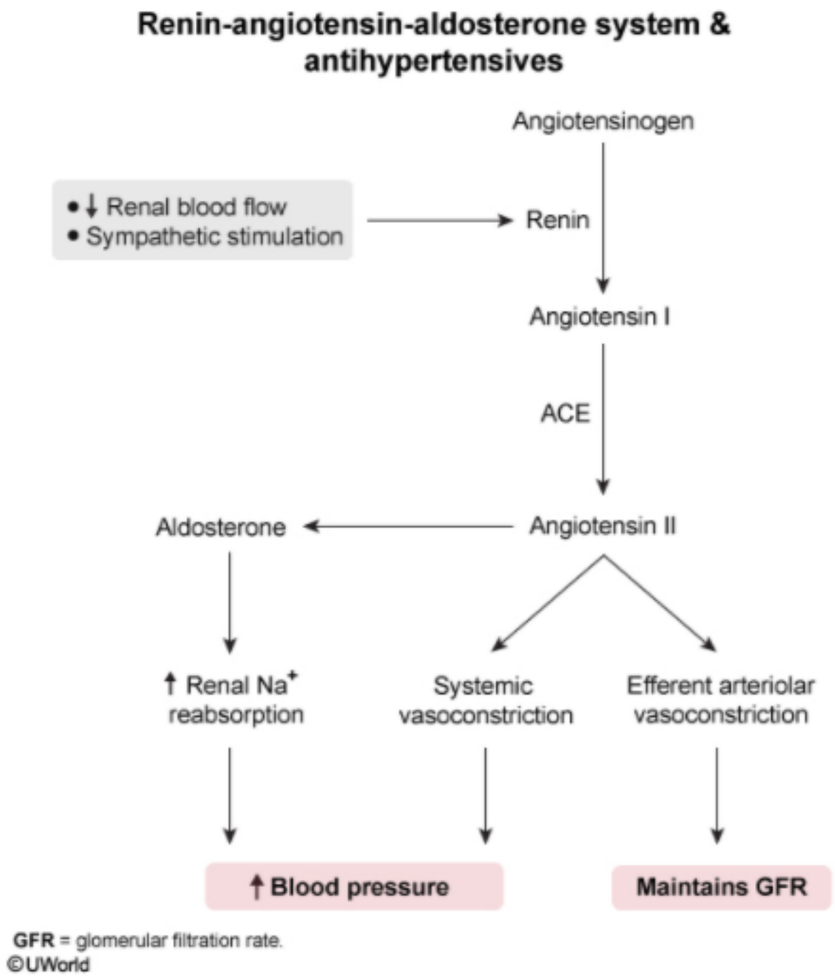

Zoom In | Zoom Out | Reset | Add To New Card | Existing Card

References

4
5
6
7
8
9
10
11
12
13
14
15
16
17
18
19
20
21
22
23
24
25
26
27
28
29
30
31
32
33
34

Researchers are observing how coronary blood flow changes in response to progressive increases in the mean arterial blood pressure (see graph below).

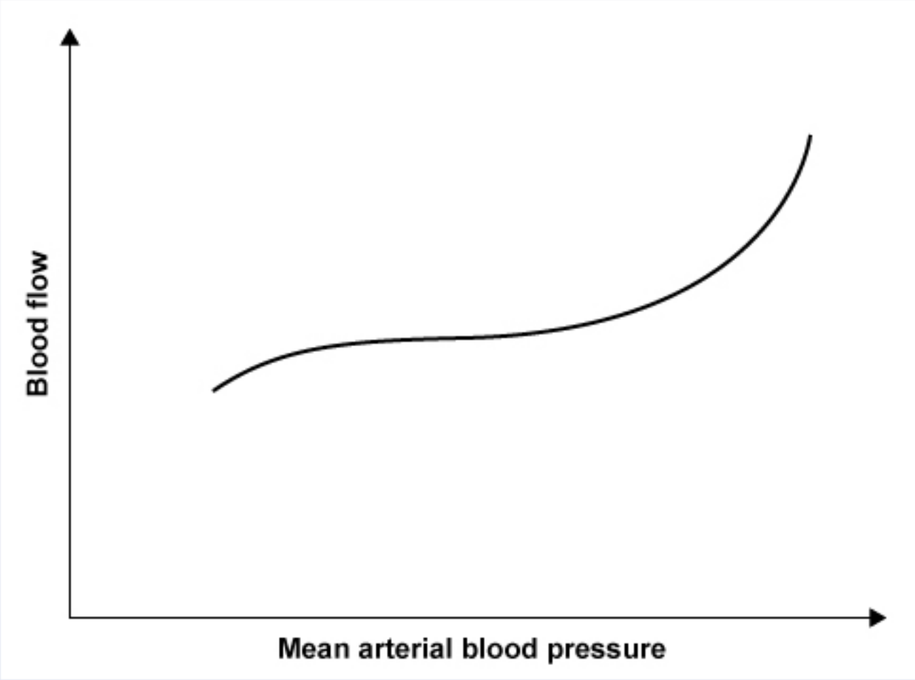

The mostly horizontal portion of the slope indicates a region where coronary blood flow is relatively insensitive to blood pressure changes. Within this zone of autoregulation, the metabolic demands of the myocardium are the main determinant of coronary blood flow. Which of the following endogenous factors is most responsible for controlling coronary blood flow within this range?

A. Acetylcholine

B. Angiotensin II

C. Histamine

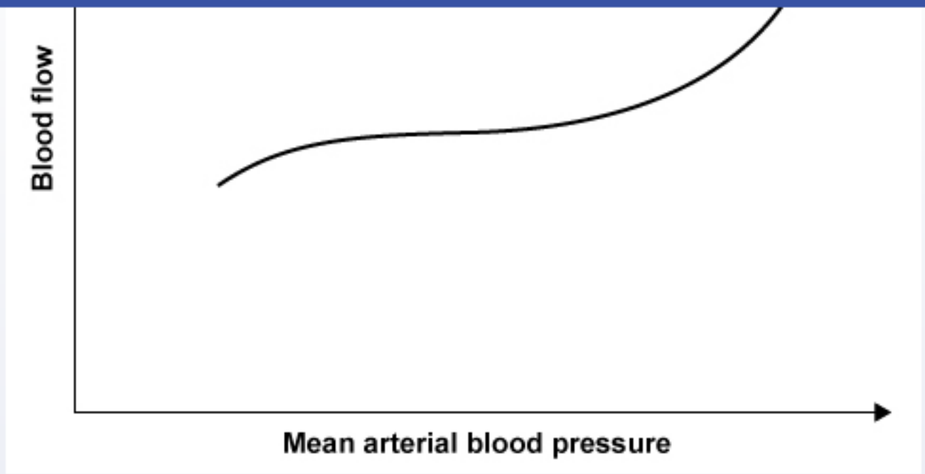

The mostly horizontal portion of the slope indicates a region where coronary blood flow is relatively insensitive to blood pressure changes. Within this zone of autoregulation, the metabolic demands of the myocardium are the main determinant of coronary blood flow. Which of the following endogenous factors is most responsible for controlling coronary blood flow within this range?

A. Acetylcholine
B. Angiotensin II
C. Histamine
D. Nitric oxide
E. Norepinephrine
F. Serotonin

Submit

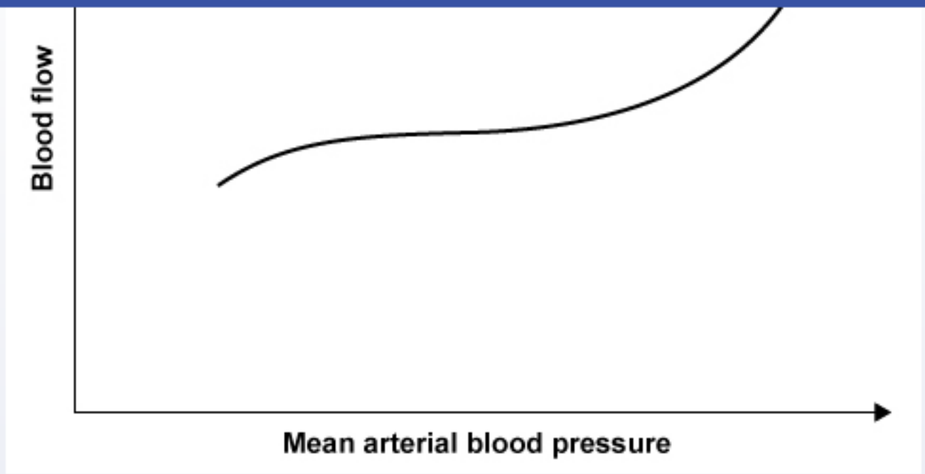

The mostly horizontal portion of the slope indicates a region where coronary blood flow is relatively insensitive to blood pressure changes. Within this zone of autoregulation, the metabolic demands of the myocardium are the main determinant of coronary blood flow. Which of the following endogenous factors is most responsible for controlling coronary blood flow within this range?

- A. Acetylcholine (8%)
- B. Angiotensin II (5%)
- C. Histamine (0%)
- ✓ D. Nitric oxide (75%)
- E. Norepinephrine (8%)
- F. Serotonin (0%)

Omitted
Correct answer

75%
Answered correctly

05 secs
Time Spent

04/26/2020
Last Updated

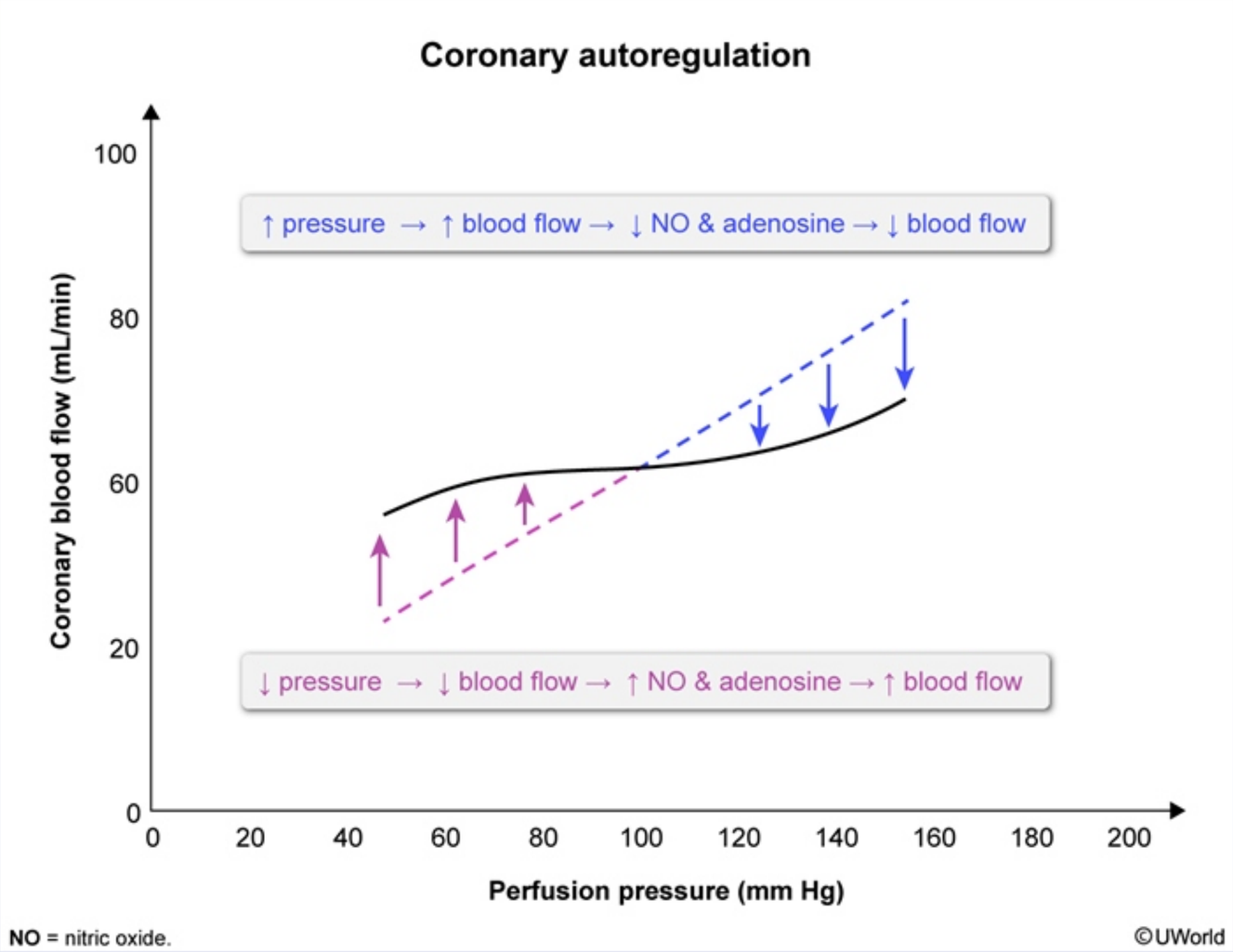

The myocardium has the highest resting oxygen requirement of any tissue in the body, extracting >70% of available oxygen from the blood at baseline (compared to ~30% in most other tissues). As such, a significant **increase in myocardial oxygen demand** can only be met through a corresponding **increase in coronary blood flow**.

4
5
6
7
8
9
10
11
12
13
14
15
16
17
18
19
20
21
22
23
24
25
26
27
28
29
30
31
32
33
34

The myocardium has the highest resting oxygen requirement of any tissue in the body, extracting >70% of available oxygen from the blood at baseline (compared to ~30% in most other tissues). As such, a significant **increase in myocardial oxygen demand** can only be met through a corresponding **increase in coronary blood flow**.

Coronary autoregulation is a process that **maintains myocardial blood flow** in settings of decreased coronary perfusion pressure (eg, hemorrhage, sepsis). Within the region of autoregulation (eg, 60-140 mm Hg), changes in coronary blood flow are driven primarily by myocardial oxygen demand. This is accomplished mostly by automated alterations in vascular resistance via the release of locally acting mediators, namely **adenosine** (released from cardiomyocytes as ATP is broken down for energy) and **nitric oxide** (synthesized by endothelial cells in response to chemical mediators and mechanical stress).

When myocardial perfusion pressure decreases, there is decreased oxygen delivery to the myocardium and less ATP is regenerated via oxidative metabolism, resulting in increased levels of adenosine. Myocardial hypoxia also triggers increased synthesis of nitric oxide. Increased levels of both adenosine and nitric oxide act on vascular smooth muscle to stimulate **vasodilation**, allowing for a relative increase in coronary blood flow at the new, lower perfusion pressure (ie, coronary blood flow is maintained). A similar process occurs when coronary perfusion pressure increases; decreased levels of adenosine and nitric oxide increase vascular resistance, causing coronary blood flow to remain relatively unchanged at the new, higher perfusion pressure.

(Choices A and E) Acetylcholine causes coronary vasodilation (via stimulation of endothelial nitric oxide release), and norepinephrine causes coronary vasoconstriction (via stimulation of alpha-1 receptors on vascular smooth muscle). However, compared to locally released mediators, autonomic nervous system stimulation has a relatively small effect on coronary blood flow.

(Choice B) Angiotensin II stimulates vasoconstriction of coronary arteries, but it is not involved in coronary autoregulation.

(Choice C) Histamine has variable vasoconstrictive and vasodilatory effects on coronary arteries depending on the type of histamine receptor triggered. However, histamine does not play a significant role in coronary autoregulation.

(Choice F) Serotonin primarily functions in the gastrointestinal tract and CNS. It may cause vasoconstriction of coronary arteries, evidenced by an association between $5HT_1$-receptor agonists (eg, sumatriptan) and coronary vasospasm. However, it is not significantly involved in coronary autoregulation.

Educational objective:

chemical mediators and mechanical stress).

When myocardial perfusion pressure decreases, there is decreased oxygen delivery to the myocardium and less ATP is regenerated via oxidative metabolism, resulting in increased levels of adenosine. Myocardial hypoxia also triggers increased synthesis of nitric oxide. Increased levels of both adenosine and nitric oxide act on vascular smooth muscle to stimulate **vasodilation**, allowing for a relative increase in coronary blood flow at the new, lower perfusion pressure (ie, coronary blood flow is maintained). A similar process occurs when coronary perfusion pressure increases; decreased levels of adenosine and nitric oxide increase vascular resistance, causing coronary blood flow to remain relatively unchanged at the new, higher perfusion pressure.

(Choices A and E) Acetylcholine causes coronary vasodilation (via stimulation of endothelial nitric oxide release), and norepinephrine causes coronary vasoconstriction (via stimulation of alpha-1 receptors on vascular smooth muscle). However, compared to locally released mediators, autonomic nervous system stimulation has a relatively small effect on coronary blood flow.

(Choice B) Angiotensin II stimulates vasoconstriction of coronary arteries, but it is not involved in coronary autoregulation.

(Choice C) Histamine has variable vasoconstrictive and vasodilatory effects on coronary arteries depending on the type of histamine receptor triggered. However, histamine does not play a significant role in coronary autoregulation.

(Choice F) Serotonin primarily functions in the gastrointestinal tract and CNS. It may cause vasoconstriction of coronary arteries, evidenced by an association between $5HT_1$-receptor agonists (eg, sumatriptan) and coronary vasospasm. However, it is not significantly involved in coronary autoregulation.

Educational objective:
Coronary autoregulation allows coronary blood flow to be primarily driven by myocardial oxygen demand over a wide range of perfusion pressures (60-140 mm Hg). It is mostly accomplished by alterations in vascular resistance via release of adenosine and nitric oxide in response to myocardial hypoxia.

Physiology	Cardiovascular System	Coronary blood flow
Subject	System	Topic

Copyright © UWorld. All rights reserved.

4
5
6
7
8
9
10
11
12
13
14
15
16
17
18
19
20
21
22
23
24
25
26
27
28
29
30
31
32
33
34

A 32-year-old man comes to the office due to progressive dyspnea, dizziness, and chest discomfort. He has no prior medical problems but had a mild respiratory illness 2 weeks earlier that resolved spontaneously. His father has a history of myocardial infarction. Echocardiogram shows pericardial fluid accumulation with late diastolic collapse of the right atrium. Which of the following physical examination findings is most likely to be seen in this patient?

A. Beat-to-beat variation in pulse amplitude
B. Drop in pulse amplitude during inspiration
C. Pulse with 2 distinct peaks
D. Rapidly rising pulse with high amplitude
E. Slow-rising low-amplitude pulse

Submit

4
5
6
7
8
9
10
11
12
13
14
15
16
17
18
19
20
21
22
23
24
25
26
27
28
29
30
31
32
33
34

A 32-year-old man comes to the office due to progressive dyspnea, dizziness, and chest discomfort. He has no prior medical problems but had a mild respiratory illness 2 weeks earlier that resolved spontaneously. His father has a history of myocardial infarction. Echocardiogram shows pericardial fluid accumulation with late diastolic collapse of the right atrium. Which of the following physical examination findings is most likely to be seen in this patient?

A. Beat-to-beat variation in pulse amplitude (10%)
✓ B. Drop in pulse amplitude during inspiration (66%)
C. Pulse with 2 distinct peaks (8%)
D. Rapidly rising pulse with high amplitude (3%)
E. Slow-rising low-amplitude pulse (10%)

Omitted
Correct answer
B

66%
Answered correctly

01 sec
Time Spent

03/10/2020
Last Updated

Explanation

This patient has a pericardial effusion with associated **cardiac tamponade**. Classic signs of cardiac tamponade include hypotension, elevated jugular venous pressure, and muffled heart sounds (Beck triad). Echocardiography will show pericardial fluid accumulation with late diastolic collapse of the right atrium (due to displacement of pericardial fluid with ventricular expansion). **Pulsus paradoxus** is an important physical finding in cardiac tamponade and refers to an exaggerated drop in systolic blood pressure (>10 mm Hg) during inspiration. Fluid accumulation in the pericardium causes limitation of right ventricular expansion that is exacerbated during inspiration by the increase in venous return. This leads to bowing of the interventricular septum toward the left ventricle, decreasing left ventricular (LV) end-diastolic volume and stroke volume. The

4
5
6
7
8
9
10
11
12
13
14
15
16
17
18
19
20
21
22
23
24
25
26
27
28
29
30
31
32
33
34

This patient has a pericardial effusion with associated **cardiac tamponade**. Classic signs of cardiac tamponade include hypotension, elevated jugular venous pressure, and muffled heart sounds (Beck triad). Echocardiography will show pericardial fluid accumulation with late diastolic collapse of the right atrium (due to displacement of pericardial fluid with ventricular expansion). **Pulsus paradoxus** is an important physical finding in cardiac tamponade and refers to an exaggerated drop in systolic blood pressure (>10 mm Hg) during inspiration. Fluid accumulation in the pericardium causes limitation of right ventricular expansion that is exacerbated during inspiration by the increase in venous return. This leads to bowing of the interventricular septum toward the left ventricle, decreasing left ventricular (LV) end-diastolic volume and stroke volume. The result is **decreased systolic pulse pressure during inspiration**.

(Choice A) Pulsus alternans refers to the beat-to-beat variation in pulse amplitude due to a change in systolic blood pressure; it is most commonly seen in patients with severe LV dysfunction. Electrical alternans can be seen in very large pericardial effusion or cardiac tamponade and refers to a beat-to-beat variation in the QRS complex amplitude on ECG due to the swinging motion of the heart in the pericardial fluid.

(Choice C) A dicrotic pulse is a pulse with 2 distinct peaks (one during systole and the other during diastole) due to an accentuated diastolic dicrotic wave after the dicrotic notch. This finding typically occurs in patients with severe systolic dysfunction and high systemic arterial resistance.

(Choice D) A hyperkinetic pulse is a rapidly rising pulse with high amplitude due to the rapid ejection of a large stroke volume against a decreased afterload. This can occur with aortic regurgitation and high-output conditions (eg, thyrotoxicosis, arterio-venous fistula).

(Choice E) Fixed LV outflow tract obstruction (eg, valvular aortic stenosis) can cause pulsus parvus et tardus, which is palpable as a slow-rising low-amplitude pulse due to diminished stroke volume (pulsus parvus) and prolonged LV ejection time (pulsus tardus).

Educational objective:
Pulsus paradoxus refers to an exaggerated drop (>10 mm Hg) in systolic blood pressure during inspiration. It is most commonly seen in patients with cardiac tamponade but can also occur in severe asthma, chronic obstructive pulmonary disease, hypovolemic shock, and constrictive pericarditis.

References

- Does this patient with a pericardial effusion have cardiac tamponade?

Physiology	Cardiovascular System	Pericardial effusion

4
5
6
7
8
9
10
11
12
13
14
15
16
17
18
19
20
21
22
23
24
25
26
27
28
29
30
31
32
33
34

Exhibit Display

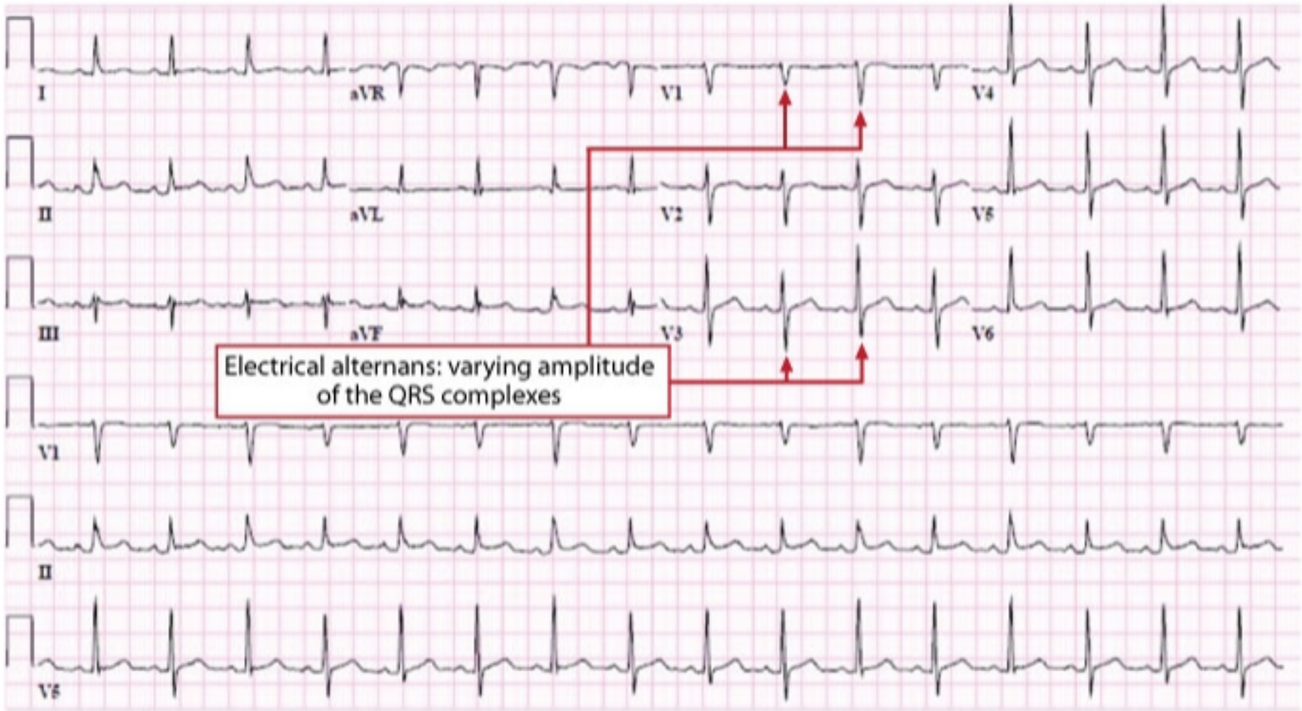

© USMLEWorld, LLC

Zoom In | Zoom Out | Reset | Add To New Card | Existing Card

4
5
6
7
8
9
10
11
12
13
14
15
16
17
18
19
20
21
22
23
24
25
26
27
28
29
30
31
32
33
34

A 46-year-old man comes to the office with chest pain and dyspnea on exertion. He has no known medical problems and leads a sedentary lifestyle. He is a lifetime nonsmoker. Noninvasive cardiac testing is nondiagnostic. Left and right heart catheterization is planned. During the procedure, the catheter records periodic pressure changes with a maximum of 25 mm Hg and minimum of 2 mm Hg. The catheter is advanced further, and then shows periodic pressure changes with a maximum of 25 mm Hg and a minimum of 10 mm Hg. Assuming the results of the procedure are normal, the first set of readings was most likely obtained from which of the following locations?

A. Left atrium
B. Left ventricle
C. Pulmonary artery
D. Right atrium
E. Right ventricle

Submit

4
5
6
7
8
9
10
11
12
13
14
15
16
17
18
19
20
21
22
23
24
25
26
27
28
29
30
31
32
33
34

A 46-year-old man comes to the office with chest pain and dyspnea on exertion. He has no known medical problems and leads a sedentary lifestyle. He is a lifetime nonsmoker. Noninvasive cardiac testing is nondiagnostic. Left and right heart catheterization is planned. During the procedure, the catheter records periodic pressure changes with a maximum of 25 mm Hg and minimum of 2 mm Hg. The catheter is advanced further, and then shows periodic pressure changes with a maximum of 25 mm Hg and a minimum of 10 mm Hg. Assuming the results of the procedure are normal, the first set of readings was most likely obtained from which of the following locations?

A. Left atrium (8%)
B. Left ventricle (3%)
C. Pulmonary artery (14%)
D. Right atrium (34%)
✓ E. Right ventricle (38%)

Omitted
Correct answer
E

38%
Answered correctly

02 secs
Time Spent

02/20/2020
Last Updated

Explanation

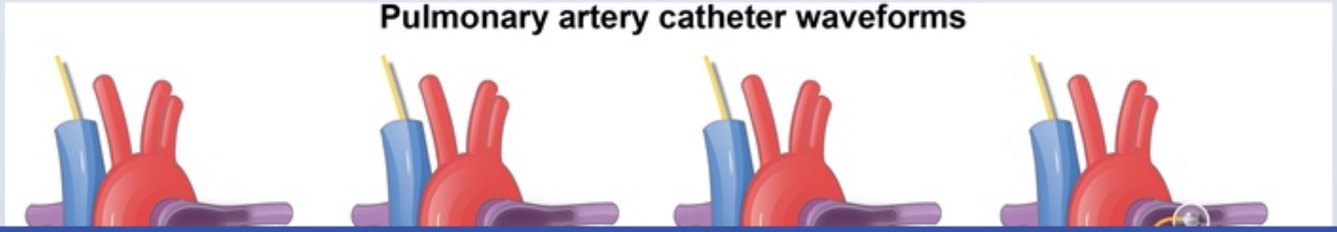

4
5
6
7
8
9
10
11
12
13
14
15
16
17
18
19
20
21
22
23
24
25
26
27
28
29
30
31
32
33
34

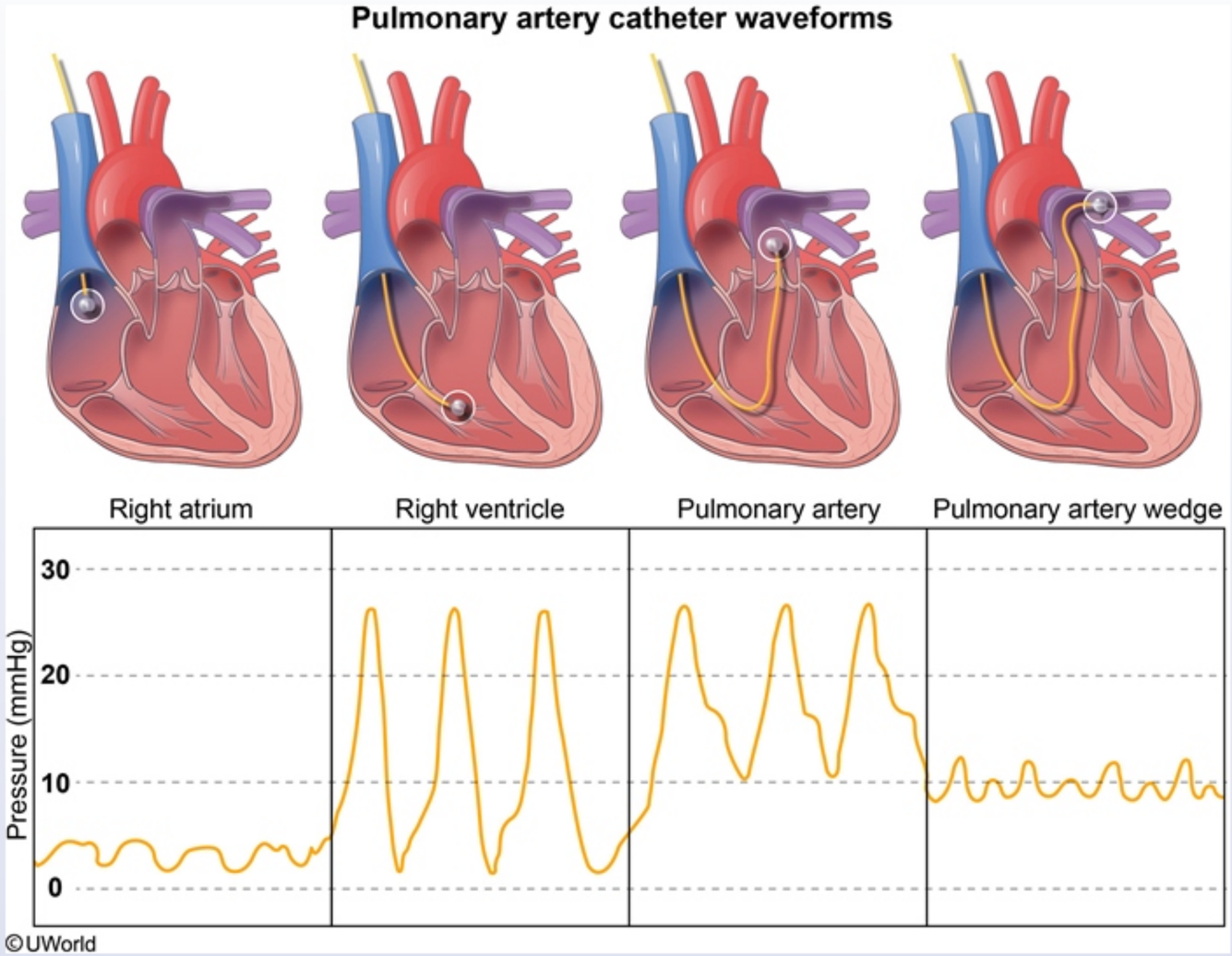

Cardiac catheterization is performed to evaluate for cardiac etiologies and obtain direct measurements of intracardiac pressures in patients with unexplained symptoms. In general, right-sided pressures are much lower than those of the left side as the right ventricle is pumping blood into a much lower resistance pulmonary vasculature.

Cardiac catheterization is performed to evaluate for cardiac etiologies and obtain direct measurements of intracardiac pressures in patients with unexplained symptoms. In general, right-sided pressures are much lower than those of the left side as the right ventricle is pumping blood into a much lower resistance pulmonary vasculature.

A balloon-tipped pulmonary artery (PA) catheter (attached distally to a pressure transducer) is inserted into the subclavian or internal jugular vein. When the PA catheter enters the superior vena cava (SVC), a venous waveform appears, and the balloon is inflated with air and the catheter is advanced. The location of the catheter tip is determined by the pressure readings as follows:

1. The venous pressure waveform of the SVC appears as small-amplitude oscillations. The pressure remains unchanged as the catheter is advanced into the right atrium (RA). Normal pressure in the SVC and RA is 1-6 mm Hg **(Choice D)**.
2. As the catheter is advanced across the tricuspid valve into the right ventricle (RV), a pulsatile waveform appears. The peak (systolic) pressure is the strength of right ventricular contraction, and the lowest (diastolic) pressure is just below the RA pressure. RV systolic pressure is normally 15-30 mm Hg.
3. As the catheter advances across the pulmonic valve into a main pulmonary artery, the pressure waveform shows a sudden increase in diastolic pressure with no change in systolic pressure. This rise in diastolic pressure is due to pulmonary capillary resistance and backward transmission of left atrial pressure. The PA diastolic pressure is normally 6-12 mm Hg **(Choice C)**.
4. When the catheter is advanced into the distal PA branches, a venous type waveform appears; this is called the PA occlusion pressure or pulmonary capillary wedge pressure (PCWP). This pressure is reflective of venous pressure in the left heart (left atrial pressure and left ventricular diastolic pressure) **(Choice A)**. PCWP is usually equal to PA diastolic pressure (6-12 mm Hg).

(Choice B) Left-sided pressures are much higher than right heart pressures in order to maintain systemic perfusion. The normal left ventricular systolic pressure is approximately 90-140 mm Hg with a left ventricular end-diastolic pressure of 6-12 mm Hg.

Educational objective:
Right-sided pressures in the heart are lower than left-sided pressures due to lower resistance in the pulmonary vasculature. Right ventricular diastolic pressure is similar to right atrial/central venous pressure (1-6 mm Hg), whereas pulmonary artery diastolic pressure is slightly higher (6-12 mm Hg) due to resistance to flow in the pulmonary circulation.

Physiology Cardiovascular System Cardiac catheterization

much lower resistance pulmonary vasculature.

A balloon-tipped pulmonary artery (PA) catheter (attached distally to a pressure transducer) is inserted into the subclavian or internal jugular vein. When the PA catheter enters the superior vena cava (SVC), a venous waveform appears, and the balloon is inflated with air and the catheter is advanced. The location of the catheter tip is determined by the pressure readings as follows:

1. The venous pressure waveform of the SVC appears as small-amplitude oscillations. The pressure remains unchanged as the catheter is advanced into the right atrium (RA). Normal pressure in the SVC and RA is 1-6 mm Hg **(Choice D)**.
2. As the catheter is advanced across the tricuspid valve into the right ventricle (RV), a pulsatile waveform appears. The peak (systolic) pressure is the strength of right ventricular contraction, and the lowest (diastolic) pressure is just below the RA pressure. RV systolic pressure is normally 15-30 mm Hg.
3. As the catheter advances across the pulmonic valve into a main pulmonary artery, the pressure waveform shows a sudden increase in diastolic pressure with no change in systolic pressure. This rise in diastolic pressure is due to pulmonary capillary resistance and backward transmission of left atrial pressure. The PA diastolic pressure is normally 6-12 mm Hg **(Choice C)**.
4. When the catheter is advanced into the distal PA branches, a venous type waveform appears; this is called the PA occlusion pressure or pulmonary capillary wedge pressure (PCWP). This pressure is reflective of venous pressure in the left heart (left atrial pressure and left ventricular diastolic pressure) **(Choice A)**. PCWP is usually equal to PA diastolic pressure (6-12 mm Hg).

(Choice B) Left-sided pressures are much higher than right heart pressures in order to maintain systemic perfusion. The normal left ventricular systolic pressure is approximately 90-140 mm Hg with a left ventricular end-diastolic pressure of 6-12 mm Hg.

Educational objective:
Right-sided pressures in the heart are lower than left-sided pressures due to lower resistance in the pulmonary vasculature. Right ventricular diastolic pressure is similar to right atrial/central venous pressure (1-6 mm Hg), whereas pulmonary artery diastolic pressure is slightly higher (6-12 mm Hg) due to resistance to flow in the pulmonary circulation.

Physiology	Cardiovascular System	Cardiac catheterization
Subject	System	Topic

4
5
6
7
8
9
10
11
12
13
14
15
16
17
18
19
20
21
22
23
24
25
26
27
28
29
30
31
32
33
34

Exhibit Display

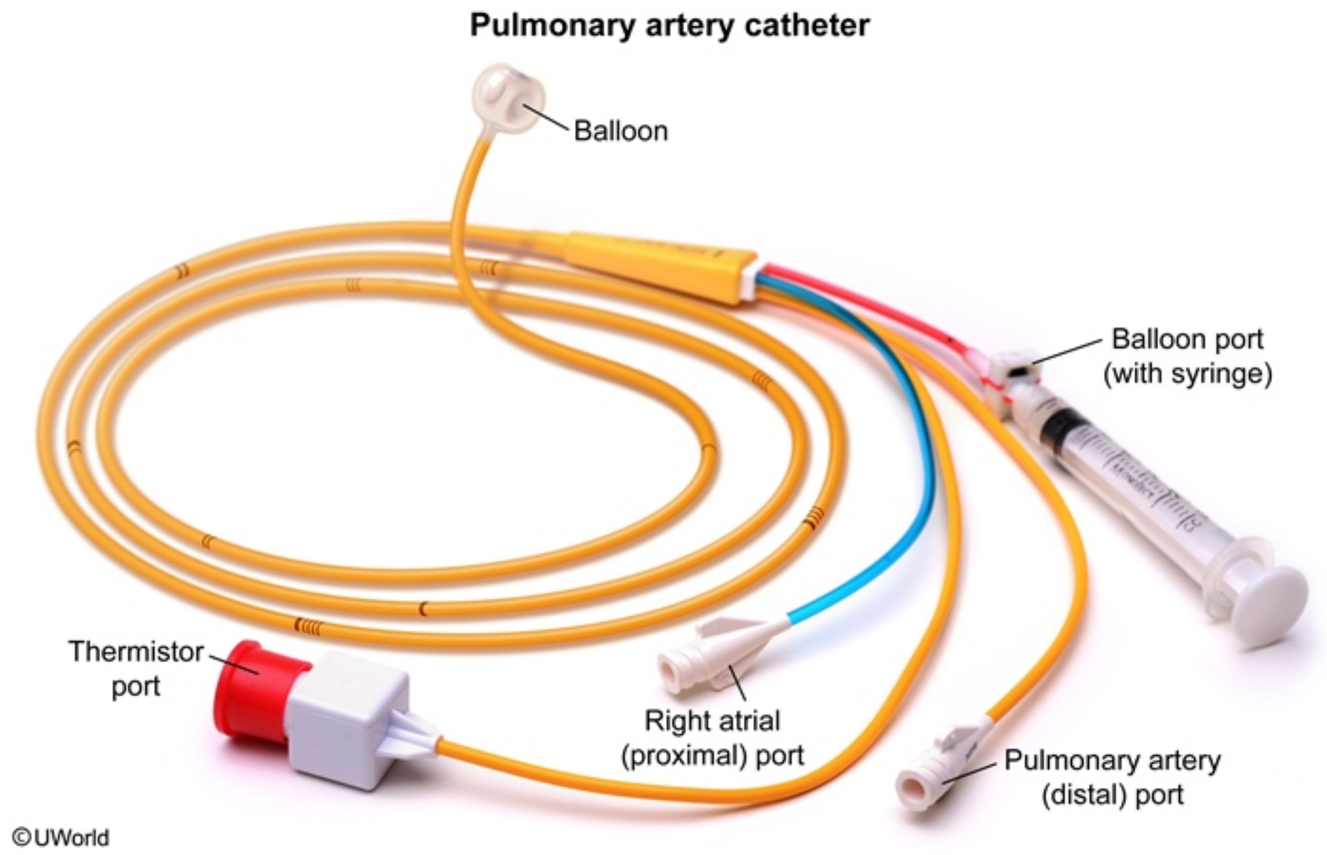

Zoom In | Zoom Out | Reset | Add To New Card | Existing Card

ventricular diastolic pressure) **(Choice A)**. PCWP is usually equal to PA diastolic pressure (6-12 mm Hg).

Exhibit Display

Normal hemodynamic findings	
Location	**Pressure (mm Hg)**
Right atrium	Mean: 1-6
Right ventricle	Systolic: 15-30 Diastolic: 1-6
Pulmonary artery	Systolic: 15-30 Diastolic: 6-12
Left atrial/PCWP/LVEDP	Mean: 6-12

LVEDP = left ventricular end-diastolic pressure;
PCWP = pulmonary capillary wedge pressure.

©UWorld

Zoom In Zoom Out Reset Add To New Card | Existing Card

ventricular diastolic pressure) **(Choice A)**. PCWP is usually equal to PA diastolic pressure (6-12 mm Hg).

4
5
6
7
8
9
10
11
12
13
14
15
16
17
18
19
20
21
22
23
24
25
26
27
28
29
30
31
32
33
34

A 53-year-old man comes to the office due to difficulty breathing and increasing fatigue. He has shortness of breath at night and has been sleeping in a recliner to help relieve his dyspnea. Medical history is significant for hypertension and hyperlipidemia. Two months ago, the patient suffered a myocardial infarction that was not revascularized due to a delay in seeking treatment. He quit smoking afterward, but had previously smoked a pack of cigarettes daily for 25 years. On cardiac auscultation, a low-frequency diastolic heart sound is heard shortly after the second heart sound when the patient lies in the left lateral decubitus position. Cardiac imaging shows hypokinesis of the left ventricular free wall. Which of the following is most likely to accentuate this patient's abnormal auscultation finding?

A. Amyl nitrite inhalation
B. Furosemide injection
C. Having the patient stand up
D. Listening at end expiration
E. Phase 2 of the Valsalva maneuver

Submit

A 53-year-old man comes to the office due to difficulty breathing and increasing fatigue. He has shortness of breath at night and has been sleeping in a recliner to help relieve his dyspnea. Medical history is significant for hypertension and hyperlipidemia. Two months ago, the patient suffered a myocardial infarction that was not revascularized due to a delay in seeking treatment. He quit smoking afterward, but had previously smoked a pack of cigarettes daily for 25 years. On cardiac auscultation, a low-frequency diastolic heart sound is heard shortly after the second heart sound when the patient lies in the left lateral decubitus position. Cardiac imaging shows hypokinesis of the left ventricular free wall. Which of the following is most likely to accentuate this patient's abnormal auscultation finding?

- A. Amyl nitrite inhalation (7%)
- B. Furosemide injection (2%)
- C. Having the patient stand up (13%)
- ✓ D. Listening at end expiration (43%)
- E. Phase 2 of the Valsalva maneuver (32%)

Omitted
Correct answer
D

43%
Answered correctly

03 secs
Time Spent

03/26/2020
Last Updated

Explanation

Gallop heart sounds			
	Features	Normal	Abnormal/associated conditions

Gallop heart sounds			
	Features	**Normal**	**Abnormal/associated conditions**
Third heart sound (S3)	• Ventricular gallop sound (after S2) • Heard during rapid **passive filling** of ventricles in diastole • Sudden cessation of filling as ventricle reaches its elastic limit	• Age <40 • Pregnancy	• Systolic heart failure • Mitral regurgitation • High-output states
Fourth heart sound (S4)	• Atrial gallop sound (before S1) • Heard immediately after **atrial contraction** as blood is forced into a stiff ventricle	• Healthy **older** adults	• Younger adults, children • Diastolic dysfunction (eg, LVH)

LVH = left ventricular hypertrophy.

This patient has decompensated heart failure (fatigue, dyspnea) with an audible **third heart sound (S3)**, a low-frequency sound that occurs shortly **after S2** during diastole. S3 is caused by a sudden limitation of ventricular movement during rapid **passive ventricular filling**. It can be a normal finding in healthy children and young adults. However, the presence of S3 in patients age >40 is considered abnormal and suggests **ventricular volume overload** or enlargement. It is often heard with aortic/mitral regurgitation or systolic heart failure (eg, dilated or ischemic cardiomyopathy). In this case, imaging is consistent with left ventricular systolic dysfunction secondary to the patient's recent myocardial infarction.

Left ventricular gallops (S3 and/or S4) are best heard with the bell of the stethoscope over the **cardiac apex** while the patient is in the left lateral decubitus position. Listening at **end expiration** makes the sound even more audible by decreasing lung volume and bringing the heart closer to the chest wall.

(Choice A) Amyl nitrite inhalation causes vasodilation, resulting in a transient decrease in venous return and blood pressure. It would lessen S3 intensity due to the reduction in end-systolic ventricular volume.

(Choice B) Furosemide injection would lead to brisk diuresis, resulting in a decrease in end-systolic ventricular volume that would likely lessen S3 intensity.

LVH = left ventricular hypertrophy.

This patient has decompensated heart failure (fatigue, dyspnea) with an audible **third heart sound (S3)**, a low-frequency sound that occurs shortly **after S2** during diastole. S3 is caused by a sudden limitation of ventricular movement during rapid **passive ventricular filling**. It can be a normal finding in healthy children and young adults. However, the presence of S3 in patients age >40 is considered abnormal and suggests **ventricular volume overload** or enlargement. It is often heard with aortic/mitral regurgitation or systolic heart failure (eg, dilated or ischemic cardiomyopathy). In this case, imaging is consistent with left ventricular systolic dysfunction secondary to the patient's recent myocardial infarction.

Left ventricular gallops (S3 and/or S4) are best heard with the bell of the stethoscope over the **cardiac apex** while the patient is in the left lateral decubitus position. Listening at **end expiration** makes the sound even more audible by decreasing lung volume and bringing the heart closer to the chest wall.

(Choice A) Amyl nitrite inhalation causes vasodilation, resulting in a transient decrease in venous return and blood pressure. It would lessen S3 intensity due to the reduction in end-systolic ventricular volume.

(Choice B) Furosemide injection would lead to brisk diuresis, resulting in a decrease in end-systolic ventricular volume that would likely lessen S3 intensity.

(Choices C and E) The straining phase (phase 2) of the Valsalva maneuver (bearing down against a closed glottis) as well as abrupt standing decreases venous return to the heart and ventricular volumes, reducing S3 intensity.

Educational objective:
The third heart sound (S3) is a low-frequency sound occurring during early diastole after S2. Left ventricular gallops (S3 and/or S4) are best heard with the bell of the stethoscope over the cardiac apex while the patient is in the left lateral decubitus position at end expiration.

Physiology	Cardiovascular System	Heart sounds
Subject	System	Topic

Copyright © UWorld. All rights reserved.

A 56-year-old man comes to the emergency department due to chest palpitations. He feels that his heartbeat is fast and very irregular. The patient has no chest pain, shortness of breath, or dizziness. Physical examination confirms the presence of an irregularly irregular rhythm with a heart rate of 120/min. He hosted a party last night for his wife's birthday and consumed a large amount of alcohol. The patient normally drinks only 2-3 times a year. He is otherwise healthy and takes no medications. Which of the following ECG findings is most likely in this patient?

A. Absent P waves

B. High voltage in precordial leads

C. Prolonged QRS complex

D. Prolonged QT interval

E. ST elevation

Submit

A 56-year-old man comes to the emergency department due to chest palpitations. He feels that his heartbeat is fast and very irregular. The patient has no chest pain, shortness of breath, or dizziness. Physical examination confirms the presence of an irregularly irregular rhythm with a heart rate of 120/min. He hosted a party last night for his wife's birthday and consumed a large amount of alcohol. The patient normally drinks only 2-3 times a year. He is otherwise healthy and takes no medications. Which of the following ECG findings is most likely in this patient?

- ✓ A. Absent P waves (81%)
- B. High voltage in precordial leads (5%)
- C. Prolonged QRS complex (4%)
- D. Prolonged QT interval (7%)
- E. ST elevation (1%)

Omitted
Correct answer
A

81%
Answered correctly

02 secs
Time Spent

04/26/2020
Last Updated

Explanation

This patient's presentation (palpitations, tachycardia, and irregularly irregular rhythm) is suggestive of **atrial fibrillation (AF)**. The ECG in patients with AF typically shows an **absence of P waves** and **irregularly irregular** rhythm with **varying R-R intervals**. Some patients have irregular, low-amplitude, fine **fibrillatory waves** (f waves) between the QRS complexes that represent the chaotic atrial activation. AF is the most common tachyarrhythmia and is often precipitated by acute systemic illness or increased sympathetic tone. It is occasionally seen in patients after excessive **alcohol consumption** ("holiday heart syndrome"). Systemic illnesses that can precipitate AF include long-standing hypertension, heart failure, and hyperthyroidism.

This patient's presentation (palpitations, tachycardia, and irregularly irregular rhythm) is suggestive of **atrial fibrillation (AF)**. The ECG in patients with AF typically shows an **absence of P waves** and **irregularly irregular** rhythm with **varying R-R intervals**. Some patients have irregular, low-amplitude, fine **fibrillatory waves** (f waves) between the QRS complexes that represent the chaotic atrial activation. AF is the most common tachyarrhythmia and is often precipitated by acute systemic illness or increased sympathetic tone. It is occasionally seen in patients after excessive **alcohol consumption** ("holiday heart syndrome"). Systemic illnesses that can precipitate AF include long-standing hypertension, heart failure, and hyperthyroidism.

(Choice B) High QRS voltage in the precordial leads is a sign of ventricular hypertrophy, which most commonly results from prolonged untreated hypertension. Although hypertension can cause AF, this patient has no history of long-standing hypertension, making his acute binge drinking a more likely etiology.

(Choice C) The QRS complexes are narrow in AF. Prolongation of the QRS interval occurs as a result of delay in intraventricular conduction due to fascicular or bundle branch block. The heart rhythm remains regular in patients with intraventricular conduction abnormalities.

(Choice D) A prolonged QT interval can be congenital or acquired. It is associated with an increased risk of torsades de pointes (polymorphic ventricular tachycardia) and sudden cardiac death. The QT interval can be prolonged with chronic, heavy alcohol use, but this would be unlikely in a patient who drinks only a few times a year.

(Choice E) ST segment elevation on an ECG is typically seen in patients with acute transmural myocardial infarction. In the absence of associated arrhythmias, the heart rhythm is typically regular.

Educational objective:
Palpitations refer to a subjective sensation/awareness of the heartbeat due to rapid arrhythmias or forceful ventricular contractions. Atrial fibrillation is the most common cause of an irregularly irregular rhythm and is detected on ECG by an absence of organized P waves and varying R-R intervals.

References

- Long-term alcohol consumption and the risk of atrial fibrillation in the Framingham Study.

Physiology | Cardiovascular System | Atrial fibrillation

Exhibit Display

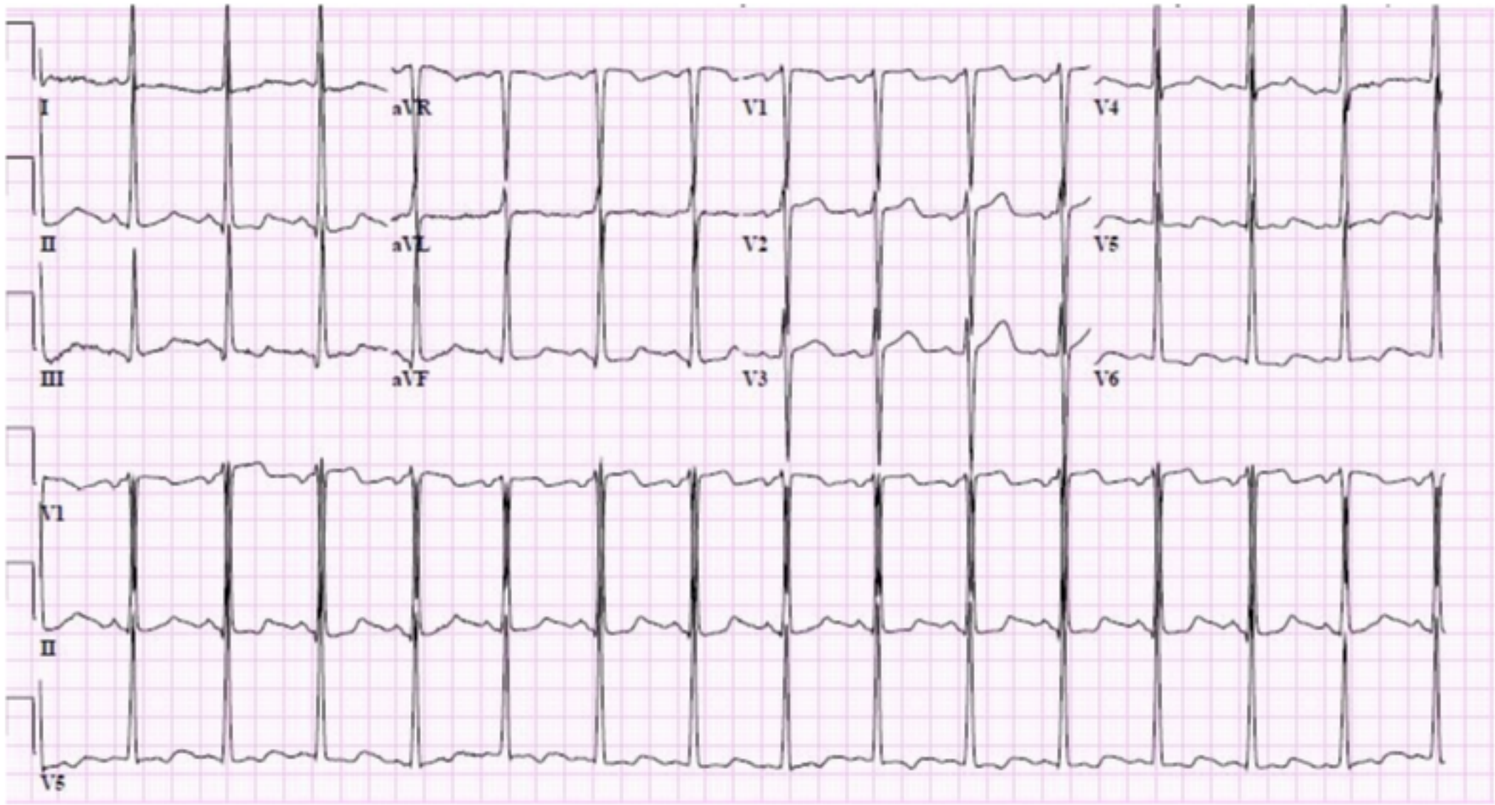

Zoom In | Zoom Out | Reset | Add To New Card | Existing Card

Exhibit Display

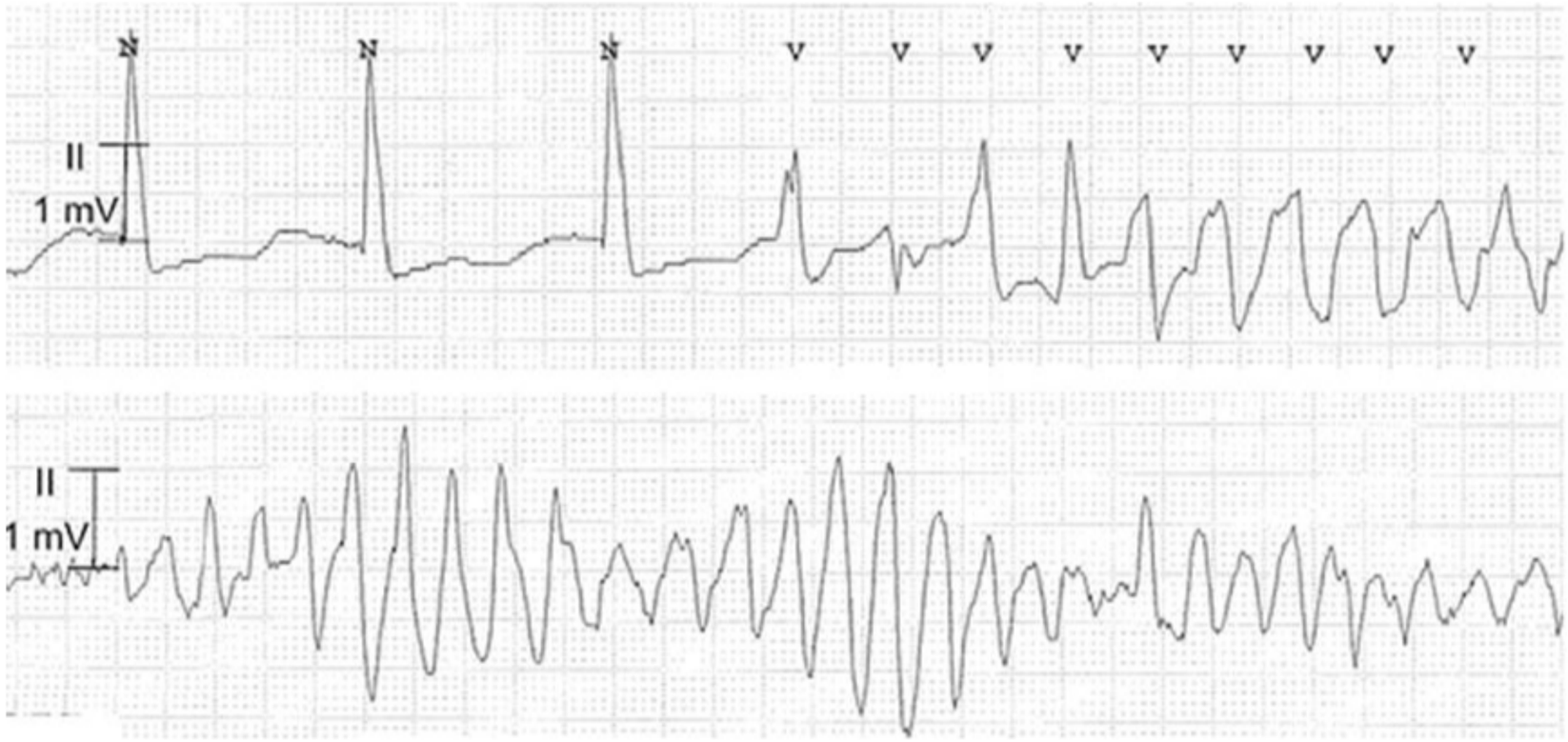

Zoom In | Zoom Out | Reset | Add To New Card | Existing Card

A 43-year-old woman comes to the emergency department due to nausea and vomiting with left-sided chest pain. She states that the pain began 30 minutes ago while playing with her children. She has a history of dyslipidemia and hypertension. The patient's mother died from a myocardial infarction at age 51. Physical examination reveals mild tenderness to palpation over the left chest. An ECG and cardiac biomarkers are normal. She is scheduled for an exercise stress test. During the test, which of the following parameters is likely to be the most similar between the systemic and pulmonary circulation?

A. Arterial oxygen content
B. Arterial resistance
C. Blood flow per minute
D. Diastolic arterial pressure
E. Driving pressure for blood flow
F. Mean arterial pressure

Submit

A 43-year-old woman comes to the emergency department due to nausea and vomiting with left-sided chest pain. She states that the pain began 30 minutes ago while playing with her children. She has a history of dyslipidemia and hypertension. The patient's mother died from a myocardial infarction at age 51. Physical examination reveals mild tenderness to palpation over the left chest. An ECG and cardiac biomarkers are normal. She is scheduled for an exercise stress test. During the test, which of the following parameters is likely to be the most similar between the systemic and pulmonary circulation?

- A. Arterial oxygen content (9%)
- B. Arterial resistance (5%)
- ✓ C. Blood flow per minute (64%)
- D. Diastolic arterial pressure (6%)
- E. Driving pressure for blood flow (5%)
- F. Mean arterial pressure (8%)

Omitted
Correct answer
C

64%
Answered correctly

02 secs
Time Spent

02/04/2020
Last Updated

Explanation

In order to maintain blood flow through the body, the blood flow (mL/min) in the **pulmonary circulation** must closely **match** the blood flow in the **systemic circulation**. This is true for conditions of both exercise and rest as the circulatory system is a continuous circuit. If the flow of blood through the pulmonary circulation is less than the flow of blood through the systemic circulation, the left ventricle would soon empty completely. Alternately, if the flow of blood is significantly greater in the pulmonary circulation than it is in the systemic circulation, the left ventricle would soon

In order to maintain blood flow through the body, the blood flow (mL/min) in the **pulmonary circulation** must closely **match** the blood flow in the **systemic circulation**. This is true for conditions of both exercise and rest as the circulatory system is a continuous circuit. If the flow of blood through the pulmonary circulation is less than the flow of blood through the systemic circulation, the left ventricle would soon empty completely. Alternately, if the flow of blood is significantly greater in the pulmonary circulation than it is in the systemic circulation, the left ventricle would soon be overloaded.

The major exception to this is the bronchial circuit, which supplies oxygen and nutrients to the pulmonary parenchyma from the systemic circulation but drains mostly to the left atrium as opposed to the right atrium (creating a right to left shunt that acts as a partially independent circuit). However, this typically accounts for <5% of the systemic cardiac output.

(Choice A) The arterial oxygen contents of the pulmonary and systemic circulations are dramatically different due to deoxygenated blood in the pulmonary arterial circulation and oxygenated blood in the systemic arterial circulation.

(Choice B) Although the resistance of the pulmonary vasculature may be increased in some circumstances (eg, high altitudes, idiopathic pulmonary hypertension), the arterial resistance in the systemic circulation is considerably higher in all scenarios.

(Choices D, E, and F) The mean arterial pressure, diastolic arterial pressure, and driving pressure for blood flow (difference between mean arterial and venous pressures) are considerably different in the pulmonary and systemic circulations both at rest and during exercise. The normal mean systemic arterial pressure ranges between 70-100 mm Hg and the normal mean pulmonary arterial pressure is approximately 14 mm Hg, whereas venous pressures in both circuits approach 0 mm Hg. Due to the low resistance of the pulmonary circuit, only a small difference between arterial and venous pressures is needed to maintain blood flow compared to the relatively large difference needed between systemic arterial and venous pressures.

Educational objective:
The circulatory system is a continuous circuit, and therefore the volume output of the left ventricle must closely match the output of the right ventricle. This balance is necessary to maintain continuous blood flow through the body and exists both at rest and during exercise.

References

- Organ-specific physiological responses to acute physical exercise and long-term training in humans.

Explanation

Exhibit Display

Bronchopulmonary anastomosis

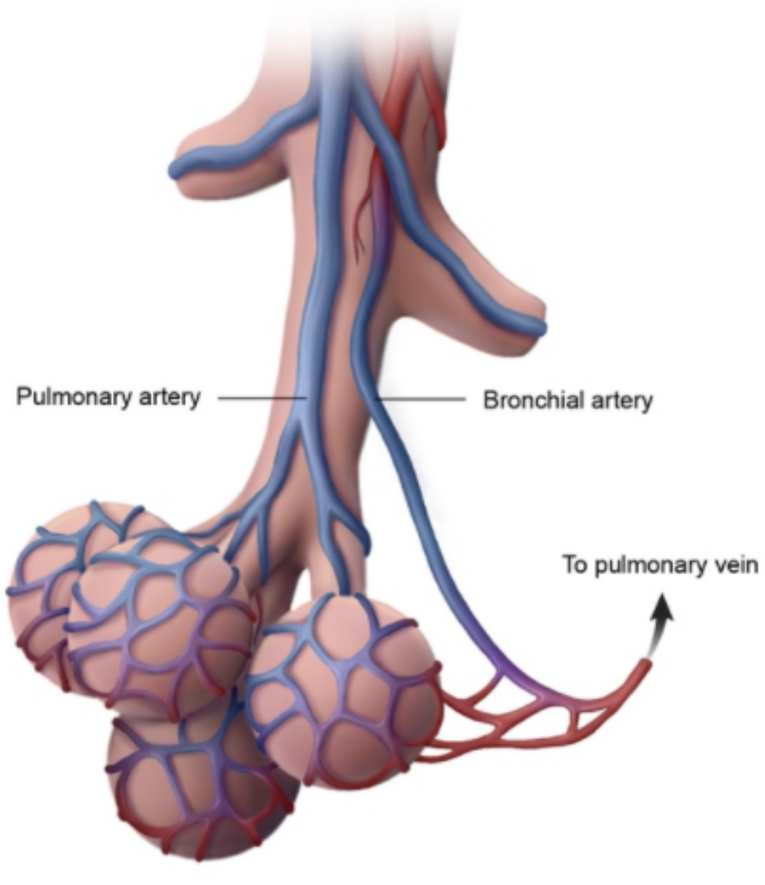

Zoom In | Zoom Out | Reset | Add To New Card | Existing Card

Alternately, if the flow of blood is significantly greater in the pulmonary circulation than it is in the systemic circulation, the left ventricle would soon be overloaded.

The major exception to this is the bronchial circuit, which supplies oxygen and nutrients to the pulmonary parenchyma from the systemic circulation but drains mostly to the left atrium as opposed to the right atrium (creating a right to left shunt that acts as a partially independent circuit). However, this typically accounts for <5% of the systemic cardiac output.

(Choice A) The arterial oxygen contents of the pulmonary and systemic circulations are dramatically different due to deoxygenated blood in the pulmonary arterial circulation and oxygenated blood in the systemic arterial circulation.

(Choice B) Although the resistance of the pulmonary vasculature may be increased in some circumstances (eg, high altitudes, idiopathic pulmonary hypertension), the arterial resistance in the systemic circulation is considerably higher in all scenarios.

(Choices D, E, and F) The mean arterial pressure, diastolic arterial pressure, and driving pressure for blood flow (difference between mean arterial and venous pressures) are considerably different in the pulmonary and systemic circulations both at rest and during exercise. The normal mean systemic arterial pressure ranges between 70-100 mm Hg and the normal mean pulmonary arterial pressure is approximately 14 mm Hg, whereas venous pressures in both circuits approach 0 mm Hg. Due to the low resistance of the pulmonary circuit, only a small difference between arterial and venous pressures is needed to maintain blood flow compared to the relatively large difference needed between systemic arterial and venous pressures.

Educational objective:
The circulatory system is a continuous circuit, and therefore the volume output of the left ventricle must closely match the output of the right ventricle. This balance is necessary to maintain continuous blood flow through the body and exists both at rest and during exercise.

References

- Organ-specific physiological responses to acute physical exercise and long-term training in humans.

Physiology	Cardiovascular System	Pulmonary blood flow
Subject	System	Topic

Copyright © UWorld. All rights reserved.

A 75-year-old man is found unresponsive in his home. Emergency medical services are called by the neighbor, but the patient is pronounced dead at the scene. The patient had a history of hypertension, type 2 diabetes mellitus, and coronary artery disease, as well as a 25-pack-year smoking history. He worked at a coal mine in the remote past and retired as an auto mechanic 15 years ago. Autopsy is performed; a section of lung tissue stained with hematoxylin and eosin is shown below.

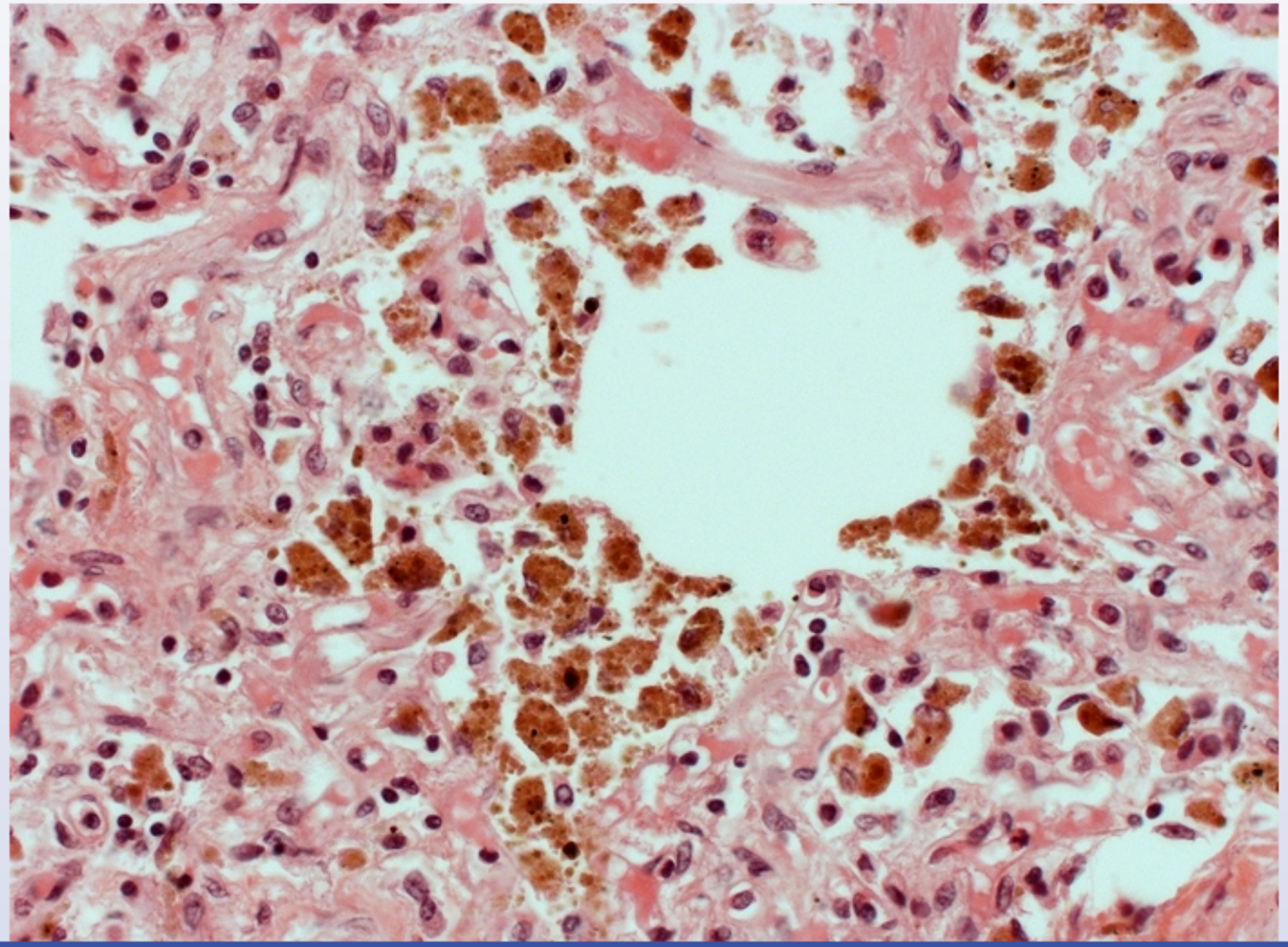

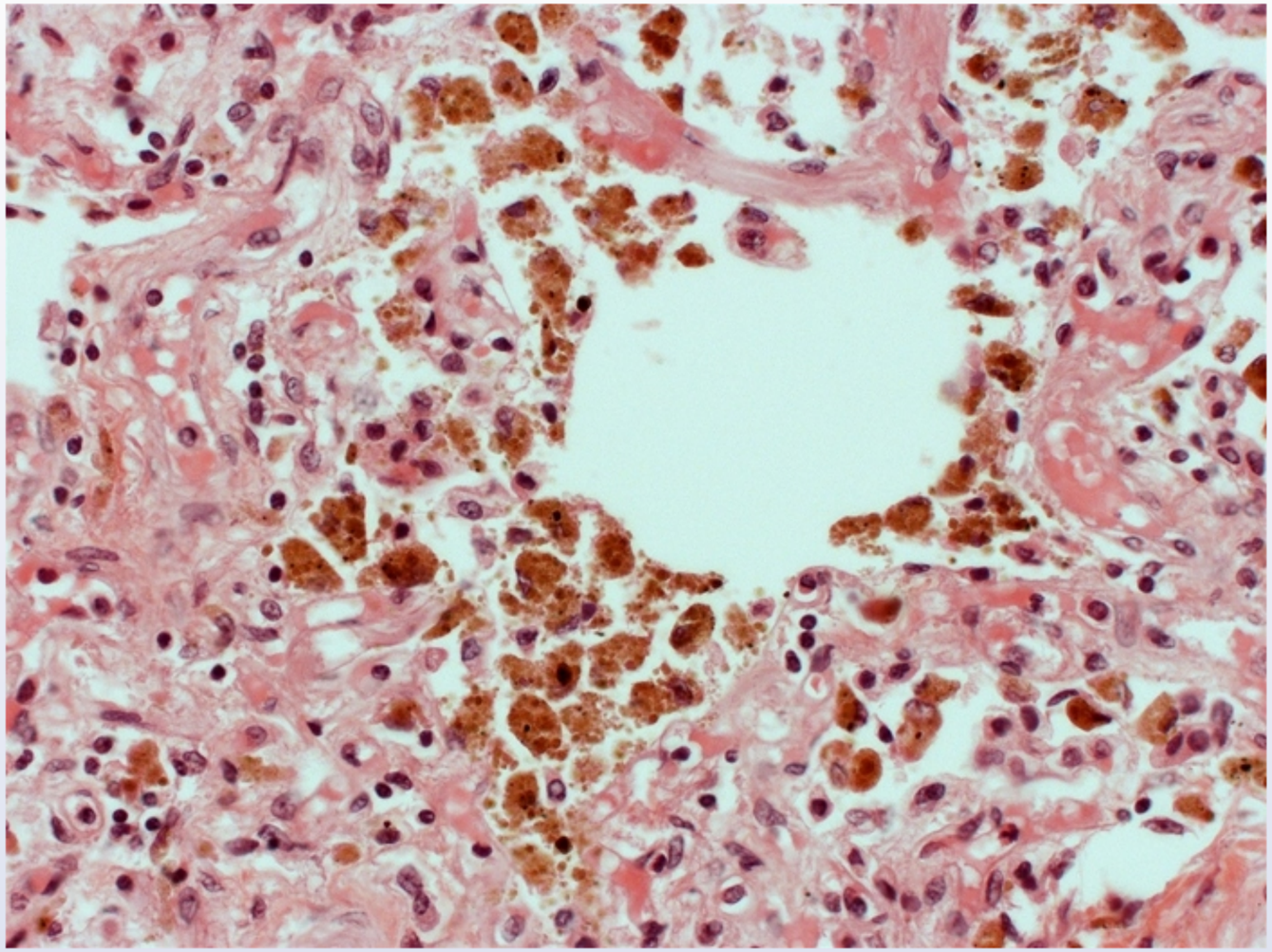

Which of the following is the most likely cause of the histopathology findings in this patient?

- A. Chronic inflammation triggered by crystalline silica
- B. Decreased left ventricular systolic function

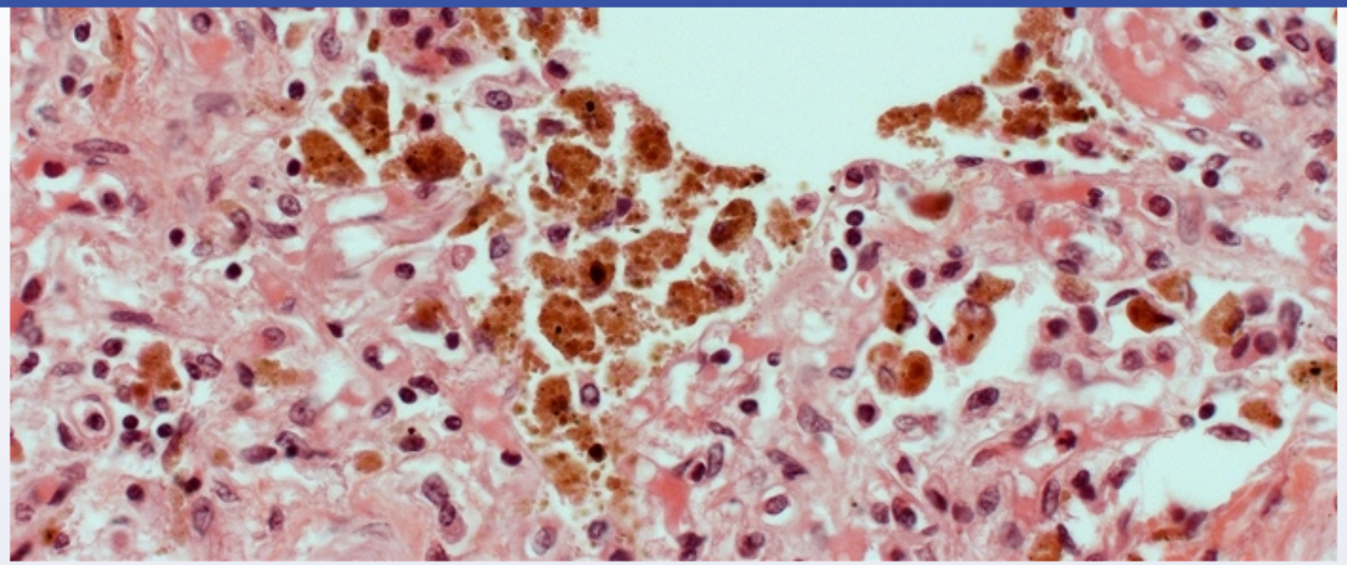

Which of the following is the most likely cause of the histopathology findings in this patient?

- A. Chronic inflammation triggered by crystalline silica
- B. Decreased left ventricular systolic function
- C. Excessive deposition of extracellular collagen
- D. Hyperreactivity of airways to extrinsic allergens
- E. Malignant transformation of bronchial epithelial cells
- F. Neutrophil elastase-mediated alveolar septal destruction

Submit

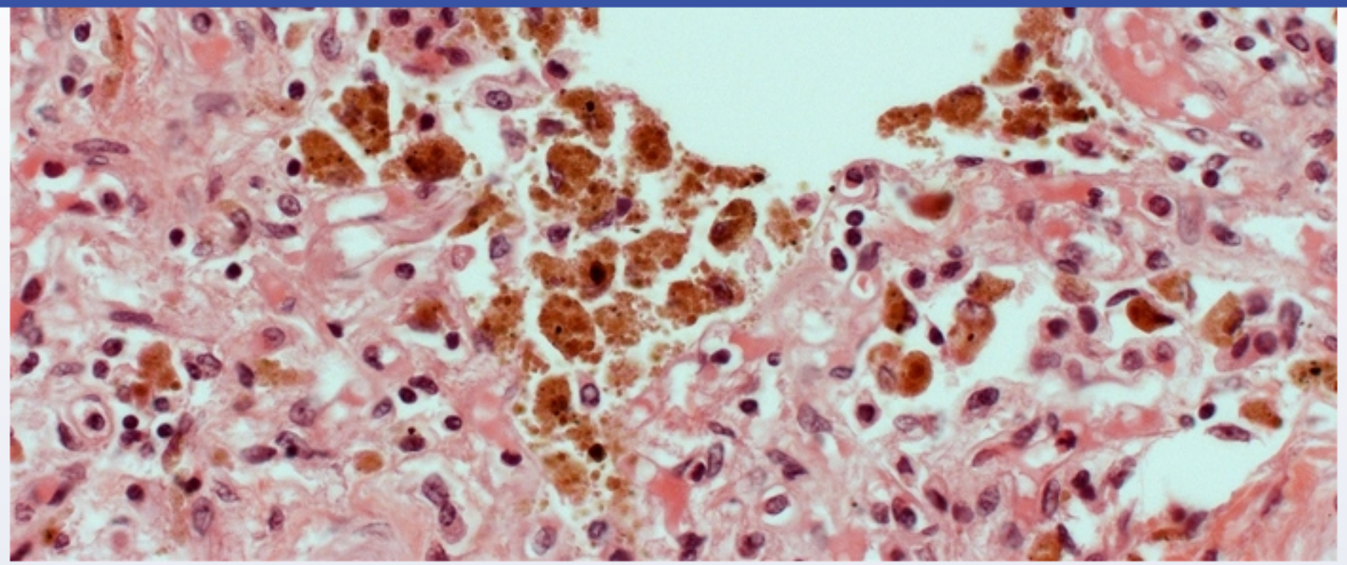

Which of the following is the most likely cause of the histopathology findings in this patient?

- A. Chronic inflammation triggered by crystalline silica (18%)
- ✓ B. Decreased left ventricular systolic function (51%)
- C. Excessive deposition of extracellular collagen (11%)
- D. Hyperreactivity of airways to extrinsic allergens (5%)
- E. Malignant transformation of bronchial epithelial cells (4%)
- F. Neutrophil elastase-mediated alveolar septal destruction (8%)

Omitted
Correct answer

51%
Answered correctly

14 secs
Time Spent

01/11/2020
Last Updated

This patient's autopsy demonstrates an abundance of alveolar macrophages filled with brown pigment in the lung parenchyma. **Hemosiderin-laden macrophages** located in the lungs are usually the result of **chronic passive lung congestion** in the setting of **heart failure** (eg, left ventricular systolic dysfunction). Elevated pulmonary venous pressure leads to transudation of fluid across the alveolar-capillary membrane **(pulmonary edema)** and can cause breaks in the endothelium with extravasation of red blood cells into the alveoli and lung parenchyma. As alveolar macrophages engulf and degrade the extravasated red blood cells, the released iron accumulates as intracellular hemosiderin.

Severe left ventricular systolic dysfunction is associated with an increased risk of fatal ventricular arrhythmia (ie, ventricular tachycardia or fibrillation), which was the likely cause of death in this patient.

(Choices A and C) Silicosis results from chronic inflammation triggered by inhaled particles of crystalline silica. Histopathology typically shows silicotic nodules consisting of whorls of concentric collagen fibers. As with other causes of interstitial lung disease, excessive deposition of extracellular collagen eventually leads to pulmonary fibrosis.

(Choice D) Hyperreactivity of airways to environmental allergens occurs in asthma. Microscopic analysis of sputum may reveal Curschmann spirals, which represent spiral-shaped mucus plugs.

(Choice E) Malignant transformation of bronchial epithelial cells underlies the development of most types of lung cancer. Histopathology typically shows hyperchromatic nuclei and poorly organized cell structure, such as in squamous cell carcinoma of the lung.

(Choice F) Neutrophil elastase-mediated alveolar septal destruction underlies the pathogenesis of emphysema, which can occur with smoking or alpha-1 antitrypsin deficiency. Microscopy shows cystic enlargement of the airspaces with loss of the normal lobular architecture.

Educational objective:
Left-sided heart failure leads to chronically elevated pulmonary venous and capillary pressures, with resulting pulmonary edema and extravasation of red blood cells into the alveolar parenchyma. The iron from red blood cells is taken up by alveolar macrophages and stored as hemosiderin, appearing as brown pigment on histopathology.

Physiology	Cardiovascular System	Chronic heart failure
Subject	System	Topic

Copyright © UWorld. All rights reserved.

Exhibit Display

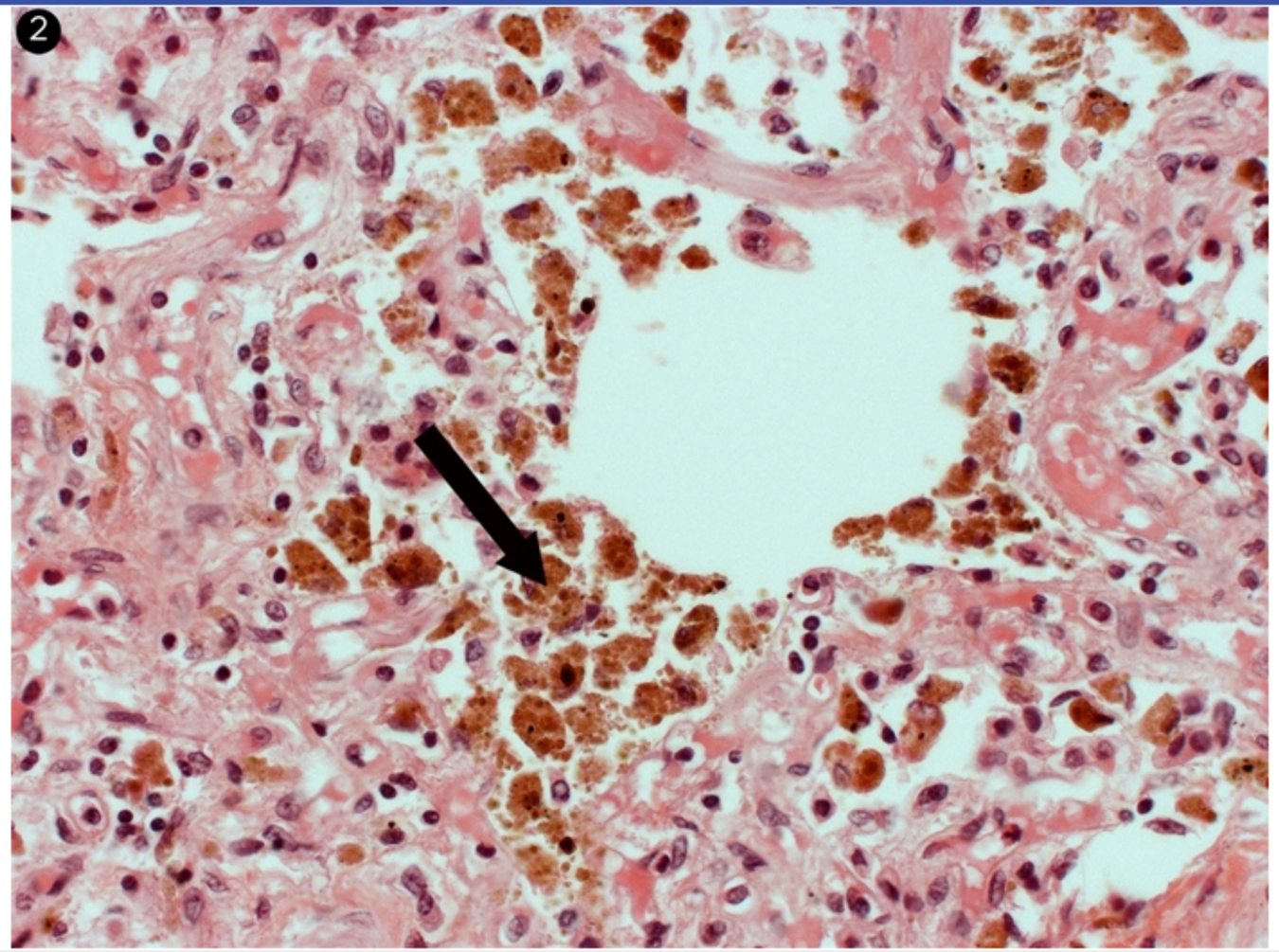

Zoom In | Zoom Out | Reset | Add To New Card | Existing Card

Copyright © UWorld. All rights reserved.

4
5
6
7
8
9
10
11
12
13
14
15
16
17
18
19
20
21
22
23
24
25
26
27
28
29
30
31
32
33
34

Exhibit Display

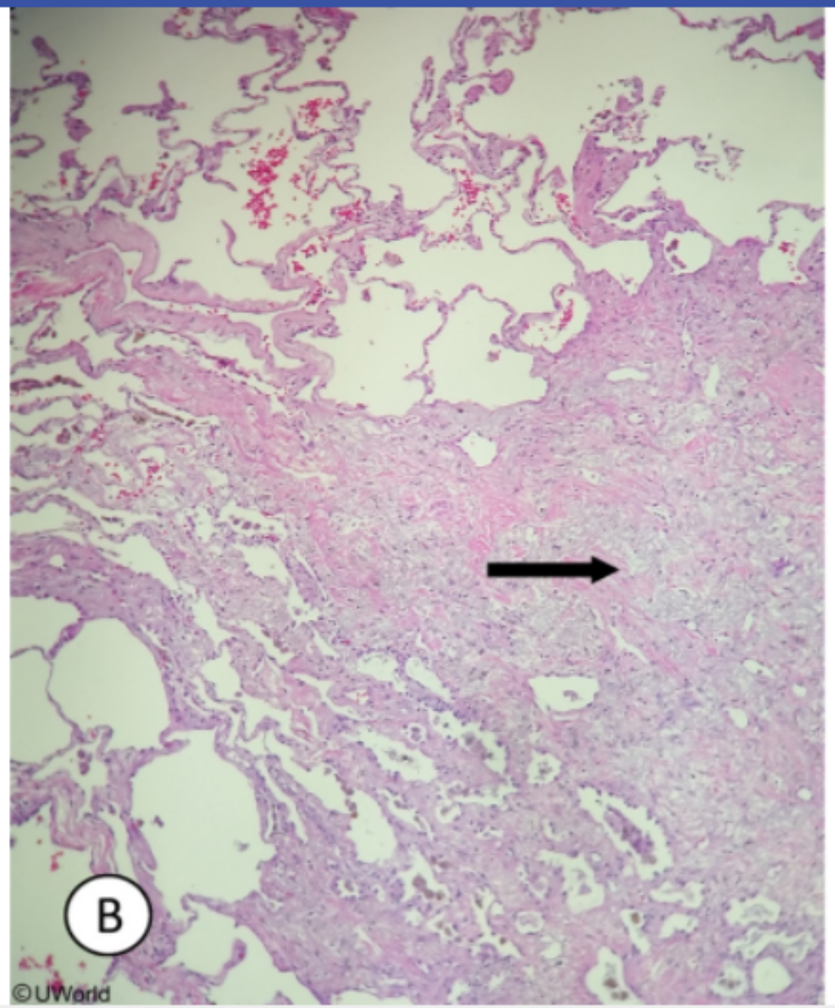

Zoom In | Zoom Out | Reset | Add To New Card | Existing Card

Copyright © UWorld. All rights reserved.

Exhibit Display

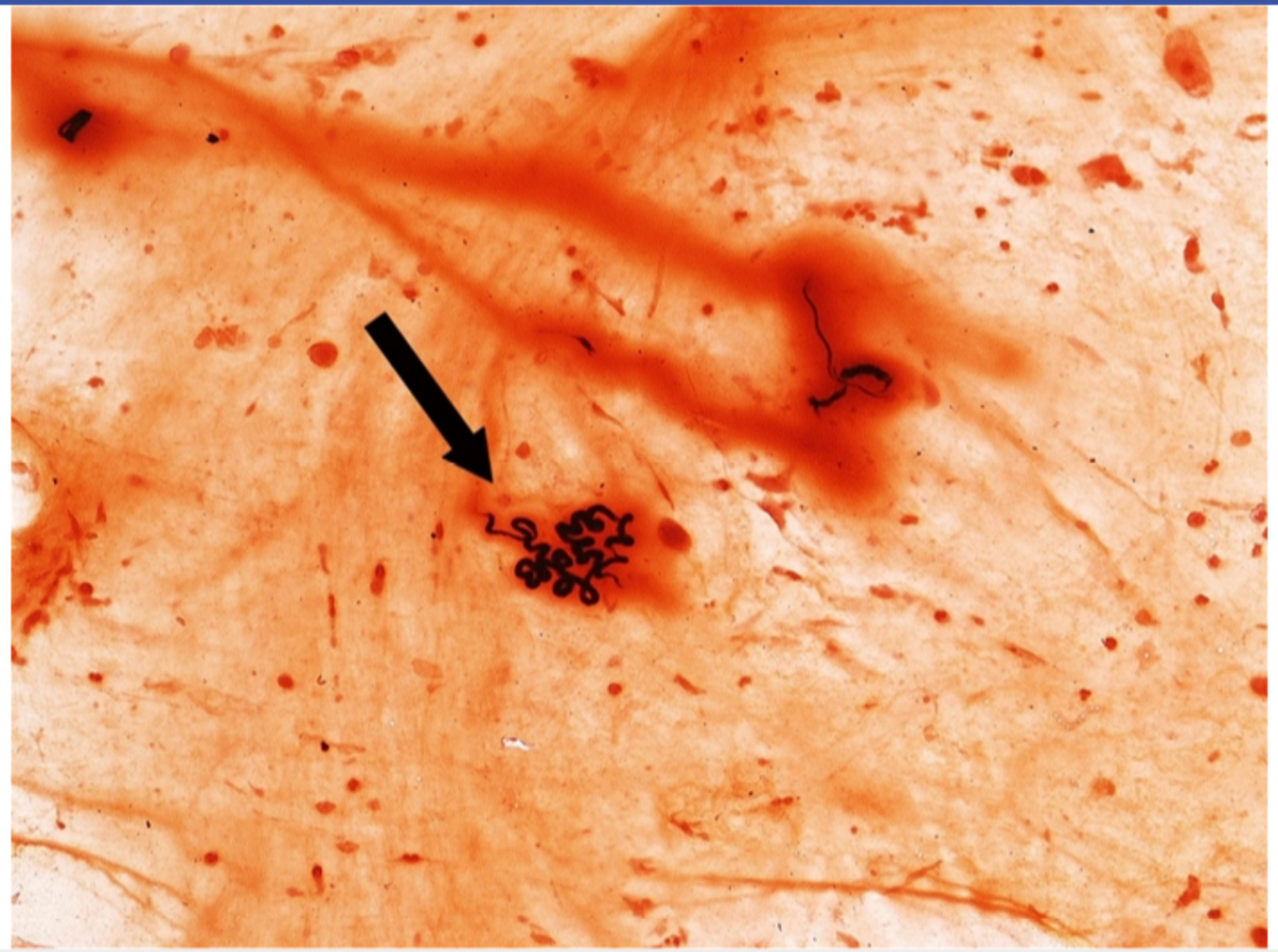

Zoom In | Zoom Out | Reset | Add To New Card | Existing Card

Copyright © UWorld. All rights reserved.

Exhibit Display

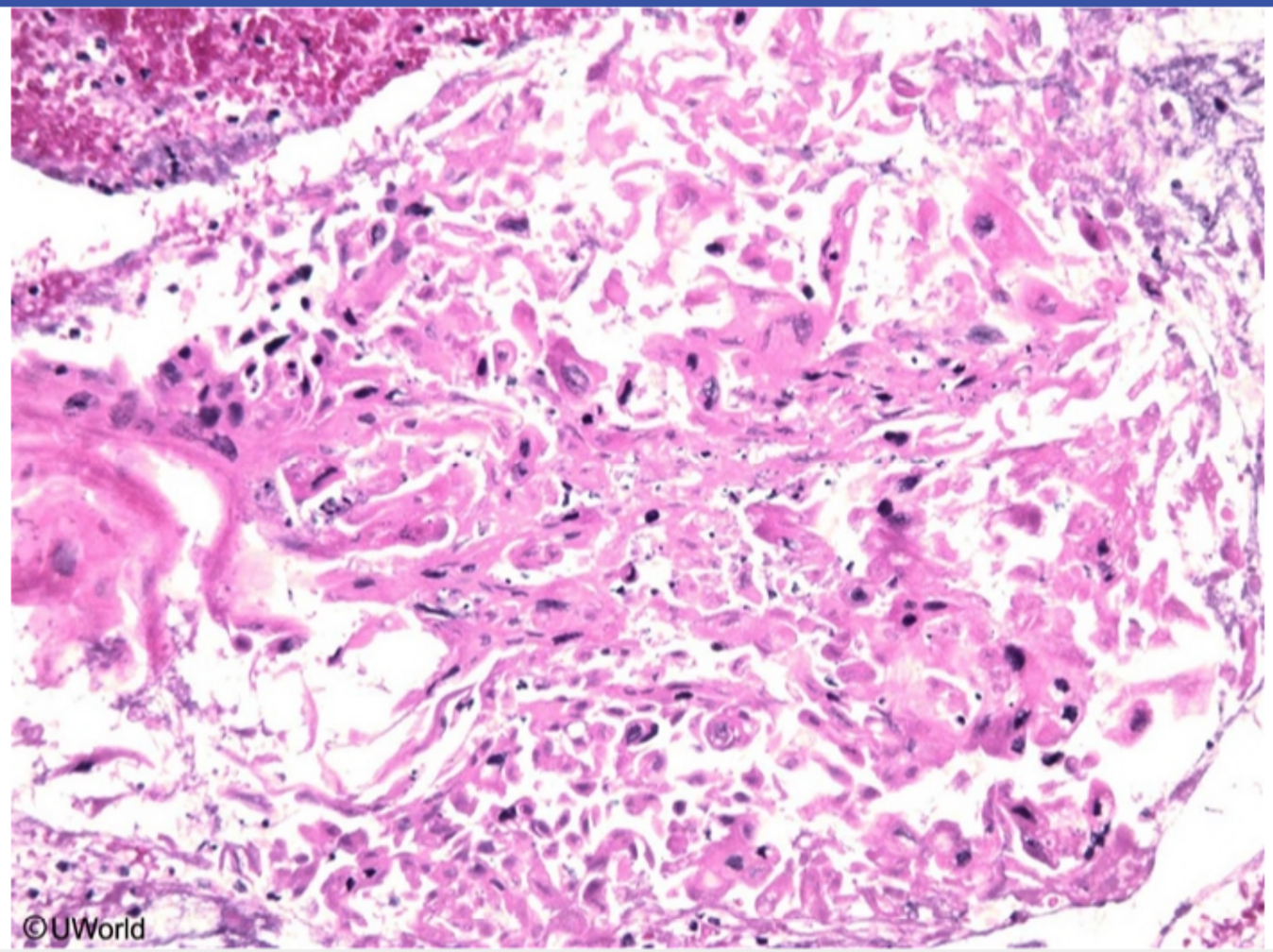

Zoom In | Zoom Out | Reset | Add To New Card | Existing Card

Copyright © UWorld. All rights reserved.

A 32-year-old woman comes to the office for preconception medical evaluation. She feels well, reports no health concerns, and has had regular menstruation periods. The patient is an elite long-distance swimmer and recently retired from a professional career of 10 years. She continues to swim regularly. The patient does not use tobacco, alcohol, or illicit drugs. Blood pressure is 114/66 mm Hg and pulse is 60/min. Physical examination shows no abnormalities. Compared to a person of similar age and sex with a sedentary lifestyle, which set of the following cardiac changes is most likely present in this patient?

	Left ventricular ejection fraction	Left ventricle cavity size	Maximum cardiac output
A.	Decreased	Increased	Increased
B.	Increased	Decreased	Increased
C.	Increased	Decreased	Unchanged
D.	Unchanged	Increased	Increased
E.	Decreased	Unchanged	Unchanged

Submit

A 32-year-old woman comes to the office for preconception medical evaluation. She feels well, reports no health concerns, and has had regular menstruation periods. The patient is an elite long-distance swimmer and recently retired from a professional career of 10 years. She continues to swim regularly. The patient does not use tobacco, alcohol, or illicit drugs. Blood pressure is 114/66 mm Hg and pulse is 60/min. Physical examination shows no abnormalities. Compared to a person of similar age and sex with a sedentary lifestyle, which set of the following cardiac changes is most likely present in this patient?

	Left ventricular ejection fraction	Left ventricle cavity size	Maximum cardiac output
A. (4%)	Decreased	Increased	Increased
B. (43%)	Increased	Decreased	Increased
C. (5%)	Increased	Decreased	Unchanged
✓ D. (44%)	Unchanged	Increased	Increased
E. (2%)	Decreased	Unchanged	Unchanged

Omitted
Correct answer
D

44%
Answered correctly

02 secs
Time Spent

06/26/2020
Last Updated

Explanation

Explanation

Resting cardiac output is approximately 5 L/min and commonly increases to 15-20 L/min with exercise. The cardiac output of highly trained athletes with the characteristic cardiovascular adaptations of **athlete's heart** is often increased to 35-40 L/min. Maximum heart rate does not significantly increase in highly trained athletes; therefore, the **increased maximum cardiac output** is due primarily to **increased stroke volume** (cardiac output = stroke volume × heart rate).

To meet the metabolic demands of frequent and intense **endurance training** (eg, long-distance swimming), the body gradually increases both red blood cell mass and plasma volume to increase oxygen-carrying capacity. In addition, skeletal muscles develop increased arteriolar and capillary density, which improves oxygen uptake and causes overall **reduced systemic vascular resistance** (SVR).

Both increased blood volume and reduced SVR contribute to increased cardiac venous return (ie, preload), which places increased volume load on the left ventricle. In response, the left ventricle undergoes physiologic eccentric hypertrophy to **increase left ventricular cavity size** and muscle mass, improving diastolic filling capacity. The resulting increase in end-diastolic volume capacity is the primary driver of the marked increase in stroke volume that occurs with endurance training. Because end-diastolic volume and stroke volume are both proportionally increased, **left ventricular ejection fraction** is mostly **unchanged**.

The right ventricle also undergoes similar cavity enlargement to support the increase in maximum cardiac output.

Educational objective:
With endurance training, the physiologic changes of athlete's heart allow for increased maximum cardiac output via an increase in stroke volume. The left ventricle undergoes eccentric hypertrophy to increase left ventricular cavity size and improve diastolic filling capacity. The resulting increase in end-diastolic volume capacity allows for increased stroke volume and cardiac output. Because end-diastolic volume and stroke volume are both proportionally increased, left ventricular ejection fraction is mostly unchanged.

Physiology	Cardiovascular System	Physical exercise
Subject	System	Topic

Copyright © UWorld. All rights reserved.

Exhibit Display

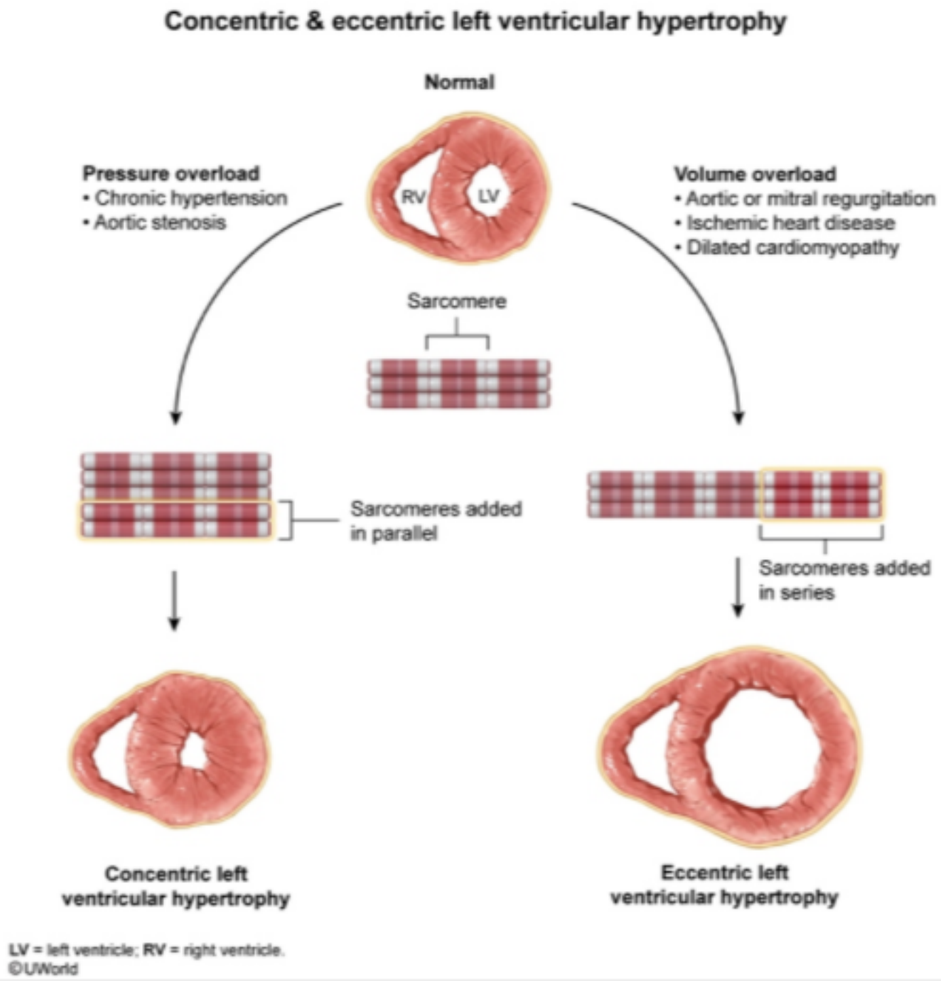

Zoom In Zoom Out Reset Add To Flash Card

Exhibit Display

Stroke volume & ejection fraction

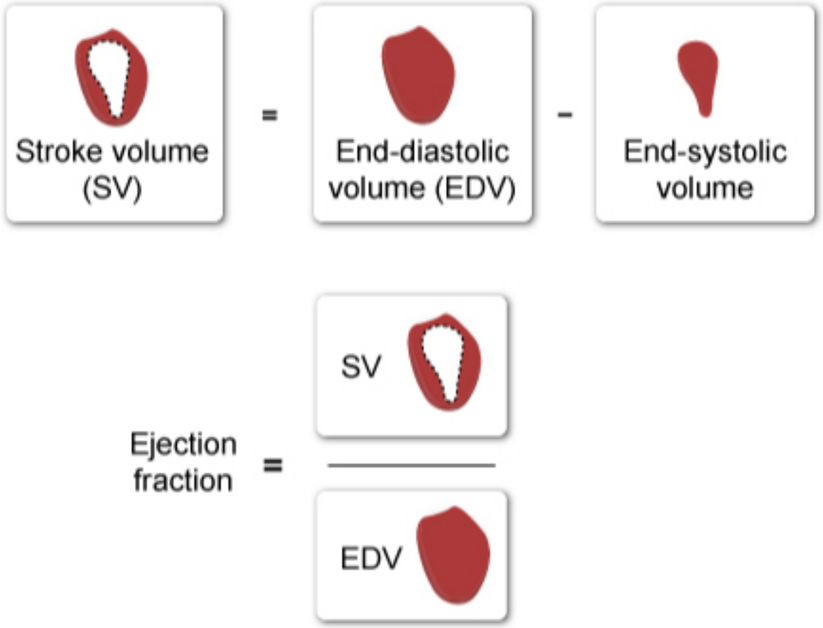

©UWorld

Zoom In Zoom Out Reset Add To Flash Card

A multinational research institute conducting experiments on human circulatory physiology enrolls a healthy 30-year-old male volunteer to assess the oxygen consumption rate of various organs. During the study, the blood oxygen content of the aorta and several other vessels is measured at rest. The greatest difference in these measurements will most likely be between the aorta and which of the following blood vessels?

- A. Brachial vein
- B. Coronary sinus
- C. Internal jugular vein
- D. Portal vein
- E. Pulmonary artery
- F. Renal vein

Submit

A multinational research institute conducting experiments on human circulatory physiology enrolls a healthy 30-year-old male volunteer to assess the oxygen consumption rate of various organs. During the study, the blood oxygen content of the aorta and several other vessels is measured at rest. The greatest difference in these measurements will most likely be between the aorta and which of the following blood vessels?

- A. Brachial vein (1%)
- ✓ B. Coronary sinus (29%)
- C. Internal jugular vein (8%)
- D. Portal vein (4%)
- E. Pulmonary artery (52%)
- F. Renal vein (3%)

Omitted
Correct answer
B

29%
Answered correctly

02 secs
Time Spent

02/24/2020
Last Updated

Explanation

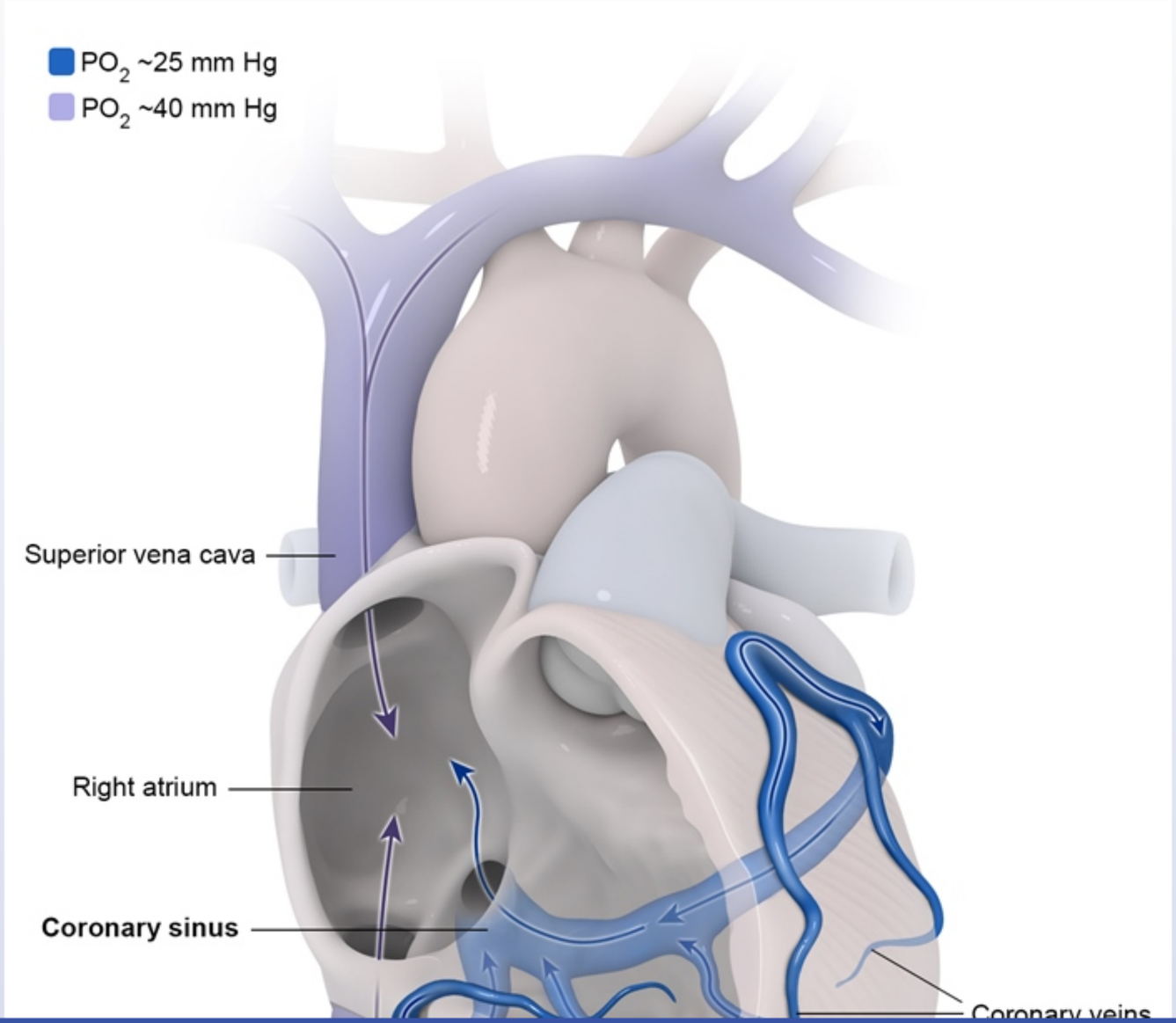
PO_2 ~25 mm Hg
PO_2 ~40 mm Hg
Superior vena cava
Right atrium
Coronary sinus
Coronary veins

4
5
6
7
8
9
10
11
12
13
14
15
16
17
18
19
20
21
22
23
24
25
26
27
28
29
30
31
32
33
34

Exhibit Display

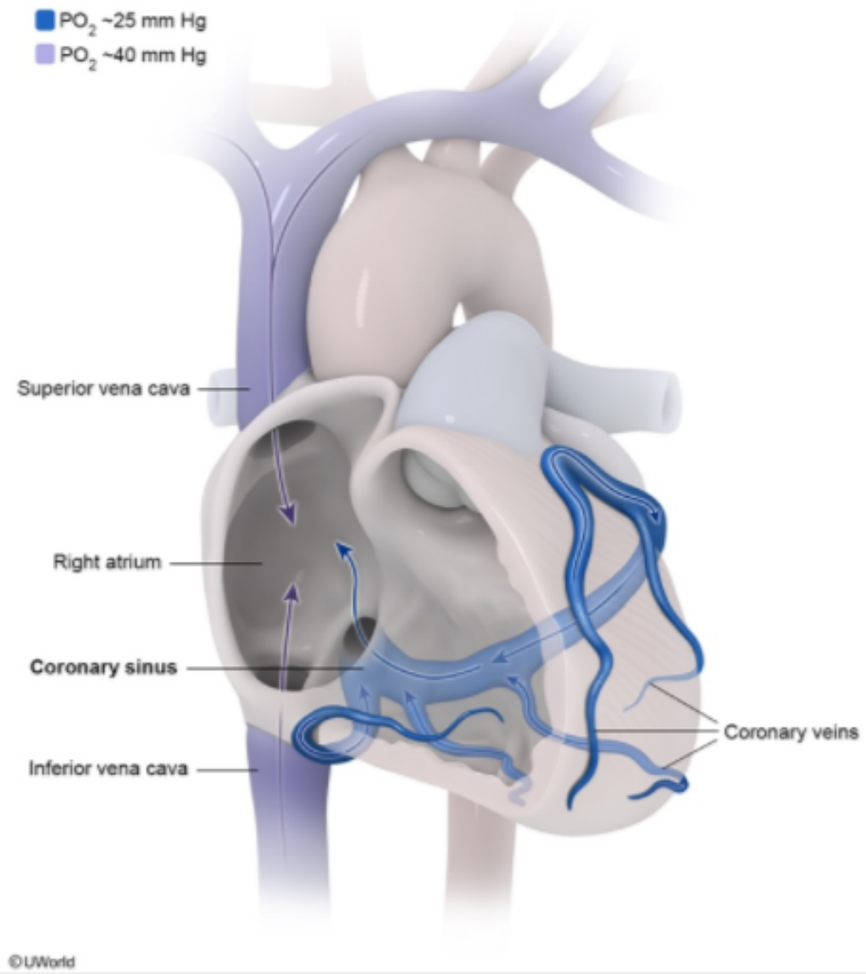

Zoom In | Zoom Out | Reset | Add To New Card | Existing Card

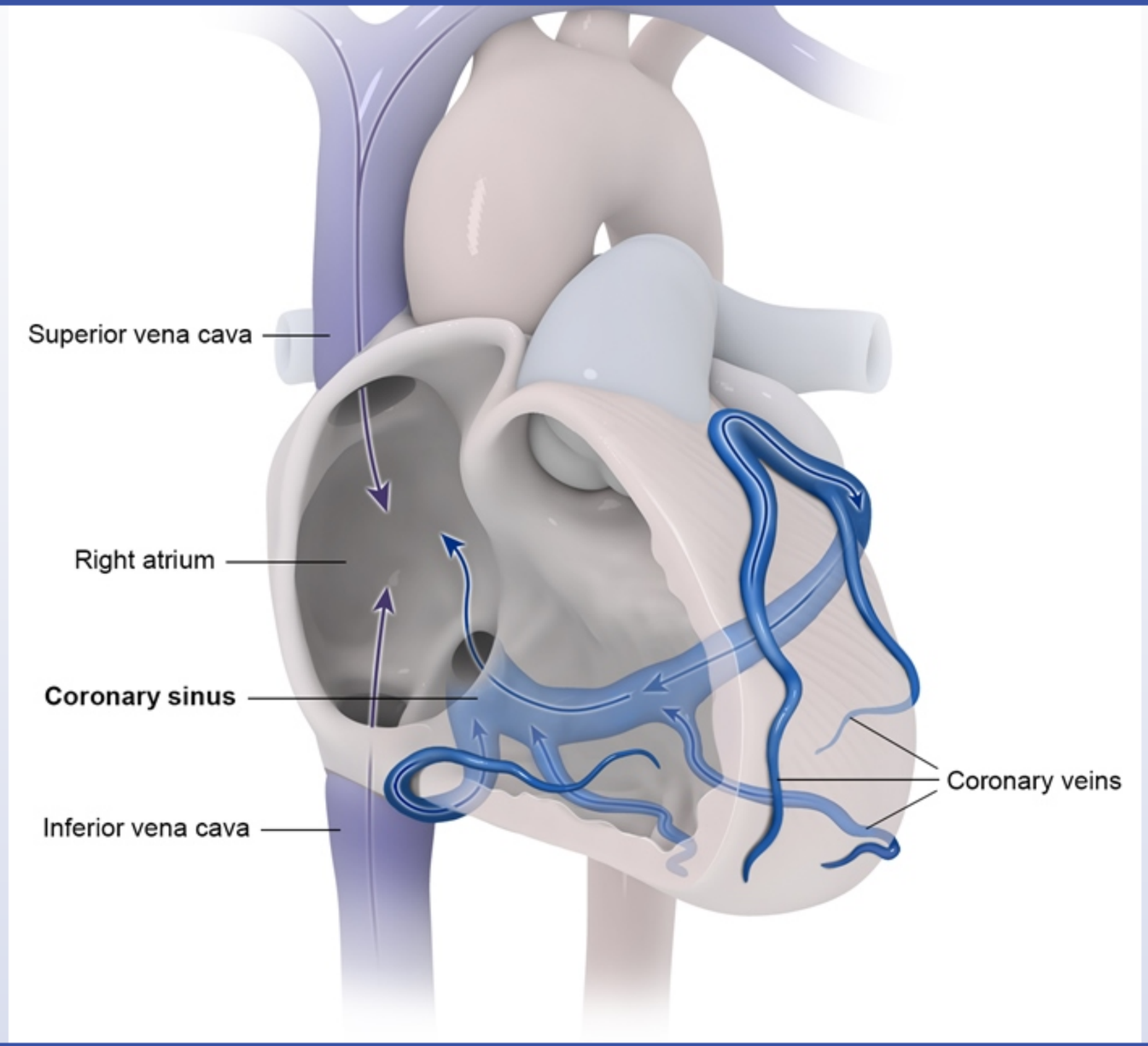
Superior vena cava
Right atrium
Coronary sinus
Inferior vena cava
Coronary veins

Arterial blood supply to the cardiac muscle (myocardium) is provided by the right and left coronary arteries arising directly from the aortic root. Most cardiac venous blood drains into the right atrium via the **coronary sinus**, with the remainder draining directly into the other chambers of the heart. Three specific features distinguish cardiac circulation from blood flow to skeletal muscle and viscera:

1. **The left ventricle is perfused only during diastole.** Myocardial contraction during systole leads to compression of the coronary vessels and disruption of blood flow. Wall tension is highest near the endocardium, making the subendocardial region the most prone to ischemia.
2. **Myocardial oxygen extraction is very high.** The heart has a capillary density far exceeding that of skeletal muscle. Oxygen extraction from arterial blood is very effective within the heart as the resting myocardium extracts 60%-75% of oxygen from blood. This amount is higher than that extracted by any other tissue or organ in the body. As a result, the cardiac venous blood in the coronary sinus, before it reaches the right atrium and mixes with blood returning from the systemic circulation, is the most deoxygenated blood in the body **(Choices A, C, D, and F)**.
3. **Myocardial oxygen demand and coronary blood flow are tightly coupled.** Because oxygen extraction by the resting heart is already very high, there is little capacity to increase myocardial oxygen extraction during periods of increased oxygen demand (eg, during exercise). Therefore, increased oxygen delivery to the heart can be achieved only through increased **coronary blood flow**. Adenosine and nitric oxide are the most important vasodilators responsible for increasing coronary flow.

(Choice E) Deoxygenated systemic blood returning via the vena cava contains more oxygen than coronary sinus venous blood. Because the pulmonary artery contains an admixture of blood returning via coronary sinus and systemic venous circulation, its oxygen content is also higher than pure coronary venous return.

Educational objective:
Myocardial oxygen extraction exceeds that of any other tissue or organ; therefore, the cardiac venous blood in the coronary sinus is the most deoxygenated blood in the body. Due to the high degree of oxygen extraction, increases in myocardial oxygen demand can only be met by an increase in coronary blood flow.

References

- Regulation of coronary blood flow during exercise.

Physiology Cardiovascular System Coronary blood flow

1. **The left ventricle is perfused only during diastole.** Myocardial contraction during systole leads to compression of the coronary vessels and disruption of blood flow. Wall tension is highest near the endocardium, making the subendocardial region the most prone to ischemia.

2. **Myocardial oxygen extraction is very high.** The heart has a capillary density far exceeding that of skeletal muscle. Oxygen extraction from arterial blood is very effective within the heart as the resting myocardium extracts 60%-75% of oxygen from blood. This amount is higher than that extracted by any other tissue or organ in the body. As a result, the cardiac venous blood in the coronary sinus, before it reaches the right atrium and mixes with blood returning from the systemic circulation, is the most deoxygenated blood in the body **(Choices A, C, D, and F)**.

3. **Myocardial oxygen demand and coronary blood flow are tightly coupled.** Because oxygen extraction by the resting heart is already very high, there is little capacity to increase myocardial oxygen extraction during periods of increased oxygen demand (eg, during exercise). Therefore, increased oxygen delivery to the heart can be achieved only through increased **coronary blood flow**. Adenosine and nitric oxide are the most important vasodilators responsible for increasing coronary flow.

(Choice E) Deoxygenated systemic blood returning via the vena cava contains more oxygen than coronary sinus venous blood. Because the pulmonary artery contains an admixture of blood returning via coronary sinus and systemic venous circulation, its oxygen content is also higher than pure coronary venous return.

Educational objective:
Myocardial oxygen extraction exceeds that of any other tissue or organ; therefore, the cardiac venous blood in the coronary sinus is the most deoxygenated blood in the body. Due to the high degree of oxygen extraction, increases in myocardial oxygen demand can only be met by an increase in coronary blood flow.

References

- Regulation of coronary blood flow during exercise.

Physiology	Cardiovascular System	Coronary blood flow
Subject	System	Topic

Copyright © UWorld. All rights reserved.

A 65-year-old woman is brought to the hospital due to sudden-onset chest heaviness and shortness of breath that began an hour ago. Her medical history is significant for type 2 diabetes mellitus, obesity, and hypertension. Temperature is 36.7 C (98.1 F), blood pressure is 80/50 mm Hg, pulse is 110/min, and respirations are 20/min. Extremities are cold and clammy. Diaphoresis is present. ECG shows ST-segment elevation in the anterior leads. Which of the following hemodynamic changes are most likely present in this patient?

	Cardiac contractility	Systemic vascular resistance	Pulmonary artery systolic pressure
A.	Decreased	Decreased	Decreased
B.	Decreased	Increased	Decreased
C.	Decreased	Increased	Increased
D.	Increased	Decreased	Decreased
E.	Increased	Increased	Increased

Submit

A 65-year-old woman is brought to the hospital due to sudden-onset chest heaviness and shortness of breath that began an hour ago. Her medical history is significant for type 2 diabetes mellitus, obesity, and hypertension. Temperature is 36.7 C (98.1 F), blood pressure is 80/50 mm Hg, pulse is 110/min, and respirations are 20/min. Extremities are cold and clammy. Diaphoresis is present. ECG shows ST-segment elevation in the anterior leads. Which of the following hemodynamic changes are most likely present in this patient?

	Cardiac contractility	Systemic vascular resistance	Pulmonary artery systolic pressure
A. (8%)	Decreased	Decreased	Decreased
B. (28%)	Decreased	Increased	Decreased
✓ C. (53%)	Decreased	Increased	Increased
D. (4%)	Increased	Decreased	Decreased
E. (4%)	Increased	Increased	Increased

Omitted
Correct answer
C

53%
Answered correctly

18 secs
Time Spent

05/07/2020
Last Updated

Explanation

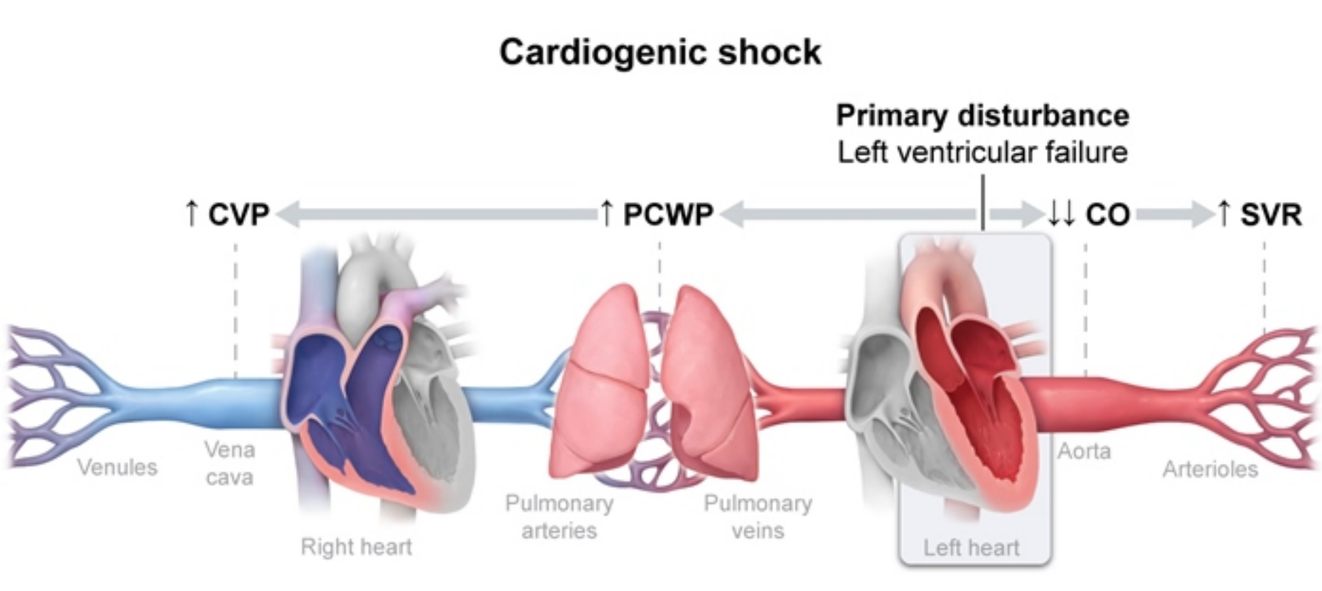

CO = cardiac output; **CVP** = central venous pressure;
PCWP = pulmonary capillary wedge pressure; **SVR** = systemic vascular resistance.

©UWorld

This patient with acute-onset chest heaviness and shortness of breath and ECG showing anterior ST-segment elevation has a **myocardial infarction** (MI). Hypotension and cold and clammy extremities (evidence of poor tissue perfusion) suggest **cardiogenic shock** due to MI-induced acute left ventricular (LV) failure.

A large MI can cause profoundly **decreased cardiac contractility**. The resulting LV systolic failure leads to markedly **reduced cardiac output** and **hypotension**. In response to the hypotension, the aortic and carotid baroreceptors stimulate peripheral vasoconstriction to **increase systemic vascular resistance** in an effort to maintain blood pressure. Heart rate is also increased (ie, tachycardia) to help increase cardiac output.

Failure to eject blood from the left ventricle also increases LV end-diastolic pressure, which is transmitted backward to **increase pulmonary capillary wedge pressure** (an estimate of left atrial pressure) and cause pulmonary edema. This increase in pulmonary venous pressure also necessitates **higher pulmonary arterial systolic pressure** to maintain forward blood movement, which may precipitate acute right ventricular

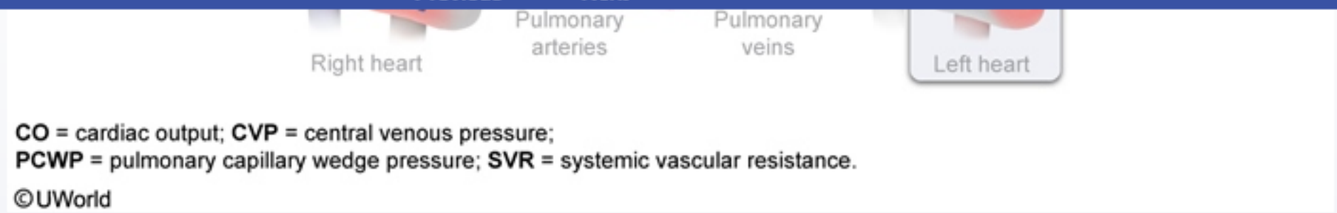

CO = cardiac output; **CVP** = central venous pressure;
PCWP = pulmonary capillary wedge pressure; **SVR** = systemic vascular resistance.

©UWorld

This patient with acute-onset chest heaviness and shortness of breath and ECG showing anterior ST-segment elevation has a **myocardial infarction** (MI). Hypotension and cold and clammy extremities (evidence of poor tissue perfusion) suggest **cardiogenic shock** due to MI-induced acute left ventricular (LV) failure.

A large MI can cause profoundly **decreased cardiac contractility**. The resulting LV systolic failure leads to markedly **reduced cardiac output** and **hypotension**. In response to the hypotension, the aortic and carotid baroreceptors stimulate peripheral vasoconstriction to **increase systemic vascular resistance** in an effort to maintain blood pressure. Heart rate is also increased (ie, tachycardia) to help increase cardiac output.

Failure to eject blood from the left ventricle also increases LV end-diastolic pressure, which is transmitted backward to **increase pulmonary capillary wedge pressure** (an estimate of left atrial pressure) and cause pulmonary edema. This increase in pulmonary venous pressure also necessitates **higher pulmonary arterial systolic pressure** to maintain forward blood movement, which may precipitate acute right ventricular failure.

Educational objective:
Myocardial infarction may cause acute left ventricular (LV) failure and cardiogenic shock. Decreased cardiac contractility leads to reduced cardiac output and hypotension. In response, systemic vascular resistance is increased (via peripheral vasoconstriction) to maintain blood pressure. The LV systolic failure increases LV end-diastolic pressure, which is transmitted backward to increase pulmonary capillary wedge pressure and pulmonary arterial pressure.

Physiology	Cardiovascular System	Cardiogenic shock
Subject	System	Topic

Copyright © UWorld. All rights reserved.

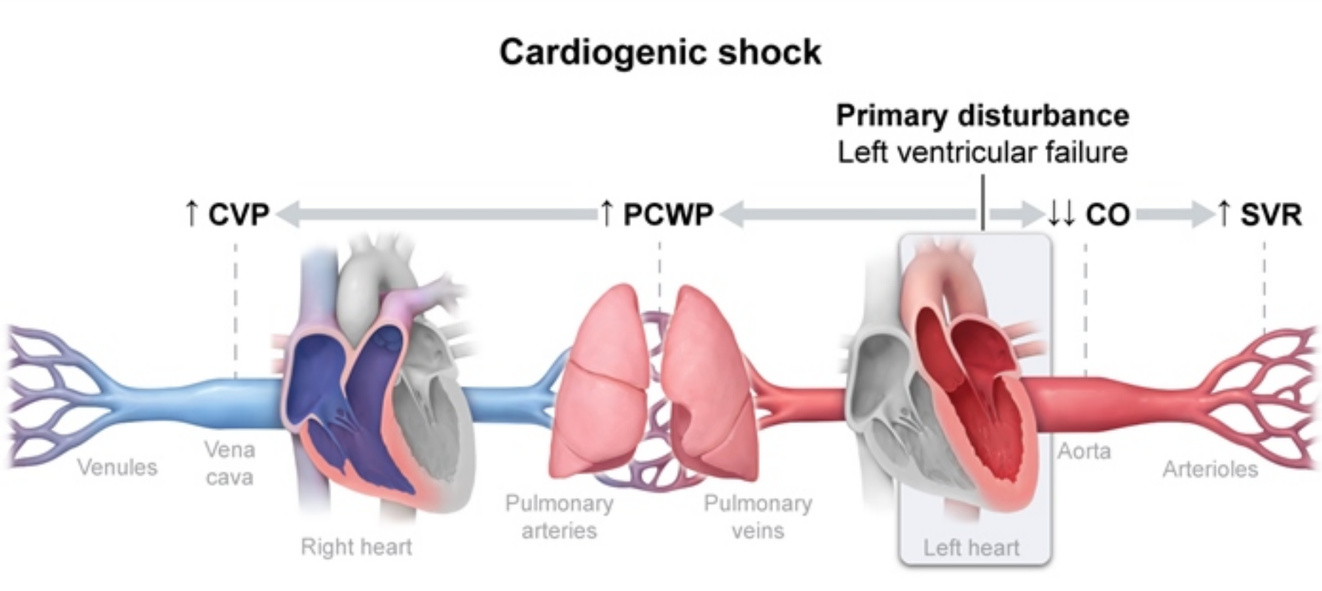

CO = cardiac output; **CVP** = central venous pressure;
PCWP = pulmonary capillary wedge pressure; **SVR** = systemic vascular resistance.

©UWorld

This patient with acute-onset chest heaviness and shortness of breath and ECG showing anterior ST-segment elevation has a **myocardial infarction** (MI). Hypotension and cold and clammy extremities (evidence of poor tissue perfusion) suggest **cardiogenic shock** due to MI-induced acute left ventricular (LV) failure.

A large MI can cause profoundly **decreased cardiac contractility**. The resulting LV systolic failure leads to markedly **reduced cardiac output** and **hypotension**. In response to the hypotension, the aortic and carotid baroreceptors stimulate peripheral vasoconstriction to **increase systemic vascular resistance** in an effort to maintain blood pressure. Heart rate is also increased (ie, tachycardia) to help increase cardiac output.

Failure to eject blood from the left ventricle also increases LV end-diastolic pressure, which is transmitted backward to **increase pulmonary capillary wedge pressure** (an estimate of left atrial pressure) and cause pulmonary edema. This increase in pulmonary venous pressure also necessitates **higher pulmonary arterial systolic pressure** to maintain forward blood movement, which may precipitate acute right ventricular

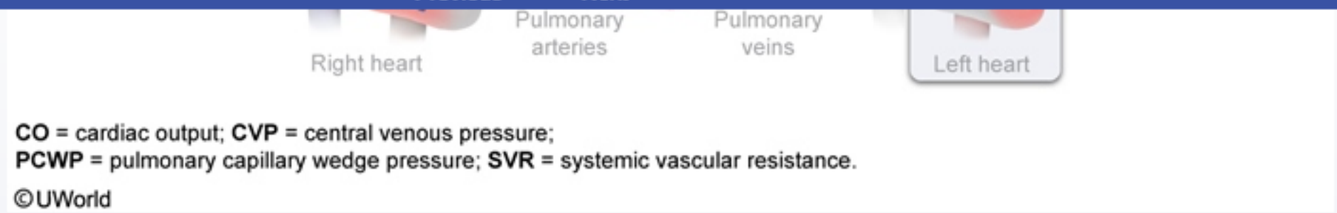

CO = cardiac output; **CVP** = central venous pressure;
PCWP = pulmonary capillary wedge pressure; **SVR** = systemic vascular resistance.

©UWorld

This patient with acute-onset chest heaviness and shortness of breath and ECG showing anterior ST-segment elevation has a **myocardial infarction** (MI). Hypotension and cold and clammy extremities (evidence of poor tissue perfusion) suggest **cardiogenic shock** due to MI-induced acute left ventricular (LV) failure.

A large MI can cause profoundly **decreased cardiac contractility**. The resulting LV systolic failure leads to markedly **reduced cardiac output** and **hypotension**. In response to the hypotension, the aortic and carotid baroreceptors stimulate peripheral vasoconstriction to **increase systemic vascular resistance** in an effort to maintain blood pressure. Heart rate is also increased (ie, tachycardia) to help increase cardiac output.

Failure to eject blood from the left ventricle also increases LV end-diastolic pressure, which is transmitted backward to **increase pulmonary capillary wedge pressure** (an estimate of left atrial pressure) and cause pulmonary edema. This increase in pulmonary venous pressure also necessitates **higher pulmonary arterial systolic pressure** to maintain forward blood movement, which may precipitate acute right ventricular failure.

Educational objective:
Myocardial infarction may cause acute left ventricular (LV) failure and cardiogenic shock. Decreased cardiac contractility leads to reduced cardiac output and hypotension. In response, systemic vascular resistance is increased (via peripheral vasoconstriction) to maintain blood pressure. The LV systolic failure increases LV end-diastolic pressure, which is transmitted backward to increase pulmonary capillary wedge pressure and pulmonary arterial pressure.

Physiology	Cardiovascular System	Cardiogenic shock
Subject	System	Topic

Copyright © UWorld. All rights reserved.

A 45-year-old man comes to the emergency department due to a 2-day history of dyspnea, orthopnea, and ankle swelling. This morning, he also had nausea, vomiting, and a headache. Blood pressure is elevated, and physical examination shows pulmonary crackles and bilateral pitting edema up to the knees. A sodium nitroprusside infusion is begun. Which of the following left ventricular pressure/volume relationships best represents the effects of this therapy?

*Solid line = before nitroprusside; dashed line = during nitroprusside infusion.

A.

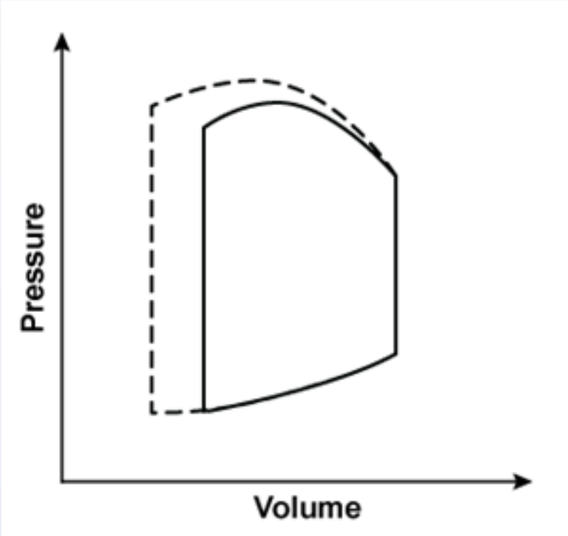

B.

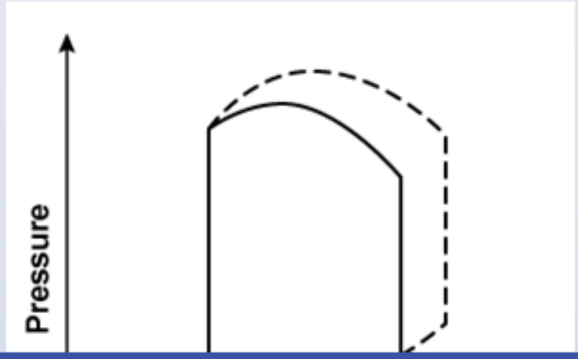

B.

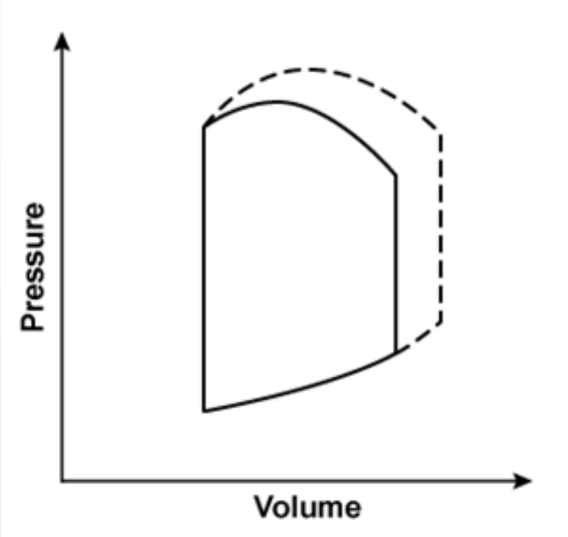

C.

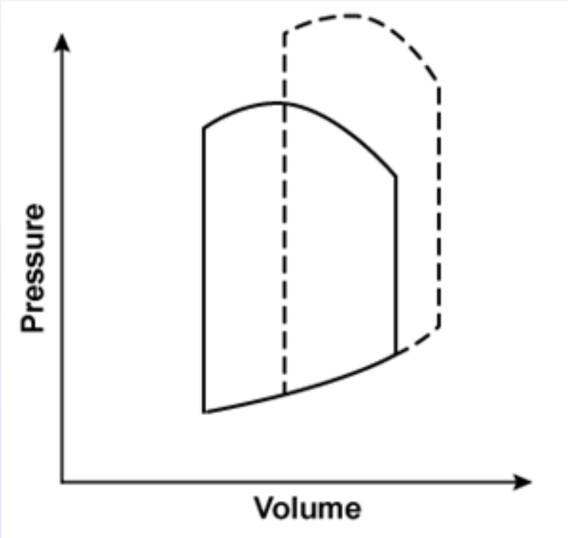

D.

D.

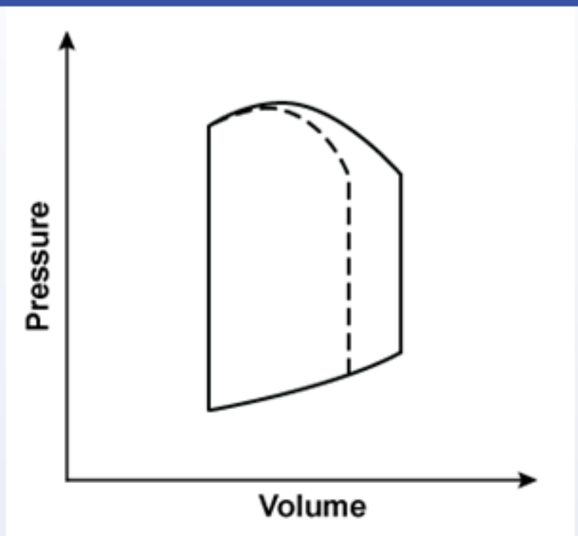

E.

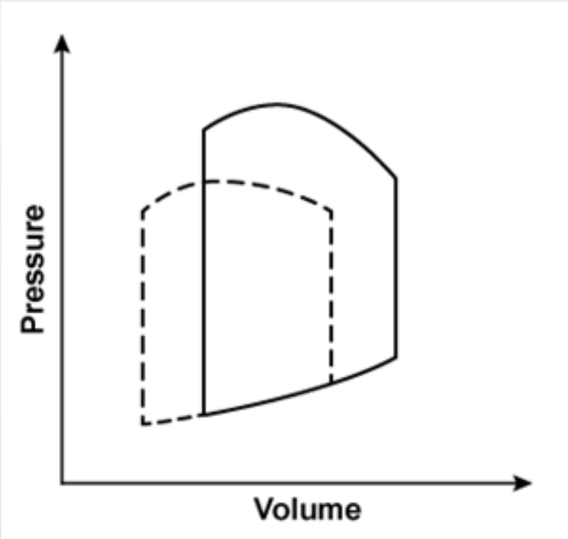

Submit

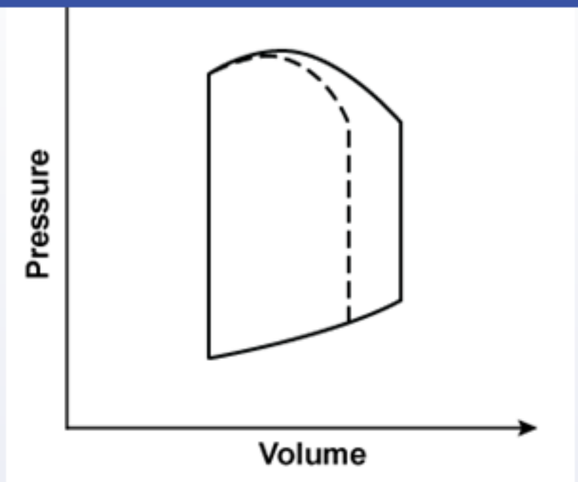

E. (52%)

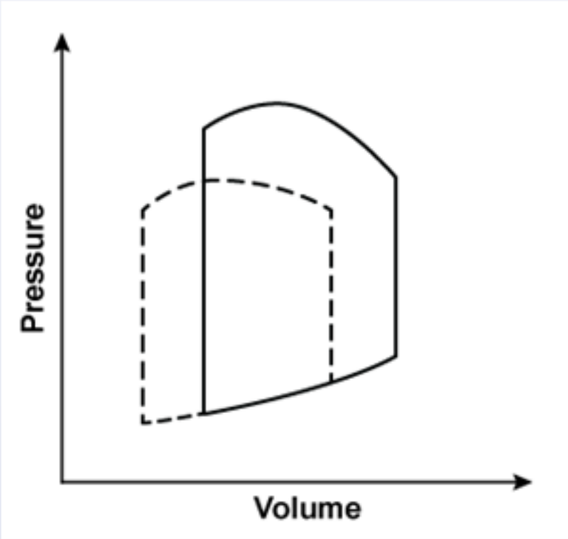

Omitted
Correct answer

52%
Answered correctly

42 secs
Time Spent

02/11/2020
Last Updated

Explanation

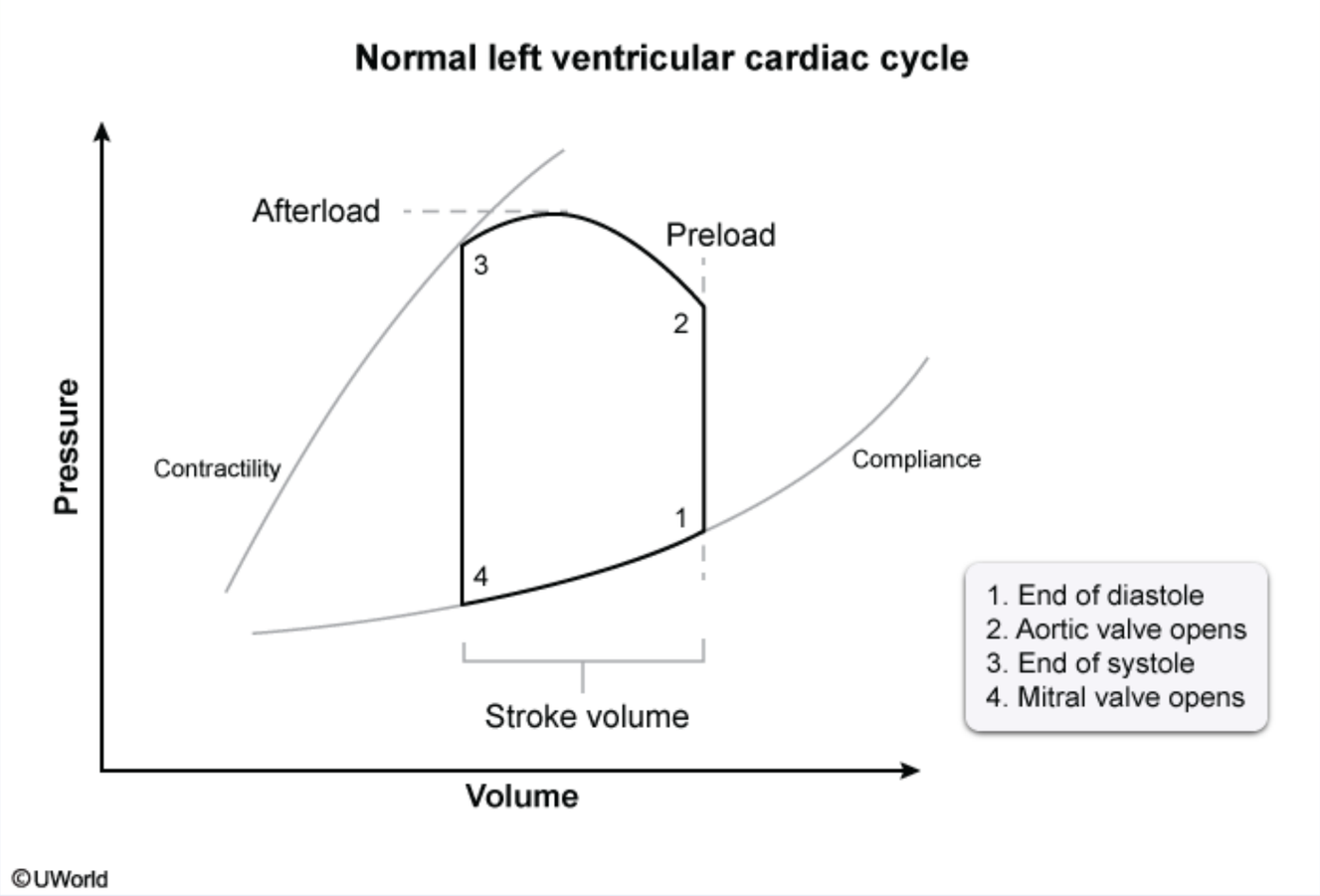

This patient most likely has **acute heart failure** due to **systemic hypertension**, which can be treated with an infusion of **sodium nitroprusside**. Sodium nitroprusside is a short-acting agent that causes **balanced vasodilation** of the veins and arteries; as such, it **decreases** left ventricular (LV) **preload and afterload**, allowing for maintenance of cardiac output (**unchanged stroke volume**) at a lower LV pressure (decreased LV work). LV contractility is essentially unchanged.

Of the choices given, only graph E shows a reduction in both LV end-diastolic volume (preload) and LV systolic pressure (afterload) without a

This patient most likely has **acute heart failure** due to **systemic hypertension**, which can be treated with an infusion of **sodium nitroprusside**. Sodium nitroprusside is a short-acting agent that causes **balanced vasodilation** of the veins and arteries; as such, it **decreases** left ventricular (LV) **preload and afterload**, allowing for maintenance of cardiac output (**unchanged stroke volume**) at a lower LV pressure (decreased LV work). LV contractility is essentially unchanged.

Of the choices given, only graph E shows a reduction in both LV end-diastolic volume (preload) and LV systolic pressure (afterload) without a decrease in stroke volume.

(Choice A) This graph depicts unchanged preload with increased stroke volume due to an increase in LV contractility (point 3 is moved upward and to the left). The slight increase in afterload occurs secondary to the increase in contractility. Such changes are expected with the administration of a positive inotrope with minimal vasodilatory/vasoconstrictive effect (eg, digoxin).

(Choice B) This graph depicts increased preload with an increase in stroke volume and no change in contractility. The increase in afterload is secondary to the increase in stroke volume (higher stroke volume increases systolic pressure). Such changes are consistent with the Frank-Starling response to increased preload.

(Choice C) This graph depicts an increase in preload and afterload with a reduction in stroke volume and no change in contractility. Such changes are detrimental in heart failure and would be expected with a vasoconstrictor affecting both the veins and arteries but with no effect on the myocardium (eg, the alpha-1 agonist phenylephrine).

(Choice D) This graph depicts a decrease in preload and stroke volume with a minimal reduction in afterload and no change in contractility. These changes are expected with predominantly venous dilators such as nitrates (eg, nitroglycerin, isosorbide mononitrate, isosorbide dinitrate). Sodium nitroprusside differs from nitrates in that it generates nitric oxide in the bloodstream rather than in the venous smooth muscle, creating a balanced vasodilatory effect on both the arteries and veins.

Educational objective:
Sodium nitroprusside is a short-acting agent that causes balanced vasodilation of the veins and arteries to decrease both left ventricular (LV) preload and afterload. The balanced vasodilation allows for maintenance of stroke volume and cardiac output at a lower LV pressure (lower cardiac work).

Physiology Cardiovascular System Diastolic dysfunction

work). LV contractility is essentially unchanged.

Of the choices given, only graph E shows a reduction in both LV end-diastolic volume (preload) and LV systolic pressure (afterload) without a decrease in stroke volume.

(Choice A) This graph depicts unchanged preload with increased stroke volume due to an increase in LV contractility (point 3 is moved upward and to the left). The slight increase in afterload occurs secondary to the increase in contractility. Such changes are expected with the administration of a positive inotrope with minimal vasodilatory/vasoconstrictive effect (eg, digoxin).

(Choice B) This graph depicts increased preload with an increase in stroke volume and no change in contractility. The increase in afterload is secondary to the increase in stroke volume (higher stroke volume increases systolic pressure). Such changes are consistent with the Frank-Starling response to increased preload.

(Choice C) This graph depicts an increase in preload and afterload with a reduction in stroke volume and no change in contractility. Such changes are detrimental in heart failure and would be expected with a vasoconstrictor affecting both the veins and arteries but with no effect on the myocardium (eg, the alpha-1 agonist phenylephrine).

(Choice D) This graph depicts a decrease in preload and stroke volume with a minimal reduction in afterload and no change in contractility. These changes are expected with predominantly venous dilators such as nitrates (eg, nitroglycerin, isosorbide mononitrate, isosorbide dinitrate). Sodium nitroprusside differs from nitrates in that it generates nitric oxide in the bloodstream rather than in the venous smooth muscle, creating a balanced vasodilatory effect on both the arteries and veins.

Educational objective:
Sodium nitroprusside is a short-acting agent that causes balanced vasodilation of the veins and arteries to decrease both left ventricular (LV) preload and afterload. The balanced vasodilation allows for maintenance of stroke volume and cardiac output at a lower LV pressure (lower cardiac work).

Physiology	Cardiovascular System	Diastolic dysfunction
Subject	System	Topic

Copyright © UWorld. All rights reserved.

work). LV contractility is essentially unchanged.

Exhibit Display

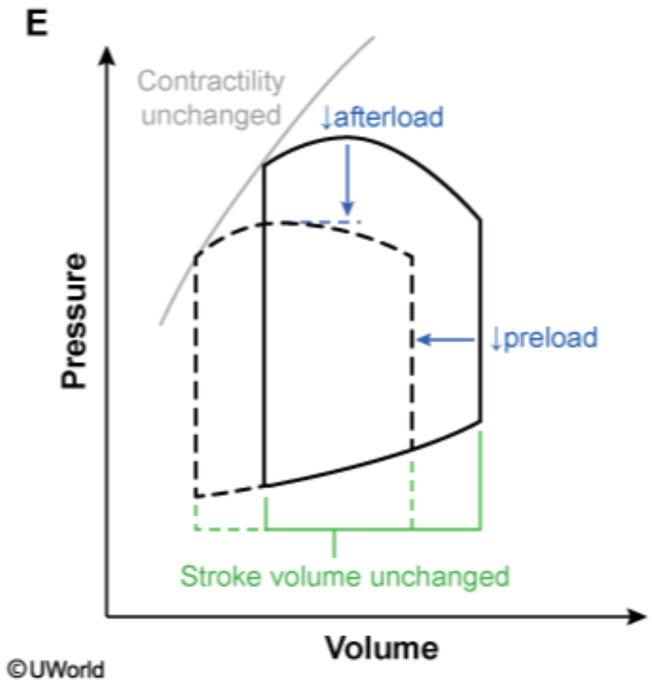

Zoom In | Zoom Out | Reset | Add To New Card | Existing Card

work). LV contractility is essentially unchanged.

Exhibit Display

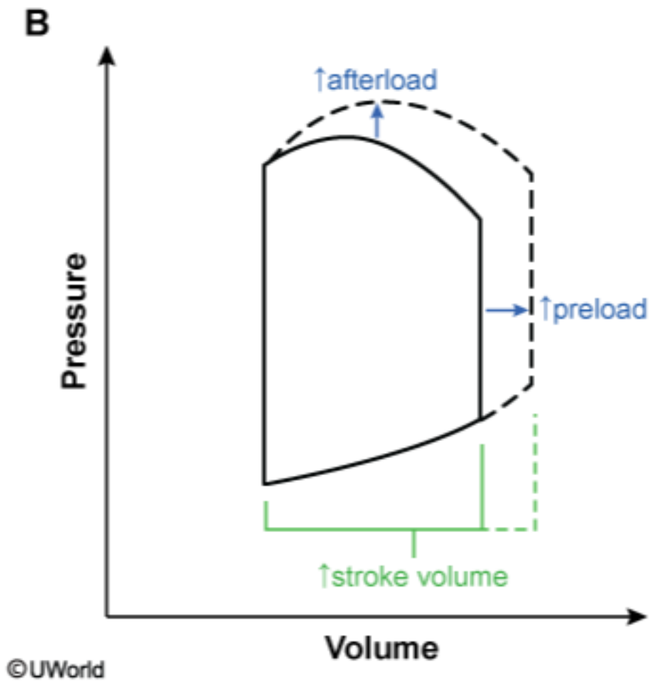

Zoom In Zoom Out Reset Add To New Card | Existing Card

work). LV contractility is essentially unchanged.

Exhibit Display

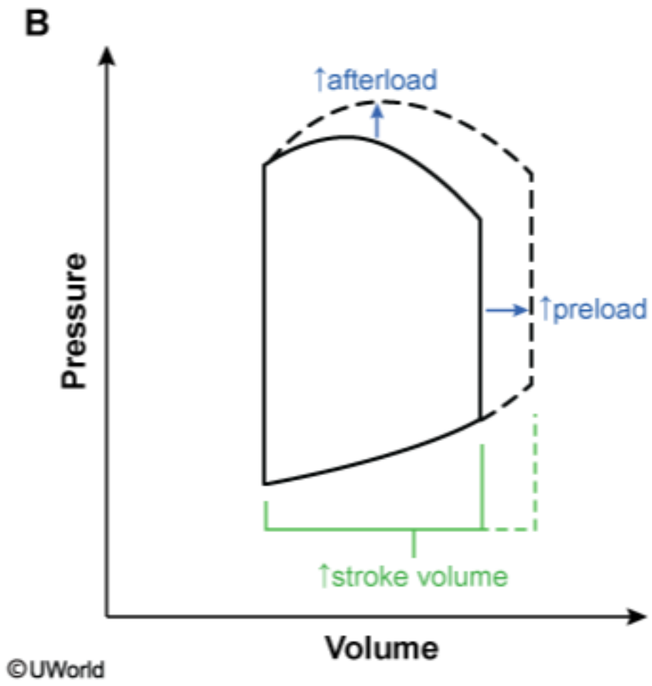

Zoom In Zoom Out Reset Add To New Card | Existing Card

work). LV contractility is essentially unchanged.

Of the choices given, only graph E shows a reduction in both LV end-diastolic volum
decrease in stroke volume.

(Choice A) This graph depicts unchanged preload with increased stroke volume du
and to the left). The slight increase in afterload occurs secondary to the increase in
administration of a positive inotrope with minimal vasodilatory/vasoconstrictive effec

(Choice B) This graph depicts increased preload with an increase in stroke volume
secondary to the increase in stroke volume (higher stroke volume increases systolic
Starling response to increased preload.

(Choice C) This graph depicts an increase in preload and afterload with a reduction
changes are detrimental in heart failure and would be expected with a vasoconstrict
myocardium (eg, the alpha-1 agonist phenylephrine).

(Choice D) This graph depicts a decrease in preload and stroke volume with a mini
These changes are expected with predominantly venous dilators such as nitrates (e
Sodium nitroprusside differs from nitrates in that it generates nitric oxide in the blood
balanced vasodilatory effect on both the arteries and veins.

Educational objective:
Sodium nitroprusside is a short-acting agent that causes balanced vasodilation of th
preload and afterload. The balanced vasodilation allows for maintenance of stroke v
cardiac work).

Physiology	Cardiovascular System	Diastolic dysfunction
Subject	System	Topic

Copyright © UWorld. All rights rese

Exhibit Display

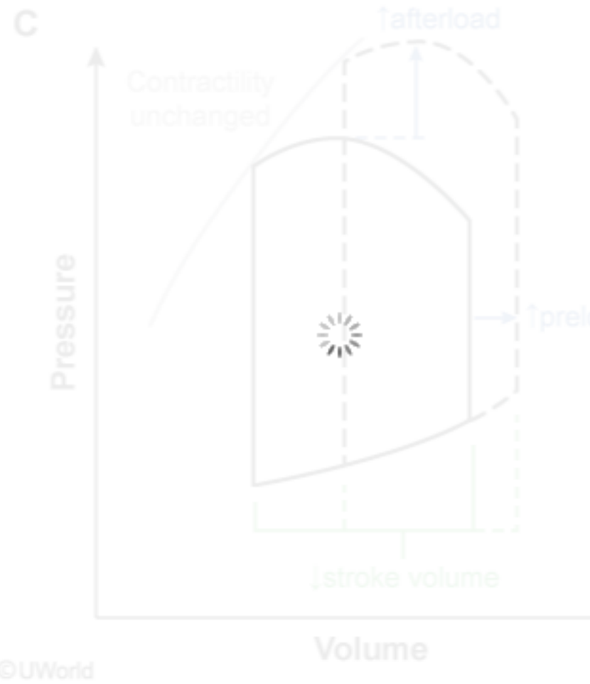

Zoom In
Zoom Out
Reset
Add To New

work). LV contractility is essentially unchanged.

Of the choices given, only graph E shows a reduction in both LV end-diastolic volume (preload) and LV systolic pressure (afterload) without a decrease in stroke v

(Choice A) This gra
and to the left). The
administration of a p

(Choice B) This gra
secondary to the inc
Starling response to

(Choice C) This gra
changes are detrime
myocardium (eg, the

(Choice D) This gra
These changes are
Sodium nitroprussid
balanced vasodilato

Educational object
Sodium nitroprussid
preload and afterloa
cardiac work).

Physiology
Subject

Exhibit Display

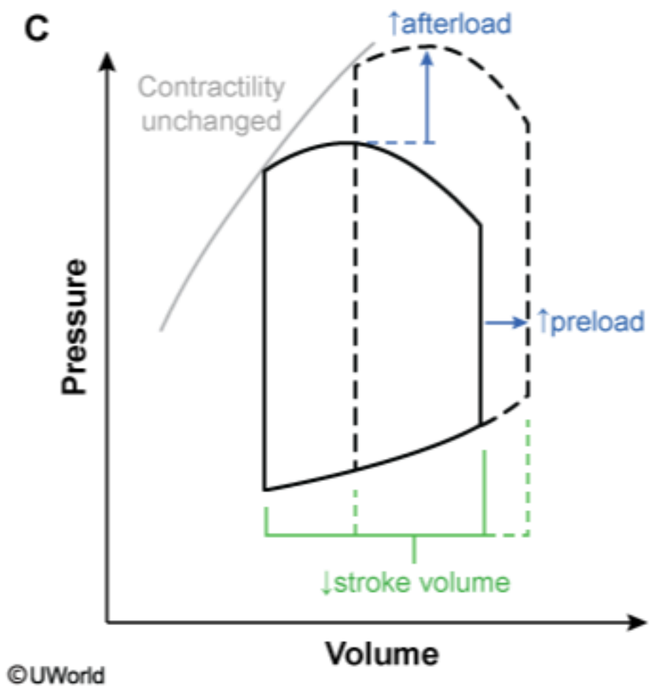

Zoom In | Zoom Out | Reset | Add To New Card | Existing Card

work). LV contractility is essentially unchanged.

Exhibit Display

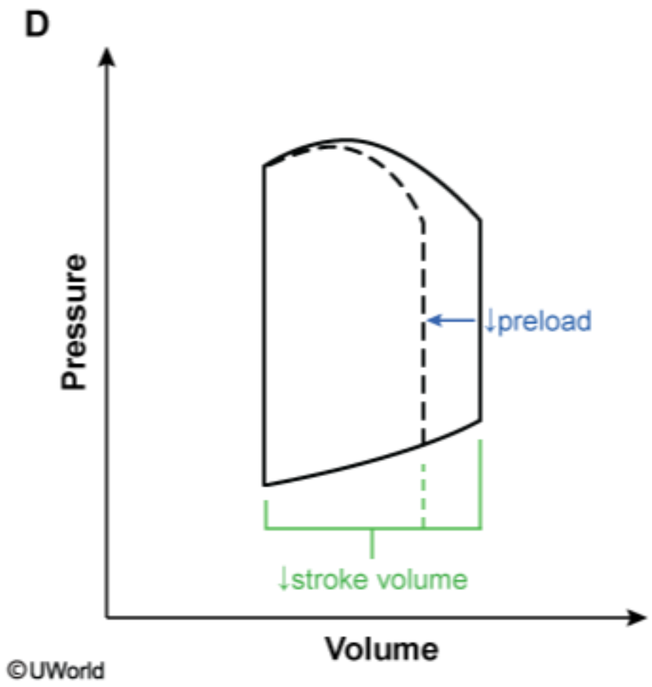

Zoom In | Zoom Out | Reset | Add To New Card | Existing Card

A 70-year-old woman comes to the office due to progressive exertional dyspnea over the last year. She has no chest pain or lower-extremity swelling. The patient has long-standing hypertension but has not always been adherent to her medical regimen. She is a lifetime nonsmoker. Blood pressure is 164/73 mm Hg and pulse is 67/min and regular. An S4 is heard on cardiac auscultation. The lungs are clear. Echocardiogram reveals left atrial enlargement, moderate concentric left ventricular hypertrophy, and a left ventricular ejection fraction of 67%. Which of the following changes are most likely to be seen in this patient?

	Left ventricular compliance	Angiotensin II signaling	Cardiac myosin heavy chain-beta expression
A.	Decreased	Increased	Increased
B.	Decreased	Decreased	Increased
C.	Decreased	Increased	Decreased
D.	Increased	Increased	Increased
E.	Increased	Increased	Decreased
F.	Increased	Decreased	Decreased

Submit

A 70-year-old woman comes to the office due to progressive exertional dyspnea over the last year. She has no chest pain or lower-extremity swelling. The patient has long-standing hypertension but has not always been adherent to her medical regimen. She is a lifetime nonsmoker. Blood pressure is 164/73 mm Hg and pulse is 67/min and regular. An S4 is heard on cardiac auscultation. The lungs are clear. Echocardiogram reveals left atrial enlargement, moderate concentric left ventricular hypertrophy, and a left ventricular ejection fraction of 67%. Which of the following changes are most likely to be seen in this patient?

	Left ventricular compliance	Angiotensin II signaling	Cardiac myosin heavy chain-beta expression
✓ A. (59%)	Decreased	Increased	Increased
B. (26%)	Decreased	Decreased	Increased
C. (8%)	Decreased	Increased	Decreased
D. (2%)	Increased	Increased	Increased
E. (1%)	Increased	Increased	Decreased
F. (0%)	Increased	Decreased	Decreased

Omitted
Correct answer
A

59%
Answered correctly

03 secs
Time Spent

01/26/2020
Last Updated

This patient's clinical presentation and echocardiography findings are consistent with **concentric left ventricular (LV) hypertrophy** leading to **impaired diastolic functioning** (heart failure with preserved ejection fraction).

In response to LV pressure overload (eg, prolonged systemic hypertension), there is **upregulation** of genes encoding for contractile proteins of the cardiac sarcomere, including **beta-myosin heavy chain**. The additional contractile fibers are added in parallel to increase the contractile strength of the LV wall. Although LV contractility and ejection fraction are increased, the thickened LV walls are now stiff and less compliant, which is often evidenced by an S4 on cardiac auscultation as blood strikes the stiff LV wall during atrial systole.

Subsequent impaired diastolic filling of the **noncompliant left ventricle** leads to reduced cardiac output and decreased renal perfusion. Sensing a need to increase blood volume and organ perfusion, the kidneys activate the renin-angiotensin-aldosterone system (RAAS) to stimulate sodium retention (via increased aldosterone) and vasoconstriction (via **increased angiotensin II**). Although this response can temporarily maintain cardiac output, increasing fluid retention will ultimately precipitate decompensated heart failure.

(Choices B, C, E, and F) These combinations of changes in LV compliance, angiotensin II signaling, and beta-myosin heavy chain expression are not consistent with readily identifiable, untreated disease processes.

(Choice D) Increases in LV compliance, angiotensin II signaling, and beta-myosin heavy chain expression are consistent with heart failure with reduced ejection fraction due to dilated cardiomyopathy. There is upregulation of contractile proteins; however, this occurs in response to volume overload rather than pressure overload, and therefore the contractile fibers are added in series (ie, eccentric hypertrophy) rather than in parallel. There is dilation of the LV cavity with increased compliance. Impaired LV systolic function leads to reduced cardiac output with subsequent activation of the RAAS and increased angiotensin II signaling.

Educational objective:
Prolonged systemic hypertension leads to concentric left ventricular (LV) hypertrophy via the addition of myocardial contractile fibers in parallel. The thickening of the LV walls reduces LV compliance, leading to impaired diastolic filling and heart failure with preserved ejection fraction. In response to reduced cardiac output, the kidneys activate the renin-angiotensin-aldosterone system, stimulating sodium retention and vasoconstriction that worsens volume overload and can lead to decompensated heart failure.

Physiology	Cardiovascular System	Diastolic dysfunction
Subject	System	Topic

This patient's clinical presentation and echocardiography findings are consistent with **concentric left ventricular (LV) hypertrophy** leading to

Exhibit Display

Cardiac sarcomere protein structure

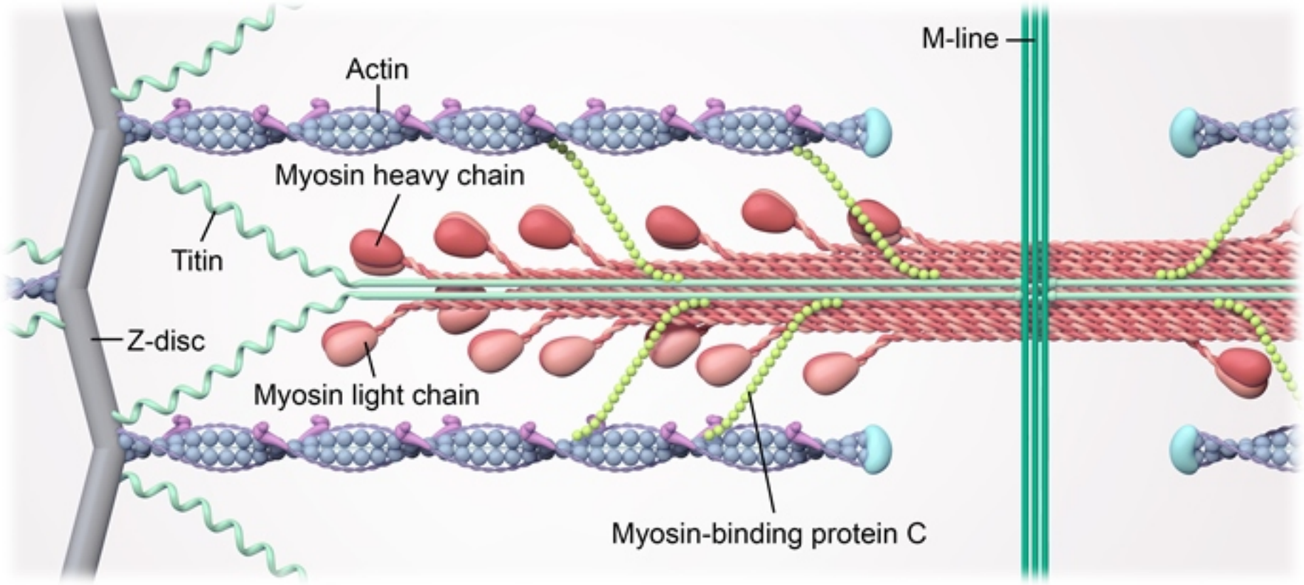

©UWorld

Zoom In | Zoom Out | Reset | Add To New Card | Existing Card

Subject System Topic

This patient's clinical presentation and echocardiography findings are consistent with **concentric left ventricular (LV) hypertrophy** leading to

Exhibit Display

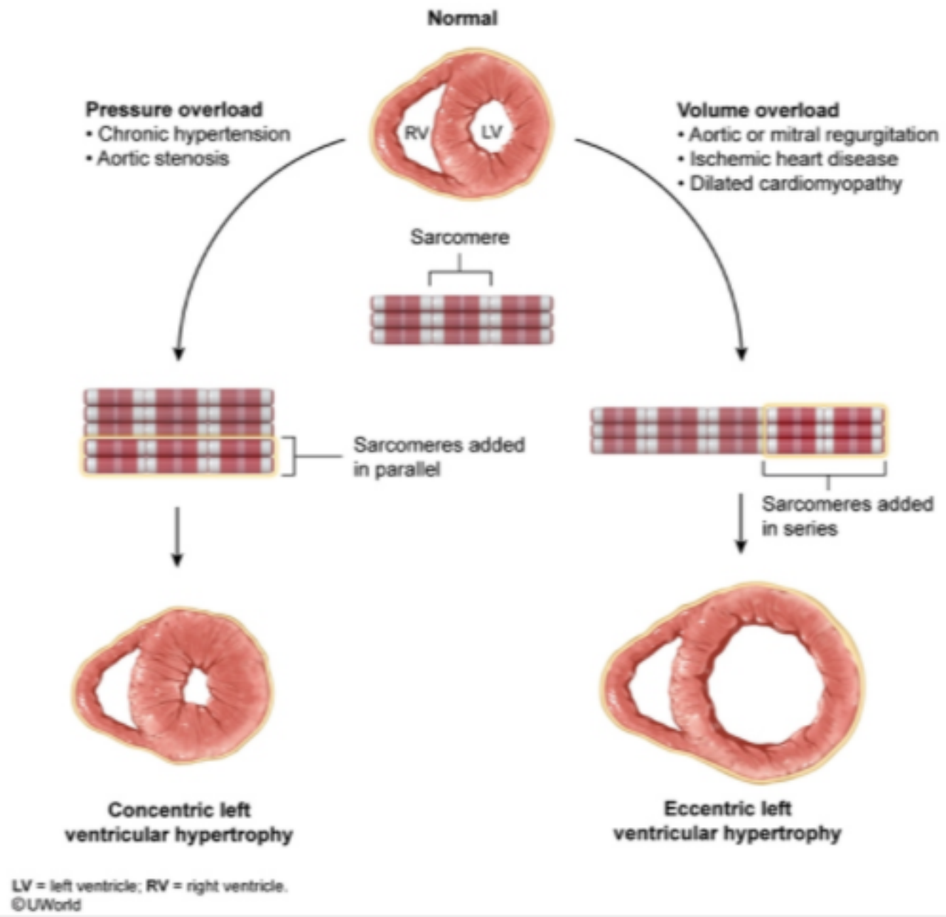

Zoom In | Zoom Out | Reset | Add To New Card | Existing Card

Subject System Topic

This patient's clinical presentation and echocardiography findings are consistent with **concentric left ventricular (LV) hypertrophy** leading to

Exhibit Display

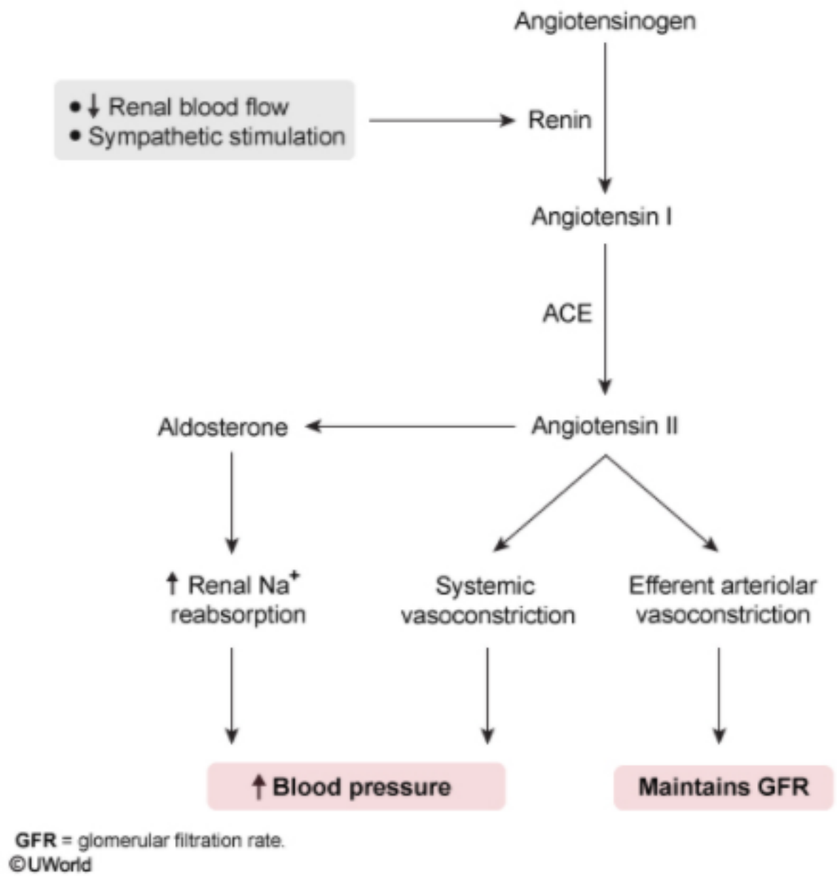

Zoom In | Zoom Out | Reset | Add To New Card | Existing Card

Subject System Topic

A 43-year-old man comes to the emergency department after experiencing 4 episodes of coffee ground emesis that started earlier this morning. He also describes epigastric pain over the last 3-4 months that was relieved by over-the-counter antacids. He has no other past medical history. The patient has smoked a pack of cigarettes daily for the last 20 years but does not use alcohol or illicit drugs. Blood pressure is 70/40 mm Hg and pulse is 130/min and regular. Extremities are cool to the touch with loss of skin turgor. Intravenous access is obtained via 2 large-bore peripheral catheters, and rapid infusion of 2 liters of normal saline is initiated. This intervention is most likely to increase which of the following hemodynamic parameters?

- A. Aortic wall elasticity
- B. Diastolic ventricular compliance
- C. End-diastolic sarcomere length
- D. Heart rate
- E. Plasma renin activity
- F. Total peripheral resistance
- G. Ventricular muscle contraction velocity

Submit

A 43-year-old man comes to the emergency department after experiencing 4 episodes of coffee ground emesis that started earlier this morning. He also describes epigastric pain over the last 3-4 months that was relieved by over-the-counter antacids. He has no other past medical history. The patient has smoked a pack of cigarettes daily for the last 20 years but does not use alcohol or illicit drugs. Blood pressure is 70/40 mm Hg and pulse is 130/min and regular. Extremities are cool to the touch with loss of skin turgor. Intravenous access is obtained via 2 large-bore peripheral catheters, and rapid infusion of 2 liters of normal saline is initiated. This intervention is most likely to increase which of the following hemodynamic parameters?

- A. Aortic wall elasticity (0%)
- B. Diastolic ventricular compliance (5%)
- ✓ C. End-diastolic sarcomere length (70%)
- D. Heart rate (1%)
- E. Plasma renin activity (2%)
- F. Total peripheral resistance (15%)
- G. Ventricular muscle contraction velocity (2%)

Omitted
Correct answer
C

70%
Answered correctly

02 secs
Time Spent

02/17/2020
Last Updated

Explanation

This patient's hypotension, tachycardia, and cool extremities are indicative of hypovolemic shock most likely due to upper gastrointestinal bleeding

This patient's hypotension, tachycardia, and cool extremities are indicative of hypovolemic shock most likely due to upper gastrointestinal bleeding from peptic ulcer disease (coffee ground emesis due to oxidation of heme iron by exposure to gastric acid). Decreased intravascular volume from significant blood loss **activates** the **sympathetic nervous system** and **renin-angiotensin-aldosterone system** (RAAS), which help to maintain systemic blood pressure via the following compensatory mechanisms:

1. Stimulation of the heart results in increased contractility and heart rate, helping to maintain cardiac output.
2. Constriction of the arteriolar beds serves to increase total peripheral resistance and maintain end-organ perfusion. This also shunts blood away from the extremities and skin and toward the vital organs.
3. Constriction of the systemic veins increases venous return to the heart, thereby assisting in maintaining preload.
4. Increased renal sodium and water retention help to prevent further volume loss.

In the treatment of hypovolemic shock, the most important intervention other than identifying and eliminating the source of bleeding is **rapid infusion of blood** products and crystalloid solutions such as **normal saline**. By infusing intravenous fluids, intravascular volume and ventricular preload can be increased rapidly. The increase in preload stretches the myocardium and **increases the end-diastolic sarcomere length**, leading to an increase in stroke volume and cardiac output by the Frank-Starling mechanism.

(Choice A) Aortic wall elasticity is based on the intrinsic structure of the aortic media and is not affected by fluid infusions.

(Choice B) The diastolic ventricular compliance is determined by intrinsic properties of the myocardium and is unaffected by crystalloid infusions. Conditions that decrease ventricular compliance include left ventricular hypertrophy (aortic stenosis, hypertension), hypertrophic cardiomyopathy, and infiltrative disorders (amyloidosis, sarcoidosis).

(Choice D) Adequate fluid resuscitation in a hypovolemic patient decreases the sympathetic drive and endogenous catecholamine release, resulting in decreased heart rate.

(Choice E) Plasma renin activity increases in patients with hypovolemic shock due to activation of RAAS and would be expected to decrease after intravenous fluid resuscitation.

(Choices F and G) In a patient with hypovolemic shock, total peripheral resistance and myocardial contraction velocity are high due to sympathetic activation. Administration of fluids will reduce sympathetic activation and decrease both of these parameters.

Educational objective:

3. Constriction of the systemic veins increases venous return to the heart, thereby assisting in maintaining preload.
4. Increased renal sodium and water retention help to prevent further volume loss.

In the treatment of hypovolemic shock, the most important intervention other than identifying and eliminating the source of bleeding is **rapid infusion of blood** products and crystalloid solutions such as **normal saline**. By infusing intravenous fluids, intravascular volume and ventricular preload can be increased rapidly. The increase in preload stretches the myocardium and **increases the end-diastolic sarcomere length**, leading to an increase in stroke volume and cardiac output by the Frank-Starling mechanism.

(Choice A) Aortic wall elasticity is based on the intrinsic structure of the aortic media and is not affected by fluid infusions.

(Choice B) The diastolic ventricular compliance is determined by intrinsic properties of the myocardium and is unaffected by crystalloid infusions. Conditions that decrease ventricular compliance include left ventricular hypertrophy (aortic stenosis, hypertension), hypertrophic cardiomyopathy, and infiltrative disorders (amyloidosis, sarcoidosis).

(Choice D) Adequate fluid resuscitation in a hypovolemic patient decreases the sympathetic drive and endogenous catecholamine release, resulting in decreased heart rate.

(Choice E) Plasma renin activity increases in patients with hypovolemic shock due to activation of RAAS and would be expected to decrease after intravenous fluid resuscitation.

(Choices F and G) In a patient with hypovolemic shock, total peripheral resistance and myocardial contraction velocity are high due to sympathetic activation. Administration of fluids will reduce sympathetic activation and decrease both of these parameters.

Educational objective:
Intravenous fluids increase the intravascular and left ventricular end-diastolic volumes. The increase in preload stretches the myocardium and increases the end-diastolic sarcomere length, leading to an increase in stroke volume and cardiac output by the Frank-Starling mechanism.

Physiology	Cardiovascular System	Hypovolemia
Subject	System	Topic

Copyright © UWorld. All rights reserved.

D. Heart rate (170)

Exhibit Display

Hemodynamic measurements in shock

Parameter	Hypovolemic shock	Cardiogenic shock	Septic shock
Right atrial pressure (preload)	↓	↑	Normal to slight ↓
Pulmonary capillary wedge pressure (preload)	↓	↑	Normal to slight ↓
Cardiac output (pump function)	↓	↓↓	↑
Systemic vascular resistance (afterload)	↑	↑	↓

©UWorld

Zoom In Zoom Out Reset Add To New Card | Existing Card

leading to an increase in stroke volume and cardiac output by the Frank-Starling mechanism.

1
2
3
4
5
6
7
8
9
10
11
12
13
14
15
16
17
18
19
20
21
22
23

Explanation

Exhibit Display

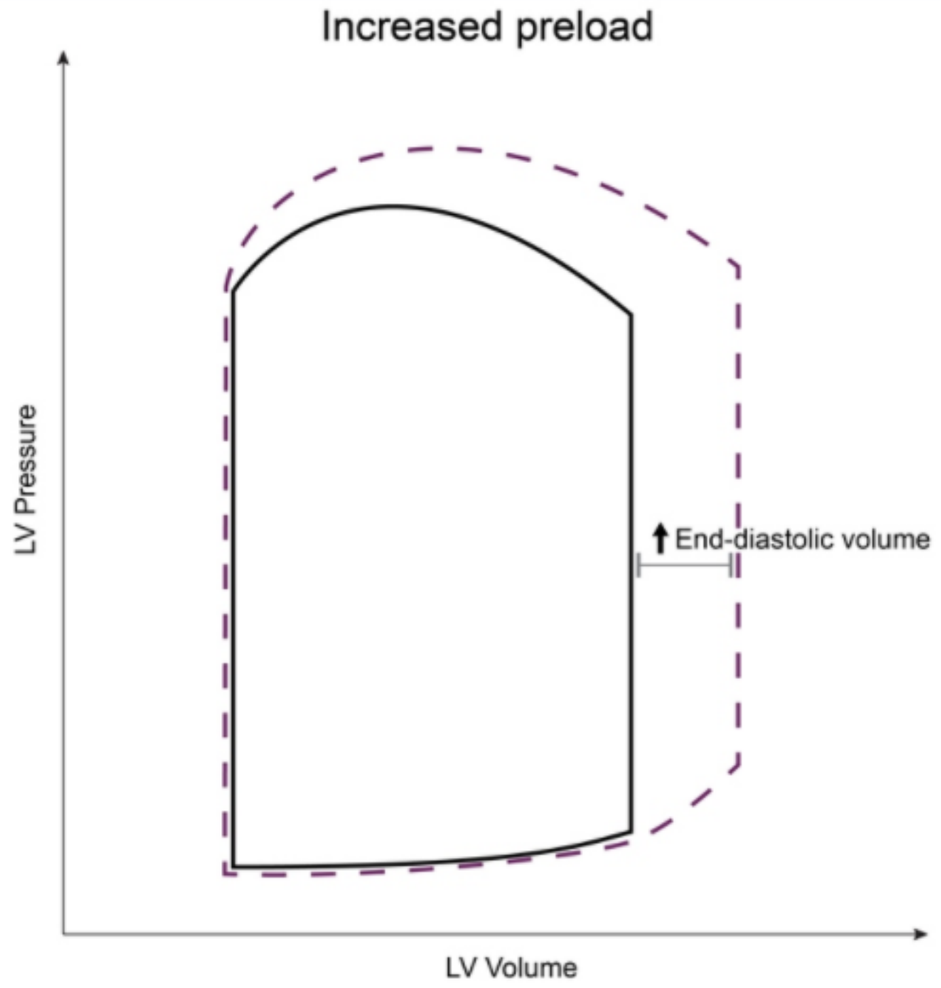

Zoom In Zoom Out Reset Add To New Card | Existing Card

sympathetic activation. Administration of fluids will reduce sympathetic activation and decrease both of these parameters.

A 44-year-old man is hospitalized with multiple injuries following a motor vehicle collision. An arteriovenous fistula created by an injury would most likely result in which of the following changes to the left ventricular pressure-volume loop?

Solid line = preinjury
Dashed line = postinjury

A.

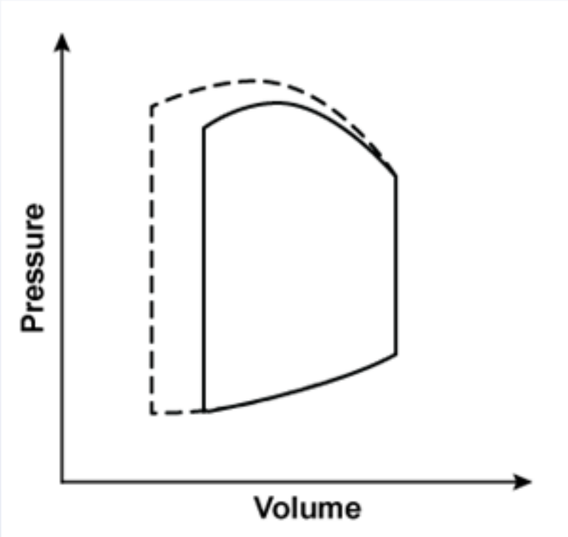

B.

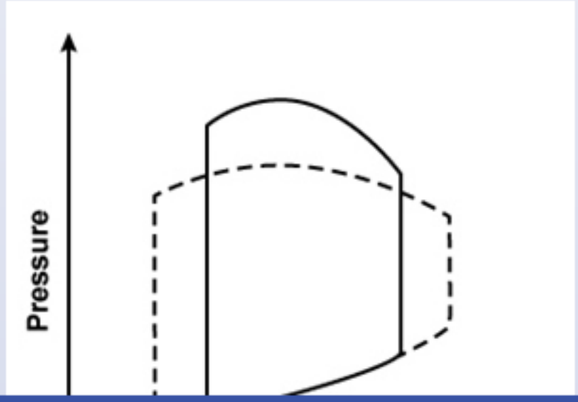

B.

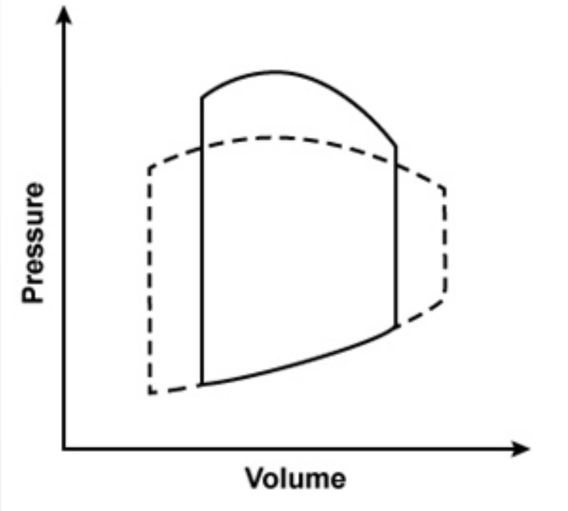

C.

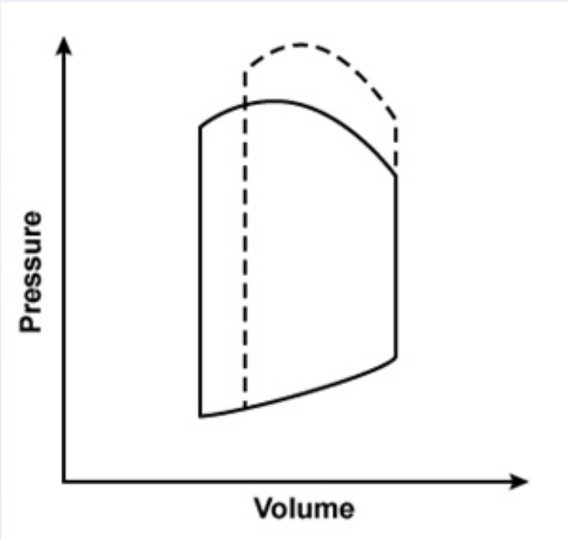

D.

1
2
3
4
5
6
7
8
9
10
11
12
13
14
15
16
17
18
19
20
21
22
23

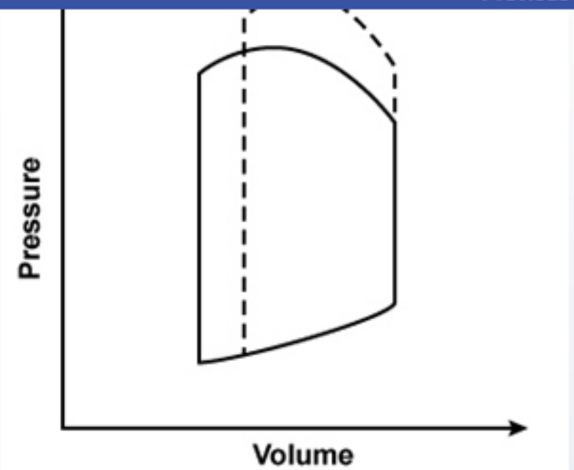

D.

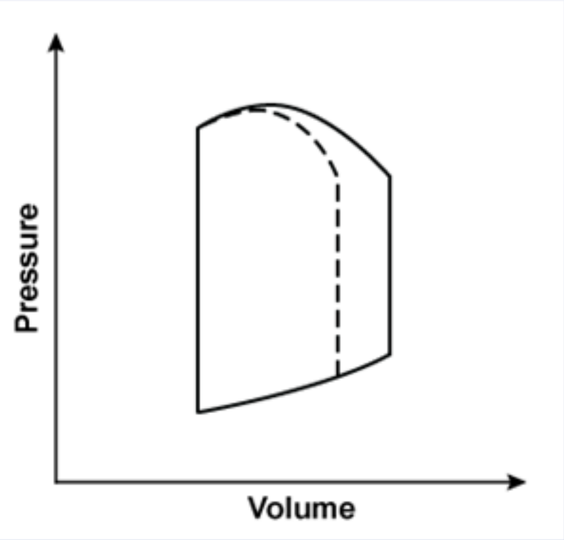

Submit

1
2
3
4
5
6
7
8
9
10
11
12
13
14
15
16
17
18
19
20
21
22
23

A. (14%)

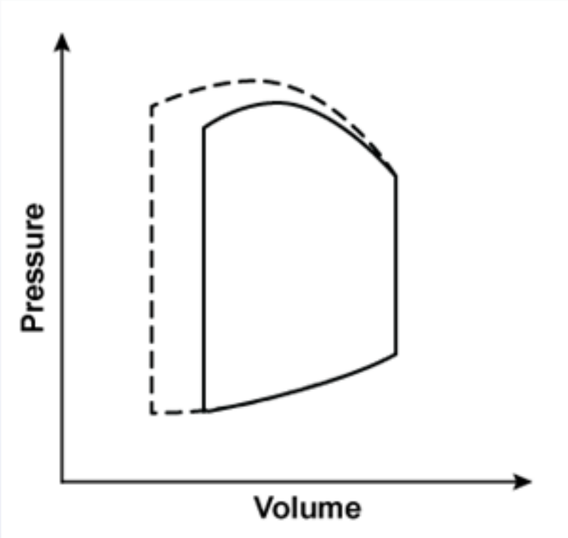

B. (57%)

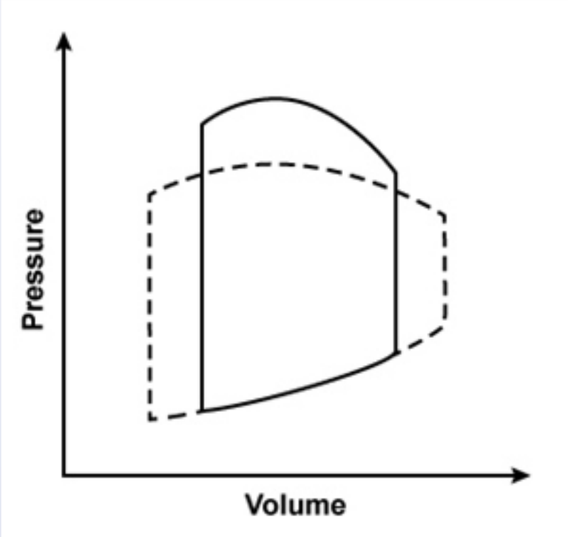

C. (12%)

1
2
3
4
5
6
7
8
9
10
11
12
13
14
15
16
17
18
19
20
21
22
23

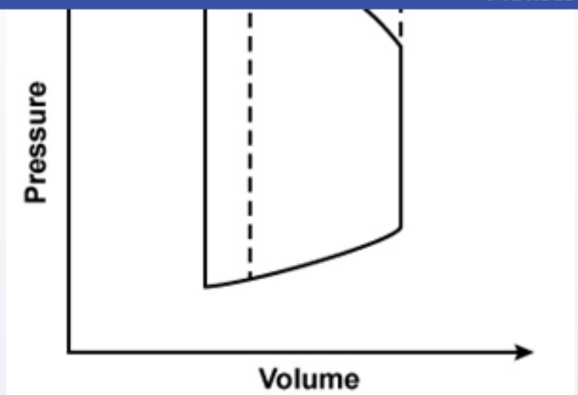

D.

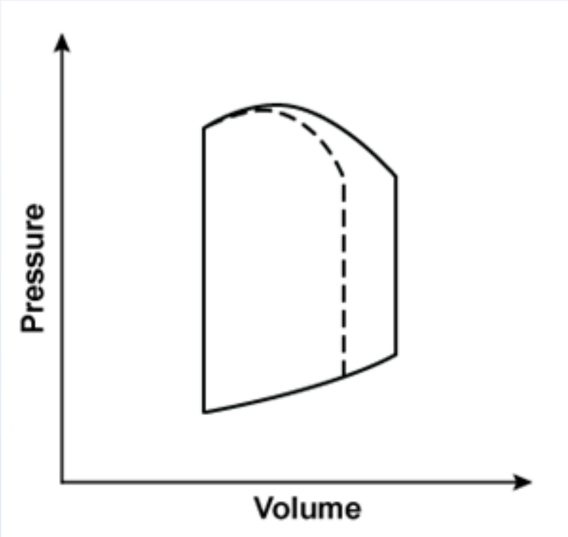

(15%)

Omitted
Correct answer
B

57%
Answered correctly

08 secs
Time Spent

06/24/2020
Last Updated

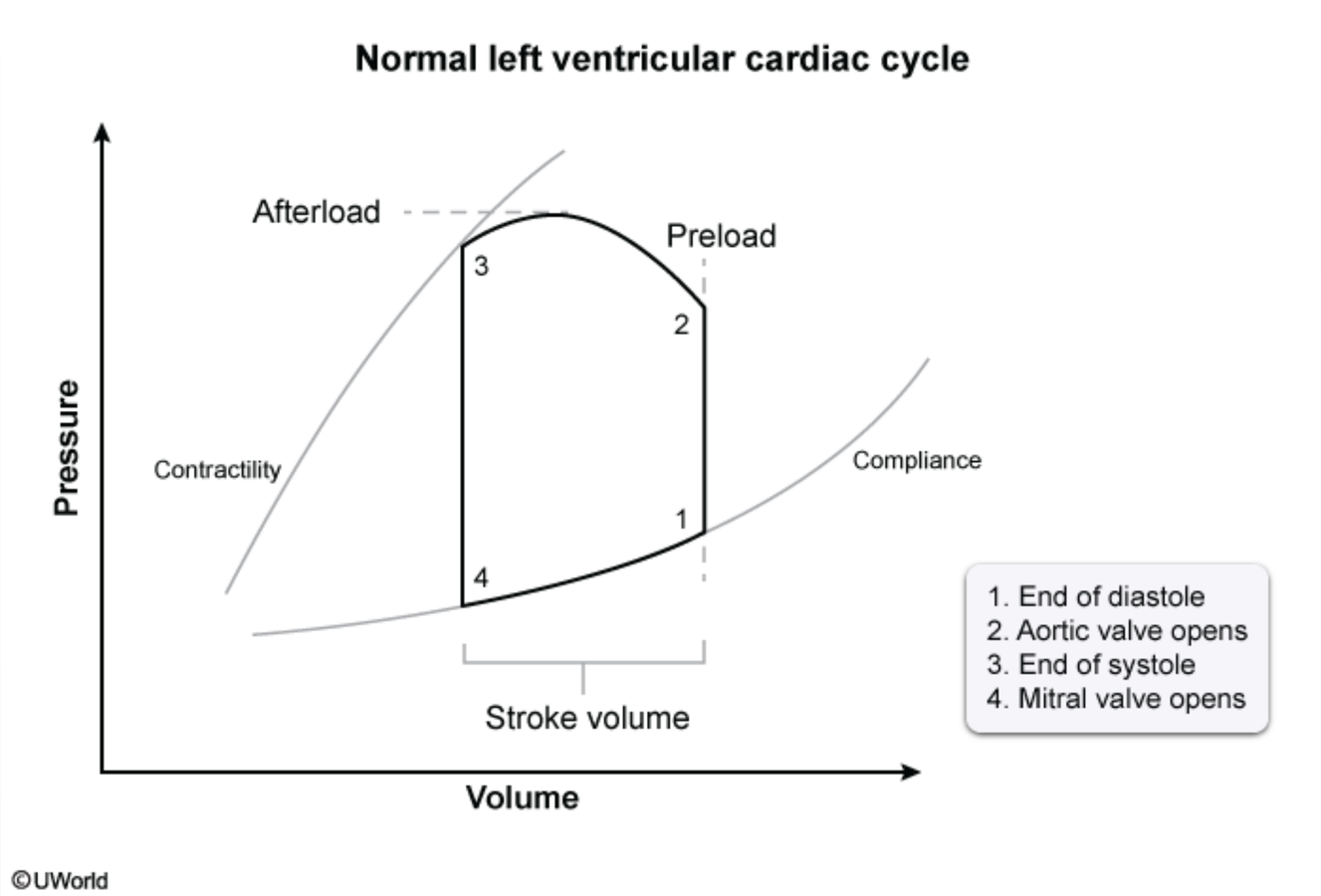

The **left ventricular (LV) pressure-volume loop** follows the cardiac cycle. At point 1, the left ventricle is full of blood and begins isovolumetric contraction until the aortic valve opens at point 2, causing blood to eject into the aorta and LV volume to decrease. LV contraction ends at point 3, and LV pressure rapidly decreases to point 4, where the mitral valve opens and LV diastolic filling begins again.

An **arteriovenous fistula**, which can be congenital (eg, arteriovenous malformation) or acquired (eg, traumatic injury, surgical placement for hemodialysis), allows blood to shunt from the arterial circulation to the venous circulation without passing through the high resistance of the

©UWorld

The **left ventricular (LV) pressure-volume loop** follows the cardiac cycle. At point 1, the left ventricle is full of blood and begins isovolumetric contraction until the aortic valve opens at point 2, causing blood to eject into the aorta and LV volume to decrease. LV contraction ends at point 3, and LV pressure rapidly decreases to point 4, where the mitral valve opens and LV diastolic filling begins again.

An **arteriovenous fistula**, which can be congenital (eg, arteriovenous malformation) or acquired (eg, traumatic injury, surgical placement for hemodialysis), allows blood to shunt from the arterial circulation to the venous circulation without passing through the high resistance of the systemic arterioles. This has the following effects on the LV pressure-volume loop:

- The low-resistance fistula pathway creates overall reduced systemic vascular resistance (ie, **reduced afterload**).
- Blood quickly and easily passes through the reduced peripheral resistance, resulting in increased venous return to the right atrium (ie, **increased preload**).
- Both the reduced afterload and increased preload facilitate **increased stroke volume**, which increases cardiac output and helps maintain blood pressure.
- Contractility is unchanged initially but may eventually increase via the baroreceptor reflex if there is sustained hypotension.

With a large arteriovenous fistula, the left ventricle may be unable to keep up with the increased venous return despite a sustained increase in cardiac output, leading to high-output heart failure.

(Choice A) This pressure-volume loop shows increased contractility with a resulting increase in stroke volume and slight increase in afterload. Such changes are expected with administration of a positive inotropic agent such as digoxin.

(Choice C) This pressure-volume loop shows increased afterload with a resulting decrease in stroke volume. Contractility is unchanged. Such changes are expected with the obstruction to LV outflow that occurs with aortic stenosis.

(Choice D) This pressure-volume loop shows decreased preload with a resulting decrease in stroke volume and slight decrease in afterload. Such changes are expected with administration of a primarily venous vasodilator such as nitroglycerin.

Educational objective:
An arteriovenous fistula allows blood to shunt from the arterial circulation to the venous circulation, bypassing the high resistance of the systemic

systemic arterioles. This has the following effects on the LV pressure-volume loop:

- The low-resistance fistula pathway creates overall reduced systemic vascular resistance (ie, **reduced afterload**).
- Blood quickly and easily passes through the reduced peripheral resistance, resulting in increased venous return to the right atrium (ie, **increased preload**).
- Both the reduced afterload and increased preload facilitate **increased stroke volume**, which increases cardiac output and helps maintain blood pressure.
- Contractility is unchanged initially but may eventually increase via the baroreceptor reflex if there is sustained hypotension.

With a large arteriovenous fistula, the left ventricle may be unable to keep up with the increased venous return despite a sustained increase in cardiac output, leading to high-output heart failure.

(Choice A) This pressure-volume loop shows increased contractility with a resulting increase in stroke volume and slight increase in afterload. Such changes are expected with administration of a positive inotropic agent such as digoxin.

(Choice C) This pressure-volume loop shows increased afterload with a resulting decrease in stroke volume. Contractility is unchanged. Such changes are expected with the obstruction to LV outflow that occurs with aortic stenosis.

(Choice D) This pressure-volume loop shows decreased preload with a resulting decrease in stroke volume and slight decrease in afterload. Such changes are expected with administration of a primarily venous vasodilator such as nitroglycerin.

Educational objective:
An arteriovenous fistula allows blood to shunt from the arterial circulation to the venous circulation, bypassing the high resistance of the systemic arterioles. This leads to reduced systemic vascular resistance (ie, reduced afterload), increased venous return (ie, increased preload), and increased stroke volume. Left ventricular contractility is unchanged.

Physiology	Cardiovascular System	Av fistula
Subject	System	Topic

Copyright © UWorld. All rights reserved.

1
2
3
4
5
6
7
8
9
10
11
12
13
14
15
16
17
18
19
20
21
22
23

Exhibit Display

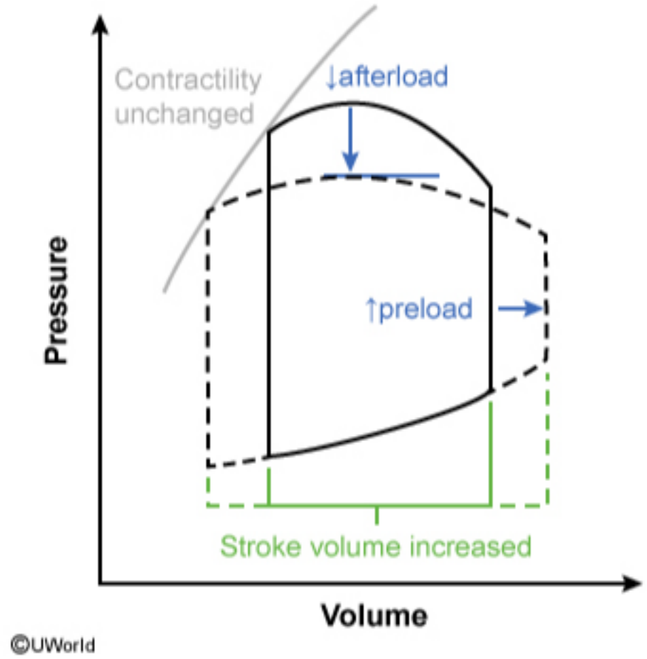

Zoom In | Zoom Out | Reset | Add To New Card | Existing Card

cardiac output, leading to high-output heart failure.

1
2
3
4
5
6
7
8
9
10
11
12
13
14
15
16
17
18
19
20
21
22
23

systemic arterioles. This has the following effects on the LV pressure-volume loop:

Exhibit Display

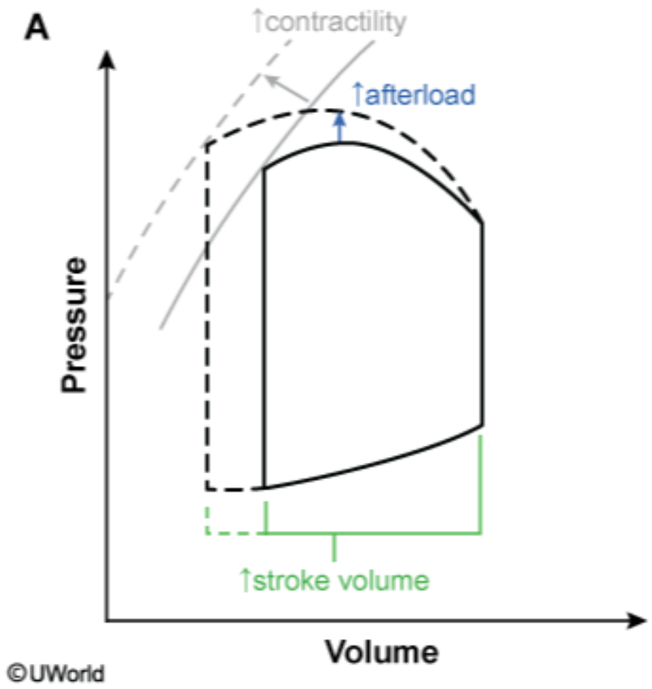

Zoom In | Zoom Out | Reset | Add To New Card | Existing Card

1
2
3
4
5
6
7
8
9
10
11
12
13
14
15
16
17
18
19
20
21
22
23

systemic arterioles. This has the following effects on the LV pressure-volume loop:

Exhibit Display

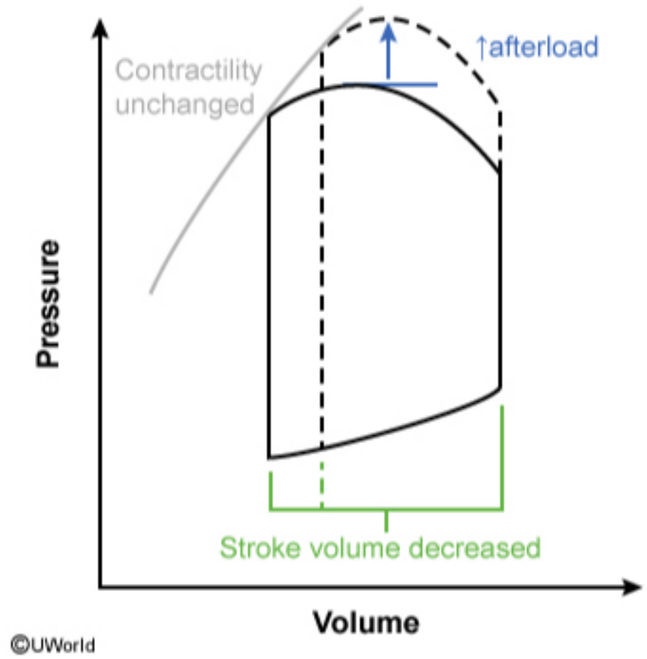

Zoom In | Zoom Out | Reset | Add To New Card | Existing Card

1
2
3
4
5
6
7
8
9
10
11
12
13
14
15
16
17
18
19
20
21
22
23

systemic arterioles. This has the following effects on the LV pressure-volume loop:

Exhibit Display

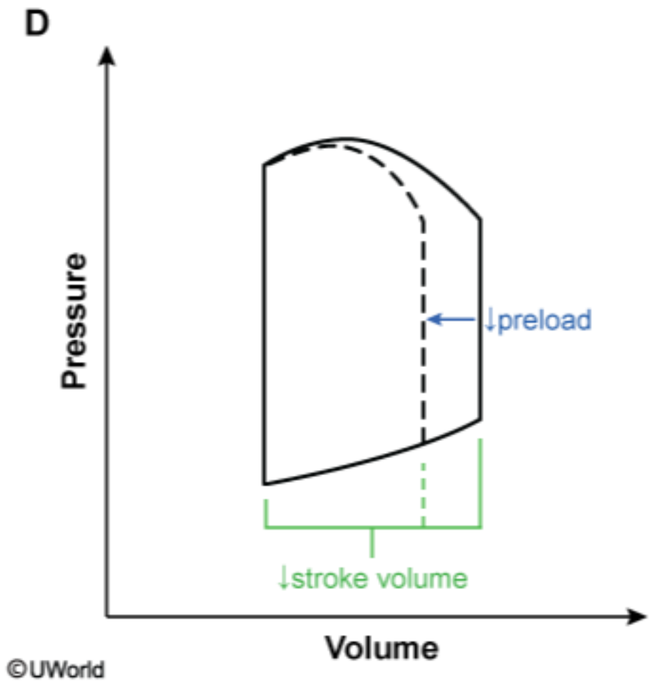

Zoom In | Zoom Out | Reset | Add To New Card | Existing Card

A 32-year-old man is evaluated in the emergency department due to fever, night sweats, and chills over the last several days. The patient has been using intravenous drugs recently as he is "stressed out." He has otherwise been in good health with no medical problems. Temperature is 38.3 C (101 F), blood pressure is 120/80 mm Hg, and pulse is 105/min and regular. Further evaluation reveals aortic valve endocarditis with an intracardiac abscess and small fistula formation between the aortic root and right ventricle. Doppler ultrasound interrogation of the fistula will most likely reveal which of the following blood flow patterns?

- A. Flow from the aortic root to the right ventricle continuously
- B. Flow from the aortic root to the right ventricle only in diastole
- C. Flow from the aortic root to the right ventricle only in systole
- D. Flow from the right ventricle to the aortic root continuously
- E. Flow from the right ventricle to the aortic root only in diastole
- F. Flow from the right ventricle to the aortic root only in systole

Submit

A 32-year-old man is evaluated in the emergency department due to fever, night sweats, and chills over the last several days. The patient has been using intravenous drugs recently as he is "stressed out." He has otherwise been in good health with no medical problems. Temperature is 38.3 C (101 F), blood pressure is 120/80 mm Hg, and pulse is 105/min and regular. Further evaluation reveals aortic valve endocarditis with an intracardiac abscess and small fistula formation between the aortic root and right ventricle. Doppler ultrasound interrogation of the fistula will most likely reveal which of the following blood flow patterns?

- ✓ A. Flow from the aortic root to the right ventricle continuously (41%)
- B. Flow from the aortic root to the right ventricle only in diastole (15%)
- C. Flow from the aortic root to the right ventricle only in systole (28%)
- D. Flow from the right ventricle to the aortic root continuously (4%)
- E. Flow from the right ventricle to the aortic root only in diastole (3%)
- F. Flow from the right ventricle to the aortic root only in systole (6%)

Omitted
Correct answer
A

41%
Answered correctly

17 secs
Time Spent

02/14/2020
Last Updated

Explanation

1
2
3
4
5
6
7
8
9
10
11
12
13
14
15
16
17
18
19
20
21
22
23

Cardiac pressures

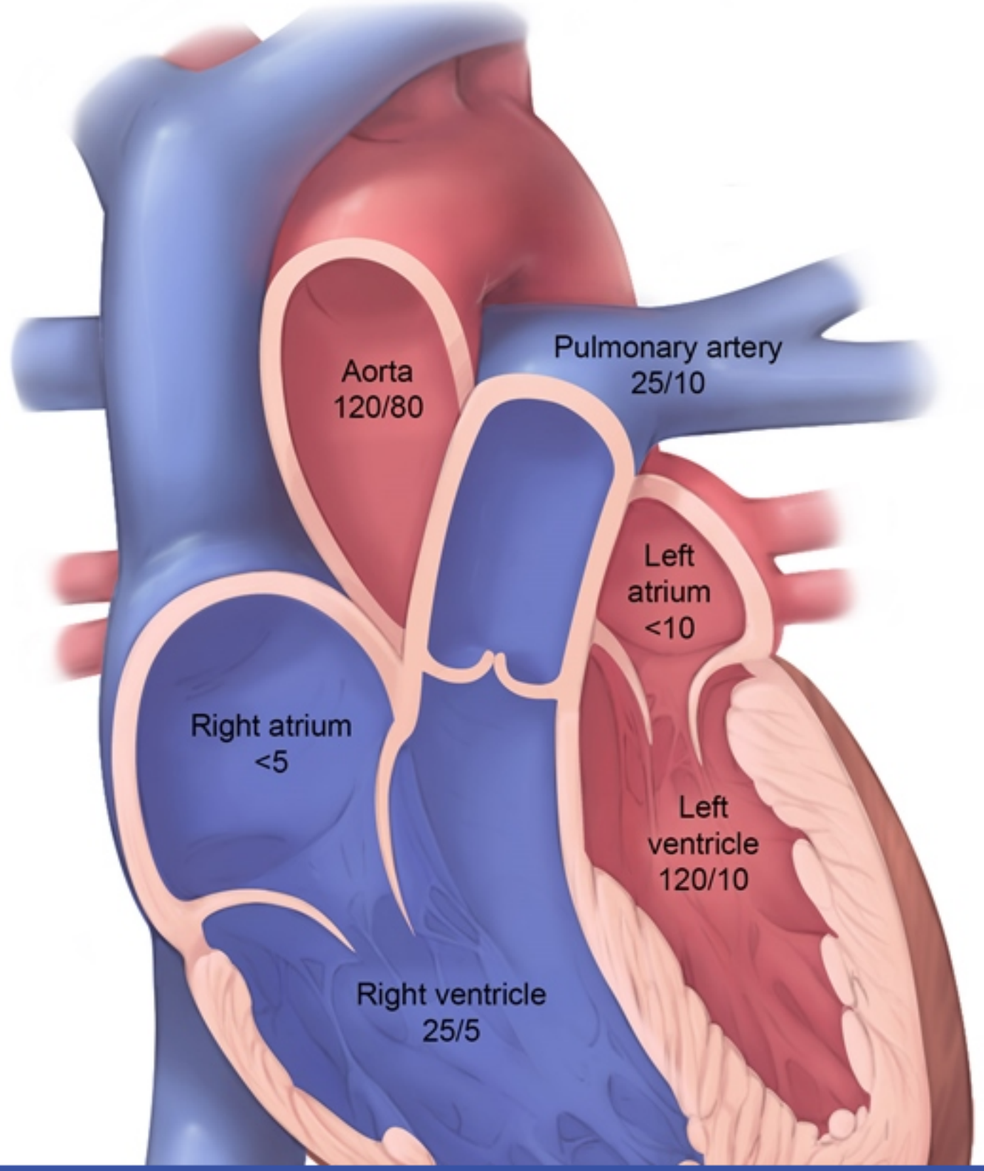

This patient with aortic valve endocarditis has developed an intracardiac fistula between the aortic root and right ventricle. **Aortocavitary fistulas** are an uncommon complication of **bacterial endocarditis** caused by extension of the infection from the valve to the adjacent myocardium.

Echocardiography with Doppler analysis can be used to detect and quantify shunts in patients with intracardiac fistulas. During the normal cardiac cycle, central aortic pressure (eg, 120/80 mm Hg) is higher than right ventricular pressure (eg, 25/5 mm Hg) during systole and diastole. Consequently, in patients with aortocavitary fistula, Doppler interrogation will most likely demonstrate **continuous blood flow** from the **higher-pressure aortic root** to the lower-pressure **right ventricle** (left-to-right cardiac shunt) **(Choices B and C)**. This can lead to a continuous murmur heard on cardiac auscultation.

(Choices D, E, and F) Pressure in the aortic root is always greater than in the right ventricle throughout systole and diastole; therefore, blood flow from the right ventricle to the aortic root would not be expected in this patient.

Educational objective:
During the normal cardiac cycle, central aortic pressure is higher than right ventricular pressure during systole and diastole. Consequently, an intracardiac fistula between the aortic root and right ventricle will most likely demonstrate a left-to-right cardiac shunt as blood continuously flows from the aortic root (high pressure) to the right ventricle (low pressure).

References

- Aorto-cavitary fistulous tract formation in infective endocarditis: clinical and echocardiographic features of 76 cases and risk factors for mortality.

Physiology	Cardiovascular System	Endocarditis
Subject	System	Topic

Copyright © UWorld. All rights reserved.

A 66-year-old man comes to the office for follow-up. The patient has a history of nonischemic cardiomyopathy and has had persistent dyspnea despite taking the maximal dosage of his heart failure medications. He has had no lightheadedness or chest pain. Blood pressure is 133/72 mm Hg and pulse is 76/min. Physical examination shows normal lung sounds and no lower extremity edema. His medical treatment is modified with the addition of a combination pill that inhibits neprilysin and blocks angiotensin II receptors. Which of the following is the most likely effect of this medication?

- A. Decreased renal free-water reabsorption
- B. Decreased venous compliance
- C. Increased myocardial contractility
- D. Increased peripheral arterial resistance
- E. Increased urinary sodium excretion

Submit

A 66-year-old man comes to the office for follow-up. The patient has a history of nonischemic cardiomyopathy and has had persistent dyspnea despite taking the maximal dosage of his heart failure medications. He has had no lightheadedness or chest pain. Blood pressure is 133/72 mm Hg and pulse is 76/min. Physical examination shows normal lung sounds and no lower extremity edema. His medical treatment is modified with the addition of a combination pill that inhibits neprilysin and blocks angiotensin II receptors. Which of the following is the most likely effect of this medication?

- A. Decreased renal free-water reabsorption (21%)
- B. Decreased venous compliance (2%)
- C. Increased myocardial contractility (4%)
- D. Increased peripheral arterial resistance (2%)
- ✓ E. Increased urinary sodium excretion (69%)

Omitted
Correct answer
E

69%
Answered correctly

03 secs
Time Spent

01/12/2020
Last Updated

Explanation

Medical therapy for **heart failure** (eg, beta blockers, ACE inhibitors, angiotensin II receptor blockers) is primarily targeted toward the inhibition of detrimental neurohormonal pathways involving the sympathetic nervous system and renin-angiotensin-aldosterone system (RAAS). However, an additional strategy involves augmenting beneficial counter-regulatory mechanisms, such as those involving **natriuretic peptides**.

Atrial natriuretic peptide (ANP) and brain natriuretic peptide (BNP) are released from the myocardium in response to high atrial and ventricular

1
2
3
4
5
6
7
8
9
10
11
12
13
14
15
16
17
18
19
20
21
22
23

Neprilysin inhibition and heart failure

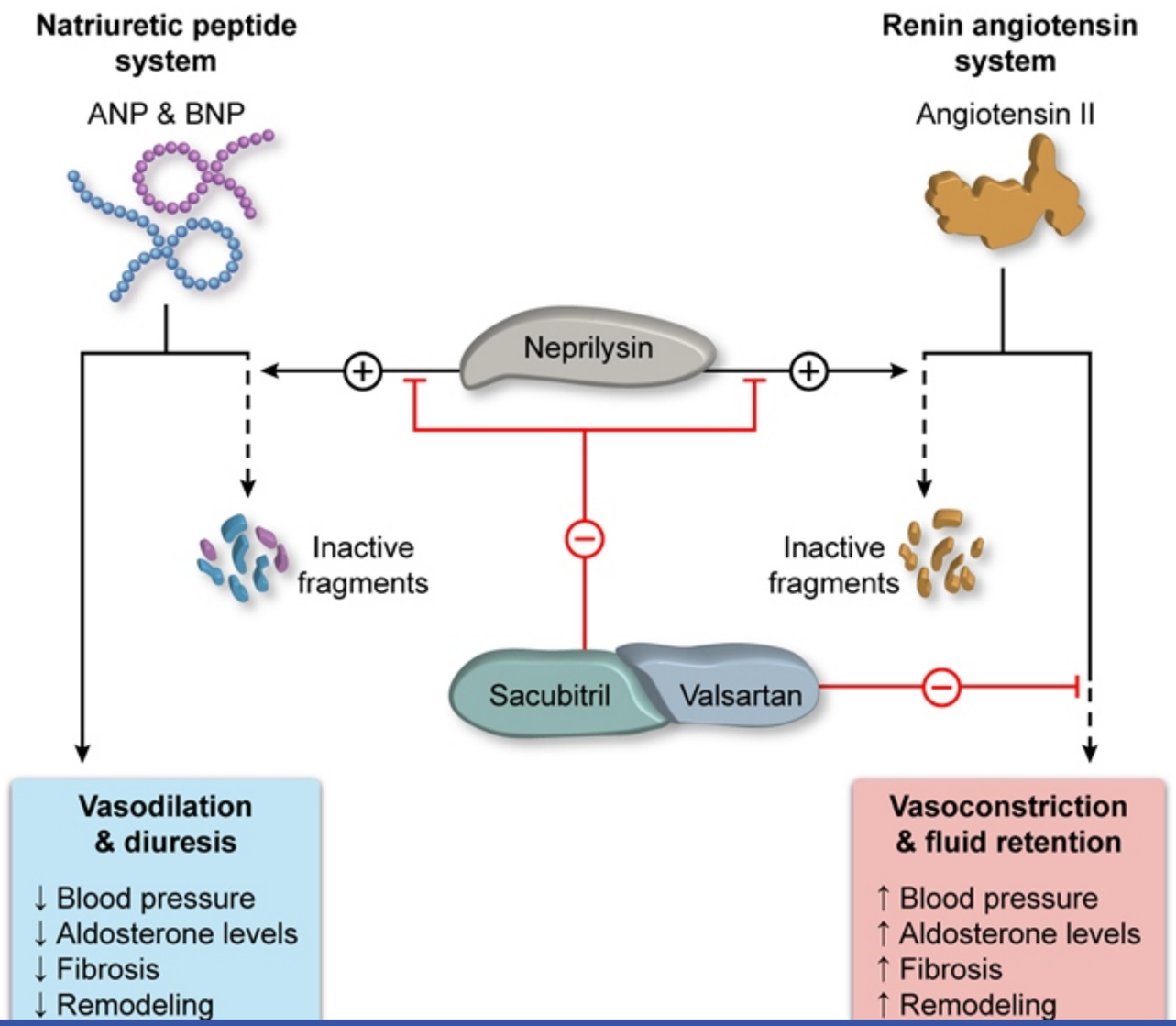

1
2
3
4
5
6
7
8
9
10
11
12
13
14
15
16
17
18
19
20
21
22
23

Exhibit Display

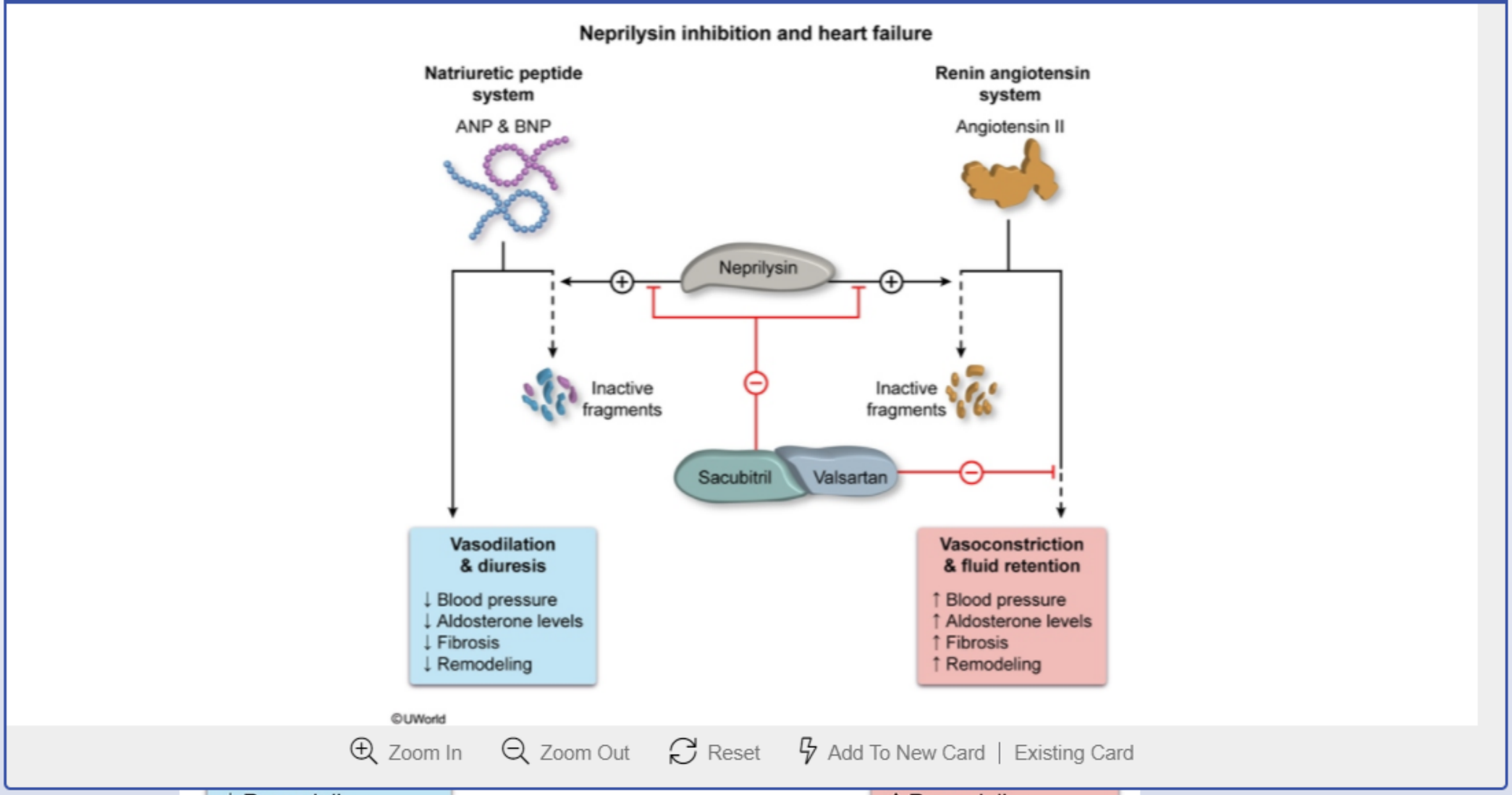

↓ Remodeling ↑ Remodeling

©UWorld

Medical therapy for **heart failure** (eg, beta blockers, ACE inhibitors, angiotensin II receptor blockers) is primarily targeted toward the inhibition of detrimental neurohormonal pathways involving the sympathetic nervous system and renin-angiotensin-aldosterone system (RAAS). However, an additional strategy involves augmenting beneficial counter-regulatory mechanisms, such as those involving **natriuretic peptides**.

Atrial natriuretic peptide (ANP) and brain natriuretic peptide (BNP) are released from the myocardium in response to high atrial and ventricular filling pressures (myocardial stretch). These peptides induce **vasodilation** and **diuresis** by antagonizing the actions of RAAS and also protect against the deleterious myocardial remodeling and fibrosis that occur in heart failure. Neprilysin is a metalloprotease that cleaves and inactivates both ANP and BNP. Therefore, medications that **inhibit neprilysin** (eg, sacubitril) lead to **increased levels of ANP and BNP** and promote beneficial effects in heart failure.

However, because neprilysin is also responsible for inactivating angiotensin II, inhibition of neprilysin further stimulates deleterious vasoconstriction and fluid retention via increased angiotensin II levels. Therefore, in treating heart failure, neprilysin inhibitors are **combined** with an **angiotensin II-receptor blocker** (eg, sacubitril-valsartan) to mitigate these negative effects.

(Choice A) Increased levels of ANP and BNP stimulate the excretion of both salt and water. Decreased reabsorption of free water (water without solute) can be achieved with medications that block vasopressin-2 receptors (eg, tolvaptan) on the renal collecting tubule.

(Choices B and D) The vasodilatory effects of ANP and BNP increase (rather than decrease) venous compliance and decrease (rather than increase) peripheral arterial resistance, leading to a reduction in both cardiac preload and afterload and a consequent reduction in cardiac work. These effects would be counteracted by angiotensin II-induced vasoconstriction, but angiotensin II activity is blocked by combining the neprilysin inhibitor with an angiotensin II-receptor blocker.

(Choice C) Neprilysin inhibition combined with angiotensin II receptor blockade improves cardiac output in heart failure via a reduction in the cardiac work required to attain a certain stroke volume; however, cardiac contractility is not significantly affected.

Educational objective:
Neprilysin is responsible for the breakdown of the natriuretic peptides and angiotensin II; therefore, inhibition of neprilysin increases the activity of these peptides. For treatment of heart failure, neprilysin inhibition is combined with angiotensin II receptor blockade to optimize the positive effects of the natriuretic peptides (eg, vasodilation, diuresis) while blocking the negative effects of angiotensin II (eg, vasoconstriction, fluid retention).

References

against the deleterious myocardial remodeling and fibrosis that occur in heart failure. Neprilysin is a metalloprotease that cleaves and inactivates both ANP and BNP. Therefore, medications that **inhibit neprilysin** (eg, sacubitril) lead to **increased levels of ANP and BNP** and promote beneficial effects in heart failure.

However, because neprilysin is also responsible for inactivating angiotensin II, inhibition of neprilysin further stimulates deleterious vasoconstriction and fluid retention via increased angiotensin II levels. Therefore, in treating heart failure, neprilysin inhibitors are **combined** with an **angiotensin II-receptor blocker** (eg, sacubitril-valsartan) to mitigate these negative effects.

(Choice A) Increased levels of ANP and BNP stimulate the excretion of both salt and water. Decreased reabsorption of free water (water without solute) can be achieved with medications that block vasopressin-2 receptors (eg, tolvaptan) on the renal collecting tubule.

(Choices B and D) The vasodilatory effects of ANP and BNP increase (rather than decrease) venous compliance and decrease (rather than increase) peripheral arterial resistance, leading to a reduction in both cardiac preload and afterload and a consequent reduction in cardiac work. These effects would be counteracted by angiotensin II-induced vasoconstriction, but angiotensin II activity is blocked by combining the neprilysin inhibitor with an angiotensin II-receptor blocker.

(Choice C) Neprilysin inhibition combined with angiotensin II receptor blockade improves cardiac output in heart failure via a reduction in the cardiac work required to attain a certain stroke volume; however, cardiac contractility is not significantly affected.

Educational objective:
Neprilysin is responsible for the breakdown of the natriuretic peptides and angiotensin II; therefore, inhibition of neprilysin increases the activity of these peptides. For treatment of heart failure, neprilysin inhibition is combined with angiotensin II receptor blockade to optimize the positive effects of the natriuretic peptides (eg, vasodilation, diuresis) while blocking the negative effects of angiotensin II (eg, vasoconstriction, fluid retention).

References

- Angiotensin-neprilysin inhibition versus enalapril in heart failure.

Physiology	Cardiovascular System	Chronic heart failure
Subject	System	Topic

Copyright © UWorld. All rights reserved.

A 32-year-old woman comes to the outpatient clinic due to shortness of breath for the past 6 months. The patient says she can walk only 3-4 blocks on level ground before feeling out of breath. She also has an occasional dry cough at night. The patient denies any chest pain, palpitations, syncope, weight loss, or lower extremity swelling. She immigrated from Guatemala 8 years ago. Medical history is unremarkable. On physical examination, the patient appears comfortable. Blood pressure is 128/75 mm Hg and pulse is 78/min and regular. Peripheral pulses are full and symmetric. The lungs are clear on auscultation. S1 is loud. With the patient positioned on her left side and breath held at the end of expiration, a diastolic murmur is heard at mid- and end diastole. Otherwise, examination is unremarkable. Which of the following are the most likely left ventricular hemodynamic findings at rest in this patient?

	Diastolic pressure	Afterload	Contractility
A.	Increased	Increased	Decreased
B.	Increased	Increased	Normal
C.	Normal	Normal	Decreased
D.	Normal	Normal	Normal

Submit

A 32-year-old woman comes to the outpatient clinic due to shortness of breath for the past 6 months. The patient says she can walk only 3-4 blocks on level ground before feeling out of breath. She also has an occasional dry cough at night. The patient denies any chest pain, palpitations, syncope, weight loss, or lower extremity swelling. She immigrated from Guatemala 8 years ago. Medical history is unremarkable. On physical examination, the patient appears comfortable. Blood pressure is 128/75 mm Hg and pulse is 78/min and regular. Peripheral pulses are full and symmetric. The lungs are clear on auscultation. S1 is loud. With the patient positioned on her left side and breath held at the end of expiration, a diastolic murmur is heard at mid- and end diastole. Otherwise, examination is unremarkable. Which of the following are the most likely left ventricular hemodynamic findings at rest in this patient?

	Diastolic pressure	Afterload	Contractility
A. (19%)	Increased	Increased	Decreased
B. (31%)	Increased	Increased	Normal
C. (13%)	Normal	Normal	Decreased
✓ D. (35%)	Normal	Normal	Normal

Omitted
Correct answer
D

35%
Answered correctly

02 secs
Time Spent

04/10/2020
Last Updated

Explanation

1
2
3
4
5
6
7
8
9
10
11
12
13
14
15
16
17
18
19
20
21
22
23

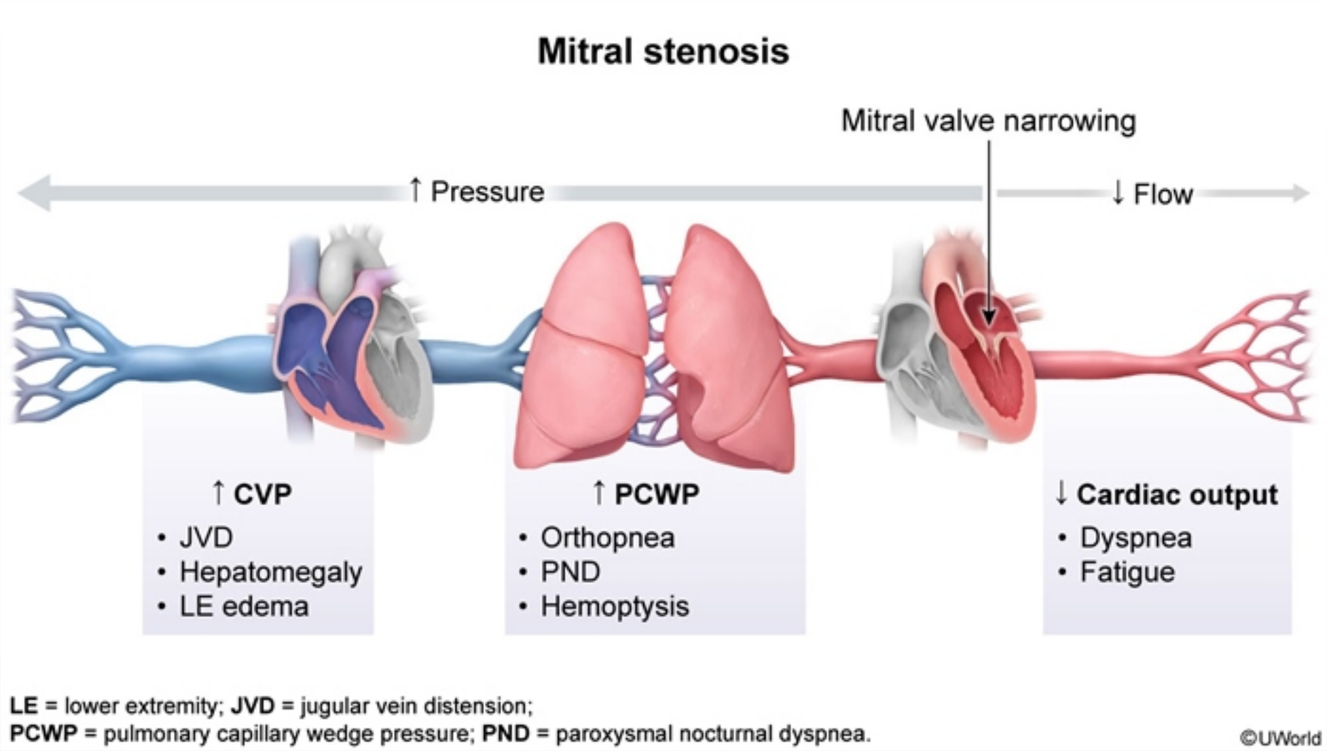

This patient's **mid-to-late diastolic murmur** is consistent with **mitral stenosis** (MS). MS usually occurs due to underlying rheumatic heart disease, which in the United States is most commonly seen in patients who emigrated from Latin America, Africa, or Asia.

MS can lead to heart failure due to restriction of left ventricular (LV) diastolic filling. Patients usually experience **exertional dyspnea** as the first symptom, which results from an inability to increase cardiac output to meet exertional demands. As MS worsens, elevated left atrial pressure can lead to orthopnea, paroxysmal nocturnal dyspnea, productive cough/hemoptysis, and eventual right-sided heart failure with resulting jugular venous distension and lower extremity edema.

This patient's presentation with exertional dyspnea in the **absence of volume overload** (ie, dry cough, no pulmonary crackles, no peripheral edema) suggests relatively **early, mild-to-moderate** disease. A **loud S1** (caused by the stiff leaflets snapping shut) is further suggestive of more

This patient's **mid-to-late diastolic murmur** is consistent with **mitral stenosis** (MS). MS usually occurs due to underlying rheumatic heart disease, which in the United States is most commonly seen in patients who emigrated from Latin America, Africa, or Asia.

MS can lead to heart failure due to restriction of left ventricular (LV) diastolic filling. Patients usually experience **exertional dyspnea** as the first symptom, which results from an inability to increase cardiac output to meet exertional demands. As MS worsens, elevated left atrial pressure can lead to orthopnea, paroxysmal nocturnal dyspnea, productive cough/hemoptysis, and eventual right-sided heart failure with resulting jugular venous distension and lower extremity edema.

This patient's presentation with exertional dyspnea in the **absence of volume overload** (ie, dry cough, no pulmonary crackles, no peripheral edema) suggests relatively **early, mild-to-moderate** disease. A **loud S1** (caused by the stiff leaflets snapping shut) is further suggestive of more mild disease, as the intensity of S1 diminishes with disease progression due to heavy calcification that limits valve motion. Although severe MS can cause reductions in **LV diastolic pressure** and **afterload** (due to reduced ventricular filling), these parameters typically remain normal until later in the disease course (especially at rest). **LV contractility** is also **normal** at rest in early disease; however, with severe MS the reduction in cardiac output stimulates increased sympathetic activity to increase LV contractility.

(Choices A and C) Decreased LV contractility occurs in heart failure due to LV systolic dysfunction (eg, dilated cardiomyopathy, ischemic heart disease). LV diastolic pressure and afterload are initially near normal but increase over time due to worsening systolic function and progressive ventricular dilation.

(Choice B) Increased LV diastolic pressure in the setting of normal contractility occurs in heart failure due to LV diastolic dysfunction. Depending on etiology, afterload may be increased (eg, early stages of hypertensive heart disease) or normal (eg, cardiac amyloidosis).

Educational objective:
Mitral stenosis usually occurs due to underlying rheumatic heart disease and initially presents with exertional dyspnea. Orthopnea, paroxysmal nocturnal dyspnea, productive cough, and hemoptysis can develop as the disease becomes more advanced. At rest, left ventricular diastolic pressure, afterload, and contractility remain normal until the mitral stenosis is severe.

References

- Mitral stenosis.

Physiology Cardiovascular System Mitral stenosis

This patient's **mid-to-late diastolic murmur** is consistent with **mitral stenosis** (MS). MS usually occurs due to underlying rheumatic heart

Exhibit Display

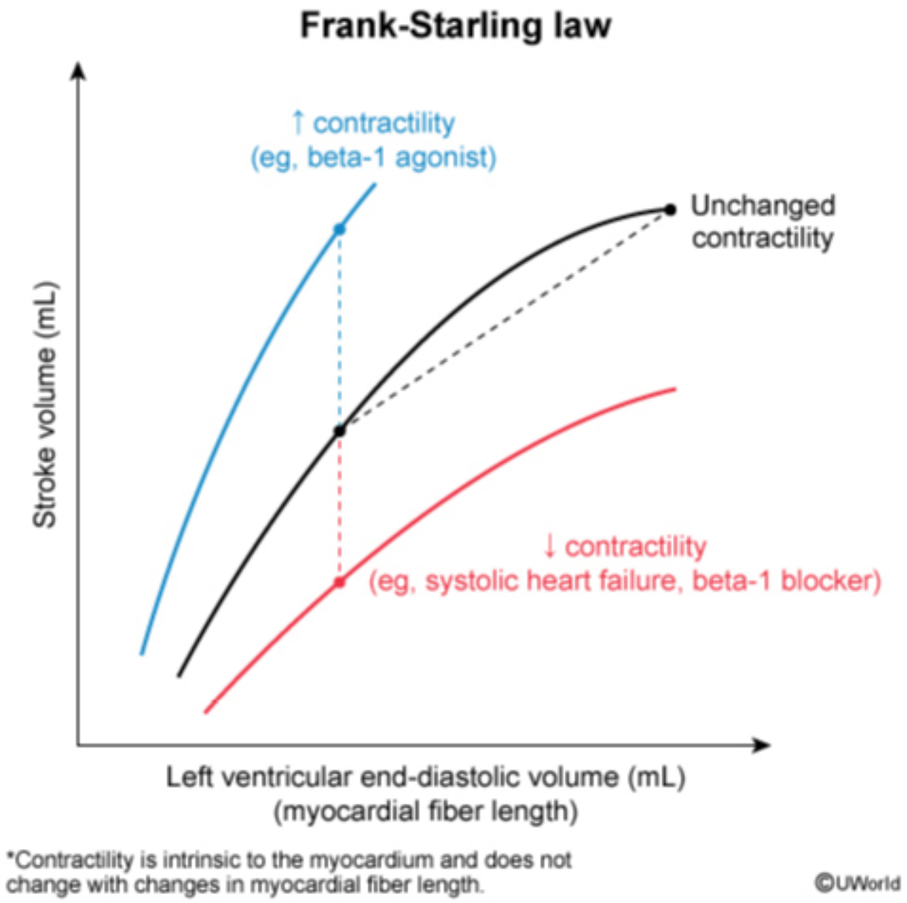

Zoom In Zoom Out Reset Add To Flash Card

Physiology Cardiovascular System Mitral stenosis

This patient's **mid-to-late diastolic murmur** is consistent with **mitral stenosis** (MS). MS usually occurs due to underlying rheumatic heart

Exhibit Display

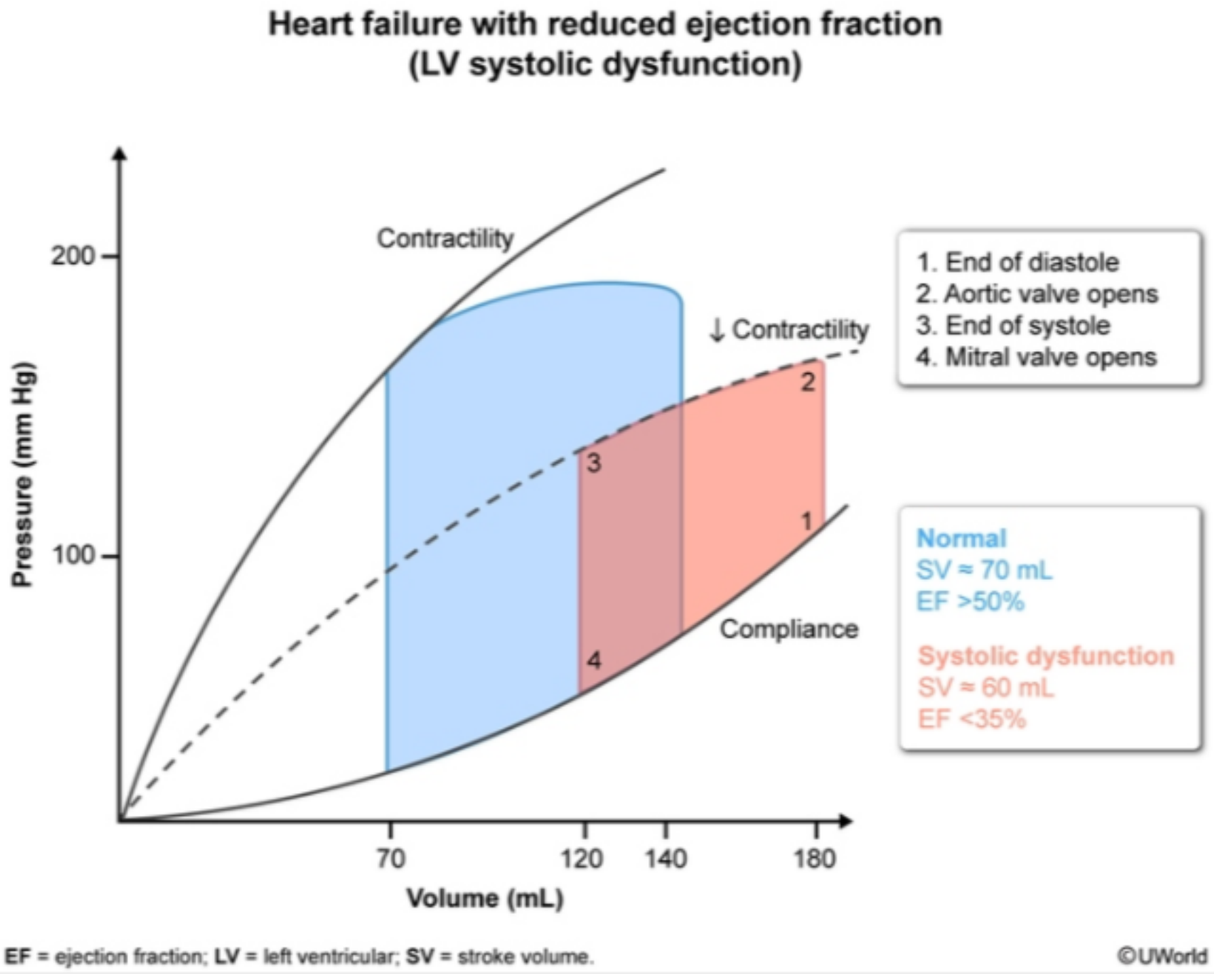

Zoom In Zoom Out Reset Add To Flash Card

Physiology Cardiovascular System Mitral stenosis

This patient's **mid-to-late diastolic murmur** is consistent with **mitral stenosis** (MS). MS usually occurs due to underlying rheumatic heart

Exhibit Display

Heart failure with preserved ejection fraction due to LV diastolic dysfunction

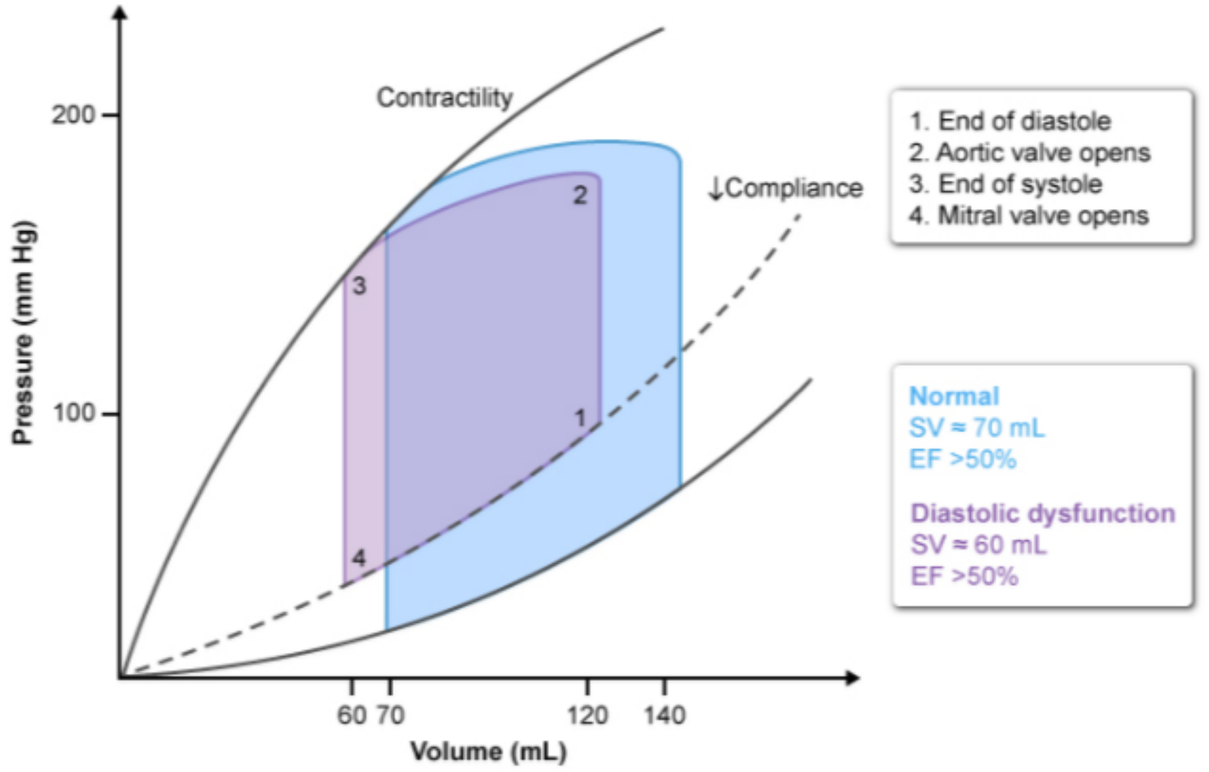

EF = ejection fraction; **LV** = left ventricular; **SV** = stroke volume.

©UWorld

Zoom In Zoom Out Reset Add To Flash Card

Physiology Cardiovascular System Mitral stenosis

A 2-year-old, previously healthy boy is brought to the emergency department due to a 4-day history of poor feeding, diarrhea, and abdominal pain. The patient has had 5-7 bowel movements every day for the past 4 days. Temperature is 36.8 C (98.2 F) and blood pressure is 65/42 mm Hg. On physical examination, the patient is lethargic. Mucous membranes are dry, and the eyes are sunken. The lungs are clear to auscultation. No murmurs are heard. Abdominal examination shows distension and tenderness; bowel sounds are hyperactive throughout. Which of the following changes is most likely present in this patient?

- A. Extravasation of fluid from systemic capillaries
- B. Increased arteriolar capacitance
- C. Increased central venous pressure
- D. Increased ventilatory rate
- E. Relaxation of venous smooth muscle

Submit

A 2-year-old, previously healthy boy is brought to the emergency department due to a 4-day history of poor feeding, diarrhea, and abdominal pain. The patient has had 5-7 bowel movements every day for the past 4 days. Temperature is 36.8 C (98.2 F) and blood pressure is 65/42 mm Hg. On physical examination, the patient is lethargic. Mucous membranes are dry, and the eyes are sunken. The lungs are clear to auscultation. No murmurs are heard. Abdominal examination shows distension and tenderness; bowel sounds are hyperactive throughout. Which of the following changes is most likely present in this patient?

- A. Extravasation of fluid from systemic capillaries (16%)
- B. Increased arteriolar capacitance (9%)
- C. Increased central venous pressure (20%)
- ✓ D. Increased ventilatory rate (47%)
- E. Relaxation of venous smooth muscle (6%)

Omitted
Correct answer
D

47%
Answered correctly

02 secs
Time Spent

05/13/2020
Last Updated

Explanation

1
2
3
4
5
6
7
8
9
10
11
12
13
14
15
16
17
18
19
20
21
22
23

Explanation

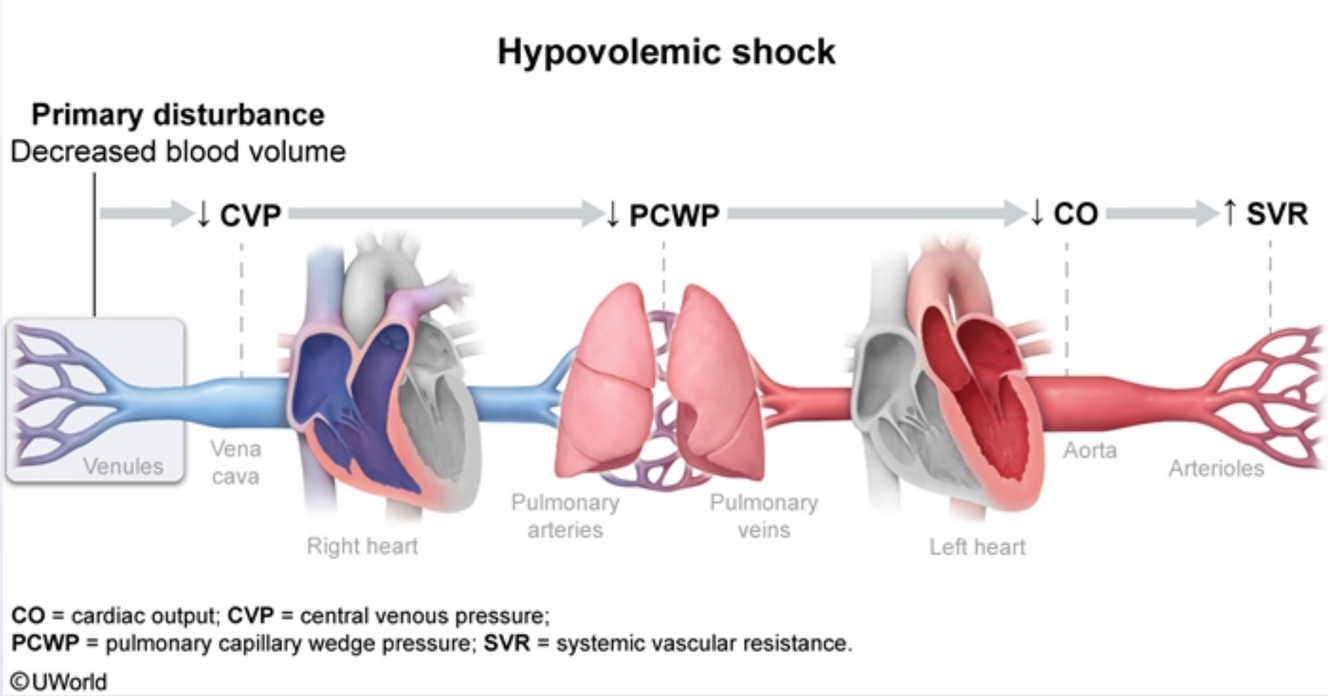

This patient has had several days of poor oral intake and diarrhea and now has signs of **hypovolemia** (eg, dry mucous membranes, sunken eyes) and **shock** (eg, lethargy, severe hypotension). With shock, there is poor organ and tissue perfusion that leads to **tissue hypoxia** with increased anaerobic metabolism and consequent **lactic acidosis**. In response to the reduction in pH caused by metabolic acidosis there is **increased ventilation** to increase CO_2 exhalation (ie, **compensatory respiratory alkalosis**).

Severe diarrhea causes loss of bicarbonate in the stool, further contributing to metabolic acidosis and a compensatory increase in ventilation in this patient.

(Choices A, B, and E) The reduced cardiac output in hypovolemic shock stimulates arteriolar vasoconstriction to increase systemic vascular resistance and help increase blood pressure. This reduces arteriolar capacitance. There is also contraction of venous smooth muscle to cause venular constriction and help increase venous return to the heart. The constricted vasculature reduces extravasation of intravascular fluid. In

CO = cardiac output; **CVP** = central venous pressure;
PCWP = pulmonary capillary wedge pressure; **SVR** = systemic vascular resistance.

©UWorld

This patient has had several days of poor oral intake and diarrhea and now has signs of **hypovolemia** (eg, dry mucous membranes, sunken eyes) and **shock** (eg, lethargy, severe hypotension). With shock, there is poor organ and tissue perfusion that leads to **tissue hypoxia** with increased anaerobic metabolism and consequent **lactic acidosis**. In response to the reduction in pH caused by metabolic acidosis there is **increased ventilation** to increase CO_2 exhalation (ie, **compensatory respiratory alkalosis**).

Severe diarrhea causes loss of bicarbonate in the stool, further contributing to metabolic acidosis and a compensatory increase in ventilation in this patient.

(Choices A, B, and E) The reduced cardiac output in hypovolemic shock stimulates arteriolar vasoconstriction to increase systemic vascular resistance and help increase blood pressure. This reduces arteriolar capacitance. There is also contraction of venous smooth muscle to cause venular constriction and help increase venous return to the heart. The constricted vasculature reduces extravasation of intravascular fluid. In contrast, septic shock involves peripheral vasodilation with relaxation of vascular smooth muscle, increased vascular capacitance, and extravasation of intravascular fluid.

(Choice C) Blood volume is markedly decreased in hypovolemic shock, leading to decreased central venous pressure. Central venous pressure is increased in cardiogenic shock and obstructive shock.

Educational objective:
Hypovolemic shock results from markedly decreased blood volume, which reduces central venous pressure and cardiac output and leads to increased systemic vascular resistance (peripheral vasoconstriction). Shock causes reduced organ and tissue perfusion, which leads to lactic acidosis (metabolic acidosis) and a compensatory increase in ventilation (ie, compensatory respiratory alkalosis).

Physiology	Cardiovascular System	Hypovolemic shock
Subject	System	Topic

Copyright © UWorld. All rights reserved.

Exhibit Display



Zoom In Zoom Out Reset Add To Flash Card

1
2
3
4
5
6
7
8
9
10
11
12
13
14
15
16
17
18
19
20
21
22
23

Exhibit Display

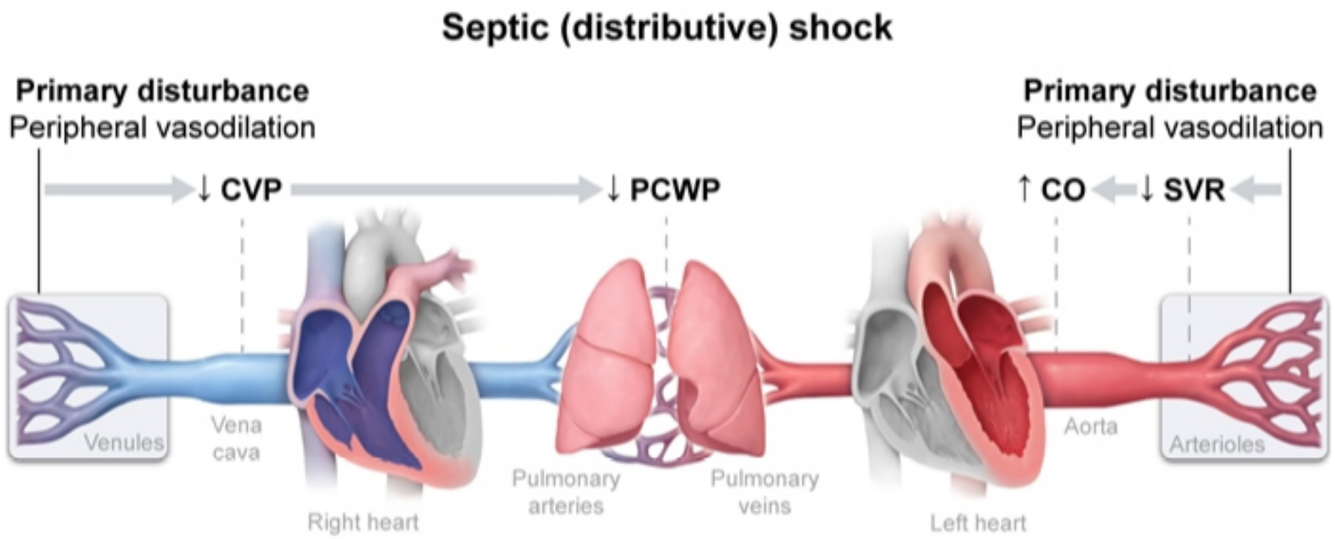

CO = cardiac output; **CVP** = central venous pressure;
PCWP = pulmonary capillary wedge pressure; **SVR** = systemic vascular resistance.

©UWorld

Zoom In Zoom Out Reset Add To Flash Card

1
2
3
4
5
6
7
8
9
10
11
12
13
14
15
16
17
18
19
20
21
22
23

Exhibit Display

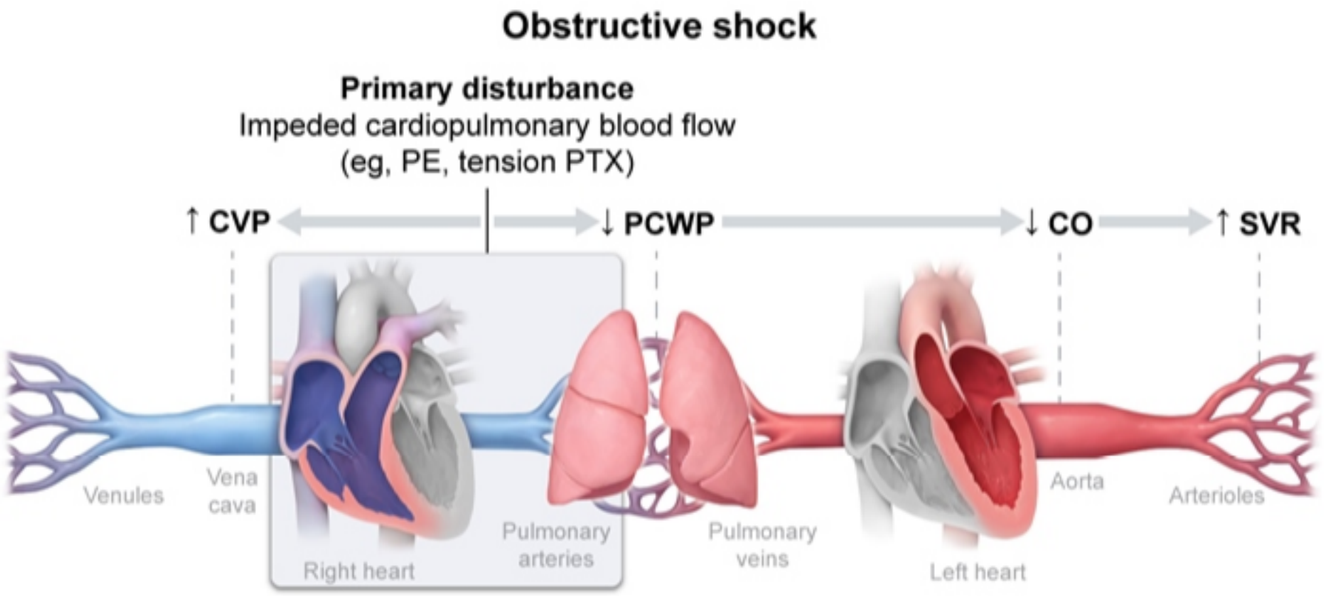

CO = cardiac output; **CVP** = central venous pressure; **PCWP** = pulmonary capillary wedge pressure; **PE** = pulmonary embolism; **PTX** = pneumothorax; **SVR** = systemic vascular resistance.

©UWorld

Zoom In Zoom Out Reset Add To Flash Card

1
2
3
4
5
6
7
8
9
10
11
12
13
14
15
16
17
18
19
20
21
22
23

Exhibit Display

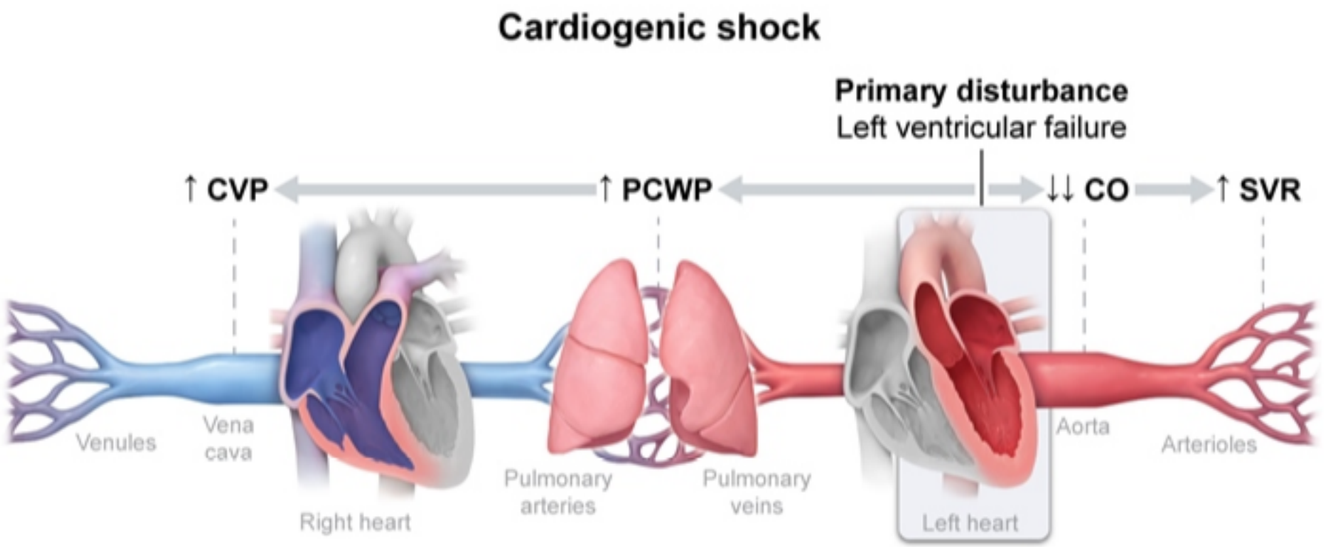

CO = cardiac output; **CVP** = central venous pressure;
PCWP = pulmonary capillary wedge pressure; **SVR** = systemic vascular resistance.

©UWorld

Zoom In Zoom Out Reset Add To Flash Card

A 33-year-old man comes to the office due to fatigue and decreased exercise tolerance over the past 6 months. The patient was diagnosed with infective endocarditis in the setting of intravenous drug use a year ago and completed a course of antibiotic therapy. He has not used drugs since then. The patient has no other medical problems and takes no medications. A cardiac murmur is heard on auscultation. Both carotid arteries demonstrate a rapid rise and fall of the arterial pulse. Partial compression of the femoral arteries by the stethoscope elicits a systolic-diastolic bruit. Which of the following sets of pressure findings is most likely to be observed during cardiac catheterization of this patient?

	Aortic pressure	Left ventricular pressure
A.	110/75	160/20
B.	120/80	120/10
C.	120/75	120/30
D.	160/60	160/20
E.	160/95	160/10

Submit

A 33-year-old man comes to the office due to fatigue and decreased exercise tolerance over the past 6 months. The patient was diagnosed with infective endocarditis in the setting of intravenous drug use a year ago and completed a course of antibiotic therapy. He has not used drugs since then. The patient has no other medical problems and takes no medications. A cardiac murmur is heard on auscultation. Both carotid arteries demonstrate a rapid rise and fall of the arterial pulse. Partial compression of the femoral arteries by the stethoscope elicits a systolic-diastolic bruit. Which of the following sets of pressure findings is most likely to be observed during cardiac catheterization of this patient?

	Aortic pressure	Left ventricular pressure
A. (28%)	110/75	160/20
B. (4%)	120/80	120/10
C. (7%)	120/75	120/30
✓ D. (48%)	160/60	160/20
E. (10%)	160/95	160/10

Omitted
Correct answer
D

48%
Answered correctly

02 secs
Time Spent

02/23/2020
Last Updated

Explanation

1
2
3
4
5
6
7
8
9
10
11
12
13
14
15
16
17
18
19
20
21
22
23

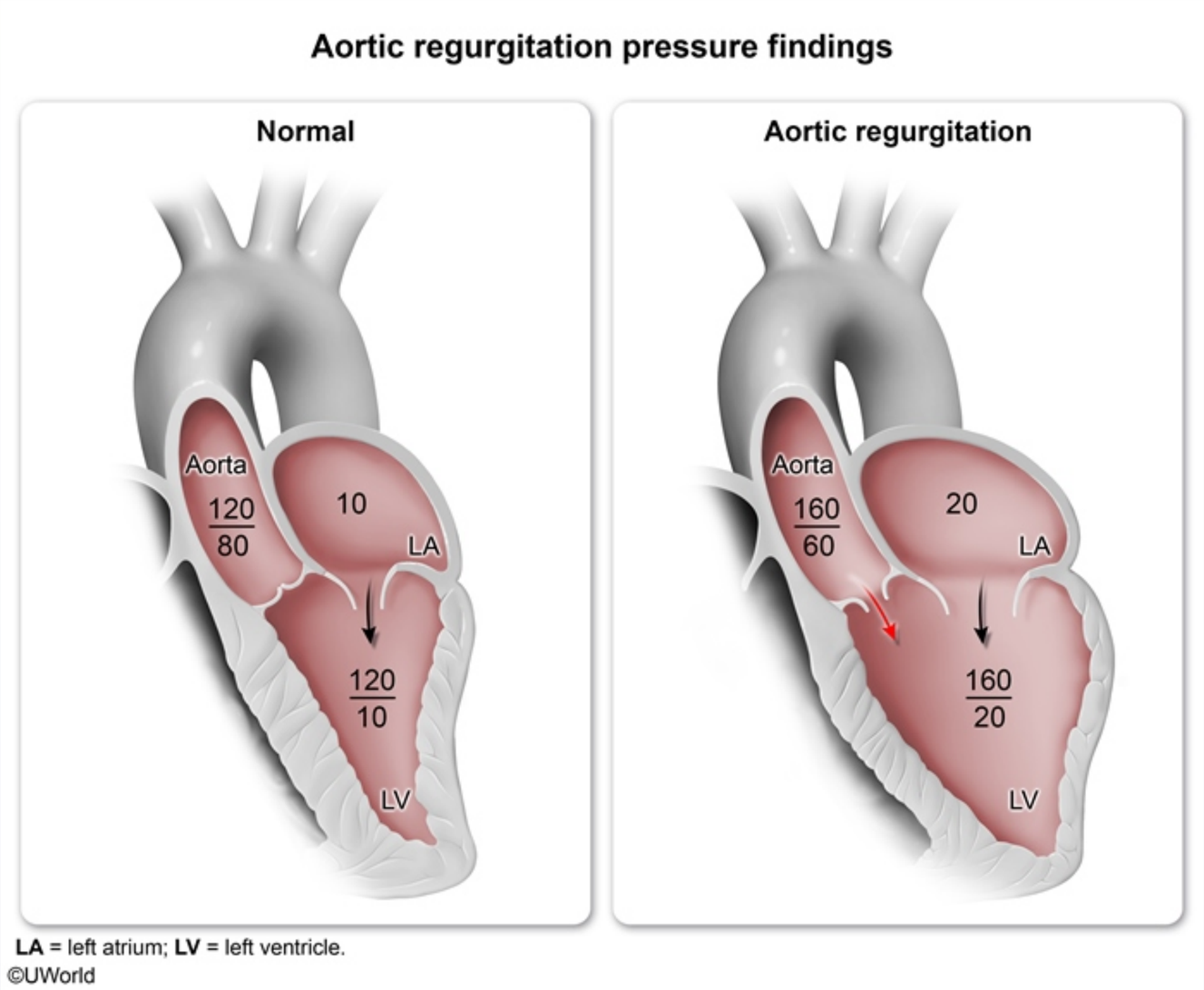

This patient's presentation is consistent with **aortic regurgitation** (AR), which likely developed as a complication of infective endocarditis. AR is characterized by a rapid **loss of aortic pressure** during diastole due to backflow of blood into the left ventricle. The left ventricle becomes dilated

This patient's presentation is consistent with **aortic regurgitation** (AR), which likely developed as a complication of infective endocarditis. AR is characterized by a rapid **loss of aortic pressure** during diastole due to backflow of blood into the left ventricle. The left ventricle becomes dilated with an increase in end-diastolic volume and undergoes eccentric hypertrophy that allows for a compensatory **increase in stroke volume** and cardiac output. The result of these effects is a characteristic high-amplitude, **rapid rise-rapid fall pulsation** with each ventricular contraction that manifests as widened pulse pressure, rapid distension and collapse of the carotid arteries (Corrigan sign), and a "to-and-fro" bruit appreciated over the femoral arteries (Duroziez sign).

The hemodynamic changes in AR are evident on cardiac catheterization and include **reduced aortic diastolic pressure** and **elevated left ventricular (LV) diastolic pressure** due to backflow of blood during diastole. In addition, **aortic and LV systolic pressures are increased** due to high stroke volume and a compensatory increase in cardiac contractility.

(Choice A) LV systolic pressure that is higher than aortic systolic pressure is consistent with aortic stenosis. Patients with aortic stenosis have weak and delayed pulses (pulsus parvus et tardus) and pulse pressure may be reduced due to restricted stroke volume. The LV often undergoes concentric hypertrophy (wall-thickening) due to pressure overload.

(Choice B) These are normal LV and aortic pressure findings on cardiac catheterization.

(Choice C) Normal LV systolic and aortic pressures but elevated LV end-diastolic pressure is consistent with compensated heart failure. The left ventricle often undergoes eccentric hypertrophy due to volume overload.

(Choice E) Elevated aortic pressures with no systolic pressure gradient across the aortic valve and normal LV diastolic pressure is consistent with systemic hypertension. Concentric hypertrophy may develop due to pressure overload.

Educational objective:
Aortic regurgitation causes a rapid fall in aortic pressure during diastole with an increase in left ventricular end-diastolic volume and a compensatory increase in stroke volume. These hemodynamic changes create characteristic pressure changes, including reduced aortic diastolic pressure, increased aortic systolic pressure, and increased left ventricular diastolic and systolic pressures.

References

- Clinical practice. Aortic regurgitation.

Physiology Cardiovascular System Aortic regurgitation

This patient's presentation is consistent with **aortic regurgitation** (AR), which likely developed as a complication of infective endocarditis. AR is

Exhibit Display

Aortic stenosis pressure findings

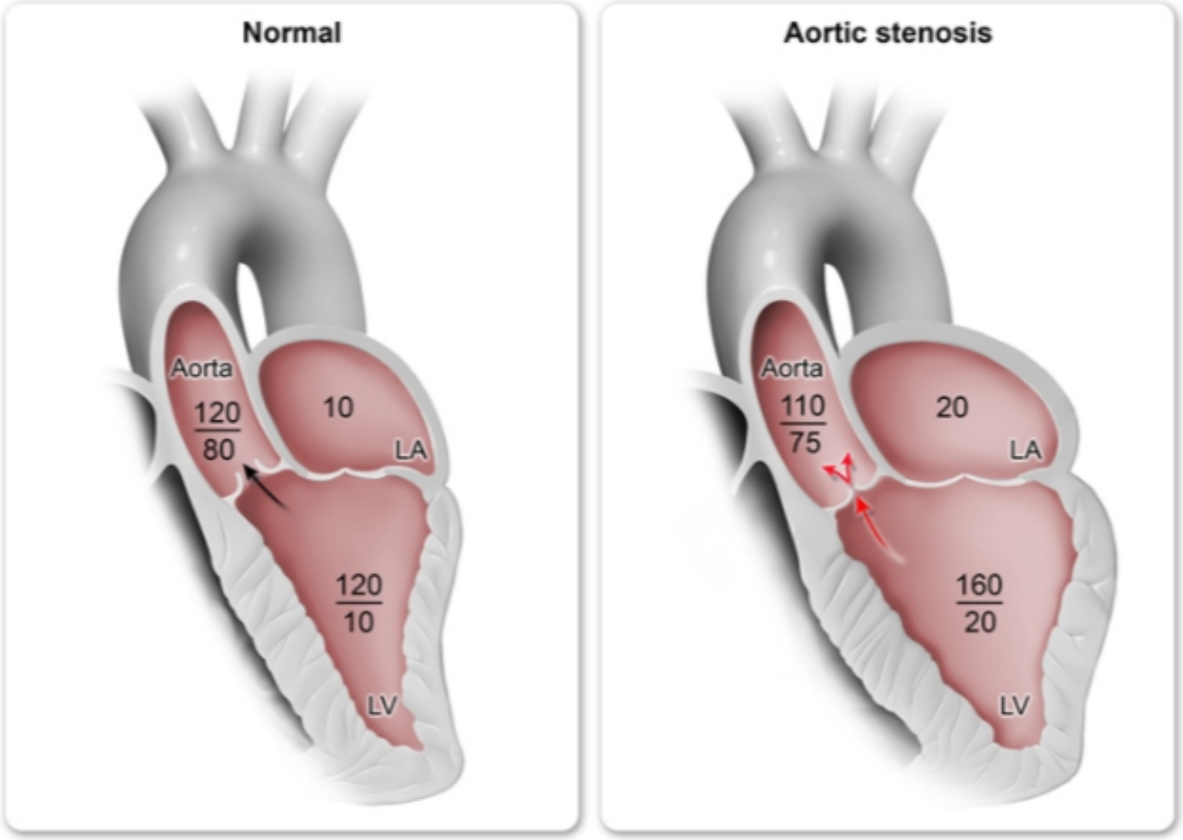

LA = left atrium; **LV** = left ventricle.

©UWorld

Zoom In | Zoom Out | Reset | Add To New Card | Existing Card

This patient's presentation is consistent with **aortic regurgitation** (AR), which likely developed as a complication of infective endocarditis. AR is

Exhibit Display

Heart failure pressure findings

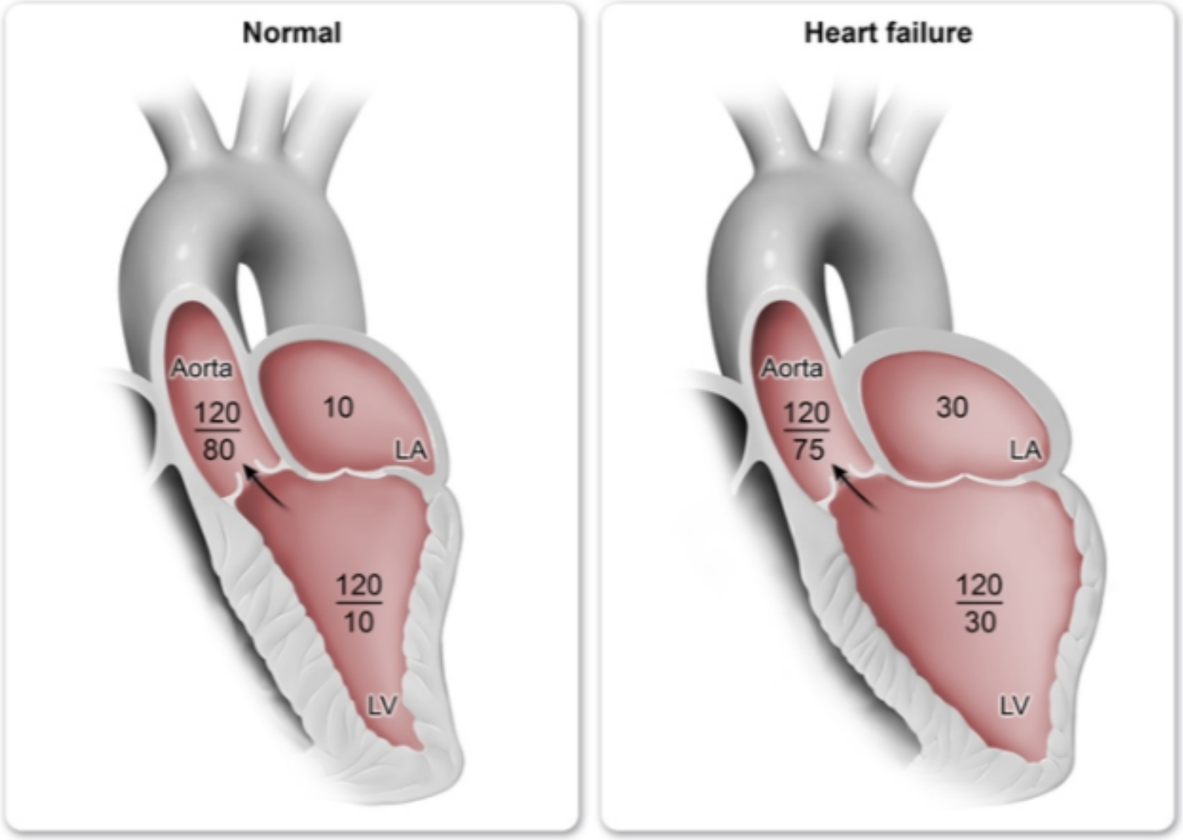

LA = left atrium; **LV** = left ventricle.

©UWorld

Zoom In | Zoom Out | Reset | Add To New Card | Existing Card

1
2
3
4
5
6
7
8
9
10
11
12
13
14
15
16
17
18
19
20
21
22
23

This patient's presentation is consistent with **aortic regurgitation** (AR), which likely developed as a complication of infective endocarditis. AR is

Exhibit Display

Systemic hypertension pressure findings

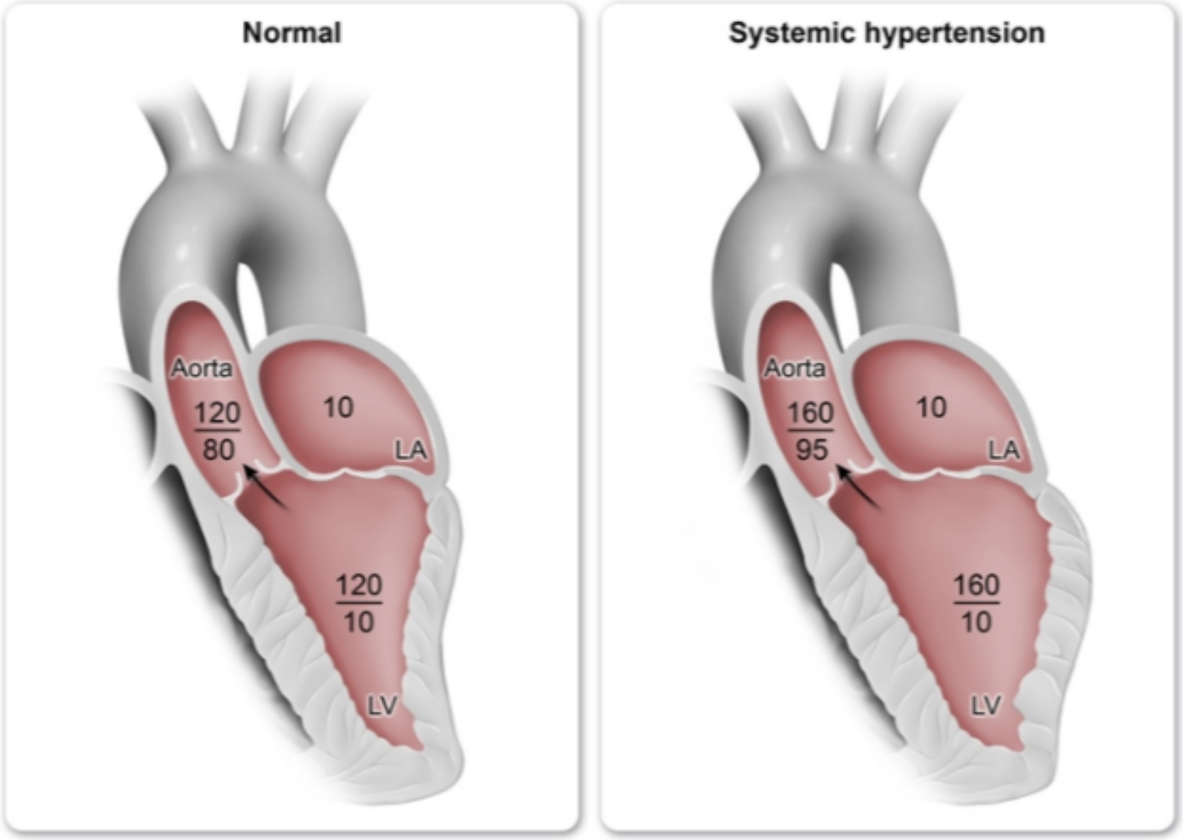

LA = left atrium; **LV** = left ventricle.

©UWorld

Zoom In | Zoom Out | Reset | Add To New Card | Existing Card

A 10-year-old boy is brought to the clinic by his parents due to chronic fatigue, shortness of breath, and failure to gain weight. The child was recently adopted from an orphanage in Asia. He weighs 20 kg (44.2 lb). Vital signs are within normal limits. Physical examination reveals a loud systolic murmur. Echocardiogram shows pulmonary stenosis and subaortic ventricular septal defect with deviation of the origin of the aorta to the right. The mother describes occasional episodes of severe dyspnea and cyanosis, during which the child quickly assumes a squatting position. Which of the following mechanisms during squatting relieves this child's symptoms?

- A. Decreasing left ventricular workload
- B. Decreasing pulmonary blood flow
- C. Decreasing pulmonary vascular resistance
- D. Improving lung compliance
- E. Increasing systemic vascular resistance

Submit

A 10-year-old boy is brought to the clinic by his parents due to chronic fatigue, shortness of breath, and failure to gain weight. The child was recently adopted from an orphanage in Asia. He weighs 20 kg (44.2 lb). Vital signs are within normal limits. Physical examination reveals a loud systolic murmur. Echocardiogram shows pulmonary stenosis and subaortic ventricular septal defect with deviation of the origin of the aorta to the right. The mother describes occasional episodes of severe dyspnea and cyanosis, during which the child quickly assumes a squatting position. Which of the following mechanisms during squatting relieves this child's symptoms?

- A. Decreasing left ventricular workload (9%)
- B. Decreasing pulmonary blood flow (3%)
- C. Decreasing pulmonary vascular resistance (10%)
- D. Improving lung compliance (0%)
- ✓ E. Increasing systemic vascular resistance (75%)

Omitted
Correct answer
E

75%
Answered correctly

02 secs
Time Spent

04/11/2020
Last Updated

Explanation

1
2
3
4
5
6
7
8
9
10
11
12
13
14
15
16
17
18
19
20
21
22
23

Tetralogy of Fallot

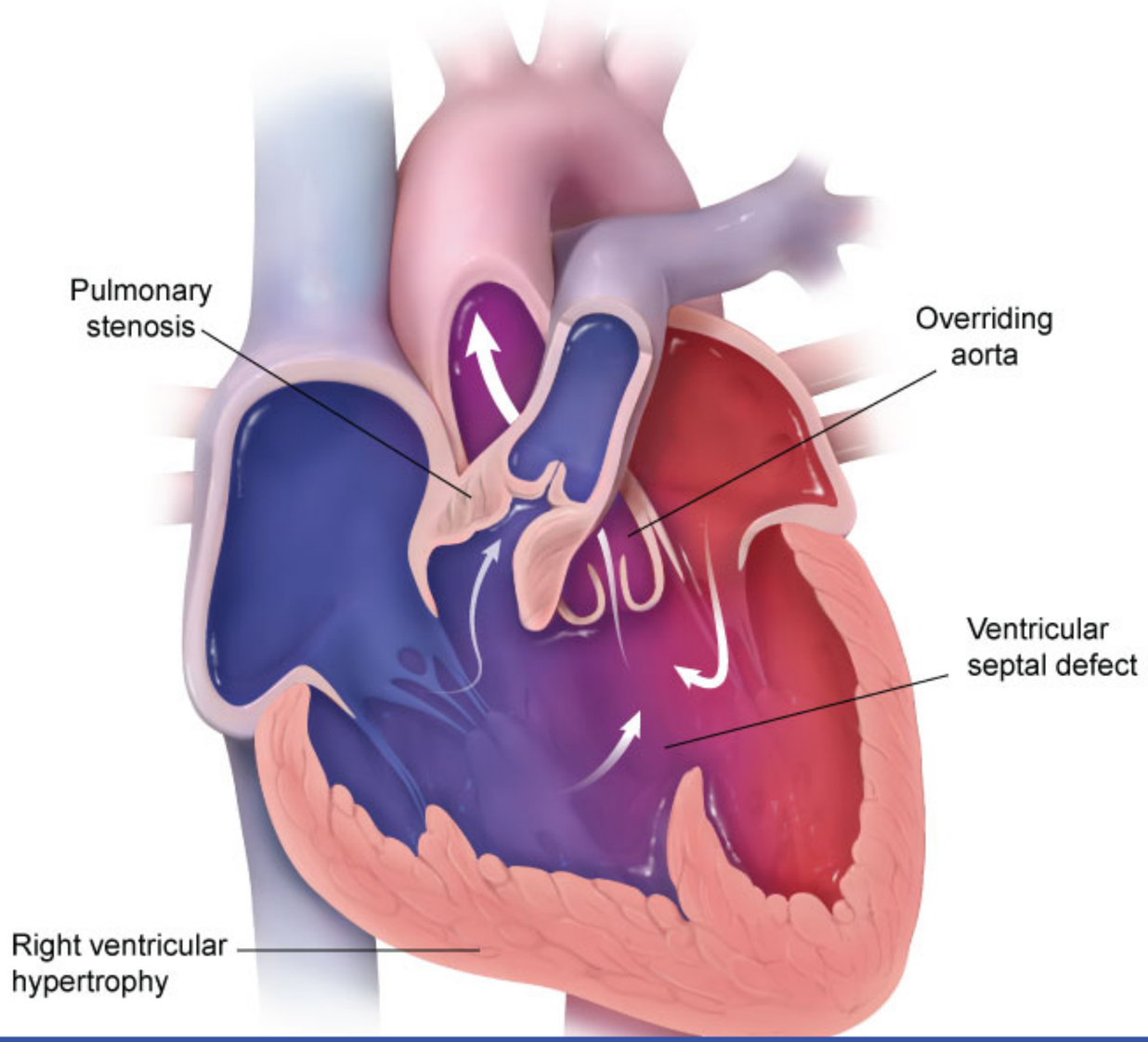

1
2
3
4
5
6
7
8
9
10
11
12
13
14
15
16
17
18
19
20
21
22
23

This child has **Tetralogy of Fallot** (ToF) with ventricular septal defect, overriding aorta, pulmonic stenosis, and right ventricular hypertrophy. The pulmonic stenosis and overriding aorta cause a relatively low ratio of systemic vascular resistance (SVR) to pulmonary vascular resistance (PVR). This low SVR:PVR ratio allows the **deoxygenated** right ventricular output to take the low-resistance route to the **systemic** circulation, leading to acute hypoxemia ("Tet spell"). Tet spells are most common in infancy but can occur at any age in children with unrepaired ToF. The mechanism of Tet spells has not been clearly defined but may be caused by acute changes of the infundibular septum leading to more right ventricular outflow tract obstruction.

Children with ToF quickly learn to squat to relieve Tet spells (infants who cannot squat can be placed in the knee-to-chest position by their caregiver). This posture quickly **increases SVR** without changing PVR, increasing the SVR:PVR ratio. The increased SVR forces a higher proportion of right ventricular output to enter the pulmonary circulation and oxygenate in the pulmonary capillary beds, increasing arterial oxygen concentration and relieving the Tet spell.

(Choices A and D) Squatting restricts chest wall expansion and slightly increases work of breathing. Lung compliance is not changed by this positioning.

(Choices B and C) Squatting does not significantly impact PVR as the compressed vessels are primarily in the abdomen and lower extremities. Pulmonary blood flow increases – not decreases – due to decreased right-to-left shunt with increased SVR.

Educational objective:
In patients with Tetralogy of Fallot, squatting during a Tet spell increases systemic vascular resistance and decreases right-to-left shunting, thereby increasing pulmonary blood flow and improving oxygenation status.

Physiology	Cardiovascular System	Tetralogy of fallot
Subject	System	Topic

Copyright © UWorld. All rights reserved.

Physiologists conducting research on the electrical properties of the heart measure action potential conduction velocity at 4 different points within normal cardiac tissue. The results, expressed in terms of speed of conduction (meters per second), are as follows:

Point 1 – 0.05 m/sec
Point 2 – 0.3 m/sec
Point 3 – 1.1 m/sec
Point 4 – 2.2 m/sec

From the following list of locations, which most likely corresponds to the order of points 1-2-3-4 (AV = atrioventricular)?

A. Atrial muscle, ventricular muscle, Purkinje system, AV node
B. AV node, Purkinje system, ventricular muscle, atrial muscle
C. AV node, ventricular muscle, atrial muscle, Purkinje system
D. Purkinje system, AV node, ventricular muscle, atrial muscle
E. Ventricular muscle, AV node, Purkinje system, atrial muscle

Submit

Physiologists conducting research on the electrical properties of the heart measure action potential conduction velocity at 4 different points within normal cardiac tissue. The results, expressed in terms of speed of conduction (meters per second), are as follows:

Point 1 – 0.05 m/sec
Point 2 – 0.3 m/sec
Point 3 – 1.1 m/sec
Point 4 – 2.2 m/sec

From the following list of locations, which most likely corresponds to the order of points 1-2-3-4 (AV = atrioventricular)?

A. Atrial muscle, ventricular muscle, Purkinje system, AV node (15%)
B. AV node, Purkinje system, ventricular muscle, atrial muscle (15%)
✓ C. AV node, ventricular muscle, atrial muscle, Purkinje system (49%)
D. Purkinje system, AV node, ventricular muscle, atrial muscle (14%)
E. Ventricular muscle, AV node, Purkinje system, atrial muscle (3%)

Omitted
Correct answer
C

49%
Answered correctly

03 secs
Time Spent

03/24/2020
Last Updated

Explanation

1
2
3
4
5
6
7
8
9
10
11
12
13
14
15
16
17
18
19
20
21
22
23

Cardiac tissue conduction velocity

Fastest

Purkinje system

↓

Atrial muscle

↓

Ventricular muscle

↓

AV node

1
2
3
4
5
6
7
8
9
10
11
12
13
14
15
16
17
18
19
20
21
22
23

Exhibit Display

Cardiac tissue conduction velocity

Fastest

Purkinje system

↓

Atrial muscle

↓

Ventricular muscle

↓

AV node

Slowest

Mnemonic: "**Park At Venture Avenue**"

©UWorld

Zoom In | Zoom Out | Reset | Add To New Card | Existing Card

Slowest

Mnemonic: "**P**ark **At** **Ven**ture **A**venue"

©UWorld

Cardiac impulses normally originate in the sinoatrial (SA) node. SA node depolarization delivers an electrical impulse to the surrounding atrial myocardium, which carries the action potential to the atrioventricular (AV) node at a rate of 1.1 m/sec. Speed of conduction in the **AV node** is the **slowest** (0.05 m/sec), and this delay allows the ventricles to completely fill with blood during diastole. From the AV node, the action potential enters the His-Purkinje system. Impulses travel the **fastest** through the **Purkinje fibers** (2.2 m/sec), which ensures that the ventricles contract in a bottom-up fashion (necessary for efficient propulsion of blood into the pulmonary artery and aorta). From the Purkinje fibers, the action potential is transmitted to the ventricular myocardium, where it travels at a rate of 0.3 m/sec.

Points 1-2-3-4 are arranged in order of increasing **conduction speed** (not conduction time), as follows:

Point 1 – AV node (0.05 m/sec)
Point 2 – Ventricular muscle (0.3 m/sec)
Point 3 – Atrial muscle (1.1 m/sec)
Point 4 – Purkinje system (2.2 m/sec)

Educational objective:
The cardiac action potential conduction speed is slowest in the atrioventricular node and fastest in the Purkinje system. Conduction speed of the atrial muscle is faster than that of the ventricular muscle.

Physiology	Cardiovascular System	Cardiac physiology
Subject	System	Topic

Copyright © UWorld. All rights reserved.

A 34-year-old man comes to the clinic for evaluation of a heart murmur. The patient has no chest pain, palpitations, dizziness, or shortness of breath at rest. He also exercises regularly without any abnormal symptoms. Cardiac auscultation in the second right intercostal space reveals an ejection click along with a soft systolic murmur radiating to the neck. A normal volume and pressure tracing of the left ventricle is shown in the image below. Which of the following letters corresponds to the opening of the valve most likely affected in this patient?

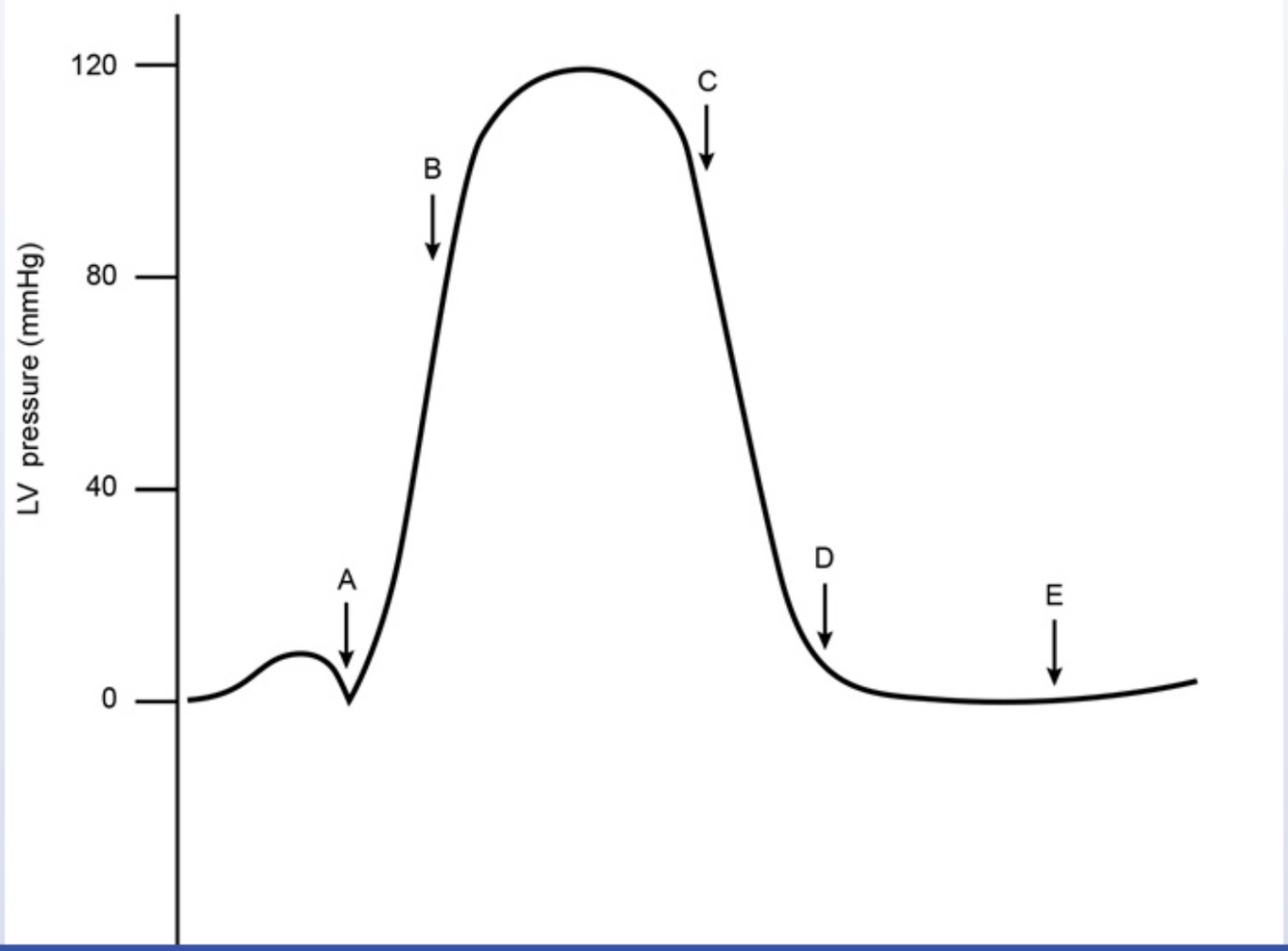

1
2
3
4
5
6
7
8
9
10
11
12
13
14
15
16
17
18
19
20
21
22
23

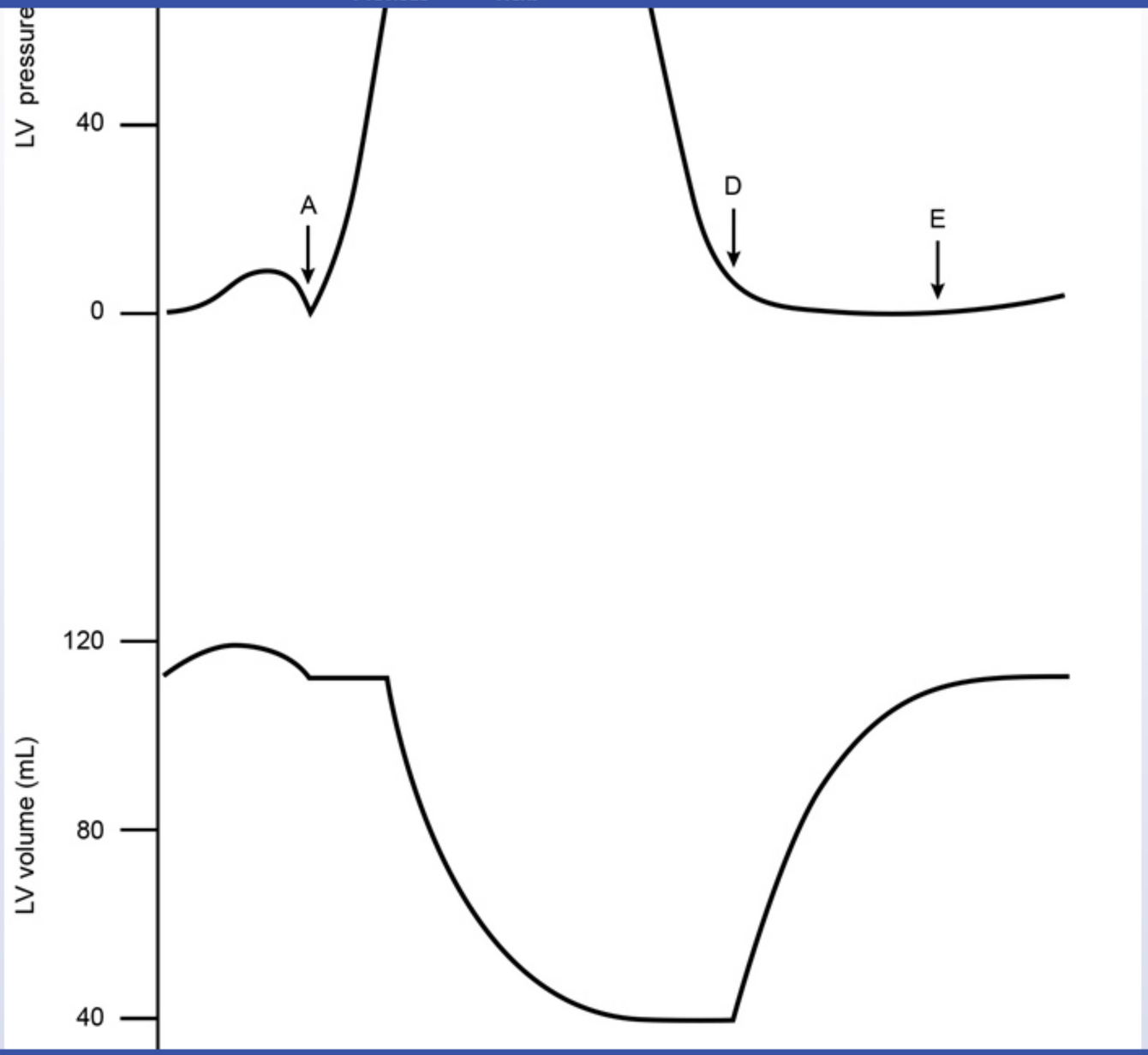

1
2
3
4
5
6
7
8
9
10
11
12
13
14
15
16
17
18
19
20
21
22
23

Exhibit Display

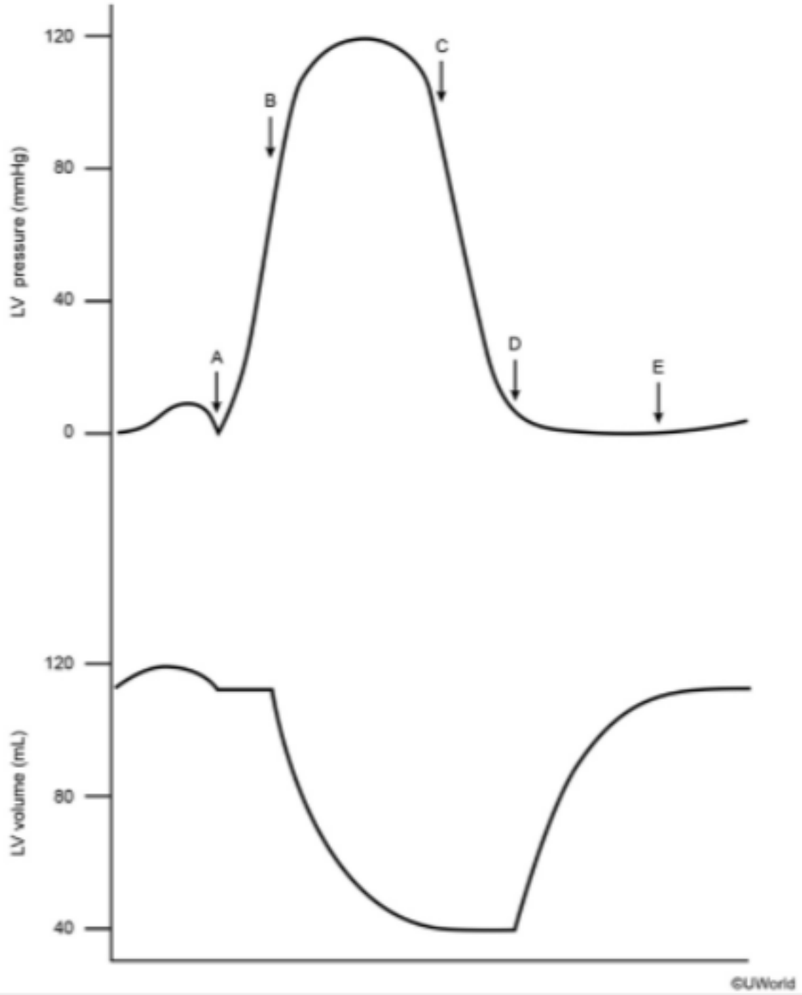

Zoom In | Zoom Out | Reset | Add To New Card | Existing Card

1
2
3
4
5
6
7
8
9
10
11
12
13
14
15
16
17
18
19
20
21
22
23

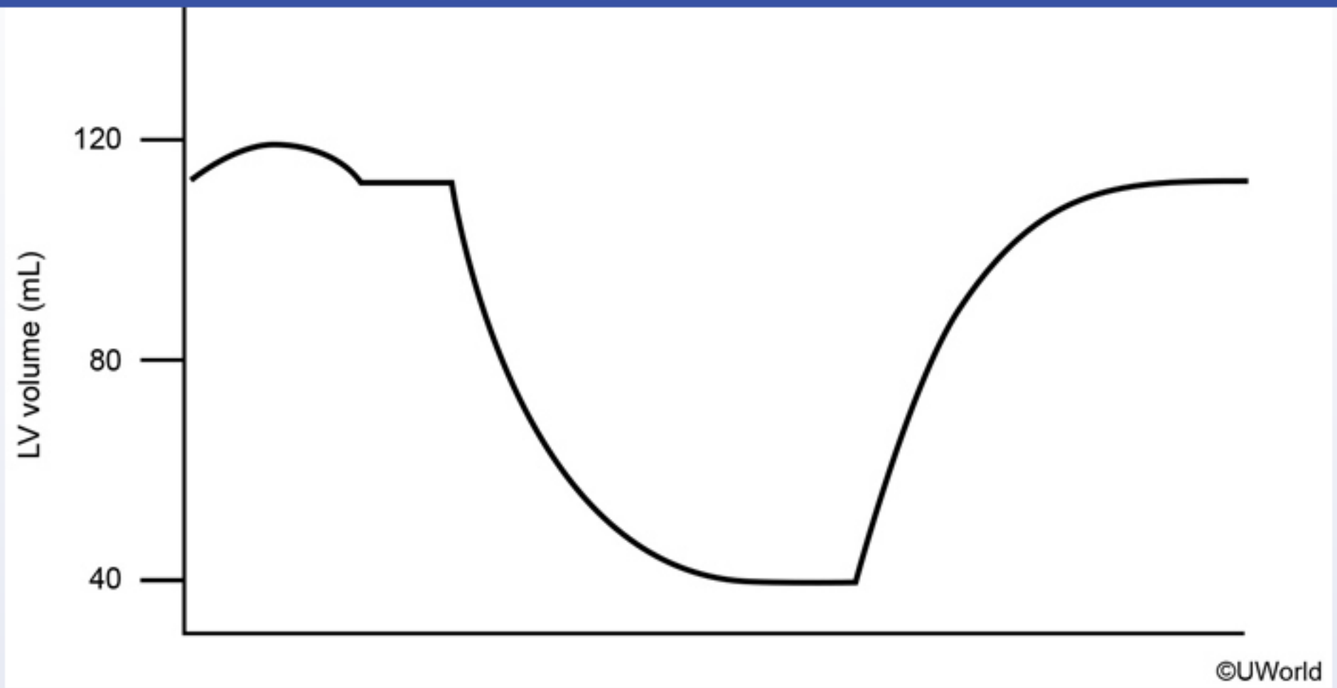

A. A
B. B
C. C
D. D
E. E

Submit

1
2
3
4
5
6
7
8
9
10
11
12
13
14
15
16
17
18
19
20
21
22
23

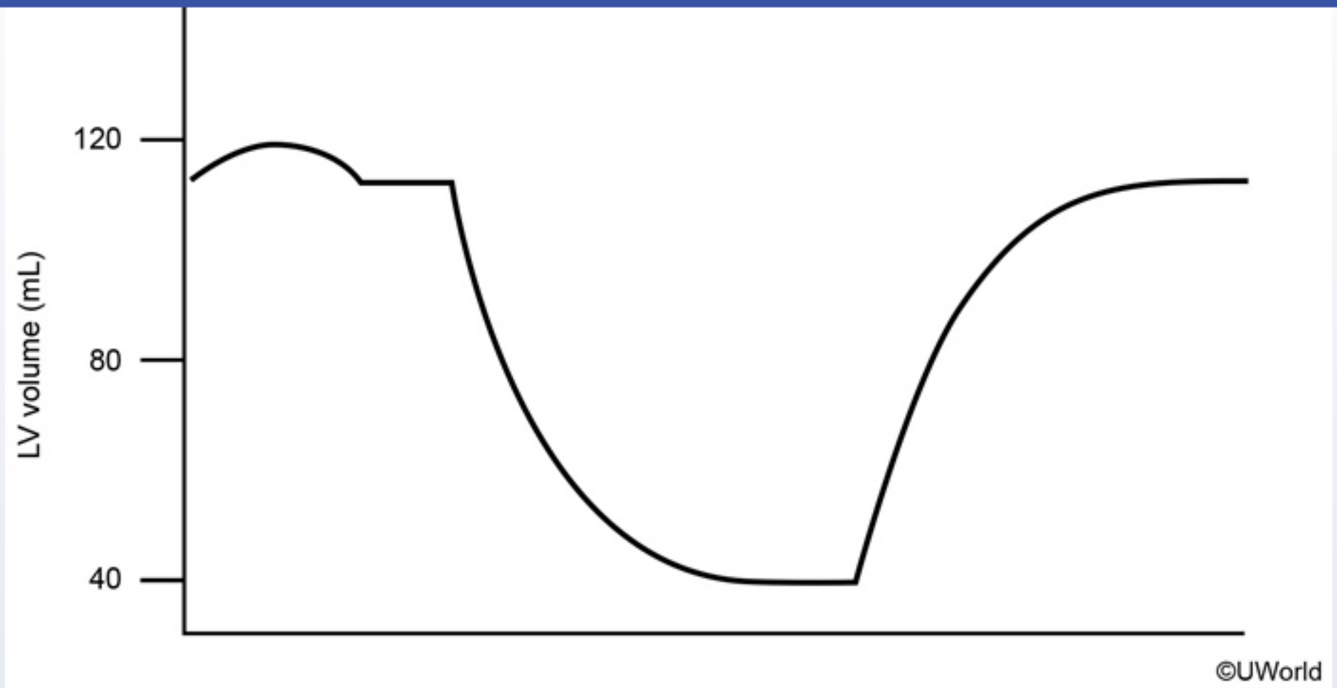

A. A (7%)
B. B (77%) ✓
C. C (8%)
D. D (5%)
E. E (0%)

Omitted
Correct answer

77%
Answered correctly

13 secs
Time Spent

03/30/2020
Last Updated

1
2
3
4
5
6
7
8
9
10
11
12
13
14
15
16
17
18
19
20
21
22
23

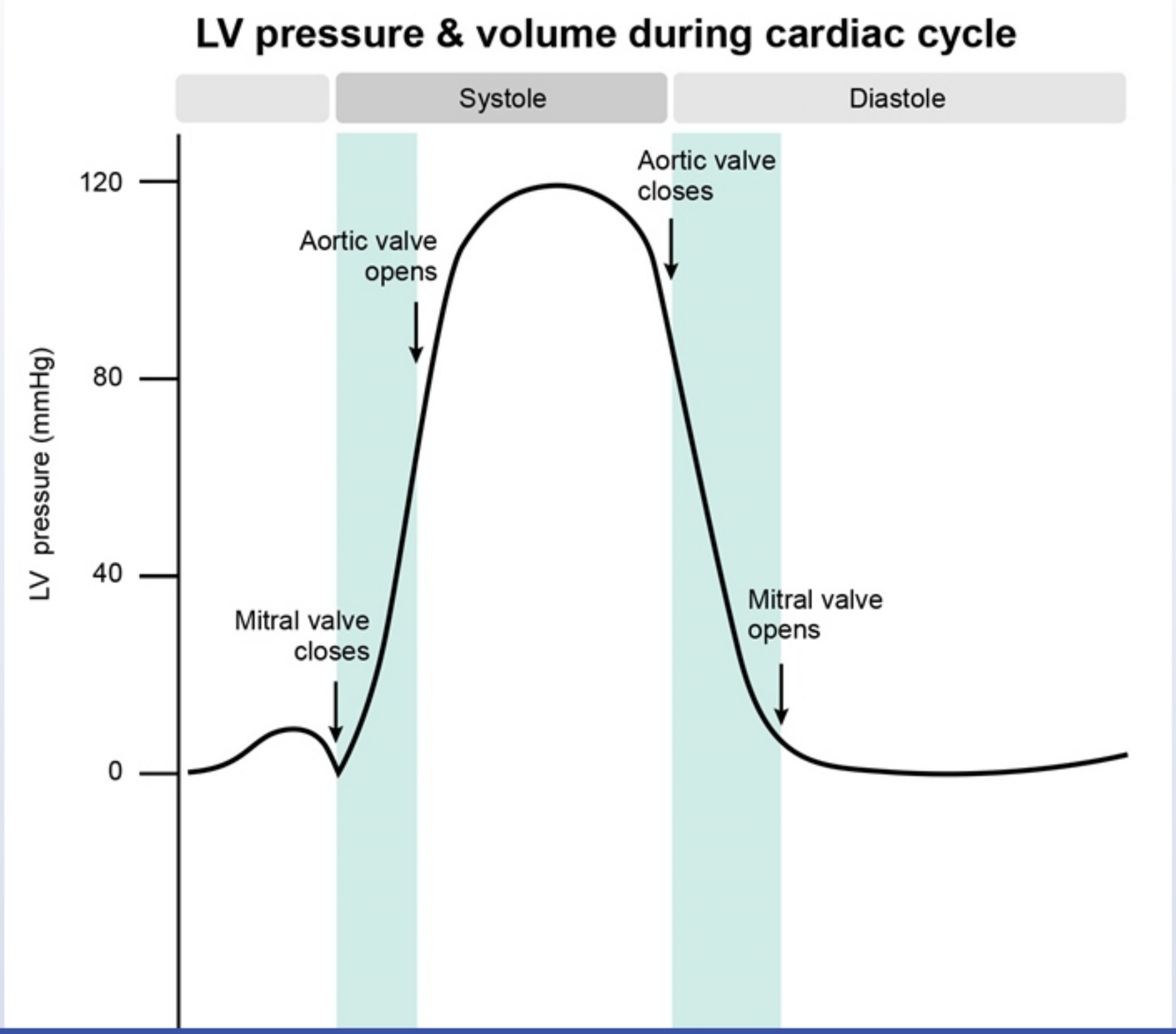

1
2
3
4
5
6
7
8
9
10
11
12
13
14
15
16
17
18
19
20
21
22
23

Exhibit Display

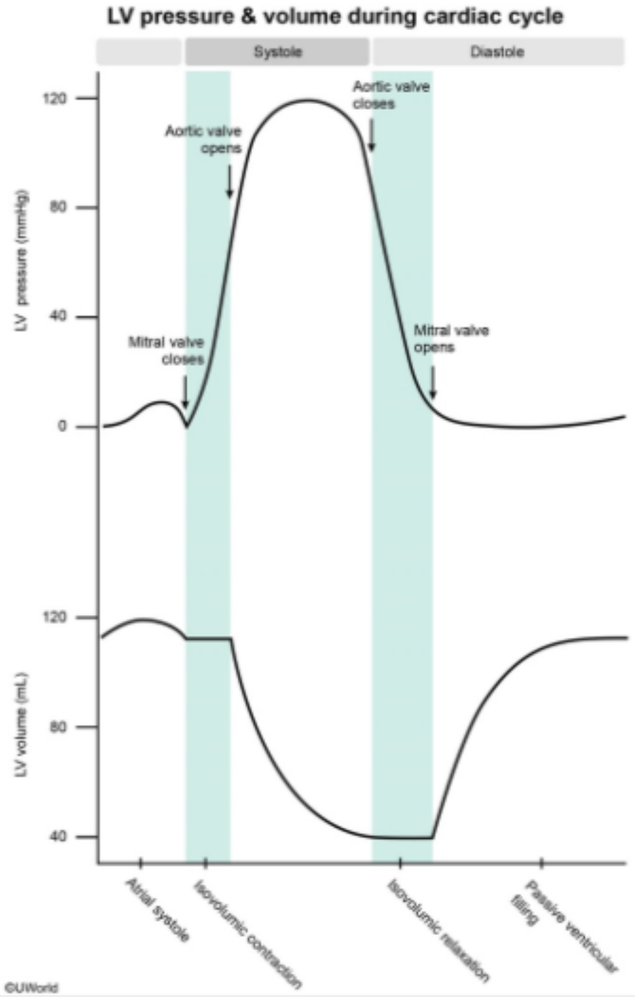

Zoom In | Zoom Out | Reset | Add To New Card | Existing Card

1
2
3
4
5
6
7
8
9
10
11
12
13
14
15
16
17
18
19
20
21
22
23

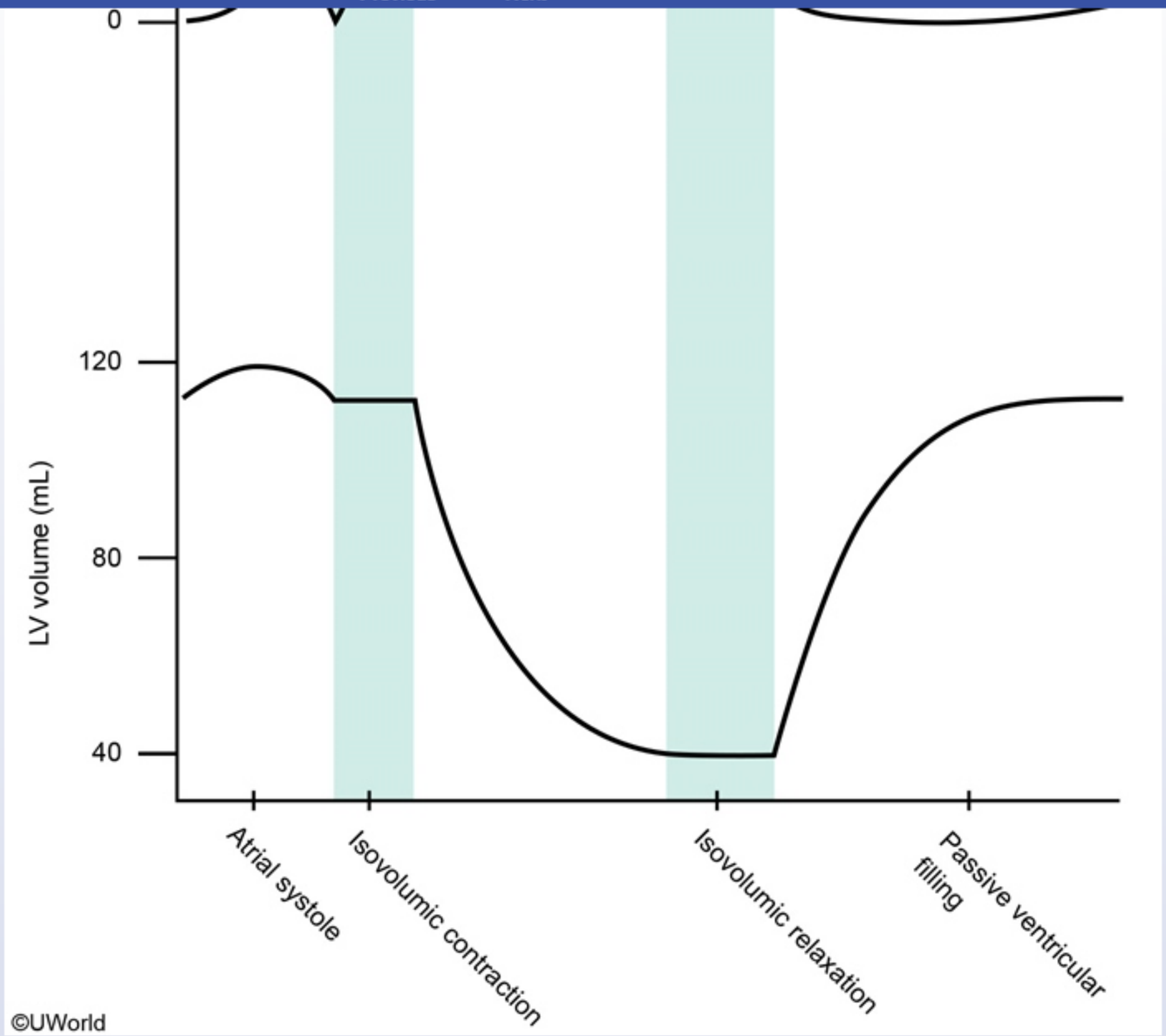

This young, asymptomatic patient with a soft systolic ejection murmur at the right second intercostal space most likely has a **bicuspid aortic**

©UWorld

This young, asymptomatic patient with a soft systolic ejection murmur at the right second intercostal space most likely has a **bicuspid aortic valve**.

The graph above depicts the normal left ventricular (LV) pressure and volume curves during the cardiac cycle. Ventricular pressure and volume curves allow one to identify the phases of the cardiac cycle and to determine the exact time of opening and closure of the cardiac valves. **Aortic valve opening** occurs when the LV pressure exceeds the central aortic pressure at the **end of isovolumetric contraction**. Subsequently, LV pressure continues to rise with forward blood flow into the aorta, until the pressure in the left ventricle falls below the aortic pressure leading to aortic valve closure.

(Choice A) The initial part of the LV pressure and volume curves corresponds to atrial systole, which results in a slight increase in LV volume and pressure. This is immediately followed by mitral valve closure and the beginning of isovolumetric contraction, where the LV pressure rises rapidly while LV volume remains constant.

(Choice C) This point corresponds to aortic valve closure, where LV pressure falls below the central aortic pressure. This also marks the beginning of isovolumetric relaxation, where the LV pressure rapidly falls while LV volume remains relatively constant.

(Choice D) Left atrial pressure gradually increases from passive filling from the pulmonary veins and exceeds LV pressure at the end of isovolumetric relaxation, leading to the opening of the mitral valves.

(Choice E) This point corresponds to passive LV filling with blood flow from the left atrium, which results in a gradual rise in LV volume and pressure.

Educational objective:
Ventricular pressure and volume curves allow one to identify the phases of the cardiac cycle and to determine the exact time of opening and closure of the cardiac valves. The aortic valve opens when left ventricular pressure exceeds the central aortic pressure at the end of isovolumetric contraction.

References

- The cardiac cycle and the physiological basis of left ventricular contraction, ejection, relaxation, and filling.

A 38-year-old woman is being evaluated for shortness of breath. The patient has had poor exercise tolerance for the last several months that she initially attributed to deconditioning. Over the last several weeks, her symptoms have gotten progressively worse and she currently feels short of breath even during mild exertion. The patient has no family history of heart disease. As part of her evaluation, she undergoes right and left heart catheterization. The following data are obtained:

Left ventricular end-diastolic pressure	10 mm Hg (normal: 3-12 mm Hg)
Left ventricular peak systolic pressure	110 mm Hg (normal: 100-140 mm Hg)
Pulmonary capillary wedge pressure	36 mm Hg (normal: <12 mm Hg)

Which of the following is the most likely cause of this patient's symptoms?

A. Aortic stenosis
B. Cardiac tamponade
C. Dilated cardiomyopathy
D. Mitral stenosis
E. Restrictive cardiomyopathy

Submit

A 38-year-old woman is being evaluated for shortness of breath. The patient has had poor exercise tolerance for the last several months that she initially attributed to deconditioning. Over the last several weeks, her symptoms have gotten progressively worse and she currently feels short of breath even during mild exertion. The patient has no family history of heart disease. As part of her evaluation, she undergoes right and left heart catheterization. The following data are obtained:

Left ventricular end-diastolic pressure	10 mm Hg (normal: 3-12 mm Hg)
Left ventricular peak systolic pressure	110 mm Hg (normal: 100-140 mm Hg)
Pulmonary capillary wedge pressure	36 mm Hg (normal: <12 mm Hg)

Which of the following is the most likely cause of this patient's symptoms?

A. Aortic stenosis (2%)
B. Cardiac tamponade (2%)
C. Dilated cardiomyopathy (4%)
✓ D. Mitral stenosis (83%)
E. Restrictive cardiomyopathy (6%)

Omitted
Correct answer
D

83%
Answered correctly

02 secs
Time Spent

03/30/2020
Last Updated

Explanation

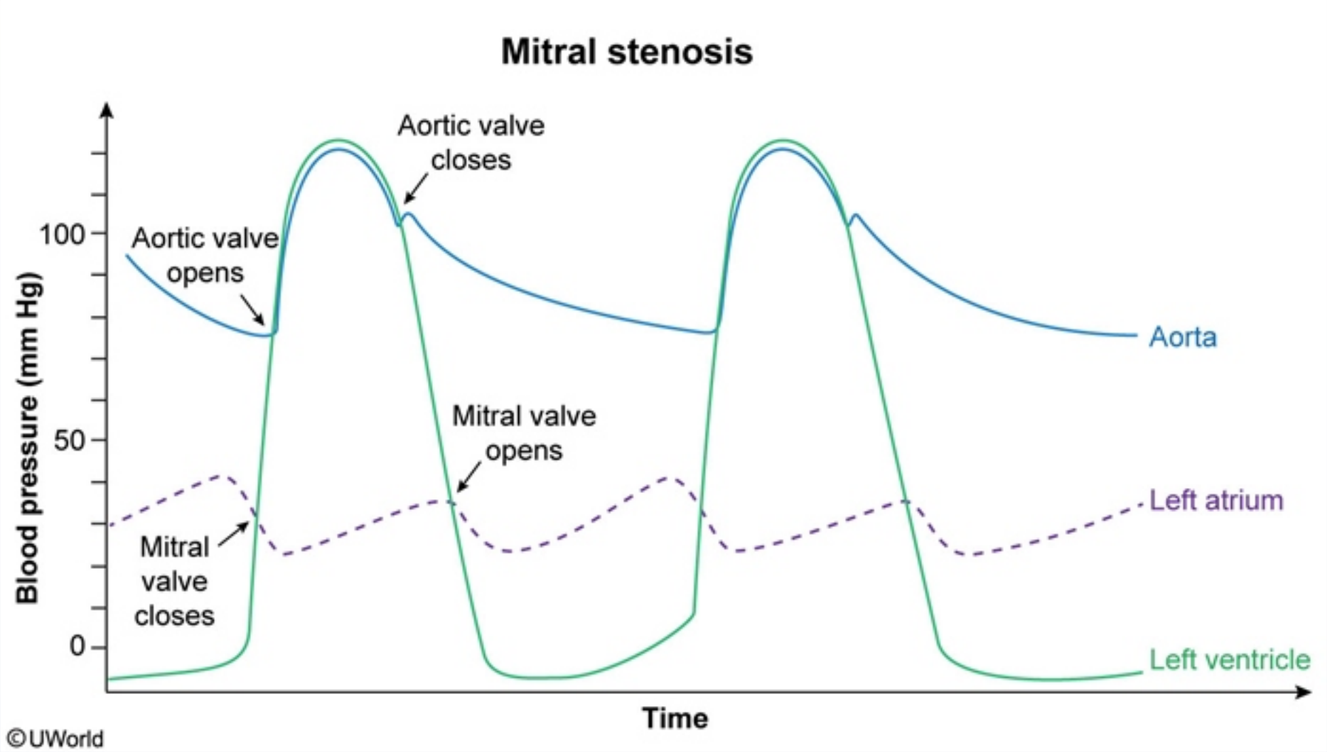

A balloon-tipped pulmonary artery (Swan-Ganz) catheter is often used to obtain hemodynamic measurements in patients with shock and certain cardiopulmonary conditions. During pulmonary artery (right heart) catheterization, the catheter is advanced to a small branch of the pulmonary artery and the balloon is inflated to obstruct blood flow in that vessel and its distal branches (which eventually form the pulmonary veins). Because blood flow toward the left atrium (LA) is obstructed beyond this point of occlusion, the pressure at the tip of the "wedged" catheter becomes nearly equal to the LA pressure and left ventricular end-diastolic pressure (LVEDP). This is referred to as the pulmonary capillary wedge pressure (PCWP).

During normal diastole, the LA pressure is nearly equal to the LVEDP as the open mitral valve offers minimal resistance to flow between the 2 chambers. In patients with **mitral stenosis**, there is resistance to blood flow from the LA to LV that leads to an **increase** in the **LA pressure**. This increase in LA pressure is transmitted back to the pulmonary veins and is recorded as **elevated PCWP** during pulmonary artery catheterization. If



A balloon-tipped pulmonary artery (Swan-Ganz) catheter is often used to obtain hemodynamic measurements in patients with shock and certain cardiopulmonary conditions. During pulmonary artery (right heart) catheterization, the catheter is advanced to a small branch of the pulmonary artery and the balloon is inflated to obstruct blood flow in that vessel and its distal branches (which eventually form the pulmonary veins). Because blood flow toward the left atrium (LA) is obstructed beyond this point of occlusion, the pressure at the tip of the "wedged" catheter becomes nearly equal to the LA pressure and left ventricular end-diastolic pressure (LVEDP). This is referred to as the pulmonary capillary wedge pressure (PCWP).

During normal diastole, the LA pressure is nearly equal to the LVEDP as the open mitral valve offers minimal resistance to flow between the 2 chambers. In patients with **mitral stenosis**, there is resistance to blood flow from the LA to LV that leads to an **increase** in the **LA pressure**. This increase in LA pressure is transmitted back to the pulmonary veins and is recorded as **elevated PCWP** during pulmonary artery catheterization. If the LA pressure is sufficiently high to overcome the resistance between the LA and LV, LV filling may not be significantly affected, resulting in **normal LVEDP**.

(Choice A) Aortic stenosis causes a pressure gradient between LV and aortic peak systolic pressures. LVEDP and PCWP can be elevated in patients with aortic stenosis; however, both these values would remain in approximately the same range.

(Choice B) Cardiac tamponade leads to equalization of average intracardiac diastolic pressures (left ventricular, right ventricular, and pulmonary artery diastolic pressures). LVEDP and PCWP are both elevated to a similar degree.

(Choices C and E) Both dilated and restrictive cardiomyopathy are associated with pulmonary and systemic venous congestion, resulting in a similar increase in both LVEDP and PCWP. In dilated cardiomyopathy, this occurs due to systolic dysfunction (impaired ventricular contractility), whereas in restrictive cardiomyopathy this occurs due to diastolic dysfunction (impaired ventricular relaxation/filling).

Educational objective:
Under normal circumstances, pulmonary capillary wedge pressure (PCWP) closely reflects left atrial (LA) and left ventricular end-diastolic pressure (LVEDP). Mitral stenosis leads to an increase in the LA pressure that is reflected as elevated PCWP during pulmonary artery catheterization. Left ventricular filling may be normal, resulting in an increased pressure gradient between the LA and LV during diastole.

References

1
2
3
4
5
6
7
8
9
10
11
12
13
14
15
16
17
18
19
20
21
22
23

Exhibit Display

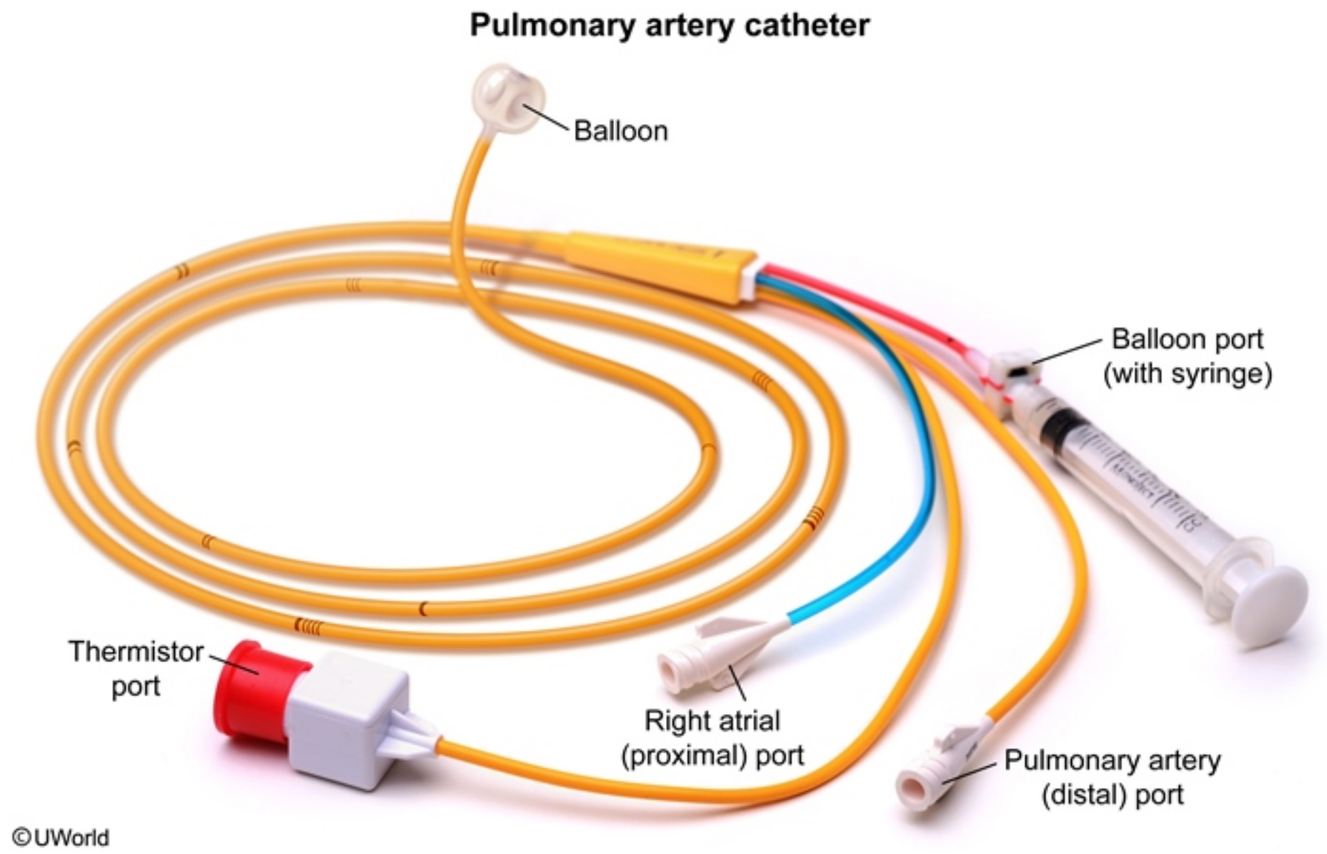

Zoom In | Zoom Out | Reset | Add To New Card | Existing Card

References

1
2
3
4
5
6
7
8
9
10
11
12
13
14
15
16
17
18
19
20
21
22
23

Exhibit Display

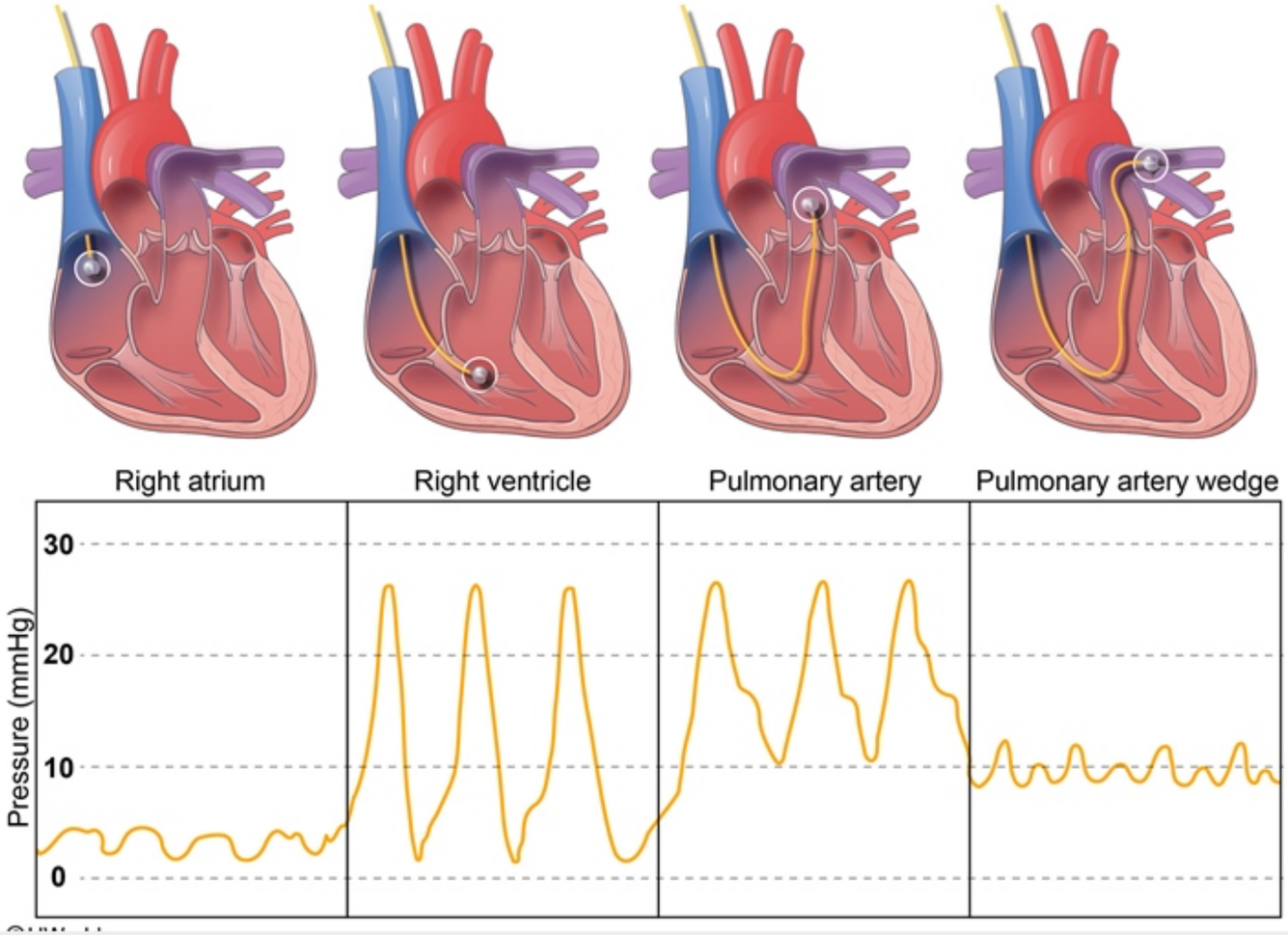

Zoom In | Zoom Out | Reset | Add To New Card | Existing Card

References

1
2
3
4
5
6
7
8
9
10
11
12
13
14
15
16
17
18
19
20
21
22
23

Exhibit Display

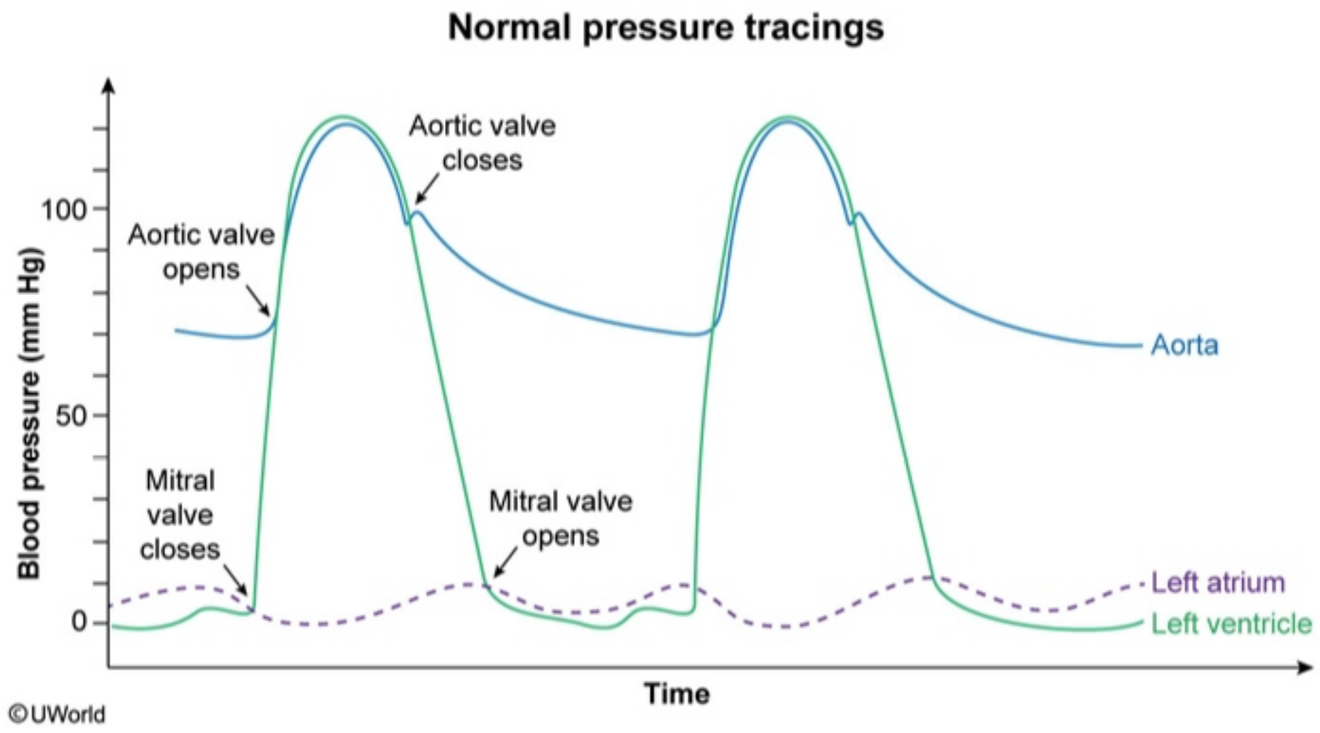

Zoom In | Zoom Out | Reset | Add To New Card | Existing Card

References

equal to the LA pressure and left ventricular end-diastolic pressure (LVEDP). This is referred to as the pulmonary capillary wedge pressure (PCWP).

During normal diastole, the LA pressure is nearly equal to the LVEDP as the open mitral valve offers minimal resistance to flow between the 2 chambers. In patients with **mitral stenosis**, there is resistance to blood flow from the LA to LV that leads to an **increase** in the **LA pressure**. This increase in LA pressure is transmitted back to the pulmonary veins and is recorded as **elevated PCWP** during pulmonary artery catheterization. If the LA pressure is sufficiently high to overcome the resistance between the LA and LV, LV filling may not be significantly affected, resulting in **normal LVEDP**.

(Choice A) Aortic stenosis causes a pressure gradient between LV and aortic peak systolic pressures. LVEDP and PCWP can be elevated in patients with aortic stenosis; however, both these values would remain in approximately the same range.

(Choice B) Cardiac tamponade leads to equalization of average intracardiac diastolic pressures (left ventricular, right ventricular, and pulmonary artery diastolic pressures). LVEDP and PCWP are both elevated to a similar degree.

(Choices C and E) Both dilated and restrictive cardiomyopathy are associated with pulmonary and systemic venous congestion, resulting in a similar increase in both LVEDP and PCWP. In dilated cardiomyopathy, this occurs due to systolic dysfunction (impaired ventricular contractility), whereas in restrictive cardiomyopathy this occurs due to diastolic dysfunction (impaired ventricular relaxation/filling).

Educational objective:
Under normal circumstances, pulmonary capillary wedge pressure (PCWP) closely reflects left atrial (LA) and left ventricular end-diastolic pressure (LVEDP). Mitral stenosis leads to an increase in the LA pressure that is reflected as elevated PCWP during pulmonary artery catheterization. Left ventricular filling may be normal, resulting in an increased pressure gradient between the LA and LV during diastole.

References

- Hemodynamics in the cardiac catheterization laboratory of the 21st century.

Physiology	Cardiovascular System	Mitral stenosis
Subject	System	Topic

Copyright © UWorld. All rights reserved.

A 63-year-old man comes to the emergency department due to dyspnea. Over the past several days, the patient has experienced progressively worsening shortness of breath while walking his dog around the block. In addition, he could not breathe while lying in bed last night and fell asleep only after moving to a recliner. The patient had an acute myocardial infarction 2 years ago and has been nonadherent with his medications and follow-up appointments. Temperature is 36.7 C (98 F), blood pressure is 122/74 mm Hg, pulse is 94/min, and respirations are 22/min. Physical examination shows bibasilar lung crackles, jugular venous distension, and bilateral pitting edema in the lower extremities. Chest x-ray reveals cardiomegaly and pulmonary venous congestion. Which of the following factors is most likely contributing to this patient's symptoms?

- A. Decreased arteriolar resistance
- B. Decreased plasma renin activity
- C. Decreased ventricular end-diastolic pressure
- D. Increased plasma brain natriuretic peptide concentration
- E. Increased sympathetic nervous system activity

Submit

A 63-year-old man comes to the emergency department due to dyspnea. Over the past several days, the patient has experienced progressively worsening shortness of breath while walking his dog around the block. In addition, he could not breathe while lying in bed last night and fell asleep only after moving to a recliner. The patient had an acute myocardial infarction 2 years ago and has been nonadherent with his medications and follow-up appointments. Temperature is 36.7 C (98 F), blood pressure is 122/74 mm Hg, pulse is 94/min, and respirations are 22/min. Physical examination shows bibasilar lung crackles, jugular venous distension, and bilateral pitting edema in the lower extremities. Chest x-ray reveals cardiomegaly and pulmonary venous congestion. Which of the following factors is most likely contributing to this patient's symptoms?

A. Decreased arteriolar resistance (5%)

B. Decreased plasma renin activity (2%)

C. Decreased ventricular end-diastolic pressure (21%)

D. Increased plasma brain natriuretic peptide concentration (17%)

✓ E. Increased sympathetic nervous system activity (52%)

Omitted
Correct answer
E

52%
Answered correctly

02 secs
Time Spent

03/16/2020
Last Updated

Explanation

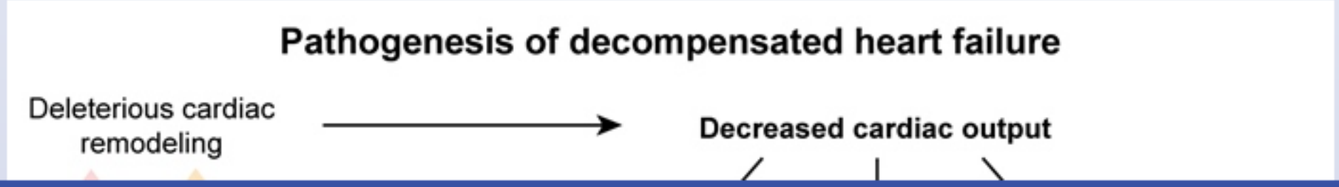

Explanation

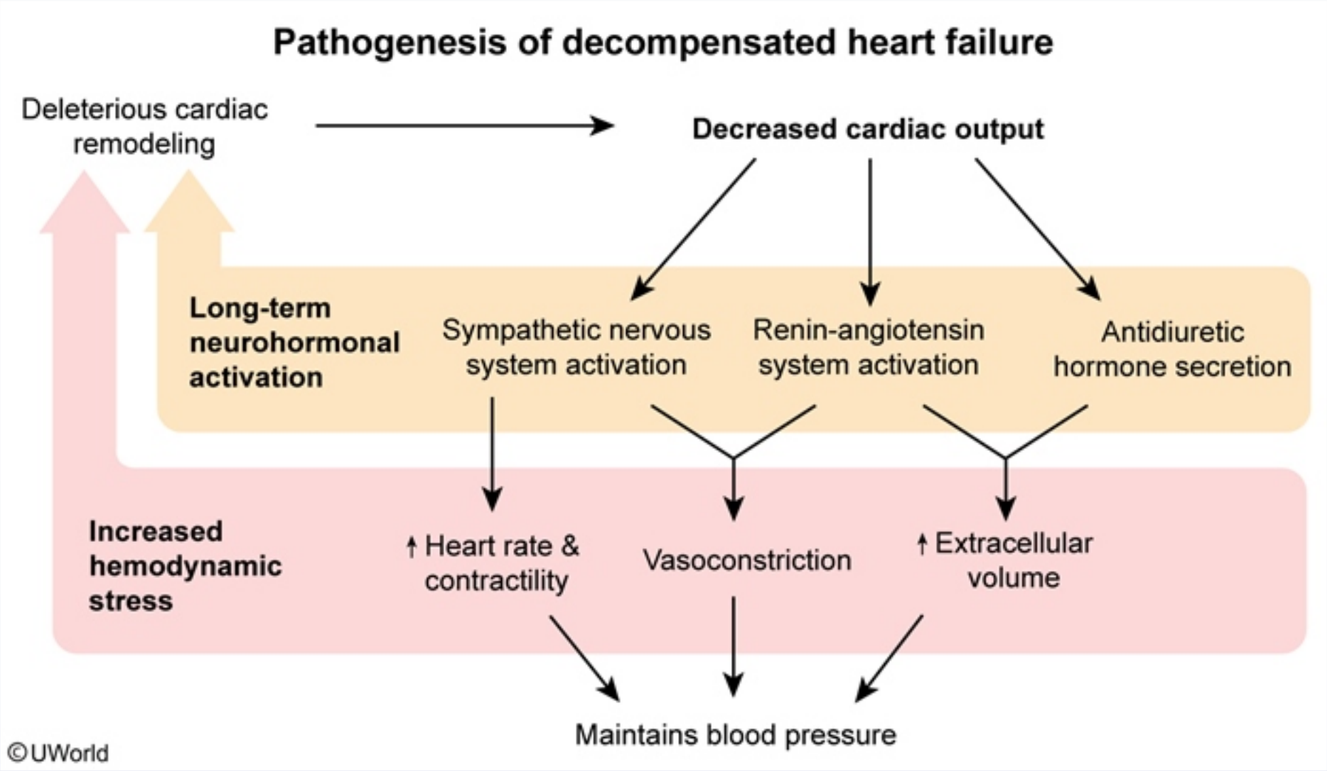

This patient's progressive dyspnea, orthopnea, and lower extremity swelling are consistent with acute decompensated **heart failure**. Heart failure occurs when a structural or functional cardiac disorder impairs ventricular filling or ejection of blood, causing **reduced cardiac output** and elevated filling pressure. The reduced cardiac output causes an initial drop in blood pressure, which triggers compensatory neurohormonal activity mainly via **stimulation** of the **sympathetic nervous system** and **renin-angiotensin-aldosterone system** (RAAS).

These **adaptations** function together in an effort to **improve organ perfusion** by increasing cardiac chronotropy and inotropy (improves cardiac output), promoting arterial and venous vasoconstriction (maintains perfusion pressure), and expanding the extracellular fluid compartment (improves circulating blood volume). However, **over time**, these responses lead to adverse consequences that perpetuate a downward spiral of

This patient's progressive dyspnea, orthopnea, and lower extremity swelling are consistent with acute decompensated **heart failure**. Heart failure occurs when a structural or functional cardiac disorder impairs ventricular filling or ejection of blood, causing **reduced cardiac output** and elevated filling pressure. The reduced cardiac output causes an initial drop in blood pressure, which triggers compensatory neurohormonal activity mainly via **stimulation** of the **sympathetic nervous system** and **renin-angiotensin-aldosterone system** (RAAS).

These **adaptations** function together in an effort to **improve organ perfusion** by increasing cardiac chronotropy and inotropy (improves cardiac output), promoting arterial and venous vasoconstriction (maintains perfusion pressure), and expanding the extracellular fluid compartment (improves circulating blood volume). However, **over time**, these responses lead to adverse consequences that perpetuate a downward spiral of **progressive cardiac deterioration**. Chronic hemodynamic stress (eg, increased preload and afterload) and prolonged exposure to sympathetic drive (catecholamines) and RAAS stimulation (angiotensin II, aldosterone) lead to **deleterious remodeling** with worsening cardiac function and eventual symptomatic decompensation.

(Choices A and B) Decreased cardiac output in heart failure stimulates increased RAAS activity and sympathetic output, resulting in increased arteriolar resistance.

(Choice C) Ventricular end-systolic and end-diastolic pressures are increased in heart failure due to increased preload and afterload.

(Choice D) Heart failure triggers the myocardium to secrete natriuretic peptides (ie, atrial natriuretic peptide, brain natriuretic peptide) in response to myocardial stretch from volume overload. These peptides stimulate vasodilation and increase salt and water excretion to improve the symptoms of heart failure; however, these positive effects are overpowered by the negative effects of increased sympathetic drive and RAAS activation.

Educational objective:
The reduced cardiac output in heart failure triggers compensatory activation of the sympathetic nervous system and renin-angiotensin-aldosterone pathway, resulting in vasoconstriction (increased afterload), fluid retention (increased preload), and deleterious cardiac remodeling. These mechanisms perpetuate a downward spiral of cardiac deterioration, leading to symptomatic decompensated heart failure.

Physiology	Cardiovascular System	Chronic heart failure
Subject	System	Topic

Copyright © UWorld. All rights reserved.

This patient's progressive dyspnea, orthopnea, and lower extremity swelling are consistent with acute decompensated **heart failure**. Heart failure

Exhibit Display

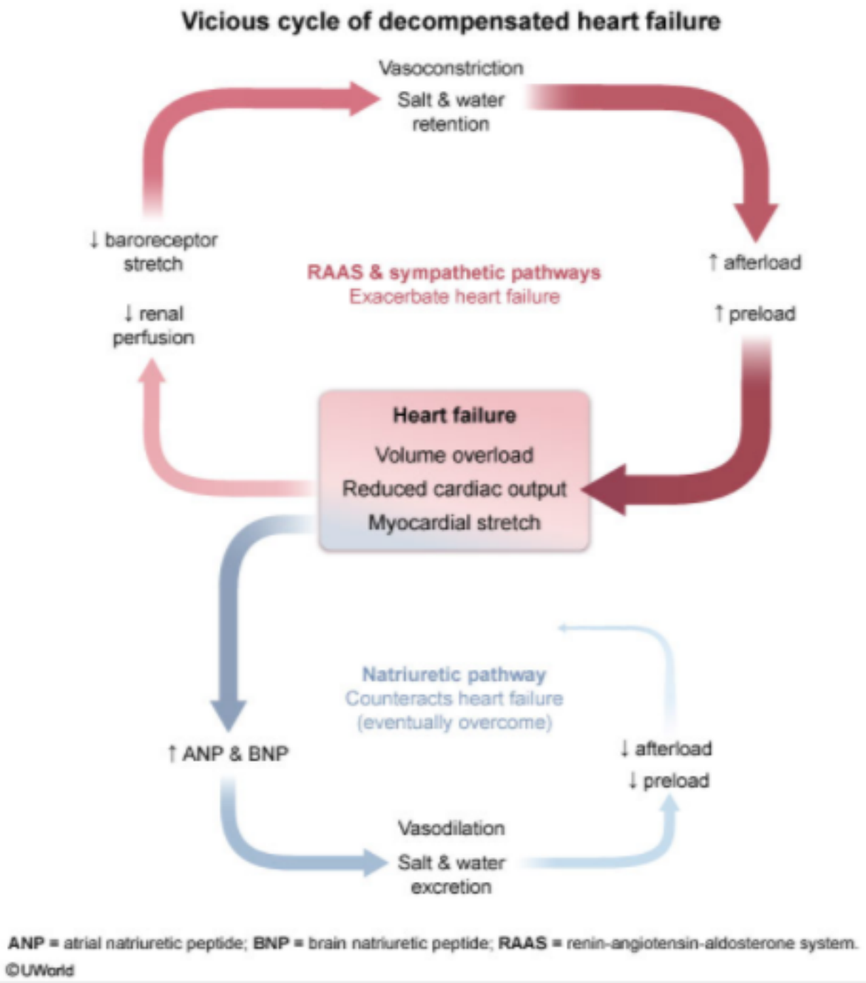

Zoom In | Zoom Out | Reset | Add To New Card | Existing Card

Copyright © UWorld. All rights reserved.

1
2
3
4
5
6
7
8
9
10
11
12
13
14
15
16
17
18
19
20
21
22
23

A 44-year-old man comes to the office due to increasing shortness of breath. While climbing the stairs to his second-floor apartment, the patient must now stop halfway to catch his breath. He has a history of nonischemic cardiomyopathy and chronic heart failure with reduced ejection fraction. After evaluation, treatment with a new medication is begun that improves his symptoms by increasing urine output and decreasing peripheral vascular resistance. The medication works by inhibiting a metalloprotease to prolong the action of endogenous polypeptides. These polypeptides are most likely secreted by which of the following cell types?

A. Adrenal zona glomerulosa cells
B. Cardiomyocytes
C. Hepatic stellate cells
D. Myocardial Purkinje fibers
E. Renal juxtaglomerular cells
F. Vascular endothelial cells

Submit

1
2
3
4
5
6
7
8
9
10
11
12
13
14
15
16
17
18
19
20
21
22
23

A 44-year-old man comes to the office due to increasing shortness of breath. While climbing the stairs to his second-floor apartment, the patient must now stop halfway to catch his breath. He has a history of nonischemic cardiomyopathy and chronic heart failure with reduced ejection fraction. After evaluation, treatment with a new medication is begun that improves his symptoms by increasing urine output and decreasing peripheral vascular resistance. The medication works by inhibiting a metalloprotease to prolong the action of endogenous polypeptides. These polypeptides are most likely secreted by which of the following cell types?

- A. Adrenal zona glomerulosa cells (5%)
- ✓ B. Cardiomyocytes (56%)
- C. Hepatic stellate cells (3%)
- D. Myocardial Purkinje fibers (1%)
- E. Renal juxtaglomerular cells (13%)
- F. Vascular endothelial cells (19%)

Omitted
Correct answer
B

56%
Answered correctly

02 secs
Time Spent

03/18/2020
Last Updated

Explanation

Effects of the natriuretic peptides

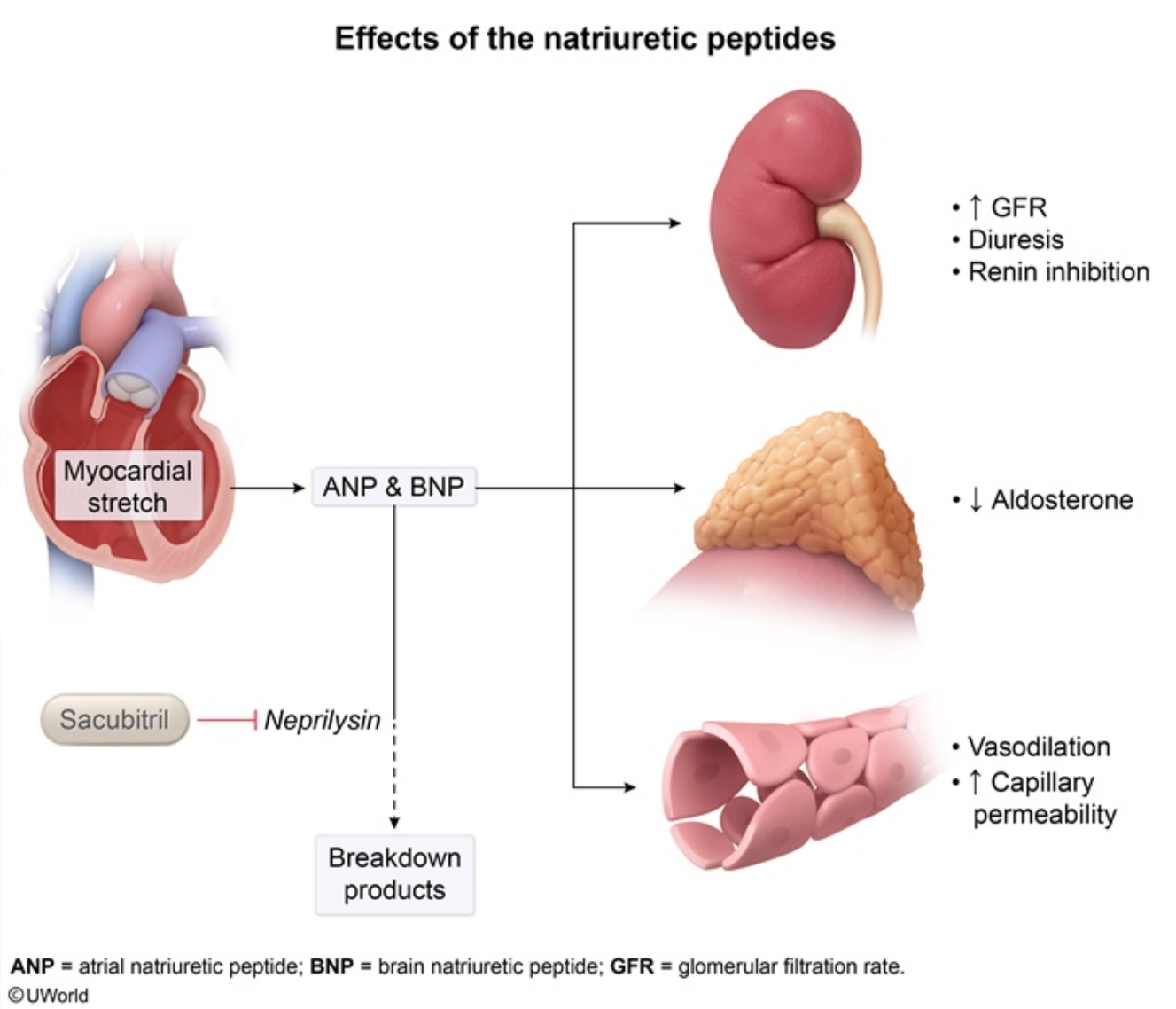

ANP = atrial natriuretic peptide; **BNP** = brain natriuretic peptide; **GFR** = glomerular filtration rate.

©UWorld

In response to myocardial stretching due to volume overload, atrial and ventricular **cardiomyocytes** secrete **atrial natriuretic peptide** (ANP) and

In response to myocardial stretching due to volume overload, atrial and ventricular **cardiomyocytes** secrete **atrial natriuretic peptide** (ANP) and **brain natriuretic peptide** (BNP). These peptides are subsequently broken down and inactivated by the metalloprotease **neprilysin**. This patient with **chronic heart failure** was most likely given a **neprilysin inhibitor** (eg, sacubitril), allowing for enhanced activity of ANP and BNP.

Once secreted, ANP and BNP bind to natriuretic peptide receptors to activate guanylate cyclase and form cyclic GMP, which stimulates **diuresis** and peripheral **vasodilation** to help alleviate volume overload. Several organs and tissues are affected as follows:

- **Kidneys**: The afferent arterioles are dilated and the efferent arterioles are constricted, raising the glomerular filtration rate and increasing urinary excretion of sodium and water. Renin secretion from the juxtaglomerular cells is inhibited **(Choice E)**, counteracting renin-angiotensin-aldosterone-system (RAAS) activity.
- **Adrenal glands**: Secretion of aldosterone from the zona glomerulosa cells is inhibited **(Choice A)**, further counteracting RAAS activity and bolstering the increase in sodium and water excretion.
- **Blood vessels**: Arteriolar and venular smooth muscle relaxes, producing vasodilation. There is also increased capillary permeability, leading to fluid extravasation into the interstitium and a decrease in circulating blood volume.

(Choice C) Hepatic stellate cells (perisinusoidal cells of Ito) may help regulate hepatic blood flow via release of local mediators; however, these cells do not play a significant role in heart failure.

(Choice D) Myocardial Purkinje fibers facilitate the organized transport of electrical impulses from the sinoatrial node through the atria, atrioventricular node, and ventricles; however, these fibers are not known to have endocrine function.

(Choice F) Vascular endothelial cells regulate systemic blood flow via release of vasodilators, such as nitric oxide and prostacyclin, and vasoconstrictors, such as endothelin and thromboxane A2. However, these local mediators are not a significant target of therapy for chronic heart failure.

Educational objective:
Atrial natriuretic peptide (ANP) and brain natriuretic peptide (BNP) are secreted by atrial and ventricular cardiomyocytes in response to myocardial stretching induced by hypervolemia. These natriuretic peptides inhibit the renin-angiotensin-aldosterone system and stimulate peripheral vasodilation and increased urinary excretion of sodium and water. Neprilysin inhibitors (eg, sacubitril) prevent the degradation of ANP and BNP, enhancing their beneficial effects in heart failure.

urinary excretion of sodium and water. Renin secretion from the juxtaglomerular cells is inhibited **(Choice E)**, counteracting renin-angiotensin-aldosterone-system (RAAS) activity.

- **Adrenal glands**: Secretion of aldosterone from the zona glomerulosa cells is inhibited **(Choice A)**, further counteracting RAAS activity and bolstering the increase in sodium and water excretion.
- **Blood vessels**: Arteriolar and venular smooth muscle relaxes, producing vasodilation. There is also increased capillary permeability, leading to fluid extravasation into the interstitium and a decrease in circulating blood volume.

(Choice C) Hepatic stellate cells (perisinusoidal cells of Ito) may help regulate hepatic blood flow via release of local mediators; however, these cells do not play a significant role in heart failure.

(Choice D) Myocardial Purkinje fibers facilitate the organized transport of electrical impulses from the sinoatrial node through the atria, atrioventricular node, and ventricles; however, these fibers are not known to have endocrine function.

(Choice F) Vascular endothelial cells regulate systemic blood flow via release of vasodilators, such as nitric oxide and prostacyclin, and vasoconstrictors, such as endothelin and thromboxane A2. However, these local mediators are not a significant target of therapy for chronic heart failure.

Educational objective:
Atrial natriuretic peptide (ANP) and brain natriuretic peptide (BNP) are secreted by atrial and ventricular cardiomyocytes in response to myocardial stretching induced by hypervolemia. These natriuretic peptides inhibit the renin-angiotensin-aldosterone system and stimulate peripheral vasodilation and increased urinary excretion of sodium and water. Neprilysin inhibitors (eg, sacubitril) prevent the degradation of ANP and BNP, enhancing their beneficial effects in heart failure.

References

- The natriuretic peptide system in the pathophysiology of heart failure: from molecular basis to treatment.

Physiology	Cardiovascular System	Chronic heart failure
Subject	System	Topic

Copyright © UWorld. All rights reserved.

A 20-year-old, previously healthy woman is brought to the emergency department after a motor vehicle collision. The patient was a restrained, rear-seat passenger when another car struck the side door. There was extensive damage to the vehicle, resulting in a prolonged extrication time. On arrival at the emergency department, blood pressure is 90/60 mm Hg and pulse is 120/min. On physical examination, the patient is alert but appears anxious, pale, and diaphoretic. There is no obvious head or neck injury. The lungs are clear bilaterally and cardiac auscultation reveals tachycardia. The abdomen is soft. Several actively bleeding lacerations are present on the lower extremities. X-rays show pelvic and left femoral shaft fractures. Which of the following findings are most likely present in this patient?

	Cardiac contractility	Baroreceptor firing	Atrial natriuretic peptide release
A.	↑	↑	↑
B.	↓	↑	↑
C.	↑	↓	↑
D.	↓	↑	↓
E.	↑	↓	↓
F.	↓	↓	↓
G.	↓	↓	↑
H.	↑	↑	↓

Submit

A 20-year-old, previously healthy woman is brought to the emergency department after a motor vehicle collision. The patient was a restrained, rear-seat passenger when another car struck the side door. There was extensive damage to the vehicle, resulting in a prolonged extrication time. On arrival at the emergency department, blood pressure is 90/60 mm Hg and pulse is 120/min. On physical examination, the patient is alert but appears anxious, pale, and diaphoretic. There is no obvious head or neck injury. The lungs are clear bilaterally and cardiac auscultation reveals tachycardia. The abdomen is soft. Several actively bleeding lacerations are present on the lower extremities. X-rays show pelvic and left femoral shaft fractures. Which of the following findings are most likely present in this patient?

	Cardiac contractility	Baroreceptor firing	Atrial natriuretic peptide release
A. (5%)	↑	↑	↑
B. (1%)	↓	↑	↑
C. (4%)	↑	↓	↑
D. (3%)	↓	↑	↓
✓ E. (52%)	↑	↓	↓
F. (5%)	↓	↓	↓
G. (0%)	↓	↓	↑
H.	↑	↑	↓

1
2
3
4
5
6
7
8
9
10
11
12
13
14
15
16
17
18
19
20
21
22
23

tachycardia. The abdomen is soft. Several actively bleeding lacerations are present on the lower extremities. X-rays show pelvic and left femoral shaft fractures. Which of the following findings are most likely present in this patient?

	Cardiac contractility	Baroreceptor firing	Atrial natriuretic peptide release
A. (5%)	↑	↑	↑
B. (1%)	↓	↑	↑
C. (4%)	↑	↓	↑
D. (3%)	↓	↑	↓
✓ E. (52%)	↑	↓	↓
F. (5%)	↓	↓	↓
G. (0%)	↓	↓	↑
H. (24%)	↑	↑	↓

Omitted
Correct answer
E

52%
Answered correctly

01 sec
Time Spent

05/06/2020
Last Updated

1
2
3
4
5
6
7
8
9
10
11
12
13
14
15
16
17
18
19
20
21
22
23

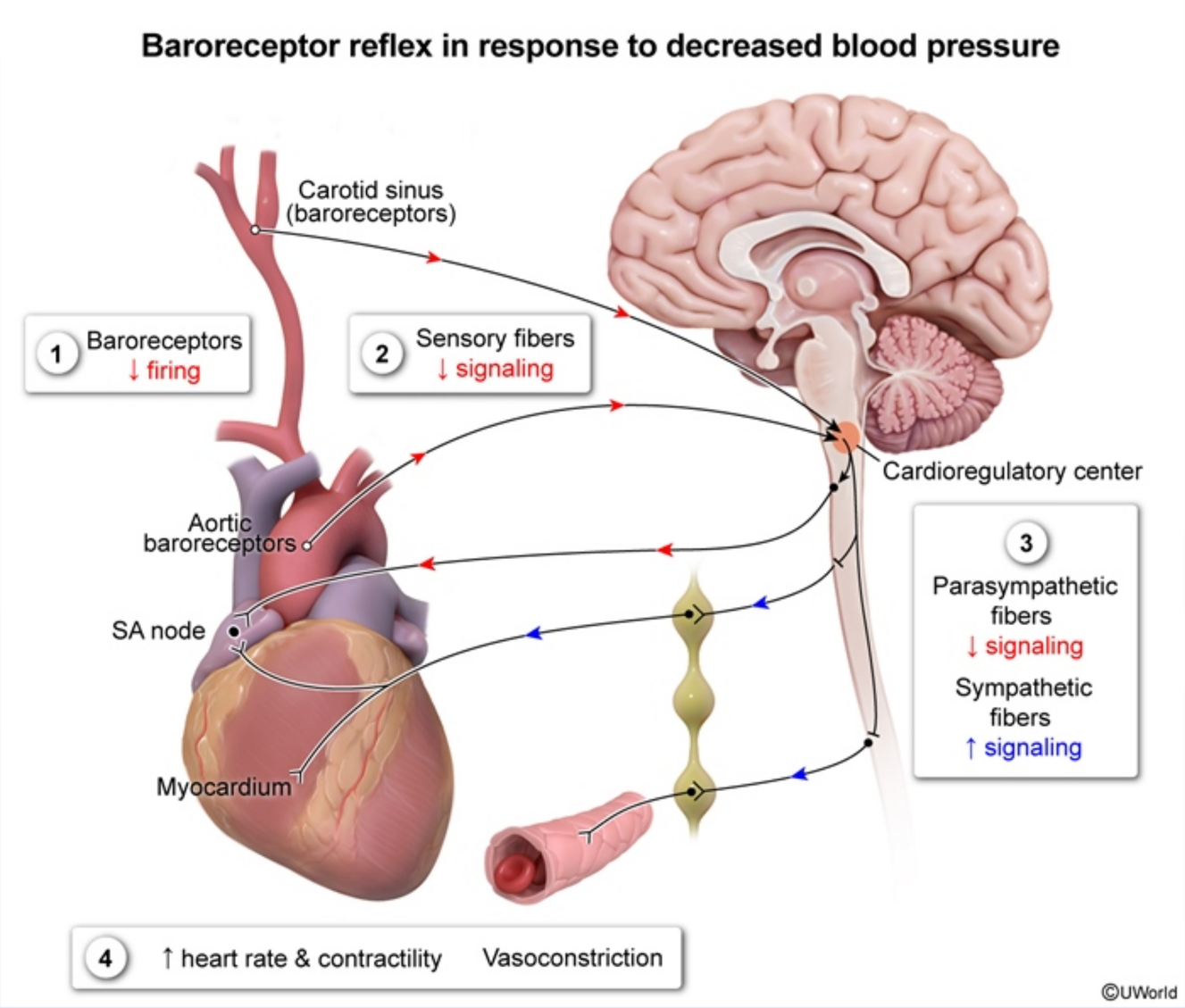

This patient's **hypotension** and tachycardia in the setting of multiple lacerations and pelvic fracture (a common cause of severe internal bleeding)

©UWorld

This patient's **hypotension** and tachycardia in the setting of multiple lacerations and pelvic fracture (a common cause of severe internal bleeding) are consistent with hypovolemic shock due to **massive hemorrhage**. Following significant intravascular volume depletion, baroreceptors in the aorta and carotid arteries rapidly adjust autonomic output to help maintain blood pressure.

Baroreceptors are stretch-sensitive mechanoreceptors that increase their firing rate in response to arterial distension. These impulses are transmitted to the solitary nucleus, which then modulates sympathetic and parasympathetic output in response to the firing rate.

With a rapid **decrease in blood pressure** (eg, acute blood loss, standing from a seated position), reduced stretch of the arterial walls leads to **reduced baroreceptor firing** and decreased activation of the solitary nucleus. This causes an increase in sympathetic outflow with a corresponding reduction in parasympathetic tone, leading to **vasoconstriction** (increases peripheral resistance) and **increased heart rate and contractility** (increases cardiac output), minimizing the drop in blood pressure.

Via a similar mechanism, stretch receptors in the atrial walls of the heart control secretion of atrial natriuretic peptide (ANP). With hypovolemia there is **reduced atrial stretch** that leads to **decreased ANP secretion**.

(Choices A, F, G, and H) Because baroreceptor firing reduces sympathetic output, the degree of baroreceptor firing is usually inversely related to cardiac contractility.

(Choice B) In hypervolemic states, blood pressure is increased, leading to increased baroreceptor firing with a decrease in sympathetic outflow and corresponding increase in parasympathetic outflow. A resulting decrease in vascular tone, heart rate, and cardiac contractility reduces blood pressure. Increased stretching of the atrial walls leads to increased ANP release, which promotes vasodilation and diuresis.

(Choices C and D) Because conditions that increase (eg, hypervolemia) or decrease (eg, hypovolemia) baroreceptor stretch typically have the same effect on atrial stretch, the degree of baroreceptor firing is usually directly related to the level of ANP release.

Educational objective:
Low blood pressure results in decreased arterial distension and reduced firing of aortic and carotid baroreceptors. This leads to an increase in sympathetic outflow and decrease in parasympathetic outflow, stimulating vasoconstriction and increased heart rate and contractility in order to help maintain blood pressure. Hypovolemia reduces atrial stretch, causing decreased atrial natriuretic peptide secretion.

References

1
2
3
4
5
6
7
8
9
10
11
12
13
14
15
16
17
18
19
20
21
22
23

are consistent with hypovolemic shock due to **massive hemorrhage**. Following significant intravascular volume depletion, baroreceptors in the

Exhibit Display

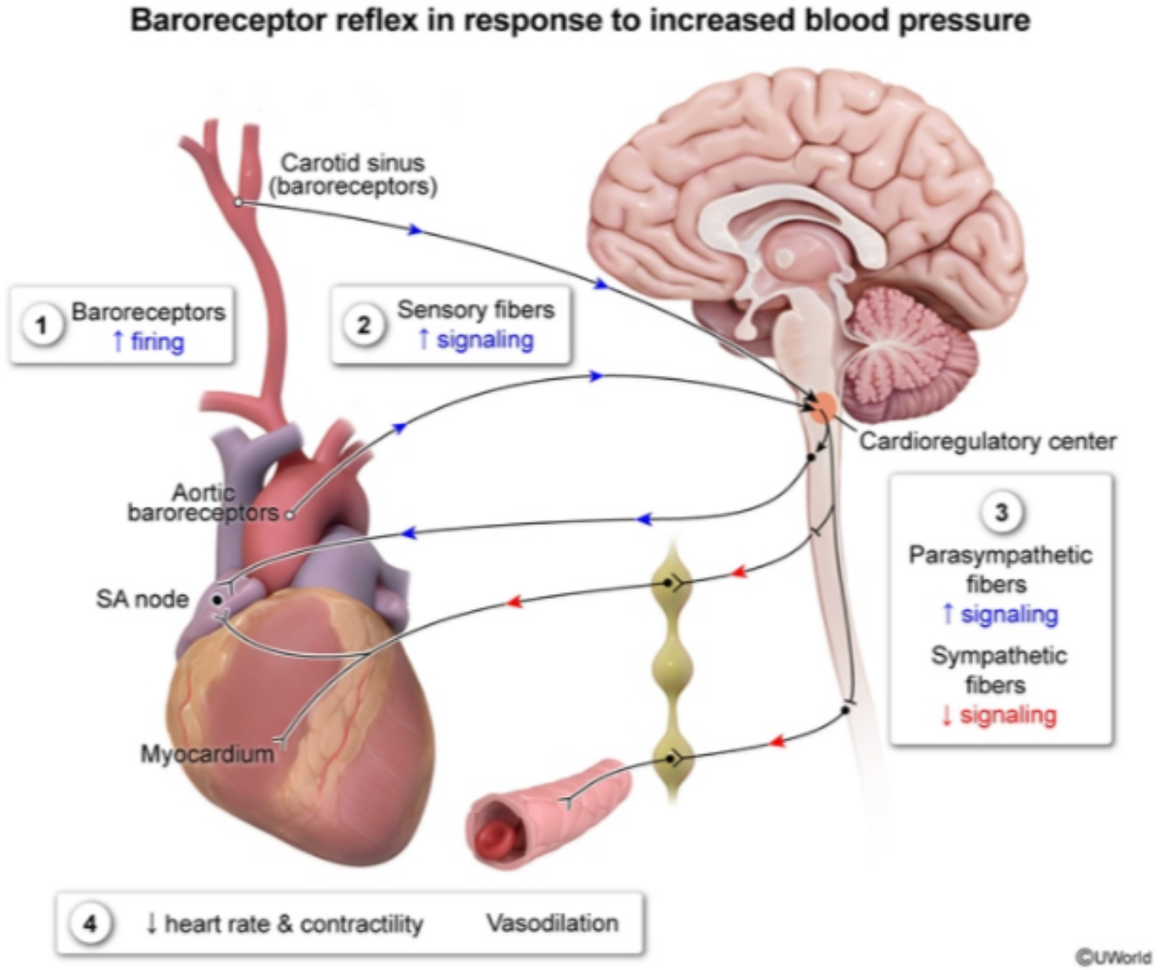

Zoom In Zoom Out Reset Add To Flash Card

A 55-year-old man is immediately brought to the hospital after experiencing a sudden collapse at home 20 minutes ago. The patient reported chest pain and then collapsed to the floor while trying to sit down. Medical history is significant for type 2 diabetes mellitus and hypertension. Temperature is 36.7 C (98.1 F), blood pressure is 80/50 mm Hg, pulse is 120/min, and respirations are 22/min. On examination, the patient is in marked respiratory distress. Bilateral crackles are present. An S3 is audible. ECG reveals ST-segment elevation in leads V2 through V6. Which of the following hemodynamic changes are most likely present in this patient?

	Pulmonary capillary wedge pressure	Central venous pressure	Coronary perfusion pressure
A.	Decreased	Decreased	Decreased
B.	Decreased	Increased	Decreased
C.	Increased	Decreased	Increased
D.	Increased	Increased	Decreased
E.	Increased	Increased	Increased

Submit

A 55-year-old man is immediately brought to the hospital after experiencing a sudden collapse at home 20 minutes ago. The patient reported chest pain and then collapsed to the floor while trying to sit down. Medical history is significant for type 2 diabetes mellitus and hypertension. Temperature is 36.7 C (98.1 F), blood pressure is 80/50 mm Hg, pulse is 120/min, and respirations are 22/min. On examination, the patient is in marked respiratory distress. Bilateral crackles are present. An S3 is audible. ECG reveals ST-segment elevation in leads V2 through V6. Which of the following hemodynamic changes are most likely present in this patient?

	Pulmonary capillary wedge pressure	Central venous pressure	Coronary perfusion pressure
A. (6%)	Decreased	Decreased	Decreased
B. (7%)	Decreased	Increased	Decreased
C. (6%)	Increased	Decreased	Increased
✓ D. (69%)	Increased	Increased	Decreased
E. (9%)	Increased	Increased	Increased

Omitted
Correct answer
D

69%
Answered correctly

02 secs
Time Spent

05/12/2020
Last Updated

1
2
3
4
5
6
7
8
9
10
11
12
13
14
15
16
17
18
19
20
21
22
23

Hemodynamic measurements in shock				
Parameter	**Hypovolemic shock**	**Cardiogenic shock**	**Obstructive shock**	**Distributive shock**
CVP (right-sided preload)	↓	↑	↑	↓
PCWP (left-sided preload)	↓	↑	↓*	↓
Cardiac index (LV output)	↓	↓	↓	↑**
SVR (afterload)	↑	↑	↑	↓
SvO_2	↓	↓	↓	↑**

*In tamponade, left-sided preload is decreased, but measured PCWP is paradoxically increased due to external compression by pericardial fluid.
**Cardiac index and SvO_2 are usually decreased in neurogenic shock due to impaired sympathetic reflexes.
CVP = central venous pressure; **LV** = left ventricular; **PCWP** = pulmonary capillary wedge pressure; **SvO_2** = mixed venous oxygen saturation; **SVR** = systemic vascular resistance.

This patient with sudden-onset chest pain and ST-segment elevation in contiguous ECG leads has an ST-elevation **myocardial infarction** (MI).

CVP = central venous pressure; **LV** = left ventricular; **PCWP** = pulmonary capillary wedge pressure; **SvO_2** = mixed venous oxygen saturation; **SVR** = systemic vascular resistance.

This patient with sudden-onset chest pain and ST-segment elevation in contiguous ECG leads has an ST-elevation **myocardial infarction** (MI). Hypotension, pulmonary crackles, and an audible S3 suggest MI-induced acute left ventricular (LV) failure and **cardiogenic shock**.

In cardiogenic shock, LV systolic failure causes increased LV end-diastolic pressure, which is transmitted backward to cause **increased pulmonary capillary wedge pressure** (PCWP) (an estimate of left atrial pressure) and pulmonary edema. The increased pressure also impairs right ventricular function, resulting in **increased central venous pressure** (CVP). Markedly decreased cardiac output leads to hypotension with **decreased coronary perfusion pressure** (as coronary perfusion pressure is driven by aortic diastolic pressure) **(Choices C and E)**. In response to the reduced cardiac output, compensatory peripheral vasoconstriction occurs to increase systemic vascular resistance in an effort to maintain organ and tissue perfusion.

(Choice A) Decreased CVP, PCWP, and coronary perfusion pressure are expected with hypovolemic and septic shock.

(Choice B) Increased CVP with decreased PCWP and coronary perfusion pressure are expected with obstructive shock due to pulmonary embolism (ie, blood flow blocked at the pulmonary arteries) or tension pneumothorax (ie, blood flow blocked at the right atrium due to thoracic pressure–induced vena cava collapse).

Educational objective:
Myocardial infarction may be complicated by acute left ventricular failure (LV) and cardiogenic shock. In cardiogenic shock, increased LV end-diastolic pressure is transmitted backward to cause increased pulmonary capillary wedge pressure (evidenced by pulmonary edema) and increased central venous pressure. There is markedly decreased cardiac output, which causes hypotension and decreased coronary perfusion pressure.

Physiology	Cardiovascular System	Cardiogenic shock
Subject	System	Topic

Copyright © UWorld. All rights reserved.

1
2
3
4
5
6
7
8
9
10
11
12
13
14
15
16
17
18
19
20
21
22
23

CVP = central venous pressure; **LV** = left ventricular; **PCWP** = pulmonary capillary

Exhibit Display

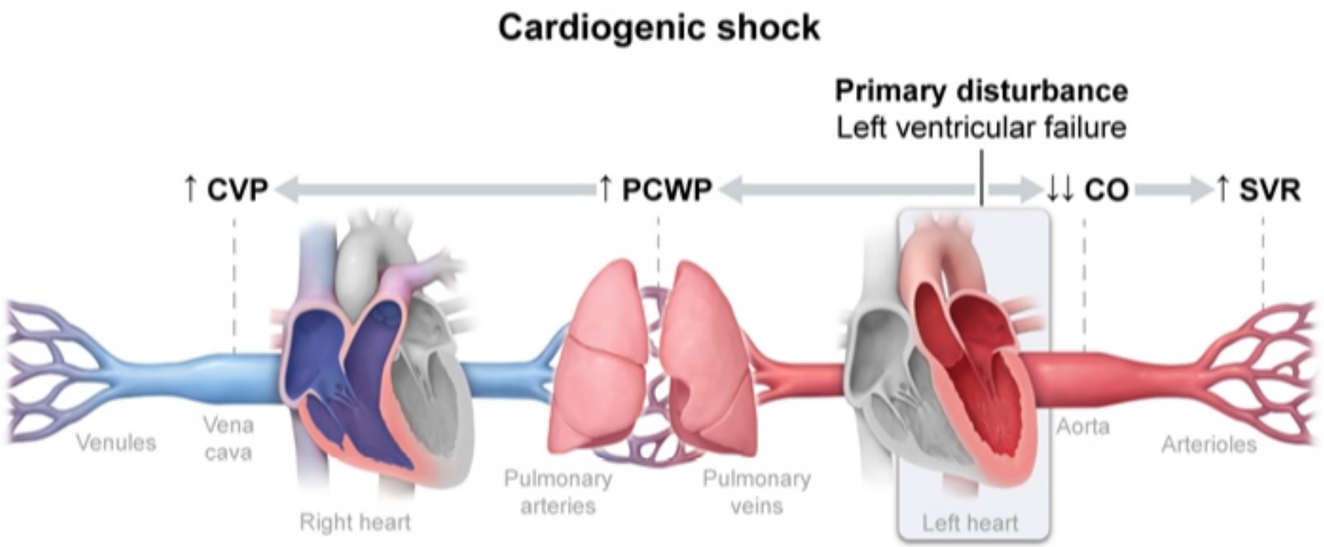

CO = cardiac output; **CVP** = central venous pressure;
PCWP = pulmonary capillary wedge pressure; **SVR** = systemic vascular resistance.

©UWorld

Zoom In Zoom Out Reset Add To Flash Card

1
2
3
4
5
6
7
8
9
10
11
12
13
14
15
16
17
18
19
20
21
22
23

CVP = central venous pressure; LV = left ventricular; PCWP = pulmonary capillary

Exhibit Display

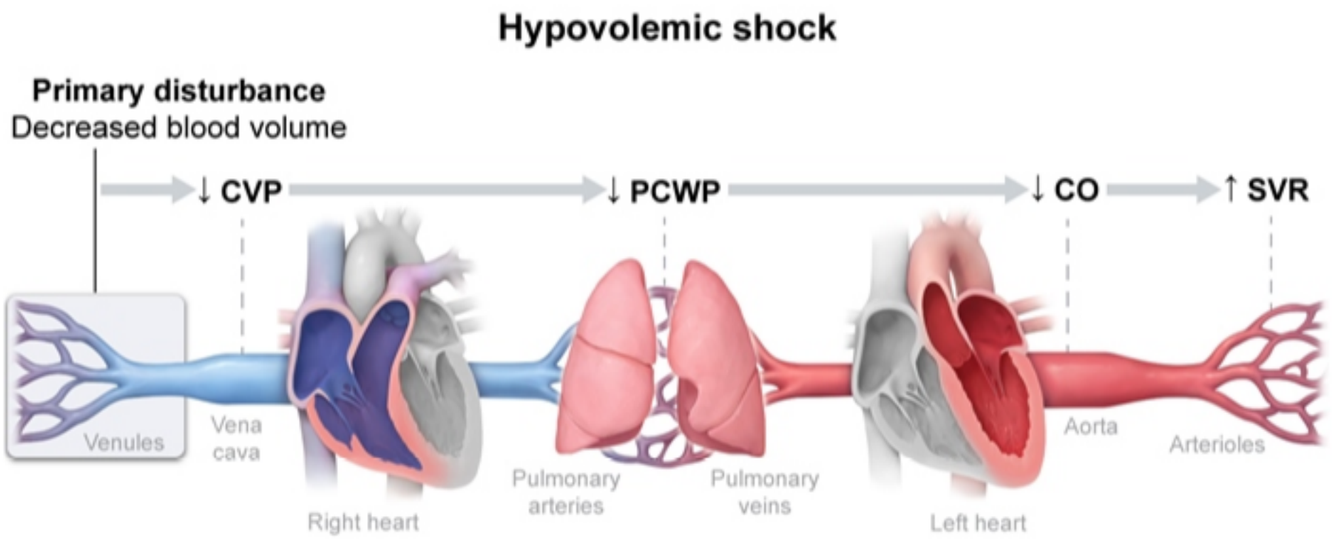

CO = cardiac output; CVP = central venous pressure;
PCWP = pulmonary capillary wedge pressure; SVR = systemic vascular resistance.

©UWorld

Zoom In Zoom Out Reset Add To Flash Card

CVP = central venous pressure; **LV** = left ventricular; **PCWP** = pulmonary capillary

Exhibit Display

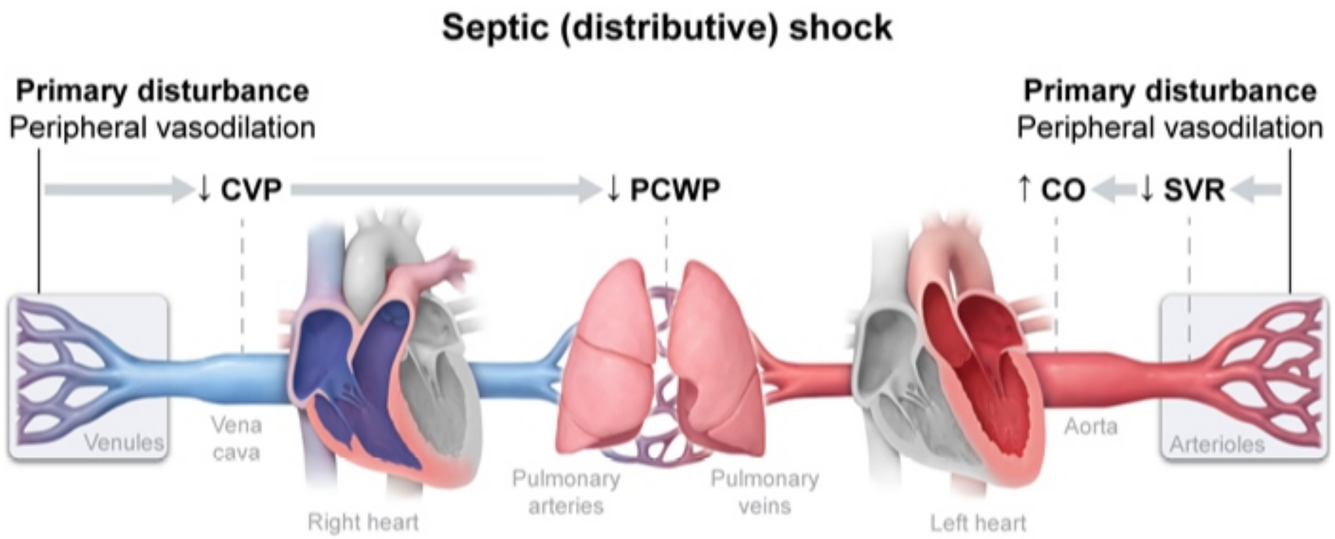

CO = cardiac output; **CVP** = central venous pressure;
PCWP = pulmonary capillary wedge pressure; **SVR** = systemic vascular resistance.

©UWorld

Zoom In Zoom Out Reset Add To Flash Card

1
2
3
4
5
6
7
8
9
10
11
12
13
14
15
16
17
18
19
20
21
22
23

CVP = central venous pressure; **LV** = left ventricular; **PCWP** = pulmonary capillary

Exhibit Display

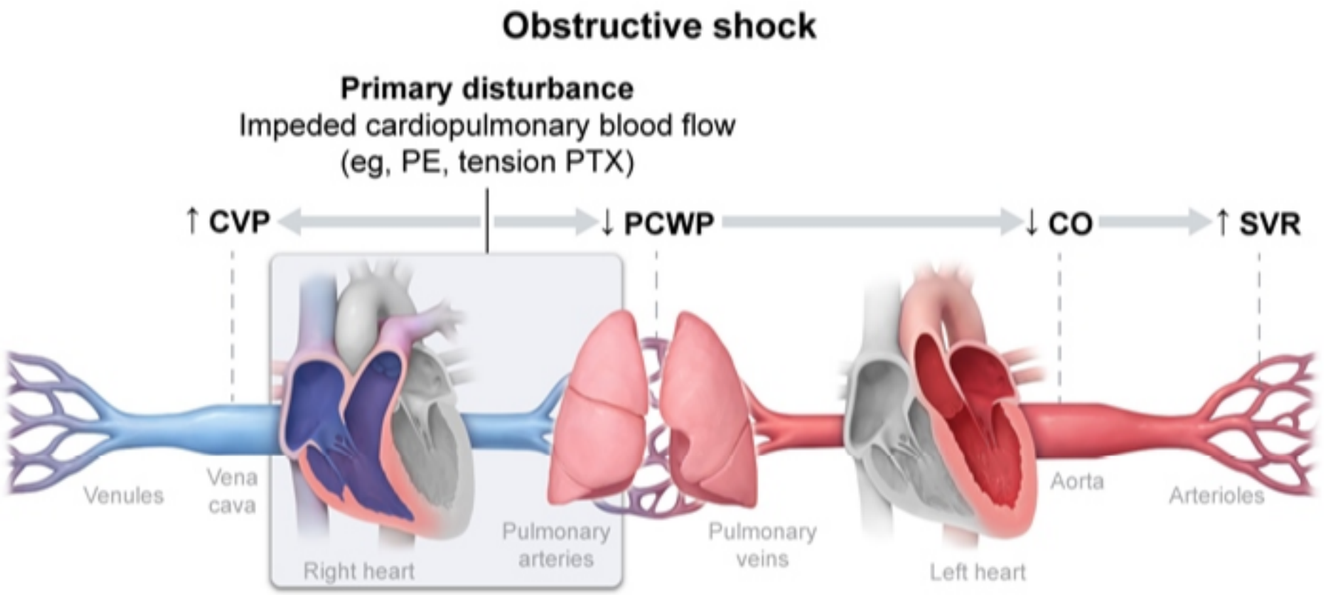

CO = cardiac output; **CVP** = central venous pressure; **PCWP** = pulmonary capillary wedge pressure; **PE** = pulmonary embolism; **PTX** = pneumothorax; **SVR** = systemic vascular resistance.

©UWorld

Zoom In Zoom Out Reset Add To Flash Card

1
2
3
4
5
6
7
8
9
10
11
12
13
14
15
16
17
18
19
20
21
22
23

A 55-year-old man comes to the office for follow-up of hypertension and coronary heart disease. He has been on several medications in the past with suboptimal blood pressure control. The physician considers adding verapamil to the patient's current regimen, as its vasodilatory properties make it useful for controlling systemic hypertension. Verapamil also affects cardiac contractility but has a minimal effect on skeletal muscle. Which of the following properties of skeletal muscle is responsible for its resistance to the medication?

A. Calmodulin-independent excitation-contraction coupling

B. Decreased troponin affinity to intracellular calcium

C. Elaborate T-tubular system

D. Lack of internal automaticity

E. Little dependence on extracellular calcium influx

Submit

1
2
3
4
5
6
7
8
9
10
11
12
13
14
15
16
17
18
19
20
21
22
23

A 55-year-old man comes to the office for follow-up of hypertension and coronary heart disease. He has been on several medications in the past with suboptimal blood pressure control. The physician considers adding verapamil to the patient's current regimen, as its vasodilatory properties make it useful for controlling systemic hypertension. Verapamil also affects cardiac contractility but has a minimal effect on skeletal muscle. Which of the following properties of skeletal muscle is responsible for its resistance to the medication?

A. Calmodulin-independent excitation-contraction coupling (17%)

B. Decreased troponin affinity to intracellular calcium (3%)

C. Elaborate T-tubular system (11%)

D. Lack of internal automaticity (15%)

✓ E. Little dependence on extracellular calcium influx (52%)

Omitted
Correct answer
E

52%
Answered correctly

02 secs
Time Spent

06/04/2020
Last Updated

Explanation

Effect of Verapamil on skeletal muscle cell (mechanical coupling)

Normal state

Verapamil blockade

1
2
3
4
5
6
7
8
9
10
11
12
13
14
15
16
17
18
19
20
21
22
23

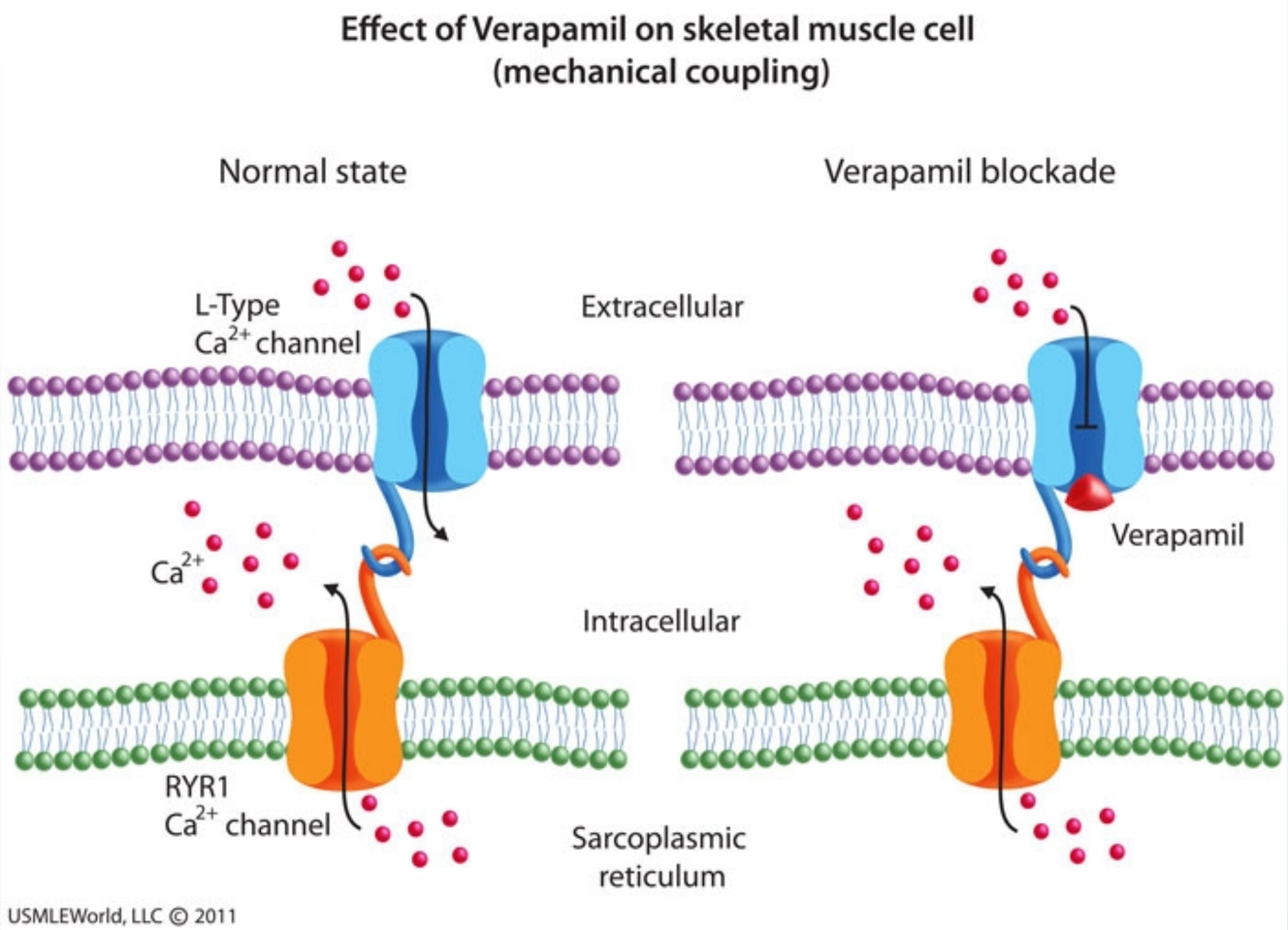

Calcium plays an important role in excitation-contraction coupling in cardiac, smooth, and skeletal muscle cells. Myocyte depolarization causes activation of L-type calcium channels on the plasma membrane. In **cardiac and smooth muscle cells**, this leads to an **influx of extracellular calcium** that activates sarcoplasmic RyR channels, inducing the release of additional calcium from the sarcoplasmic reticulum (calcium-induced calcium release). The released calcium binds to troponin (cardiac muscle) or calmodulin (smooth muscle), allowing actin and myosin to interact and cause muscle contraction.

Calcium plays an important role in excitation-contraction coupling in cardiac, smooth, and skeletal muscle cells. Myocyte depolarization causes activation of L-type calcium channels on the plasma membrane. In **cardiac and smooth muscle cells**, this leads to an **influx of extracellular calcium** that activates sarcoplasmic RyR channels, inducing the release of additional calcium from the sarcoplasmic reticulum (calcium-induced calcium release). The released calcium binds to troponin (cardiac muscle) or calmodulin (smooth muscle), allowing actin and myosin to interact and cause muscle contraction.

In contrast, the L-type calcium channels in **skeletal muscle** directly interact with RyR calcium channels to release calcium from the sarcoplasmic reticulum. This **mechanical coupling** between the receptors allows sarcoplasmic calcium release to occur without significant influx of calcium across the plasma membrane. **Verapamil** is a nondihydropyridine calcium channel blocker that acts by **blocking L-type calcium channels**, preventing the initial calcium influx into cardiac myocytes and vascular smooth muscle cells. Because skeletal muscle is not dependent on extracellular calcium influx, calcium channel blockers do not affect skeletal muscle contractility.

(Choice A) Troponin (but not calmodulin) is responsible for contraction of both cardiac and skeletal muscle. Unlike skeletal muscle, cardiac muscle is affected by verapamil due to its dependence on extracellular calcium to induce calcium release from the sarcoplasmic reticulum.

(Choice B) A rise in intracellular calcium concentration results in a structural change in the troponin complex that allows actin and myosin to interact and cause skeletal muscle contraction. Calcium channel blockers do not affect troponin's affinity to intracellular calcium.

(Choice C) An elaborate T tubule system is present in skeletal and cardiac muscle but not in smooth muscle. T tubules are a communication of the extracellular space that allows the depolarization impulse to reach deep into the cell, nearer to the myofilaments. They are in close proximity to the sarcoplasmic reticulum and therefore facilitate rapid release of intracellular calcium stores.

(Choice D) Unlike cardiac myocytes and specialized smooth muscle tissue (eg, gastrointestinal tract, ureters), skeletal muscle does not display automaticity and contracts only in response to the neurotransmitter acetylcholine. However, the mechanical coupling between L-type and RyR calcium channels is responsible for skeletal muscle's resistance to verapamil.

Educational objective:
Contraction initiation in cardiac and smooth muscle cells is dependent on extracellular calcium influx through L-type calcium channels, which can be prevented by calcium channel blockers (eg, verapamil). Skeletal muscle is resistant to calcium channel blockers, as calcium release by the sarcoplasmic reticulum is triggered by a mechanical interaction between L-type and RyR calcium channels.

1
2
3
4
5
6
7
8
9
10
11
12
13
14
15
16
17
18
19
20
21
22
23

Exhibit Display

Effect of Verapamil on Cardiac Muscle Cell | Effect of Verapamil on Smooth Muscle Cell

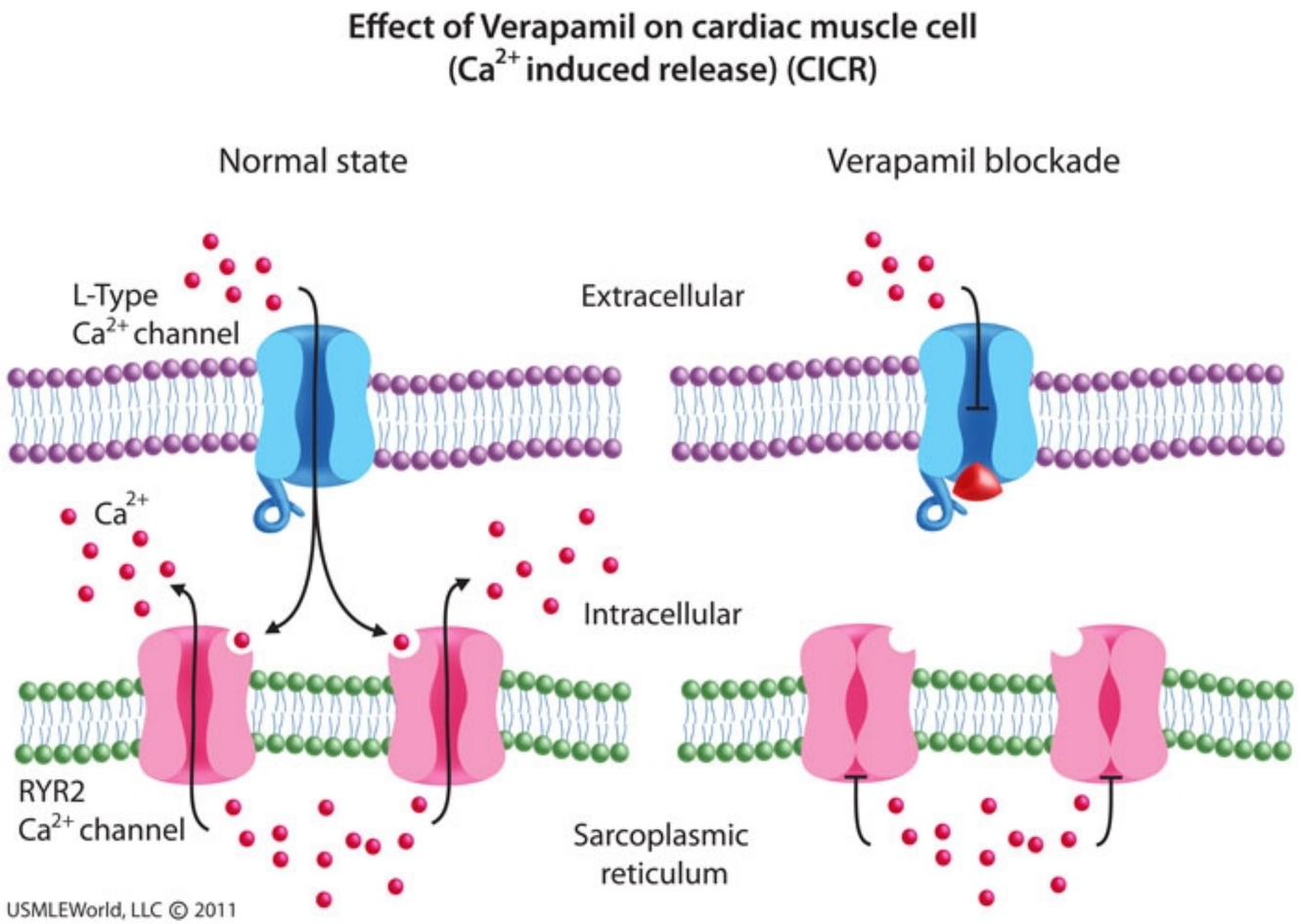

Zoom In | Zoom Out | Reset | Add To New Card | Existing Card

1
2
3
4
5
6
7
8
9
10
11
12
13
14
15
16
17
18
19
20
21
22
23

Exhibit Display

Effect of Verapamil on Cardiac Muscle Cell | Effect of Verapamil on Smooth Muscle Cell

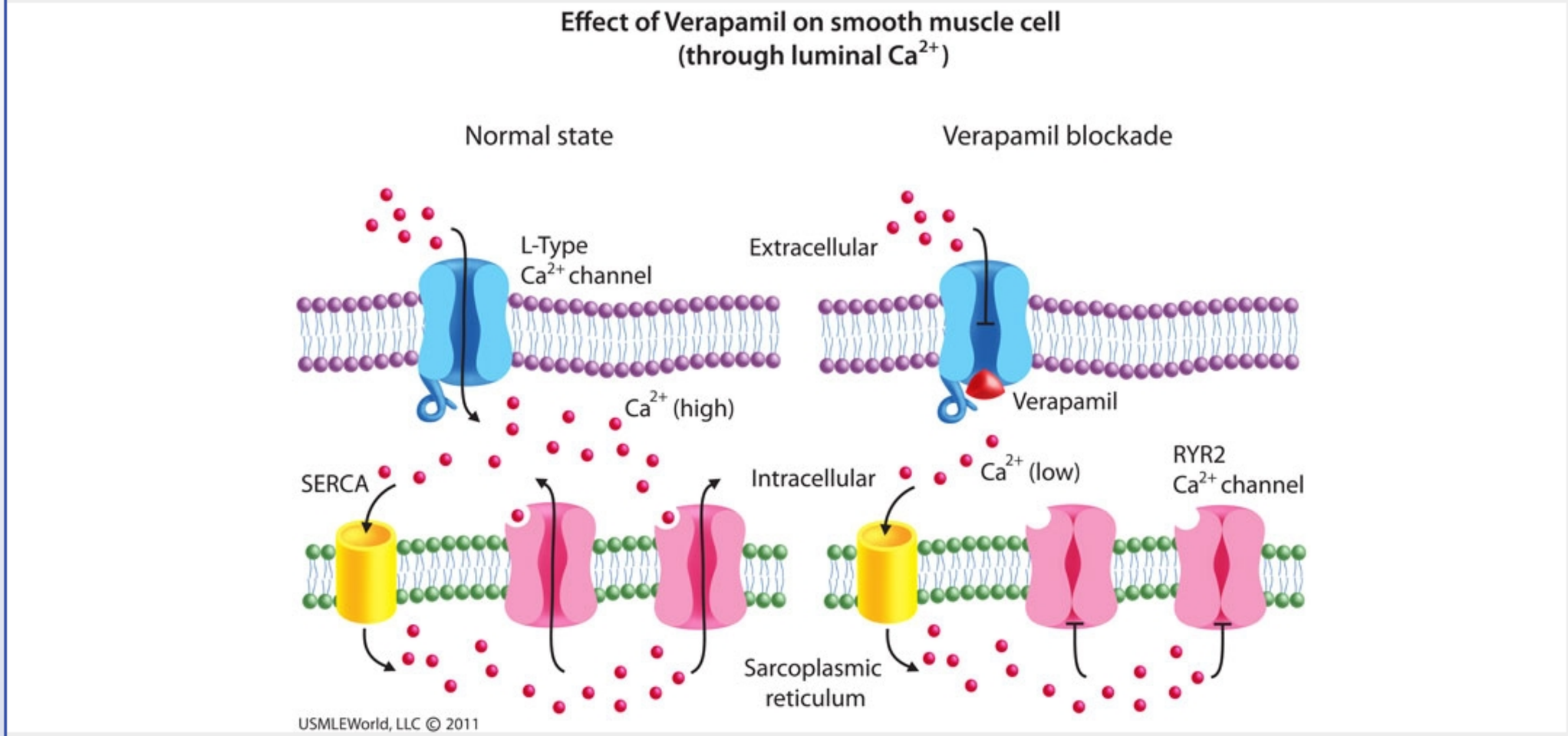

Zoom In | Zoom Out | Reset | Add To New Card | Existing Card

calcium release). The released calcium binds to troponin (cardiac muscle) or calmodulin (smooth muscle), allowing actin and myosin to interact and cause muscle contraction.

In contrast, the L-type calcium channels in **skeletal muscle** directly interact with RyR calcium channels to release calcium from the sarcoplasmic reticulum. This **mechanical coupling** between the receptors allows sarcoplasmic calcium release to occur without significant influx of calcium across the plasma membrane. **Verapamil** is a nondihydropyridine calcium channel blocker that acts by **blocking L-type calcium channels**, preventing the initial calcium influx into cardiac myocytes and vascular smooth muscle cells. Because skeletal muscle is not dependent on extracellular calcium influx, calcium channel blockers do not affect skeletal muscle contractility.

(Choice A) Troponin (but not calmodulin) is responsible for contraction of both cardiac and skeletal muscle. Unlike skeletal muscle, cardiac muscle is affected by verapamil due to its dependence on extracellular calcium to induce calcium release from the sarcoplasmic reticulum.

(Choice B) A rise in intracellular calcium concentration results in a structural change in the troponin complex that allows actin and myosin to interact and cause skeletal muscle contraction. Calcium channel blockers do not affect troponin's affinity to intracellular calcium.

(Choice C) An elaborate T tubule system is present in skeletal and cardiac muscle but not in smooth muscle. T tubules are a communication of the extracellular space that allows the depolarization impulse to reach deep into the cell, nearer to the myofilaments. They are in close proximity to the sarcoplasmic reticulum and therefore facilitate rapid release of intracellular calcium stores.

(Choice D) Unlike cardiac myocytes and specialized smooth muscle tissue (eg, gastrointestinal tract, ureters), skeletal muscle does not display automaticity and contracts only in response to the neurotransmitter acetylcholine. However, the mechanical coupling between L-type and RyR calcium channels is responsible for skeletal muscle's resistance to verapamil.

Educational objective:
Contraction initiation in cardiac and smooth muscle cells is dependent on extracellular calcium influx through L-type calcium channels, which can be prevented by calcium channel blockers (eg, verapamil). Skeletal muscle is resistant to calcium channel blockers, as calcium release by the sarcoplasmic reticulum is triggered by a mechanical interaction between L-type and RyR calcium channels.

References

- Role of ryanodine receptor subtypes in initiation and formation of calcium sparks in arterial smooth muscle: comparison with striated muscle.

1
2
3
4
5
6
7
8
9
10
11
12
13
14
15
16
17
18
19
20
21
22
23

A 50-year-old man comes to the emergency department due to intermittent palpitations over the last 6 months. The patient describes them as "very uncomfortable" and says the episodes occur randomly, last for several hours, and resolve spontaneously or with sleep. The current episode started an hour ago and has been accompanied by lightheadedness. He has no medical history and says that he does not like seeing doctors. He is a lifetime nonsmoker. The patient drinks beer on weekends. He has no family history of cardiovascular disease. Temperature is normal and blood pressure is 122/75 mm Hg. BMI is 30 kg/m^2. Chest examination reveals no murmurs and the lungs are clear on auscultation. There is trace peripheral edema. Cardiac rhythm strip obtained in the emergency department is shown in the exhibit. Aberrant electrical activity in which of the following anatomic structures is the most likely trigger for this patient's current condition?

A. Crista terminalis
B. Papillary muscles
C. Pulmonary veins
D. Right ventricular outflow tract
E. Sinoatrial node
F. Tricuspid valve annulus

Submit

1
2
3
4
5
6
7
8
9
10
11
12
13
14
15
16
17
18
19
20
21
22
23

Exhibit Display

©UWorld

Zoom In | Zoom Out | Reset | Add To New Card | Existing Card

1
2
3
4
5
6
7
8
9
10
11
12
13
14
15
16
17
18
19
20
21
22
23

A 50-year-old man comes to the emergency department due to intermittent palpitations over the last 6 months. The patient describes them as "very uncomfortable" and says the episodes occur randomly, last for several hours, and resolve spontaneously or with sleep. The current episode started an hour ago and has been accompanied by lightheadedness. He has no medical history and says that he does not like seeing doctors. He is a lifetime nonsmoker. The patient drinks beer on weekends. He has no family history of cardiovascular disease. Temperature is normal and blood pressure is 122/75 mm Hg. BMI is 30 kg/m^2. Chest examination reveals no murmurs and the lungs are clear on auscultation. There is trace peripheral edema. Cardiac rhythm strip obtained in the emergency department is shown in the exhibit. Aberrant electrical activity in which of the following anatomic structures is the most likely trigger for this patient's current condition?

- A. Crista terminalis (9%)
- B. Papillary muscles (1%)
- ✓ C. Pulmonary veins (30%)
- D. Right ventricular outflow tract (6%)
- E. Sinoatrial node (41%)
- F. Tricuspid valve annulus (10%)

Omitted
Correct answer
C

30%
Answered correctly

07 secs
Time Spent

06/01/2020
Last Updated

Explanation

Pulmonary vein ablation for atrial fibrillation

1
2
3
4
5
6
7
8
9
10
11
12
13
14
15
16
17
18
19
20
21
22
23

Explanation

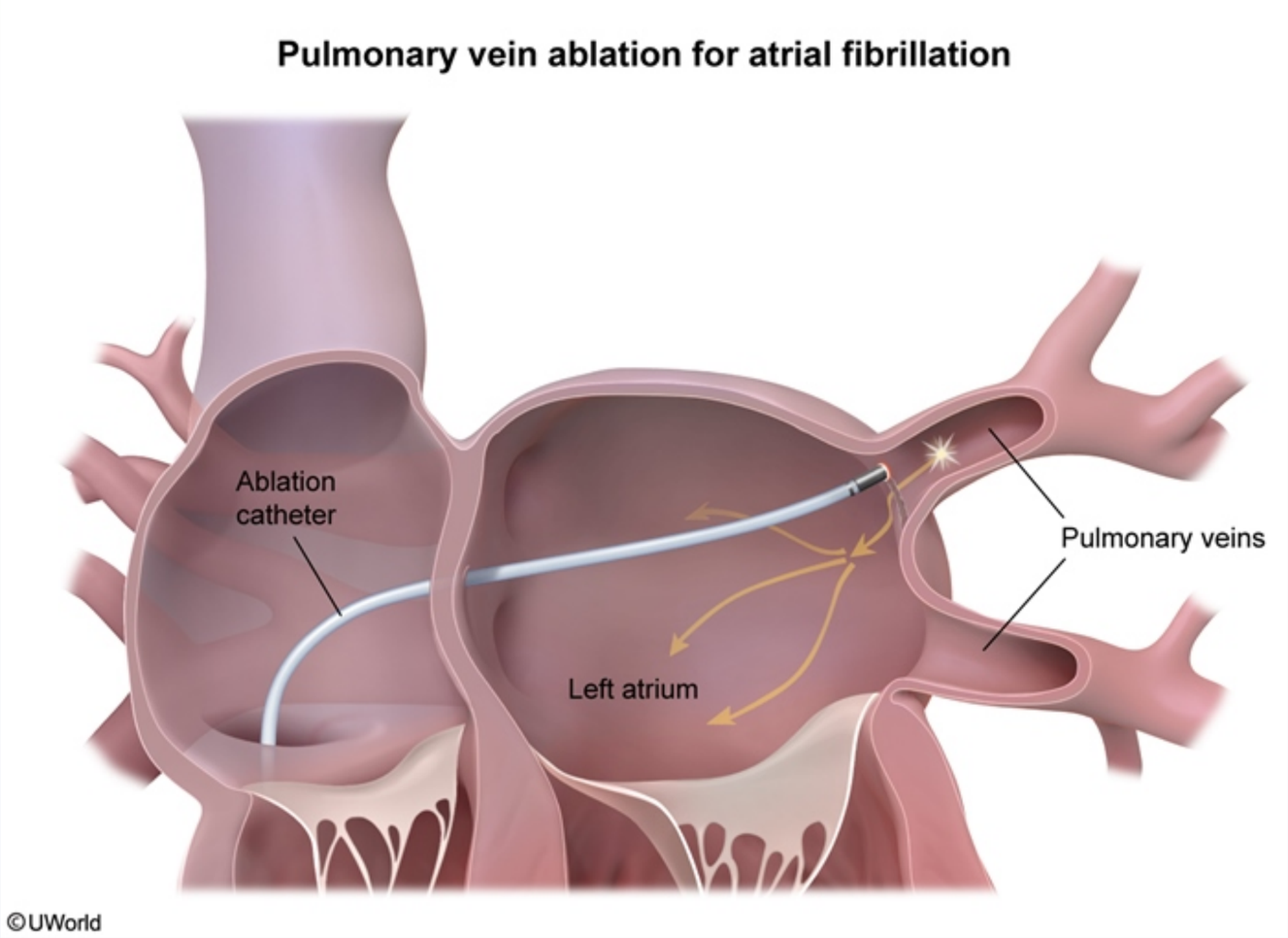

This patient's presentation with intermittent palpitations and cardiac rhythm strip showing an **irregularly irregular rhythm** with varying R-R intervals and **no discernible P waves** is consistent with **paroxysmal atrial fibrillation** (AF).

The development of AF involves structural and electrical changes that predispose to the initiation and maintenance of electrical reentrant circuits

This patient's presentation with intermittent palpitations and cardiac rhythm strip showing an **irregularly irregular rhythm** with varying R-R intervals and **no discernible P waves** is consistent with **paroxysmal atrial fibrillation** (AF).

The development of AF involves structural and electrical changes that predispose to the initiation and maintenance of electrical reentrant circuits and/or ectopic foci. These pathologic changes, termed **atrial remodeling**, can occur as a result of normal aging or diseases that cause atrial dilation (eg, hypertension, mitral regurgitation). The remodeling leads to shortening of the atrial refractory period and heterogeneity in localized electrical conduction between atrial myocytes, creating a **substrate** for the development of AF.

In predisposed patients, AF can spawn from specific triggers such as focal electrical discharges, increased atrial stretch, elevated sympathetic activity (eg, sepsis, emotional stress), and ingestion of alcohol. The most common trigger is aberrant electrical foci in the **pulmonary veins** near their ostia into the left atrium; therefore, catheter ablation of pulmonary vein trigger sites (pulmonary vein isolation) is used for the treatment of symptomatic, paroxysmal AF.

(Choices A and F) The cavotricuspid isthmus is the area of right atrial tissue between the crista terminalis (ridge that runs along the vena cava) and the tricuspid annulus, and is usually part of the reentry circuit in atrial flutter. ECG during atrial flutter typically shows a saw-tooth pattern of flutter waves, and the ventricular rhythm can be regular or irregular.

(Choices B and D) Monomorphic ventricular tachycardia most commonly originates from areas of ischemic myocardium; however, it can sometimes originate from nonischemic sites in the papillary muscles or right ventricular outflow tract. ECG of ventricular tachycardia typically demonstrates regular R-R intervals and wide QRS complexes.

(Choice E) The sinoatrial node is the site of origin of sinus tachycardia; ECG shows regular rhythm with P waves and a rate >100/min.

Educational objective:
Atrial fibrillation is recognized by an irregularly irregular rhythm with variable R-R intervals and absence of P waves on ECG. The development of AF most commonly involves ectopic electrical foci in the pulmonary veins that trigger fibrillatory conduction in abnormal (remodeled) atrial tissue.

References

- Atrial fibrillation: classification, pathophysiology, mechanisms, and drug treatment.

Physiology	Cardiovascular System	Atrial fibrillation
Subject	System	Topic

1
2
3
4
5
6
7
8
9
10
11
12
13
14
15
16
17
18
19
20
21
22
23

This patient's presentation with intermittent palpitations and cardiac rhythm strip showing an **irregularly irregular rhythm** with varying R-R

Exhibit Display

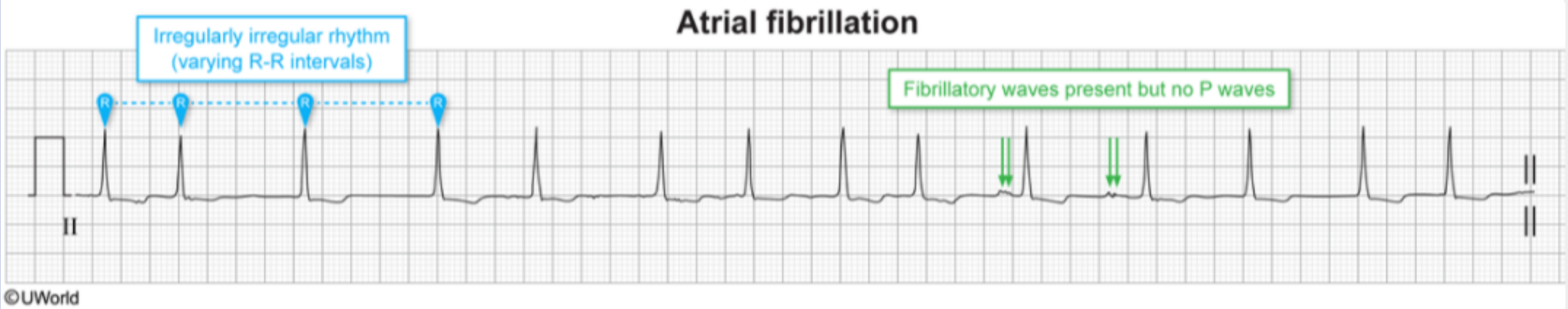

Zoom In | Zoom Out | Reset | Add To New Card | Existing Card

1
2
3
4
5
6
7
8
9
10
11
12
13
14
15
16
17
18
19
20
21
22
23

This patient's presentation with intermittent palpitations and cardiac rhythm strip showing an **irregularly irregular rhythm** with varying R-R

Exhibit Display

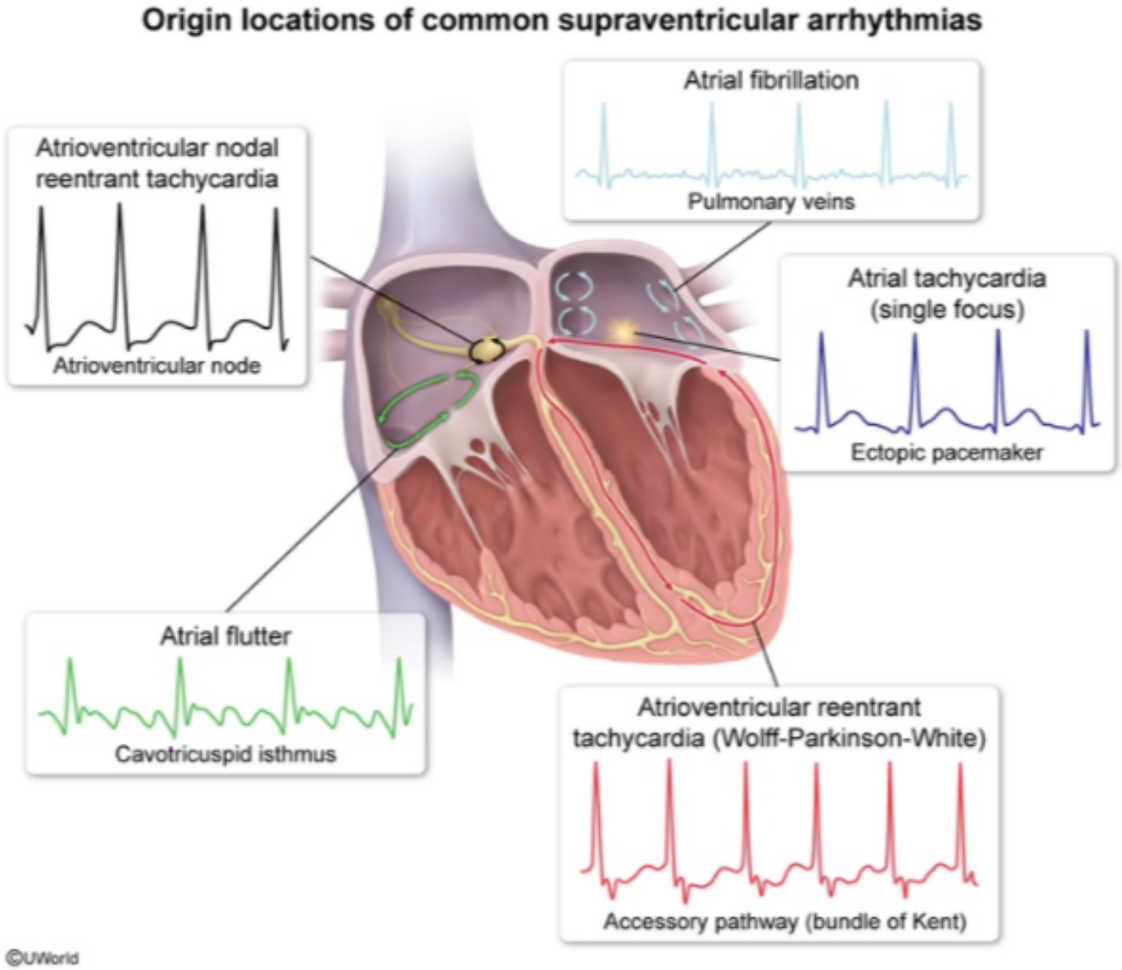

Zoom In | Zoom Out | Reset | Add To New Card | Existing Card

1
2
3
4
5
6
7
8
9
10
11
12
13
14
15
16
17
18
19
20
21
22
23

Exhibit Display

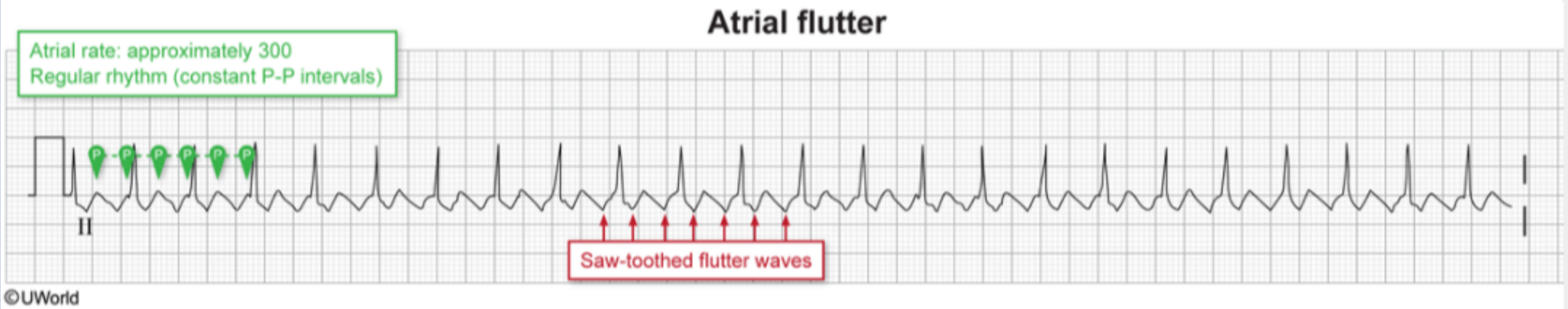

Zoom In | Zoom Out | Reset | Add To New Card | Existing Card

Copyright © UWorld. All rights reserved.

1
2
3
4
5
6
7
8
9
10
11
12
13
14
15
16
17
18
19
20
21
22
23

Exhibit Display

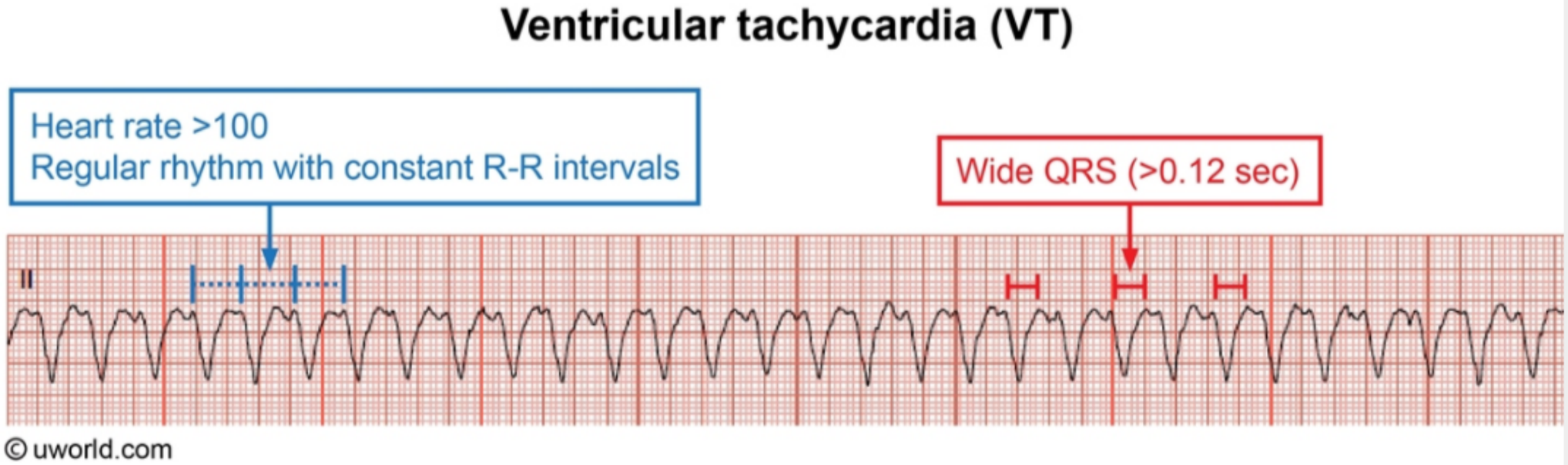

Zoom In | Zoom Out | Reset | Add To New Card | Existing Card

Copyright © UWorld. All rights reserved.

1
2
3
4
5
6
7
8
9
10
11
12
13
14
15
16
17
18
19
20
21
22
23

A 69-year-old man is brought to the emergency department with sudden onset palpitations and dyspnea. His past medical history is significant for hypertension and gastroesophageal reflux disease. An electrocardiogram (ECG) reveals a heart rate of 120 beats per minute with an irregular rhythm, narrow QRS complexes, and no P waves. Which of the following physiologic factors most likely determines the ventricular contraction rate in this patient?

A. Atrial muscle depolarization rate
B. Atrioventricular node refractory period
C. Bundle branch conductivity
D. Purkinje system pacemaker activity
E. Sinoatrial node discharge rate
F. Ventricular muscle refractory period

Submit

A 69-year-old man is brought to the emergency department with sudden onset palpitations and dyspnea. His past medical history is significant for hypertension and gastroesophageal reflux disease. An electrocardiogram (ECG) reveals a heart rate of 120 beats per minute with an irregular rhythm, narrow QRS complexes, and no P waves. Which of the following physiologic factors most likely determines the ventricular contraction rate in this patient?

- A. Atrial muscle depolarization rate (5%)
- ✓ B. Atrioventricular node refractory period (54%)
- C. Bundle branch conductivity (5%)
- D. Purkinje system pacemaker activity (15%)
- E. Sinoatrial node discharge rate (7%)
- F. Ventricular muscle refractory period (11%)

Omitted
Correct answer
B

54%
Answered correctly

02 secs
Time Spent

05/28/2020
Last Updated

Explanation

This patient's electrocardiogram (ECG) findings are diagnostic for **atrial fibrillation (AF)** with rapid ventricular response. AF is the most common cardiac arrhythmia and is characterized by **absent P waves, irregularly irregular R-R intervals**, and **narrow QRS complexes**. Rapid, irregular, low amplitude fibrillatory waves are also frequently seen and represent chaotic, continuous atrial depolarizations.

AF is initiated by aberrant electrical impulses that arise within regions of heightened atrial excitability (most often the pulmonary veins). Once triggered, AF leads to electrical remodeling of the atria with the development of shortened refractory periods and increased conductivity. This

Explanation

This patient's electrocardiogram (ECG) findings are diagnostic for **atrial fibrillation (AF)** with rapid ventricular response. AF is the most common cardiac arrhythmia and is characterized by **absent P waves, irregularly irregular R-R intervals**, and **narrow QRS complexes**. Rapid, irregular, low amplitude fibrillatory waves are also frequently seen and represent chaotic, continuous atrial depolarizations.

AF is initiated by aberrant electrical impulses that arise within regions of heightened atrial excitability (most often the pulmonary veins). Once triggered, AF leads to electrical remodeling of the atria with the development of shortened refractory periods and increased conductivity. This facilitates the creation and persistence of multiple ectopic foci and re-entrant impulses within the atria, increasing the risk and chronicity of subsequent episodes (AF begets AF).

Ventricular response in AF is dependent on the transmission of abnormal atrial impulses through the **atrioventricular (AV) node**. Each time the AV node is excited, it enters a refractory period during which additional atrial impulses cannot be transmitted to the ventricles; consequently, the majority of atrial impulses never reach the ventricles **(Choice A)**. The average ventricular rate in AF usually ranges between 90-170 beats per minute. Because atrial excitation is chaotic, the ventricular rate is irregular with no set intervals between contractions.

(Choice C) Bundle branch conductivity determines the duration of the QRS complexes, which are widened when there is bundle branch block. It does not affect the ventricular contraction rate.

(Choice D) The Purkinje system can assume pacemaker activity in patients with severe bradycardia (<40 beats per minute), but it would not generate impulses in AF since the ventricular rate is typically elevated.

(Choice E) During AF, the atria are in a state of chaotic, continuous depolarization that is independent of sinoatrial node activity.

(Choice F) The ventricular muscle refractory period does not limit the ventricular contraction rate during AF (the ventricular heart rate can approach 300 beats per minute in ventricular tachycardia).

Educational objective:
Atrial fibrillation occurs due to irregular, chaotic electrical activity within the atria and presents with absent P waves, irregularly irregular R-R intervals, and narrow QRS complexes. The atrioventricular node refractory period regulates the number of atrial impulses that reach the ventricle and determines the ventricular contraction rate in conditions where the atria undergo rapid depolarization.

1
2
3
4
5
6
7
8
9
10
11
12
13
14
15
16
17
18
19
20
21
22
23

Explanation

Exhibit Display

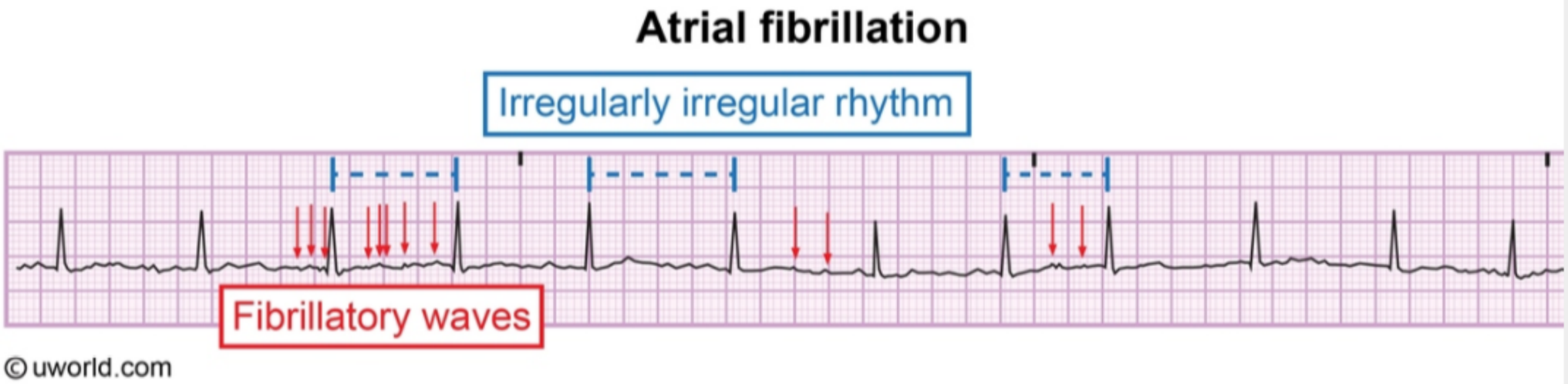

Zoom In | Zoom Out | Reset | Add To New Card | Existing Card

AF is initiated by aberrant electrical impulses that arise within regions of heightened atrial excitability (most often the pulmonary veins). Once triggered, AF leads to electrical remodeling of the atria with the development of shortened refractory periods and increased conductivity. This facilitates the creation and persistence of multiple ectopic foci and re-entrant impulses within the atria, increasing the risk and chronicity of subsequent episodes (AF begets AF).

Ventricular response in AF is dependent on the transmission of abnormal atrial impulses through the **atrioventricular (AV) node**. Each time the AV node is excited, it enters a refractory period during which additional atrial impulses cannot be transmitted to the ventricles; consequently, the majority of atrial impulses never reach the ventricles **(Choice A)**. The average ventricular rate in AF usually ranges between 90-170 beats per minute. Because atrial excitation is chaotic, the ventricular rate is irregular with no set intervals between contractions.

(Choice C) Bundle branch conductivity determines the duration of the QRS complexes, which are widened when there is bundle branch block. It does not affect the ventricular contraction rate.

(Choice D) The Purkinje system can assume pacemaker activity in patients with severe bradycardia (<40 beats per minute), but it would not generate impulses in AF since the ventricular rate is typically elevated.

(Choice E) During AF, the atria are in a state of chaotic, continuous depolarization that is independent of sinoatrial node activity.

(Choice F) The ventricular muscle refractory period does not limit the ventricular contraction rate during AF (the ventricular heart rate can approach 300 beats per minute in ventricular tachycardia).

Educational objective:
Atrial fibrillation occurs due to irregular, chaotic electrical activity within the atria and presents with absent P waves, irregularly irregular R-R intervals, and narrow QRS complexes. The atrioventricular node refractory period regulates the number of atrial impulses that reach the ventricle and determines the ventricular contraction rate in conditions where the atria undergo rapid depolarization.

Physiology	Cardiovascular System	Atrial fibrillation
Subject	System	Topic

Copyright © UWorld. All rights reserved.

1
2
3
4
5
6
7
8
9
10
11
12
13
14
15
16
17
18
19
20
21
22
23

The following vignette applies to the next **2** items. The items in the set must be answered in sequential order. Once you click **Proceed to Next Item**, you will not be able to add or change an answer.

A 52-year-old man comes to the office with a 2-week history of shortness of breath and dry cough. The patient has noticed decreased exercise tolerance that limits his daily activities. A Doppler probe placed at the cardiac apex reveals the following blood flow pattern across the patient's mitral valve.

Item 1 of 2

The point marked by the arrow would best correspond to which of the following auscultation findings?

A. Fourth heart sound

B. Midsystolic click

C. Second heart sound

D. Third heart sound

Submit

1
2
3
4
5
6
7
8
9
10
11
12
13
14
15
16
17
18
19
20
21
22
23

The following vignette applies to the next **2** items. The items in the set must be answered in sequential order. Once you click **Proceed to Next Item**, you will not be able to add or change an answer.

A 52-year-old man comes to the office with a 2-week history of shortness of breath and dry cough. The patient has noticed decreased exercise tolerance that limits his daily activities. A Doppler probe placed at the cardiac apex reveals the following blood flow pattern across the patient's mitral valve.

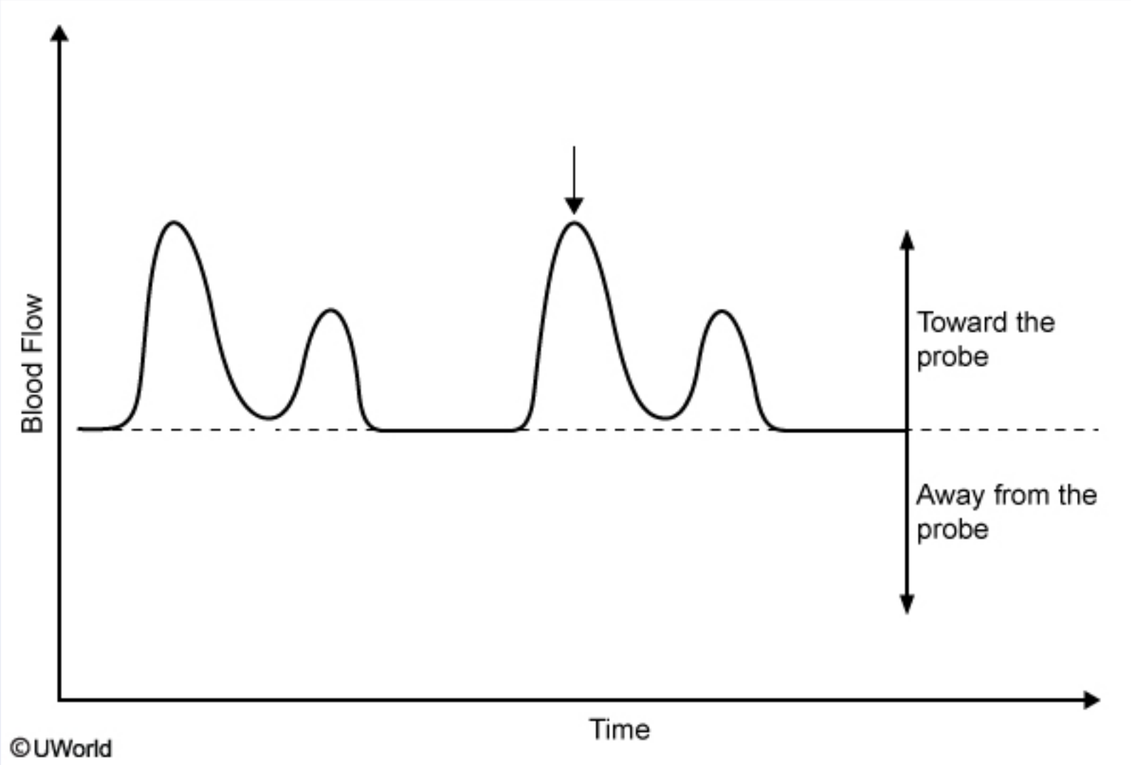

Item 1 of 2

The point marked by the arrow would best correspond to which of the following auscultation findings?

1
2
3
4
5
6
7
8
9
10
11
12
13
14
15
16
17
18
19
20
21
22
23

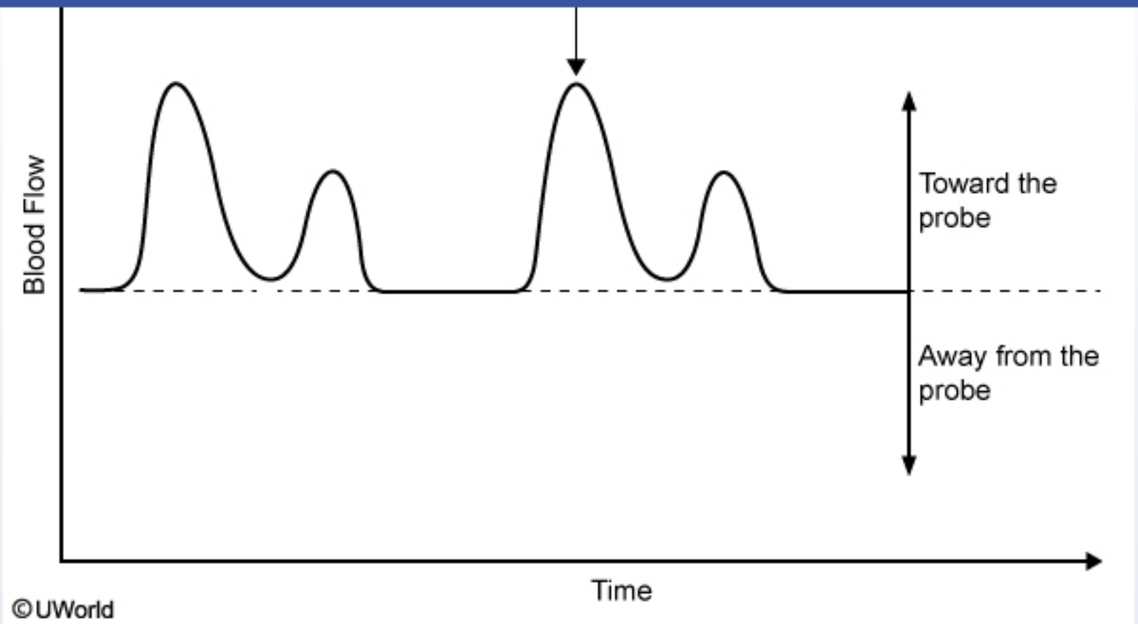

Item 1 of 2

The point marked by the arrow would best correspond to which of the following auscultation findings?

- A. Fourth heart sound
- B. Midsystolic click
- C. Second heart sound
- D. Third heart sound

Submit

1
2
3
4
5
6
7
8
9
10
11
12
13
14
15
16
17
18
19
20
21
22
23

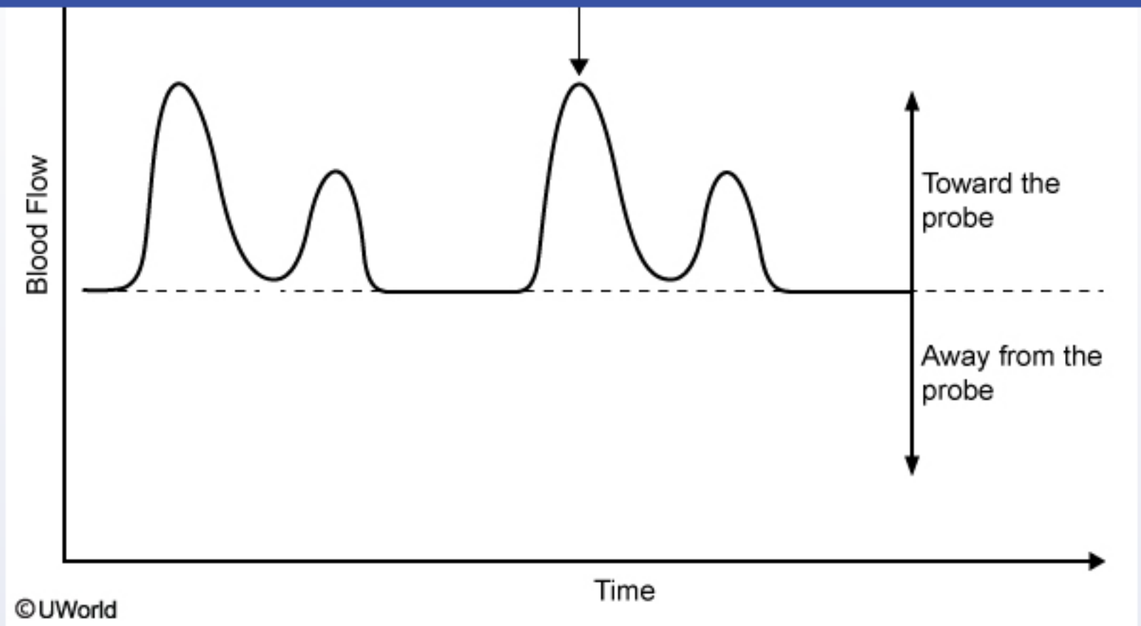

Item 1 of 2

The point marked by the arrow would best correspond to which of the following auscultation findings?

A. Fourth heart sound (14%)

B. Midsystolic click (19%)

C. Second heart sound (26%)

✓ D. Third heart sound (39%)

Omitted
Correct answer

39%
Answered correctly

06 secs
Time Spent

05/27/2020
Last Updated

1
2
3
4
5
6
7
8
9
10
11
12
13
14
15
16
17
18
19
20
21
22
23

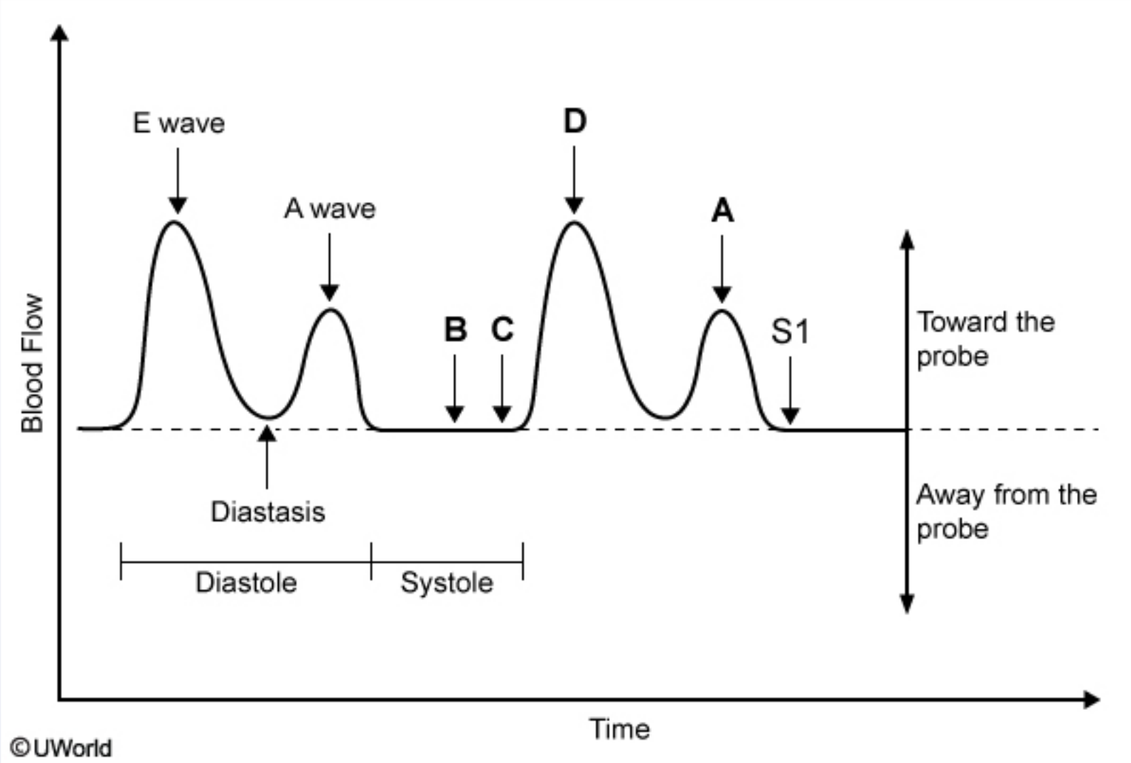

The graph shows the normal pattern of blood flow across the **mitral valve** from the left atrium to left ventricle during **diastole**. There is an initial phase of rapid transmitral blood flow after the mitral valve opens, which represents **early passive ventricular filling** (E wave). This is followed by a period of minimal blood flow (diastasis), which occurs due to equalization in pressure between the left atrium and ventricle. Finally, there is a second peak corresponding to increased transmitral blood flow due to **atrial contraction** (A wave). The A wave ends with the first heart sound (S1) caused by mitral (and tricuspid) valve closure.

When present, a **third heart sound** (S3) occurs during diastole and is best heard with the bell of the stethoscope over the cardiac apex with the patient in the left lateral decubitus position. It is due to sudden limitation of ventricular movement **during passive ventricular filling**. An S3 may be a normal finding in healthy young adults; however, in patients age >40 it suggests abnormal ventricular cavity enlargement (ie, eccentric

The graph shows the normal pattern of blood flow across the **mitral valve** from the left atrium to left ventricle during **diastole**. There is an initial phase of rapid transmitral blood flow after the mitral valve opens, which represents **early passive ventricular filling** (E wave). This is followed by a period of minimal blood flow (diastasis), which occurs due to equalization in pressure between the left atrium and ventricle. Finally, there is a second peak corresponding to increased transmitral blood flow due to **atrial contraction** (A wave). The A wave ends with the first heart sound (S1) caused by mitral (and tricuspid) valve closure.

When present, a **third heart sound** (S3) occurs during diastole and is best heard with the bell of the stethoscope over the cardiac apex with the patient in the left lateral decubitus position. It is due to sudden limitation of ventricular movement **during passive ventricular filling**. An S3 may be a normal finding in healthy young adults; however, in patients age >40 it suggests abnormal ventricular cavity enlargement (ie, eccentric hypertrophy). An S3 is often associated with chronic severe mitral regurgitation, chronic aortic regurgitation, or dilated cardiomyopathy; occasionally, it may be present in high cardiac output states such as pregnancy or thyrotoxicosis.

(Choice A) A fourth heart sound is a low-frequency, late diastolic sound coinciding with atrial systole. It is caused by a sudden rise in end-diastolic pressure as blood strikes a stiff left ventricular wall, and most commonly suggests concentric left ventricular hypertrophy such as occurs in prolonged hypertension or severe aortic stenosis.

(Choice B) A midsystolic click is associated with mitral valve prolapse. In patients with mitral valve prolapse and mitral regurgitation, there will be blood flow away from an apical Doppler probe during systole.

(Choice C) The second heart sound results from closure of the semilunar valves (aortic and pulmonic) at the end of systole.

Educational objective:
A third heart sound (S3) occurs due to sudden limitation of ventricular movement during passive ventricular filling in diastole. An S3 in patients age >40 suggests abnormal ventricular cavity enlargement such as occurs in chronic severe mitral regurgitation, chronic aortic regurgitation, or dilated cardiomyopathy.

Physiology	Cardiovascular System	Mitral regurgitation
Subject	System	Topic

Copyright © UWorld. All rights reserved.

1
2
3
4
5
6
7
8
9
10
11
12
13
14
15
16
17
18
19
20
21
22
23

The graph shows the normal pattern of blood flow across the **mitral valve** from the left atrium to left ventricle during **diastole**. There is an initial

Exhibit Display

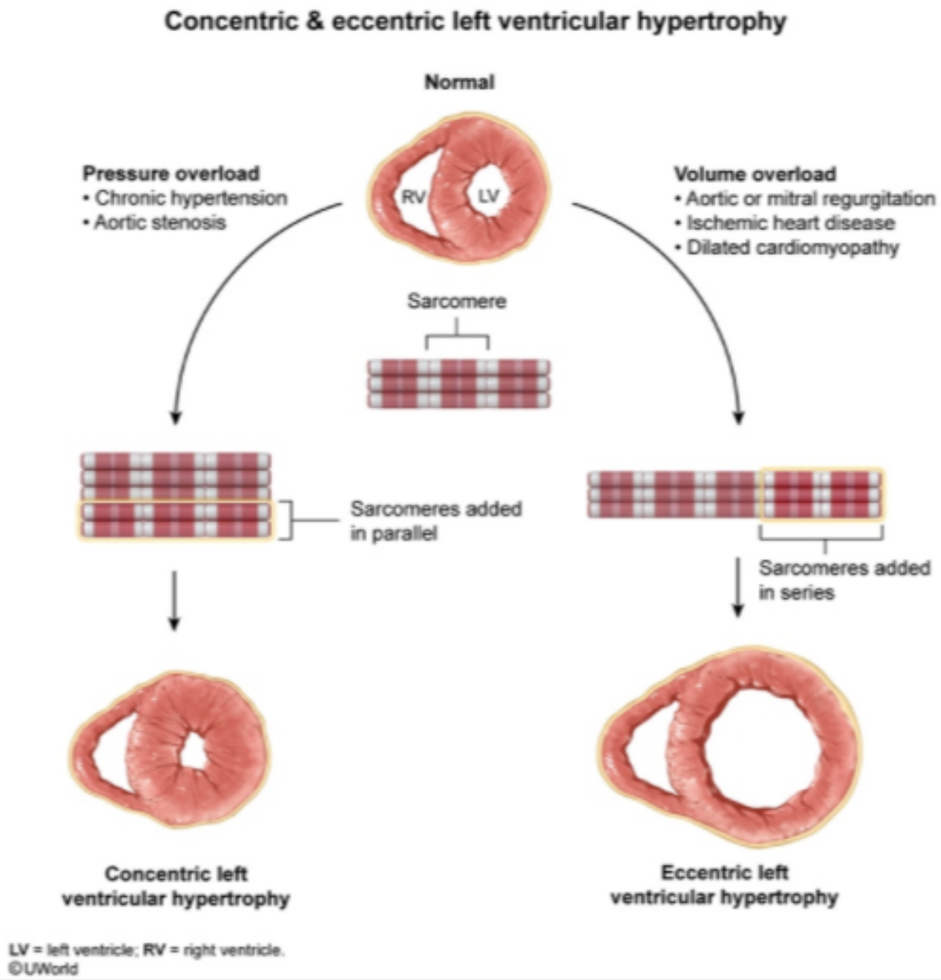

Zoom In Zoom Out Reset Add To Flash Card

Item 2 of 2

On physical examination, jugular venous pressure is elevated, breath sounds are decreased at the right lung base with dullness to percussion, and 2+ bilateral lower extremity pitting edema is present. Chest x-ray shows cephalization of the blood vessels, Kerley B lines, and a right pleural effusion. Thoracentesis is performed for pleural fluid analysis. In comparison to plasma fluid, which of the following pleural fluid findings is most likely to be observed?

- A. High amylase content
- B. High protein content
- C. High white blood cell count
- D. Low glucose content
- E. Low lactate dehydrogenase content

Submit

Item 2 of 2

On physical examination, jugular venous pressure is elevated, breath sounds are decreased at the right lung base with dullness to percussion, and 2+ bilateral lower extremity pitting edema is present. Chest x-ray shows cephalization of the blood vessels, Kerley B lines, and a right pleural effusion. Thoracentesis is performed for pleural fluid analysis. In comparison to plasma fluid, which of the following pleural fluid findings is most likely to be observed?

- A. High amylase content (1%)
- B. High protein content (20%)
- C. High white blood cell count (3%)
- D. Low glucose content (13%)
- ✓ E. Low lactate dehydrogenase content (61%)

Omitted
Correct answer
E

61%
Answered correctly

02 secs
Time Spent

05/27/2020
Last Updated

Explanation

Exudative & transudative pleural effusions		
	Exudate	**Transudate**
	• Pleural fluid protein/serum protein ratio >0.5	

Exudative & transudative pleural effusions		
	Exudate	**Transudate**
Light criteria	• Pleural fluid protein/serum protein ratio >0.5 OR • Pleural fluid LDH/serum LDH ratio >0.6 OR • Pleural fluid LDH >two-thirds upper limit of normal of serum LDH	• Exudate criteria not met
Pathophysiology	• Inflammation	• Hydrostatic or oncotic pressure
Common causes	• Infection (eg, pneumonia) • Malignancy • Rheumatologic disease	• Heart failure • Cirrhosis (hepatic hydrothorax) • Nephrotic syndrome

LDH = lactate dehydrogenase.

In determining the etiology of a **pleural effusion**, differentiating whether the effusion is transudative or exudative is an important step. The **Light criteria** allows differentiation of these two types of effusion via analysis of the protein and lactate dehydrogenase levels of the fluid.

Transudative pleural effusions form due to an imbalance in hydrostatic or oncotic pressure. **Heart failure** causes increased hydrostatic pressure in the pulmonary circulation due to backup of blood flow from the failing left ventricle. This increased pressure leads to leakage of fluid from the pulmonary capillaries and causes a **transudative pleural effusion**, which is characterized by **low protein** and **low lactate dehydrogenase** levels compared to serum values.

In contrast, exudative effusions result from inflammatory disruption of vascular permeability (eg, infection, malignancy) and demonstrate high protein levels **(Choice B)** due to increased capillary permeability and reduced sieving of proteins as fluid traverses the capillary wall. Lactate dehydrogenase levels also tend to be high in exudative effusions.

(Choice A) High amylase content is suggestive of a pleural effusion due to pancreatitis, pancreatic pseudocyst, or esophageal rupture.

In determining the etiology of a **pleural effusion**, differentiating whether the effusion is transudative or exudative is an important step. The **Light criteria** allows differentiation of these two types of effusion via analysis of the protein and lactate dehydrogenase levels of the fluid.

Transudative pleural effusions form due to an imbalance in hydrostatic or oncotic pressure. **Heart failure** causes increased hydrostatic pressure in the pulmonary circulation due to backup of blood flow from the failing left ventricle. This increased pressure leads to leakage of fluid from the pulmonary capillaries and causes a **transudative pleural effusion**, which is characterized by **low protein** and **low lactate dehydrogenase** levels compared to serum values.

In contrast, exudative effusions result from inflammatory disruption of vascular permeability (eg, infection, malignancy) and demonstrate high protein levels **(Choice B)** due to increased capillary permeability and reduced sieving of proteins as fluid traverses the capillary wall. Lactate dehydrogenase levels also tend to be high in exudative effusions.

(Choice A) High amylase content is suggestive of a pleural effusion due to pancreatitis, pancreatic pseudocyst, or esophageal rupture.

(Choice C) High leukocyte count is typical of a complicated parapneumonic effusion or some types of malignant pleural effusion. Transudative effusions do not demonstrate high leukocyte counts.

(Choice D) Low glucose content is seen in the setting of malignant or infectious pleural effusion due to consumption of glucose by bacteria, neutrophils, and/or malignant cells.

Educational objective:
Heart failure can cause transudative pleural effusion due to an increase in pulmonary capillary hydrostatic pressure. Light criteria are useful to differentiate transudative and exudative pleural effusions; transudative effusions are characterized by low protein and lactate dehydrogenase content compared to serum values.

References

- The Light criteria: the beginning and why they are useful 40 years later.

Physiology	Cardiovascular System	Pleural effusion
Subject	System	Topic

Copyright © UWorld. All rights reserved.

A 75-year-old man is brought to the emergency department after his family found him to be lethargic and confused. The patient has a history of hypertension, coronary artery disease, and heart failure. Temperature is 35 C (95 F), blood pressure is 78/46 mm Hg, and pulse is 110/min. The patient is admitted to the intensive care unit and a pulmonary artery catheter is placed, which demonstrates the following readings:

Cardiac output	high
Central venous pressure	low
Pulmonary capillary wedge pressure	low
Mixed venous O_2 saturation	high
Systemic vascular resistance	low

Which of the following is the most likely cause of this patient's hypotension?

- A. Bacterial infection
- B. Gastrointestinal bleeding
- C. Heart failure
- D. Hypothermia
- E. Myocardial infarction
- F. Pulmonary embolism

Submit

A 75-year-old man is brought to the emergency department after his family found him to be lethargic and confused. The patient has a history of hypertension, coronary artery disease, and heart failure. Temperature is 35 C (95 F), blood pressure is 78/46 mm Hg, and pulse is 110/min. The patient is admitted to the intensive care unit and a pulmonary artery catheter is placed, which demonstrates the following readings:

Cardiac output	high
Central venous pressure	low
Pulmonary capillary wedge pressure	low
Mixed venous O_2 saturation	high
Systemic vascular resistance	low

Which of the following is the most likely cause of this patient's hypotension?

- ✓ A. Bacterial infection (44%)
- B. Gastrointestinal bleeding (21%)
- C. Heart failure (7%)
- D. Hypothermia (14%)
- E. Myocardial infarction (2%)
- F. Pulmonary embolism (9%)

Omitted
Correct answer
A

44%
Answered correctly

06 secs
Time Spent

04/11/2020
Last Updated

Hemodynamic measurements in shock				
Parameter	**Hypovolemic shock**	**Cardiogenic shock**	**Obstructive shock**	**Distributive shock**
CVP (right-sided preload)	↓	↑	↑	↓
PCWP (left-sided preload)	↓	↑	↓*	↓
Cardiac index (LV output)	↓	↓	↓	↑**
SVR (afterload)	↑	↑	↑	↓
SvO_2	↓	↓	↓	↑**

*In tamponade, left-sided preload is decreased, but measured PCWP is paradoxically increased due to external compression by pericardial fluid.
**Cardiac index and SvO_2 are usually decreased in neurogenic shock due to impaired sympathetic reflexes.
CVP = central venous pressure; **LV** = left ventricular; **PCWP** = pulmonary capillary wedge pressure; **SvO_2** = mixed venous oxygen saturation; **SVR** = systemic vascular resistance.

This patient with severe **hypotension** and evidence of **end-organ dysfunction** (eg, confusion) is in **shock**, which is a state of **inadequate oxygen delivery** to the organs and tissues of the body. Left untreated, shock can rapidly lead to multiorgan failure and death; therefore, prompt diagnosis and treatment are essential. Pulmonary arterial catheterization can help determine the type of shock to help guide treatment.

This patient with severe **hypotension** and evidence of **end-organ dysfunction** (eg, confusion) is in **shock**, which is a state of **inadequate oxygen delivery** to the organs and tissues of the body. Left untreated, shock can rapidly lead to multiorgan failure and death; therefore, prompt diagnosis and treatment are essential. Pulmonary arterial catheterization can help determine the type of shock to help guide treatment.

The **low systemic vascular resistance** (SVR) in this patient is consistent with the peripheral vasodilation that occurs in **distributive shock**; septic shock (usually due to **bacterial infection**) is the most common type of distributive shock. Central venous pressure (CVP), or right-sided preload, is decreased in septic shock due to widespread vasodilation in response to systemic release of proinflammatory mediators. Pulmonary capillary wedge pressure (PCWP), which is an estimate of left atrial pressure (left-sided preload), is decreased as well due to reduced venous return. A compensatory increase in sympathetic drive increases cardiac contractility and heart rate resulting in **increased cardiac output (CO)**. The high rate of blood flow through the systemic capillaries prevents complete extraction of oxygen by the tissues, resulting in **high mixed venous oxygen saturation**.

(Choice B) Gastrointestinal bleeding can lead to hemorrhagic (hypovolemic) shock characterized by low CVP, PCWP, and CO, with a compensatory increase in SVR.

(Choices C and E) Myocardial infarction can lead to heart failure and cardiogenic shock, characterized by high PCWP and CVP. CO decreases, with a compensatory increase in SVR.

(Choice D) Moderate to severe hypothermia (ie, <32 C) can produce hypotension due to bradycardia, but mild hypothermia does not typically lead to shock. Septic shock can present with either hyper- or hypothermia; **hypothermic presentation** may be due to cytokine-induced dysregulation of temperature control in the hypothalamus and is associated with poorer outcomes.

(Choice F) Acute pulmonary embolism is a potential cause of obstructive shock. Blood flow through the pulmonary circulation is impeded, resulting in reduced left-sided preload (low PCWP) and consequently reduced CO with a compensatory increase in SVR. Blood backs up in the capacitance veins leading to high CVP.

Educational objective:
Septic shock can present with either hyper- or hypothermia. The initial disturbance is peripheral vasodilation leading to decreased systemic vascular resistance, decreased central venous pressure, and decreased pulmonary capillary wedge pressure. A compensatory increase in sympathetic drive causes an increase in cardiac output; the resulting high flow rates lead to incomplete oxygen extraction in the tissues, resulting

Exhibit Display

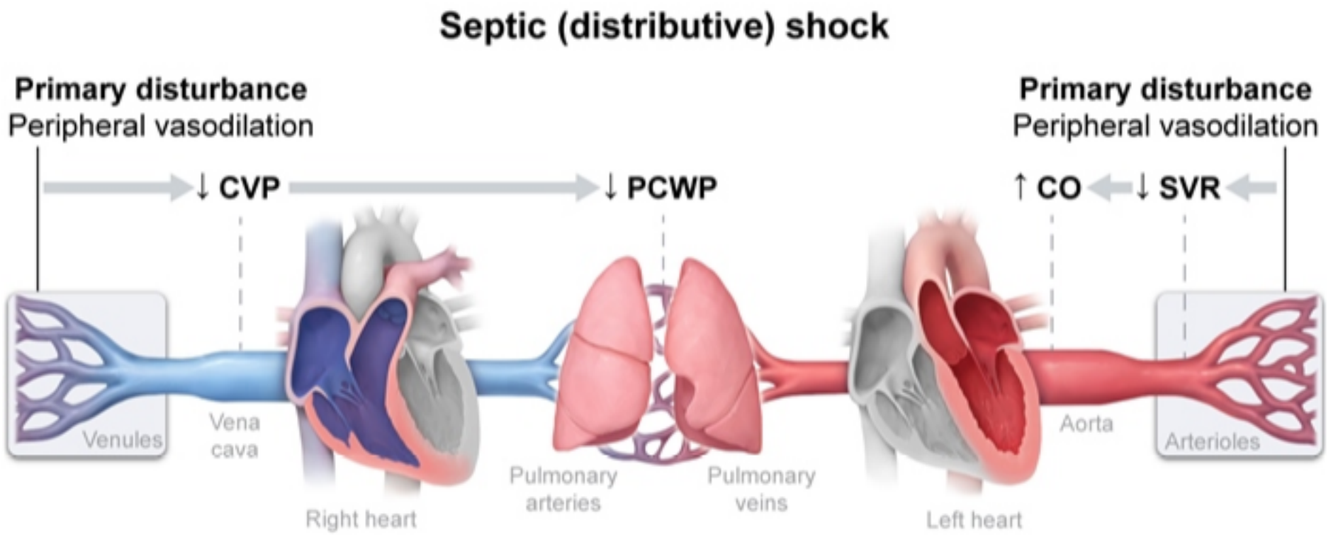

CO = cardiac output; **CVP** = central venous pressure;
PCWP = pulmonary capillary wedge pressure; **SVR** = systemic vascular resistance.

©UWorld

Zoom In | Zoom Out | Reset | Add To New Card | Existing Card

sympathetic drive causes an increase in cardiac output; the resulting high flow rates lead to incomplete oxygen extraction in the tissues, resulting

Exhibit Display

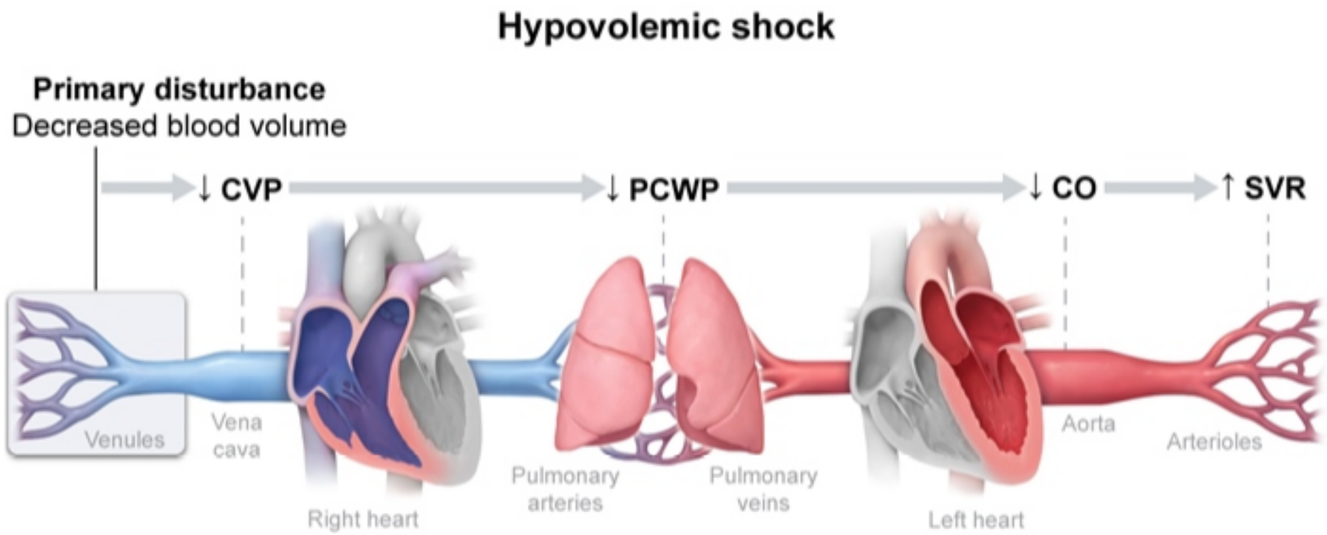

CO = cardiac output; **CVP** = central venous pressure;
PCWP = pulmonary capillary wedge pressure; **SVR** = systemic vascular resistance.

©UWorld

Zoom In | Zoom Out | Reset | Add To New Card | Existing Card

sympathetic drive causes an increase in cardiac output; the resulting high flow rates lead to incomplete oxygen extraction in the tissues, resulting

1 2 3 4 5 6 7 8 9 10 11 12 13 14 15 16 17 18 19 20 21 22 23 24 25 26 27 28 29 30 31

Exhibit Display

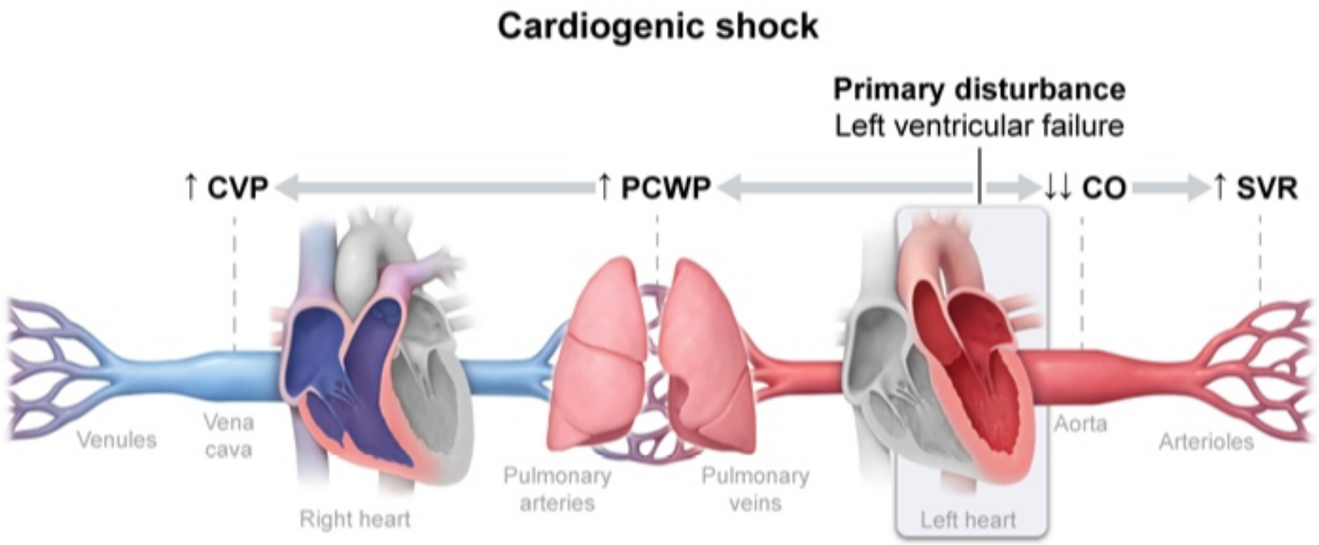

CO = cardiac output; **CVP** = central venous pressure;
PCWP = pulmonary capillary wedge pressure; **SVR** = systemic vascular resistance.

©UWorld

Zoom In | Zoom Out | Reset | Add To New Card | Existing Card

sympathetic drive causes an increase in cardiac output; the resulting high flow rates lead to incomplete oxygen extraction in the tissues, resulting

Exhibit Display

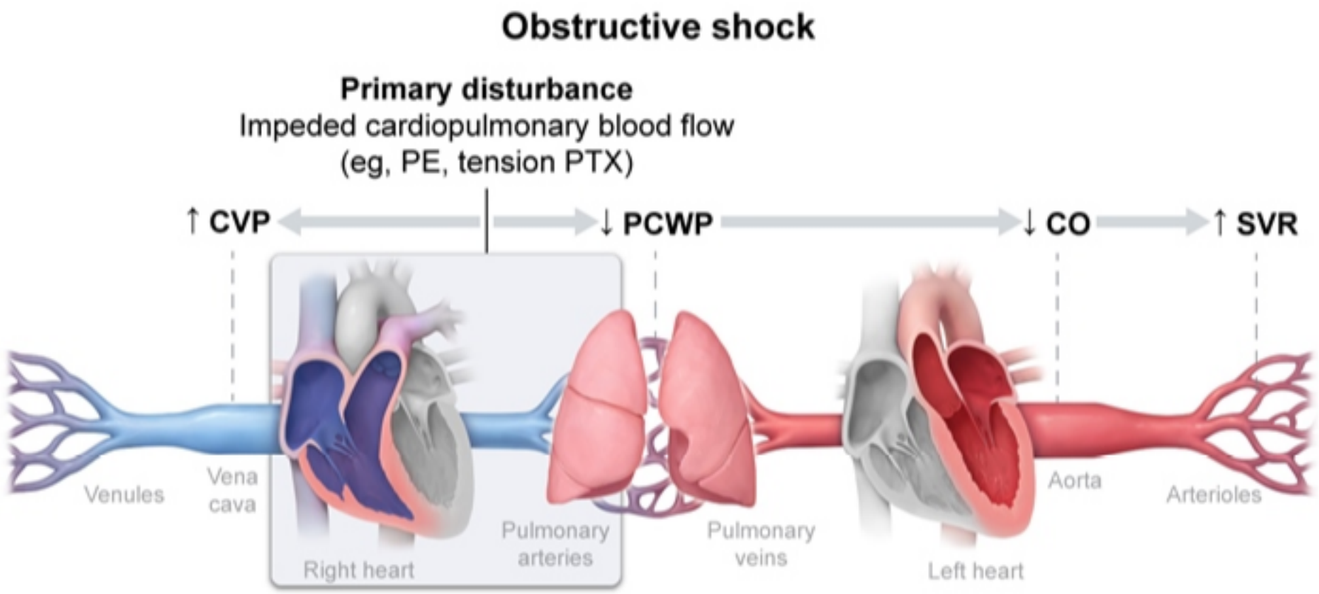

CO = cardiac output; **CVP** = central venous pressure; **PCWP** = pulmonary capillary wedge pressure; **PE** = pulmonary embolism; **PTX** = pneumothorax; **SVR** = systemic vascular resistance.

©UWorld

Zoom In | Zoom Out | Reset | Add To New Card | Existing Card

sympathetic drive causes an increase in cardiac output; the resulting high flow rates lead to incomplete oxygen extraction in the tissues, resulting

The high rate of blood flow through the systemic capillaries prevents complete extraction of oxygen by the tissues, resulting in **high mixed venous oxygen saturation**.

(Choice B) Gastrointestinal bleeding can lead to hemorrhagic (hypovolemic) shock characterized by low CVP, PCWP, and CO, with a compensatory increase in SVR.

(Choices C and E) Myocardial infarction can lead to heart failure and cardiogenic shock, characterized by high PCWP and CVP. CO decreases, with a compensatory increase in SVR.

(Choice D) Moderate to severe hypothermia (ie, <32 C) can produce hypotension due to bradycardia, but mild hypothermia does not typically lead to shock. Septic shock can present with either hyper- or hypothermia; **hypothermic presentation** may be due to cytokine-induced dysregulation of temperature control in the hypothalamus and is associated with poorer outcomes.

(Choice F) Acute pulmonary embolism is a potential cause of obstructive shock. Blood flow through the pulmonary circulation is impeded, resulting in reduced left-sided preload (low PCWP) and consequently reduced CO with a compensatory increase in SVR. Blood backs up in the capacitance veins leading to high CVP.

Educational objective:

Septic shock can present with either hyper- or hypothermia. The initial disturbance is peripheral vasodilation leading to decreased systemic vascular resistance, decreased central venous pressure, and decreased pulmonary capillary wedge pressure. A compensatory increase in sympathetic drive causes an increase in cardiac output; the resulting high flow rates lead to incomplete oxygen extraction in the tissues, resulting in high mixed venous oxygen saturation.

References

- Pulmonary artery catheterization in critically ill patients: a prospective analysis of outcome changes associated with catheter-prompted changes in therapy.

Pathophysiology	Cardiovascular System	Sepsis
Subject	System	Topic

Copyright © UWorld. All rights reserved.

1
2
3
4
5
6
7
8
9
10
11
12
13
14
15
16
17
18
19
20
21
22
23
24
25
26
27
28
29
30
31

A 21-year-old man comes to the office due to recurrent heart palpitations that start and stop abruptly. After initial workup, the physician suspects that there is an abnormal conduction pathway in this patient's heart that bypasses the atrioventricular node. Assuming the diagnosis is correct, which part of the patient's ECG is most likely to be affected during normal sinus rhythm?

- A. A
- B. B
- C. C
- D. D
- E. E

Submit

A 21-year-old man comes to the office due to recurrent heart palpitations that start and stop abruptly. After initial workup, the physician suspects that there is an abnormal conduction pathway in this patient's heart that bypasses the atrioventricular node. Assuming the diagnosis is correct, which part of the patient's ECG is most likely to be affected during normal sinus rhythm?

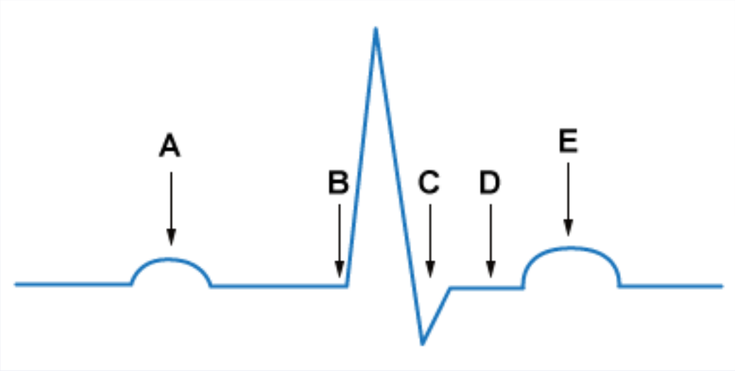

A. A
B. B
C. C
D. D
E. E

Submit

A 21-year-old man comes to the office due to recurrent heart palpitations that start and stop abruptly. After initial workup, the physician suspects that there is an abnormal conduction pathway in this patient's heart that bypasses the atrioventricular node. Assuming the diagnosis is correct, which part of the patient's ECG is most likely to be affected during normal sinus rhythm?

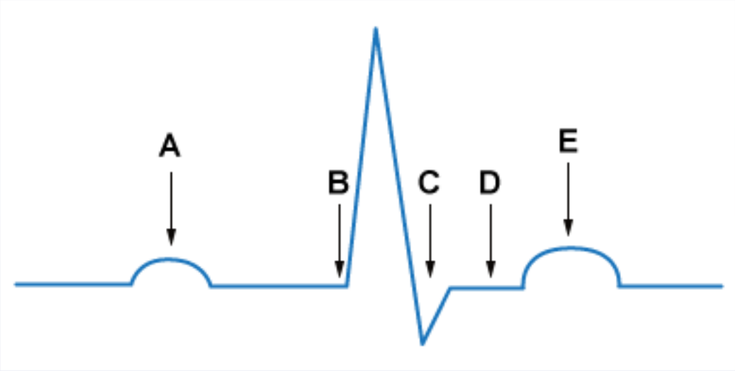

- A. A (9%)
- ✓ B. B (87%)
- C. C (1%)
- D. D (1%)
- E. E (0%)

Omitted
Correct answer
B

87%
Answered correctly

05 secs
Time Spent

05/24/2020
Last Updated

Explanation

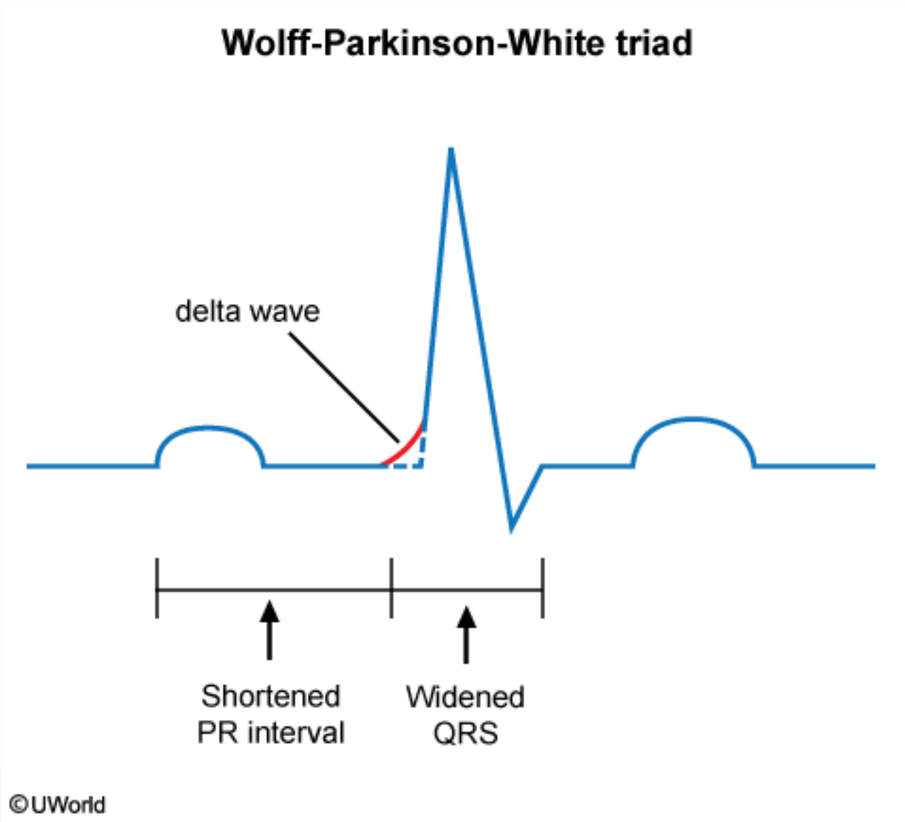

This young patient's repeated episodes of palpitations are suggestive of paroxysmal supraventricular tachycardia, and the physician suspects **Wolff-Parkinson-White (WPW) syndrome**. WPW syndrome is caused by an **accessory conduction pathway** (bundle of Kent) that allows electrical conduction impulses to bypass the atrioventricular node and cause **preexcitation** of the ventricles. This preexcitation leads to characteristic findings on baseline ECG, including a **shortened PR interval** (often <0.12 seconds), early upslope of the QRS complex (**delta wave**), and a **widened QRS complex**.

Many patients with an accessory conduction pathway can be asymptomatic and are diagnosed only when a WPW pattern is incidentally

This young patient's repeated episodes of palpitations are suggestive of paroxysmal supraventricular tachycardia, and the physician suspects **Wolff-Parkinson-White (WPW) syndrome**. WPW syndrome is caused by an **accessory conduction pathway** (bundle of Kent) that allows electrical conduction impulses to bypass the atrioventricular node and cause **preexcitation** of the ventricles. This preexcitation leads to characteristic findings on baseline ECG, including a **shortened PR interval** (often <0.12 seconds), early upslope of the QRS complex (**delta wave**), and a **widened QRS complex**.

Many patients with an accessory conduction pathway can be asymptomatic and are diagnosed only when a WPW pattern is incidentally recognized on ECG. However, some patients will develop symptomatic arrhythmias. **Atrioventricular reentry tachycardia** (AVRT), a type of paroxysmal supraventricular tachycardia, is the most common arrhythmia that occurs with WPW. AVRT results from a rapid **reentrant circuit** that typically travels down the AV node to the ventricles and back up the accessory pathway, with patients often experiencing palpitations and a racing heart.

(Choice A) Except during periods of paroxysmal supraventricular tachycardia, a patient with an accessory conduction pathway should have a normal P wave on ECG.

(Choice C) The S wave on ECG is typically unaffected in patients with an accessory conduction pathway.

(Choices D and E) The ST segment and T wave roughly correspond to the plateau and repolarization phases, respectively, of the ventricular cardiomyocyte action potential. Due to changes in the normal geographic sequence of ventricular depolarization and repolarization as a result of preexcitation, there may be variable ST-segment/T-wave abnormalities. However, these findings are less common than the usual WPW triad of ECG abnormalities and, when present, are nonspecific for diagnosing an accessory conduction pathway.

Educational objective:
Wolff-Parkinson-White syndrome is characterized by symptomatic paroxysmal supraventricular tachycardia (eg, atrioventricular reentrant tachycardia) due to the presence of an accessory conduction pathway. During normal sinus rhythm, the presence of this accessory pathway causes ventricular preexcitation, which can be identified on ECG by the triad of a shortened PR interval, early upslope of the QRS complex (delta wave), and a widened QRS interval.

Pathophysiology	Cardiovascular System	Wolff parkinson white syndrome
Subject	System	Topic

electrical conduction impulses to bypass the atrioventricular node and cause **preexcitation** of the ventricles. This preexcitation leads to characteristic findings on baseline ECG, including a **shortened PR interval** (often <0.12 seconds), early upslope of the QRS complex (**delta wave**), and a **widened QRS complex**.

Many patients with an accessory conduction pathway can be asymptomatic and are diagnosed only when a WPW pattern is incidentally recognized on ECG. However, some patients will develop symptomatic arrhythmias. **Atrioventricular reentry tachycardia** (AVRT), a type of paroxysmal supraventricular tachycardia, is the most common arrhythmia that occurs with WPW. AVRT results from a rapid **reentrant circuit** that typically travels down the AV node to the ventricles and back up the accessory pathway, with patients often experiencing palpitations and a racing heart.

(Choice A) Except during periods of paroxysmal supraventricular tachycardia, a patient with an accessory conduction pathway should have a normal P wave on ECG.

(Choice C) The S wave on ECG is typically unaffected in patients with an accessory conduction pathway.

(Choices D and E) The ST segment and T wave roughly correspond to the plateau and repolarization phases, respectively, of the ventricular cardiomyocyte action potential. Due to changes in the normal geographic sequence of ventricular depolarization and repolarization as a result of preexcitation, there may be variable ST-segment/T-wave abnormalities. However, these findings are less common than the usual WPW triad of ECG abnormalities and, when present, are nonspecific for diagnosing an accessory conduction pathway.

Educational objective:
Wolff-Parkinson-White syndrome is characterized by symptomatic paroxysmal supraventricular tachycardia (eg, atrioventricular reentrant tachycardia) due to the presence of an accessory conduction pathway. During normal sinus rhythm, the presence of this accessory pathway causes ventricular preexcitation, which can be identified on ECG by the triad of a shortened PR interval, early upslope of the QRS complex (delta wave), and a widened QRS interval.

Pathophysiology	Cardiovascular System	Wolff parkinson white syndrome
Subject	System	Topic

Copyright © UWorld. All rights reserved.

1
2
3
4
5
6
7
8
9
10
11
12
13
14
15
16
17
18
19
20
21
22
23
24
25
26
27
28
29
30
31

electrical conduction impulses to bypass the atrioventricular node and cause **preexcitation** of the ventricles. This preexcitation leads to

Exhibit Display

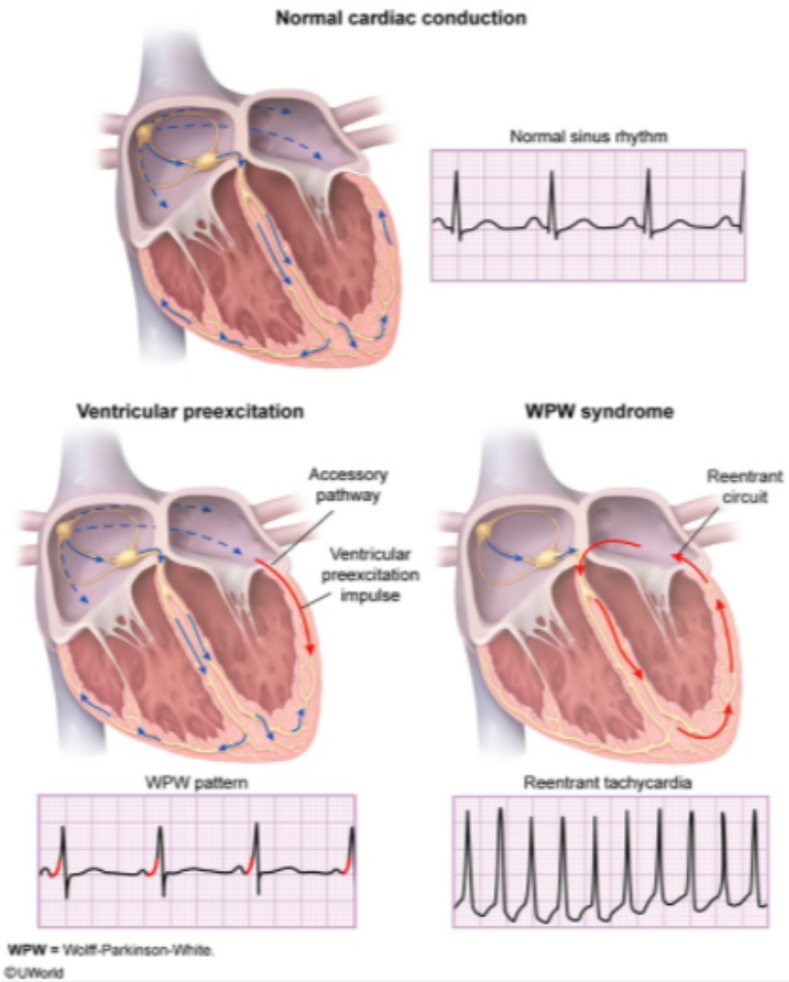

Zoom In | Zoom Out | Reset | Add To New Card | Existing Card

A 54-year-old man comes to the office for evaluation of hypertension. He was diagnosed with hypertension 2 years ago but has had inconsistent follow-up and has not seen a physician in the last 6 months. The patient is not currently taking any medications but feels well and has good exercise tolerance. He has a family history of hypertension and ischemic stroke. His BMI is 26 kg/m^2. Physical examination is unremarkable. Serum creatinine level is normal. The patient is started on valsartan and hydrochlorothiazide, and the following values were measured at baseline (before starting treatment) and after 3 weeks of therapy:

	Blood pressure	Plasma renin activity, morning
Baseline	165/95 mm Hg	2.5 ng/mL per hour (normal: 1-4 ng/mL per hour)
After 3 weeks	162/96 mm Hg	2.4 ng/mL per hour

Which of the following best explains the observed findings in this patient?

A. Low sodium diet
B. Medication noncompliance
C. Obstructive sleep apnea
D. Primary hyperaldosteronism
E. Renal artery stenosis

Submit

A 54-year-old man comes to the office for evaluation of hypertension. He was diagnosed with hypertension 2 years ago but has had inconsistent follow-up and has not seen a physician in the last 6 months. The patient is not currently taking any medications but feels well and has good exercise tolerance. He has a family history of hypertension and ischemic stroke. His BMI is 26 kg/m^2. Physical examination is unremarkable. Serum creatinine level is normal. The patient is started on valsartan and hydrochlorothiazide, and the following values were measured at baseline (before starting treatment) and after 3 weeks of therapy:

	Blood pressure	Plasma renin activity, morning
Baseline	165/95 mm Hg	2.5 ng/mL per hour (normal: 1-4 ng/mL per hour)
After 3 weeks	162/96 mm Hg	2.4 ng/mL per hour

Which of the following best explains the observed findings in this patient?

- A. Low sodium diet (1%)
- ✓ B. Medication noncompliance (67%)
- C. Obstructive sleep apnea (1%)
- D. Primary hyperaldosteronism (10%)
- E. Renal artery stenosis (19%)

Omitted
Correct answer
B

67%
Answered correctly

02 secs
Time Spent

01/07/2020
Last Updated

Explanation

1
2
3
4
5
6
7
8
9
10
11
12
13
14
15
16
17
18
19
20
21
22
23
24
25
26
27
28
29
30
31

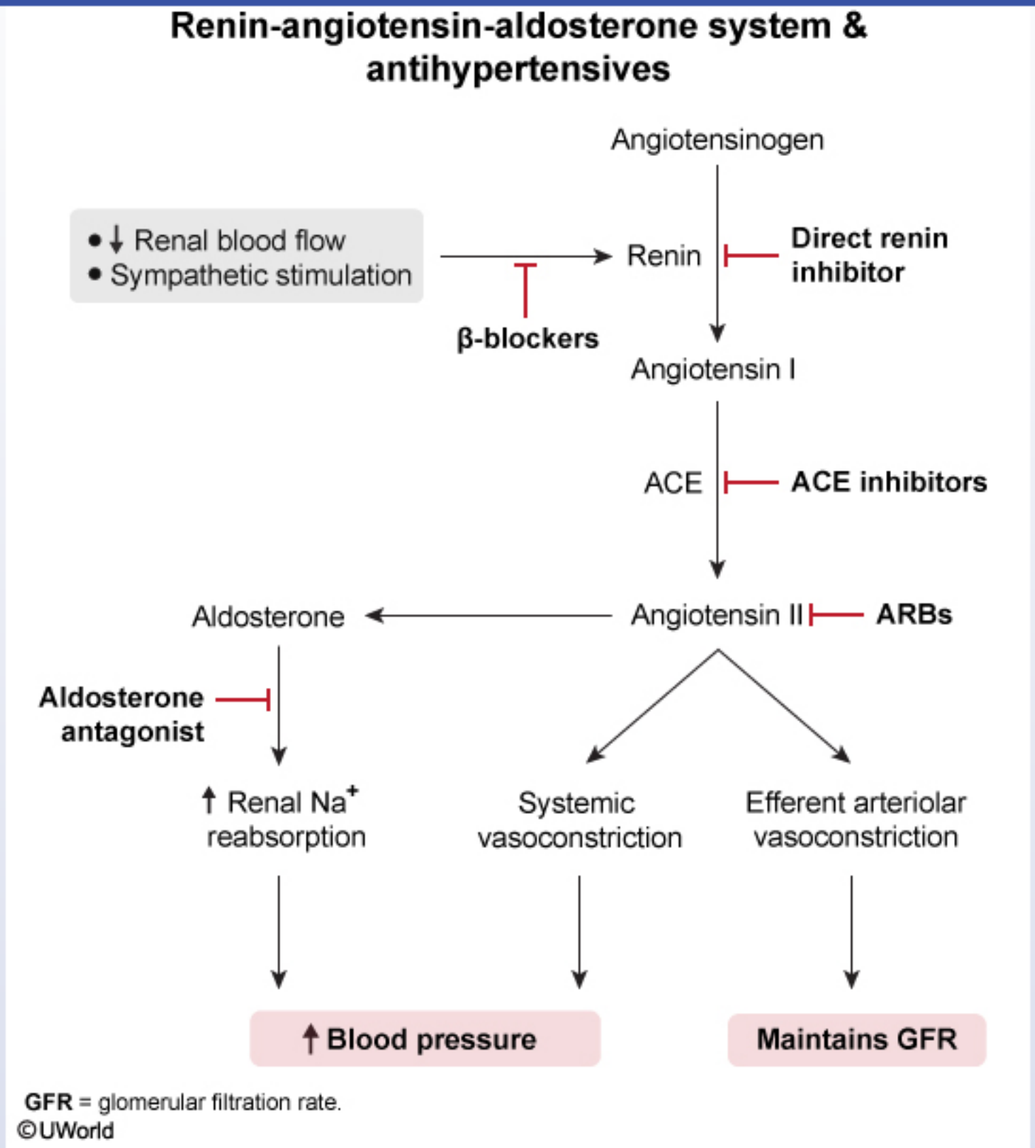

Renin converts angiotensinogen to angiotensin I, which is then converted in the lung to angiotensin II, a potent vasoconstrictor that stimulates

Renin converts angiotensinogen to angiotensin I, which is then converted in the lung to angiotensin II, a potent vasoconstrictor that stimulates aldosterone secretion. **Plasma renin activity** (PRA) is measured as the amount of angiotensin I generated per unit of time and is a useful tool for assessing the function of the renin-angiotensin-aldosterone (RAAS) axis.

ACE inhibitors and angiotensin II receptor antagonists (eg, valsartan) block the RAAS pathway, causing a feedback increase in serum renin levels. **Diuretic-induced hypovolemia** leads to decreased renal blood flow, which also **increases renin** levels and activates RAAS. By contrast, drugs that block sympathetic stimulation (eg, beta blockers and clonidine) reduce renin levels. Because this patient's PRA did not increase after being prescribed valsartan and hydrochlorothiazide, this suggests likely medication noncompliance.

(Choice A) Sodium intake increases intravascular volume, which suppresses renin production by inducing pressure natriuresis and increased distal tubule sodium delivery. In contrast, a low sodium diet usually leads to increased serum renin and aldosterone levels. However, this patient's normal PRA makes a low sodium diet less likely.

(Choice C) Obstructive sleep apnea (OSA) is a secondary cause of hypertension but usually does not directly affect PRA. In addition, this patient does not have the typical findings of OSA (eg, excessive daytime sleepiness, snoring at night, obesity).

(Choice D) Primary hyperaldosteronism causes inappropriately elevated serum aldosterone, which suppresses renin production and would cause low serum renin levels.

(Choice E) Renal artery stenosis decreases the effective arterial volume to the kidney, which can lead to increased PRA, increased aldosterone, and elevated blood pressure. This patient has a normal PRA. In addition, initiation of angiotensin II receptor antagonists often cause a precipitous drop in blood pressure, along with acute kidney injury, in patients with underlying renal artery stenosis.

Educational objective:
Plasma renin activity (PRA) is a measure of the amount of angiotensin I generated per unit of time. It provides a useful assessment of the renin-angiotensin-aldosterone axis. Factors that increase PRA include low sodium intake and antihypertensive medications such as diuretics (eg, hydrochlorothiazide), ACE inhibitors, and angiotensin II receptor blockers (eg, valsartan).

References

- The plasma renin test reveals the contribution of body sodium-volume content (V) and renin-angiotensin (R) vasoconstriction to long-term blood pressure

levels. **Diuretic-induced hypovolemia** leads to decreased renal blood flow, which also **increases renin** levels and activates RAAS. By contrast, drugs that block sympathetic stimulation (eg, beta blockers and clonidine) reduce renin levels. Because this patient's PRA did not increase after being prescribed valsartan and hydrochlorothiazide, this suggests likely medication noncompliance.

(Choice A) Sodium intake increases intravascular volume, which suppresses renin production by inducing pressure natriuresis and increased distal tubule sodium delivery. In contrast, a low sodium diet usually leads to increased serum renin and aldosterone levels. However, this patient's normal PRA makes a low sodium diet less likely.

(Choice C) Obstructive sleep apnea (OSA) is a secondary cause of hypertension but usually does not directly affect PRA. In addition, this patient does not have the typical findings of OSA (eg, excessive daytime sleepiness, snoring at night, obesity).

(Choice D) Primary hyperaldosteronism causes inappropriately elevated serum aldosterone, which suppresses renin production and would cause low serum renin levels.

(Choice E) Renal artery stenosis decreases the effective arterial volume to the kidney, which can lead to increased PRA, increased aldosterone, and elevated blood pressure. This patient has a normal PRA. In addition, initiation of angiotensin II receptor antagonists often cause a precipitous drop in blood pressure, along with acute kidney injury, in patients with underlying renal artery stenosis.

Educational objective:
Plasma renin activity (PRA) is a measure of the amount of angiotensin I generated per unit of time. It provides a useful assessment of the renin-angiotensin-aldosterone axis. Factors that increase PRA include low sodium intake and antihypertensive medications such as diuretics (eg, hydrochlorothiazide), ACE inhibitors, and angiotensin II receptor blockers (eg, valsartan).

References

- The plasma renin test reveals the contribution of body sodium-volume content (V) and renin-angiotensin (R) vasoconstriction to long-term blood pressure

Pathophysiology	Cardiovascular System	Primary hypertension
Subject	System	Topic

Copyright © UWorld. All rights reserved.

A 49-year-old woman comes to the emergency department with a 2-day history of fever, dysuria, and flank pain. The patient has a history of poorly controlled type 2 diabetes mellitus. Temperature is 38.3 C (101 F), blood pressure is 80/44 mm Hg, pulse is 134/min, and respirations are 34/min. On physical examination, the patient appears lethargic, flushed, and diaphoretic. Neck veins are flat. The lungs are clear on auscultation and heart sounds are normal. There is right-sided costovertebral tenderness. Which of the following hemodynamic parameters are most likely to be present in this patient?

	Pulmonary capillary wedge pressure (PCWP)	Cardiac index (CI)	Systemic vascular resistance (SVR)	Mixed venous O2 saturation (SvO2)
A.	↑	↓	↑	↓
B.	↑	↑	↓	↑
C.	↓	↓	↑	↓
D.	↓	↓	↓	↓
E.	↓	↑	↓	↑

Submit

A 49-year-old woman comes to the emergency department with a 2-day history of fever, dysuria, and flank pain. The patient has a history of poorly controlled type 2 diabetes mellitus. Temperature is 38.3 C (101 F), blood pressure is 80/44 mm Hg, pulse is 134/min, and respirations are 34/min. On physical examination, the patient appears lethargic, flushed, and diaphoretic. Neck veins are flat. The lungs are clear on auscultation and heart sounds are normal. There is right-sided costovertebral tenderness. Which of the following hemodynamic parameters are most likely to be present in this patient?

	Pulmonary capillary wedge pressure (PCWP)	Cardiac index (CI)	Systemic vascular resistance (SVR)	Mixed venous O2 saturation (SvO2)
A. (6%)	↑	↓	↑	↓
B. (9%)	↑	↑	↓	↑
C. (17%)	↓	↓	↑	↓
D. (28%)	↓	↓	↓	↓
✓ E. (37%)	↓	↑	↓	↑

Omitted
Correct answer
E

37%
Answered correctly

02 secs
Time Spent

02/04/2020
Last Updated

Explanation

Hemodynamic measurements in shock				
Parameter	**Hypovolemic shock**	**Cardiogenic shock**	**Obstructive shock**	**Distributive shock**
CVP (right-sided preload)	↓	↑	↑	↓
PCWP (left-sided preload)	↓	↑	↓*	↓
Cardiac index (LV output)	↓	↓	↓	↑**
SVR (afterload)	↑	↑	↑	↓
SvO_2	↓	↓	↓	↑**

*In tamponade, left-sided preload is decreased, but measured PCWP is paradoxically increased due to external compression by pericardial fluid.
**Cardiac index and SvO_2 are usually decreased in neurogenic shock due to impaired sympathetic reflexes.
CVP = central venous pressure; **LV** = left ventricular; **PCWP** = pulmonary capillary wedge pressure; **SvO_2** = mixed venous oxygen saturation; **SVR** = systemic vascular resistance.

This patient with fever, dysuria, flank pain, and right costovertebral angle tenderness likely has **pyelonephritis**. In addition, her **hypotension** in the setting of infection suggests **septic shock**. Septic shock is the most common type of distributive shock; other types include anaphylactic

This patient with fever, dysuria, flank pain, and right costovertebral angle tenderness likely has **pyelonephritis**. In addition, her **hypotension** in the setting of infection suggests **septic shock**. Septic shock is the most common type of distributive shock; other types include anaphylactic shock and neurogenic shock.

The primary disturbance in septic shock is **widespread vasodilation** leading to **decreased systemic vascular resistance** (SVR). Increased vascular permeability (third-spacing) and peripheral venous dilation also cause a reduction in central venous pressure and pulmonary capillary wedge pressure (PCWP) **(Choice B)**. Initially, the hypotension and inflammation from sepsis trigger a compensatory increase in sympathetic drive that increases heart rate and myocardial contractility, leading to **increased cardiac index** (cardiac output per body surface area). The high blood flow rates prevent complete extraction of oxygen by the tissues, resulting in **high mixed venous oxygen saturation**. As shock progresses, tissue ischemia and accumulation of cytotoxic mediators eventually cause a reduction in cardiac output with end-organ dysfunction.

(Choice A) Low cardiac index with high PCWP is consistent with cardiogenic shock. The primary disturbance is typically left ventricular failure with a compensatory increase in SVR in an effort to maintain adequate blood pressure for organ perfusion.

(Choice C) Low PCWP with low cardiac index and high SVR occurs in both hypovolemic shock and some types of obstructive shock (eg, pulmonary embolism, tension pneumothorax). Central venous pressure is low in hypovolemic shock and high in obstructive shock.

(Choice D) Low PCWP with low cardiac index and low SVR occurs in neurogenic shock. As in sepsis, the primary disturbance is peripheral vasodilation. However, due to nerve injury there is no sympathetic-mediated increase in heart rate and myocardial contractility; therefore, cardiac output is low. These parameters are also seen in the late stages of septic shock; however, this patient's flushing is consistent with the high cardiac output seen in early septic shock.

Educational objective:
Septic shock causes widespread arteriolar vasodilation, which leads to a decrease in systemic vascular resistance and a compensatory increase in cardiac output. Central venous pressure and pulmonary capillary wedge pressure are also decreased due to pooling of blood in the dilated veins. Increased flow rates through the peripheral capillaries lead to incomplete oxygen extraction by the tissues and high mixed venous oxygen saturation.

References

- Circulatory shock.

shock and neurogenic shock.

The primary disturbance in septic shock is **widespread vasodilation** leading to **decreased systemic vascular resistance** (SVR). Increased vascular permeability (third-spacing) and peripheral venous dilation also cause a reduction in central venous pressure and pulmonary capillary wedge pressure (PCWP) **(Choice B)**. Initially, the hypotension and inflammation from sepsis trigger a compensatory increase in sympathetic drive that increases heart rate and myocardial contractility, leading to **increased cardiac index** (cardiac output per body surface area). The high blood flow rates prevent complete extraction of oxygen by the tissues, resulting in **high mixed venous oxygen saturation**. As shock progresses, tissue ischemia and accumulation of cytotoxic mediators eventually cause a reduction in cardiac output with end-organ dysfunction.

(Choice A) Low cardiac index with high PCWP is consistent with cardiogenic shock. The primary disturbance is typically left ventricular failure with a compensatory increase in SVR in an effort to maintain adequate blood pressure for organ perfusion.

(Choice C) Low PCWP with low cardiac index and high SVR occurs in both hypovolemic shock and some types of obstructive shock (eg, pulmonary embolism, tension pneumothorax). Central venous pressure is low in hypovolemic shock and high in obstructive shock.

(Choice D) Low PCWP with low cardiac index and low SVR occurs in neurogenic shock. As in sepsis, the primary disturbance is peripheral vasodilation. However, due to nerve injury there is no sympathetic-mediated increase in heart rate and myocardial contractility; therefore, cardiac output is low. These parameters are also seen in the late stages of septic shock; however, this patient's flushing is consistent with the high cardiac output seen in early septic shock.

Educational objective:
Septic shock causes widespread arteriolar vasodilation, which leads to a decrease in systemic vascular resistance and a compensatory increase in cardiac output. Central venous pressure and pulmonary capillary wedge pressure are also decreased due to pooling of blood in the dilated veins. Increased flow rates through the peripheral capillaries lead to incomplete oxygen extraction by the tissues and high mixed venous oxygen saturation.

References

- Circulatory shock.

Pathophysiology	Cardiovascular System	Sepsis
Subject	System	Topic

This item has associated media that may require the use of headphones. Please ensure your system/speaker volume is set to an audible level.

A 71-year-old man comes to the office with a 2-month history of progressive exertional dyspnea. The patient is unable to walk half a block without resting and can no longer climb stairs without stopping every few steps. He also has had difficulty sleeping due to repeatedly waking up at night feeling like he is suffocating. Physical examination shows bilateral lower extremity edema and distended neck veins. Cardiac auscultation findings over the apex are given below. This patient's auscultatory findings most likely reflect which of the following?

Play Media

A. Aortic valve sclerosis
B. Bulging of the interventricular septum
C. Dynamic left ventricular outflow obstruction
D. Elevated pulmonary arterial pressure
E. Increased left ventricular end-systolic volume

Submit

This item has associated media that may require the use of headphones. Please ensure your system/speaker volume is set to an audible level.

A 71-year-old man comes to the office with a 2-month history of progressive exertional dyspnea. The patient is unable to walk half a block without resting and can no longer climb stairs without stopping every few steps. He also has had difficulty sleeping due to repeatedly waking up at night feeling like he is suffocating. Physical examination shows bilateral lower extremity edema and distended neck veins. Cardiac auscultation findings over the apex are given below. This patient's auscultatory findings most likely reflect which of the following?

Play Media

A. Aortic valve sclerosis (13%)

B. Bulging of the interventricular septum (5%)

C. Dynamic left ventricular outflow obstruction (10%)

D. Elevated pulmonary arterial pressure (27%)

✓ E. Increased left ventricular end-systolic volume (43%)

Omitted
Correct answer
E

43%
Answered correctly

03 secs
Time Spent

03/22/2020
Last Updated

Explanation

Gallop heart sounds

Gallop heart sounds

	Features	Normal	Abnormal/associated conditions
Third heart sound (S3)	• Ventricular gallop sound (after S2) • Heard during rapid **passive filling** of ventricles in diastole • Sudden cessation of filling as ventricle reaches its elastic limit	• Age <40 • Pregnancy	• Systolic heart failure • Mitral regurgitation • High-output states
Fourth heart sound (S4)	• Atrial gallop sound (before S1) • Heard immediately after **atrial contraction** as blood is forced into a stiff ventricle	• Healthy **older** adults	• Younger adults, children • Diastolic dysfunction (eg, LVH)

LVH = left ventricular hypertrophy.

Cardiac auscultation in this patient reveals a **low-frequency** sound occurring **after S2**, known as the **third heart sound (S3)**. Although the S3 can be normal in young individuals and pregnant patients, its presence in those age >40 is typically a sign of left ventricular (LV) **volume overload/failure** (causing exertional dyspnea and paroxysmal nocturnal dyspnea in this patient).

In early diastole, the ventricles relax and the atrioventricular valves open, allowing blood to rush in and fill the ventricles. An S3 develops with **forceful rapid passive filling** that exceeds the expansion capacity of the ventricle, leading to sudden deceleration of the entering blood column and reverberation of the ventricular walls. As a result, S3 is often heard in pathologic settings causing high ventricular filling pressures and/or volume overload, particularly aortic or mitral regurgitation and dilated cardiomyopathy.

(Choice A) Aortic valve sclerosis may produce a midsystolic ejection murmur but would not produce an extra heart sound. Progression to severe aortic stenosis may eventually produce an S3 indicative of LV systolic failure.

(Choice B) In cardiac tamponade, accumulation of large quantities of pericardial fluid prevents the expansion of the ventricular free walls. During inspiration, venous blood return increases and the intraventricular septum bulges into the left ventricle to allow the right ventricle to accommodate the increased blood volume. The resultant decrease in LV filling volume causes pulsus paradoxus (>10 mm Hg decrease in systolic blood pressure during inspiration).

LVH = left ventricular hypertrophy.

Cardiac auscultation in this patient reveals a **low-frequency** sound occurring **after S2**, known as the **third heart sound (S3)**. Although the S3 can be normal in young individuals and pregnant patients, its presence in those age >40 is typically a sign of left ventricular (LV) **volume overload/failure** (causing exertional dyspnea and paroxysmal nocturnal dyspnea in this patient).

In early diastole, the ventricles relax and the atrioventricular valves open, allowing blood to rush in and fill the ventricles. An S3 develops with **forceful rapid passive filling** that exceeds the expansion capacity of the ventricle, leading to sudden deceleration of the entering blood column and reverberation of the ventricular walls. As a result, S3 is often heard in pathologic settings causing high ventricular filling pressures and/or volume overload, particularly aortic or mitral regurgitation and dilated cardiomyopathy.

(Choice A) Aortic valve sclerosis may produce a midsystolic ejection murmur but would not produce an extra heart sound. Progression to severe aortic stenosis may eventually produce an S3 indicative of LV systolic failure.

(Choice B) In cardiac tamponade, accumulation of large quantities of pericardial fluid prevents the expansion of the ventricular free walls. During inspiration, venous blood return increases and the intraventricular septum bulges into the left ventricle to allow the right ventricle to accommodate the increased blood volume. The resultant decrease in LV filling volume causes pulsus paradoxus (>10 mm Hg decrease in systolic blood pressure during inspiration).

(Choice C) Hypertrophic cardiomyopathy can cause dynamic LV outflow obstruction, producing a crescendo-decrescendo ejection systolic murmur. The outflow obstruction can also cause systolic anterior motion of the mitral valve, resulting in mitral regurgitation (holosystolic murmur).

(Choice D) Elevated pulmonary arterial pressure (pulmonary hypertension) can present with exertional dyspnea and fatigue and eventual right ventricular failure (elevated jugular venous pressure, peripheral edema). However, auscultation will show increased intensity of the pulmonic closure sound (P2), and affected patients typically lack nocturnal dyspnea due to intact LV function.

Educational objective:
The third heart sound (S3) is a low-frequency sound occurring immediately after S2 that is commonly associated with increased ventricular end-systolic volume. S3 frequently occurs in the setting of mitral regurgitation and systolic heart failure (eg, dilated cardiomyopathy).

Pathophysiology	Cardiovascular System	Chronic heart failure
Subject	System	Topic

This item has associated media that may require the use of headphones. Please ensure your system/speaker volume is set to an audible level.

A 12-month-old boy is brought to the pediatrician by his parents for an upper respiratory infection. His temperature is 38.3 C (101 F), blood pressure is 92/45 mm Hg, pulse is 110/min, and respirations are 25/min. Physical examination reveals erythema and swelling of the nasal mucosa and nasal discharge. Cardiac auscultation findings at the left sternal border are given below. The remainder of the examination is unremarkable. Which of the following is the most likely diagnosis?

Play Media

A. Aortic aneurysm
B. Aortic coarctation
C. Atrial septal defect
D. Mitral valve prolapse
E. Patent ductus arteriosus

Submit

This item has associated media that may require the use of headphones. Please ensure your system/speaker volume is set to an audible level.

A 12-month-old boy is brought to the pediatrician by his parents for an upper respiratory infection. His temperature is 38.3 C (101 F), blood pressure is 92/45 mm Hg, pulse is 110/min, and respirations are 25/min. Physical examination reveals erythema and swelling of the nasal mucosa and nasal discharge. Cardiac auscultation findings at the left sternal border are given below. The remainder of the examination is unremarkable. Which of the following is the most likely diagnosis?

Play Media

A. Aortic aneurysm (1%)
B. Aortic coarctation (3%)
C. Atrial septal defect (25%)
D. Mitral valve prolapse (19%)
✓ E. Patent ductus arteriosus (50%)

Omitted
Correct answer
E

50%
Answered correctly

02 secs
Time Spent

02/25/2020
Last Updated

Explanation

The audio recording reveals a continuous murmur along with inspiratory splitting of S2. The key characteristic of this patient's murmur is its continuous nature, which is classic for patent ductus arteriosus (PDA). The symptoms caused by a PDA are quite variable depending on its length

Explanation

The audio recording reveals a continuous murmur along with inspiratory splitting of S2. The key characteristic of this patient's murmur is its continuous nature, which is classic for patent ductus arteriosus (PDA). The symptoms caused by a PDA are quite variable depending on its length and size, both of which relate to the degree of left-to-right shunting. Because this patient's PDA was detected incidentally, he most likely has a small PDA. Diagnosis of small PDAs is often suspected on routine auscultation and confirmed with echocardiography. PDA is associated with a continuous murmur heard best in the left infraclavicular region with maximal intensity at S2. Patients at greatest risk of PDA are those born prematurely and those with cyanotic congenital heart disease.

(Choice A) An ascending aortic aneurysm is often associated with aortic regurgitation, which would result in an early diastolic murmur as opposed to a continuous murmur.

(Choice B) Coarctation of the aorta can be associated with a continuous murmur due to large collateral vessels, but this would be much less common than a PDA. In addition, other characteristics of aortic coarctation, such as differing blood pressure or pulse delay between the upper and lower extremities, would likely be evident on physical examination.

(Choice C) A small atrial septal defect can cause a continuous murmur in rare instances, and typically does so only when associated with mitral valve obstruction due to an elevated pressure gradient across the atria (Lutembacher syndrome). This would be much less common than a PDA.

(Choice D) Mitral valve prolapse classically results in a midsystolic click and a mid-to-late systolic murmur.

Educational objective:
Patent ductus arteriosus (PDA) is characterized by a continuous murmur heard best in the left infraclavicular region with maximal intensity at S2. A small PDA is often asymptomatic and is usually detected incidentally during routine cardiac auscultation. It occurs most commonly in patients born prematurely and those with cyanotic congenital heart disease.

Pathophysiology	Cardiovascular System	Patent ductus arteriosus
Subject	System	Topic

Copyright © UWorld. All rights reserved.

1
2
3
4
5
6
7
8
9
10
11
12
13
14
15
16
17
18
19
20
21
22
23
24
25
26
27
28
29
30
31

This item has associated media that may require the use of headphones. Please ensure your system/speaker volume is set to an audible level.

A 54-year-old Caucasian male complains of "dizzy spells" when walking his dog in the morning. He denies any chest pain, shortness of breath, weakness, or headaches. Cardiac auscultation findings at the right sternal border are given below. Which of the following is the most likely cause of this patient's symptoms?

Play Media

A. Bicuspid aortic valve
B. Infective endocarditis
C. Marfan syndrome
D. Mitral valve prolapse
E. Ventricular septal defect

Submit

This item has associated media that may require the use of headphones. Please ensure your system/speaker volume is set to an audible level.

A 54-year-old Caucasian male complains of "dizzy spells" when walking his dog in the morning. He denies any chest pain, shortness of breath, weakness, or headaches. Cardiac auscultation findings at the right sternal border are given below. Which of the following is the most likely cause of this patient's symptoms?

Play Media

- ✓ A. Bicuspid aortic valve (69%)
- B. Infective endocarditis (5%)
- C. Marfan syndrome (2%)
- D. Mitral valve prolapse (12%)
- E. Ventricular septal defect (9%)

Omitted
Correct answer
A

69%
Answered correctly

01 sec
Time Spent

06/24/2020
Last Updated

Explanation

The cardiac auscultation findings in this patient demonstrate a harsh, crescendo-decrescendo systolic ejection murmur at the right sternal border, which are classic for aortic stenosis. Patients with aortic stenosis typically remain asymptomatic for a prolonged period of time. In more advanced cases, symptoms usually first present with exertion and can include syncope, dizziness, angina, or heart failure.

Explanation

The cardiac auscultation findings in this patient demonstrate a harsh, crescendo-decrescendo systolic ejection murmur at the right sternal border, which are classic for aortic stenosis. Patients with aortic stenosis typically remain asymptomatic for a prolonged period of time. In more advanced cases, symptoms usually first present with exertion and can include syncope, dizziness, angina, or heart failure.

The three major causes of valvular aortic stenosis are a congenitally abnormal valve with calcification (e.g. bicuspid valve), a calcified normal valve, or rheumatic heart disease. Although rheumatic heart disease is the most common cause worldwide, calcific aortic valve disease (in either a bicuspid or tricuspid valve) is more common in the United States.

(Choice B) Although infective endocarditis can produce a heart murmur, involvement of the aortic valve is much less common than the other valves because of the relatively high blood flow. In addition, this patient does not have other clinical features suggestive of infective endocarditis (i.e. fever).

(Choice C) Marfan syndrome is associated with aortic root disease, which results in aneurysmal dilatation, aortic regurgitation, and aortic dissection. Aortic regurgitation would cause a diastolic murmur, not systolic.

(Choice D) Mitral valve prolapse produces a mid-systolic click and a late systolic murmur heard best over the cardiac apex, as opposed to the crescendo-decrescendo murmur in this case.

(Choice E) A holosystolic murmur is typically heard in patients with a ventricular septal defect, which can be differentiated from this patient's crescendo-decrescendo murmur.

Educational objective:
A bicuspid aortic valve is a common cause of aortic stenosis in the United States. The classic auscultatory finding in patients with aortic stenosis is a harsh, crescendo-decrescendo systolic ejection murmur heard best in the right second intercostal space with radiation to the carotids.

Pathophysiology	Cardiovascular System	Aortic stenosis
Subject	System	Topic

Copyright © UWorld. All rights reserved.

A 4-month-old boy is brought to the cardiology clinic by his parents for continued follow-up of tetralogy of Fallot. The diagnosis was made during routine antenatal sonography, and the pregnancy and delivery were otherwise uncomplicated. The infant has been seen frequently in the clinic and has not had any cyanosis, respiratory distress, or difficulty feeding. The parents become concerned when their son's surgical plan is discussed because he does not have the clinical signs that other children with tetralogy of Fallot demonstrate. Which of the following is the major determinant of symptom severity in this condition?

- A. Aortic valve insufficiency
- B. Associated pulmonary malformations
- C. Right ventricular outflow tract obstruction
- D. Tricuspid valve insufficiency
- E. Ventricular septal defect

Submit

A 4-month-old boy is brought to the cardiology clinic by his parents for continued follow-up of tetralogy of Fallot. The diagnosis was made during routine antenatal sonography, and the pregnancy and delivery were otherwise uncomplicated. The infant has been seen frequently in the clinic and has not had any cyanosis, respiratory distress, or difficulty feeding. The parents become concerned when their son's surgical plan is discussed because he does not have the clinical signs that other children with tetralogy of Fallot demonstrate. Which of the following is the major determinant of symptom severity in this condition?

- A. Aortic valve insufficiency (2%)
- B. Associated pulmonary malformations (8%)
- ✓ C. Right ventricular outflow tract obstruction (70%)
- D. Tricuspid valve insufficiency (0%)
- E. Ventricular septal defect (17%)

Omitted
Correct answer
C

70%
Answered correctly

01 sec
Time Spent

02/09/2020
Last Updated

Explanation

1
2
3
4
5
6
7
8
9
10
11
12
13
14
15
16
17
18
19
20
21
22
23
24
25
26
27
28
29
30
31

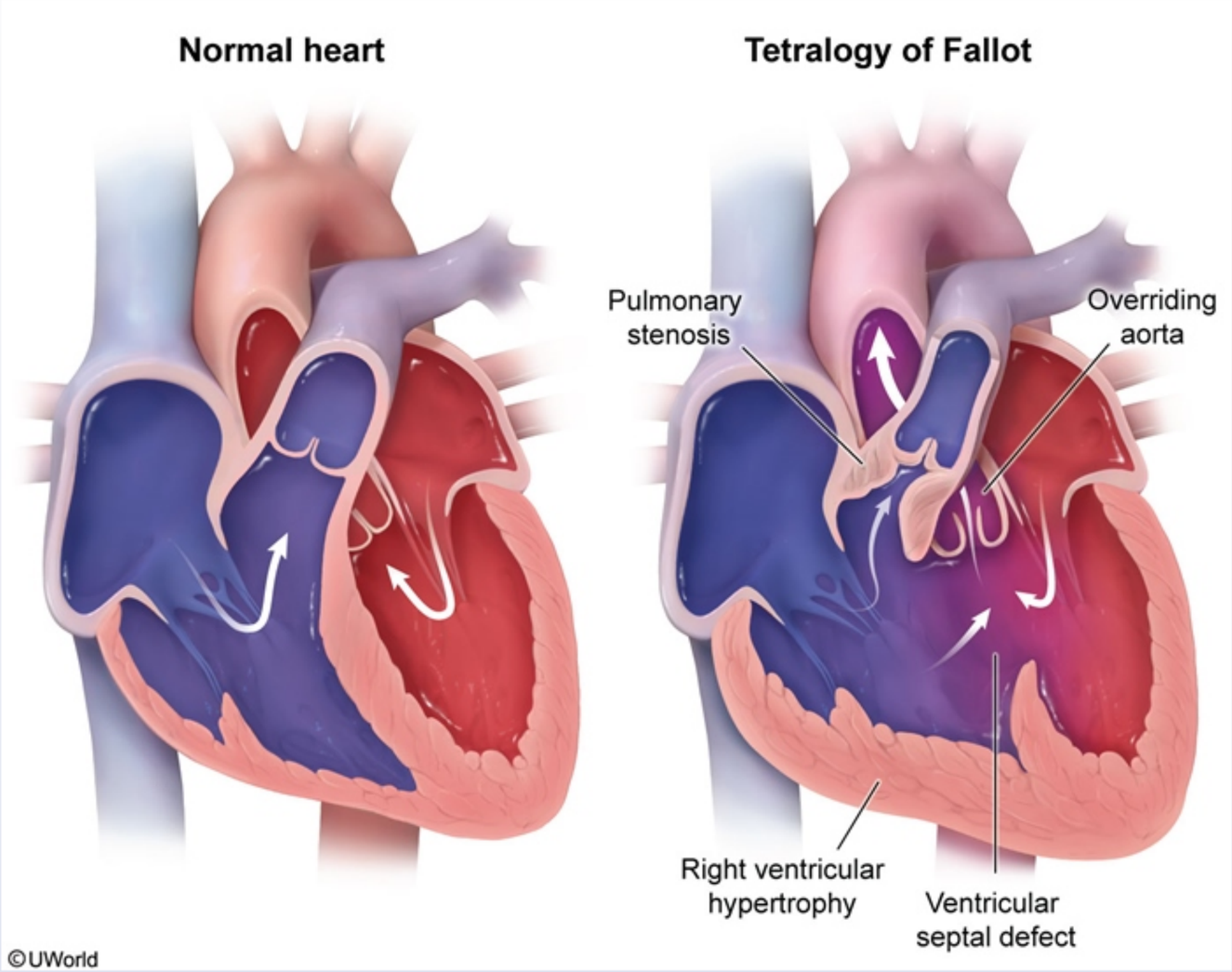

Tetralogy of Fallot (TOF) is characterized by ventricular septal defect (VSD), overriding aorta, right ventricular outflow tract (RVOT) obstruction, and right ventricular hypertrophy. The VSD generally is large, which allows for equal pressure in the right and left ventricles. Therefore, it is the amount of **RVOT obstruction** that determines how much deoxygenated blood is delivered to the systemic circulation. Infants with significant

1
2
3
4
5
6
7
8
9
10
11
12
13
14
15
16
17
18
19
20
21
22
23
24
25
26
27
28
29
30
31

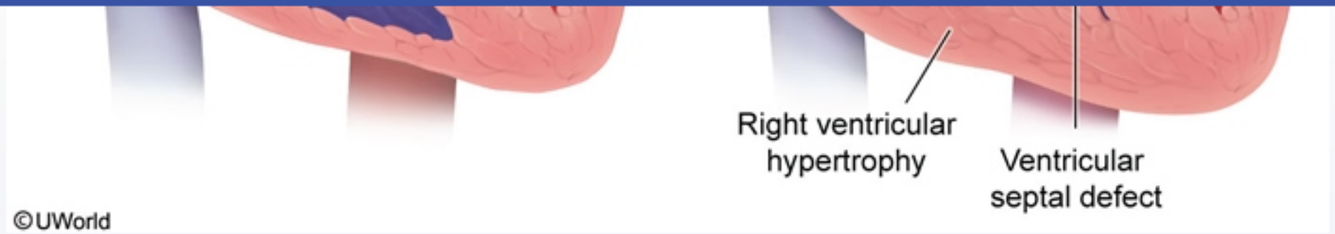

Tetralogy of Fallot (TOF) is characterized by ventricular septal defect (VSD), overriding aorta, right ventricular outflow tract (RVOT) obstruction, and right ventricular hypertrophy. The VSD generally is large, which allows for equal pressure in the right and left ventricles. Therefore, it is the amount of **RVOT obstruction** that determines how much deoxygenated blood is delivered to the systemic circulation. Infants with significant RVOT obstruction shunt more deoxygenated blood across the VSD to the aorta and are more cyanotic. Infants with no or minimal RVOT obstruction, such as this patient, deliver more deoxygenated blood to the lungs and appear acyanotic. The degree of RVOT obstruction is **dynamic** and can increase suddenly, leading to profound cyanosis ("tet spells"). These can be caused by dehydration or hyperventilation but are usually idiopathic.

(Choices A and D) Although the pulmonary valve is usually small and stenotic in TOF (contributes to RVOT obstruction), involvement of the aortic or tricuspid valves is unusual.

(Choice B) Less than 25% of patients with TOF have extracardiac malformations. The most common associated syndromes include Down, Alagille, and DiGeorge. Pulmonary malformations are extremely rare.

(Choice E) A VSD is universally present in TOF. The VSD invariably is large and does not determine the degree of cyanosis.

Educational objective:
In patients with Tetralogy of Fallot, the degree of right ventricular outflow tract obstruction is the major determinant of the degree of right-to-left intracardiac shunting and resulting cyanosis.

Pathophysiology	Cardiovascular System	Tetralogy of fallot
Subject	System	Topic

Copyright © UWorld. All rights reserved.

The following vignette applies to the next **2** items. The items in the set must be answered in sequential order. Once you click **Proceed to Next Item**, you will not be able to add or change an answer.

A 67-year-old man comes to the emergency department due to progressive shortness of breath and chest tightness. He has had no lightheadedness or syncope. The patient takes lisinopril for hypertension and metformin for type 2 diabetes mellitus. He has smoked a pack of cigarettes daily for the last 40 years. The blood pressure cuff is inflated to 140 mm Hg and the pressure is released very slowly. At 120 mm Hg, intermittent Korotkoff sounds are heard only during expiration. At 100 mm Hg, Korotkoff sounds are heard throughout the respiratory cycle.

Item 1 of 2

This physical examination finding can be seen in which of the following conditions?

A. Aortic valve disease
B. Mitral valve disease
C. Myocardial ischemia
D. Pericardial disease
E. Peripheral vascular disease

Submit

The following vignette applies to the next **2** items. The items in the set must be answered in sequential order. Once you click **Proceed to Next Item**, you will not be able to add or change an answer.

A 67-year-old man comes to the emergency department due to progressive shortness of breath and chest tightness. He has had no lightheadedness or syncope. The patient takes lisinopril for hypertension and metformin for type 2 diabetes mellitus. He has smoked a pack of cigarettes daily for the last 40 years. The blood pressure cuff is inflated to 140 mm Hg and the pressure is released very slowly. At 120 mm Hg, intermittent Korotkoff sounds are heard only during expiration. At 100 mm Hg, Korotkoff sounds are heard throughout the respiratory cycle.

Item 1 of 2

This physical examination finding can be seen in which of the following conditions?

- A. Aortic valve disease (24%)
- B. Mitral valve disease (9%)
- C. Myocardial ischemia (5%)
- ✓ D. Pericardial disease (44%)
- E. Peripheral vascular disease (15%)

Omitted
Correct answer
D

44%
Answered correctly

02 secs
Time Spent

05/10/2020
Last Updated

Explanation

Explanation

Systemic arterial pressure normally falls by <10 mm Hg during normal inspiration. Pulsus paradoxus refers to an exaggerated drop (**>10 mm Hg**) in systolic blood pressure during **inspiration**. It is detected by inflating a blood pressure cuff above systolic pressure and gradually deflating it. The difference between the systolic pressure at which Korotkoff sounds first become audible during expiration and the pressure at which they are heard throughout all phases of respiration quantifies pulsus paradoxus (20 mm Hg in this patient).

Inspiration causes an increase in systemic venous return, resulting in increased right heart volumes. Under normal conditions, this results in expansion of the right ventricle into the pericardial space with little impact on the left side of the heart. However, in conditions that impair expansion into the pericardial space (eg, acute cardiac tamponade), the increased right ventricular volume occurring with inspiration leads to **bowing of the interventricular septum** toward the left ventricle. This leads to a decrease in left ventricular (LV) end-diastolic volume and stroke volume, with a resultant decrease in systolic pressure during inspiration.

(Choice A) Fixed LV outflow tract obstruction (eg, valvular aortic stenosis) can cause pulsus parvus et tardus, which is palpable as a slow-rising, low-amplitude pulse due to diminished stroke volume (pulsus parvus) and prolonged LV ejection time (pulsus tardus).

(Choice B) Patients with chronic severe mitral regurgitation have a bounding pulse with a brisk upstroke due to increased LV ejection volumes. Arterial pulses are overall reduced in amplitude in patients with mitral stenosis due to reduced stroke volume.

(Choice C) Myocardial ischemia or infarction can lead to decreased systemic blood pressure or hypotension due to reduced cardiac output, but it would not be expected to cause pulsus paradoxus.

(Choice E) Peripheral vascular disease causes decreased pulse amplitude within the affected extremities. This is most commonly observed in the lower extremities, which will have diminished or absent distal pulses caused by widespread peripheral arterial disease.

Educational objective:
Pulsus paradoxus is defined by a decrease in systolic blood pressure of >10 mm Hg with inspiration. It is most commonly seen in patients with cardiac tamponade but can also occur in severe asthma, chronic obstructive pulmonary disease, and constrictive pericarditis.

References

- Pulsus paradoxus.

Explanation

Exhibit Display

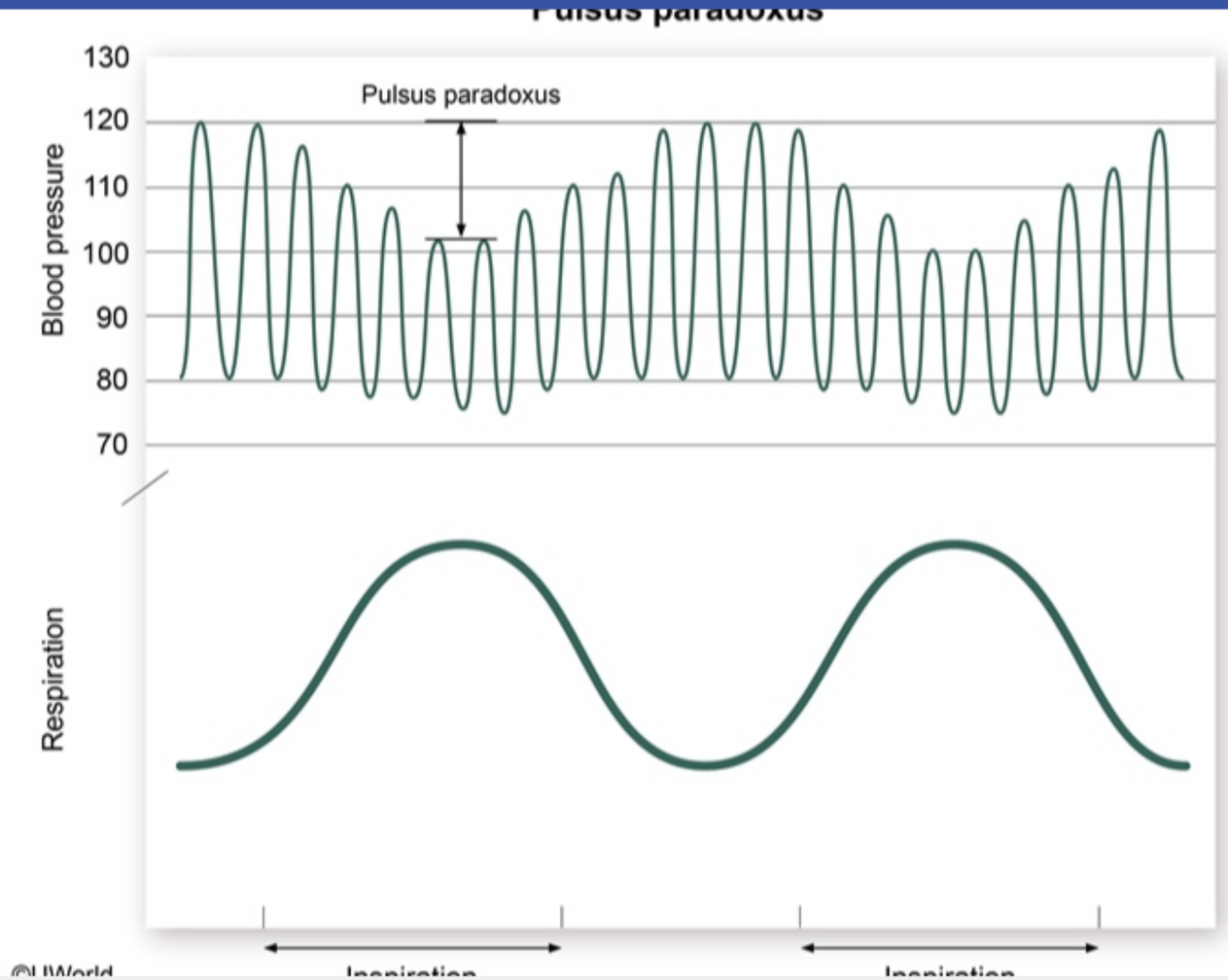

Zoom In | Zoom Out | Reset | Add To New Card | Existing Card

Explanation

Exhibit Display

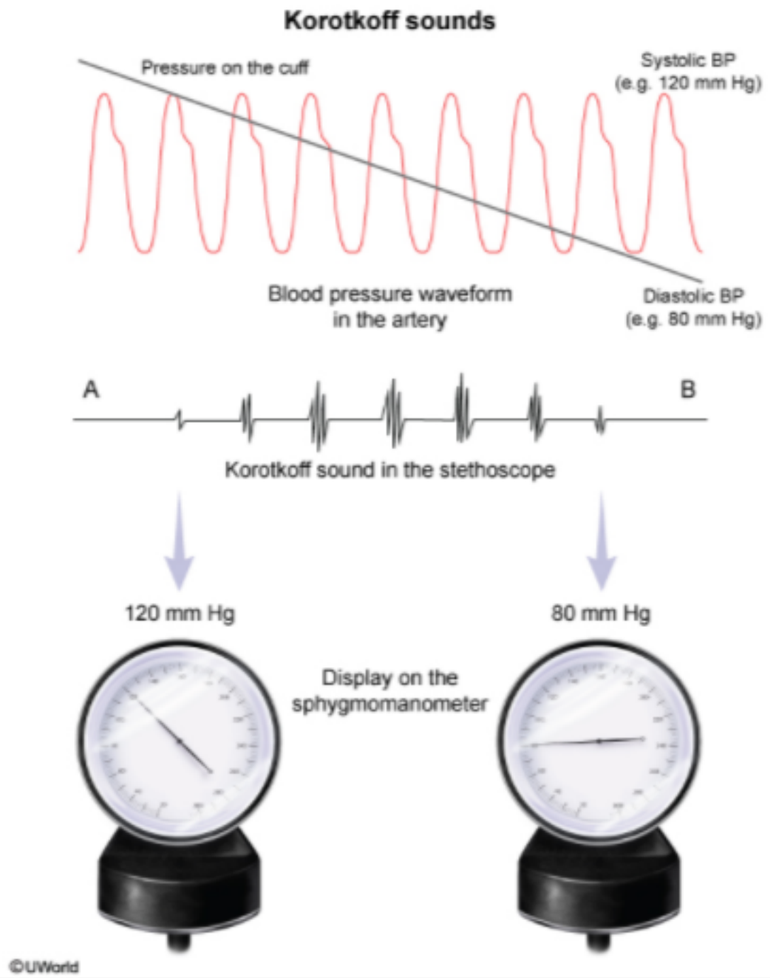

Zoom In | Zoom Out | Reset | Add To New Card | Existing Card

1
2
3
4
5
6
7
8
9
10
11
12
13
14
15
16
17
18
19
20
21
22
23
24
25
26
27
28
29
30
31

Item 2 of 2

The patient is tachypneic and unable to speak in full sentences. Examination reveals prolonged expiration and prominent bilateral wheezing. Heart sounds are normal. Chest imaging shows a normal-sized heart and hyperinflated lungs with a flattened diaphragm. Bedside echocardiogram reveals no intrapericardial fluid accumulation or pericardial thickening. Which of the following physiologic changes is most likely to provide immediate relief in this patient?

A. cAMP accumulation in smooth muscle cells

B. Cell membrane stabilization of mast cells

C. Inhibition of eosinophil degranulation

D. Interrupted histamine receptor firing in epithelial cells

E. Opening of calcium channels in smooth muscle cells

Submit

Item 2 of 2

The patient is tachypneic and unable to speak in full sentences. Examination reveals prolonged expiration and prominent bilateral wheezing. Heart sounds are normal. Chest imaging shows a normal-sized heart and hyperinflated lungs with a flattened diaphragm. Bedside echocardiogram reveals no intrapericardial fluid accumulation or pericardial thickening. Which of the following physiologic changes is most likely to provide immediate relief in this patient?

- ✓ A. cAMP accumulation in smooth muscle cells (57%)
- B. Cell membrane stabilization of mast cells (10%)
- C. Inhibition of eosinophil degranulation (7%)
- D. Interrupted histamine receptor firing in epithelial cells (9%)
- E. Opening of calcium channels in smooth muscle cells (15%)

Omitted
Correct answer
A

57%
Answered correctly

02 secs
Time Spent

05/10/2020
Last Updated

Explanation

This patient's presentation with dyspnea, tachypnea, prolonged expiration, and bilateral wheezing is suggestive of acute exacerbation of **obstructive pulmonary disease** (asthma or COPD). Acute obstructive pulmonary exacerbations are primarily treated with **beta-adrenergic agonists**, which produce relaxation of bronchial smooth muscle by stimulating the beta-2-adrenergic receptor. This receptor is a G_S protein-coupled receptor that activates adenylyl cyclase and **increases intracellular cAMP** concentrations.

Asthma and COPD exacerbation are the most frequent causes of pulsus paradoxus in the absence of significant pericardial disease (pericardial

Explanation

This patient's presentation with dyspnea, tachypnea, prolonged expiration, and bilateral wheezing is suggestive of acute exacerbation of **obstructive pulmonary disease** (asthma or COPD). Acute obstructive pulmonary exacerbations are primarily treated with **beta-adrenergic agonists**, which produce relaxation of bronchial smooth muscle by stimulating the beta-2-adrenergic receptor. This receptor is a G_S protein-coupled receptor that activates adenylyl cyclase and **increases intracellular cAMP** concentrations.

Asthma and COPD exacerbation are the most frequent causes of pulsus paradoxus in the absence of significant pericardial disease (pericardial effusion or constrictive pericarditis). There is a small normal variation in intrathoracic pressure with respiration, which drops 2-5 mm Hg below the atmospheric pressure during inspiration. In patients with severe asthma or COPD exacerbation, this drop in intrathoracic pressure becomes greatly exaggerated and is transmitted to extrathoracic structures. This leads to an excessive drop in blood pressure with inspiration that is detected as pulsus paradoxus.

(Choice B) Cromolyn sodium inhibits mast cell degranulation and release of histamine and leukotrienes. It is used occasionally for management of chronic asthma but is not effective for immediate relief of acute asthmatic or COPD exacerbations.

(Choice C) Eosinophil degranulation would be impaired by corticosteroids, which play an important role in treatment of acute asthma or COPD exacerbations. However, beta agonists provide immediate relief, whereas corticosteroids would take several hours to a few days to take effect.

(Choice D) Histamine is one of several mediators released in response to a hypersensitivity reaction that can lead to bronchial smooth muscle contraction. However, antihistamine therapy is not an effective treatment for asthma or COPD exacerbation.

(Choice E) Calcium channel agonists are not used in acute treatment of asthma or COPD exacerbation. On the contrary, increased calcium influx could potentially worsen bronchial smooth muscle contraction.

Educational objective:
Asthma and chronic obstructive pulmonary disease (COPD) exacerbation are the most frequent causes of pulsus paradoxus in the absence of significant pericardial disease. Beta-adrenergic agonists control acute asthma and COPD exacerbations by causing bronchial smooth muscle relaxation via increased intracellular cAMP.

References

- Effects of antihistamines in adult asthma: a meta-analysis of clinical trials.

1
2
3
4
5
6
7
8
9
10
11
12
13
14
15
16
17
18
19
20
21
22
23
24
25
26
27
28
29
30
31

A 73-year-old man is evaluated for exertional dyspnea. His exercise tolerance has decreased over the last year, and he can barely walk 2-3 blocks without stopping. The patient also reports occasional episodes of lightheadedness and palpitations. He has had no chest pain or syncope. He was diagnosed with hypertension in the past but does not take any medications. Physical examination reveals a cardiac murmur. The patient is referred to a cardiologist for further evaluation. Cardiac catheterization is performed, and the findings are shown in the image below. Which of the following points most likely corresponds to the peak murmur intensity in this patient?

A. A
B. B
C. C
D. D
E. E

Submit

1 2 3 4 5 6 7 8 9 10 11 12 13 14 15 16 17 18 19 20 21 22 23 24 25 26 27 28 29 30 31

A 73-year-old man is evaluated for exertional dyspnea. His exercise tolerance has decreased over the last year, and he can barely walk 2-3 blocks without stopping. The patient also reports occasional episodes of lightheadedness and palpitations. He has had no chest pain or syncope. He was diagnosed with hypertension in the past but does not take any medications. Physical examination reveals a cardiac murmur. The patient is referred to a cardiologist for further evaluation. Cardiac catheterization is performed, and the findings are shown in the image below. Which of the following points most likely corresponds to the peak murmur intensity in this patient?

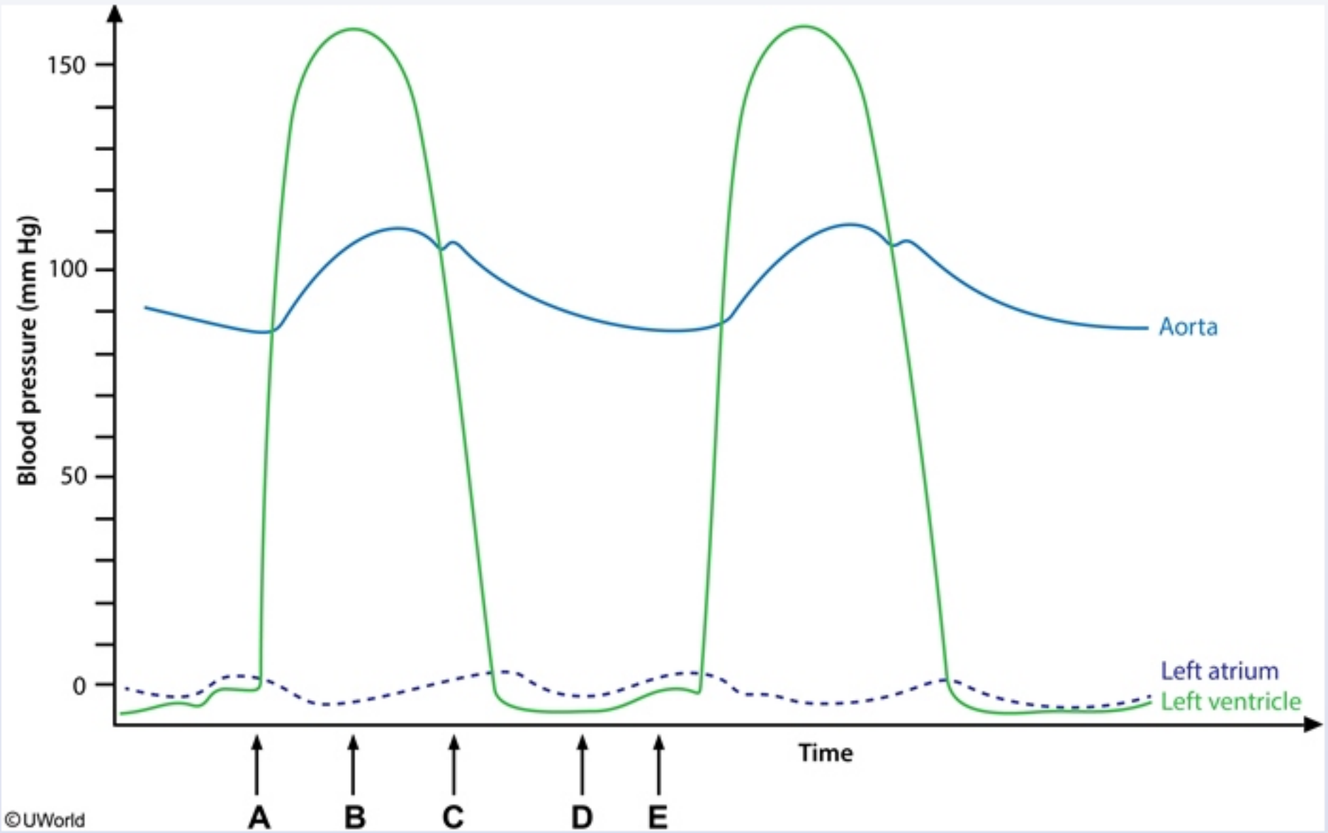

A. A

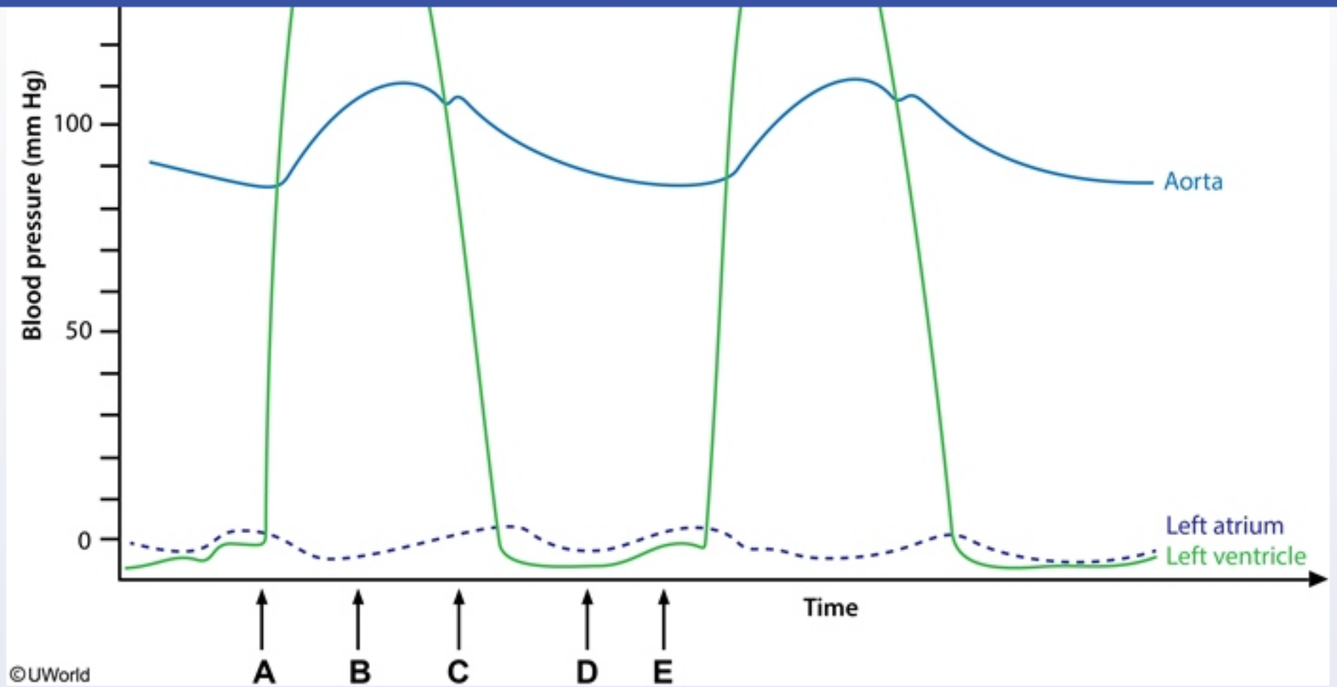

A. A

B. B

C. C

D. D

E. E

Submit

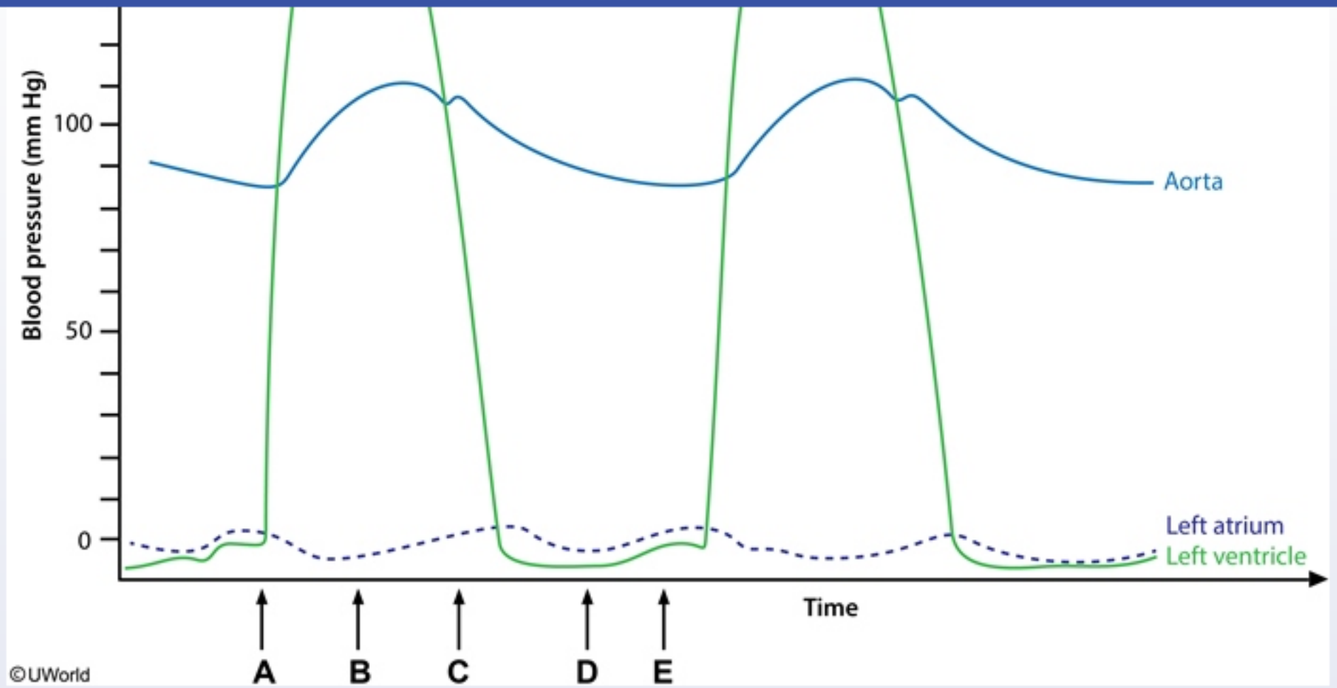

A. A (15%)

✓ B. B (57%)

C. C (17%)

D. D (5%)

E. E (3%)

Omitted
Correct answer

57%
Answered correctly

13 secs
Time Spent

04/18/2020
Last Updated

Explanation

In the absence of any aortic valve pathology, the pressure in the aorta is similar to left ventricular pressure during systole. However, this patient's hemodynamic profile shows an abnormal pressure gradient between the left ventricular and aortic pressure tracings during systole (compare to normal), indicating significant aortic stenosis (AS). The intensity of the murmur of AS is directly related to the magnitude of the left ventricle to aorta pressure gradient. The maximum pressure difference between the left ventricular and aortic pressure tracings is noted at point B and corresponds to the peak intensity of a cardiac murmur during auscultation.

(Choices A and C) The murmur of AS is a systolic ejection-type crescendo-decrescendo murmur that starts after the first heart sound following the opening of the aortic valve (point A). It typically ends before the A2 component of the second heart sound (point C). At points A and C, the left ventricular and aortic pressures are nearly equal with no or minimal flow across the aortic valve, and the murmur of AS would not be appreciated.

(Choices D and E) These points occur during diastole, when the aortic valve is closed and the mitral valve is open. There is no abnormally elevated pressure gradient between the left atrium and left ventricle. This is consistent with normal, unobstructed diastolic filling of the left ventricle, and no murmur would be heard during diastole.

Educational objective:
The murmur of aortic stenosis (AS) is a systolic ejection-type, crescendo-decrescendo murmur that starts after the first heart sound and typically ends before the A2 component of the second heart sound. The intensity of the murmur is proportional to the magnitude of the left ventricle to aorta pressure gradient during systole.

References

- The patient with a systolic murmur: severe aortic stenosis may be missed during cardiovascular examination.

Pathophysiology	Cardiovascular System	Aortic stenosis
Subject	System	Topic

Copyright © UWorld. All rights reserved.

1
2
3
4
5
6
7
8
9
10
11
12
13
14
15
16
17
18
19
20
21
22
23
24
25
26
27
28
29
30
31

Exhibit Display

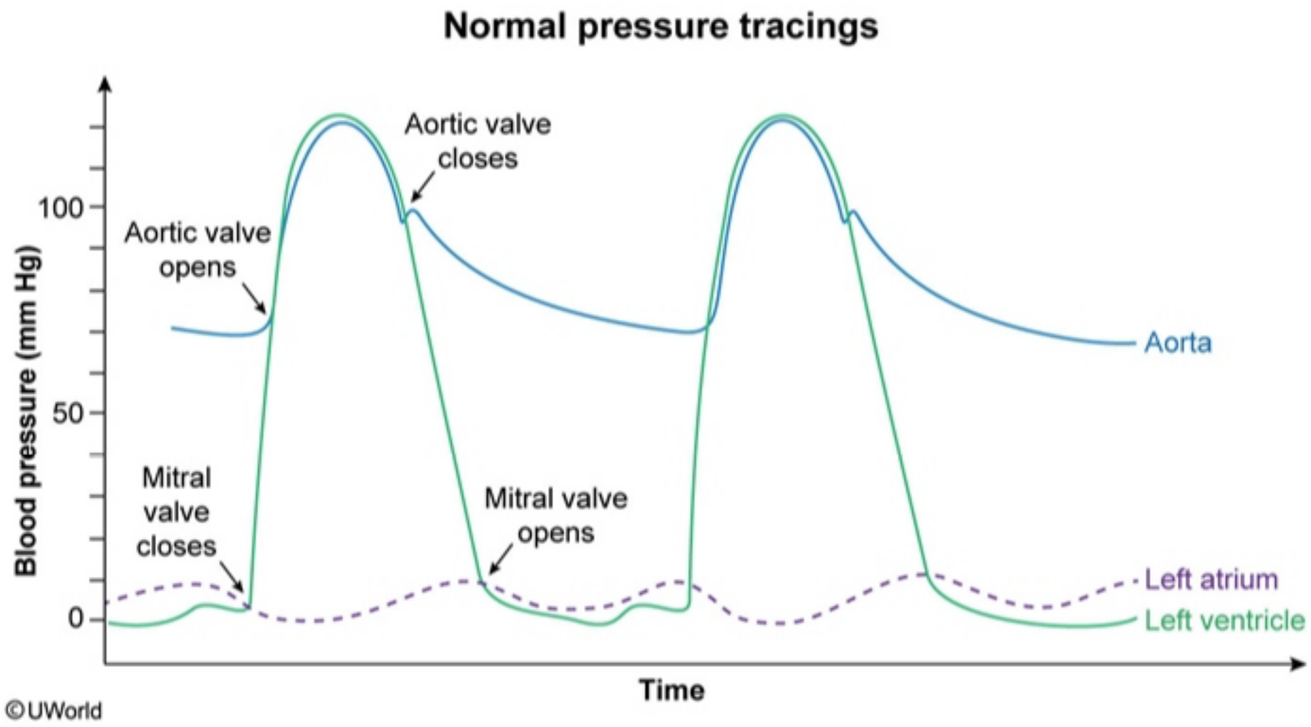

Zoom In | Zoom Out | Reset | Add To New Card | Existing Card

A 34-year-old woman is brought to the emergency department due to chest pain. The patient reports that she went to bed feeling well and woke up in the middle of the night with severe, crushing chest pain that radiated to her left arm. She has had similar episodes over the past year that typically occur in early morning and spontaneously resolve after several minutes. The patient has a history of occasional migraine that responds to acetaminophen. She does not use tobacco, alcohol, or illicit drugs. Blood pressure is 150/100 mm Hg, pulse is 110/min, and respirations are 14/min. On physical examination, the patient appears distressed and is diaphoretic. ECG reveals ST-segment elevations in leads I, aVL, and V4-V6. The patient is given nitroglycerin, which improves her symptoms. Percutaneous coronary angiography is performed, and no obstructive lesions are observed. Which of the following is most likely to be involved in the pathogenesis of this patient's chest pain?

- A. Decreased endothelial expression of endothelin-1
- B. Granulomatous inflammation of arterial media
- C. Hyperreactivity of vascular smooth muscle
- D. Increased endothelial expression of prostacyclin
- E. Ulceration of thin atheromatous fibrous cap

Submit

A 34-year-old woman is brought to the emergency department due to chest pain. The patient reports that she went to bed feeling well and woke up in the middle of the night with severe, crushing chest pain that radiated to her left arm. She has had similar episodes over the past year that typically occur in early morning and spontaneously resolve after several minutes. The patient has a history of occasional migraine that responds to acetaminophen. She does not use tobacco, alcohol, or illicit drugs. Blood pressure is 150/100 mm Hg, pulse is 110/min, and respirations are 14/min. On physical examination, the patient appears distressed and is diaphoretic. ECG reveals ST-segment elevations in leads I, aVL, and V4-V6. The patient is given nitroglycerin, which improves her symptoms. Percutaneous coronary angiography is performed, and no obstructive lesions are observed. Which of the following is most likely to be involved in the pathogenesis of this patient's chest pain?

- A. Decreased endothelial expression of endothelin-1 (3%)
- B. Granulomatous inflammation of arterial media (4%)
- ✓ C. Hyperreactivity of vascular smooth muscle (83%)
- D. Increased endothelial expression of prostacyclin (3%)
- E. Ulceration of thin atheromatous fibrous cap (5%)

Omitted
Correct answer
C

83%
Answered correctly

02 secs
Time Spent

05/28/2020
Last Updated

Explanation

Vasospastic angina	
Pathogenesis	• Hyperreactivity of coronary smooth muscle due to

Vasospastic angina	
Pathogenesis	• Hyperreactivity of coronary smooth muscle due to endothelial dysfunction & autonomic imbalance

Clinical presentation	• Young age (<50)
	• Minimal CAD risk factors (other than smoking)
	• Recurrent chest discomfort
	  ◦ At rest or during sleep
	  ◦ Spontaneous resolution ≤15 min

Diagnosis	• ECG: ST-segment elevation during episode • Coronary angiography: no CAD
CAD = coronary artery disease.	

This patient most likely has **vasospastic angina** (formerly Prinzmetal angina), which involves **intermittent coronary artery vasospasm** leading to myocardial ischemia. The condition likely results from hyperreactivity of arterial smooth muscle due to a combination of **endothelial dysfunction** and **autonomic imbalance**.

The major underlying defect in vasospastic angina is likely a deficiency of vasodilatory nitric oxide in the coronary artery endothelium, causing acetylcholine released from vagus nerve terminals to trigger vasoconstriction rather than vasodilation. Patients typically experience episodes of **recurrent chest discomfort** that spontaneously **resolve within 15 minutes**. The episodes often occur at rest or **during sleep**, when vagal tone is at a peak. As with typical angina, there may be associated diaphoresis, nausea, and dyspnea, but unlike typical angina, patients are usually young (age <50) and lack most risk factors for atherosclerotic coronary artery disease (CAD) (eg, hypertension, diabetes). However, smoking is a strong risk factor, likely due to its contribution to endothelial dysfunction.

Vasospastic angina is usually diagnosed by ambulatory ECG (Holter monitor) that shows **ST elevation** during an episode of chest discomfort, followed by coronary angiography to rule out atherosclerotic CAD. Sublingual nitroglycerin is effective in relieving an active episode of vasospastic angina, and calcium channel blockers (eg, diltiazem, amlodipine) are effective in preventing episodes.

This patient most likely has **vasospastic angina** (formerly Prinzmetal angina), which involves **intermittent coronary artery vasospasm** leading to myocardial ischemia. The condition likely results from hyperreactivity of arterial smooth muscle due to a combination of **endothelial dysfunction** and **autonomic imbalance**.

The major underlying defect in vasospastic angina is likely a deficiency of vasodilatory nitric oxide in the coronary artery endothelium, causing acetylcholine released from vagus nerve terminals to trigger vasoconstriction rather than vasodilation. Patients typically experience episodes of **recurrent chest discomfort** that spontaneously **resolve within 15 minutes**. The episodes often occur at rest or **during sleep**, when vagal tone is at a peak. As with typical angina, there may be associated diaphoresis, nausea, and dyspnea, but unlike typical angina, patients are usually young (age <50) and lack most risk factors for atherosclerotic coronary artery disease (CAD) (eg, hypertension, diabetes). However, smoking is a strong risk factor, likely due to its contribution to endothelial dysfunction.

Vasospastic angina is usually diagnosed by ambulatory ECG (Holter monitor) that shows **ST elevation** during an episode of chest discomfort, followed by coronary angiography to rule out atherosclerotic CAD. Sublingual nitroglycerin is effective in relieving an active episode of vasospastic angina, and calcium channel blockers (eg, diltiazem, amlodipine) are effective in preventing episodes.

(Choices A and D) Endothelin-1 is a potent vasoconstrictor and prostacyclin is a vasodilator. Therefore, decreased expression of endothelin-1 or increased expression of prostacyclin would stimulate coronary vasodilation rather than vasospasm.

(Choice B) Granulomatous inflammation of arterial media occurs in Takayasu arteritis, a large-vessel vasculitis affecting the aorta and its major branches. Young women of Asian descent are most commonly affected and sometimes develop angina due to coronary artery involvement; however, limb claudication (due to subclavian artery involvement) accompanied by constitutional symptoms (eg, fever, fatigue) is a more common presentation.

(Choice E) Ulceration of the thin fibrous cap overlying an atherosclerotic plaque can lead to unstable angina, characterized by intermittent chest discomfort similar to that of vasospastic angina. However, atherosclerotic CAD is unlikely in this young woman without significant CAD risk factors.

Educational objective:
Vasospastic angina involves hyperreactivity of coronary artery smooth muscle. Patients are usually young (age <50) and without significant risk factors for coronary artery disease; they experience recurrent episodes of chest discomfort that typically occur during rest or sleep and resolve within 15 minutes.

1 2 3 4 5 6 7 8 9 10 11 12 13 14 15 16 17 18 19 20 21 22 23 24 25 26 27 28 29 30 31

recurrent chest discomfort that spontaneously **resolve within 15 minutes**. The episodes often occur at rest or **during sleep**, when vagal tone is at a peak. As with typical angina, there may be associated diaphoresis, nausea, and dyspnea, but unlike typical angina, patients are usually young (age <50) and lack most risk factors for atherosclerotic coronary artery disease (CAD) (eg, hypertension, diabetes). However, smoking is a strong risk factor, likely due to its contribution to endothelial dysfunction.

Vasospastic angina is usually diagnosed by ambulatory ECG (Holter monitor) that shows **ST elevation** during an episode of chest discomfort, followed by coronary angiography to rule out atherosclerotic CAD. Sublingual nitroglycerin is effective in relieving an active episode of vasospastic angina, and calcium channel blockers (eg, diltiazem, amlodipine) are effective in preventing episodes.

(Choices A and D) Endothelin-1 is a potent vasoconstrictor and prostacyclin is a vasodilator. Therefore, decreased expression of endothelin-1 or increased expression of prostacyclin would stimulate coronary vasodilation rather than vasospasm.

(Choice B) Granulomatous inflammation of arterial media occurs in Takayasu arteritis, a large-vessel vasculitis affecting the aorta and its major branches. Young women of Asian descent are most commonly affected and sometimes develop angina due to coronary artery involvement; however, limb claudication (due to subclavian artery involvement) accompanied by constitutional symptoms (eg, fever, fatigue) is a more common presentation.

(Choice E) Ulceration of the thin fibrous cap overlying an atherosclerotic plaque can lead to unstable angina, characterized by intermittent chest discomfort similar to that of vasospastic angina. However, atherosclerotic CAD is unlikely in this young woman without significant CAD risk factors.

Educational objective:
Vasospastic angina involves hyperreactivity of coronary artery smooth muscle. Patients are usually young (age <50) and without significant risk factors for coronary artery disease; they experience recurrent episodes of chest discomfort that typically occur during rest or sleep and resolve within 15 minutes.

Pathophysiology	Cardiovascular System	Vasospastic angina
Subject	System	Topic

Copyright © UWorld. All rights reserved.

This item has associated media that may require the use of headphones. Please ensure your system/speaker volume is set to an audible level.

A 65-year-old man with a long history of hypertension and type 2 diabetes mellitus comes to the physician for a routine check-up. He is an ex-smoker with a 15 pack-year smoking history. He jogs 3 miles per day. His BMI is 28.5 kg/m^2. His family history is unremarkable. Cardiac auscultation findings over the apex are given below. The auscultatory findings are best explained by which of the following?

Play Media

A. Aortic root dilation

B. Atrial septal defect

C. Left ventricular hypertrophy

D. Mitral valve prolapse

E. Pericardial effusion

Submit

This item has associated media that may require the use of headphones. Please ensure your system/speaker volume is set to an audible level.

A 65-year-old man with a long history of hypertension and type 2 diabetes mellitus comes to the physician for a routine check-up. He is an ex-smoker with a 15 pack-year smoking history. He jogs 3 miles per day. His BMI is 28.5 kg/m^2. His family history is unremarkable. Cardiac auscultation findings over the apex are given below. The auscultatory findings are best explained by which of the following?

Play Media

- A. Aortic root dilation (4%)
- B. Atrial septal defect (2%)
- ✓ C. Left ventricular hypertrophy (52%)
- D. Mitral valve prolapse (38%)
- E. Pericardial effusion (1%)

Omitted
Correct answer
C

52%
Answered correctly

01 sec
Time Spent

05/13/2020
Last Updated

Explanation

The auscultatory findings in this case demonstrate an extra low frequency heart sound at the end of diastole just before S1 known as S4. This fourth heart sound is often heard in older adults due to an age-related decrease in left ventricular compliance, and in such cases is a relatively benign finding. However, the louder the sound, the more likely it is due to a pathologically stiff left ventricle, which occurs in restrictive

1 2 3 4 5 6 7 8 9 10 11 12 13 14 15 16 17 18 19 20 21 22 23 24 25 26 27 28 29 30 31

The auscultatory findings in this case demonstrate an extra low frequency heart sound at the end of diastole just before S1 known as S4. This fourth heart sound is often heard in older adults due to an age-related decrease in left ventricular compliance, and in such cases is a relatively benign finding. However, the louder the sound, the more likely it is due to a pathologically stiff left ventricle, which occurs in restrictive cardiomyopathy and in left ventricular hypertrophy following prolonged hypertension (likely the cause in this case). Unlike the S3 sound, auscultation of an S4 in younger patients is always pathologic. It is thought that the S4 coincides with atrial contraction and is produced by the resultant onrush of blood striking a stiff left ventricle.

(Choice A) Aortic root dilation can be associated with aortic regurgitation, which would result in an early diastolic murmur as opposed to an extra heart sound.

(Choice B) An atrial septal defect produces fixed splitting of the second heart sound. This can be distinguished from an S4, which occurs just before S1.

(Choice D) Mitral valve prolapse is classically associated with a mid-systolic click and a mid-to-late systolic murmur.

(Choice E) Physical examination signs of a pericardial effusion are neither sensitive nor specific, and a S4 is not an associated finding.

Educational objective:
The fourth heart sound (S4) is a low frequency sound heard at the end of diastole just before S1. It is due to decreased left ventricular compliance and is often associated with restrictive cardiomyopathy and left ventricular hypertrophy.

References

- Association of the fourth heart sound with increased left ventricular end-diastolic stiffness.
- Correlation of an audible fourth heart sound with level of diastolic dysfunction.

Pathophysiology	Cardiovascular System	Heart sounds
Subject	System	Topic

Copyright © UWorld. All rights reserved.

1
2
3
4
5
6
7
8
9
10
11
12
13
14
15
16
17
18
19
20
21
22
23
24
25
26
27
28
29
30
31

A 2-month-old boy is found unresponsive in his crib. He had previously been well and had a normal physical examination at his 2-month visit approximately 1 week earlier. An autopsy is performed to determine the cause of death. The pathologist concludes that the infant likely died of sudden infant death syndrome. The autopsy also shows an incidental finding of bicuspid aortic valve. If this patient had survived, he would have been at greatest risk for which of the following events?

A. Aortic dissection in his 30s
B. Aortic stenosis in his 50s
C. Atrial fibrillation in his 40s
D. Endocarditis in his 20s
E. Severe aortic stenosis in infancy
F. Ventricular arrhythmia in childhood

Submit

1 2 3 4 5 6 7 8 9 10 11 12 13 14 15 16 17 18 19 20 21 22 23 24 25 26 27 28 29 30 31

A 2-month-old boy is found unresponsive in his crib. He had previously been well and had a normal physical examination at his 2-month visit approximately 1 week earlier. An autopsy is performed to determine the cause of death. The pathologist concludes that the infant likely died of sudden infant death syndrome. The autopsy also shows an incidental finding of bicuspid aortic valve. If this patient had survived, he would have been at greatest risk for which of the following events?

- A. Aortic dissection in his 30s (9%)
- ✓ B. Aortic stenosis in his 50s (73%)
- C. Atrial fibrillation in his 40s (1%)
- D. Endocarditis in his 20s (6%)
- E. Severe aortic stenosis in infancy (5%)
- F. Ventricular arrhythmia in childhood (2%)

Omitted
Correct answer
B

73%
Answered correctly

01 sec
Time Spent

06/02/2020
Last Updated

Explanation

Bicuspid aortic valve disease

1
2
3
4
5
6
7
8
9
10
11
12
13
14
15
16
17
18
19
20
21
22
23
24
25
26
27
28
29
30
31

Bicuspid aortic valve disease

Normal aortic valve

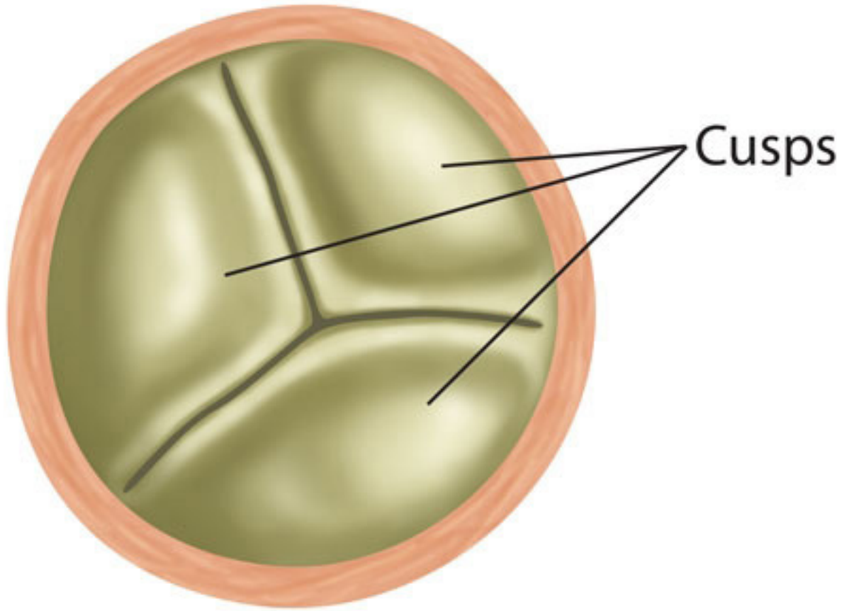

Bicuspid aortic valve

1
2
3
4
5
6
7
8
9
10
11
12
13
14
15
16
17
18
19
20
21
22
23
24
25
26
27
28
29
30
31

Bicuspid aortic valve disease

Exhibit Display

Bicuspid aortic valve disease

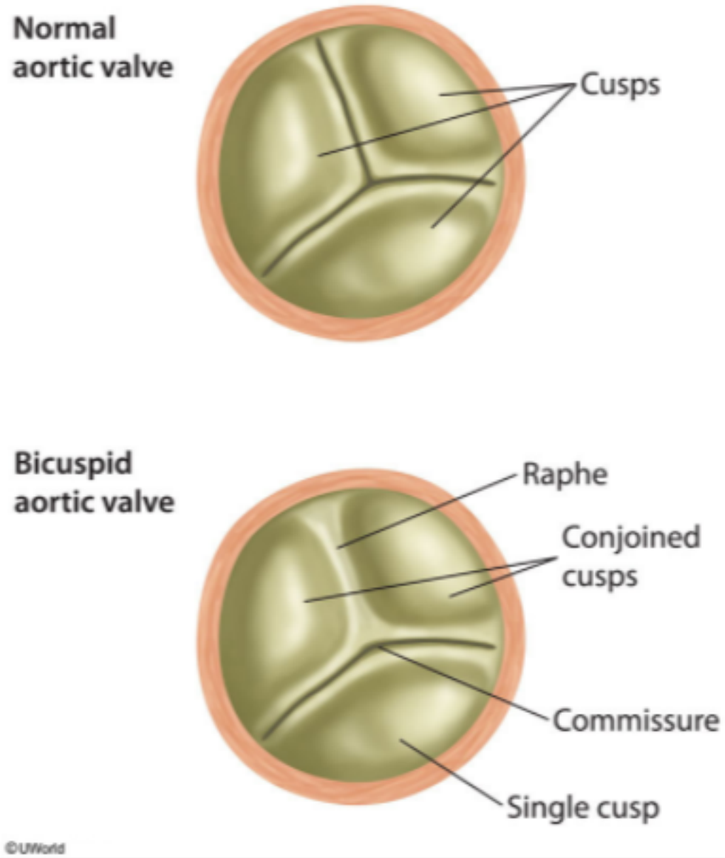

Zoom In | Zoom Out | Reset | Add To New Card | Existing Card

©UWorld

Bicuspid aortic valves (right and left aortic cusp fusion) occur in approximately 1%-2% of live births, making it one of the **most common** congenital heart defects. The abnormally shaped valve experiences increased hemodynamic stress, which accelerates the normal aging process and causes premature **atherosclerosis** and **calcification** of the aortic valve. These deposits begin accumulating as early as adolescence and lead to **aortic stenosis** in **>50%** of affected patients. Symptomatic aortic stenosis develops on average around age 50 (10 years earlier than the average onset of senile calcific aortic stenosis in patients with normal aortic valves).

(Choice A) Patients with bicuspid aortic valves have a higher risk of aortic dissection. However, the absolute risk of aortic dissection is still <1%. As with other complications of bicuspid aortic valves, the risk increases with advancing age.

(Choice C) Atrial fibrillation has not been associated with bicuspid aortic valves.

(Choice D) Patients with bicuspid aortic valves are at increased risk for infective endocarditis. The risk is 2%-3% and rises with age due to increasingly turbulent blood flow across the abnormal valve.

(Choice E) In early childhood, isolated bicuspid aortic valves usually are asymptomatic, without any hemodynamically significant degree of aortic outflow tract obstruction or murmurs. In contrast, congenital aortic stenosis usually produces a systolic murmur as a result of severe subvalvular, valvular, or supravalvular anatomic defects.

(Choice F) The most common cause of ventricular fibrillation at age <30 is hypertrophic cardiomyopathy. This condition is not associated with bicuspid aortic valves.

Educational objective:
Aortic stenosis is the most common complication of bicuspid aortic valves. Patients with bicuspid aortic valves develop clinically significant aortic stenosis on average around age 50. In comparison, senile calcific stenosis of normal aortic valves generally becomes symptomatic age >65.

Pathophysiology	Cardiovascular System	Bicuspid aortic valve
Subject	System	Topic

Copyright © UWorld. All rights reserved.

1
2
3
4
5
6
7
8
9
10
11
12
13
14
15
16
17
18
19
20
21
22
23
24
25
26
27
28
29
30
31

A 72-year-old man with long-standing dyspnea was seen in the clinic after experiencing an episode of syncope. Physical examination showed weak and slowly rising arterial pulses. Cardiac auscultation showed a harsh midsystolic murmur best heard at the second right intercostal space with decreased intensity of the second heart sound. Electrocardiogram and echocardiogram confirmed the diagnosis of severe aortic stenosis. Two months later, the patient comes to the emergency department with palpitations and increased shortness of breath. His blood pressure is 90/60 mm Hg and his heart rate is 130/min with an irregularly irregular rhythm. Electrocardiogram shows new-onset atrial fibrillation without significant ST-segment or T-wave changes. Chest x-ray shows bilateral pulmonary edema. Which of the following hemodynamic changes is most likely associated with this patient's current presentation?

A. Insidious right ventricular failure

B. Sudden decrease in left ventricular preload

C. Sudden decrease in left ventricular systolic function

D. Sudden increase in left ventricular afterload

E. Sudden increase in left ventricular filling

Submit

A 72-year-old man with long-standing dyspnea was seen in the clinic after experiencing an episode of syncope. Physical examination showed weak and slowly rising arterial pulses. Cardiac auscultation showed a harsh midsystolic murmur best heard at the second right intercostal space with decreased intensity of the second heart sound. Electrocardiogram and echocardiogram confirmed the diagnosis of severe aortic stenosis. Two months later, the patient comes to the emergency department with palpitations and increased shortness of breath. His blood pressure is 90/60 mm Hg and his heart rate is 130/min with an irregularly irregular rhythm. Electrocardiogram shows new-onset atrial fibrillation without significant ST-segment or T-wave changes. Chest x-ray shows bilateral pulmonary edema. Which of the following hemodynamic changes is most likely associated with this patient's current presentation?

- A. Insidious right ventricular failure (10%)
- ✓ B. Sudden decrease in left ventricular preload (28%)
- C. Sudden decrease in left ventricular systolic function (39%)
- D. Sudden increase in left ventricular afterload (15%)
- E. Sudden increase in left ventricular filling (5%)

Omitted
Correct answer
B

28%
Answered correctly

02 secs
Time Spent

03/02/2020
Last Updated

Explanation

This patient's sudden-onset heart failure was most likely precipitated by acute **atrial fibrillation**, a condition that occurs in up to 10% of patients with **severe aortic stenosis** (AS). Patients with severe AS already have reduced cardiac output due to significant valvular obstruction, which can be exacerbated by the sudden **loss of normal atrial contraction** that contributes to ventricular filling. Atrial contraction is especially important for

1
2
3
4
5
6
7
8
9
10
11
12
13
14
15
16
17
18
19
20
21
22
23
24
25
26
27
28
29
30
31

Hemodynamics of severe aortic stenosis

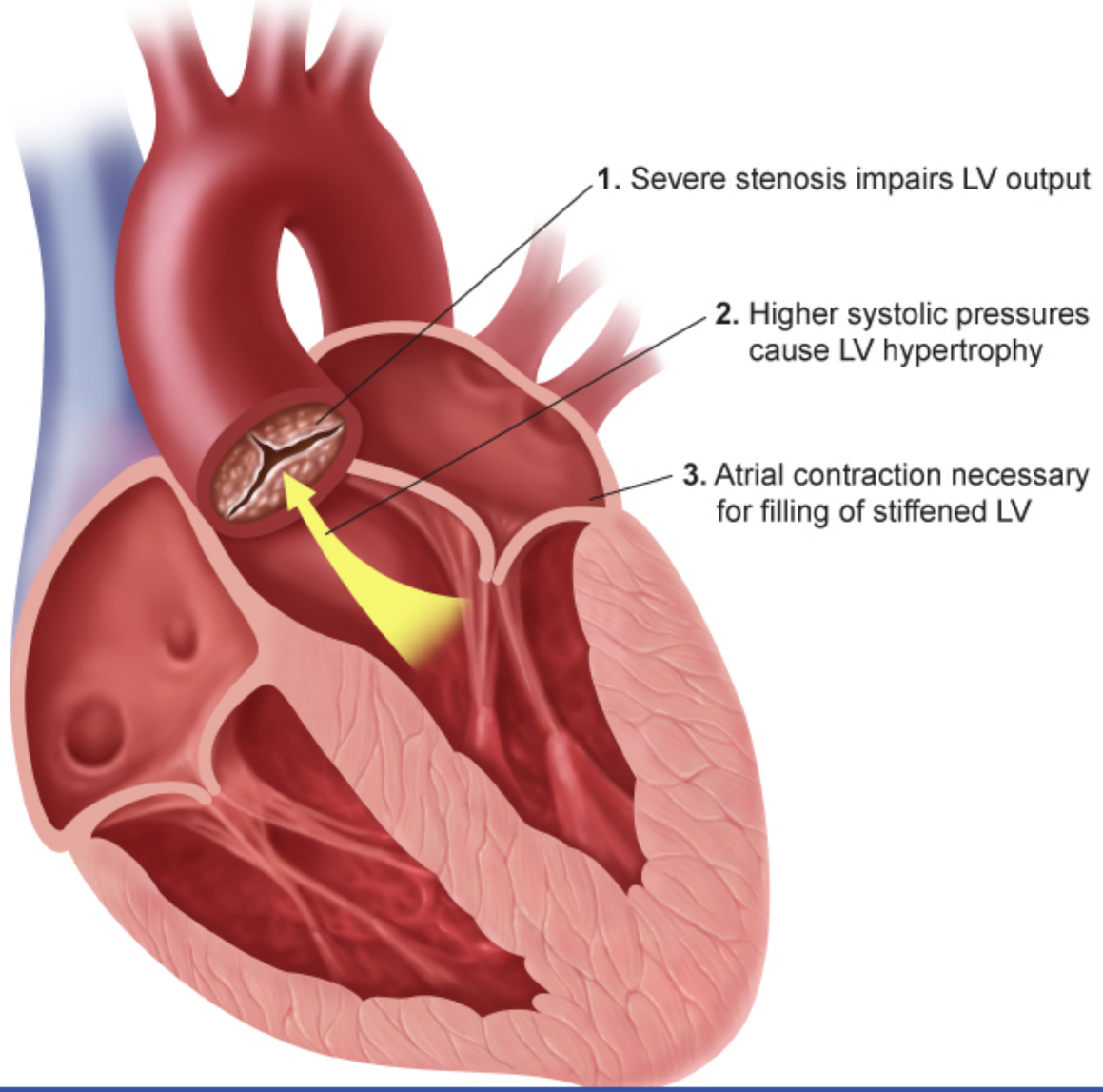

Atrial fibrillation: Loss of contraction reduces LV filling, causing hypotension & pulmonary edema

©UWorld

This patient's sudden-onset heart failure was most likely precipitated by acute **atrial fibrillation**, a condition that occurs in up to 10% of patients with **severe aortic stenosis** (AS). Patients with severe AS already have reduced cardiac output due to significant valvular obstruction, which can be exacerbated by the sudden **loss of normal atrial contraction** that contributes to ventricular filling. Atrial contraction is especially important for these patients as many have concentric left ventricular (LV) hypertrophy and therefore reduced LV compliance. As a result, they become dependent on atrial contraction to maintain adequate LV filling. Without atrial contraction, LV preload can decrease to the point of producing severe **hypotension**. In addition, loss of the atrial kick can result in significantly increased mean pulmonary venous pressure due to buildup of blood in the left atrium and pulmonary veins, leading to **acute pulmonary edema**. As a result, cardioversion is indicated for acute atrial fibrillation in patients with severe AS.

(Choice A) Cardiogenic pulmonary edema is characteristic of left, not right, heart failure. When the forward pumping function of the left heart is impaired, pressure can build up in the left atrium. This rise in pressure is transmitted to the pulmonary veins and capillaries, resulting in increased fluid transudation into the alveoli and pulmonary interstitium.

(Choices C and E) This patient has no evidence of myocardial ischemia on electrocardiogram, meaning that LV systolic function is most likely unchanged. Under these circumstances, an increase in LV filling (preload) would increase cardiac output and mean arterial pressure due to the Frank-Starling mechanism. This patient's decreased cardiac output is most likely due to decreased LV preload.

(Choice D) In a patient with AS, LV afterload is determined by the mean systolic blood pressure and the degree of transvalvular obstruction. In degenerative calcific AS and most other forms of adult AS, the transvalvular obstruction gradually increases over years to decades, making an acute increase in LV afterload unlikely. In addition, this patient's acute hypotension would actually cause a reduction in afterload.

Educational objective:
In patients with chronic aortic stenosis and concentric left ventricular hypertrophy, atrial contraction contributes significantly to left ventricular filling. Loss of atrial contraction due to atrial fibrillation can reduce left ventricular preload and cardiac output sufficiently to cause systemic hypotension. Decreased forward filling of the left ventricle can also result in backup of blood in the left atrium and pulmonary veins, leading to acute pulmonary edema.

A 77-year-old woman is brought to the emergency department with severe lightheadedness and near-syncope that began earlier in the day. Over the past several months, she has experienced occasional episodes of lightheadedness and feeling unsteady, which she attributed to "old age." The patient has not had chest pain, shortness of breath, or lower extremity swelling. She was diagnosed with hypertension 10 years ago and has been taking losartan. The patient does not take any other medications. She lives alone and is independent in her daily activities. An ECG obtained in the emergency department is shown in the exhibit. Cell degeneration in which of the following locations is most likely responsible for this patient's current condition?

A. Interatrial septum

B. Interventricular septum

C. Left atrial wall

D. Left ventricular free wall

E. Right atrial wall

Submit

1
2
3
4
5
6
7
8
9
10
11
12
13
14
15
16
17
18
19
20
21
22
23
24
25
26
27
28
29
30
31

Exhibit Display

Zoom In | Zoom Out | Reset | Add To New Card | Existing Card

A 77-year-old woman is brought to the emergency department with severe lightheadedness and near-syncope that began earlier in the day. Over the past several months, she has experienced occasional episodes of lightheadedness and feeling unsteady, which she attributed to "old age." The patient has not had chest pain, shortness of breath, or lower extremity swelling. She was diagnosed with hypertension 10 years ago and has been taking losartan. The patient does not take any other medications. She lives alone and is independent in her daily activities. An ECG obtained in the emergency department is shown in the exhibit. Cell degeneration in which of the following locations is most likely responsible for this patient's current condition?

- A. Interatrial septum (24%)
- B. Interventricular septum (15%)
- C. Left atrial wall (5%)
- D. Left ventricular free wall (3%)
- ✓ E. Right atrial wall (51%)

Omitted
Correct answer
E

51%
Answered correctly

11 secs
Time Spent

03/16/2020
Last Updated

Explanation

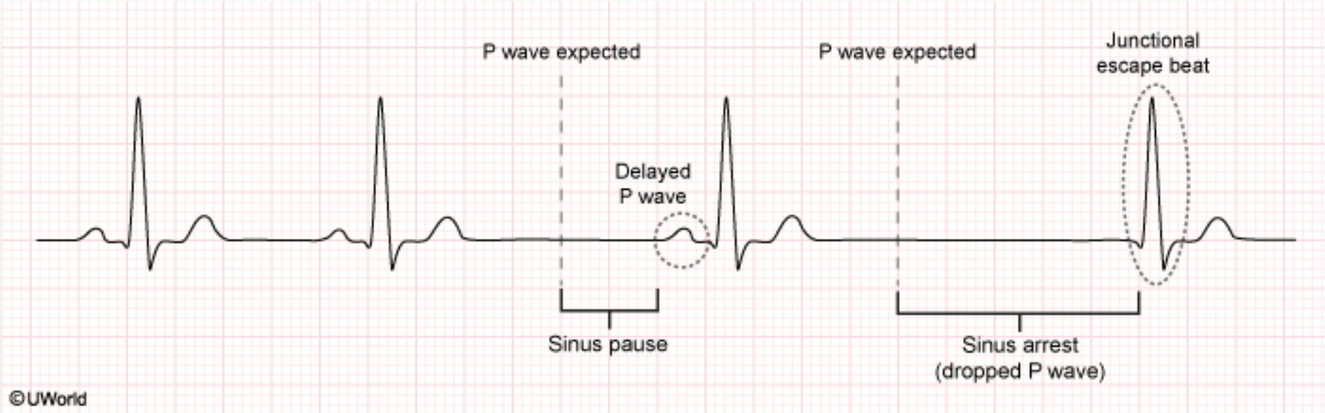

This elderly patient with recent lightheadedness and near-syncope has an ECG showing **bradycardia** with dropped P waves; these findings are consistent with **sick sinus syndrome**. Sick sinus syndrome most commonly results from **age-related degeneration** of the **sinoatrial node**, which is located on the right atrial wall and is responsible for initiating normal cardiac conduction. Impaired signaling from the sinoatrial node can markedly slow the rate of ventricular contraction, leading to **reduced cardiac output** and symptoms of dyspnea, fatigue, lightheadedness, presyncope, and syncope.

Typical ECG findings include bradycardia, **sinus pauses** (delayed P waves), and **sinus arrest** (prolonged delay of a P wave such that the P wave is dropped). Because the atrioventricular node triggers conduction based on its own pacemaker if it does not receive a timely signal from the sinoatrial node, sinus arrest will lead to a **junctional escape beat** (narrow QRS complex preceded by a long pause and no P wave). Sick sinus syndrome can also cause brief periods of atrial tachycardia (eg, atrial fibrillation) alternating with bradycardia.

(Choice A) The inferior portion of the interatrial septum contains the His bundle. Conduction abnormalities in this region can manifest as varying degrees of atrioventricular block with prolongation of the PR interval (first degree), dropped QRS complexes (second degree), or dissociation of P waves and QRS complexes (third degree).

(Choice B) Conduction through the interventricular septum mostly involves the left and right bundle branches. Conduction abnormalities in this region can lead to bundle branch blocks; the QRS complex is widened in bundle branch block due to impaired synchronization of ventricular depolarization.

This elderly patient with recent lightheadedness and near-syncope has an ECG showing **bradycardia** with dropped P waves; these findings are consistent with **sick sinus syndrome**. Sick sinus syndrome most commonly results from **age-related degeneration** of the **sinoatrial node**, which is located on the right atrial wall and is responsible for initiating normal cardiac conduction. Impaired signaling from the sinoatrial node can markedly slow the rate of ventricular contraction, leading to **reduced cardiac output** and symptoms of dyspnea, fatigue, lightheadedness, presyncope, and syncope.

Typical ECG findings include bradycardia, **sinus pauses** (delayed P waves), and **sinus arrest** (prolonged delay of a P wave such that the P wave is dropped). Because the atrioventricular node triggers conduction based on its own pacemaker if it does not receive a timely signal from the sinoatrial node, sinus arrest will lead to a **junctional escape beat** (narrow QRS complex preceded by a long pause and no P wave). Sick sinus syndrome can also cause brief periods of atrial tachycardia (eg, atrial fibrillation) alternating with bradycardia.

(Choice A) The inferior portion of the interatrial septum contains the His bundle. Conduction abnormalities in this region can manifest as varying degrees of atrioventricular block with prolongation of the PR interval (first degree), dropped QRS complexes (second degree), or dissociation of P waves and QRS complexes (third degree).

(Choice B) Conduction through the interventricular septum mostly involves the left and right bundle branches. Conduction abnormalities in this region can lead to bundle branch blocks; the QRS complex is widened in bundle branch block due to impaired synchronization of ventricular depolarization.

(Choice C) After initiation in the sinoatrial node, conduction propagates through the cardiomyocytes of the left atrial wall to stimulate left atrial contraction. Abnormal electrical foci can develop in the nearby pulmonary veins, which is a common trigger for atrial fibrillation.

(Choice D) Conduction abnormalities may originate in ischemic areas of the left ventricular free wall, leading to ventricular tachycardia.

Educational objective:
Sick sinus syndrome results from degeneration (usually age-related) of the sinoatrial node, leading to impaired conduction and reduced cardiac output with symptoms of dyspnea, fatigue, lightheadedness, presyncope, and syncope. ECG typically demonstrates bradycardia with sinus pauses (delayed P waves), sinus arrest (dropped P waves), and junctional escape beats.

Pathophysiology	Cardiovascular System	Sick Sinus Syndrome

1
2
3
4
5
6
7
8
9
10
11
12
13
14
15
16
17
18
19
20
21
22
23
24
25
26
27
28
29
30
31

Exhibit Display

Normal cardiac conduction system

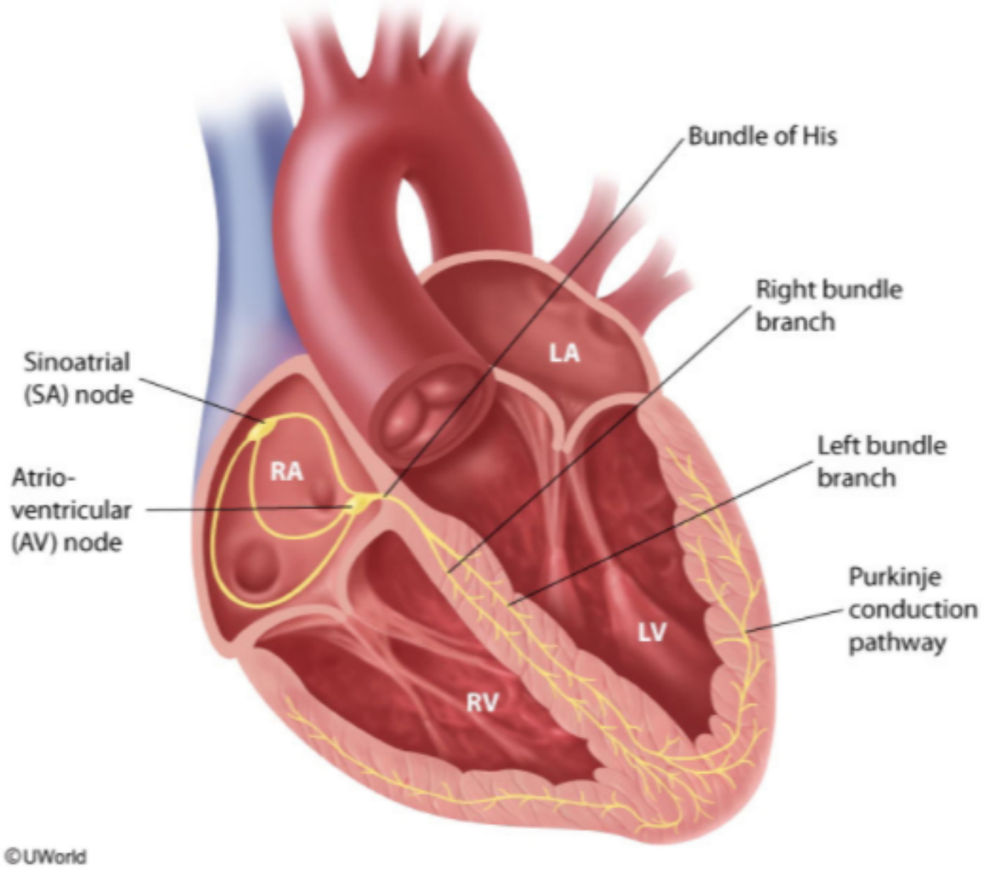

Zoom In | Zoom Out | Reset | Add To New Card | Existing Card

1
2
3
4
5
6
7
8
9
10
11
12
13
14
15
16
17
18
19
20
21
22
23
24
25
26
27
28
29
30
31

Exhibit Display

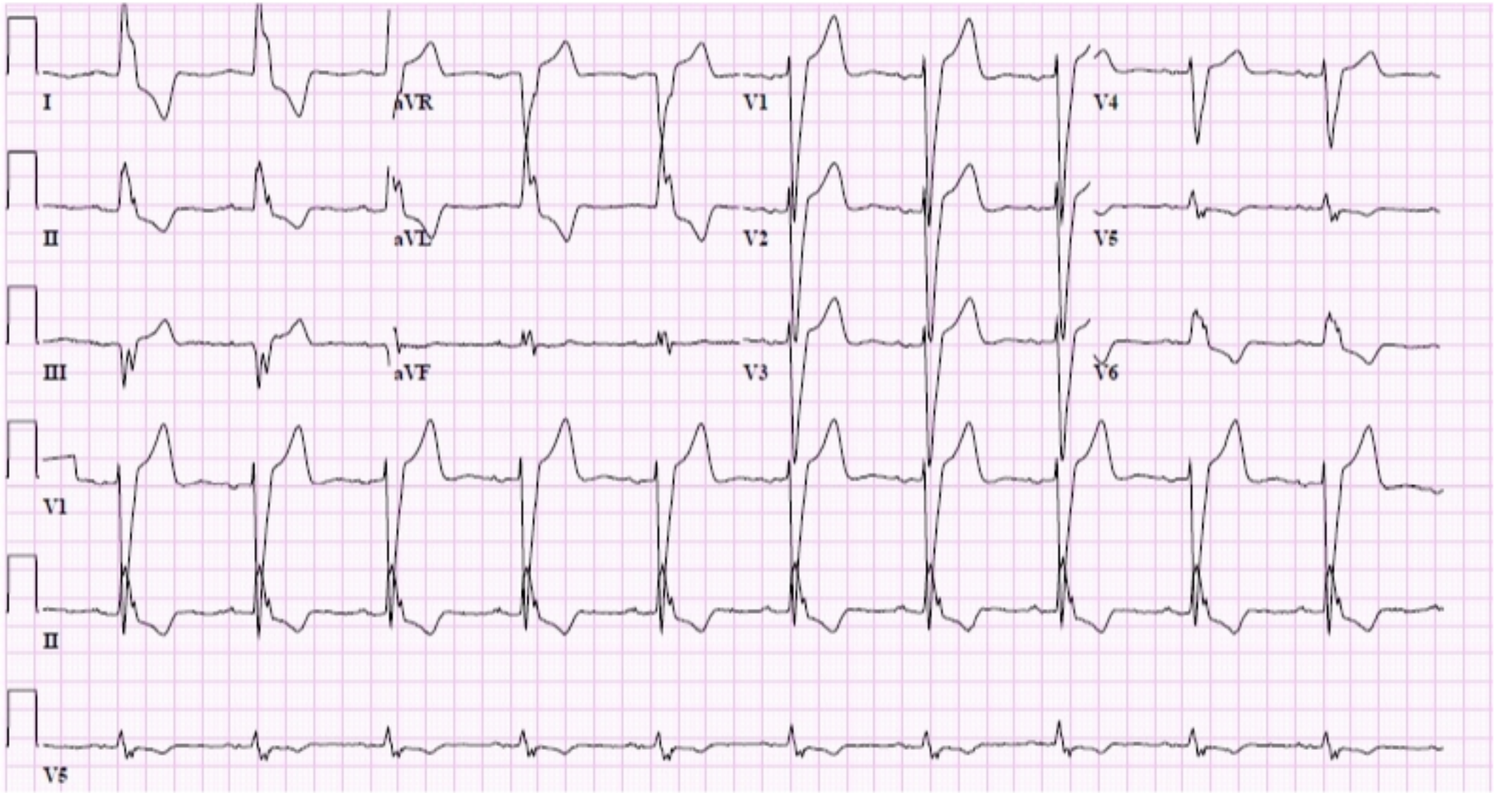

Zoom In | Zoom Out | Reset | Add To New Card | Existing Card

1
2
3
4
5
6
7
8
9
10
11
12
13
14
15
16
17
18
19
20
21
22
23
24
25
26
27
28
29
30
31

Exhibit Display

Atrial fibrillation

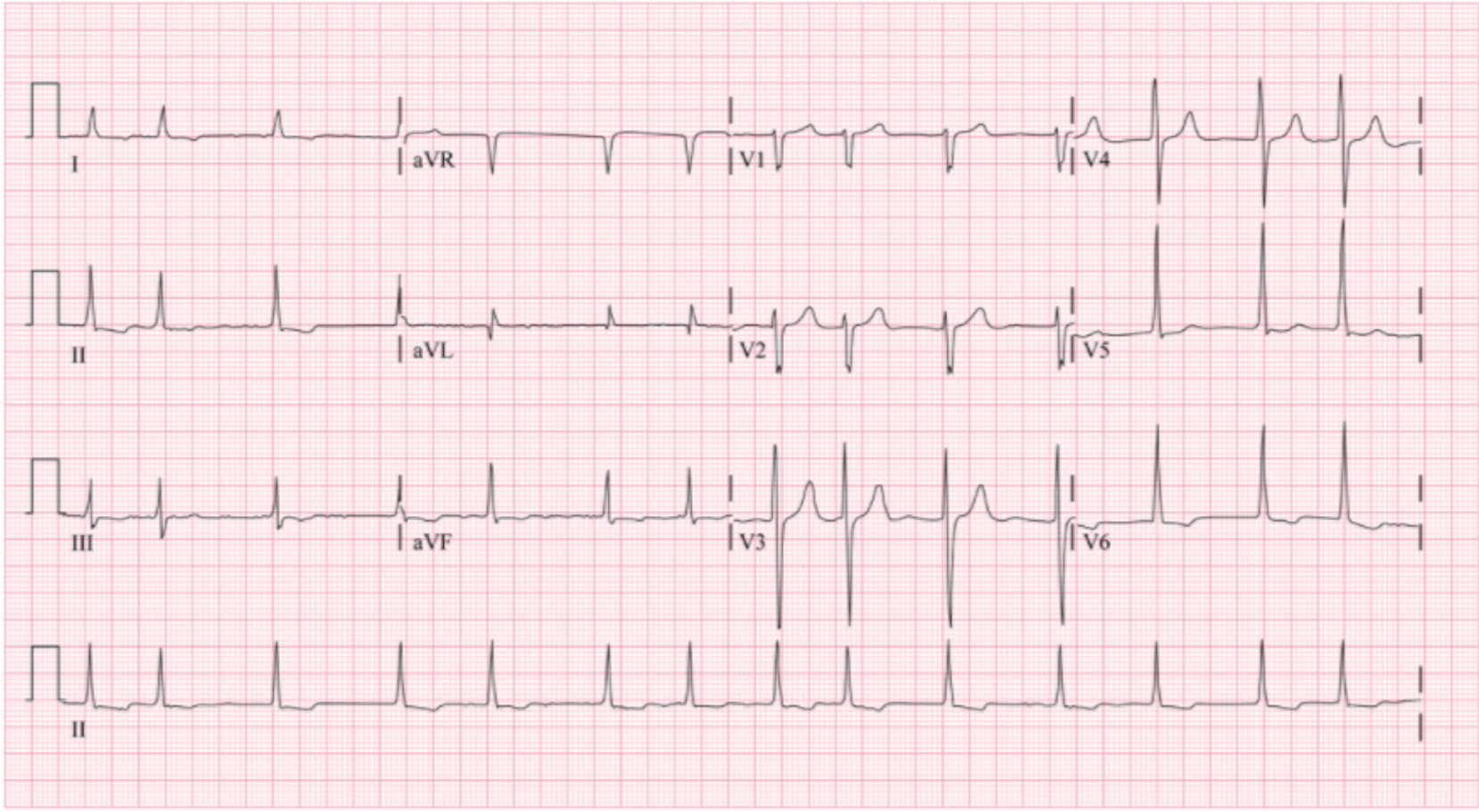

©UWorld

Zoom In | Zoom Out | Reset | Add To New Card | Existing Card

1
2
3
4
5
6
7
8
9
10
11
12
13
14
15
16
17
18
19
20
21
22
23
24
25
26
27
28
29
30
31

Exhibit Display

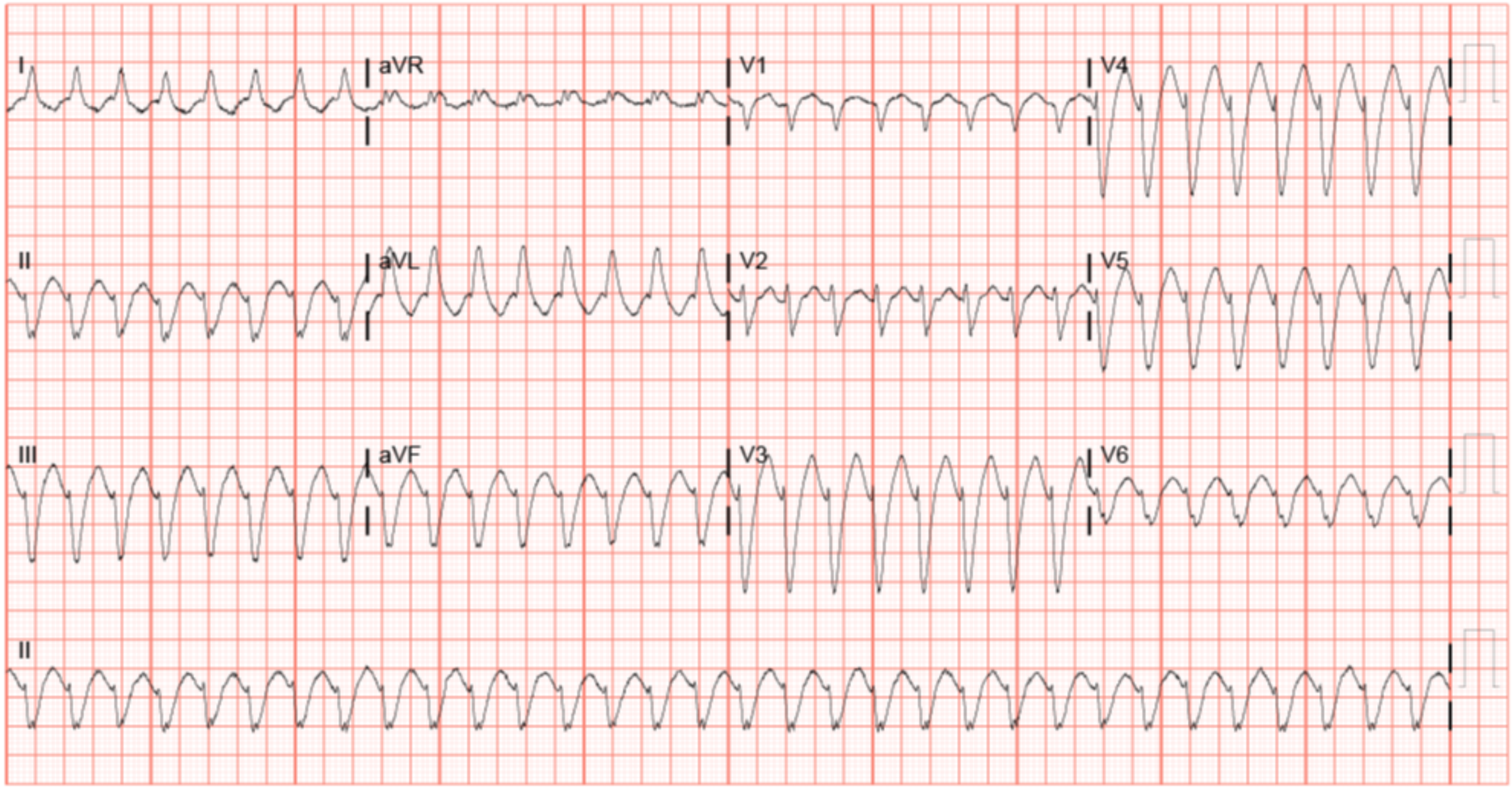

Zoom In | Zoom Out | Reset | Add To New Card | Existing Card

1
2
3
4
5
6
7
8
9
10
11
12
13
14
15
16
17
18
19
20
21
22
23
24
25
26
27
28
29
30
31

A 62-year-old man with a long history of hypertension comes to the clinic for a routine physical examination. Blood pressure is 150/90 mm Hg and heart rate is 74/min and regular. Cardiac auscultation reveals a low-frequency, presystolic sound that immediately precedes the S1 heart sound and is best heard during expiration when the patient is lying on his left side. Chest x-ray reveals extensive calcification around the mitral and aortic valves. Which of the following is the most likely explanation for the additional heart sound?

A. Increased flow velocity through the aortic valve

B. Increased stiffness of the left ventricular wall

C. Rapid passive filling of the ventricles

D. Restricted motion of the aortic valve cusps

E. Systolic anterior motion of the mitral valve

Submit

A 62-year-old man with a long history of hypertension comes to the clinic for a routine physical examination. Blood pressure is 150/90 mm Hg and heart rate is 74/min and regular. Cardiac auscultation reveals a low-frequency, presystolic sound that immediately precedes the S1 heart sound and is best heard during expiration when the patient is lying on his left side. Chest x-ray reveals extensive calcification around the mitral and aortic valves. Which of the following is the most likely explanation for the additional heart sound?

- A. Increased flow velocity through the aortic valve (3%)
- ✓ B. Increased stiffness of the left ventricular wall (67%)
- C. Rapid passive filling of the ventricles (8%)
- D. Restricted motion of the aortic valve cusps (12%)
- E. Systolic anterior motion of the mitral valve (8%)

Omitted
Correct answer
B

67%
Answered correctly

02 secs
Time Spent

04/25/2020
Last Updated

Explanation

Gallop heart sounds			
	Features	**Normal**	**Abnormal/associated conditions**
Third heart sound	• Ventricular gallop sound (after S2) • Heard during rapid **passive filling** of ventricles in diastole	• Age <40	• Systolic heart failure • Mitral regurgitation

Gallop heart sounds			
	Features	**Normal**	**Abnormal/associated conditions**
Third heart sound (S3)	• Ventricular gallop sound (after S2) • Heard during rapid **passive filling** of ventricles in diastole • Sudden cessation of filling as ventricle reaches its elastic limit	• Age <40 • Pregnancy	• Systolic heart failure • Mitral regurgitation • High-output states
Fourth heart sound (S4)	• Atrial gallop sound (before S1) • Heard immediately after **atrial contraction** as blood is forced into a stiff ventricle	• Healthy **older** adults	• Younger adults, children • Diastolic dysfunction (eg, LVH)

LVH = left ventricular hypertrophy.

This patient has a **fourth heart sound (S4)** secondary to extensive left ventricular hypertrophy from long-standing hypertension (**hypertensive heart disease**). The calcifications revealed on chest x-ray likely represent degenerative mitral and aortic valve calcification, which is associated with systemic hypertension.

An S4 is a sign of **diastolic dysfunction**. It occurs due to a sudden rise in end-diastolic ventricular pressure caused by **atrial contraction** against a ventricle that has reached its elastic limit. An S4 may be present in any condition that causes **reduced ventricular compliance** (eg, hypertensive heart disease, aortic stenosis, hypertrophic cardiomyopathy). It is heard as a **low-frequency, late diastolic sound** that occurs just prior to the first heart sound (S1) after the onset of the P wave on ECG (coinciding with the active phase of ventricular filling).

A left-sided S4 is best heard with the bell of the stethoscope over the cardiac apex with the patient in the left lateral decubitus position; it will intensify during expiration due to increased blood flow from the lungs to the left atrium.

(Choice A) Increased flow velocity through the aortic valve would produce a crescendo-decrescendo ejection murmur during systole (after S1 and before S2) similar to the murmur of aortic stenosis.

(Choice C) Sudden cessation of passive ventricular filling causes a diastolic third heart sound (S3) that is heard shortly after S2. It is often heard

LVH = left ventricular hypertrophy.

This patient has a **fourth heart sound (S4)** secondary to extensive left ventricular hypertrophy from long-standing hypertension (**hypertensive heart disease**). The calcifications revealed on chest x-ray likely represent degenerative mitral and aortic valve calcification, which is associated with systemic hypertension.

An S4 is a sign of **diastolic dysfunction**. It occurs due to a sudden rise in end-diastolic ventricular pressure caused by **atrial contraction** against a ventricle that has reached its elastic limit. An S4 may be present in any condition that causes **reduced ventricular compliance** (eg, hypertensive heart disease, aortic stenosis, hypertrophic cardiomyopathy). It is heard as a **low-frequency, late diastolic sound** that occurs just prior to the first heart sound (S1) after the onset of the P wave on ECG (coinciding with the active phase of ventricular filling).

A left-sided S4 is best heard with the bell of the stethoscope over the cardiac apex with the patient in the left lateral decubitus position; it will intensify during expiration due to increased blood flow from the lungs to the left atrium.

(Choice A) Increased flow velocity through the aortic valve would produce a crescendo-decrescendo ejection murmur during systole (after S1 and before S2) similar to the murmur of aortic stenosis.

(Choice C) Sudden cessation of passive ventricular filling causes a diastolic third heart sound (S3) that is heard shortly after S2. It is often heard in patients with systolic heart failure (eg, dilated cardiomyopathy), ventricular volume overload (eg, mitral regurgitation), and in high-output cardiac states (eg, pregnancy, thyrotoxicosis).

(Choice D) Restricted motion of the aortic valve cusps (due to scarring/thickening) can lead to aortic stenosis and/or aortic regurgitation and may be associated with a high-frequency aortic ejection click. The ejection click is heard after S1 just before the systole murmur of aortic stenosis; the diastolic murmur of aortic regurgitation begins immediately after S2.

(Choice E) Systolic anterior motion (SAM) of the mitral valve occurs in patients with hypertrophic cardiomyopathy and can cause eccentric mitral regurgitation and exacerbation of left ventricular outflow tract obstruction. However, these would result in systolic murmurs (after S1 and before S2).

Educational objective:
A low-frequency, late diastolic sound on cardiac auscultation that immediately precedes the first heart sound (S1) is most often a fourth heart sound (S4). An abnormal S4 can be heard in patients with reduced ventricular compliance (eg, hypertensive heart disease, aortic stenosis,

1 2 3 4 5 6 7 8 9 10 11 12 13 14 15 16 17 18 19 20 21 22 23 24 25 26 27 28 29 30 31

a ventricle that has reached its elastic limit. An S4 may be present in any condition that causes **reduced ventricular compliance** (eg, hypertensive heart disease, aortic stenosis, hypertrophic cardiomyopathy). It is heard as a **low-frequency, late diastolic sound** that occurs just prior to the first heart sound (S1) after the onset of the P wave on ECG (coinciding with the active phase of ventricular filling).

A left-sided S4 is best heard with the bell of the stethoscope over the cardiac apex with the patient in the left lateral decubitus position; it will intensify during expiration due to increased blood flow from the lungs to the left atrium.

(Choice A) Increased flow velocity through the aortic valve would produce a crescendo-decrescendo ejection murmur during systole (after S1 and before S2) similar to the murmur of aortic stenosis.

(Choice C) Sudden cessation of passive ventricular filling causes a diastolic third heart sound (S3) that is heard shortly after S2. It is often heard in patients with systolic heart failure (eg, dilated cardiomyopathy), ventricular volume overload (eg, mitral regurgitation), and in high-output cardiac states (eg, pregnancy, thyrotoxicosis).

(Choice D) Restricted motion of the aortic valve cusps (due to scarring/thickening) can lead to aortic stenosis and/or aortic regurgitation and may be associated with a high-frequency aortic ejection click. The ejection click is heard after S1 just before the systole murmur of aortic stenosis; the diastolic murmur of aortic regurgitation begins immediately after S2.

(Choice E) Systolic anterior motion (SAM) of the mitral valve occurs in patients with hypertrophic cardiomyopathy and can cause eccentric mitral regurgitation and exacerbation of left ventricular outflow tract obstruction. However, these would result in systolic murmurs (after S1 and before S2).

Educational objective:
A low-frequency, late diastolic sound on cardiac auscultation that immediately precedes the first heart sound (S1) is most often a fourth heart sound (S4). An abnormal S4 can be heard in patients with reduced ventricular compliance (eg, hypertensive heart disease, aortic stenosis, hypertrophic cardiomyopathy) due to a sudden rise in end-diastolic pressure with atrial contraction.

Pathophysiology	Cardiovascular System	Diastolic dysfunction
Subject	System	Topic

Copyright © UWorld. All rights reserved.

1
2
3
4
5
6
7
8
9
10
11
12
13
14
15
16
17
18
19
20
21
22
23
24
25
26
27
28
29
30
31

A 32-year-old woman comes to the office due to exertional dyspnea that has progressed over the last year. She can hardly walk a block without stopping to rest. The patient's mother died of "heart failure" at age 40. During auscultation, the pulmonary component of S2 is louder than the aortic component in the right and left second intercostal space. An accentuated impulse can also be palpated along the left upper sternal border. Chest x-ray shows clear lungs. Which of the following is the most likely cause of this patient's findings?

A. Hypertensive heart disease
B. Hypertrophic cardiomyopathy
C. Left bundle branch block
D. Pulmonary hypertension
E. Pulmonic valve stenosis

Submit

A 32-year-old woman comes to the office due to exertional dyspnea that has progressed over the last year. She can hardly walk a block without stopping to rest. The patient's mother died of "heart failure" at age 40. During auscultation, the pulmonary component of S2 is louder than the aortic component in the right and left second intercostal space. An accentuated impulse can also be palpated along the left upper sternal border. Chest x-ray shows clear lungs. Which of the following is the most likely cause of this patient's findings?

A. Hypertensive heart disease (0%)
B. Hypertrophic cardiomyopathy (4%)
C. Left bundle branch block (2%)
✓ D. Pulmonary hypertension (72%)
E. Pulmonic valve stenosis (19%)

Omitted
Correct answer
D

72%
Answered correctly

01 sec
Time Spent

03/16/2020
Last Updated

Explanation

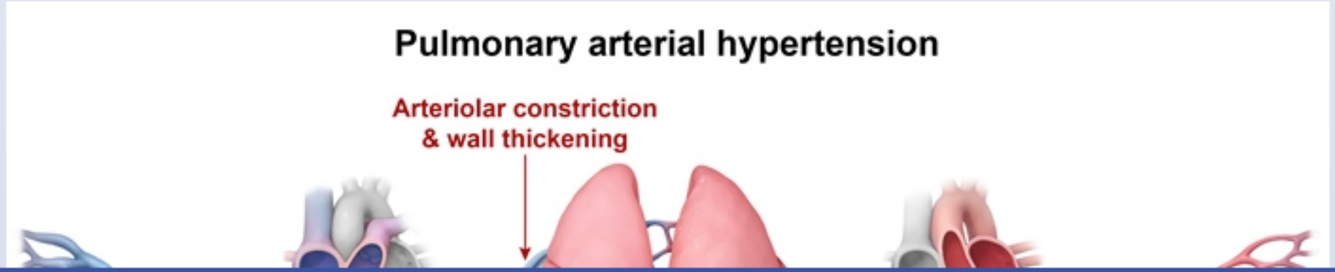

1
2
3
4
5
6
7
8
9
10
11
12
13
14
15
16
17
18
19
20
21
22
23
24
25
26
27
28
29
30
31

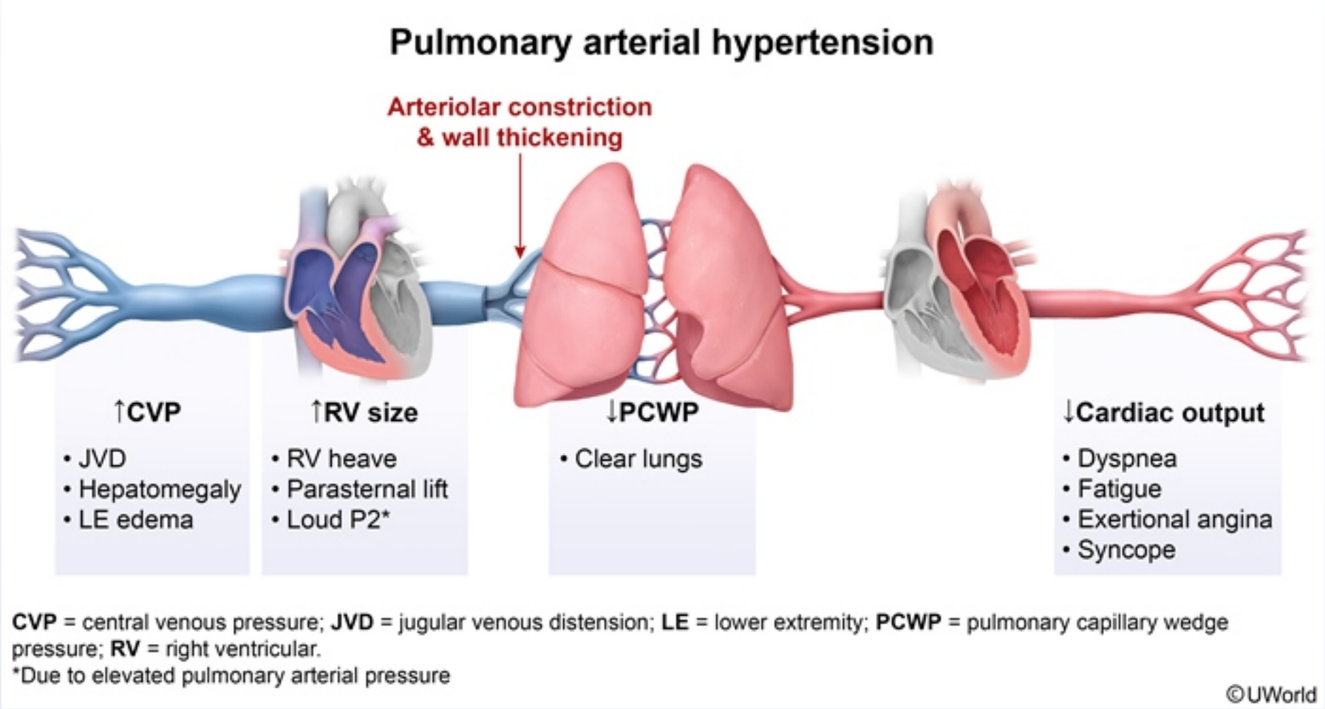

This patient's clinical presentation is consistent with **pulmonary hypertension**. The disease most commonly presents with progressive dyspnea, and patients may also experience exertional angina or syncope. Physical examination reveals a **loud pulmonic component (P2) of S2**, caused by forceful pulmonic valve closure in the setting of high pulmonary arterial pressure. In addition, the right ventricle becomes enlarged due to increased pressure load (ie, concentric right ventricular hypertrophy), which can create an accentuated impulse palpated at the left sternal border (**left parasternal lift** due to **right ventricular heave**).

Pulmonary arterial hypertension describes pulmonary hypertension directly caused by vascular remodeling of the small pulmonary arteries/arterioles; relatively young women are most commonly affected. Fatigue and exertional dyspnea are common and result from decreased cardiac output due to the inability of the right ventricle to pump blood through the lungs. Right-sided heart failure eventually develops, but because left ventricular function remains intact, there is an **absence of pulmonary edema** in pulmonary arterial hypertension.

This patient's clinical presentation is consistent with **pulmonary hypertension**. The disease most commonly presents with progressive dyspnea, and patients may also experience exertional angina or syncope. Physical examination reveals a **loud pulmonic component (P2) of S2**, caused by forceful pulmonic valve closure in the setting of high pulmonary arterial pressure. In addition, the right ventricle becomes enlarged due to increased pressure load (ie, concentric right ventricular hypertrophy), which can create an accentuated impulse palpated at the left sternal border (**left parasternal lift** due to **right ventricular heave**).

Pulmonary arterial hypertension describes pulmonary hypertension directly caused by vascular remodeling of the small pulmonary arteries/arterioles; relatively young women are most commonly affected. Fatigue and exertional dyspnea are common and result from decreased cardiac output due to the inability of the right ventricle to pump blood through the lungs. Right-sided heart failure eventually develops, but because left ventricular function remains intact, there is an **absence of pulmonary edema** in pulmonary arterial hypertension.

(Choice A) Hypertensive heart disease occurs as the result of prolonged systemic hypertension. It involves concentric left ventricular hypertrophy, leading to impaired ventricular compliance and diastolic heart failure. Pulmonary edema is expected with diastolic heart failure that is severe enough to cause dyspnea.

(Choice B) Hypertrophic cardiomyopathy typically demonstrates a crescendo-decrescendo systolic murmur best heard at the left sternal border. The murmur intensifies with maneuvers that decrease left ventricular blood volume (eg, abrupt standing, Valsalva strain phase).

(Choice C) Left bundle branch block can delay closure of the aortic valve, leading to later occurrence of the aortic component (A2) of S2 and narrowed or paradoxical splitting. However, left bundle branch block is unlikely to significantly affect the relative audible intensity of A2 and P2.

(Choice E) Pulmonic valve stenosis can delay the occurrence of P2 (later valve closure) but typically leads to a softer intensity of P2.

Educational objective:
Pulmonary hypertension can be recognized on physical examination by a loud pulmonic component of S2 and an accentuated, palpable impulse at the left sternal border (left parasternal lift due to right ventricular heave).

Pathophysiology	Cardiovascular System	Pulmonary Arterial Hypertension
Subject	System	Topic

Copyright © UWorld. All rights reserved.

This patient's clinical presentation is consistent with **pulmonary hypertension**. The disease most commonly presents with progressive dyspnea, and patients may also experience exertional angina or syncope. Physical examination reveals a **loud pulmonic component (P2) of S2**, caused by forceful pulmonic valve
increased pressure load (
(**left parasternal lift** due t

Pulmonary arterial hyperte
arteries/arterioles; relative
cardiac output due to the i
left ventricular function rer

(Choice A) Hypertensive
hypertrophy, leading to im
severe enough to cause d

(Choice B) Hypertrophic
The murmur intensifies wi

(Choice C) Left bundle b
narrowed or paradoxical s

(Choice E) Pulmonic valv

Educational objective:
Pulmonary hypertension c
at the left sternal border (l

Pathophysiology
Subject

Exhibit Display

Classification of pulmonary hypertension

Pulmonary arterial hypertension (Group 1)	• Primary change in pulmonary arteries ◦ Hereditary (eg, *BMPR2* mutation) ◦ Connective tissue disease (eg, RA, SS) ◦ HIV infection • Treatment targeted at endothelial dysfunction
Pulmonary hypertension (Groups 2-5)	• Secondary to another disease process ◦ Left-sided heart failure ◦ Chronic lung disease/hypoxia ◦ Chronic pulmonary thromboembolism • Treatment aimed at underlying disease

RA = rheumatoid arthritis; **SS** = systemic sclerosis.

Add To New Card | Existing Card

Copyright © UWorld. All rights reserved.

This patient's clinical presentation is consistent with **pulmonary hypertension**. The disease most commonly presents with progressive dyspnea,

Exhibit Display

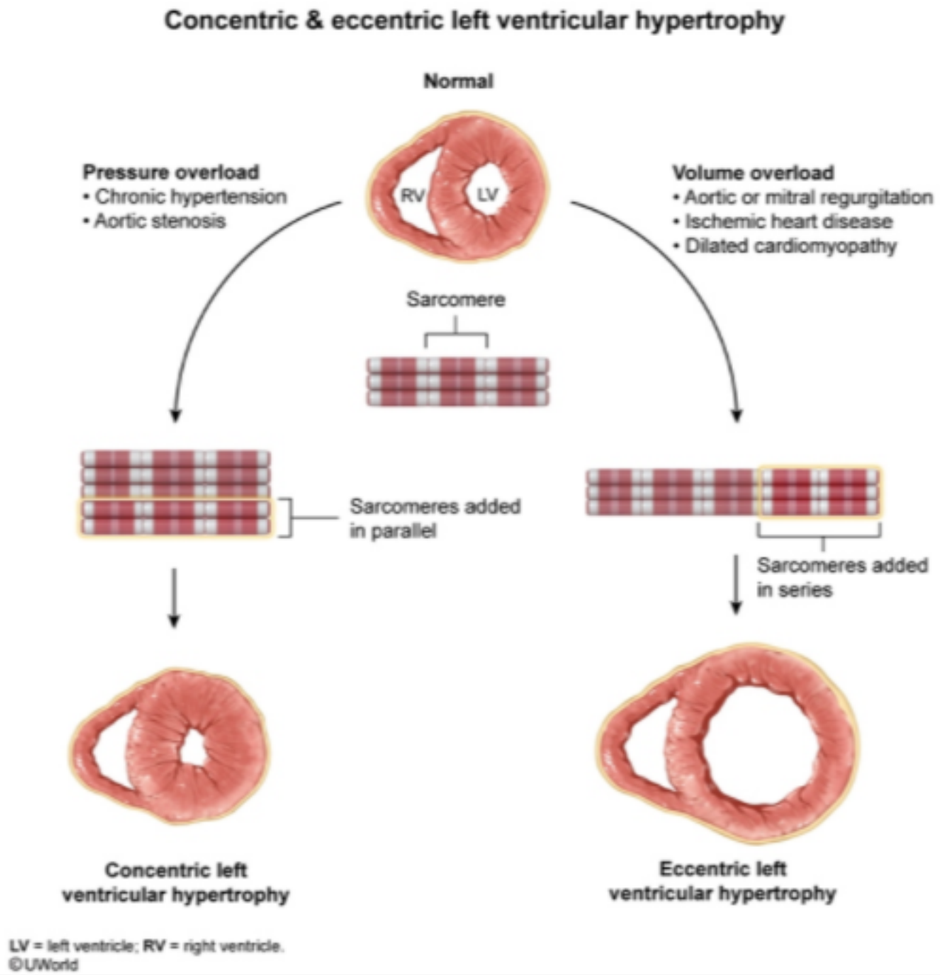

Zoom In | Zoom Out | Reset | Add To New Card | Existing Card

This patient's clinical presentation is consistent with **pulmonary hypertension**. The disease most commonly presents with progressive dyspnea,

Exhibit Display

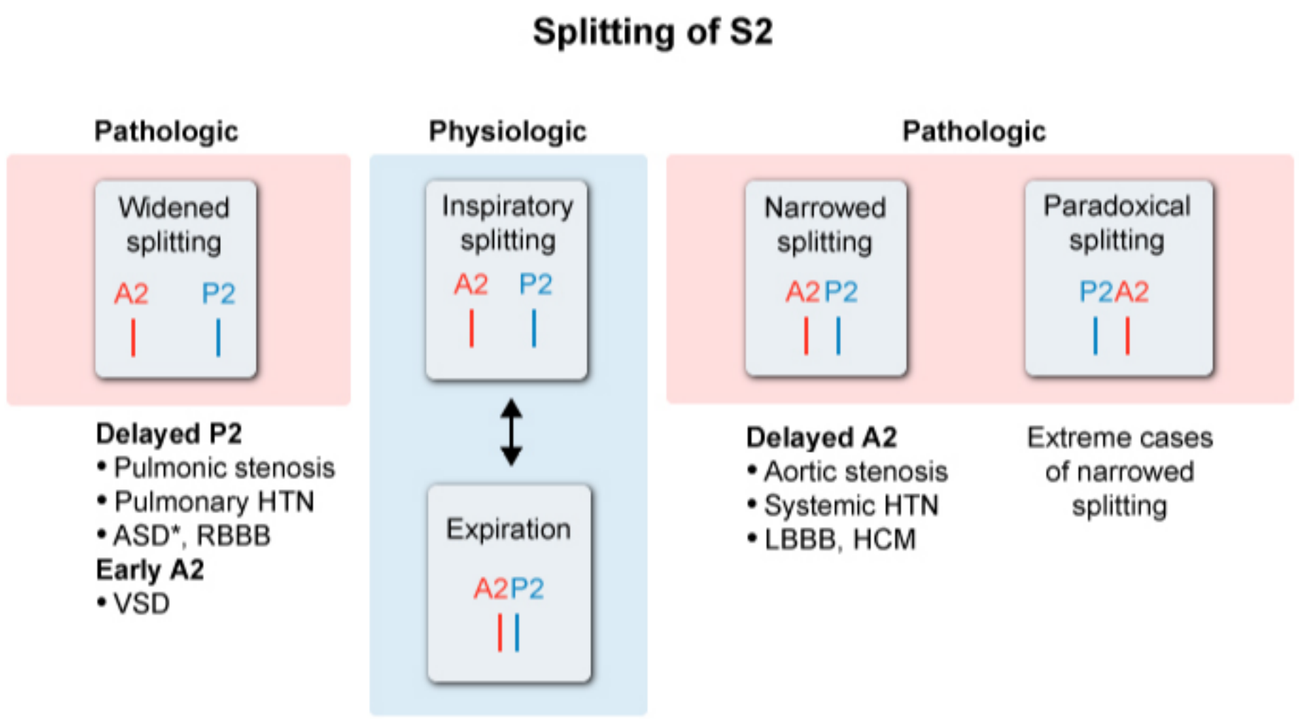

*Widened splitting is fixed throughout respiratory cycle.

ASD = atrial septal defect; **HCM** = hypertrophic cardiomyopathy; **HTN** = hypertension; **LBBB** = left bundle-branch block; **RBBB** = right bundle-branch block; **VSD** = ventricular septal defect.

©UWorld

Zoom In | Zoom Out | Reset | Add To New Card | Existing Card

1 2 3 4 5 6 7 8 9 10 11 12 13 14 15 16 17 18 19 20 21 22 23 24 25 26 27 28 29 30 31

An 81-year-old woman undergoes transcatheter aortic valve implantation through femoral access. She was diagnosed with severe calcific aortic stenosis 2 months ago after she began having shortness of breath with mild exertion. The vascular access is gained without complication, and the transcatheter valve is deployed under fluoroscopic guidance. The following hemodynamic changes are observed:

	Before deployment	After deployment
Diastolic blood pressure	76 mm Hg	44 mm Hg
Left ventricular end-diastolic pressure	12 mm Hg	25 mm Hg

Which of the following complications should be suspected in this patient?

A. Aortic regurgitation
B. Mitral stenosis
C. Prosthetic valve thrombosis
D. Retroperitoneal bleeding
E. Ventricular septal perforation

Submit

1 2 3 4 5 6 7 8 9 10 11 12 13 14 15 16 17 18 19 20 21 22 23 24 25 26 27 28 29 30 31

An 81-year-old woman undergoes transcatheter aortic valve implantation through femoral access. She was diagnosed with severe calcific aortic stenosis 2 months ago after she began having shortness of breath with mild exertion. The vascular access is gained without complication, and the transcatheter valve is deployed under fluoroscopic guidance. The following hemodynamic changes are observed:

	Before deployment	After deployment
Diastolic blood pressure	76 mm Hg	44 mm Hg
Left ventricular end-diastolic pressure	12 mm Hg	25 mm Hg

Which of the following complications should be suspected in this patient?

- A. Aortic regurgitation (65%)
- B. Mitral stenosis (6%)
- C. Prosthetic valve thrombosis (14%)
- D. Retroperitoneal bleeding (5%)
- E. Ventricular septal perforation (7%)

Omitted
Correct answer
A

65%
Answered correctly

02 secs
Time Spent

04/15/2020
Last Updated

Explanation

1
2
3
4
5
6
7
8
9
10
11
12
13
14
15
16
17
18
19
20
21
22
23
24
25
26
27
28
29
30
31

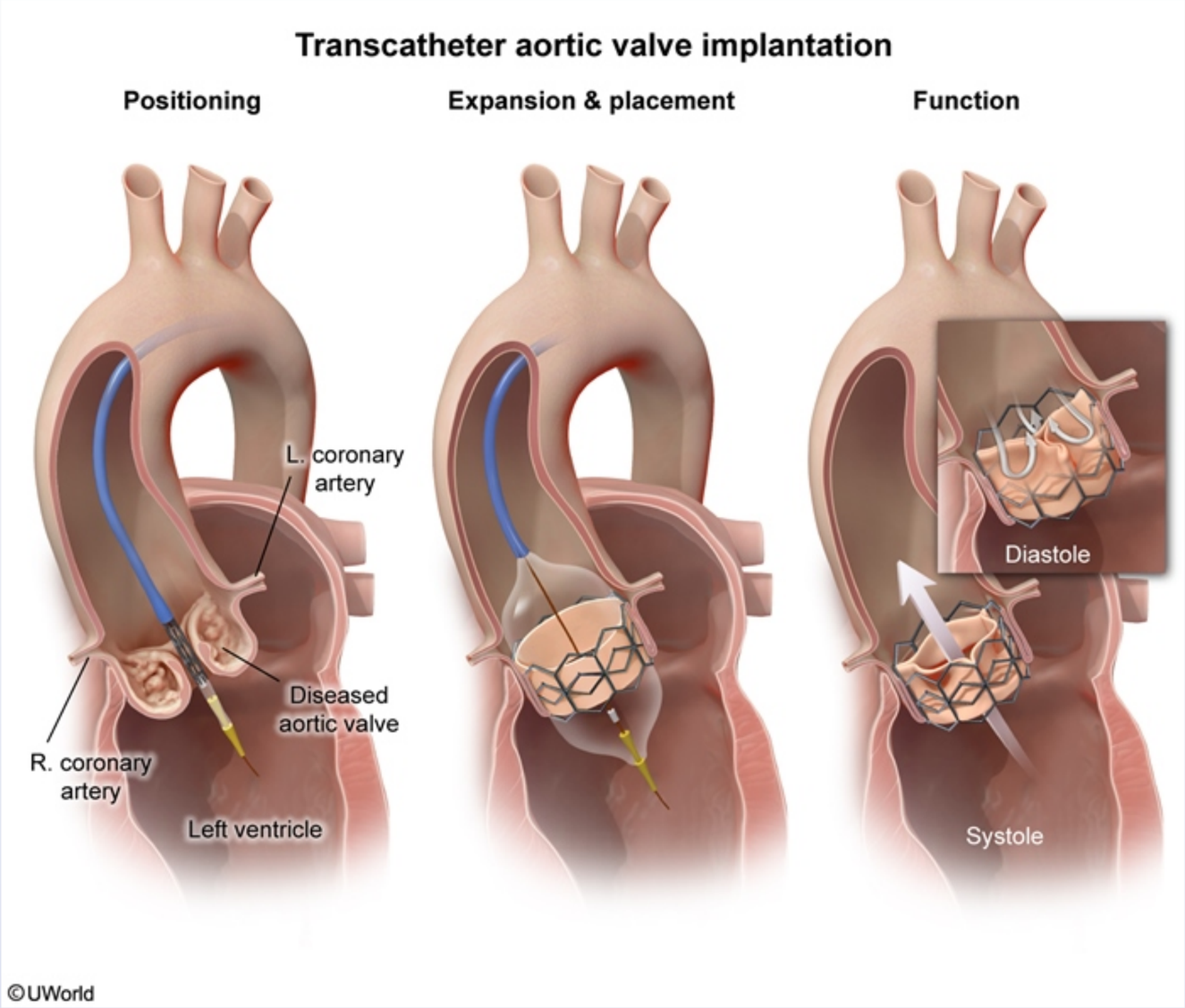

The prevalence of **severe aortic stenosis** (AS) increases with age, and definitive management necessitates surgical correction of the stenotic

©UWorld

The prevalence of **severe aortic stenosis** (AS) increases with age, and definitive management necessitates surgical correction of the stenotic valve. This often creates a complicated scenario because many **elderly patients** with severe AS have multiple other comorbidities, making them poor candidates for open surgical valve replacement due to unacceptably high operative risk. **Transcatheter aortic valve implantation** (TAVI) provides an alternative option for such patients; the catheter is advanced through the aorta to the aortic valve where a bioprosthetic valve is placed over the native aortic valve leaflets.

This patient's intraoperative pressure readings of **decreased diastolic blood pressure** and **increased LVEDP** (left ventricular end-diastolic pressure) are consistent with **aortic regurgitation**, a common complication of TAVI that results from improper sealing of the prosthetic valve to the native valve annulus, leading to paravalvular leak (blood leakage around the valve). Inappropriate valve size or improper valve positioning is often responsible.

Other intraoperative complications of TAVI include stroke (due to embolization of native valve calcification) and myocardial infarction (due to obstruction of coronary artery ostia by the implanted valve).

(Choice B) Worsening mitral stenosis can rarely occur following TAVI; such a disruption is expected to cause a decrease (rather than increase) in LVEDP due to obstructed diastolic filling.

(Choice C) Prosthetic valve thrombosis usually causes valvular obstruction but may sometimes cause valvular regurgitation with similar pressure findings to this patient. However, valvular thrombus requires time to develop and is not typically an immediate intraoperative complication.

(Choice D) Retroperitoneal bleeding can result from extension of a femoral artery hematoma and is a potential complication of any catheter-based procedure with femoral arterial access. The complication is likely to cause hemorrhagic shock with a drop in both systemic blood pressure and LVEDP.

(Choice E) Ventricular septal perforation is a potential complication of TAVI but is unlikely to cause the large and abrupt increase in LVEDP that occurred in this patient. Large perforation may eventually lead to biventricular failure and increased LVEDP, but no change or a small decrease in LVEDP is expected initially.

Educational objective:
Transcatheter aortic valve implantation (TAVI) allows for minimally invasive management of severe aortic stenosis in elderly patients who are unable to tolerate open surgical valve replacement. Paravalvular aortic regurgitation is a common complication of TAVI, resulting from improper

1 2 3 4 5 6 7 8 9 10 11 12 13 14 15 16 17 18 19 20 21 22 23 24 25 26 27 28 29 30 31

over the native aortic valve leaflets.

This patient's intraoperative pressure readings of **decreased diastolic blood pressure** and **increased LVEDP** (left ventricular end-diastolic pressure) are consistent with **aortic regurgitation**, a common complication of TAVI that results from improper sealing of the prosthetic valve to the native valve annulus, leading to paravalvular leak (blood leakage around the valve). Inappropriate valve size or improper valve positioning is often responsible.

Other intraoperative complications of TAVI include stroke (due to embolization of native valve calcification) and myocardial infarction (due to obstruction of coronary artery ostia by the implanted valve).

(Choice B) Worsening mitral stenosis can rarely occur following TAVI; such a disruption is expected to cause a decrease (rather than increase) in LVEDP due to obstructed diastolic filling.

(Choice C) Prosthetic valve thrombosis usually causes valvular obstruction but may sometimes cause valvular regurgitation with similar pressure findings to this patient. However, valvular thrombus requires time to develop and is not typically an immediate intraoperative complication.

(Choice D) Retroperitoneal bleeding can result from extension of a femoral artery hematoma and is a potential complication of any catheter-based procedure with femoral arterial access. The complication is likely to cause hemorrhagic shock with a drop in both systemic blood pressure and LVEDP.

(Choice E) Ventricular septal perforation is a potential complication of TAVI but is unlikely to cause the large and abrupt increase in LVEDP that occurred in this patient. Large perforation may eventually lead to biventricular failure and increased LVEDP, but no change or a small decrease in LVEDP is expected initially.

Educational objective:
Transcatheter aortic valve implantation (TAVI) allows for minimally invasive management of severe aortic stenosis in elderly patients who are unable to tolerate open surgical valve replacement. Paravalvular aortic regurgitation is a common complication of TAVI, resulting from improper sealing of the prosthetic valve to the native aortic valve annulus.

References

- Transcatheter aortic valve implantation: technique, complications and perspectives.

over the native aortic valve leaflets.

Exhibit Display

Aortic regurgitation due to paravalvular leak

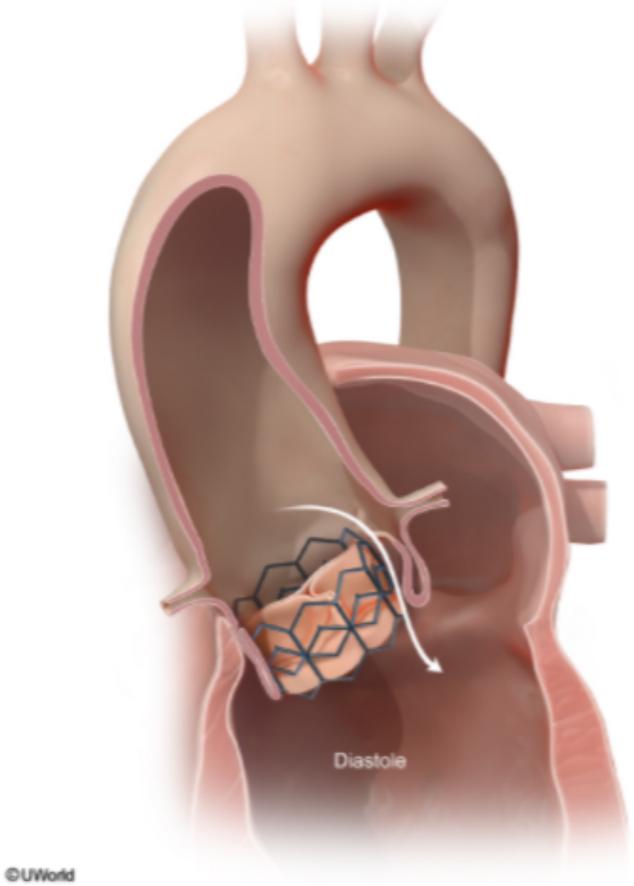

Zoom In | Zoom Out | Reset | Add To New Card | Existing Card

A 27-year-old woman comes to the office due to exertional dyspnea over the past 3 months. The patient initially had shortness of breath during exercise but now becomes dyspneic with routine activities. She has had no cough, fever, or leg swelling but has noticed increased fatigue over this time. The patient does not use tobacco, alcohol, or illicit drugs. Vital signs are within normal limits. Physical examination reveals a loud pulmonic component of S2 but is otherwise unremarkable. Chest x-ray is normal. Echocardiography shows elevated pulmonary artery systolic pressure and right ventricular hypertrophy. Left ventricular structure and function are normal. Which of the following patterns of chemical mediators is most likely present in this patient's pulmonary arteries?

	Prostacyclin	Thromboxane	Nitric Oxide
A.	Decreased	Increased	Decreased
B.	Decreased	Increased	Increased
C.	Increased	Decreased	Decreased
D.	Increased	Decreased	Increased
E.	Decreased	Decreased	Decreased

Submit

A 27-year-old woman comes to the office due to exertional dyspnea over the past 3 months. The patient initially had shortness of breath during exercise but now becomes dyspneic with routine activities. She has had no cough, fever, or leg swelling but has noticed increased fatigue over this time. The patient does not use tobacco, alcohol, or illicit drugs. Vital signs are within normal limits. Physical examination reveals a loud pulmonic component of S2 but is otherwise unremarkable. Chest x-ray is normal. Echocardiography shows elevated pulmonary artery systolic pressure and right ventricular hypertrophy. Left ventricular structure and function are normal. Which of the following patterns of chemical mediators is most likely present in this patient's pulmonary arteries?

	Prostacyclin	Thromboxane	Nitric Oxide
✓ A. (60%)	Decreased	Increased	Decreased
B. (5%)	Decreased	Increased	Increased
C. (11%)	Increased	Decreased	Decreased
D. (13%)	Increased	Decreased	Increased
E. (8%)	Decreased	Decreased	Decreased

Omitted
Correct answer
A

60%
Answered correctly

02 secs
Time Spent

03/04/2020
Last Updated

Explanation

1
2
3
4
5
6
7
8
9
10
11
12
13
14
15
16
17
18
19
20
21
22
23
24
25
26
27
28
29
30
31

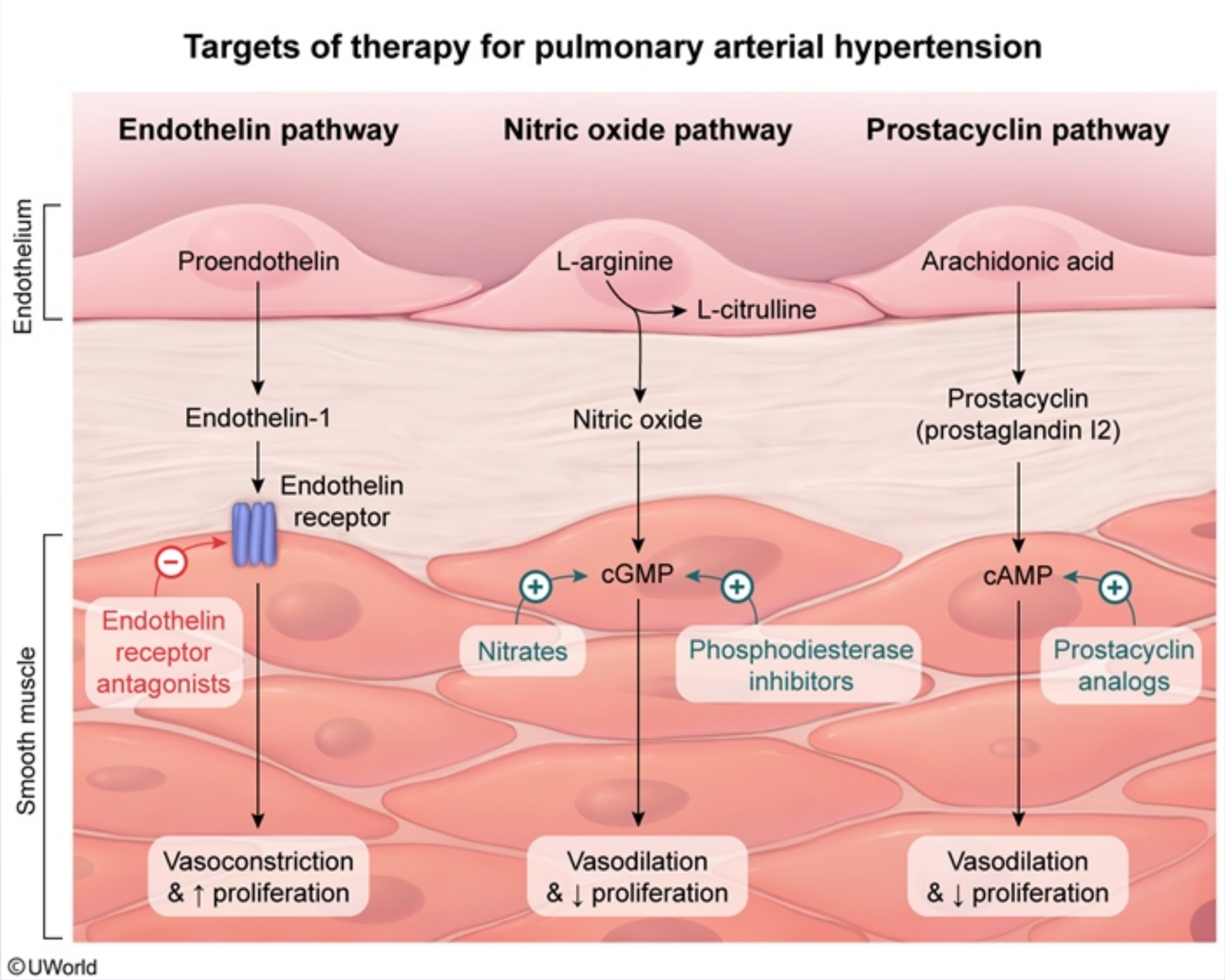

This young woman with progressive dyspnea and fatigue and a loud pulmonic component of S2 on physical examination likely has **pulmonary arterial hypertension** (PAH). PAH results from progressive remodeling of the small- and medium-sized pulmonary arteries/arterioles. Endothelial dysfunction leads to an **increase in vasoconstrictive**, **proproliferative mediators** (eg, endothelin, thromboxane A2) and a **decrease in**

1
2
3
4
5
6
7
8
9
10
11
12
13
14
15
16
17
18
19
20
21
22
23
24
25
26
27
28
29
30
31

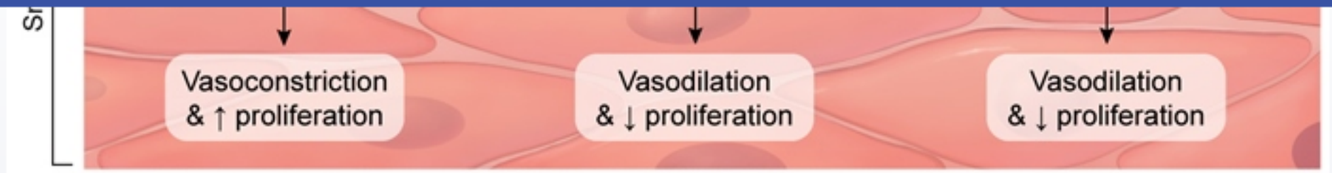

©UWorld

This young woman with progressive dyspnea and fatigue and a loud pulmonic component of S2 on physical examination likely has **pulmonary arterial hypertension** (PAH). PAH results from progressive remodeling of the small- and medium-sized pulmonary arteries/arterioles. Endothelial dysfunction leads to an **increase in vasoconstrictive**, **proproliferative mediators** (eg, endothelin, thromboxane A2) and a **decrease in vasodilative**, **antiproliferative mediators** (eg, nitric oxide, prostacyclin). The relative imbalance of these mediators leads to **vasoconstriction** and **smooth muscle proliferation** with intimal thickening of the vascular walls; consequently, there is increased pulmonary vascular resistance and elevated pulmonary arterial pressure. Over time, the right ventricle is unable to pump against the increased afterload, and right-sided heart failure develops.

Medical therapy for PAH targets the mediator imbalance created by endothelial dysfunction. Endothelin receptor antagonists (eg, bosentan) are used to reduce vasoconstriction, while prostacyclin analogues (eg, epoprostenol) and nitric oxide–enhancing agents (eg, sildenafil) are used to promote vasodilation. All of these agents help reduce tissue proliferation.

(Choices B, C, D, and E) These changes in the levels of prostacyclin, thromboxane, and nitric oxide are not consistent with the changes that occur in PAH.

Educational objective:
Pulmonary arterial hypertension results from endothelial dysfunction that leads to an increase in vasoconstrictive, proproliferative mediators (eg, endothelin, thromboxane A2) and a decrease in vasodilative, antiproliferative mediators (eg, nitric oxide, prostacyclin). The relative imbalance in these mediators leads to vasoconstriction and intimal-wall thickening with a consequent increase in pulmonary vascular resistance.

Pathophysiology	Cardiovascular System	Pulmonary Arterial Hypertension
Subject	System	Topic

Copyright © UWorld. All rights reserved.

1
2
3
4
5
6
7
8
9
10
11
12
13
14
15
16
17
18
19
20
21
22
23
24
25
26
27
28
29
30
31

The following vignette applies to the next **2** items. The items in the set must be answered in sequential order. Once you click **Proceed to Next Item**, you will not be able to add or change an answer.

A 41-year-old man comes to the emergency department due to 3 days of fever, chills, and nonproductive cough. The patient has also felt tired and weak during this period. He has a history of injection drug use and has been hospitalized several times for injection site cellulitis. Temperature is 38.3 C (101 F), blood pressure is 125/72 mm Hg, and pulse is 112/min and regular. Cardiopulmonary auscultation reveals scattered rhonchi and a cardiac murmur, which were not previously present. Laboratory evaluation shows leukocytosis, and chest x-ray reveals nodular opacities.

Item 1 of 2

Echocardiography of this patient is most likely to reveal which of the following findings?

- A. Aortic regurgitation
- B. Aortic stenosis
- C. Interventricular septal defect
- D. Mitral regurgitation
- E. Pulmonic stenosis
- F. Tricuspid regurgitation

Submit

1 2 3 4 5 6 7 8 9 10 11 12 13 14 15 16 17 18 19 20 21 22 23 24 25 26 27 28 29 30 31

The following vignette applies to the next **2** items. The items in the set must be answered in sequential order. Once you click **Proceed to Next Item**, you will not be able to add or change an answer.

A 41-year-old man comes to the emergency department due to 3 days of fever, chills, and nonproductive cough. The patient has also felt tired and weak during this period. He has a history of injection drug use and has been hospitalized several times for injection site cellulitis. Temperature is 38.3 C (101 F), blood pressure is 125/72 mm Hg, and pulse is 112/min and regular. Cardiopulmonary auscultation reveals scattered rhonchi and a cardiac murmur, which were not previously present. Laboratory evaluation shows leukocytosis, and chest x-ray reveals nodular opacities.

Item 1 of 2

Echocardiography of this patient is most likely to reveal which of the following findings?

- A. Aortic regurgitation (0%)
- B. Aortic stenosis (0%)
- C. Interventricular septal defect (0%)
- D. Mitral regurgitation (8%)
- E. Pulmonic stenosis (0%)
- ✓ F. Tricuspid regurgitation (89%)

Omitted
Correct answer
F

89%
Answered correctly

02 secs
Time Spent

04/20/2020
Last Updated

Infective endocarditis in intravenous drug users	
Pathogenesis	• Injection of abrasive particulates → damaged valvular surface → increased bacterial adhesion • Right-sided valves at greatest risk (particularly tricuspid) ◦ Pulmonary capillaries prevent particulates from reaching left heart • Most common organism: *Staphylococcus aureus* (injected from skin)
Manifestations	• Nonspecific symptoms (eg, fever, chills, weight loss) • Septic pulmonary emboli (eg, cough, pleuritic pain, dyspnea) • Right-sided heart failure (eg, elevated jugular venous pressure, edema)

Injection drug use is associated with the concurrent injection of **abrasive particulate matter** and **microorganisms** into the bloodstream. Over time, injected particulate material denudes the surface of the heart valves, thereby creating a variegated surface for microorganism attachment. This dramatically increases the risk of **infective endocarditis** (IE). The **right-sided valves** are at greatest risk because pulmonary capillaries prevent large particulate matter from reaching the left side of the heart; the **tricuspid valve** is involved in >90% of cases.

Common manifestations of tricuspid valve IE include right-sided heart failure (eg, jugular venous distension, ascites, lower extremity edema) and/or **septic pulmonary emboli** (eg, multiple pulmonary nodules on chest x-ray). Cardiopulmonary evaluation usually reveals a blowing, holosystolic murmur heard best along the left lower sternal border that is intensified during inspiration and reduced with standing. Crackles and rhonchi are often present (in the setting of septic emboli). **Echocardiography** will show valvular vegetations, which frequently result in **regurgitation** due to incomplete valve closure.

(Choices A and D) Aortic and mitral valve IE is less common in injection drug users than tricuspid valve IE because the pulmonary vasculature filters out particulate matter and microorganisms. In addition, septic emboli from the left-side of the heart usually lodge in capillary beds (eg, cutaneous) prior to returning to the right-side of the heart; therefore, septic pulmonary emboli are less common.

(Choice B) Aortic stenosis is common in older adults and usually causes dyspnea, angina, or syncope. Stenosis is not typically seen in IE, and left-sided IE does not usually present with pulmonary septic emboli.

(Choice C) An interventricular septal defect (VSD) can cause a left-to-right cardiac shunt, which can limit systemic blood flow and result in

Injection drug use is associated with the concurrent injection of **abrasive particulate matter** and **microorganisms** into the bloodstream. Over time, injected particulate material denudes the surface of the heart valves, thereby creating a variegated surface for microorganism attachment. This dramatically increases the risk of **infective endocarditis** (IE). The **right-sided valves** are at greatest risk because pulmonary capillaries prevent large particulate matter from reaching the left side of the heart; the **tricuspid valve** is involved in >90% of cases.

Common manifestations of tricuspid valve IE include right-sided heart failure (eg, jugular venous distension, ascites, lower extremity edema) and/or **septic pulmonary emboli** (eg, multiple pulmonary nodules on chest x-ray). Cardiopulmonary evaluation usually reveals a blowing, holosystolic murmur heard best along the left lower sternal border that is intensified during inspiration and reduced with standing. Crackles and rhonchi are often present (in the setting of septic emboli). **Echocardiography** will show valvular vegetations, which frequently result in **regurgitation** due to incomplete valve closure.

(Choices A and D) Aortic and mitral valve IE is less common in injection drug users than tricuspid valve IE because the pulmonary vasculature filters out particulate matter and microorganisms. In addition, septic emboli from the left-side of the heart usually lodge in capillary beds (eg, cutaneous) prior to returning to the right-side of the heart; therefore, septic pulmonary emboli are less common.

(Choice B) Aortic stenosis is common in older adults and usually causes dyspnea, angina, or syncope. Stenosis is not typically seen in IE, and left-sided IE does not usually present with pulmonary septic emboli.

(Choice C) An interventricular septal defect (VSD) can cause a left-to-right cardiac shunt, which can limit systemic blood flow and result in pulmonary hypertension. A VSD is less likely in this patient with intravenous drug use, signs of infection, and likely septic pulmonary emboli.

(Choice E) Pulmonary valve IE sometimes occurs in injection drug users; however, it generally causes pulmonary valve regurgitation (not stenosis) due to incomplete valvular closure. Patients with pulmonary stenosis often have signs of right-sided heart failure (eg, edema, ascites, elevated jugular venous distension) or dyspnea.

Educational objective:
Patients who inject drugs are at high risk for infective endocarditis (IE) due to the concurrent injection of abrasive particulate material and microorganisms. Most cases arise on the tricuspid valve. Patients with tricuspid valve IE often present with right-sided heart failure or septic pulmonary emboli. Echocardiography generally reveals valvular vegetations and incomplete valve closure (regurgitation).

1
2
3
4
5
6
7
8
9
10
11
12
13
14
15
16
17
18
19
20
21
22
23
24
25
26
27
28
29
30
31

Item 2 of 2

The patient is started on an intravenous antibiotic for his condition but develops severe pruritus and a rash immediately upon infusion. The antibiotic used in this patient demonstrates the following dynamics when tested in several healthy volunteers:

Which of the following antibiotics was most likely given to this patient?

A. Gentamicin
B. Imipenem
C. Penicillin G
D. Trimethoprim-sulfamethoxazole
E. Vancomycin

Submit

1
2
3
4
5
6
7
8
9
10
11
12
13
14
15
16
17
18
19
20
21
22
23
24
25
26
27
28
29
30
31

Item 2 of 2

The patient is started on an intravenous antibiotic for his condition but develops severe pruritus and a rash immediately upon infusion. The antibiotic used in this patient demonstrates the following dynamics when tested in several healthy volunteers:

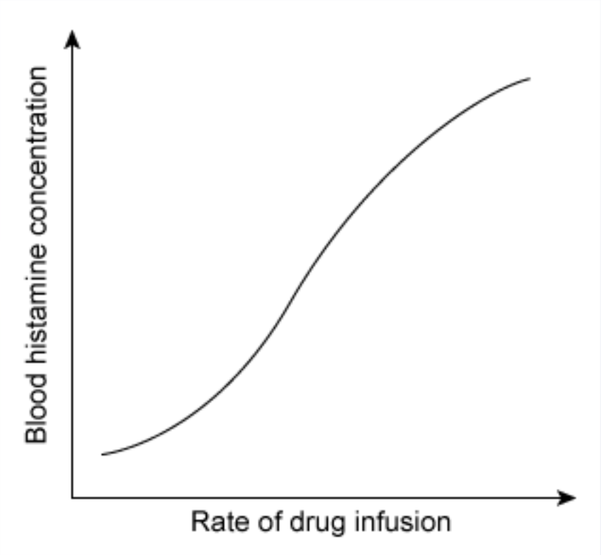

Which of the following antibiotics was most likely given to this patient?

A. Gentamicin
B. Imipenem
C. Penicillin G
D. Trimethoprim-sulfamethoxazole
E. Vancomycin

antibiotic used in this patient demonstrates the following dynamics when tested in several healthy volunteers:

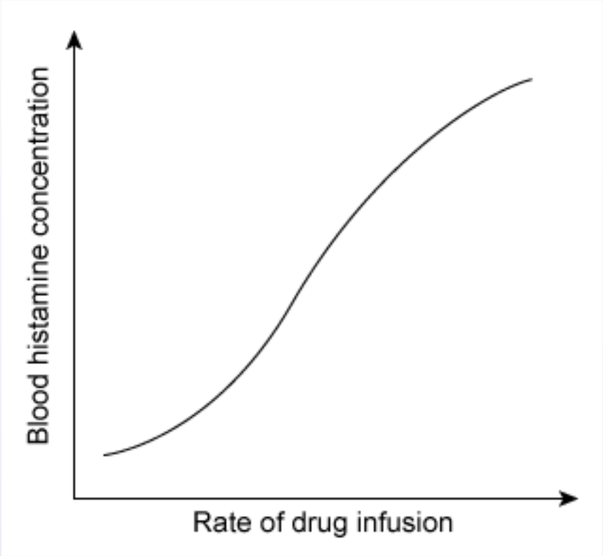

Which of the following antibiotics was most likely given to this patient?

A. Gentamicin
B. Imipenem
C. Penicillin G
D. Trimethoprim-sulfamethoxazole
E. Vancomycin

Submit

antibiotic used in this patient demonstrates the following dynamics when tested in several healthy volunteers:

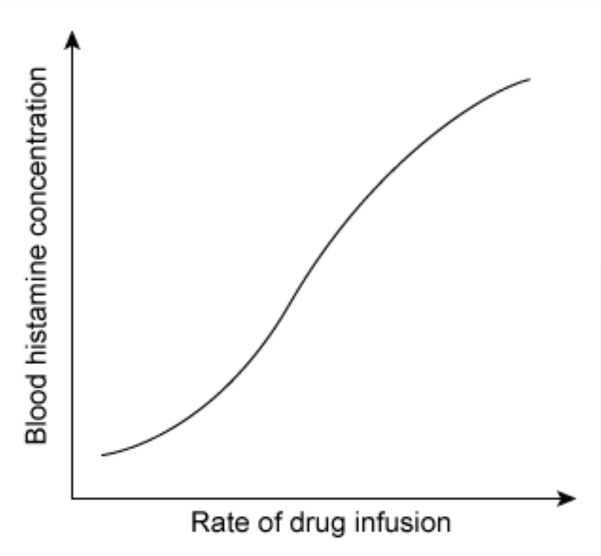

Which of the following antibiotics was most likely given to this patient?

- A. Gentamicin (1%)
- B. Imipenem (1%)
- C. Penicillin G (25%)
- D. Trimethoprim-sulfamethoxazole (3%)
- ✓ E. Vancomycin (67%)

Omitted
Correct answer

67%
Answered correctly

06 secs
Time Spent

04/20/2020
Last Updated

1
2
3
4
5
6
7
8
9
10
11
12
13
14
15
16
17
18
19
20
21
22
23
24
25
26
27
28
29
30
31

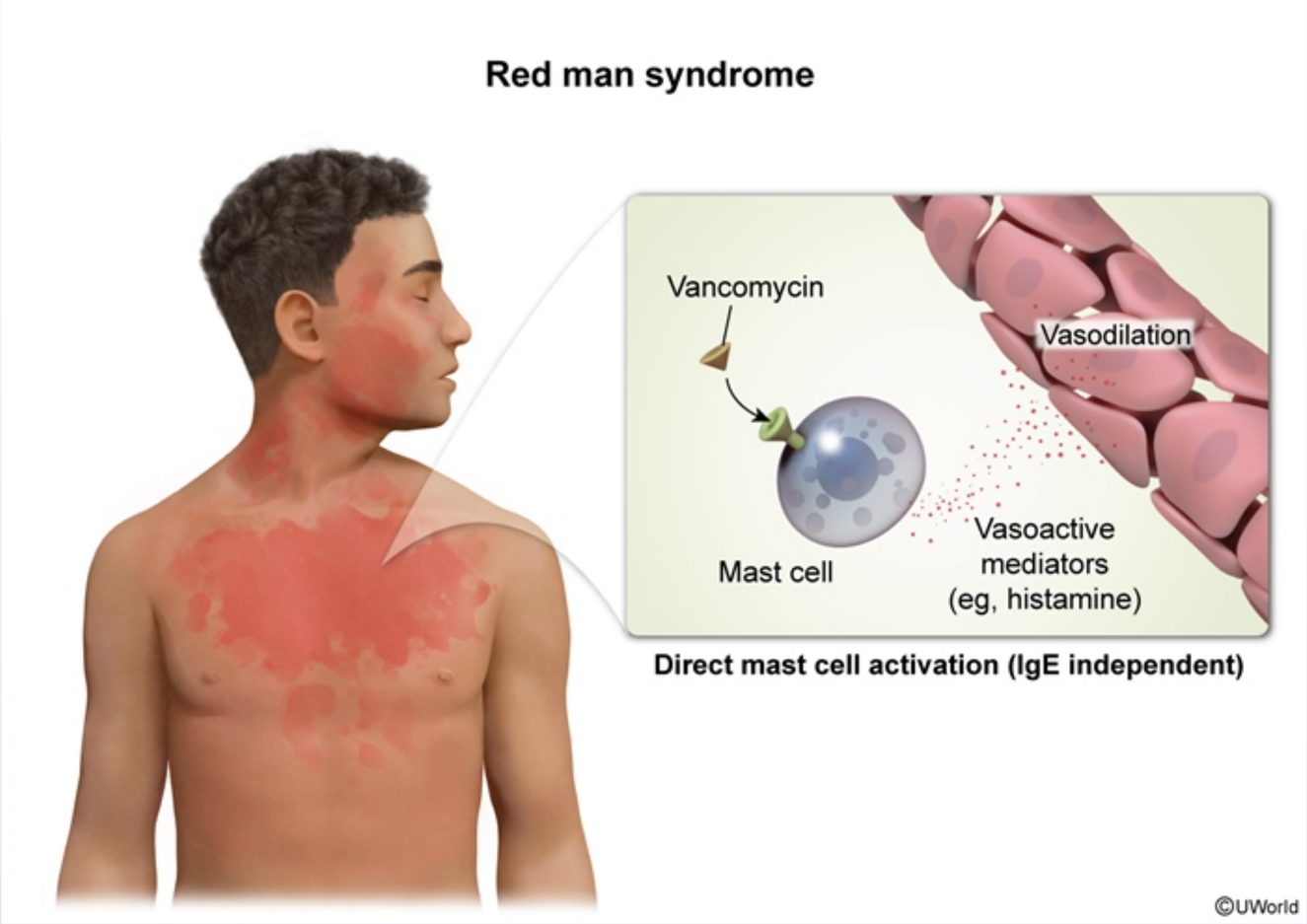

Vancomycin inhibits cell wall synthesis of gram-positive bacteria by binding to the D-Alanine-D-Alanine terminus of nascent peptidoglycan pentapeptides, thereby inhibiting peptidoglycan elongation and cross-linking. Although vancomycin is generally well tolerated, a minority of patients develop **"red man" syndrome** (RMS), a **non-allergic drug reaction** that occurs when vancomycin is **infused too rapidly**.

RMS arises due to the direct activation of mast cells by vancomycin, which results in the release of vasoactive mediators (eg, **histamine**).

1
2
3
4
5
6
7
8
9
10
11
12
13
14
15
16
17
18
19
20
21
22
23
24
25
26
27
28
29
30
31

Vancomycin inhibits cell wall synthesis of gram-positive bacteria by binding to the D-Alanine-D-Alanine terminus of nascent peptidoglycan pentapeptides, thereby inhibiting peptidoglycan elongation and cross-linking. Although vancomycin is generally well tolerated, a minority of patients develop **"red man" syndrome** (RMS), a **non-allergic drug reaction** that occurs when vancomycin is **infused too rapidly**.

RMS arises due to the direct activation of mast cells by vancomycin, which results in the release of vasoactive mediators (eg, **histamine**). Manifestations typically arise within seconds/minutes of vancomycin infusion and include **flushing, erythema, and pruritis**, primarily in the neck and upper torso. Most cases resolve spontaneously with the cessation of vancomycin and the administration of diphenhydramine. Because RMS is not a true allergic reaction **(not Ig-E mediated)**, vancomycin can be safely resumed at a **slower rate** once the symptoms have resolved.

(Choice A) Gentamicin, an aminoglycoside antibiotic, is associated with ototoxicity and nephrotoxicity.

(Choices B and C) Beta-lactam antibiotics (eg, imipenem, penicillin) generally cause IgE-mediated hypersensitivity reactions. In allergic reactions, histamine release is not linked to infusion rate, and patients usually have a history of previous exposure.

(Choice D) Trimethoprim-sulfamethoxazole can occasionally cause megaloblastic anemia, thrombocytopenia, leukopenia, and/or toxic epidermal necrolysis.

Educational objective:
Rapid infusion of vancomycin can lead to the direct activation of mast cells, which results in a massive release of histamine. This causes "red man" syndrome, a nonallergic reaction marked by flushing, erythema, and pruritis within seconds or minutes of vancomycin infusion. Because this reaction is not IgE-mediated, vancomycin can be safely resumed at a slower rate once symptoms have resolved.

Pathophysiology	Cardiovascular System	Vancomycin
Subject	System	Topic

Copyright © UWorld. All rights reserved.

A 64-year-old man comes to the emergency department due to chest discomfort and shortness of breath. Medical history includes hypertension, type 2 diabetes mellitus, and severe osteoarthritis of the left knee. The patient is an active smoker with a 20-pack-year smoking history. He undergoes dobutamine infusion with simultaneous cardiac imaging. The following is seen:

- Before infusion: normal left ventricular contractility, ejection fraction 60%
- During infusion: decreased apical contractility, ejection fraction 45%
- Five minutes after infusion: normal left ventricular contractility, ejection fraction 60%

Which of the following best explains the observed findings?

A. Coronary artery occlusion due to plaque thrombosis

B. Coronary artery vasospasm

C. Focal myocardial fibrosis

D. Normal myocardial contractile response

E. Supply-demand mismatch due to fixed coronary stenosis

Submit

A 64-year-old man comes to the emergency department due to chest discomfort and shortness of breath. Medical history includes hypertension, type 2 diabetes mellitus, and severe osteoarthritis of the left knee. The patient is an active smoker with a 20-pack-year smoking history. He undergoes dobutamine infusion with simultaneous cardiac imaging. The following is seen:

- Before infusion: normal left ventricular contractility, ejection fraction 60%
- During infusion: decreased apical contractility, ejection fraction 45%
- Five minutes after infusion: normal left ventricular contractility, ejection fraction 60%

Which of the following best explains the observed findings?

A. Coronary artery occlusion due to plaque thrombosis (9%)

B. Coronary artery vasospasm (10%)

C. Focal myocardial fibrosis (3%)

D. Normal myocardial contractile response (18%)

✓ E. Supply-demand mismatch due to fixed coronary stenosis (57%)

Omitted
Correct answer
E

57%
Answered correctly

02 secs
Time Spent

05/20/2020
Last Updated

Explanation

Stable angina results from **fixed coronary artery stenosis** in the setting of atherosclerotic coronary artery disease (CAD). Such a stenosis limits blood supply to the downstream myocardium, which, during periods of increased myocardial oxygen demand (eg, exercise), can cause a

Explanation

Stable angina results from **fixed coronary artery stenosis** in the setting of atherosclerotic coronary artery disease (CAD). Such a stenosis limits blood supply to the downstream myocardium, which, during periods of increased myocardial oxygen demand (eg, exercise), can cause a **mismatch of oxygen supply and demand** that manifests as anginal symptoms (eg, chest pain, shortness of breath).

Pharmacologic stress testing can be useful in diagnosing atherosclerotic CAD. Dobutamine, a beta-1 agonist, **increases heart rate and contractility** to mimic the increase in myocardial oxygen demand that occurs with exercise. Myocardium that is unable to obtain sufficient blood flow to meet the increased oxygen demand typically demonstrates a **transient decrease in contractility** (ie, wall motion defect), often leading to **reduced ejection fraction**. This patient with a transient wall motion defect localized to the cardiac apex most likely has a fixed atherosclerotic lesion that limits blood flow to that area of myocardium.

(Choice A) Coronary artery occlusion due to plaque rupture and thrombosis leads to acute myocardial infarction (MI). Because of total coronary artery occlusion and a completely blocked myocardial oxygen supply, a persistent (before, during, and after dobutamine infusion), rather than transient, wall motion defect would be expected.

(Choice B) Vasospastic angina is due to coronary artery vasospasm and can mimic stable angina that results from atherosclerotic CAD; however, vasospastic angina typically occurs in relatively young patients (age <50). In addition, dobutamine has only a small agonistic effect on alpha-1 receptors and is unlikely to trigger coronary vasospasm.

(Choice C) Focal myocardial fibrosis typically results from previous MI. Contractility is impaired in the fibrosed myocardium, leading to a persistent wall motion defect similar to that expected with acute MI.

(Choice D) In the normal state, dobutamine boosts myocardial contractility, and the rise in myocardial oxygen demand is met by increased myocardial oxygen supply via increased blood flow. Therefore, the normal response to dobutamine infusion is a transient increase in ejection fraction.

Educational objective:
Stable angina results from fixed coronary artery stenosis that limits blood flow to downstream myocardium, preventing the myocardial oxygen supply from increasing during exertion. Dobutamine mimics the effects of exercise and increases myocardial oxygen demand; it can be used during stress testing to provoke areas of ischemic myocardium, which can be recognized on imaging by a localized and transient decrease in

1 2 3 4 5 6 7 8 9 10 11 12 13 14 15 16 17 18 19 20 21 22 23 24 25 26 27 28 29 30 31

contractility to mimic the increase in myocardial oxygen demand that occurs with exercise. Myocardium that is unable to obtain sufficient blood flow to meet the increased oxygen demand typically demonstrates a **transient decrease in contractility** (ie, wall motion defect), often leading to **reduced ejection fraction**. This patient with a transient wall motion defect localized to the cardiac apex most likely has a fixed atherosclerotic lesion that limits blood flow to that area of myocardium.

(Choice A) Coronary artery occlusion due to plaque rupture and thrombosis leads to acute myocardial infarction (MI). Because of total coronary artery occlusion and a completely blocked myocardial oxygen supply, a persistent (before, during, and after dobutamine infusion), rather than transient, wall motion defect would be expected.

(Choice B) Vasospastic angina is due to coronary artery vasospasm and can mimic stable angina that results from atherosclerotic CAD; however, vasospastic angina typically occurs in relatively young patients (age <50). In addition, dobutamine has only a small agonistic effect on alpha-1 receptors and is unlikely to trigger coronary vasospasm.

(Choice C) Focal myocardial fibrosis typically results from previous MI. Contractility is impaired in the fibrosed myocardium, leading to a persistent wall motion defect similar to that expected with acute MI.

(Choice D) In the normal state, dobutamine boosts myocardial contractility, and the rise in myocardial oxygen demand is met by increased myocardial oxygen supply via increased blood flow. Therefore, the normal response to dobutamine infusion is a transient increase in ejection fraction.

Educational objective:
Stable angina results from fixed coronary artery stenosis that limits blood flow to downstream myocardium, preventing the myocardial oxygen supply from increasing during exertion. Dobutamine mimics the effects of exercise and increases myocardial oxygen demand; it can be used during stress testing to provoke areas of ischemic myocardium, which can be recognized on imaging by a localized and transient decrease in contractility (ie, wall motion defect).

Pathophysiology	Cardiovascular System	Coronary artery disease
Subject	System	Topic

Copyright © UWorld. All rights reserved.

1
2
3
4
5
6
7
8
9
10
11
12
13
14
15
16
17
18
19
20
21
22
23
24
25
26
27
28
29
30
31

A 34-year-old man comes to the emergency department with fatigue and lightheadedness. The patient had an upper respiratory infection last week, and since then his energy level has been low with shortness of breath on mild exertion. Otherwise, his medical history is insignificant. He is a lifetime nonsmoker. The patient's temperature is 37 C (98.6 F), blood pressure is 80/60 mm Hg, and pulse is 120/min and regular. His pulse becomes undetectable to palpation during inspiration. The lungs are clear to auscultation, but the jugular veins are distended. Which of the following is the most likely diagnosis?

- A. Acute myocardial infarction
- B. Acute viral myocarditis
- C. Cardiac tamponade
- D. Constrictive pericarditis
- E. Septic shock
- F. Tension pneumothorax

Submit

A 34-year-old man comes to the emergency department with fatigue and lightheadedness. The patient had an upper respiratory infection last week, and since then his energy level has been low with shortness of breath on mild exertion. Otherwise, his medical history is insignificant. He is a lifetime nonsmoker. The patient's temperature is 37 C (98.6 F), blood pressure is 80/60 mm Hg, and pulse is 120/min and regular. His pulse becomes undetectable to palpation during inspiration. The lungs are clear to auscultation, but the jugular veins are distended. Which of the following is the most likely diagnosis?

- A. Acute myocardial infarction (0%)
- B. Acute viral myocarditis (13%)
- ✓ C. Cardiac tamponade (48%)
- D. Constrictive pericarditis (33%)
- E. Septic shock (3%)
- F. Tension pneumothorax (1%)

Omitted
Correct answer
C

48%
Answered correctly

01 sec
Time Spent

03/18/2020
Last Updated

Explanation

Clinical features of cardiac tamponade

- Malignancy/radiation therapy

Clinical features of cardiac tamponade	
Etiology	• Malignancy/radiation therapy • Infection (eg, viral, tuberculosis, HIV) • Drugs (eg, hydralazine, isoniazid) • Connective tissue diseases (eg, systemic lupus erythematous, rheumatoid arthritis)
Clinical signs	• **Beck's triad**: Jugular venous distension, hypotension, diminished heart sounds • **Pulsus paradoxus** (abnormally large inspiratory decrease in systolic blood pressure >10 mm Hg)
Diagnosis	• **ECG**: Low-voltage QRS complexes, electrical alternans • **Chest x-ray**: Enlarged water-bottle-shaped heart, clear lungs

©UWorld

This presentation of **hypotension**, tachycardia, **jugular venous distension** with clear lungs, and **pulsus paradoxus** (manifesting as loss of palpable pulse during inspiration) is consistent with **cardiac tamponade**. This is most likely due to the patient's recent viral illness causing viral pericarditis with significant pericardial fluid accumulation. Normally there is a <10 mm Hg decrease in systolic blood pressure during inspiration. Pulsus paradoxus refers to an abnormal exaggerated decrease in systolic blood pressure >10 mm Hg on inspiration, a common finding in patients with large pericardial effusions causing tamponade.

Inspiration causes an increase in systemic venous return, resulting in increased right heart volumes. Under normal conditions, this results in expansion of the right ventricle into the pericardial space with little impact on the left side of the heart. However, in conditions that impair expansion into the pericardial space (eg, cardiac tamponade), the increased right ventricular volume that occurs with inspiration leads to bowing of

This presentation of **hypotension**, tachycardia, **jugular venous distension** with clear lungs, and **pulsus paradoxus** (manifesting as loss of palpable pulse during inspiration) is consistent with **cardiac tamponade**. This is most likely due to the patient's recent viral illness causing viral pericarditis with significant pericardial fluid accumulation. Normally there is a <10 mm Hg decrease in systolic blood pressure during inspiration. Pulsus paradoxus refers to an abnormal exaggerated decrease in systolic blood pressure >10 mm Hg on inspiration, a common finding in patients with large pericardial effusions causing tamponade.

Inspiration causes an increase in systemic venous return, resulting in increased right heart volumes. Under normal conditions, this results in expansion of the right ventricle into the pericardial space with little impact on the left side of the heart. However, in conditions that impair expansion into the pericardial space (eg, cardiac tamponade), the increased right ventricular volume that occurs with inspiration leads to bowing of the interventricular septum toward the left ventricle. This leads to a decrease in left ventricular (LV) end-diastolic volume and forward stroke volume, with a resultant decrease in systolic pressure during inspiration.

(Choice A) Acute myocardial infarction typically presents with sudden onset of substernal discomfort, diaphoresis, and/or dyspnea, and can progress to cardiogenic shock (hypotension, tachycardia, jugular venous distension, and pulmonary edema). Patients can have weak or undetectable peripheral pulses; however, pulsus paradoxus is typically not seen.

(Choice B) Acute viral myocarditis can lead to severe LV systolic dysfunction and present with acute congestive heart failure and cardiogenic shock. Patients with severe LV failure can have pulsus alternans - a variation in pulse amplitude with alternate beats. Pulsus paradoxus is typically not seen in such patients.

(Choice D) Pulsus paradoxus can also occur in patients with asthma, chronic obstructive pulmonary disease, and (less frequently) constrictive pericarditis. Constrictive pericarditis is caused by scarring and loss of elasticity of the normal pericardial sac; it takes several weeks to months to develop and only rarely occurs after recurrent episodes of acute pericarditis.

(Choice E) The initial stage of septic shock is a hyperdynamic circulatory state with lowered systemic vascular resistance and increased cardiac output (warm shock). Weak pulses and pulsus paradoxus would not be expected in such patients.

(Choice F) In tension pneumothorax, breath sounds are typically absent on the affected side with hyperresonance to percussion. Other features of tension pneumothorax include tachypnea, tachycardia, hypotension, distended neck veins, and tracheal deviation to the contralateral side.

Educational objective:

Cardiac tamponade typically presents with hypotension with pulsus paradoxus, elevated jugular venous pressure, and muffled heart sounds.

This presentation of **hypotension**, tachycardia, **jugular venous distension** with clear lungs, and **pulsus paradoxus** (manifesting as loss of

Exhibit Display

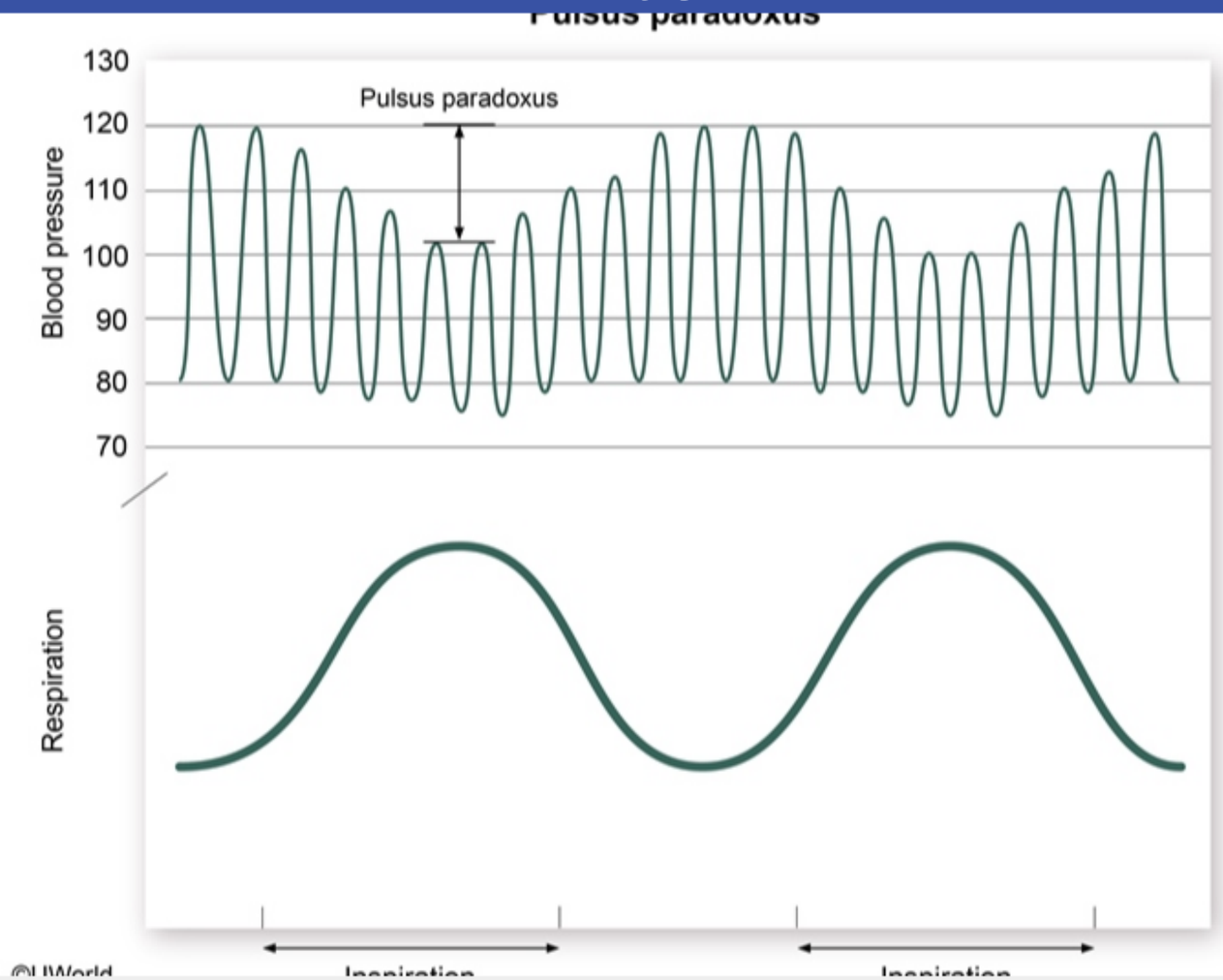

Zoom In | Zoom Out | Reset | Add To New Card | Existing Card

Cardiac tamponade typically presents with hypotension with pulsus paradoxus, elevated jugular venous pressure, and muffled heart sounds

1 2 3 4 5 6 7 8 9 10 11 12 13 14 15 16 17 18 19 20 21 22 23 24 25 26 27 28 29 30 31

expansion into the pericardial space (eg, cardiac tamponade), the increased right ventricular volume that occurs with inspiration leads to bowing of the interventricular septum toward the left ventricle. This leads to a decrease in left ventricular (LV) end-diastolic volume and forward stroke volume, with a resultant decrease in systolic pressure during inspiration.

(Choice A) Acute myocardial infarction typically presents with sudden onset of substernal discomfort, diaphoresis, and/or dyspnea, and can progress to cardiogenic shock (hypotension, tachycardia, jugular venous distension, and pulmonary edema). Patients can have weak or undetectable peripheral pulses; however, pulsus paradoxus is typically not seen.

(Choice B) Acute viral myocarditis can lead to severe LV systolic dysfunction and present with acute congestive heart failure and cardiogenic shock. Patients with severe LV failure can have pulsus alternans - a variation in pulse amplitude with alternate beats. Pulsus paradoxus is typically not seen in such patients.

(Choice D) Pulsus paradoxus can also occur in patients with asthma, chronic obstructive pulmonary disease, and (less frequently) constrictive pericarditis. Constrictive pericarditis is caused by scarring and loss of elasticity of the normal pericardial sac; it takes several weeks to months to develop and only rarely occurs after recurrent episodes of acute pericarditis.

(Choice E) The initial stage of septic shock is a hyperdynamic circulatory state with lowered systemic vascular resistance and increased cardiac output (warm shock). Weak pulses and pulsus paradoxus would not be expected in such patients.

(Choice F) In tension pneumothorax, breath sounds are typically absent on the affected side with hyperresonance to percussion. Other features of tension pneumothorax include tachypnea, tachycardia, hypotension, distended neck veins, and tracheal deviation to the contralateral side.

Educational objective:
Cardiac tamponade typically presents with hypotension with pulsus paradoxus, elevated jugular venous pressure, and muffled heart sounds (Beck's triad). Pulsus paradoxus refers to an abnormal exaggerated decrease in systolic blood pressure >10 mm Hg on inspiration, and is a common finding in patients with pericardial effusion with cardiac tamponade.

Pathophysiology	Cardiovascular System	Cardiac tamponade
Subject	System	Topic

Copyright © UWorld. All rights reserved.

1
2
3
4
5
6
7
8
9
10
11
12
13
14
15
16
17
18
19
20
21
22
23
24
25
26
27
28
29
30
31

A 65-year-old woman with chronic obstructive pulmonary disease comes to the office for a follow-up appointment. The patient reports increasing shortness of breath that is not relieved by her inhalers. Her other medical conditions include osteoarthritis. She is a former smoker with a 45-pack-year history. Blood pressure is 120/70 mm Hg, pulse is 75/min, and respirations are 22/min. Oxygen saturation on room air is 91% at rest. On physical examination, jugular venous pressure is elevated. There is increased intensity of the pulmonic component of S2. Breath sounds are decreased bilaterally with scattered wheezes but no crackles. There is 2+ lower extremity edema. Which of the following hemodynamic parameters is most likely to be increased in this patient?

A. Left ventricular preload

B. Left ventricular stroke volume

C. Pulmonary arterial compliance

D. Pulmonary capillary wedge pressure

E. Right ventricular afterload

Submit

1
2
3
4
5
6
7
8
9
10
11
12
13
14
15
16
17
18
19
20
21
22
23
24
25
26
27
28
29
30
31

A 65-year-old woman with chronic obstructive pulmonary disease comes to the office for a follow-up appointment. The patient reports increasing shortness of breath that is not relieved by her inhalers. Her other medical conditions include osteoarthritis. She is a former smoker with a 45-pack-year history. Blood pressure is 120/70 mm Hg, pulse is 75/min, and respirations are 22/min. Oxygen saturation on room air is 91% at rest. On physical examination, jugular venous pressure is elevated. There is increased intensity of the pulmonic component of S2. Breath sounds are decreased bilaterally with scattered wheezes but no crackles. There is 2+ lower extremity edema. Which of the following hemodynamic parameters is most likely to be increased in this patient?

A. Left ventricular preload

B. Left ventricular stroke volume

C. Pulmonary arterial compliance

D. Pulmonary capillary wedge pressure

E. Right ventricular afterload

Submit

A 65-year-old woman with chronic obstructive pulmonary disease comes to the office for a follow-up appointment. The patient reports increasing shortness of breath that is not relieved by her inhalers. Her other medical conditions include osteoarthritis. She is a former smoker with a 45-pack-year history. Blood pressure is 120/70 mm Hg, pulse is 75/min, and respirations are 22/min. Oxygen saturation on room air is 91% at rest. On physical examination, jugular venous pressure is elevated. There is increased intensity of the pulmonic component of S2. Breath sounds are decreased bilaterally with scattered wheezes but no crackles. There is 2+ lower extremity edema. Which of the following hemodynamic parameters is most likely to be increased in this patient?

- A. Left ventricular preload (2%)
- B. Left ventricular stroke volume (0%)
- C. Pulmonary arterial compliance (3%)
- D. Pulmonary capillary wedge pressure (15%)
- ✓ E. Right ventricular afterload (76%)

Omitted
Correct answer
E

76%
Answered correctly

03 secs
Time Spent

03/21/2020
Last Updated

Explanation

This patient with chronic obstructive pulmonary disease (COPD) has evidence of **pulmonary hypertension** complicated by **right-sided heart failure**. Hypoxic vasoconstriction is a physiologic mechanism unique to lung tissue that helps minimize ventilation-perfusion mismatch and increase overall gas exchange efficiency. However, chronic and diffuse pulmonary vasoconstriction, which occurs with advanced **hypoxic lung disease** (eg, COPD, interstitial lung disease, obesity hypoventilation syndrome), and can lead to pulmonary hypertension (ie, **increased right**

1
2
3
4
5
6
7
8
9
10
11
12
13
14
15
16
17
18
19
20
21
22
23
24
25
26
27
28
29
30
31

Explanation

This patient with chronic obstructive pulmonary disease (COPD) has evidence of **pulmonary hypertension** complicated by **right-sided heart failure**. Hypoxic vasoconstriction is a physiologic mechanism unique to lung tissue that helps minimize ventilation-perfusion mismatch and increase overall gas exchange efficiency. However, chronic and diffuse pulmonary vasoconstriction, which occurs with advanced **hypoxic lung disease** (eg, COPD, interstitial lung disease, obesity hypoventilation syndrome), and can lead to pulmonary hypertension (ie, **increased right ventricular afterload**).

Pulmonary hypertension typically presents with dyspnea and/or fatigue, and some patients may develop exertional angina or syncope due to reduced cardiac output. Physical examination can reveal **left parasternal lift** (due to right ventricular hypertrophy) and a **loud pulmonic component of S2** due to high pulmonary artery pressure. Over time, the right ventricle may be unable to pump against the increased afterload and right-sided heart failure can develop, evidenced by **jugular venous distension** and prominent **lower extremity edema**.

(Choices A, B, and D) The hemodynamic parameters in pulmonary hypertension secondary to hypoxic lung disease are similar to those in pulmonary arterial hypertension. Left ventricular preload and stroke volume (cardiac output) are decreased due to impaired pumping of blood through the lungs to the left atrium. Pulmonary capillary wedge pressure, an estimate of left atrial pressure and a representation of left-sided preload, is also decreased.

(Choice C) Pulmonary arterial compliance decreases with pulmonary hypertension due to vascular remodeling and stiffening of the pulmonary arterial wall.

Educational objective:
Advanced hypoxic lung disease (eg, chronic obstructive pulmonary disease, interstitial lung disease, obesity hypoventilation syndrome) is a common cause of pulmonary hypertension (ie, increased right ventricular afterload). The increase in pulmonary arterial pressure mainly results from chronic and diffuse hypoxic vasoconstriction, with a lesser degree of vascular remodeling than in (primary) pulmonary arterial hypertension.

Pathophysiology	Cardiovascular System	Pulmonary Arterial Hypertension
Subject	System	Topic

Copyright © UWorld. All rights reserved.

Explanation

This patient with chronic o
failure. Hypoxic vasocon
increase overall gas excha
disease (eg, COPD, inter
ventricular afterload).

Pulmonary hypertension t
reduced cardiac output. F
component of S2 due to
and right-sided heart failu

(Choices A, B, and D) T
pulmonary arterial hyperte
through the lungs to the le
preload, is also decreased

(Choice C) Pulmonary ar
arterial wall.

Educational objective:
Advanced hypoxic lung di
common cause of pulmon
from chronic and diffuse h

Pathophysiology
Subject

Exhibit Display

Classification of pulmonary hypertension	
Pulmonary arterial hypertension (Group 1)	• Primary change in pulmonary arteries ◦ Hereditary (eg, *BMPR2* mutation) ◦ Connective tissue disease (eg, RA, SS) ◦ HIV infection • Treatment targeted at endothelial dysfunction
Pulmonary hypertension (Groups 2-5)	• Secondary to another disease process ◦ Left-sided heart failure ◦ Chronic lung disease/hypoxia ◦ Chronic pulmonary thromboembolism • Treatment aimed at underlying disease

RA = rheumatoid arthritis; **SS** = systemic sclerosis.

Add To Flash Card

Copyright © UWorld. All rights reserved.

1
2
3
4
5
6
7
8
9
10
11
12
13
14
15
16
17
18
19
20
21
22
23
24
25
26
27
28
29
30
31

Explanation

Exhibit Display

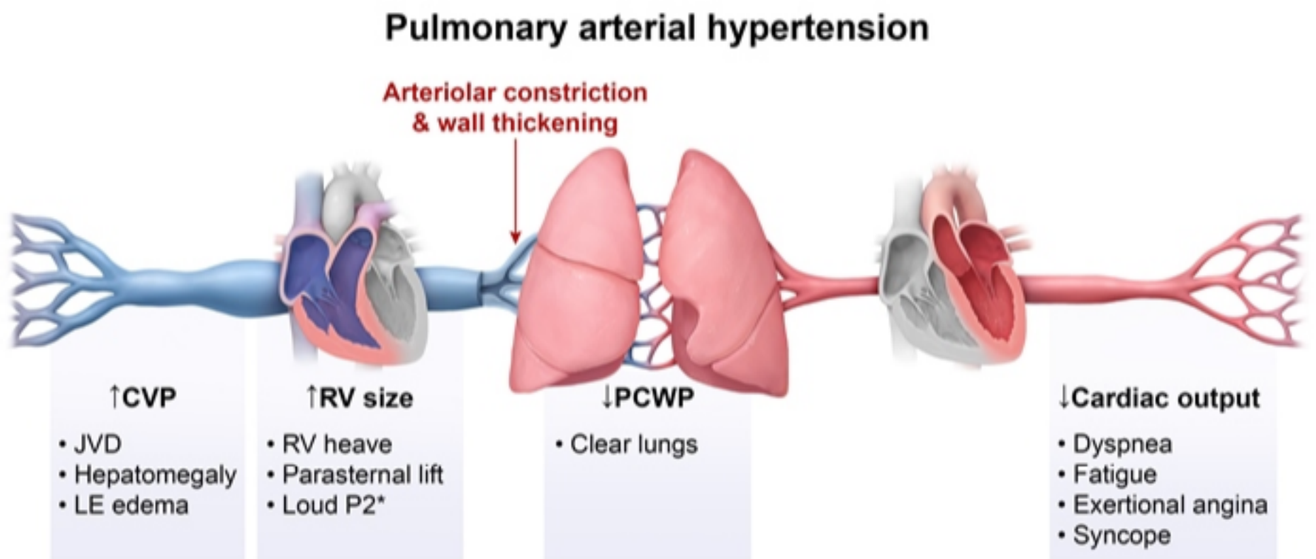

CVP = central venous pressure; **JVD** = jugular venous distension; **LE** = lower extremity; **PCWP** = pulmonary capillary wedge pressure; **RV** = right ventricular.
*Due to elevated pulmonary arterial pressure

©UWorld

Zoom In Zoom Out Reset Add To Flash Card

1
2
3
4
5
6
7
8
9
10
11
12
13
14
15
16
17
18
19
20
21
22
23
24
25
26
27
28
29
30
31

Cardiac catheterization is performed on a 7-year-old boy. The image below shows the pattern of oxygen saturation in the patient's cardiac chambers and outflow tracts (structural abnormalities are not shown).

This patient most likely has which of the following findings on physical examination?

A. Bifid carotid pulse with brisk upstroke

B. Continuous murmur over the upper precordium

C. Decreased femoral-to-brachial blood pressure ratio

D. Fixed splitting of S2 on cardiac auscultation

E. Holosystolic murmur over the left sternal border

F. Mucosal cyanosis and fingernail clubbing

Submit

1
2
3
4
5
6
7
8
9
10
11
12
13
14
15
16
17
18
19
20
21
22
23
24
25
26
27
28
29
30
31

Cardiac catheterization is performed on a 7-year-old boy. The image below shows the pattern of oxygen saturation in the patient's cardiac chambers and outflow tracts (structural abnormalities are not shown).

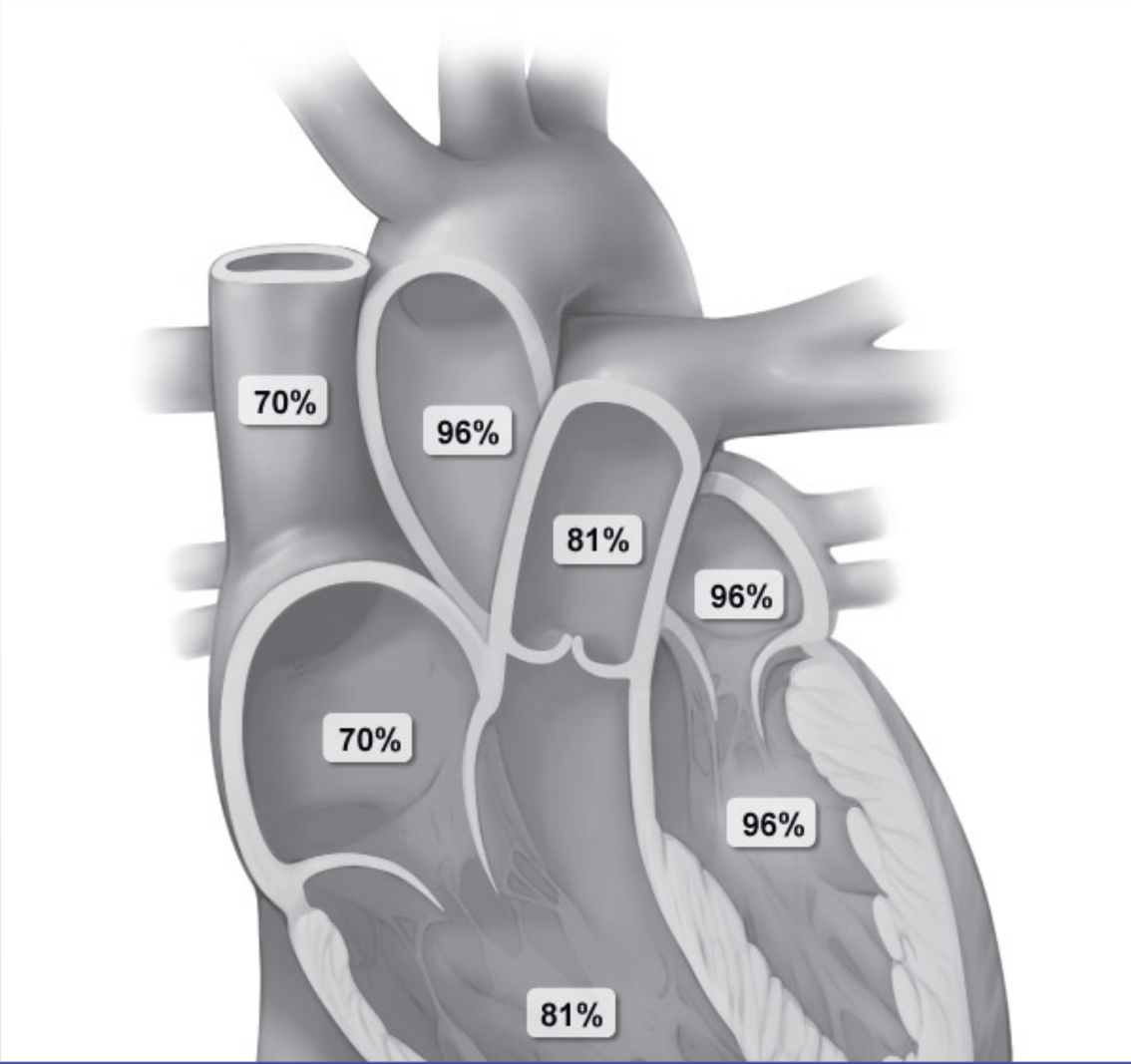

1
2
3
4
5
6
7
8
9
10
11
12
13
14
15
16
17
18
19
20
21
22
23
24
25
26
27
28
29
30
31

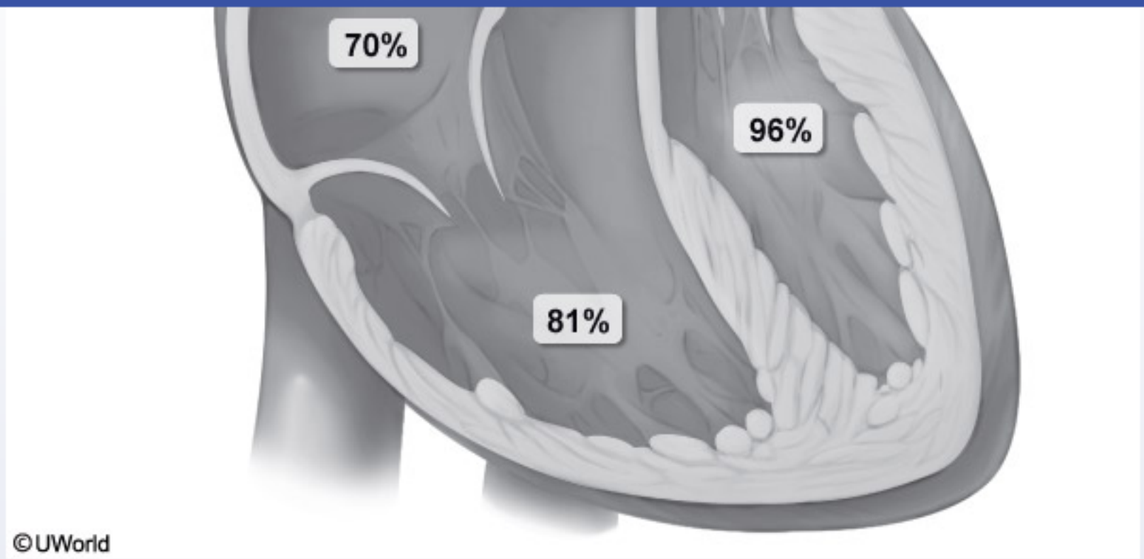

This patient most likely has which of the following findings on physical examination?

- A. Bifid carotid pulse with brisk upstroke
- B. Continuous murmur over the upper precordium
- C. Decreased femoral-to-brachial blood pressure ratio
- D. Fixed splitting of S2 on cardiac auscultation
- E. Holosystolic murmur over the left sternal border
- F. Mucosal cyanosis and fingernail clubbing

Submit

1
2
3
4
5
6
7
8
9
10
11
12
13
14
15
16
17
18
19
20
21
22
23
24
25
26
27
28
29
30
31

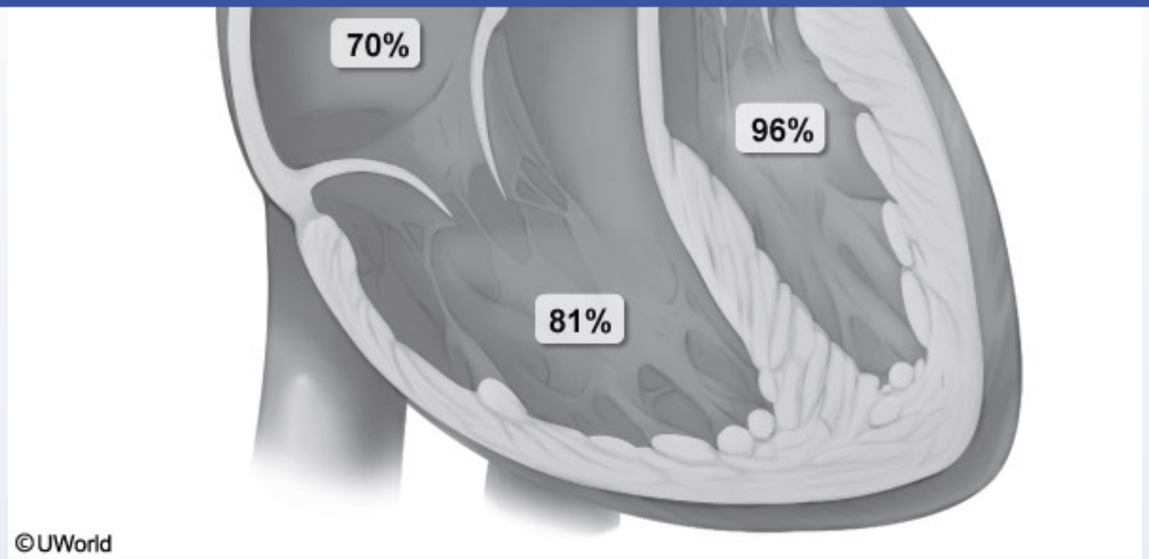

This patient most likely has which of the following findings on physical examination?

A. Bifid carotid pulse with brisk upstroke (1%)

B. Continuous murmur over the upper precordium (10%)

C. Decreased femoral-to-brachial blood pressure ratio (3%)

D. Fixed splitting of S2 on cardiac auscultation (17%)

✓ E. Holosystolic murmur over the left sternal border (61%)

F. Mucosal cyanosis and fingernail clubbing (5%)

Omitted
Correct answer

61%
Answered correctly

06 secs
Time Spent

07/02/2020
Last Updated

1
2
3
4
5
6
7
8
9
10
11
12
13
14
15
16
17
18
19
20
21
22
23
24
25
26
27
28
29
30
31

Ventricular septal defect

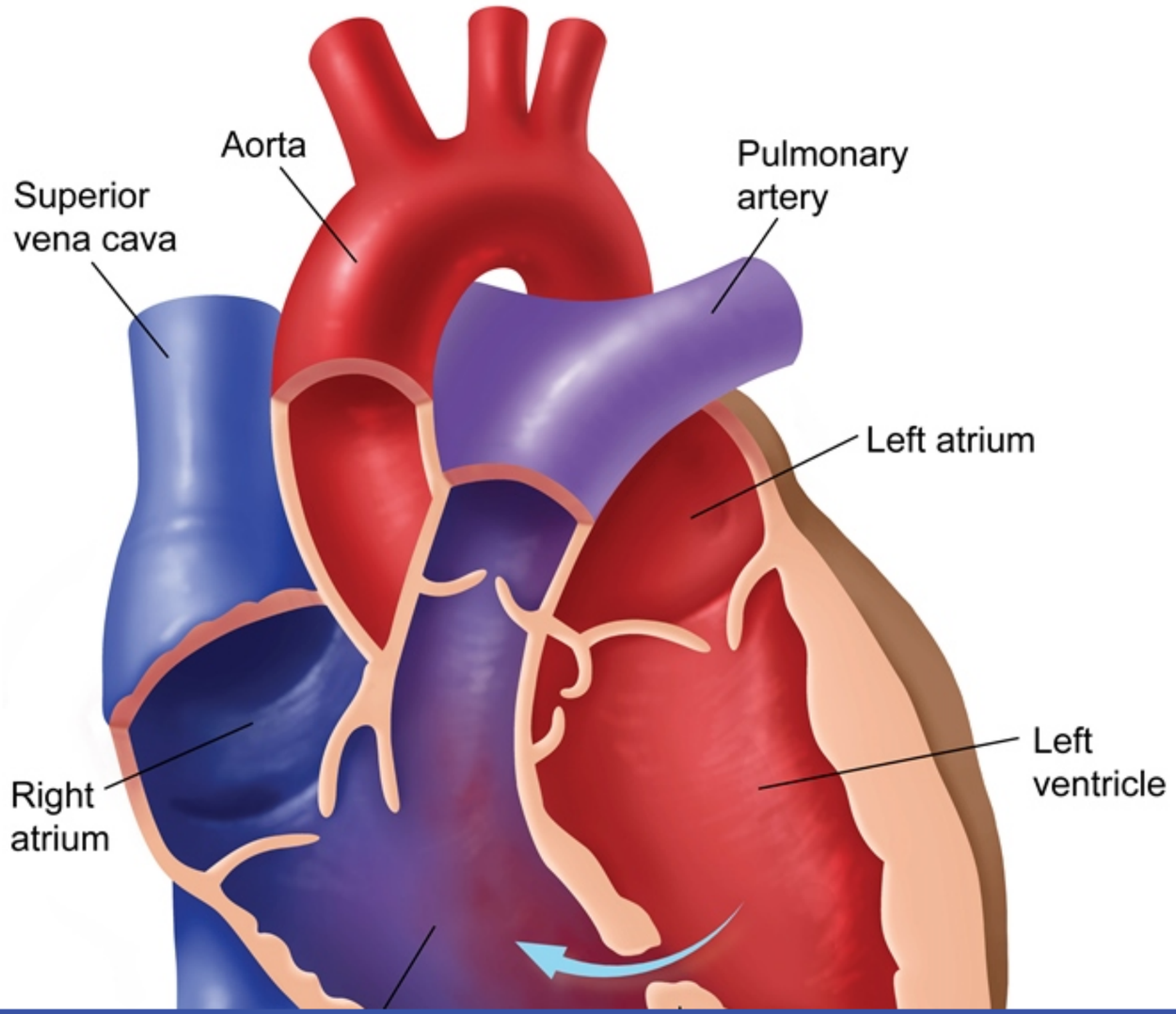

This patient has an **abnormal increase in oxygen saturation** (SpO_2) between the right atrium and the right ventricle (see normal oxygenation pattern), indicating the presence of a **left-to-right shunt** that is most likely the result of a **ventricular septal defect** (VSD). With smaller VSDs, blood is shunted mainly from left to right due to the high pressure differential between the ventricles. As a result, **right ventricular SpO_2 increases** but left ventricular SpO_2 remains relatively normal. Larger VSDs allow equalization of chamber pressures, which results in more bidirectional mixing and decreased left ventricular SpO_2. Right atrial SpO_2 remains normal with VSDs of any size, unless tricuspid regurgitation is also present.

Turbulent blood flow across a small VSD produces a loud **holosystolic murmur** best heard over the **lower left sternal border**. This murmur may be absent in larger (nonrestrictive) VSDs due to decreased resistance across the VSD and a lower trans-septal pressure gradient.

(Choice A) A bifid carotid pulse with brisk upstroke ("spike-and-dome") is characteristic of hypertrophic cardiomyopathy, a condition with dynamic left ventricular outflow tract obstruction during systole. SpO_2 in the cardiac chambers remains normal.

(Choice B) A precordial continuous, machine-like murmur indicates patent ductus arteriosus, which produces isolated pulmonary artery SpO_2 elevation.

(Choice C) A decreased femoral-to-brachial blood pressure ratio is found in coarctation of the aorta, which does not alter right ventricular SpO_2.

(Choice D) Fixed splitting of S2 occurs with an atrial septal defect (ASD), which causes increased SpO_2 in the right atrium compared with the vena cava but identical right atrial and ventricular SpO_2. VSD may result in *wide* splitting of S2 due to increased right ventricular volume causing delayed closure of the pulmonary valve; however, *fixed* splitting of S2 is more indicative of an ASD, as equalization of left and right atrial pressures minimizes the respiratory variation in ventricular blood flow.

(Choice F) Mucosal cyanosis and fingernail clubbing may be observed in cyanotic congenital heart disease or as late features of ASDs or VSDs (eg, Eisenmenger syndrome). Blood flow across the VSD in Eisenmenger syndrome is right to left due to elevated pulmonary vascular resistance, resulting in decreased SpO_2 in the left ventricle.

Educational objective:
Increased blood oxygen saturation between 2 right-sided vessels or chambers indicates the presence of a left-to-right shunt. If the abnormal oxygen increase occurs between the right atrium and the right ventricle, a ventricular septal defect (VSD) is likely present. Small VSDs produce a holosystolic murmur that is loudest over the lower left sternal border.

also present.

Turbulent blood flow across a small VSD produces a loud **holosystolic murmur** best heard over the **lower left sternal border**. This murmur may be absent in larger (nonrestrictive) VSDs due to decreased resistance across the VSD and a lower trans-septal pressure gradient.

(Choice A) A bifid carotid pulse with brisk upstroke ("spike-and-dome") is characteristic of hypertrophic cardiomyopathy, a condition with dynamic left ventricular outflow tract obstruction during systole. SpO_2 in the cardiac chambers remains normal.

(Choice B) A precordial continuous, machine-like murmur indicates patent ductus arteriosus, which produces isolated pulmonary artery SpO_2 elevation.

(Choice C) A decreased femoral-to-brachial blood pressure ratio is found in coarctation of the aorta, which does not alter right ventricular SpO_2.

(Choice D) Fixed splitting of S2 occurs with an atrial septal defect (ASD), which causes increased SpO_2 in the right atrium compared with the vena cava but identical right atrial and ventricular SpO_2. VSD may result in *wide* splitting of S2 due to increased right ventricular volume causing delayed closure of the pulmonary valve; however, *fixed* splitting of S2 is more indicative of an ASD, as equalization of left and right atrial pressures minimizes the respiratory variation in ventricular blood flow.

(Choice F) Mucosal cyanosis and fingernail clubbing may be observed in cyanotic congenital heart disease or as late features of ASDs or VSDs (eg, Eisenmenger syndrome). Blood flow across the VSD in Eisenmenger syndrome is right to left due to elevated pulmonary vascular resistance, resulting in decreased SpO_2 in the left ventricle.

Educational objective:
Increased blood oxygen saturation between 2 right-sided vessels or chambers indicates the presence of a left-to-right shunt. If the abnormal oxygen increase occurs between the right atrium and the right ventricle, a ventricular septal defect (VSD) is likely present. Small VSDs produce a holosystolic murmur that is loudest over the lower left sternal border.

References

- Shunt lesions.

Pathophysiology	Cardiovascular System	Congenital cardiac defects
Subject	System	Topic

A 55-year-old man comes to the office for follow-up. The patient was diagnosed with hypertension 3 weeks ago, and an ECG performed at that time showed features of left ventricular hypertrophy. He was subsequently referred for echocardiography. The patient feels well and has had no shortness of breath, fatigue, or leg swelling. He has no other medical conditions, takes no medications, and does not use tobacco, alcohol, or illicit drugs. Blood pressure is 155/90 mm Hg and pulse is 80/min. BMI is 35 kg/m^2. Physical examination shows normal jugular venous pressure. There are no lung crackles, heart gallops, or lower extremity edema. Echocardiography reveals a left ventricular ejection fraction of 30%. Which of the following patterns of chemical mediators is most likely present in this patient?

	Angiotensin II	Norepinephrine	Atrial natriuretic peptide
A.	Decreased	Decreased	Decreased
B.	Decreased	Decreased	Increased
C.	Decreased	Increased	Increased
D.	Increased	Decreased	Decreased
E.	Increased	Decreased	Increased
F.	Increased	Increased	Increased

Submit

A 55-year-old man comes to the office for follow-up. The patient was diagnosed with hypertension 3 weeks ago, and an ECG performed at that time showed features of left ventricular hypertrophy. He was subsequently referred for echocardiography. The patient feels well and has had no shortness of breath, fatigue, or leg swelling. He has no other medical conditions, takes no medications, and does not use tobacco, alcohol, or illicit drugs. Blood pressure is 155/90 mm Hg and pulse is 80/min. BMI is 35 kg/m^2. Physical examination shows normal jugular venous pressure. There are no lung crackles, heart gallops, or lower extremity edema. Echocardiography reveals a left ventricular ejection fraction of 30%. Which of the following patterns of chemical mediators is most likely present in this patient?

	Angiotensin II	Norepinephrine	Atrial natriuretic peptide
A. (2%)	Decreased	Decreased	Decreased
B. (11%)	Decreased	Decreased	Increased
C. (6%)	Decreased	Increased	Increased
D. (14%)	Increased	Decreased	Decreased
E. (13%)	Increased	Decreased	Increased
✓ F. (51%)	Increased	Increased	Increased

Omitted
Correct answer

51%
Answered correctly

02 secs
Time Spent

03/18/2020
Last Updated

1
2
3
4
5
6
7
8
9
10
11
12
13
14
15
16
17
18
19
20
21
22
23
24
25
26
27
28
29
30
31

Vicious cycle of decompensated heart failure

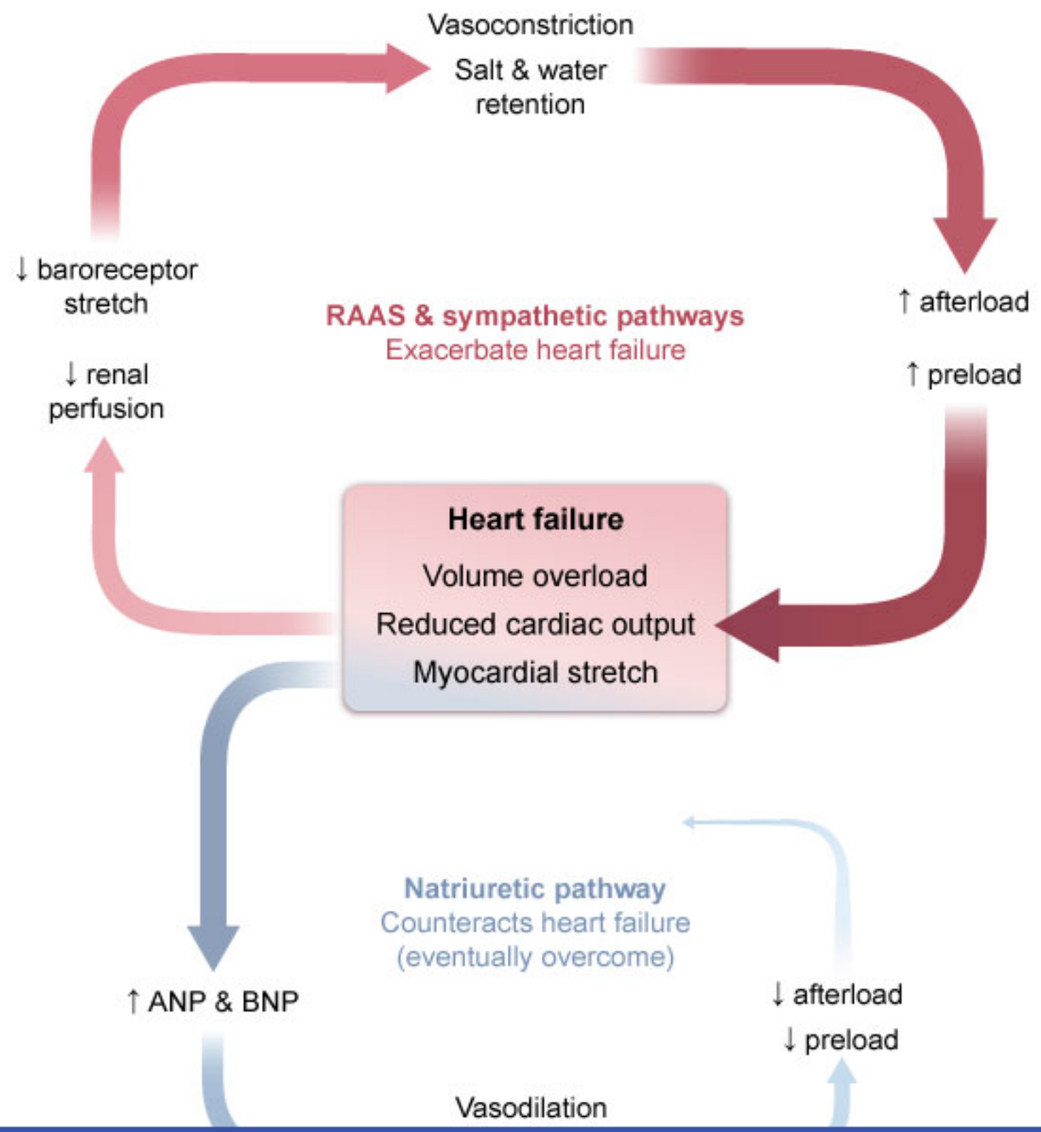

Vasoconstriction

Exhibit Display

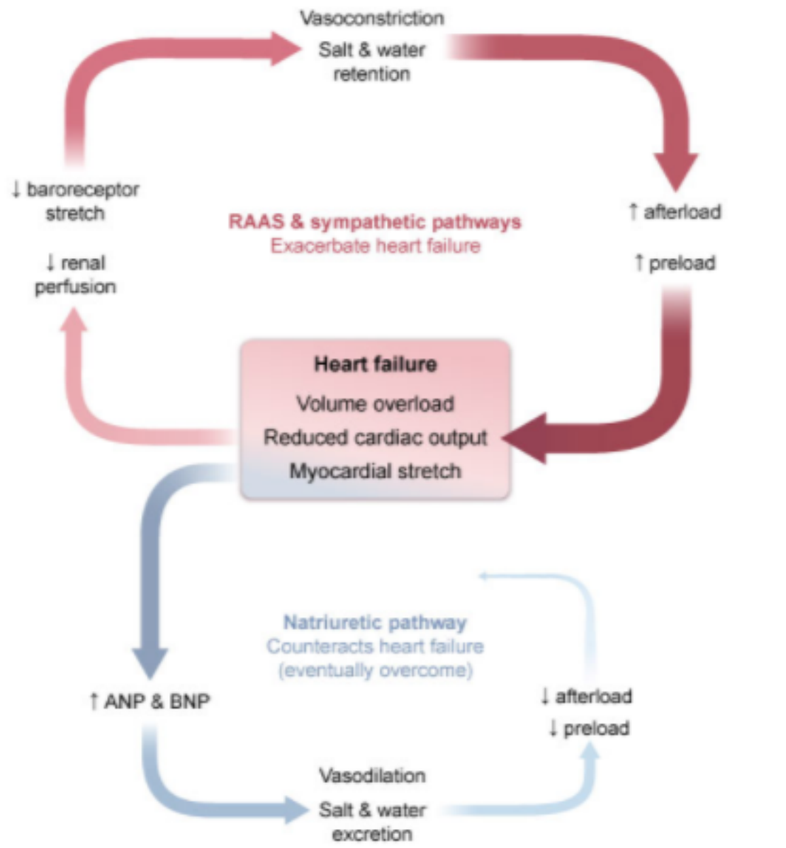

ANP = atrial natriuretic peptide; BNP = brain natriuretic peptide; RAAS = renin-angiotensin-aldosterone system.

©UWorld

Zoom In | Zoom Out | Reset | Add To New Card | Existing Card

excretion

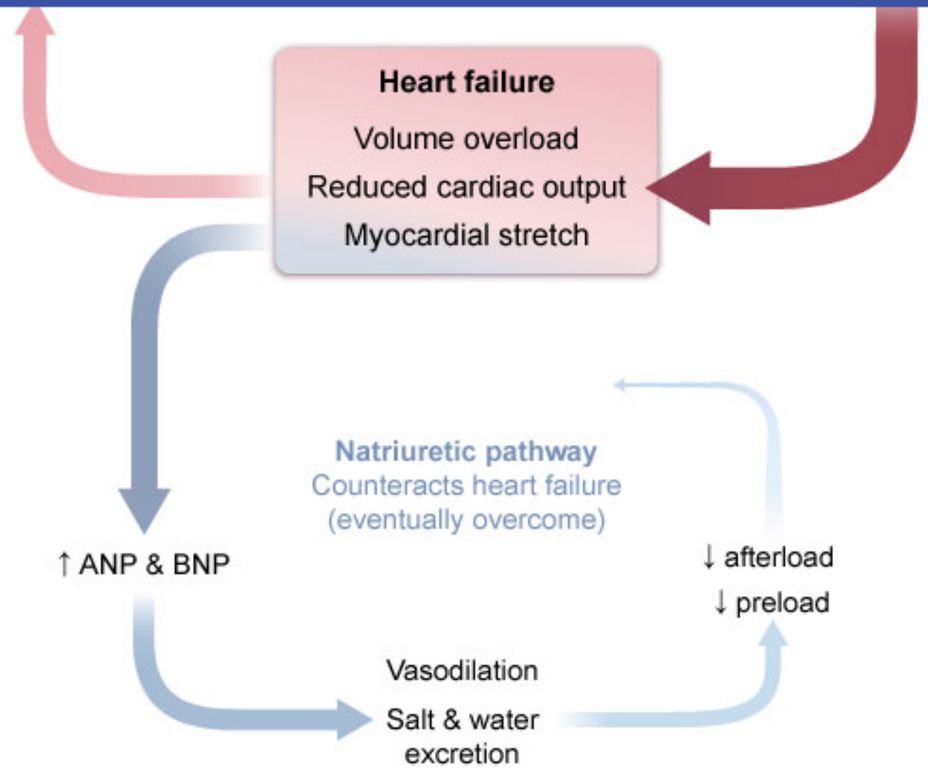

ANP = atrial natriuretic peptide; **BNP** = brain natriuretic peptide; **RAAS** = renin-angiotensin-aldosterone system.

©UWorld

This patient's echocardiography reveals a reduced left ventricular (LV) ejection fraction (<50%) in the absence of heart failure symptoms, a condition known as **asymptomatic left ventricular systolic dysfunction**. An early asymptomatic period is common in the progression of heart failure; it occurs in part due to compensatory eccentric hypertrophy in response to LV volume overload. In addition, **neurohormonal mechanisms** help maintain cardiac output and organ perfusion in the setting of declining cardiac function.

Early in the course of heart failure, small reductions in cardiac output lead to decreased stretch of aortic and carotid baroreceptors with consequent **sympathetic nervous system activation** (increased norepinephrine) to stimulate vasoconstriction, increased heart rate, and increased cardiac contractility. In addition, decreased renal perfusion stimulates the juxtaglomerular apparatus to increase renin secretion and

1 2 3 4 5 6 7 8 9 10 11 12 13 14 15 16 17 18 19 20 21 22 23 24 25 26 27 28 29 30 31

ANP = atrial natriuretic peptide; **BNP** = brain natriuretic peptide; **RAAS** = renin-angiotensin-aldosterone system.
©UWorld

This patient's echocardiography reveals a reduced left ventricular (LV) ejection fraction (<50%) in the absence of heart failure symptoms, a condition known as **asymptomatic left ventricular systolic dysfunction**. An early asymptomatic period is common in the progression of heart failure; it occurs in part due to compensatory eccentric hypertrophy in response to LV volume overload. In addition, **neurohormonal mechanisms** help maintain cardiac output and organ perfusion in the setting of declining cardiac function.

Early in the course of heart failure, small reductions in cardiac output lead to decreased stretch of aortic and carotid baroreceptors with consequent **sympathetic nervous system activation** (increased norepinephrine) to stimulate vasoconstriction, increased heart rate, and increased cardiac contractility. In addition, decreased renal perfusion stimulates the juxtaglomerular apparatus to increase renin secretion and activate the **renin-angiotensin-aldosterone system** (RAAS), leading to vasoconstriction via increased angiotensin II levels and salt and water retention via increased aldosterone levels. The volume retention (increased preload) and vasoconstriction (increased afterload) help maintain cardiac output and organ perfusion in the short term; however, the **long-term effects** are **deleterious** because increased hemodynamic stress and neurohormonal-induced cardiac remodeling eventually lead to **decompensated heart failure**.

Atrial and ventricular myocardial stretch triggers **increased atrial and brain natriuretic peptide** secretion through separate neurohormonal pathways. These peptides stimulate vasodilation and salt and water excretion, counteracting the effects of the sympathetic nervous system and RAAS; however, the natriuretic pathways are eventually overwhelmed by the downward compensatory spiral.

Educational objective:
Asymptomatic left ventricular systolic dysfunction is a common stage in the progression of heart failure. Neurohormonal mechanisms, including the sympathetic nervous system and renin-angiotensin-aldosterone system, help maintain the asymptomatic period by increasing volume retention and peripheral resistance to maintain organ perfusion. Although these mechanisms are beneficial in the short term, they are ultimately deleterious, increasing hemodynamic stress and cardiac remodeling that eventually lead to decompensated heart failure.

Pathophysiology	Cardiovascular System	Acute heart failure
Subject	System	Topic

Copyright © UWorld. All rights reserved.

1
2
3
4
5
6
7
8
9
10
11
12
13
14
15
16
17
18
19
20
21
22
23
24
25
26
27
28
29
30
31

A 53-year-old man comes to the office with progressive exertional dyspnea. He has smoked 2 packs of cigarettes per day for the last 35 years. Physical examination shows increased anteroposterior diameter of his chest. Auscultation reveals decreased breath sounds and scattered wheezes throughout his lungs. Examination of his extremities is unremarkable. An echocardiogram reveals moderate dilation of the right ventricle and increased central venous pressure. The absence of peripheral edema in this patient is best explained by which of the following compensatory mechanisms?

A. Decreased capillary permeability
B. Decreased circulating aldosterone levels
C. Decreased interstitial fluid pressure
D. Increased plasma oncotic pressure
E. Increased tissue lymphatic drainage

Submit

A 53-year-old man comes to the office with progressive exertional dyspnea. He has smoked 2 packs of cigarettes per day for the last 35 years. Physical examination shows increased anteroposterior diameter of his chest. Auscultation reveals decreased breath sounds and scattered wheezes throughout his lungs. Examination of his extremities is unremarkable. An echocardiogram reveals moderate dilation of the right ventricle and increased central venous pressure. The absence of peripheral edema in this patient is best explained by which of the following compensatory mechanisms?

A. Decreased capillary permeability (8%)

B. Decreased circulating aldosterone levels (23%)

C. Decreased interstitial fluid pressure (5%)

D. Increased plasma oncotic pressure (22%)

✓ E. Increased tissue lymphatic drainage (38%)

Omitted
Correct answer
E

38%
Answered correctly

02 secs
Time Spent

05/14/2020
Last Updated

Explanation

Factors affecting interstitial fluid volume

Hydrostatic

1
2
3
4
5
6
7
8
9
10
11
12
13
14
15
16
17
18
19
20
21
22
23
24
25
26
27
28
29
30
31

Factors affecting interstitial fluid volume

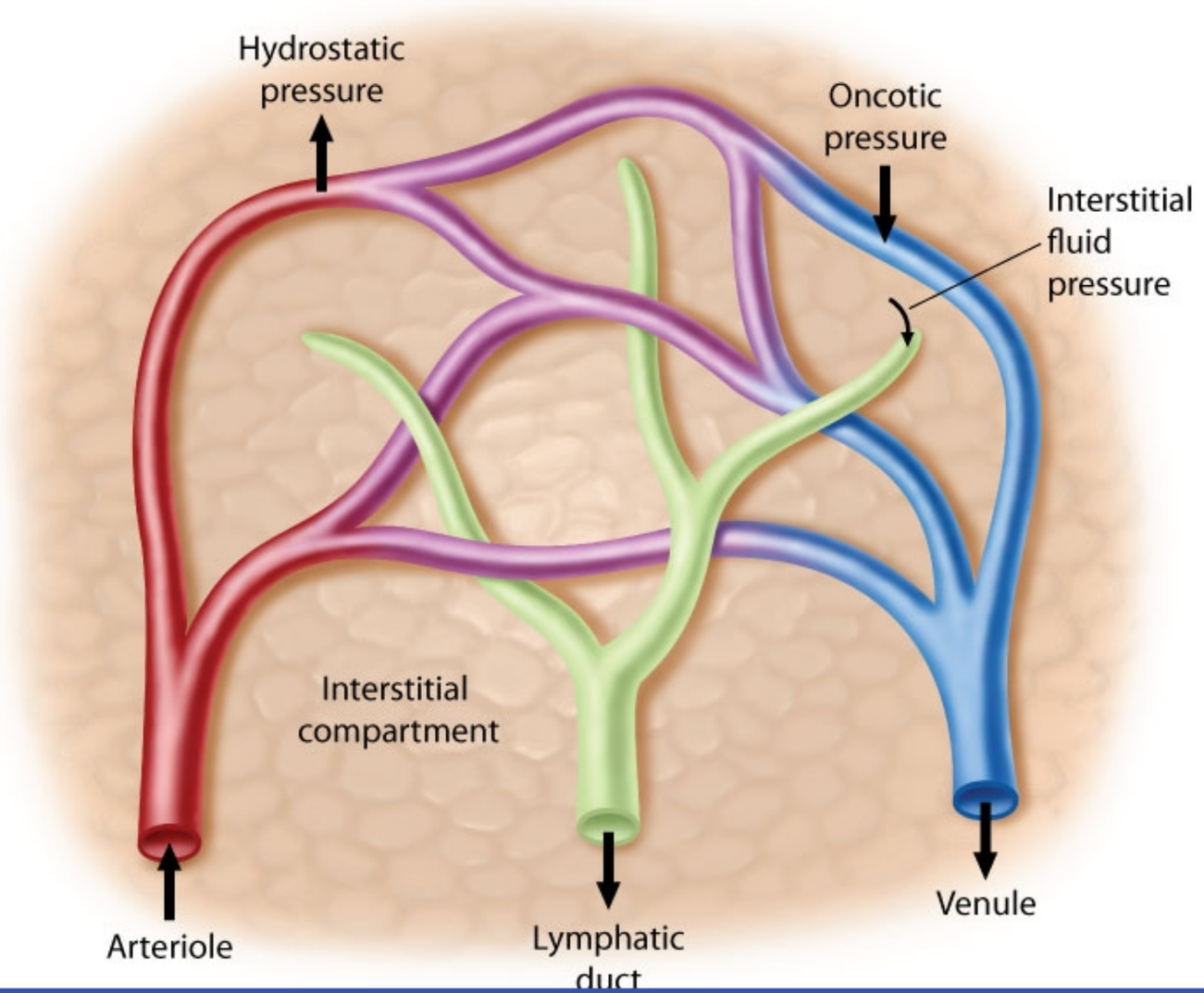

This patient has dyspnea, signs of lung hyperinflation, and a heavy smoking history, suggesting chronic obstructive pulmonary disease (COPD). Chronic hypoxia in COPD can lead to pulmonary vasoconstriction, increased pulmonary artery pressure, and right heart failure (ie, cor pulmonale), which is confirmed by this patient's echocardiogram. In turn, right heart failure leads to increased central venous pressure and excessive capillary hydrostatic pressure, which predisposes him to developing **peripheral edema**.

Fluid movement across the capillary wall (filtration) into the interstitium is dependent on hydrostatic pressure, oncotic pressure, and capillary permeability. It is tightly balanced by lymphatic drainage, which returns interstitial fluid to the vasculature. Peripheral edema (accumulation of excess fluid in the interstitial space) develops when transcapillary plasma filtration exceeds the resorptive capacity of the lymphatics. Factors that favor development of edema include:

- **Elevated capillary hydrostatic pressure:** Higher capillary pressures increase plasma filtration into the interstitium, particularly in dependent tissues. Causes include arteriolar dilation (eg, dihydropyridine calcium channel blockers) and impaired venous return (eg, high central venous pressure, venous thrombosis).
- **Decreased plasma oncotic pressure:** Plasma proteins (eg, albumin) generate oncotic pressure that pulls interstitial fluid back into the capillary bed venules. Edema develops in conditions with decreased albumin levels (eg, nephrotic syndrome, cirrhosis, malnutrition).
- **Sodium and water retention:** Increased intravascular volume raises capillary hydrostatic pressure and decreases plasma oncotic pressure (dilutes plasma proteins). Causes include kidney disease and heart failure.
- **Lymphatic obstruction:** Decreased lymphatic return impairs removal of excess interstitial fluid. Common causes of lymphatic obstruction include filariasis, invasive malignancies, and iatrogenic etiologies (eg, surgical lymph node dissection and radiation therapy).

Increased capillary fluid transudation **raises interstitial hydrostatic pressure**, resulting in **increased lymphatic drainage**. This compensatory response can delay the development of clinically apparent edema. However, progressive heart failure, cirrhosis, or renal failure can eventually overwhelm lymphatic return capacity and produce significant edema.

(Choices A and D) Although increased plasma oncotic pressure and decreased capillary permeability oppose edema formation, neither is associated with COPD. Severe COPD may cause polycythemia due to hypoxia, but erythrocyte concentration does not affect plasma oncotic pressure.

(Choice B) In patients with heart failure, activation of the renin-angiotensin-aldosterone system (RAAS) leads to increased aldosterone levels that cause sodium and water retention (exacerbating edema formation). Volume expansion causes increased atrial/brain natriuretic peptide release, which can partially counteract the effects of RAAS activation; however, aldosterone levels remain above normal in patients with heart failure.

1 2 3 4 5 6 7 8 9 10 11 12 13 14 15 16 17 18 19 20 21 22 23 24 25 26 27 28 29 30 31

dependent tissues. Causes include arteriolar dilation (eg, dihydropyridine calcium channel blockers) and impaired venous return (eg, high central venous pressure, venous thrombosis).

- **Decreased plasma oncotic pressure:** Plasma proteins (eg, albumin) generate oncotic pressure that pulls interstitial fluid back into the capillary bed venules. Edema develops in conditions with decreased albumin levels (eg, nephrotic syndrome, cirrhosis, malnutrition).
- **Sodium and water retention:** Increased intravascular volume raises capillary hydrostatic pressure and decreases plasma oncotic pressure (dilutes plasma proteins). Causes include kidney disease and heart failure.
- **Lymphatic obstruction:** Decreased lymphatic return impairs removal of excess interstitial fluid. Common causes of lymphatic obstruction include filariasis, invasive malignancies, and iatrogenic etiologies (eg, surgical lymph node dissection and radiation therapy).

Increased capillary fluid transudation **raises interstitial hydrostatic pressure**, resulting in **increased lymphatic drainage**. This compensatory response can delay the development of clinically apparent edema. However, progressive heart failure, cirrhosis, or renal failure can eventually overwhelm lymphatic return capacity and produce significant edema.

(Choices A and D) Although increased plasma oncotic pressure and decreased capillary permeability oppose edema formation, neither is associated with COPD. Severe COPD may cause polycythemia due to hypoxia, but erythrocyte concentration does not affect plasma oncotic pressure.

(Choice B) In patients with heart failure, activation of the renin-angiotensin-aldosterone system (RAAS) leads to increased aldosterone levels that cause sodium and water retention (exacerbating edema formation). Volume expansion causes increased atrial/brain natriuretic peptide release, which can partially counteract the effects of RAAS activation; however, aldosterone levels remain above normal in patients with heart failure.

(Choice C) Decreased interstitial fluid pressure favors flow into the interstitium and would contribute to the development of peripheral edema.

Educational objective:
Peripheral edema results from the accumulation of fluid in the interstitial spaces. Factors that promote edema include elevated capillary hydrostatic pressure, decreased plasma oncotic pressure, sodium and water retention, and impaired lymphatic drainage. In chronic heart failure, increased lymphatic drainage initially offsets factors favoring edema, whereas acute changes (eg, venous thrombosis, heart failure decompensation) are more likely to produce edema.

Pathophysiology	Cardiovascular System	Cor pulmonale
Subject	System	Topic

1
2
3
4
5
6
7
8
9
10
11
12
13
14
15
16
17
18
19
20
21
22
23
24
25
26
27
28
29
30
31

A 67-year-old man is brought to the emergency department due to progressive shortness of breath. He has had decreasing exercise tolerance for several months, and over the last week he could barely walk to the bathroom without becoming short of breath. The patient has been sleeping in a semirecumbent position recently. Medical history includes type 2 diabetes mellitus, hyperlipidemia, and a myocardial infarction 3 years ago. He takes no medications. The patient is an ex-smoker with a 30-pack-year history. He does not drink alcohol. BMI is 30 kg/m^2. Oxygen saturation is 92% on room air. The apical impulse is palpated in the 6th intercostal space along the anterior axillary line. There is 3+ bilateral pitting edema in the legs. Which of the following is likely increased in this patient?

A. Arteriolar resistance

B. Lung compliance

C. Mixed venous O_2 content

D. Renal perfusion

E. Stroke volume

Submit

A 67-year-old man is brought to the emergency department due to progressive shortness of breath. He has had decreasing exercise tolerance for several months, and over the last week he could barely walk to the bathroom without becoming short of breath. The patient has been sleeping in a semirecumbent position recently. Medical history includes type 2 diabetes mellitus, hyperlipidemia, and a myocardial infarction 3 years ago. He takes no medications. The patient is an ex-smoker with a 30-pack-year history. He does not drink alcohol. BMI is 30 kg/m^2. Oxygen saturation is 92% on room air. The apical impulse is palpated in the 6th intercostal space along the anterior axillary line. There is 3+ bilateral pitting edema in the legs. Which of the following is likely increased in this patient?

- ✓ A. Arteriolar resistance (66%)
- B. Lung compliance (12%)
- C. Mixed venous O_2 content (7%)
- D. Renal perfusion (3%)
- E. Stroke volume (9%)

Omitted
Correct answer
A

66%
Answered correctly

02 secs
Time Spent

03/17/2020
Last Updated

Explanation

1
2
3
4
5
6
7
8
9
10
11
12
13
14
15
16
17
18
19
20
21
22
23
24
25
26
27
28
29
30
31

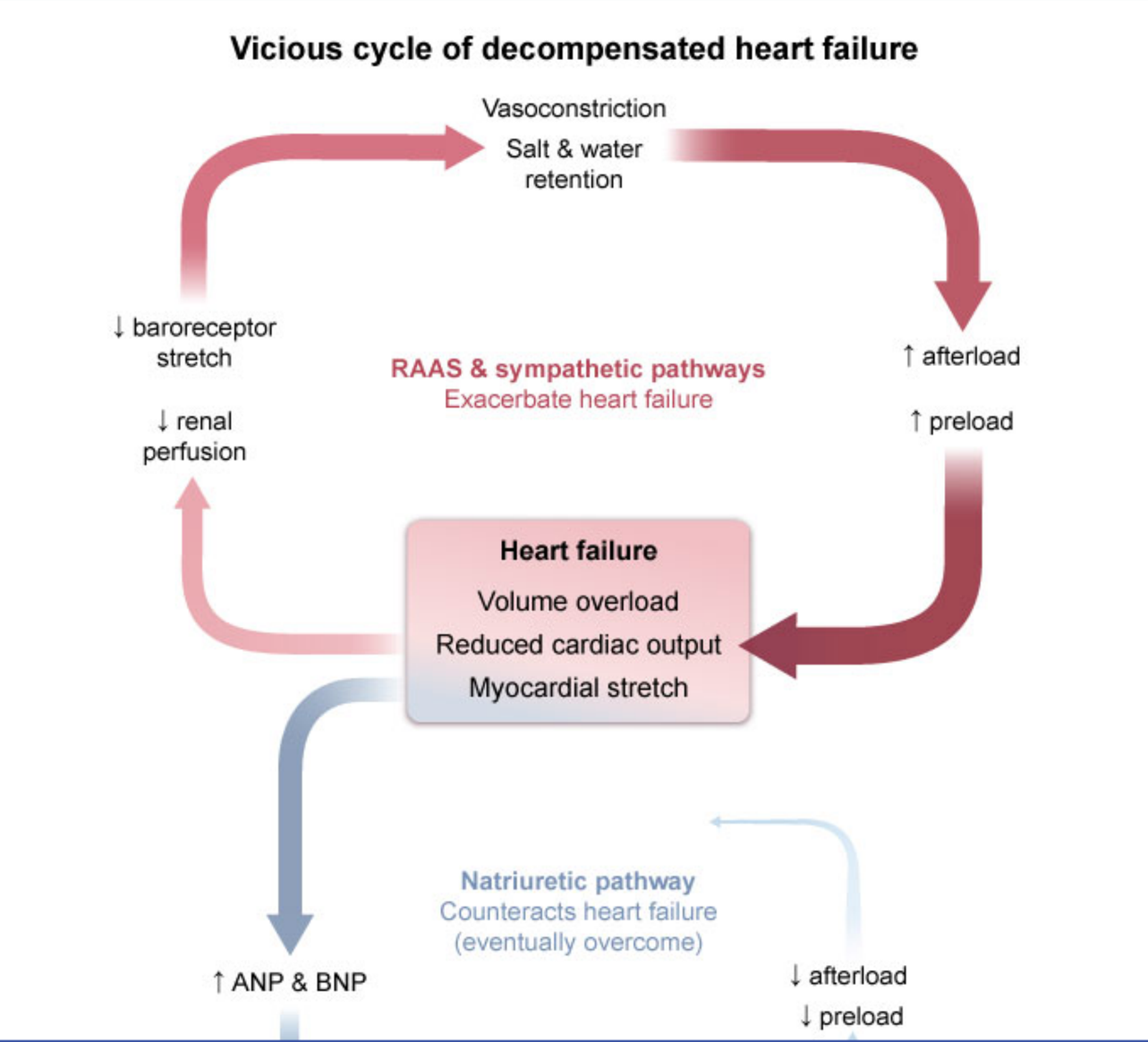

1
2
3
4
5
6
7
8
9
10
11
12
13
14
15
16
17
18
19
20
21
22
23
24
25
26
27
28
29
30
31

Exhibit Display

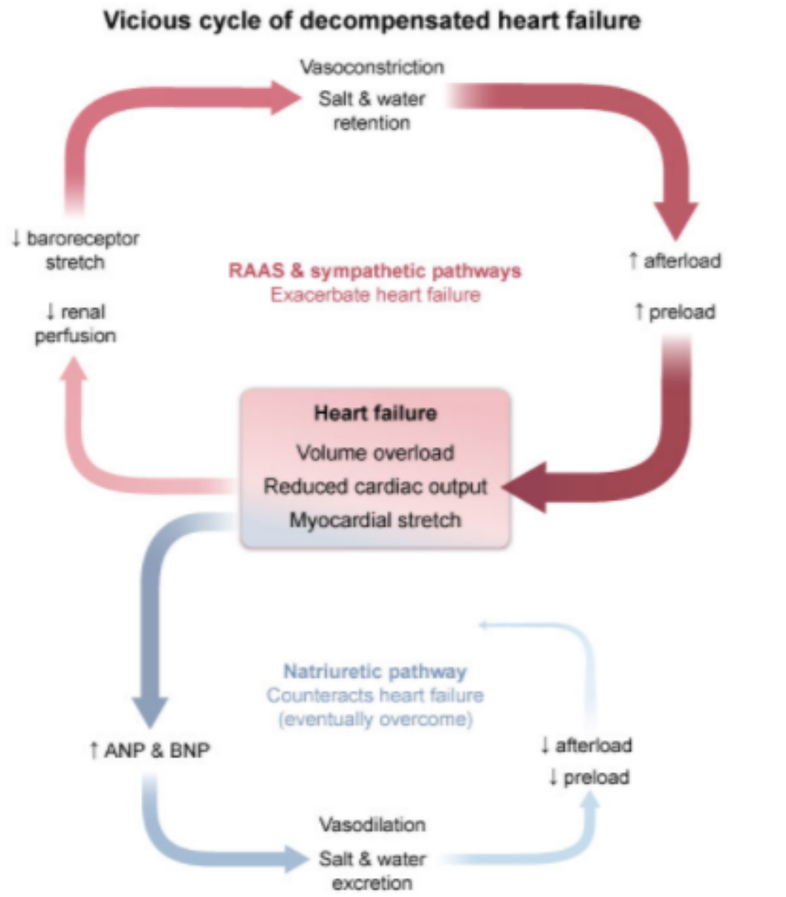

Zoom In | Zoom Out | Reset | Add To New Card | Existing Card

↓ preload

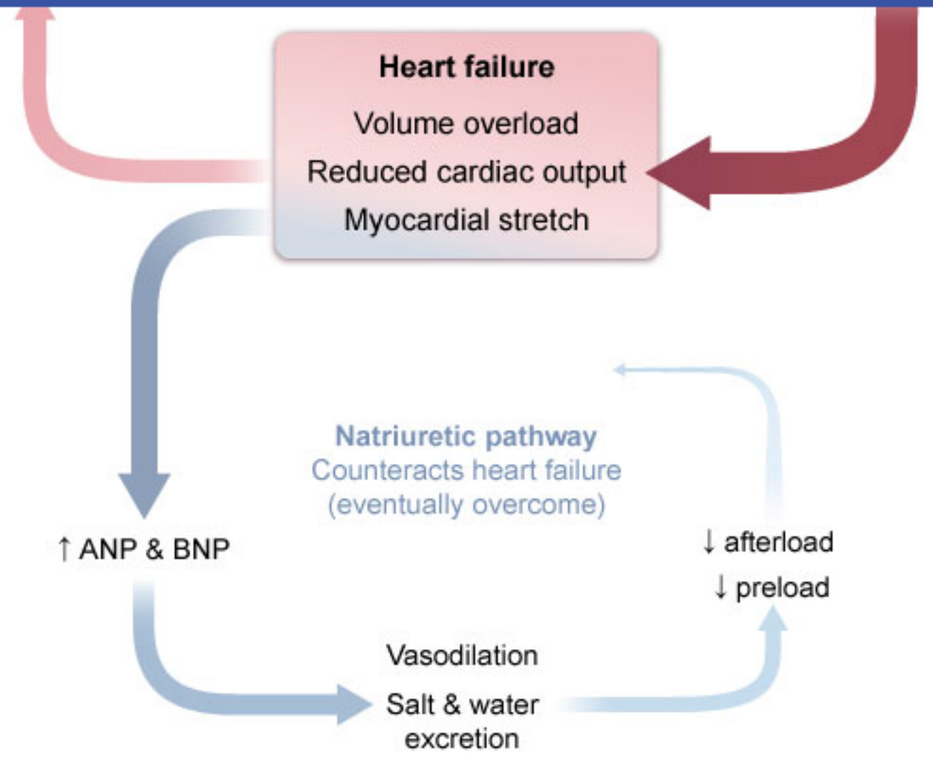

ANP = atrial natriuretic peptide; **BNP** = brain natriuretic peptide; **RAAS** = renin-angiotensin-aldosterone system.

©UWorld

This patient with progressive dyspnea, orthopnea, lower extremity swelling, and a laterally displaced point of maximal impulse has **decompensated heart failure**. Heart failure occurs due to either a progressive decline in myocardial contractility (systolic dysfunction) or impaired ability of the ventricular walls to relax during filling (diastolic dysfunction). Both etiologies eventually lead to **decreased cardiac output** and inadequate oxygen delivery to the tissues, inducing the following **neuroendocrine compensatory mechanisms** in an effort to restore organ perfusion:

- **Increased sympathetic output**: Baroreceptors sense decreased perfusion and stimulate epinephrine and norepinephrine release to increase heart rate and contractility. Vasoconstriction is also triggered, **increasing arteriolar resistance** and raising afterload.

©UWorld

This patient with progressive dyspnea, orthopnea, lower extremity swelling, and a laterally displaced point of maximal impulse has **decompensated heart failure**. Heart failure occurs due to either a progressive decline in myocardial contractility (systolic dysfunction) or impaired ability of the ventricular walls to relax during filling (diastolic dysfunction). Both etiologies eventually lead to **decreased cardiac output** and inadequate oxygen delivery to the tissues, inducing the following **neuroendocrine compensatory mechanisms** in an effort to restore organ perfusion:

- **Increased sympathetic output**: Baroreceptors sense decreased perfusion and stimulate epinephrine and norepinephrine release to increase heart rate and contractility. Vasoconstriction is also triggered, **increasing arteriolar resistance** and raising afterload.
- **Renin-angiotensin-aldosterone system (RAAS) activation**: Decreased renal perfusion **(Choice D)** leads to increased secretion of renin and increased circulating levels of angiotensin II, a potent vasoconstrictor that further increases afterload. Adrenal secretion of aldosterone also increases, which stimulates sodium and water retention and increases circulating blood volume (preload).

Although these compensatory mechanisms initially improve organ perfusion, they are overall **maladaptive**. A vicious cycle is generated as the failing heart is unable to pump against increased afterload, and volume retention creates venous congestion in the kidneys that reduces glomerular filtration rate and further impairs diuresis. Atrial and ventricular stretch triggers the release of natriuretic peptides that stimulate vasodilation and fluid diuresis to counteract the vicious cycle; however, these effects are outweighed by the downward-spiraling negative effects of sympathetic drive and RAAS activation.

(Choice B) Left ventricular failure leads to increased pulmonary venous pressure and transudation of fluid into the lung parenchyma, which stiffens the alveolar walls and decreases lung compliance.

(Choice C) With reduced cardiac output, the tissues become starved for O_2 and increase O_2 extraction from the available capillary blood. This leads to a reduction in mixed venous O_2 content.

(Choice E) Stroke volume is generally maintained early in heart failure (due to compensatory mechanisms) and decreases as decompensation takes place.

Educational objective:
Decreased cardiac output in heart failure triggers neuroendocrine compensatory mechanisms to maintain organ perfusion; however, the compensatory mechanisms are maladaptive over the long term. Increased sympathetic output and activation of the renin-angiotensin-aldosterone

increase heart rate and contractility. Vasoconstriction is also triggered, **increasing arteriolar resistance** and raising afterload.

- **Renin-angiotensin-aldosterone system (RAAS) activation**: Decreased renal perfusion **(Choice D)** leads to increased secretion of renin and increased circulating levels of angiotensin II, a potent vasoconstrictor that further increases afterload. Adrenal secretion of aldosterone also increases, which stimulates sodium and water retention and increases circulating blood volume (preload).

Although these compensatory mechanisms initially improve organ perfusion, they are overall **maladaptive**. A vicious cycle is generated as the failing heart is unable to pump against increased afterload, and volume retention creates venous congestion in the kidneys that reduces glomerular filtration rate and further impairs diuresis. Atrial and ventricular stretch triggers the release of natriuretic peptides that stimulate vasodilation and fluid diuresis to counteract the vicious cycle; however, these effects are outweighed by the downward-spiraling negative effects of sympathetic drive and RAAS activation.

(Choice B) Left ventricular failure leads to increased pulmonary venous pressure and transudation of fluid into the lung parenchyma, which stiffens the alveolar walls and decreases lung compliance.

(Choice C) With reduced cardiac output, the tissues become starved for O_2 and increase O_2 extraction from the available capillary blood. This leads to a reduction in mixed venous O_2 content.

(Choice E) Stroke volume is generally maintained early in heart failure (due to compensatory mechanisms) and decreases as decompensation takes place.

Educational objective:
Decreased cardiac output in heart failure triggers neuroendocrine compensatory mechanisms to maintain organ perfusion; however, the compensatory mechanisms are maladaptive over the long term. Increased sympathetic output and activation of the renin-angiotensin-aldosterone system stimulate vasoconstriction and volume retention, compounding the hemodynamic stress on an already failing heart and creating a vicious cycle of decompensation.

Pathophysiology	Cardiovascular System	Chronic heart failure
Subject	System	Topic

Copyright © UWorld. All rights reserved.

A 32-year-old woman comes to the emergency department with lightheadedness and shortness of breath, which started while shopping at a supermarket. During the last 6 months, she had increasing shortness of breath and had to adjust her daily activities. The patient has no other medical problems and does not use tobacco, alcohol, or illicit drugs. There is no family history of heart disease, stroke, or blood clots. Her BMI is 25 kg/m^2. After initial assessment, the patient reports that she feels "fine," refuses further evaluation, and insists on being discharged. She dies a month later. At autopsy, her heart has the following appearance (RV, right ventricle; LV, left ventricle):

Which of the following is the most likely diagnosis?

- A. Bicuspid aortic valve with acquired aortic stenosis
- B. Dilated cardiomyopathy
- C. Essential hypertension
- D. Myocardial infarction
- E. Pulmonary arterial hypertension
- F. Wolff-Parkinson-White syndrome

Submit

A 32-year-old woman comes to the emergency department with lightheadedness and shortness of breath, which started while shopping at a supermarket. During the last 6 months, she had increasing shortness of breath and had to adjust her daily activities. The patient has no other medical problems and does not use tobacco, alcohol, or illicit drugs. There is no family history of heart disease, stroke, or blood clots. Her BMI is 25 kg/m^2. After initial assessment, the patient reports that she feels "fine," refuses further evaluation, and insists on being discharged. She dies a month later. At autopsy, her heart has the following appearance (RV, right ventricle; LV, left ventricle):

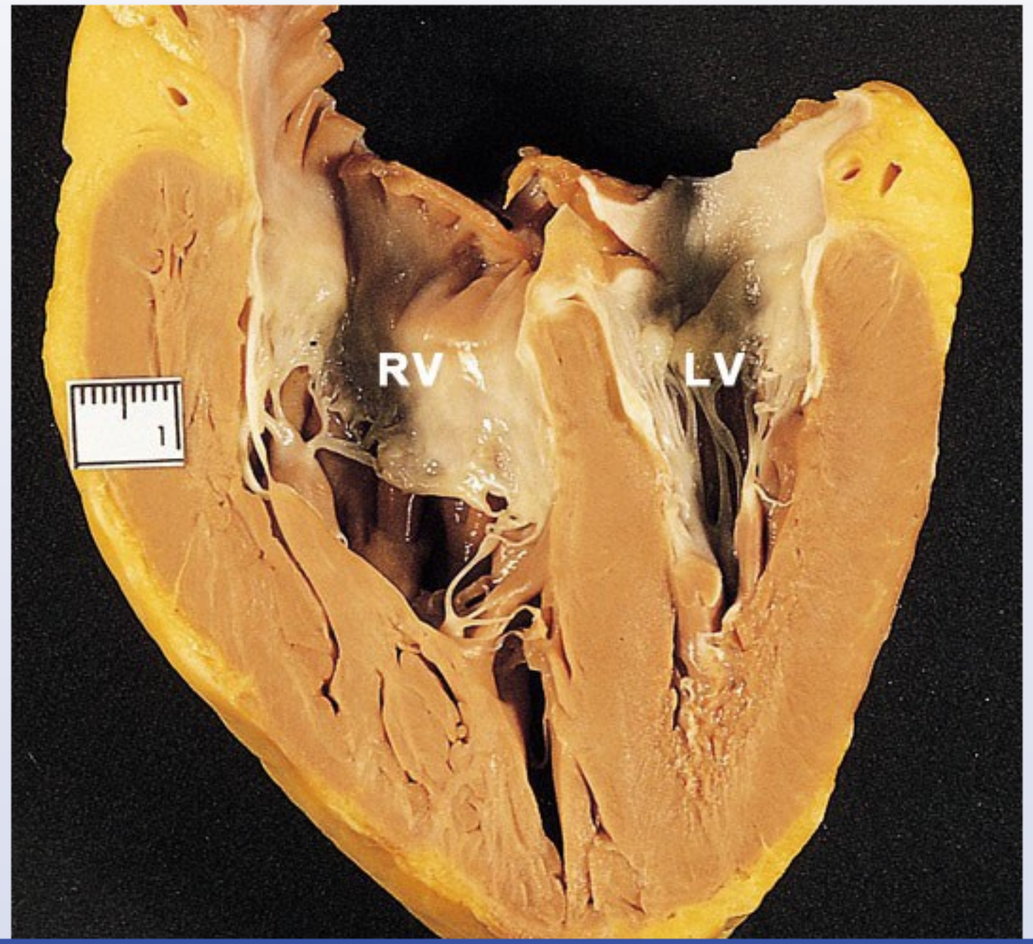

1
2
3
4
5
6
7
8
9
10
11
12
13
14
15
16
17
18
19
20
21
22
23
24
25
26
27
28
29
30
31

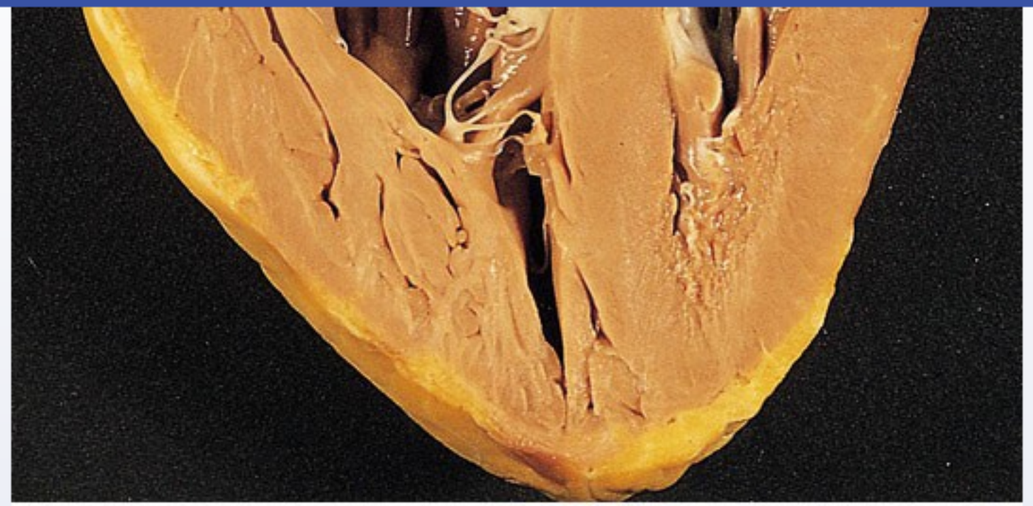

Displayed with permission from Springer Healthcare Ltd. © Copyright 2000 by Current Medicine

Which of the following is the most likely diagnosis?

- A. Bicuspid aortic valve with acquired aortic stenosis
- B. Dilated cardiomyopathy
- C. Essential hypertension
- D. Myocardial infarction
- E. Pulmonary arterial hypertension
- F. Wolff-Parkinson-White syndrome

Submit

1
2
3
4
5
6
7
8
9
10
11
12
13
14
15
16
17
18
19
20
21
22
23
24
25
26
27
28
29
30
31

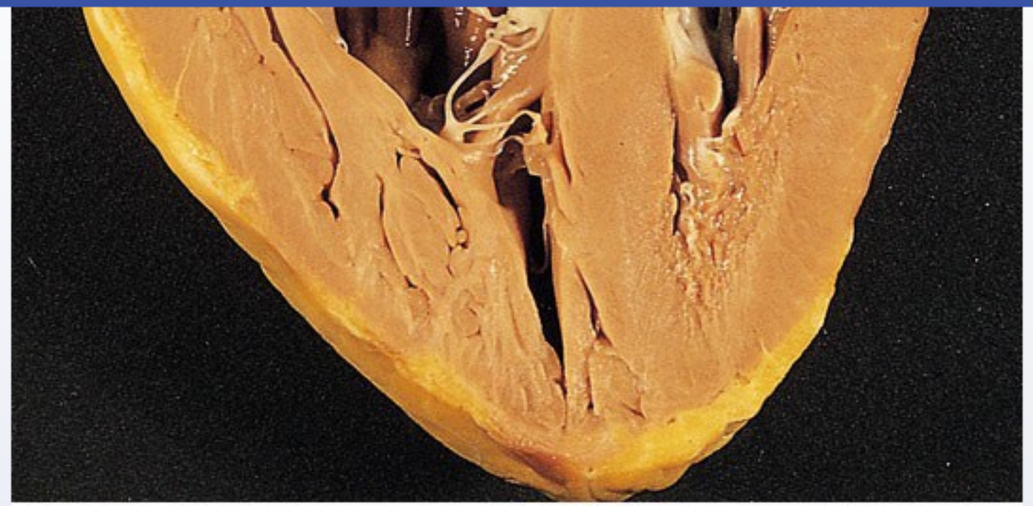

Displayed with permission from Springer Healthcare Ltd. © Copyright 2000 by Current Medicine

Which of the following is the most likely diagnosis?

- A. Bicuspid aortic valve with acquired aortic stenosis (5%)
- B. Dilated cardiomyopathy (3%)
- C. Essential hypertension (4%)
- D. Myocardial infarction (2%)
- ✓ E. Pulmonary arterial hypertension (80%)
- F. Wolff-Parkinson-White syndrome (3%)

Omitted
Correct answer

80%
Answered correctly

09 secs
Time Spent

03/10/2020
Last Updated

1
2
3
4
5
6
7
8
9
10
11
12
13
14
15
16
17
18
19
20
21
22
23
24
25
26
27
28
29
30
31

Autopsy reveals significant **thickening of the right ventricular free wall** (almost 2 cm in thickness; normal: 3-4 mm) compared to the left ventricle. This finding of severe right ventricular hypertrophy in a young woman with **progressive dyspnea** and sudden death is suggestive of **pulmonary arterial hypertension** (PAH).

Pulmonary hypertension can be caused by a number of conditions, including chronic lung disease and left heart failure. Pulmonary hypertension due to primary processes affecting the lung vasculature is referred to as PAH, a condition that most often affects women ages 20-40. PAH is characterized by intimal hyperplasia and fibrosis, medial hypertrophy, and formation of capillary tufts.

Long-standing pulmonary hypertension eventually leads to hypertrophy and/or dilation of the right ventricle (**cor pulmonale**). Patients typically present with progressive dyspnea, exertional angina, or syncope. As PAH progresses, signs of right-sided heart failure (eg, hepatomegaly, ascites, peripheral edema) can become prominent. The most common cause of death in patients with PAH is right heart failure with circulatory collapse and respiratory failure.

(Choices A and C) Aortic stenosis and essential hypertension cause left ventricular wall thickening and hypertrophy, not right ventricular hypertrophy.

(Choice B) Dilated cardiomyopathy typically increases the size of one or both ventricular chambers. This patient's ventricular cavities are small and normal in size, not enlarged. Moreover, the left ventricle is relatively normal in shape (elliptical, with a long axis approximately twice that of lateral short axis dimensions), which is not the case with left ventricular dilation.

(Choice D) Myocardial infarctions occur more frequently in older patients (age >65). Morphological changes in the myocardium include an area of reddish-blue discoloration that evolves into a yellow-tan discrete infarct with eventual formation of a white scar.

(Choice F) Wolff-Parkinson-White (WPW) syndrome should be suspected in any case of sudden cardiac death in an otherwise healthy young individual. WPW syndrome is an electrophysiological abnormality of atrioventricular (AV) node conduction that is discernible on histology as small accessory AV impulse conduction pathway(s) anatomically separate from the AV node. There are no consistent gross morphological changes to the ventricles.

Educational objective:
Pulmonary hypertension should be suspected in young and otherwise healthy patients with fatigue, progressive dyspnea, atypical chest pain, or unexplained syncope. Long-standing pulmonary hypertension leads to hypertrophy and/or dilation of the right ventricle (cor pulmonale).

1
2
3
4
5
6
7
8
9
10
11
12
13
14
15
16
17
18
19
20
21
22
23
24
25
26
27
28
29
30
31

A 52-year-old man comes to the office with concerns about a "heart problem." Three years ago, the patient was told during a routine physical examination that he had a heart murmur. Currently, he has no specific complaints, but he mentions that he has become tired more easily in the past year. He has no chest pain or lower extremity swelling or significant medical history. The patient was healthy as a child and received all his childhood vaccinations. Blood pressure is 145/90 mm Hg and pulse is 80/min and regular. Physical examination reveals a holosystolic murmur best heard at the apex of the heart that radiates to the axilla. The lungs are clear on auscultation and abdominal examination is unremarkable. Which of the following is the best indicator of the severity of this patient's valve disease?

A. Presence of audible S3

B. Presence of audible S4

C. Presence of mid-systolic click

D. S2-to-opening snap time interval

E. Splitting of S2 accentuated by inspiration

Submit

A 52-year-old man comes to the office with concerns about a "heart problem." Three years ago, the patient was told during a routine physical examination that he had a heart murmur. Currently, he has no specific complaints, but he mentions that he has become tired more easily in the past year. He has no chest pain or lower extremity swelling or significant medical history. The patient was healthy as a child and received all his childhood vaccinations. Blood pressure is 145/90 mm Hg and pulse is 80/min and regular. Physical examination reveals a holosystolic murmur best heard at the apex of the heart that radiates to the axilla. The lungs are clear on auscultation and abdominal examination is unremarkable. Which of the following is the best indicator of the severity of this patient's valve disease?

- ✓ A. Presence of audible S3 (40%)
- B. Presence of audible S4 (11%)
- C. Presence of mid-systolic click (15%)
- D. S2-to-opening snap time interval (23%)
- E. Splitting of S2 accentuated by inspiration (8%)

Omitted
Correct answer
A

40%
Answered correctly

02 secs
Time Spent

06/29/2020
Last Updated

Explanation

A holosystolic murmur at the apex with radiation to the axilla is consistent with **mitral regurgitation** (MR). The murmur is generated by regurgitant blood flow from the left ventricle back to the left atrium during systole. This results in elevated pressure and blood volume in the left atrium, which increases the amount of blood reentering the left ventricle during diastole; an **audible S3 gallop** occurs when the left ventricle is unable to accommodate the excess blood flow.

A holosystolic murmur at the apex with radiation to the axilla is consistent with **mitral regurgitation** (MR). The murmur is generated by regurgitant blood flow from the left ventricle back to the left atrium during systole. This results in elevated pressure and blood volume in the left atrium, which increases the amount of blood reentering the left ventricle during diastole; an **audible S3 gallop** occurs when the left ventricle is unable to accommodate the excess blood flow.

An S3 is generated by the sudden cessation of blood flow into the left ventricle during the passive filling phase of diastole. A higher volume of blood flow or a more dilated left ventricle is more likely to produce an S3, and although an S3 can be a normal finding in healthy young adults, it is usually a pathologic finding in older adults that is classically associated with heart failure. In patients with MR, an S3 is the best indicator of severe MR with left-sided volume overload; the **absence of an S3** can be used to **exclude severe chronic MR**.

(Choice B) An S4 is a low-frequency diastolic sound that occurs during the atrial kick of ventricular diastole, and it reflects blood colliding with a stiff ventricular wall. It often indicates pathology such as hypertrophic cardiomyopathy or concentric left ventricular hypertrophy (eg, due to hypertension or aortic stenosis).

(Choice C) A mid-systolic click is characteristic of mitral valve prolapse. It is caused by sudden tensing of the chordae tendineae as they are pulled taut by the valve leaflets ballooning into the left atrium. The timing of the click varies with left ventricular volume; it occurs earlier in systole with physical maneuvers that decrease left ventricular volume.

(Choice D) An opening snap is an early diastolic sound heard after S2 in patients with mitral or tricuspid stenosis. The S2-to-opening snap interval is the time between the closure of the aortic valve and the abrupt halting of leaflet motion during opening of a stenotic mitral valve; a shorter S2-to-opening snap interval is indicative of more severe mitral stenosis.

(Choice E) Pulmonic valve stenosis delays pulmonic valve closure leading to widened splitting of S2. The splitting is further accentuated by the increase in venous return to the right side of the heart that occurs with inspiration.

Educational objective:
Patients with severe mitral regurgitation develop left-sided volume overload with an S3 gallop due to the large volume of regurgitant flow reentering the ventricle during mid-diastole. The absence of an S3 gallop excludes severe chronic MR.

References

- Diastolic properties of the left ventricle in normal adults and in patients with third heart sounds.

A 46-year-old man with a 30-pack-year smoking history develops right leg pain and swelling after returning from an overseas trip. He is diagnosed with a lower extremity deep venous thrombosis and is started on intravenous heparin. Shortly after being hospitalized, he develops right-sided weakness and facial droop. CT scan of the head reveals a left middle cerebral artery stroke. Which of the following physical examination findings is most likely to be present in this patient?

A. Diastolic decrescendo-type murmur that decreases following amyl nitrite inhalation

B. Ejection-type systolic murmur that increases on standing

C. Presystolic murmur that disappears with atrial fibrillation

D. Midsystolic click that occurs earlier with inspiration

E. Wide splitting of S2 that does not change with respiration

Submit

A 46-year-old man with a 30-pack-year smoking history develops right leg pain and swelling after returning from an overseas trip. He is diagnosed with a lower extremity deep venous thrombosis and is started on intravenous heparin. Shortly after being hospitalized, he develops right-sided weakness and facial droop. CT scan of the head reveals a left middle cerebral artery stroke. Which of the following physical examination findings is most likely to be present in this patient?

- A. Diastolic decrescendo-type murmur that decreases following amyl nitrite inhalation (6%)
- B. Ejection-type systolic murmur that increases on standing (9%)
- C. Presystolic murmur that disappears with atrial fibrillation (15%)
- D. Midsystolic click that occurs earlier with inspiration (7%)
- ✓ E. Wide splitting of S2 that does not change with respiration (60%)

Omitted
Correct answer
E

60%
Answered correctly

02 secs
Time Spent

04/25/2020
Last Updated

Explanation

A cerebrovascular event (eg, transient ischemic attack, stroke) in the setting of known venous thromboembolic disease is suspicious for **paradoxical embolism**. Paradoxical emboli originate in the systemic venous circulation (lower or upper extremities) and enter the systemic arterial circulation via an intracardiac or intrapulmonary shunt. They can occur in patients with **patent foramen ovale, atrial septal defects**, ventricular septal defects, or large pulmonary arteriovenous malformations.

Atrial septal defects with left-to-right shunting typically cause **wide and fixed splitting** (no change with respiration) of the second heart sound (S2). Patients may also have a mid-systolic ejection murmur over the left upper sternal border resulting from increased flow across the pulmonic

1 2 3 4 5 6 7 8 9 10 11 12 13 14 15 16 17 18 19 20 21 22 23 24 25 26 27 28 29 30 31

A cerebrovascular event (eg, transient ischemic attack, stroke) in the setting of known venous thromboembolic disease is suspicious for **paradoxical embolism**. Paradoxical emboli originate in the systemic venous circulation (lower or upper extremities) and enter the systemic arterial circulation via an intracardiac or intrapulmonary shunt. They can occur in patients with **patent foramen ovale, atrial septal defects**, ventricular septal defects, or large pulmonary arteriovenous malformations.

Atrial septal defects with left-to-right shunting typically cause **wide and fixed splitting** (no change with respiration) of the second heart sound (S2). Patients may also have a mid-systolic ejection murmur over the left upper sternal border resulting from increased flow across the pulmonic valve and a mid-diastolic rumble due to increased flow across the tricuspid valve. Importantly, a paradoxical embolism can occur even in patients with net left-to-right shunting due to **transient reversal of the shunt** during periods of elevated right-sided pressure (eg, early ventricular systole, straining during coughing or defecation).

(Choice A) An early diastolic decrescendo murmur is characteristic of aortic regurgitation. Inhaled amyl nitrite produces marked vasodilatation, which reduces systemic arterial pressure and regurgitant flow (lessening the murmur).

(Choice B) A systolic ejection murmur that increases in intensity with standing can be heard in patients with hypertrophic cardiomyopathy (due to a decrease in left ventricular outflow tract size). In contrast, the murmur of valvular aortic stenosis decreases in intensity upon standing.

(Choice C) Mitral or tricuspid valve stenosis can cause a diastolic murmur with presystolic accentuation due to atrial contraction. With mild stenosis, the murmur may only be audible during the accentuation phase in late diastole; atrial fibrillation may cause the murmur to disappear completely.

(Choice D) The midsystolic click of mitral valve prolapse occurs earlier with inspiration due to the reduced left ventricular volume caused by decreased venous return to the left heart.

Educational objective:
Paradoxical embolism occurs when a thrombus from the venous system crosses into the arterial circulation via an abnormal connection between the right and left cardiac chambers (eg, patent foramen ovale, atrial septal defect, or ventricular septal defect). Atrial left-to-right shunts cause wide and fixed splitting of S2 and can facilitate paradoxical embolism due to periods of transient shunt reversal (eg, during straining or coughing).

References

- Paradoxical embolism.

A cerebrovascular event (eg, transient ischemic attack, stroke) in the setting of known venous thromboembolic disease is suspicious for **paradoxical embolism**.

arterial circulation via an i

ventricular septal defects,

Atrial septal defects with l

(S2). Patients may also h

valve and a mid-diastolic r

with net left-to-right shunti

straining during coughing

(Choice A) An early diast

which reduces systemic a

(Choice B) A systolic eje

a decrease in left ventricu

(Choice C) Mitral or tricu

stenosis, the murmur may

completely.

(Choice D) The midsysto

decreased venous return

Educational objective:

Paradoxical embolism occ

the right and left cardiac c

wide and fixed splitting of

References

- Paradoxical embolism

Exhibit Display

Auscultation of murmurs

Maneuver	Change in cardiac parameters	Murmurs that increase	Murmurs that decrease
Inspiration	↑ Venous return to right heart ↓ Venous return to left heart	Most right-sided murmurs	Most left-sided murmurs
Valsalva strain phase	↓ Preload	MVP & HCM (↓ LV volume)	Most other murmurs (↓ flow through stenotic or regurgitant valve)
Abrupt standing			
Squatting	↑ Preload ↑ Afterload	Most other murmurs (↑ flow through stenotic or regurgitant valve)	MVP & HCM (↑ LV volume)
Passive leg raise	↑ Preload		
Handgrip	↑ Afterload	AR, MR & VSD (↑ LV & aortic pressure)	HCM (↑ LV volume) AS (↓ transvalvular pressure gradient)

AR = aortic regurgitation; **AS** = aortic stenosis; **HCM** = hypertrophic cardiomyopathy; **LV** = left ventricular; **MR** = mitral regurgitation; **MVP** = mitral valve prolapse; **VSD** = ventricular septal defect.

Add To New Card | Existing Card

1
2
3
4
5
6
7
8
9
10
11
12
13
14
15
16
17
18
19
20
21
22
23
24
25
26
27
28
29
30
31

A 62-year-old woman comes to the hospital with intermittent but progressive substernal chest pain over the last 36 hours. Medical history includes hypertension and hyperlipidemia, but the patient has been poorly compliant with her medication regimen and outpatient follow-up. She previously smoked a pack daily for 30 years but quit last year. Her blood pressure is 130/75 mm Hg and pulse is 73/min. ECG on admission shows normal sinus rhythm with a 2-mm ST segment elevation in leads V2-V5. The patient is treated with medical management. However, on the fifth day of hospitalization she dies suddenly, despite adequate resuscitation. Which of the following is the most likely cause of death in this patient?

- A. Carotid artery occlusion
- B. Hypertensive emergency
- C. Increased venous return
- D. Profound hypotension
- E. True ventricular aneurysm

Submit

A 62-year-old woman comes to the hospital with intermittent but progressive substernal chest pain over the last 36 hours. Medical history includes hypertension and hyperlipidemia, but the patient has been poorly compliant with her medication regimen and outpatient follow-up. She previously smoked a pack daily for 30 years but quit last year. Her blood pressure is 130/75 mm Hg and pulse is 73/min. ECG on admission shows normal sinus rhythm with a 2-mm ST segment elevation in leads V2-V5. The patient is treated with medical management. However, on the fifth day of hospitalization she dies suddenly, despite adequate resuscitation. Which of the following is the most likely cause of death in this patient?

- A. Carotid artery occlusion (16%)
- B. Hypertensive emergency (2%)
- C. Increased venous return (3%)
- ✓ D. Profound hypotension (41%)
- E. True ventricular aneurysm (36%)

Omitted
Correct answer
D

41%
Answered correctly

02 secs
Time Spent

05/17/2020
Last Updated

Explanation

Mechanical complications of acute myocardial infarction		
Complication	**Time frame**	**Clinical findings**
Right ventricular failure	Acute	• Hypotension • Clear lungs

Mechanical complications of acute myocardial infarction		
Complication	**Time frame**	**Clinical findings**
Right ventricular failure	Acute	• Hypotension • Clear lungs • Kussmaul sign
Papillary muscle rupture	Acute or within 3-5 days	• Severe MR with flail leaflet • New holosystolic murmur • Severe pulmonary edema
Interventricular septal rupture	Acute or within 3-5 days	• Chest pain • New holosystolic murmur • Biventricular failure, shock • Step up in O_2 level from RA to RV
Ventricular free-wall rupture	Within 5 days or up to 2 weeks	• Chest pain • Tamponade, shock • Distant heart sounds
Left ventricular aneurysm	Within several months	• Subacute heart failure • Stable angina

MR = mitral regurgitation; **RA** = right atrium; **RV** = right ventricle.

This patient most likely died from profound hypotension due to **ruptured left ventricular free wall**. Her initial presentation of substernal chest discomfort and ST segment elevation in anterior precordial leads is consistent with acute anterior wall myocardial infarction (MI). Free wall rupture is a catastrophic mechanical complication that usually occurs within the first 5-14 days after a large anterior transmural MI (from left anterior descending occlusion). During this timeframe, the infarcted myocardium is substantially weakened by coagulative necrosis, neutrophilic and macrophage infiltration, and enzymatic lysis of myocardial connective tissue. Abrupt rupture of the left ventricle leads to **hemopericardium** and

This patient most likely died from profound hypotension due to **ruptured left ventricular free wall**. Her initial presentation of substernal chest discomfort and ST segment elevation in anterior precordial leads is consistent with acute anterior wall myocardial infarction (MI). Free wall rupture is a catastrophic mechanical complication that usually occurs within the first 5-14 days after a large anterior transmural MI (from left anterior descending occlusion). During this timeframe, the infarcted myocardium is substantially weakened by coagulative necrosis, neutrophilic and macrophage infiltration, and enzymatic lysis of myocardial connective tissue. Abrupt rupture of the left ventricle leads to **hemopericardium** and **cardiac tamponade**. Patients have sudden onset of chest pain and **profound hypotension and shock**, with rapid progression to pulseless electrical activity and death. Various forms of cardiac rupture (listed from most common to least common) and their associated clinical signs are as follows:

- Free wall rupture – hemopericardium and cardiac tamponade
- Ventricular septal rupture – acute ventricular septal defect and left-to-right shunting
- Papillary muscle rupture – acute onset of severe mitral regurgitation

(Choice A) Carotid artery occlusion can lead to ischemic symptoms (eg, hemiparesis, vision changes) but does not typically cause sudden death.

(Choice B) Hypertensive emergency can lead to aortic dissection that typically presents with tearing chest or back pain. Hypotension and shock can occur with retrograde extension of the dissection into the pericardial cavity or coronary arteries, with resultant hemopericardium or MI, respectively. However, this patient's presentation of initial normal blood pressure and ST segment elevation is more suggestive of acute MI with subsequent cardiac rupture.

(Choice C) Abrupt rupture of the left ventricle leads to hemopericardium and cardiac tamponade. This leads to decreased venous return to the right heart due to increased pressure in the pericardial cavity.

(Choice E) True aneurysms of the ventricular wall are bound by scarred myocardium that is tough and fibrotic. They are a late complication (>1 month) of large transmural infarcts and can cause mural thrombus, arrhythmias, and heart failure, but rarely rupture.

Educational objective:
Rupture of the left ventricular free wall is a catastrophic mechanical complication of anterior wall myocardial infarction (MI) that usually occurs within the first 5-14 days after MI. Rupture leads to hemopericardium and cardiac tamponade, causing profound hypotension and shock with rapid progression to pulseless electrical activity and death.

References

This patient most likely died from profound hypotension due to **ruptured left ventricular free wall**. Her initial presentation of substernal chest

Exhibit Display

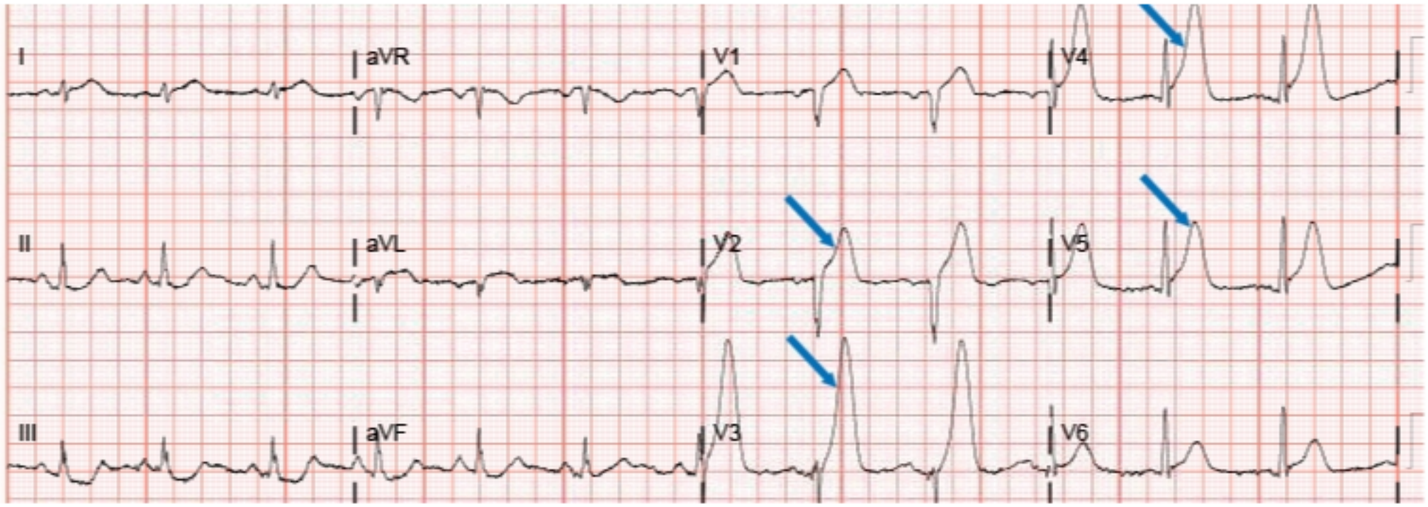

Zoom In | Zoom Out | Reset | Add To New Card | Existing Card

References

This item has associated media that may require the use of headphones. Please ensure your system/speaker volume is set to an audible level.

A 52-year-old man comes to the physician because of increasing fatigue over the last 2 weeks. He has also been experiencing exertional dyspnea and occasional headaches. Cardiac auscultation findings at the left sternal border are shown below. Which of the following is most consistent with this patient's auscultatory findings?

Play Media

A. Aortic regurgitation
B. Hypertrophic cardiomyopathy
C. Mitral valve prolapse
D. Papillary muscle dysfunction
E. Tricuspid regurgitation

Submit

This item has associated media that may require the use of headphones. Please ensure your system/speaker volume is set to an audible level.

A 52-year-old man comes to the physician because of increasing fatigue over the last 2 weeks. He has also been experiencing exertional dyspnea and occasional headaches. Cardiac auscultation findings at the left sternal border are shown below. Which of the following is most consistent with this patient's auscultatory findings?

Play Media

- A. Aortic regurgitation (34%)
- B. Hypertrophic cardiomyopathy (13%)
- C. Mitral valve prolapse (19%)
- D. Papillary muscle dysfunction (8%)
- E. Tricuspid regurgitation (24%)

Omitted
Correct answer
A

34%
Answered correctly

02 secs
Time Spent

07/03/2020
Last Updated

Explanation

Cardiac murmurs*

Cardiac murmurs*

Systolic	Aortic stenosis	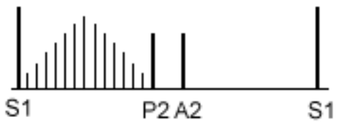	Crescendo-decrescendo at RUSB, A2 soft & delayed
	Mitral regurgitation	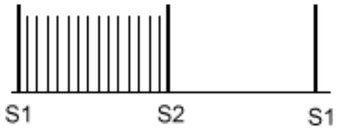	Holosystolic at apex & radiates to axilla
	Hypertrophic cardiomyopathy	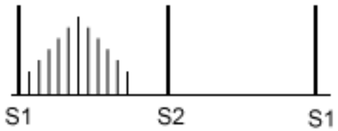	Crescendo-decrescendo at mid-left sternal border
	Mitral valve prolapse	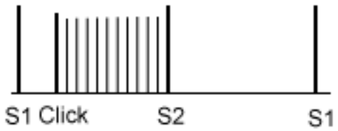	Midsystolic click followed by late systolic murmur
	Atrial septal defect	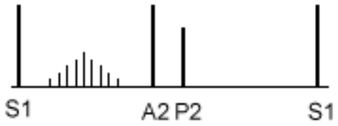	Midsystolic with wide & fixed splitting of S2
	Ventricular septal defect	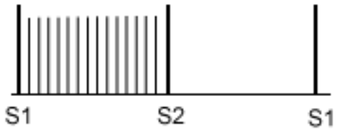	Holsystolic at left sternal border
Diastolic	Aortic regurgitation	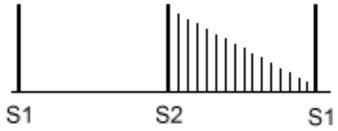	Decrescendo at LUSB (valvular), RUSB (aortic root)

Exhibit Display

Systolic	Aortic stenosis	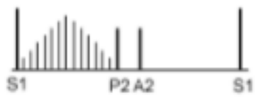	Crescendo-decrescendo at RUSB, A2 soft & delayed
	Mitral regurgitation	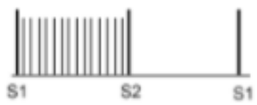	Holosystolic at apex & radiates to axilla
	Hypertrophic cardiomyopathy	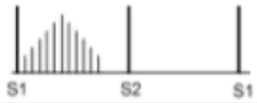	Crescendo-decrescendo at mid-left sternal border
	Mitral valve prolapse	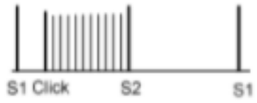	Midsystolic click followed by late systolic murmur
	Atrial septal defect		Midsystolic with wide & fixed splitting of S2
	Ventricular septal defect	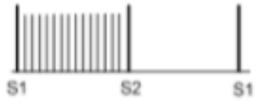	Holsystolic at left sternal border
Diastolic	Aortic regurgitation	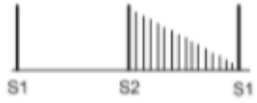	Decrescendo at LUSB (valvular), RUSB (aortic root)
	Mitral stenosis		Opening snap followed by middiastolic rumble with presystolic accentuation
			Machine-like in

Zoom In | Zoom Out | Reset | Add To New Card | Existing Card

increase in intensity with inspiration.

Exhibit Display

Systolic			
	Mitral regurgitation		Holosystolic at apex & radiates to axilla
	Hypertrophic cardiomyopathy	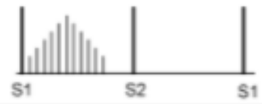	Crescendo-decrescendo at mid-left sternal border
	Mitral valve prolapse	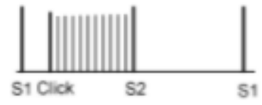	Midsystolic click followed by late systolic murmur
	Atrial septal defect	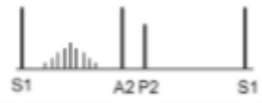	Midsystolic with wide & fixed splitting of S2
	Ventricular septal defect	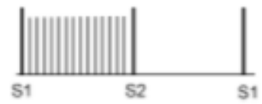	Holsystolic at left sternal border
Diastolic	Aortic regurgitation	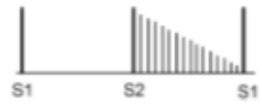	Decrescendo at LUSB (valvular), RUSB (aortic root)
	Mitral stenosis		Opening snap followed by middiastolic rumble with presystolic accentuation
Continuous	Patent ductus arteriosus		Machine-like in interscapular region (posteriorly)

Zoom In | Zoom Out | Reset | Add To New Card | Existing Card

increase in intensity with inspiration.

Systolic	Hypertrophic cardiomyopathy	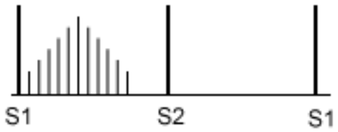	Crescendo-decrescendo at mid-left sternal border
	Mitral valve prolapse	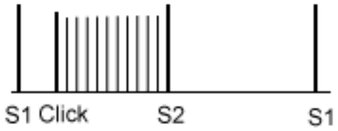	Midsystolic click followed by late systolic murmur
	Atrial septal defect	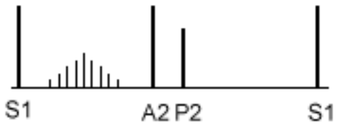	Midsystolic with wide & fixed splitting of S2
	Ventricular septal defect	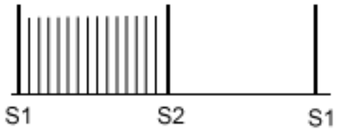	Holsystolic at left sternal border
Diastolic	Aortic regurgitation	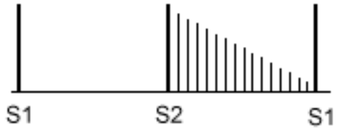	Decrescendo at LUSB (valvular), RUSB (aortic root)
	Mitral stenosis	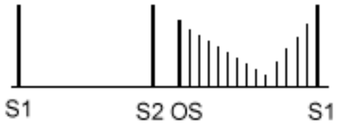	Opening snap followed by middiastolic rumble with presystolic accentuation
Continuous	Patent ductus arteriosus	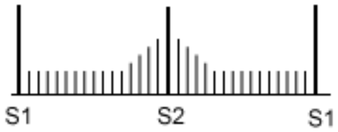	Machine-like in interscapular region (posteriorly)

*Pulmonic and tricuspid valve murmurs are similar in character to their aortic and mitral valve counterparts but with different location of optimal auscultation. These murmurs can be further differentiated from their left-sided counterparts by an increase in intensity with inspiration.

This patient has an **aortic regurgitation** (AR) murmur. It is a high-pitched, blowing, **diastolic** murmur; the intensity is maximal right after A2 (sound of aortic valve closure) and proceeds in a **decrescendo** pattern for part or all of diastole. Higher overall intensity and longer duration of the murmur correlate with the severity of AR, and A2 may be absent in severe AR.

When AR is due to **aortic root dilation** (eg, in Marfan syndrome) the murmur is best heard at the **right upper sternal border** (classic aortic valve auscultatory location). However, for AR due to **valvular pathology** (eg, bicuspid aortic valve, rheumatic heart disease) the murmur is best heard at the **left third intercostal space**. In either scenario, the murmur is best appreciated at the end of expiration with the patient leaning forward (minimized lung volume with the heart closer to the chest wall enhances left-sided murmurs).

(Choice B) Hypertrophic cardiomyopathy causes left ventricular outflow obstruction and produces a crescendo-decrescendo systolic murmur similar to that of aortic stenosis. The murmurs can be differentiated by maneuvers that increase left ventricular blood volume (eg, squatting); the murmur of hypertrophic cardiomyopathy decreases in intensity with increased left ventricular blood volume (outflow obstruction is reduced), whereas the murmur of aortic stenosis increases in intensity.

(Choice C) Mitral valve prolapse is classically associated with a midsystolic click and a late systolic murmur best heard at the cardiac apex.

(Choice D) Papillary muscle dysfunction can lead to mitral regurgitation, which causes a holosystolic murmur best heard at the cardiac apex.

(Choice E) Tricuspid regurgitation causes a holosystolic murmur that is best heard at the left lower sternal border. The murmur can be differentiated from that of mitral regurgitation by auscultation during inspiration; the murmur of tricuspid regurgitation will increase in intensity with inspiration as right ventricular blood volume is increased.

Educational objective:
Aortic regurgitation (AR) causes a high-pitched, blowing, diastolic murmur with a decrescendo intensity pattern. The murmur of AR due to aortic root dilation is best heard at the right upper sternal border, whereas the murmur of AR due to valvular pathology is best heard at the left third intercostal space.

Pathophysiology	Cardiovascular System	Aortic regurgitation
Subject	System	Topic

Copyright © UWorld. All rights reserved.

A 44-year-old man with a history of intravenous drug use came to the emergency department due to fever and chills. Multiple blood culture sets were positive for *Staphylococcus aureus*, and the patient was diagnosed with infective endocarditis. He was successfully treated with a long course of antibiotics. Six months later, he returns to the clinic for a follow-up evaluation. The patient has no symptoms and reports good exercise tolerance. He is afebrile, blood pressure is 140/62 mm Hg, pulse is 82/min, and respirations are 16/min. Chest auscultation reveals a decrescendo diastolic murmur over the third intercostal space along the left sternal border. Echocardiogram shows severe aortic regurgitation, likely as a sequela to the prior infection. Which of the following changes is most responsible for maintaining cardiac output in the setting of this valvular abnormality?

- A. Concentric left ventricular hypertrophy
- B. Decrease in left ventricular preload
- C. Increase in aortic elasticity
- D. Increase in left ventricular afterload
- E. Increase in left ventricular stroke volume
- F. Sustained increase in heart rate

Submit

A 44-year-old man with a history of intravenous drug use came to the emergency department due to fever and chills. Multiple blood culture sets were positive for *Staphylococcus aureus*, and the patient was diagnosed with infective endocarditis. He was successfully treated with a long course of antibiotics. Six months later, he returns to the clinic for a follow-up evaluation. The patient has no symptoms and reports good exercise tolerance. He is afebrile, blood pressure is 140/62 mm Hg, pulse is 82/min, and respirations are 16/min. Chest auscultation reveals a decrescendo diastolic murmur over the third intercostal space along the left sternal border. Echocardiogram shows severe aortic regurgitation, likely as a sequela to the prior infection. Which of the following changes is most responsible for maintaining cardiac output in the setting of this valvular abnormality?

- A. Concentric left ventricular hypertrophy (22%)
- B. Decrease in left ventricular preload (2%)
- C. Increase in aortic elasticity (1%)
- D. Increase in left ventricular afterload (4%)
- ✓ E. Increase in left ventricular stroke volume (56%)
- F. Sustained increase in heart rate (13%)

Omitted
Correct answer
E

56%
Answered correctly

01 sec
Time Spent

04/23/2020
Last Updated

Explanation

Pathophysiology of chronic aortic regurgitation

A 44-year-old man with a history of intravenous drug use came to the emergency department due to fever and chills. Multiple blood culture sets were positive for *Staphylococcus aureus*, and the patient was diagnosed with infective endocarditis. He was successfully treated with a long course of antibiotics. Six months later, he returns to the clinic for a follow-up evaluation. The patient has no symptoms and reports good exercise tolerance. He is afebrile, blood pressure is 140/62 mm Hg, pulse is 82/min, and respirations are 16/min. Chest auscultation reveals a decrescendo diastolic murmur over the third intercostal space along the left sternal border. Echocardiogram shows severe aortic regurgitation, likely as a sequela to the prior infection. Which of the following changes is most responsible for maintaining cardiac output in the setting of this valvular abnormality?

- A. Concentric left ventricular hypertrophy (22%)
- B. Decrease in left ventricular preload (2%)
- C. Increase in aortic elasticity (1%)
- D. Increase in left ventricular afterload (4%)
- ✓ E. Increase in left ventricular stroke volume (56%)
- F. Sustained increase in heart rate (13%)

Omitted
Correct answer
E

56%
Answered correctly

01 sec
Time Spent

04/23/2020
Last Updated

Explanation

Pathophysiology of chronic aortic regurgitation

Pathophysiology of chronic aortic regurgitation

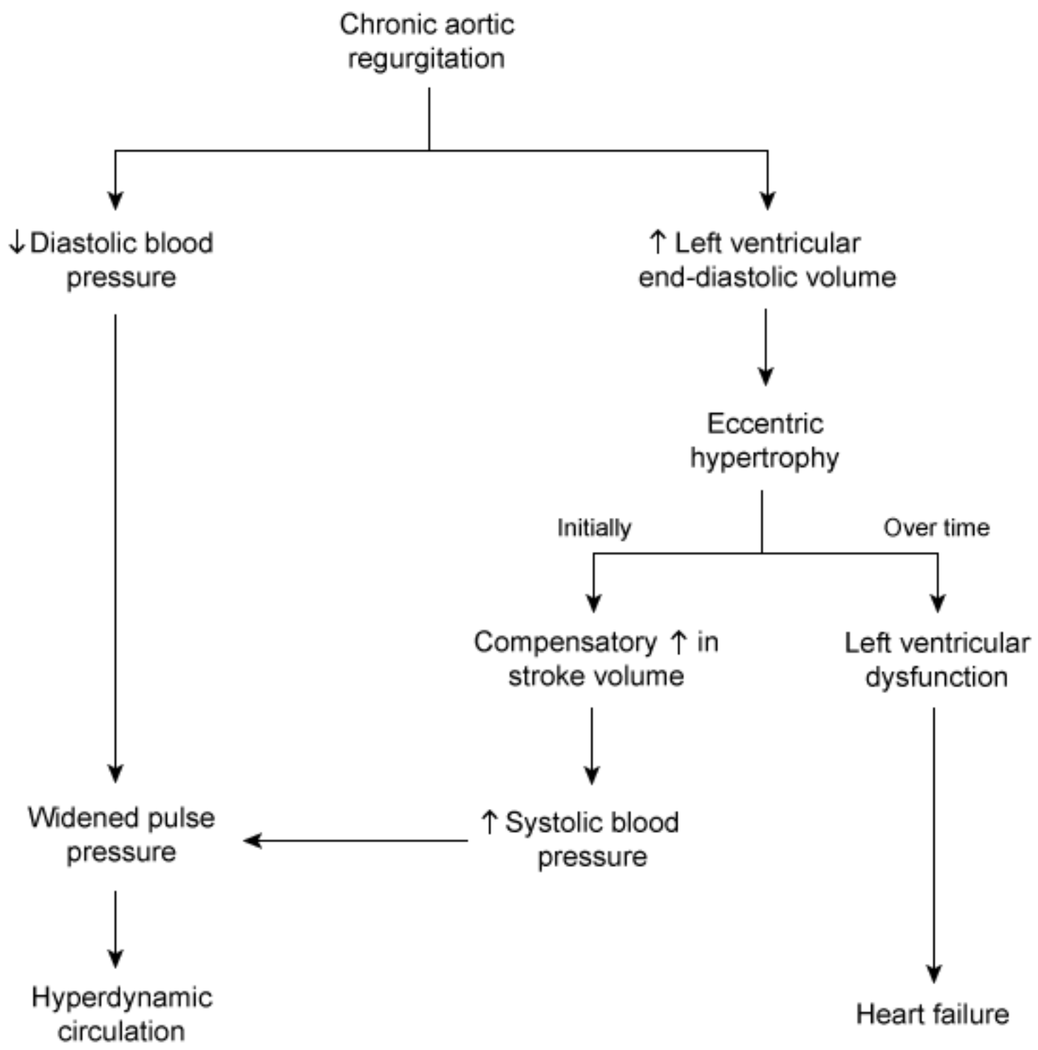

©UWorld

This patient has developed **chronic aortic regurgitation** (AR) as a consequence of infective endocarditis. Incomplete closure of the aortic valve during diastole allows a portion of left ventricular stroke volume to leak back into the left ventricle; in severe AR this regurgitant flow volume may be up to 50% of total forward stroke volume. Left ventricular dilation caused by the increase in left ventricular end-diastolic volume (LVEDV) (**volume overload**) triggers eccentric hypertrophy, which involves ventricular wall lengthening due to the addition of myocardial contractile fibrils organized in series. This compensatory response causes an **increase in stroke volume** that is able to maintain cardiac output, and allows for a relatively long asymptomatic period (eg, several years) in most patients with chronic AR.

However, the compensatory eccentric hypertrophy in chronic AR is overall **maladaptive**. Over time, progressive left ventricular dilation leads to overwhelming wall stress with decreased stroke volume and eventual left ventricular failure.

(Choice A) Concentric hypertrophy occurs due to conditions that create ventricular pressure overload (eg, hypertension, aortic stenosis); it involves ventricular wall thickening due to the addition of myocardial contractile fibrils in parallel. Although some concentric hypertrophy may occur in AR, eccentric hypertrophy due to volume overload is the predominant change.

(Choice B) In AR, left ventricular preload or LVEDV is increased, rather than decreased. This helps the ventricle maintain cardiac output via the Frank-Starling mechanism. Decreased preload would cause a reduction in cardiac output.

(Choice C) Increased aortic elasticity (ie, decreased compliance or increased aortic stiffening) occurs with aging and results in higher systolic blood pressure, widened pulse pressure, and reduced cardiac output.

(Choice D) In chronic AR, there is an effective increase in left ventricular afterload due to the enlarged chamber size (increases wall stress) and high peak systolic pressures. This increases left ventricular work, making it more difficult to maintain cardiac output and eventually leads to heart failure.

(Choice F) Because cardiac output is maintained by an increase in stroke volume, there is typically minimal increase in heart rate in chronic AR. However, in acute AR, eccentric hypertrophy does not have time to develop and the capacity to increase stroke volume is limited. The resulting decrease in cardiac output triggers a reflexive increase in heart rate, but this response is typically insufficient and most patients develop severe cardiogenic shock with pulmonary edema.

Educational objective:

In chronic aortic regurgitation, persistent left ventricular volume overload triggers eccentric hypertrophy, which causes a compensatory increase in

©UWorld

This patient has developed **chronic aortic regurgitation** (AR) as a consequence of infective endocarditis. Incomplete closure of the aortic valve during diastole allows a portion of left ventricular stroke volume to leak back into the left ventricle; in severe AR this regurgitant flow volume may be up to 50% of total forward stroke volume. Left ventricular dilation caused by the increase in left ventricular end-diastolic volume (LVEDV) (**volume overload**) triggers eccentric hypertrophy, which involves ventricular wall lengthening due to the addition of myocardial contractile fibrils organized in series. This compensatory response causes an **increase in stroke volume** that is able to maintain cardiac output, and allows for a relatively long asymptomatic period (eg, several years) in most patients with chronic AR.

However, the compensatory eccentric hypertrophy in chronic AR is overall **maladaptive**. Over time, progressive left ventricular dilation leads to overwhelming wall stress with decreased stroke volume and eventual left ventricular failure.

(Choice A) Concentric hypertrophy occurs due to conditions that create ventricular pressure overload (eg, hypertension, aortic stenosis); it involves ventricular wall thickening due to the addition of myocardial contractile fibrils in parallel. Although some concentric hypertrophy may occur in AR, eccentric hypertrophy due to volume overload is the predominant change.

(Choice B) In AR, left ventricular preload or LVEDV is increased, rather than decreased. This helps the ventricle maintain cardiac output via the Frank-Starling mechanism. Decreased preload would cause a reduction in cardiac output.

(Choice C) Increased aortic elasticity (ie, decreased compliance or increased aortic stiffening) occurs with aging and results in higher systolic blood pressure, widened pulse pressure, and reduced cardiac output.

(Choice D) In chronic AR, there is an effective increase in left ventricular afterload due to the enlarged chamber size (increases wall stress) and high peak systolic pressures. This increases left ventricular work, making it more difficult to maintain cardiac output and eventually leads to heart failure.

(Choice F) Because cardiac output is maintained by an increase in stroke volume, there is typically minimal increase in heart rate in chronic AR. However, in acute AR, eccentric hypertrophy does not have time to develop and the capacity to increase stroke volume is limited. The resulting decrease in cardiac output triggers a reflexive increase in heart rate, but this response is typically insufficient and most patients develop severe cardiogenic shock with pulmonary edema.

Educational objective:

In chronic aortic regurgitation, persistent left ventricular volume overload triggers eccentric hypertrophy, which causes a compensatory increase in

However, the compensatory eccentric hypertrophy in chronic AR is overall **maladaptive**. Over time, progressive left ventricular dilation leads to overwhelming wall stress with decreased stroke volume and eventual left ventricular failure.

(Choice A) Concentric hypertrophy occurs due to conditions that create ventricular pressure overload (eg, hypertension, aortic stenosis); it involves ventricular wall thickening due to the addition of myocardial contractile fibrils in parallel. Although some concentric hypertrophy may occur in AR, eccentric hypertrophy due to volume overload is the predominant change.

(Choice B) In AR, left ventricular preload or LVEDV is increased, rather than decreased. This helps the ventricle maintain cardiac output via the Frank-Starling mechanism. Decreased preload would cause a reduction in cardiac output.

(Choice C) Increased aortic elasticity (ie, decreased compliance or increased aortic stiffening) occurs with aging and results in higher systolic blood pressure, widened pulse pressure, and reduced cardiac output.

(Choice D) In chronic AR, there is an effective increase in left ventricular afterload due to the enlarged chamber size (increases wall stress) and high peak systolic pressures. This increases left ventricular work, making it more difficult to maintain cardiac output and eventually leads to heart failure.

(Choice F) Because cardiac output is maintained by an increase in stroke volume, there is typically minimal increase in heart rate in chronic AR. However, in acute AR, eccentric hypertrophy does not have time to develop and the capacity to increase stroke volume is limited. The resulting decrease in cardiac output triggers a reflexive increase in heart rate, but this response is typically insufficient and most patients develop severe cardiogenic shock with pulmonary edema.

Educational objective:
In chronic aortic regurgitation, persistent left ventricular volume overload triggers eccentric hypertrophy, which causes a compensatory increase in stroke volume to maintain cardiac output. This compensatory mechanism allows for a relatively long asymptomatic period in most patients; however, left ventricular dysfunction eventually occurs, leading to heart failure.

Pathophysiology	Cardiovascular System	Aortic regurgitation
Subject	System	Topic

Copyright © UWorld. All rights reserved.

A 72-year-old man comes to the office due to progressive shortness of breath. Over the past year, the patient has been unable to perform many of his usual outdoor activities, including afternoon walks and working in the yard. During the last several weeks, he has frequently become easily fatigued and short of breath, and at night he needs several pillows to sleep comfortably. He has also had ankle swelling. The patient has had no chest pain, syncope, abdominal pain, or cough. Medical history is significant for hypertension. He is a lifetime nonsmoker. Bibasilar crackles are heard on physical examination. Echocardiography reveals no valvular disease and a nondilated left ventricle with normal wall motion and left ventricular ejection fraction of 55%. Which of the following is most strongly associated with this patient's current condition?

A. Glomerular hyperfiltration

B. Increased left ventricular compliance

C. Increased systemic vascular resistance

D. Left ventricular thrombus formation

E. Right-to-left intracardiac shunting

Submit

A 72-year-old man comes to the office due to progressive shortness of breath. Over the past year, the patient has been unable to perform many of his usual outdoor activities, including afternoon walks and working in the yard. During the last several weeks, he has frequently become easily fatigued and short of breath, and at night he needs several pillows to sleep comfortably. He has also had ankle swelling. The patient has had no chest pain, syncope, abdominal pain, or cough. Medical history is significant for hypertension. He is a lifetime nonsmoker. Bibasilar crackles are heard on physical examination. Echocardiography reveals no valvular disease and a nondilated left ventricle with normal wall motion and left ventricular ejection fraction of 55%. Which of the following is most strongly associated with this patient's current condition?

- A. Glomerular hyperfiltration (12%)
- B. Increased left ventricular compliance (11%)
- ✓ C. Increased systemic vascular resistance (67%)
- D. Left ventricular thrombus formation (3%)
- E. Right-to-left intracardiac shunting (4%)

Omitted
Correct answer
C

67%
Answered correctly

01 sec
Time Spent

03/29/2020
Last Updated

Explanation

Heart failure with preserved ejection fraction due to LV diastolic dysfunction

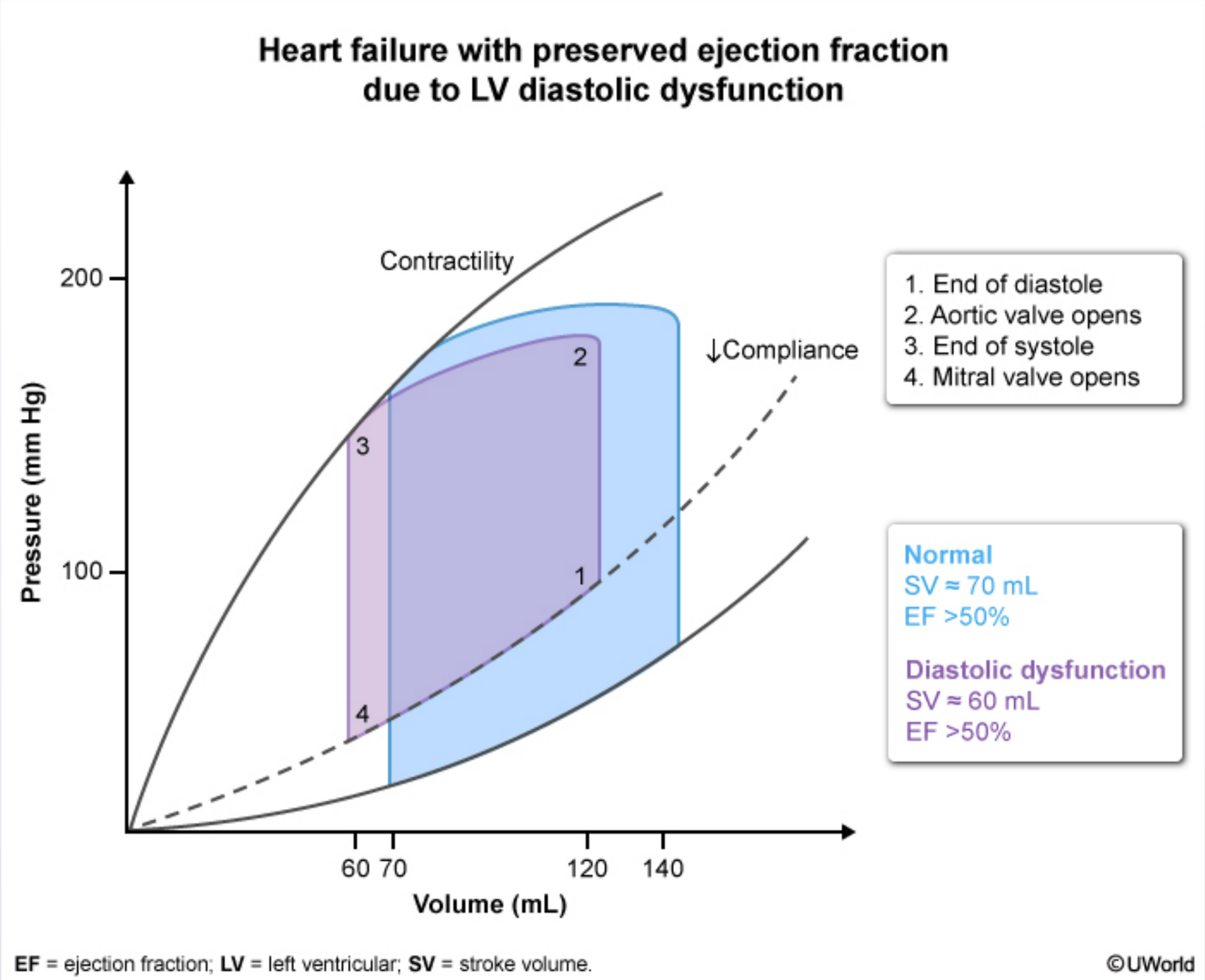

This patient has clinical signs and symptoms of decompensated heart failure (eg, dyspnea, fatigue, orthopnea, lower extremity edema, bibasilar crackles); however, echocardiography shows a preserved left ventricular (LV) ejection fraction (>50%) without chamber dilation. **Heart failure**

This patient has clinical signs and symptoms of decompensated heart failure (eg, dyspnea, fatigue, orthopnea, lower extremity edema, bibasilar crackles); however, echocardiography shows a preserved left ventricular (LV) ejection fraction (>50%) without chamber dilation. **Heart failure with preserved ejection fraction** (HFpEF) develops due to **diastolic dysfunction**, which frequently occurs in the setting of prolonged **systemic hypertension**.

Patients with longstanding hypertension typically have a normal to low cardiac output with **increased systemic vascular resistance**. Over time, increased afterload causes the left ventricle to undergo concentric hypertrophy with the addition of myocardial contractile fibers in parallel to increase contractile strength. The thickened LV walls become stiff and less compliant, leading to impaired diastolic relaxation and **increased LV end-diastolic pressure** (point 1). Over time, the elevated pressure transmits back to the pulmonary veins and capillaries, resulting in pulmonary edema. There is also an eventual decline in LV end-diastolic volume (also indicated at point 1) leading to **reduced cardiac output** and further decompensation (stroke volume decreases despite preserved ejection fraction).

(Choice A) The decreased cardiac output in heart failure leads to reduced renal perfusion pressure and glomerular hypofiltration. To compensate, the renin-angiotensin-aldosterone system is activated, and angiotensin II constricts glomerular efferent arterioles in an effort to increase glomerular filtration rate back to normal.

(Choice B) Diastolic dysfunction involves a decrease in LV compliance. LV compliance may increase with eccentric hypertrophy, as occurs with dilated cardiomyopathy.

(Choice D) LV thrombus typically results from localized stagnation of blood as can occur with an LV aneurysm or in the setting of a severely dilated LV cavity with systolic dysfunction. It is not typically associated with diastolic dysfunction and HFpEF.

(Choice E) Atrial and ventricular septal defects are often asymptomatic but can eventually lead to right-to-left intracardiac shunting (Eisenmenger syndrome), typically characterized by cyanosis and predominantly right-sided heart failure. This patient's bibasilar crackles suggest pulmonary edema consistent with left-sided heart failure.

Educational objective:
Heart failure with preserved ejection fraction is characterized by diastolic dysfunction, which frequently occurs in the setting of prolonged systemic hypertension due to concentric left ventricular hypertrophy. Patients with longstanding hypertension have increased systemic vascular resistance.

References

- Heart failure with normal ejection fraction

end-diastolic pressure (point 1). Over time, the elevated pressure transmits back to the pulmonary veins and capillaries, resulting in pulmonary edema. There is also an eventual decline in LV end-diastolic volume (also indicated at point 1) leading to **reduced cardiac output** and further decompensation (stroke volume decreases despite preserved ejection fraction).

(Choice A) The decreased cardiac output in heart failure leads to reduced renal perfusion pressure and glomerular hypofiltration. To compensate, the renin-angiotensin-aldosterone system is activated, and angiotensin II constricts glomerular efferent arterioles in an effort to increase glomerular filtration rate back to normal.

(Choice B) Diastolic dysfunction involves a decrease in LV compliance. LV compliance may increase with eccentric hypertrophy, as occurs with dilated cardiomyopathy.

(Choice D) LV thrombus typically results from localized stagnation of blood as can occur with an LV aneurysm or in the setting of a severely dilated LV cavity with systolic dysfunction. It is not typically associated with diastolic dysfunction and HFpEF.

(Choice E) Atrial and ventricular septal defects are often asymptomatic but can eventually lead to right-to-left intracardiac shunting (Eisenmenger syndrome), typically characterized by cyanosis and predominantly right-sided heart failure. This patient's bibasilar crackles suggest pulmonary edema consistent with left-sided heart failure.

Educational objective:
Heart failure with preserved ejection fraction is characterized by diastolic dysfunction, which frequently occurs in the setting of prolonged systemic hypertension due to concentric left ventricular hypertrophy. Patients with longstanding hypertension have increased systemic vascular resistance.

References

- Heart failure with normal ejection fraction.
- Management of chronic heart failure in primary care: what evidence do we have for heart failure with preserved systolic function?

Pathophysiology	Cardiovascular System	Diastolic dysfunction
Subject	System	Topic

Copyright © UWorld. All rights reserved.

A 64-year-old man is brought to the emergency department due to severe chest pain, diaphoresis, and shortness of breath. Symptoms began suddenly on awakening and have worsened over the past 2 hours. Blood pressure is 150/90 mm Hg and pulse is 102/min. Physical examination reveals an S4. ECG shows ST-segment depression and T-wave inversion in the lateral leads. Coronary angiography reveals a ruptured atherosclerotic plaque, with a thrombus in the left circumflex artery that causes near-total occlusion. Normal endothelial cells surrounding the lesion have released large amounts of a chemical substance that help decrease thrombus propagation by inhibiting platelet aggregation. Which of the following substances was most likely secreted by these endothelial cells?

- A. Hageman factor
- B. Kallikrein
- C. Prostacyclin
- D. Protein C
- E. Serotonin
- F. Thromboxane A2

Submit

A 64-year-old man is brought to the emergency department due to severe chest pain, diaphoresis, and shortness of breath. Symptoms began suddenly on awakening and have worsened over the past 2 hours. Blood pressure is 150/90 mm Hg and pulse is 102/min. Physical examination reveals an S4. ECG shows ST-segment depression and T-wave inversion in the lateral leads. Coronary angiography reveals a ruptured atherosclerotic plaque, with a thrombus in the left circumflex artery that causes near-total occlusion. Normal endothelial cells surrounding the lesion have released large amounts of a chemical substance that help decrease thrombus propagation by inhibiting platelet aggregation. Which of the following substances was most likely secreted by these endothelial cells?

- A. Hageman factor (5%)
- B. Kallikrein (6%)
- ✓ C. Prostacyclin (50%)
- D. Protein C (17%)
- E. Serotonin (1%)
- F. Thromboxane A2 (17%)

Omitted
Correct answer
C

50%
Answered correctly

02 secs
Time Spent

04/25/2020
Last Updated

Explanation

Platelet plug formation

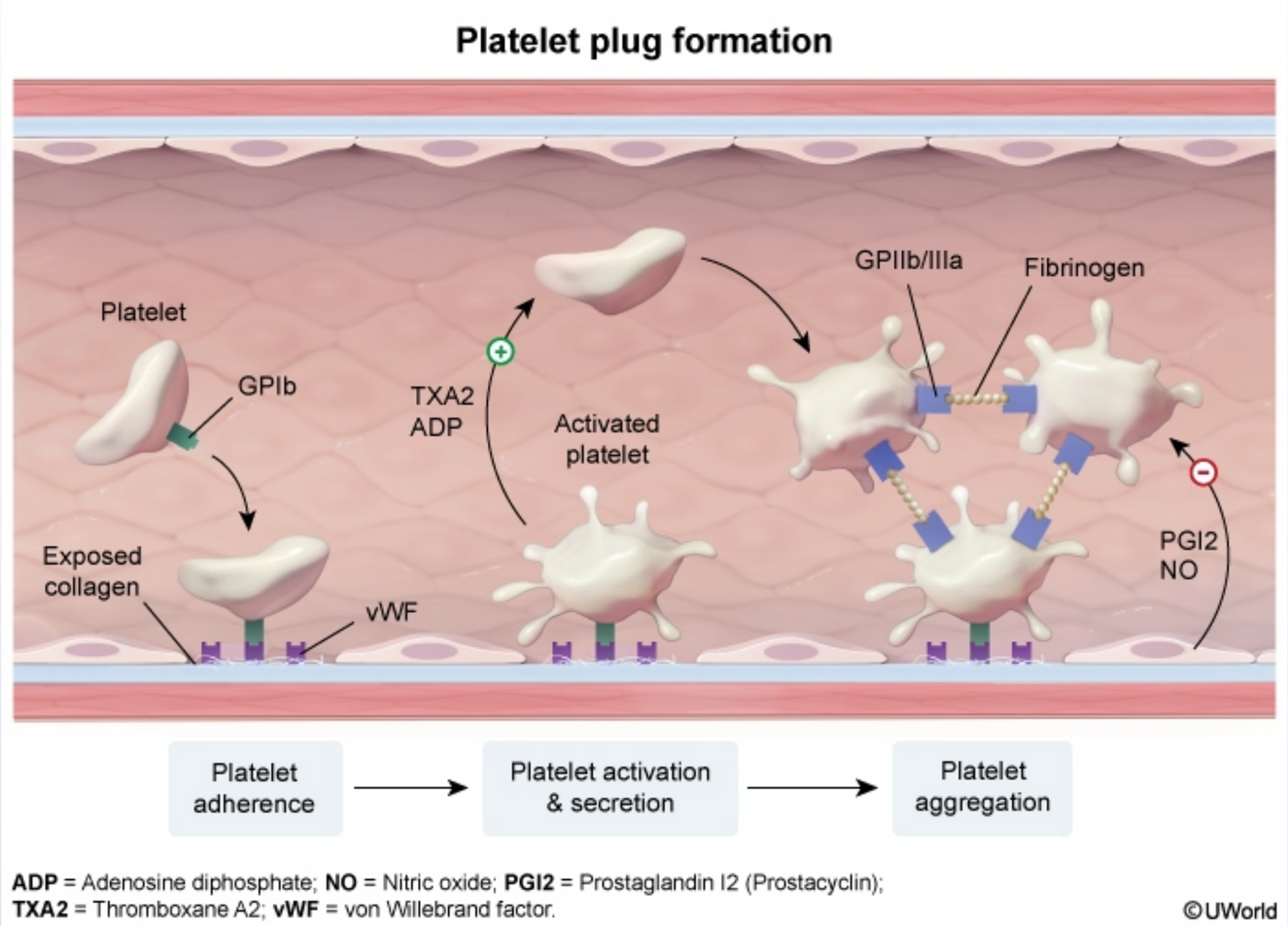

The formation of a **platelet plug** (primary hemostasis) is essential for preventing bleeding after damage to vascular endothelium; it occurs in 3 steps:

- Platelet **adhesion** takes place via von Willebrand factor acting as a connector that binds platelets to underlying collagen
- Platelets become **activated** and secrete multiple substances, including adenosine diphosphate, ionized calcium, and fibrinogen, from their

The formation of a **platelet plug** (primary hemostasis) is essential for preventing bleeding after damage to vascular endothelium; it occurs in 3 steps:

- Platelet **adhesion** takes place via von Willebrand factor acting as a connector that binds platelets to underlying collagen
- Platelets become **activated** and secrete multiple substances, including adenosine diphosphate, ionized calcium, and fibrinogen, from their alpha and delta (dense) granules.
- Thromboxane A2 **(Choice F)**, a prostaglandin, is released and acts as a vasoconstrictor and potent stimulator of platelet **aggregation**. Adenosine diphosphate also stimulates platelet aggregation.

Balance is required as excessive platelet plug formation can lead to a pathologic thrombus that restricts blood flow (eg, myocardial infarction). To oppose the functions of thromboxane A2, the endothelium secretes **prostacyclin** (prostaglandin I2), which is derived from arachidonic acid and synthesized from prostaglandin H2 by prostacyclin synthase. Once secreted, prostacyclin acts locally to **inhibit platelet aggregation** and adhesion to the vascular endothelium and to cause **vasodilation**. Nitric oxide aids in these functions as well. Atherosclerosis can impair the ability of endothelial cells to synthesize prostacyclin and nitric oxide, creating localized predisposition to excessive platelet thrombus formation.

A synthetic prostacyclin, epoprostenol, is used in the treatment of pulmonary hypertension, peripheral vascular disease, and Raynaud syndrome.

(Choice A) Hageman factor (factor XII) is synthesized by the liver and is activated by exposed collagen following damage to endothelial cells. It participates in secondary hemostasis by activating the intrinsic clotting pathway; it also activates fibrinolysis.

(Choice B) Kallikrein converts kininogen into bradykinin. It also may play a role in triggering the fibrinolytic pathway, but it does not inhibit platelet aggregation.

(Choice D) Protein C is a vitamin K–dependent factor synthesized by the liver. It regulates the coagulation cascade by inactivating factors Va and VIIIa.

(Choice E) Serotonin has a wide range of functions, including mediation of mood (in the central nervous system) and gastrointestinal motility. It is also released from the delta granules of activated platelets and facilitates localized vasoconstriction.

Educational objective:
Prostacyclin (prostaglandin I2) is synthesized from prostaglandin H2 by prostacyclin synthase in vascular endothelial cells. Once secreted, it inhibits platelet aggregation and causes vasodilation to oppose the functions of thromboxane A2 and help maintain vascular homeostasis.

Balance is required as excessive platelet plug formation can lead to a pathologic thrombus that restricts blood flow (eg, myocardial infarction). To oppose the functions of thromboxane A2, the endothelium secretes **prostacyclin** (prostaglandin I2), which is derived from arachidonic acid and synthesized from prostaglandin H2 by prostacyclin synthase. Once secreted, prostacyclin acts locally to **inhibit platelet aggregation** and adhesion to the vascular endothelium and to cause **vasodilation**. Nitric oxide aids in these functions as well. Atherosclerosis can impair the ability of endothelial cells to synthesize prostacyclin and nitric oxide, creating localized predisposition to excessive platelet thrombus formation.

A synthetic prostacyclin, epoprostenol, is used in the treatment of pulmonary hypertension, peripheral vascular disease, and Raynaud syndrome.

(Choice A) Hageman factor (factor XII) is synthesized by the liver and is activated by exposed collagen following damage to endothelial cells. It participates in secondary hemostasis by activating the intrinsic clotting pathway; it also activates fibrinolysis.

(Choice B) Kallikrein converts kininogen into bradykinin. It also may play a role in triggering the fibrinolytic pathway, but it does not inhibit platelet aggregation.

(Choice D) Protein C is a vitamin K–dependent factor synthesized by the liver. It regulates the coagulation cascade by inactivating factors Va and VIIIa.

(Choice E) Serotonin has a wide range of functions, including mediation of mood (in the central nervous system) and gastrointestinal motility. It is also released from the delta granules of activated platelets and facilitates localized vasoconstriction.

Educational objective:
Prostacyclin (prostaglandin I2) is synthesized from prostaglandin H2 by prostacyclin synthase in vascular endothelial cells. Once secreted, it inhibits platelet aggregation and causes vasodilation to oppose the functions of thromboxane A2 and help maintain vascular homeostasis.

References

- Continuing education course #2: current understanding of hemostasis.

Pathophysiology	Cardiovascular System	Prostacyclins
Subject	System	Topic

Copyright © UWorld. All rights reserved.

Balance is required as excessive platelet plug formation can lead to a pathologic thrombus that restricts blood flow (eg, myocardial infarction). To

Exhibit Display

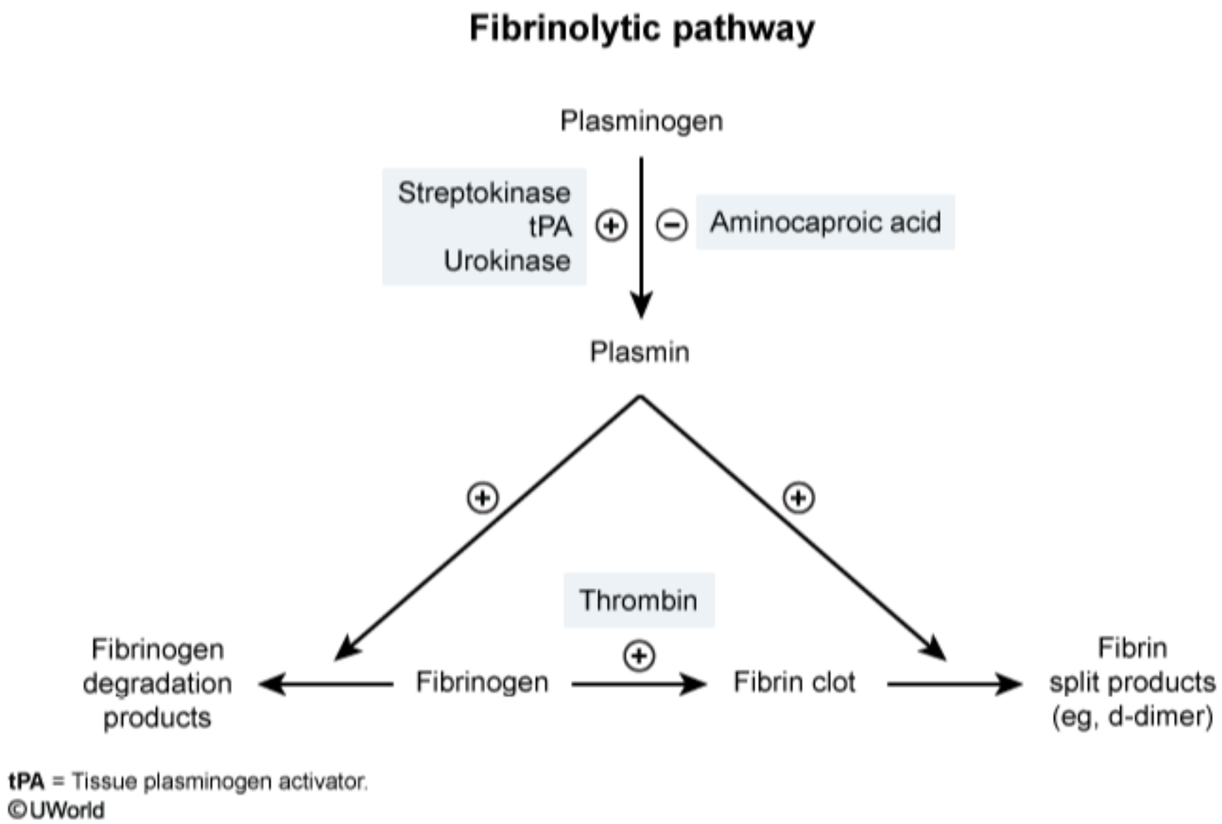

Zoom In | Zoom Out | Reset | Add To New Card | Existing Card

The public health department of a developing country performs an epidemiologic study to assess the nationwide incidence of upper respiratory infections among children. The data show a high rate of childhood bacterial pharyngitis. Current practice guidelines indicate that a rapid test should be performed in children to identify the presence of bacterial antigens. If this test is negative, a throat culture, the gold standard for definitive diagnosis, is then performed. To offset cost and avoid losing patients to follow-up, the department is considering recommending the empiric use of penicillin for the treatment of suspected bacterial pharyngitis. Which of the following would be expected to decrease after long-term implementation of this guideline?

A. Deaths associated with diarrheal illness

B. Diagnoses of serum sickness-like reactions

C. Incidence of nephritic syndrome

D. Need for cardiac surgery

E. Use of broad-spectrum antibiotics

Submit

The public health department of a developing country performs an epidemiologic study to assess the nationwide incidence of upper respiratory infections among children. The data show a high rate of childhood bacterial pharyngitis. Current practice guidelines indicate that a rapid test should be performed in children to identify the presence of bacterial antigens. If this test is negative, a throat culture, the gold standard for definitive diagnosis, is then performed. To offset cost and avoid losing patients to follow-up, the department is considering recommending the empiric use of penicillin for the treatment of suspected bacterial pharyngitis. Which of the following would be expected to decrease after long-term implementation of this guideline?

- A. Deaths associated with diarrheal illness (2%)
- B. Diagnoses of serum sickness-like reactions (2%)
- C. Incidence of nephritic syndrome (30%)
- ✓ D. Need for cardiac surgery (53%)
- E. Use of broad-spectrum antibiotics (10%)

Omitted
Correct answer
D

53%
Answered correctly

02 secs
Time Spent

05/30/2020
Last Updated

Explanation

Acute rheumatic fever	
Epidemiology	• Endemic in developing countries
	• Occurs 2-4 weeks after acute group A streptococcal pharyngitis

Acute rheumatic fever	
Epidemiology	• Endemic in developing countries
Pathogenesis	• Occurs 2-4 weeks after acute group A streptococcal pharyngitis • Molecular mimicry: Anti-streptococcal antibodies attack cardiac & neuronal antigens

Clinical features	• Acute/subacute
	  ◦ Migratory arthritis
	  ◦ Pancarditis (mitral regurgitation)
	  ◦ Sydenham chorea
	• Chronic
	  ◦ Mitral stenosis

Prevention	• Prompt treatment of streptococcal pharyngitis with penicillin

Early **penicillin** treatment of **group A streptococcal pharyngitis** is important for the **prevention of acute rheumatic fever** (ARF), a major cause of cardiovascular death in many developing nations. ARF primarily affects the heart and central nervous system because host antibodies produced in response to streptococcal antigens cross-react with host antigens in these organs. Chronic cardiac inflammation can progress to rheumatic heart disease, specifically valvular disease. The **mitral valve** is the most commonly affected and gradually thickens, fibroses, and calcifies, eventually requiring valvotomy or more invasive surgical intervention.

Empiric therapy for a condition must be considered in the context of the host characteristics, pre-test probability of the disease, benefits/risks of waiting for a definitive diagnosis, and cost of therapy versus its potential complications. If all cases of acute streptococcal pharyngitis were treated empirically, the incidence of rheumatic heart disease and associated cardiac procedures would likely decrease.

(Choice A) Antibiotic use can promote diarrhea by altering the gut microbial milieu. This alteration can lead to overgrowth of *Clostridium difficile*, a gram-positive bacterium that can cause profuse, watery diarrhea and life-threatening fulminant colitis. Therefore, increasing antibiotic use would likely result in increased diarrheal illness and potential complications.

(Choice B) Serum sickness-like reactions are associated with certain infections (eg, hepatitis B) and antibiotics (eg, penicillin). The development of circulating drug-specific immune complexes may cause fever, rash, and arthritis. If penicillin was used more frequently, serum sickness-like

Prevention	• Prompt treatment of streptococcal pharyngitis with penicillin

Early **penicillin** treatment of **group A streptococcal pharyngitis** is important for the **prevention of acute rheumatic fever** (ARF), a major cause of cardiovascular death in many developing nations. ARF primarily affects the heart and central nervous system because host antibodies produced in response to streptococcal antigens cross-react with host antigens in these organs. Chronic cardiac inflammation can progress to rheumatic heart disease, specifically valvular disease. The **mitral valve** is the most commonly affected and gradually thickens, fibroses, and calcifies, eventually requiring valvotomy or more invasive surgical intervention.

Empiric therapy for a condition must be considered in the context of the host characteristics, pre-test probability of the disease, benefits/risks of waiting for a definitive diagnosis, and cost of therapy versus its potential complications. If all cases of acute streptococcal pharyngitis were treated empirically, the incidence of rheumatic heart disease and associated cardiac procedures would likely decrease.

(Choice A) Antibiotic use can promote diarrhea by altering the gut microbial milieu. This alteration can lead to overgrowth of *Clostridium difficile*, a gram-positive bacterium that can cause profuse, watery diarrhea and life-threatening fulminant colitis. Therefore, increasing antibiotic use would likely result in increased diarrheal illness and potential complications.

(Choice B) Serum sickness-like reactions are associated with certain infections (eg, hepatitis B) and antibiotics (eg, penicillin). The development of circulating drug-specific immune complexes may cause fever, rash, and arthritis. If penicillin was used more frequently, serum sickness-like reactions would potentially increase, not decrease.

(Choice C) Post-streptococcal glomerulonephritis (PSGN) is the most common cause of nephritic syndrome in children worldwide. It is caused by deposition of immune complexes in glomeruli following pharyngitis or skin infections with group A *Streptococcus*. Although early antibiotics are effective in preventing ARF, they have not been shown to reduce the risk of PSGN.

(Choice E) Empiric use of potentially unnecessary antibiotics may cause an increase in antibiotic resistance, thereby increasing the need for broad-spectrum antibiotics. For example, methicillin-resistant *Staphylococcus aureus* (MRSA) evolved from methicillin-sensitive *S aureus* via alteration of the protein binding site for beta-lactam antibiotics. As a result, broad-spectrum antibiotics (eg, vancomycin, daptomycin) are required for MRSA infections.

Educational objective:
Acute rheumatic fever is a complication of untreated group A streptococcal pharyngitis. Rheumatic heart disease is the most common cause of acquired valvular heart disease and cardiovascular death in developing countries. The incidence of acute rheumatic fever and rheumatic heart

(Choice B) Serum sickness-like reactions are associated with certain infections (eg, hepatitis B) and antibiotics (eg, penicillin). The development of circulating drug-specific immune complexes may cause fever, rash, and arthritis. If penicillin was used more frequently, serum sickness-like reactions would potentially increase, not decrease.

(Choice C) Post-streptococcal glomerulonephritis (PSGN) is the most common cause of nephritic syndrome in children worldwide. It is caused by deposition of immune complexes in glomeruli following pharyngitis or skin infections with group A *Streptococcus*. Although early antibiotics are effective in preventing ARF, they have not been shown to reduce the risk of PSGN.

(Choice E) Empiric use of potentially unnecessary antibiotics may cause an increase in antibiotic resistance, thereby increasing the need for broad-spectrum antibiotics. For example, methicillin-resistant *Staphylococcus aureus* (MRSA) evolved from methicillin-sensitive *S aureus* via alteration of the protein binding site for beta-lactam antibiotics. As a result, broad-spectrum antibiotics (eg, vancomycin, daptomycin) are required for MRSA infections.

Educational objective:
Acute rheumatic fever is a complication of untreated group A streptococcal pharyngitis. Rheumatic heart disease is the most common cause of acquired valvular heart disease and cardiovascular death in developing countries. The incidence of acute rheumatic fever and rheumatic heart disease has been reduced in industrialized nations with prompt treatment of streptococcal pharyngitis with penicillin.

References

- Primary prevention of acute rheumatic fever and rheumatic heart disease with penicillin in South African children with pharyngitis: a cost-effectiveness analysis.
- Clinical practice guideline for the diagnosis and management of group A streptococcal pharyngitis: 2012 Update by the Infectious Diseases Society of America.
- Diagnostic criteria of acute rheumatic fever.

Pathophysiology	Cardiovascular System	Rheumatic fever
Subject	System	Topic

Copyright © UWorld. All rights reserved.

A 35-year-old man comes to the office with progressive fatigue, dyspnea on exertion, and lower extremity edema over the last 2 weeks. Preceding these symptoms, he had an episode of fever, runny nose, and myalgias that resolved after several days. The patient has no other medical history, takes no medications, and has no significant family history. He occasionally drinks alcohol and does not use tobacco. Blood pressure is 112/74 mm Hg, and pulse is 98/min and regular. Physical examination reveals jugular venous distension, bibasilar crackles on lung auscultation, and 2+ pitting edema involving the lower extremities. Which of the following echocardiographic findings is most likely to be seen in this patient?

- A. Concentric left ventricle thickening with abnormal diastolic relaxation
- B. Dilated ventricles with abnormal systolic ventricular function
- C. High systolic pressure gradient across the aortic valve
- D. Regional wall motion abnormality
- E. Systolic anterior motion of the mitral valve

Submit

A 35-year-old man comes to the office with progressive fatigue, dyspnea on exertion, and lower extremity edema over the last 2 weeks. Preceding these symptoms, he had an episode of fever, runny nose, and myalgias that resolved after several days. The patient has no other medical history, takes no medications, and has no significant family history. He occasionally drinks alcohol and does not use tobacco. Blood pressure is 112/74 mm Hg, and pulse is 98/min and regular. Physical examination reveals jugular venous distension, bibasilar crackles on lung auscultation, and 2+ pitting edema involving the lower extremities. Which of the following echocardiographic findings is most likely to be seen in this patient?

- A. Concentric left ventricle thickening with abnormal diastolic relaxation (8%)
- ✓ B. Dilated ventricles with abnormal systolic ventricular function (58%)
- C. High systolic pressure gradient across the aortic valve (4%)
- D. Regional wall motion abnormality (7%)
- E. Systolic anterior motion of the mitral valve (20%)

Omitted
Correct answer
B

58%
Answered correctly

02 secs
Time Spent

05/01/2020
Last Updated

Explanation

Causes of nonvalvular heart failure

	Ventricular wall thickness	Ventricular cavity size	Contractile function	Diastolic function
Ischemic heart disease	↓ or normal	↑	↓	↓ or normal

Explanation

Causes of nonvalvular heart failure				
	Ventricular wall thickness	Ventricular cavity size	Contractile function	Diastolic function
Ischemic heart disease	↓ or normal	↑	↓	↓ or normal
Dilated cardiomyopathy*				
Hypertensive heart disease	↑	↓	normal	↓
Hypertrophic cardiomyopathy*	↑ septal thickening	↓	normal	↓
Restrictive cardiomyopathy*	normal (but stiff)	↓ or normal	normal	↓

*Cardiomyopathies are characterized by primary myocardial dysfunction (eg, viral myocarditis, genetic disorder, infiltrative disease). Myocardial disease caused by secondary factors (eg, hypertension, coronary artery disease, valvular dysfunction) is not classified as a cardiomyopathy.

This patient's presentation with dyspnea, lower extremity edema, jugular venous distension, and pulmonary crackles is consistent with **decompensated heart failure**. In a young patient who develops heart failure following a symptomatic viral prodrome (eg, fever, sinus congestion, myalgias), **dilated cardiomyopathy** (DCM) due to **viral myocarditis** should be suspected. A number of viruses have been implicated in causing DCM including coxsackievirus, adenovirus, and influenza virus. It is believed that an inadequate immune response to the viral infection allows virus to infect and persist inside cardiomyocytes, resulting in damage due to a direct cytotoxic effect or a destructive autoimmune reaction.

Depletion of cardiomyocytes with subsequent fibrosis causes weakened myocardial contractility (**systolic dysfunction**), volume overload, and ventricular dilation (**eccentric hypertrophy**) as surviving myocytes respond to increased wall stress. Other causes of DCM include genetic disease, pregnancy, infiltrative disease (eg, late manifestation of amyloidosis or hemochromatosis), and drugs/toxins (eg, anthracyclines, chronic alcohol abuse).

(Choice A) Concentric left ventricular (LV) hypertrophy with thickened walls and abnormal diastolic relaxation is characteristic of hypertensive heart disease due to long-standing uncontrolled hypertension. Initially, the LV cavity is reduced in size and there is normal systolic function; however, over time, high afterload pressures can cause progressive systolic dysfunction, LV cavity enlargement, and heart failure.

caused by secondary factors (eg, hypertension, coronary artery disease, valvular dysfunction) is not classified as a cardiomyopathy.

This patient's presentation with dyspnea, lower extremity edema, jugular venous distension, and pulmonary crackles is consistent with **decompensated heart failure**. In a young patient who develops heart failure following a symptomatic viral prodrome (eg, fever, sinus congestion, myalgias), **dilated cardiomyopathy** (DCM) due to **viral myocarditis** should be suspected. A number of viruses have been implicated in causing DCM including coxsackievirus, adenovirus, and influenza virus. It is believed that an inadequate immune response to the viral infection allows virus to infect and persist inside cardiomyocytes, resulting in damage due to a direct cytotoxic effect or a destructive autoimmune reaction.

Depletion of cardiomyocytes with subsequent fibrosis causes weakened myocardial contractility (**systolic dysfunction**), volume overload, and ventricular dilation (**eccentric hypertrophy**) as surviving myocytes respond to increased wall stress. Other causes of DCM include genetic disease, pregnancy, infiltrative disease (eg, late manifestation of amyloidosis or hemochromatosis), and drugs/toxins (eg, anthracyclines, chronic alcohol abuse).

(Choice A) Concentric left ventricular (LV) hypertrophy with thickened walls and abnormal diastolic relaxation is characteristic of hypertensive heart disease due to long-standing uncontrolled hypertension. Initially, the LV cavity is reduced in size and there is normal systolic function; however, over time, high afterload pressures can cause progressive systolic dysfunction, LV cavity enlargement, and heart failure.

(Choice C) High systolic pressure gradient across the aortic valve is present in aortic stenosis; concentric LV hypertrophy can occur due to LV pressure overload. Aortic stenosis can develop in relatively young patients due to calcification of a bicuspid aortic valve; however, a crescendo-decrescendo systolic murmur is expected on examination.

(Choice D) Regional wall motion abnormality is suggestive of ischemic heart disease (eg, myocardial infarction). Contractile function is impaired in the damaged portion of myocardium, resulting in systolic dysfunction with LV volume overload, eccentric hypertrophy, and LV cavity enlargement. Ischemic heart disease is unlikely in this young patient without significant risk factors for cardiovascular disease.

(Choice E) In patients with hypertrophic cardiomyopathy, systolic anterior motion of the mitral valve may worsen LV outflow tract obstruction. Clinical features of hypertrophic cardiomyopathy include exercise-induced syncope (due to outflow obstruction) and sudden cardiac death (due to ventricular arrhythmia) in young athletes.

Educational objective:
Dilated cardiomyopathy results from direct damage to cardiomyocytes leading to myocardial contractile dysfunction (systolic dysfunction), volume overload, and ventricular dilation. Viral myocarditis is a common cause of dilated cardiomyopathy and should be suspected in young patients who

caused by secondary factors (eg, hypertension, coronary artery disease, valvular dysfunction) is not classified as a cardiomyopathy.

Exhibit Display

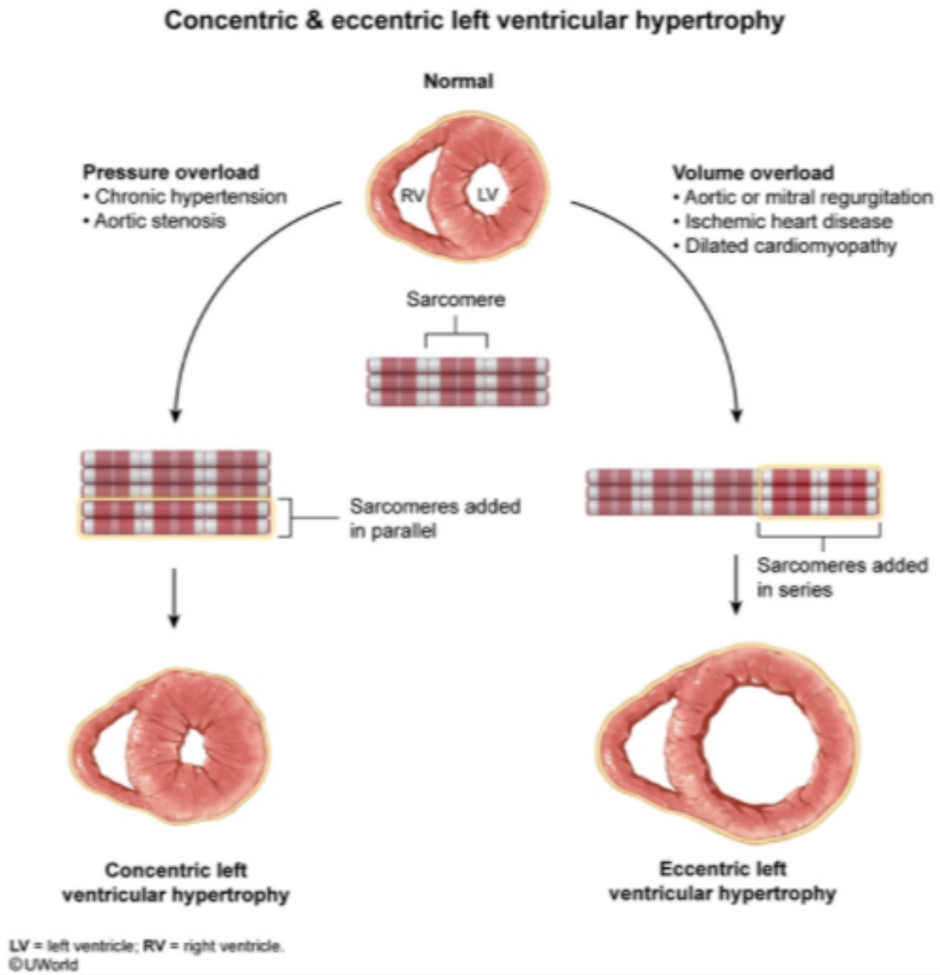

Zoom In | Zoom Out | Reset | Add To New Card | Existing Card

overload, and ventricular dilation. Viral myocarditis is a common cause of dilated cardiomyopathy and should be suspected in young patients who

caused by secondary factors (eg, hypertension, coronary artery disease, valvular dysfunction) is not classified as a cardiomyopathy.

Exhibit Display

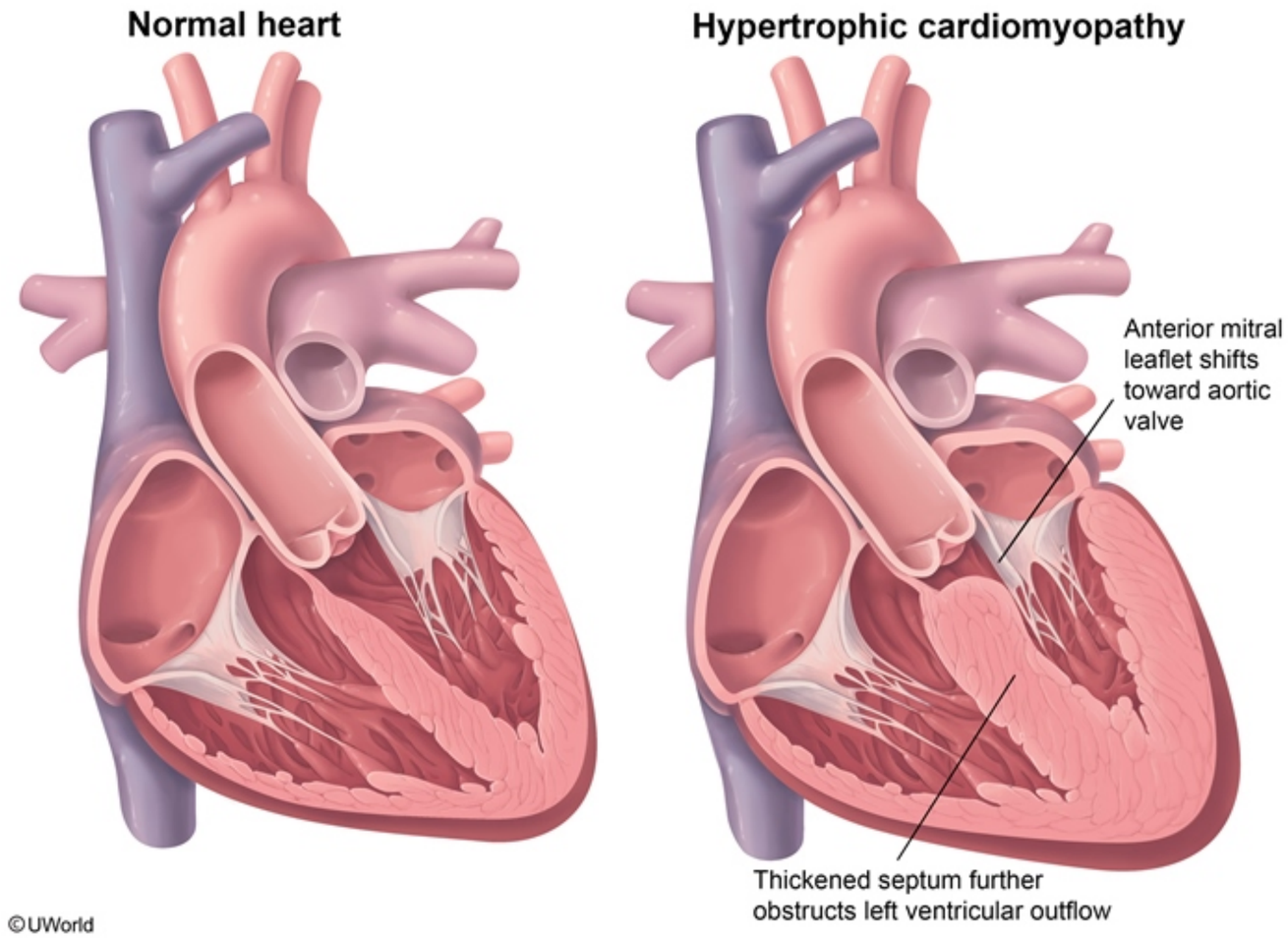

Zoom In | Zoom Out | Reset | Add To New Card | Existing Card

overload, and ventricular dilation. Viral myocarditis is a common cause of dilated cardiomyopathy and should be suspected in young patients who

(Choice A) Concentric left ventricular (LV) hypertrophy with thickened walls and abnormal diastolic relaxation is characteristic of hypertensive heart disease due to long-standing uncontrolled hypertension. Initially, the LV cavity is reduced in size and there is normal systolic function; however, over time, high afterload pressures can cause progressive systolic dysfunction, LV cavity enlargement, and heart failure.

(Choice C) High systolic pressure gradient across the aortic valve is present in aortic stenosis; concentric LV hypertrophy can occur due to LV pressure overload. Aortic stenosis can develop in relatively young patients due to calcification of a bicuspid aortic valve; however, a crescendo-decrescendo systolic murmur is expected on examination.

(Choice D) Regional wall motion abnormality is suggestive of ischemic heart disease (eg, myocardial infarction). Contractile function is impaired in the damaged portion of myocardium, resulting in systolic dysfunction with LV volume overload, eccentric hypertrophy, and LV cavity enlargement. Ischemic heart disease is unlikely in this young patient without significant risk factors for cardiovascular disease.

(Choice E) In patients with hypertrophic cardiomyopathy, systolic anterior motion of the mitral valve may worsen LV outflow tract obstruction. Clinical features of hypertrophic cardiomyopathy include exercise-induced syncope (due to outflow obstruction) and sudden cardiac death (due to ventricular arrhythmia) in young athletes.

Educational objective:
Dilated cardiomyopathy results from direct damage to cardiomyocytes leading to myocardial contractile dysfunction (systolic dysfunction), volume overload, and ventricular dilation. Viral myocarditis is a common cause of dilated cardiomyopathy and should be suspected in young patients who develop heart failure following a symptomatic viral prodrome.

References

- Cardiomyopathies: Evolution of pathogenesis concepts and potential for new therapies.
- Viral myocarditis—diagnosis, treatment options, and current controversies.

Pathophysiology	Cardiovascular System	Dilated cardiomyopathy
Subject	System	Topic

Copyright © UWorld. All rights reserved.

A 42-year-old man comes to the emergency department due to acute-onset shortness of breath. He has no medical conditions and does not use alcohol, tobacco, or illicit drugs. The patient works as a box handler at a warehouse and has excellent exercise tolerance. Family history is insignificant. Blood pressure is 98/60 mm Hg and pulse is 112/min and regular. A short systolic murmur is heard at the apex. Bilateral crackles are present on lung auscultation. Bedside echocardiography reveals a flail posterior mitral leaflet due to chordal rupture and severe mitral regurgitation. Which of the following best reflects this patient's left ventricular hemodynamics compared to the normal heart?

- A. Afterload decrease, preload decrease, ejection fraction decrease
- B. Afterload decrease, preload increase, ejection fraction increase
- C. Afterload increase, preload decrease, ejection fraction decrease
- D. Afterload increase, preload decrease, ejection fraction increase
- E. Afterload increase, preload increase, ejection fraction increase

Submit

A 42-year-old man comes to the emergency department due to acute-onset shortness of breath. He has no medical conditions and does not use alcohol, tobacco, or illicit drugs. The patient works as a box handler at a warehouse and has excellent exercise tolerance. Family history is insignificant. Blood pressure is 98/60 mm Hg and pulse is 112/min and regular. A short systolic murmur is heard at the apex. Bilateral crackles are present on lung auscultation. Bedside echocardiography reveals a flail posterior mitral leaflet due to chordal rupture and severe mitral regurgitation. Which of the following best reflects this patient's left ventricular hemodynamics compared to the normal heart?

- A. Afterload decrease, preload decrease, ejection fraction decrease (22%)
- ✓ B. Afterload decrease, preload increase, ejection fraction increase (44%)
- C. Afterload increase, preload decrease, ejection fraction decrease (19%)
- D. Afterload increase, preload decrease, ejection fraction increase (2%)
- E. Afterload increase, preload increase, ejection fraction increase (11%)

Omitted
Correct answer
B

44%
Answered correctly

03 secs
Time Spent

03/17/2020
Last Updated

Explanation

Hemodynamic changes in mitral regurgitation			
	Acute MR	Compensated chronic MR	Decompensated chronic MR
Preload	↑↑	↑	↑

Hemodynamic changes in mitral regurgitation			
	Acute MR	Compensated chronic MR	Decompensated chronic MR
Preload	↑↑	↑	↑
Afterload	↓	No change	↑
Contractile function	No change	No change	↓
Ejection fraction	↑↑	↑	↓
Forward stroke volume	↓	No change	↓

MR = mitral regurgitation.

This patient has **acute mitral regurgitation** (MR) due to a spontaneous chordae tendineae rupture. In acute MR, the left atrium (LA) is of normal size and compliance and is suddenly exposed to a large volume of regurgitant blood from the left ventricle (LV). This leads to very high LA pressures and subsequent **pulmonary edema**.

In addition, because the LV must accommodate the regurgitant blood volume along with normal pulmonary venous return, there is **increased LV end-diastolic volume** (preload). Meanwhile, the incompetent mitral valve forms a low-resistance regurgitant pathway for blood to flow into the LA during ventricular systole, **decreasing LV afterload**. The decreased afterload leads to **increased LV ejection fraction** (via increased stroke volume); however, much of the stroke volume is lost to regurgitation into the LA, resulting in overall decreased forward stroke volume and reduced cardiac output (manifesting as **hypotension** and cardiogenic shock).

In chronic MR, compensatory LA enlargement allows the LA to receive the regurgitant volume at lower filling pressures, preventing pulmonary edema from developing. Chronic volume overload also causes the LV to undergo substantial enlargement due to eccentric hypertrophy. Early on, the larger ventricular volume helps maintain forward stroke volume even in the setting of substantial regurgitant flow. However, with prolonged hemodynamic overload, progressive eccentric remodeling of the LV becomes maladaptive, resulting in an overwhelming increase in wall stress with eventual contractile dysfunction. The impaired contractility culminates in decompensation of chronic MR with reduced forward stroke volume

MR = mitral regurgitation.

This patient has **acute mitral regurgitation** (MR) due to a spontaneous chordae tendineae rupture. In acute MR, the left atrium (LA) is of normal size and compliance and is suddenly exposed to a large volume of regurgitant blood from the left ventricle (LV). This leads to very high LA pressures and subsequent **pulmonary edema**.

In addition, because the LV must accommodate the regurgitant blood volume along with normal pulmonary venous return, there is **increased LV end-diastolic volume** (preload). Meanwhile, the incompetent mitral valve forms a low-resistance regurgitant pathway for blood to flow into the LA during ventricular systole, **decreasing LV afterload**. The decreased afterload leads to **increased LV ejection fraction** (via increased stroke volume); however, much of the stroke volume is lost to regurgitation into the LA, resulting in overall decreased forward stroke volume and reduced cardiac output (manifesting as **hypotension** and cardiogenic shock).

In chronic MR, compensatory LA enlargement allows the LA to receive the regurgitant volume at lower filling pressures, preventing pulmonary edema from developing. Chronic volume overload also causes the LV to undergo substantial enlargement due to eccentric hypertrophy. Early on, the larger ventricular volume helps maintain forward stroke volume even in the setting of substantial regurgitant flow. However, with prolonged hemodynamic overload, progressive eccentric remodeling of the LV becomes maladaptive, resulting in an overwhelming increase in wall stress with eventual contractile dysfunction. The impaired contractility culminates in decompensation of chronic MR with reduced forward stroke volume (decreased cardiac output) and increased left-sided filling pressures (pulmonary edema).

Educational objective:
Regurgitant flow into the left atrium in acute mitral regurgitation leads to increased left atrial pressure and increased left ventricular end-diastolic volume (preload). The low-resistance regurgitant pathway also decreases left ventricular afterload with a resulting increase in ejection fraction but overall decrease in forward stroke volume. Increased left atrial pressure and decreased cardiac output result in pulmonary edema and severe hypotension, respectively.

References

- Left ventricular response to mitral regurgitation: implications for management.

Pathophysiology	Cardiovascular System	Mitral regurgitation
Subject	System	Topic

MR = mitral regurgitation.

Exhibit Display

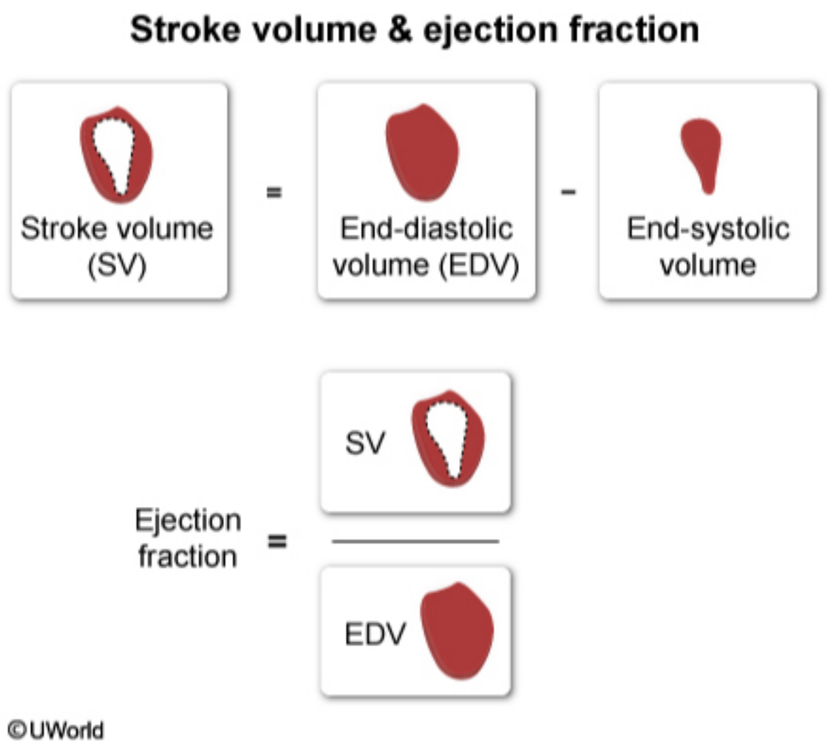

Zoom In | Zoom Out | Reset | Add To New Card | Existing Card

MR = mitral regurgitation.

Exhibit Display

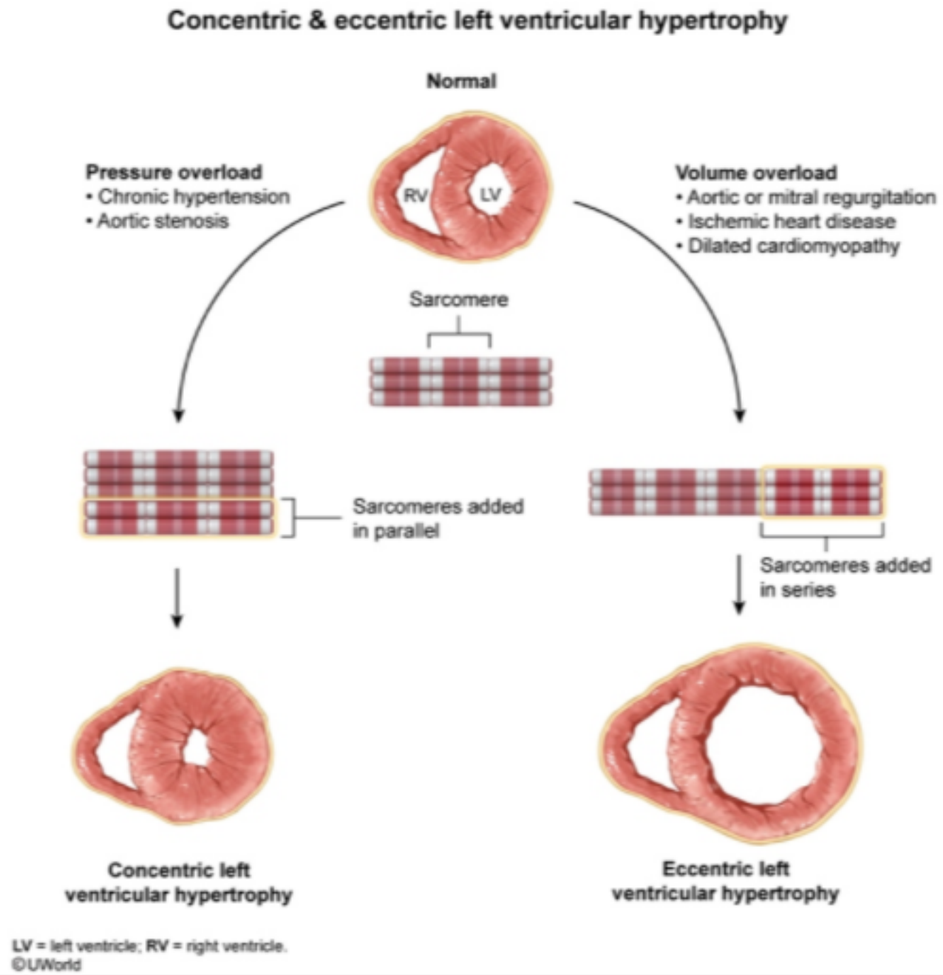

Zoom In | Zoom Out | Reset | Add To New Card | Existing Card

A 32-year-old man comes to the emergency department with chest pain that started earlier in the day. The pain is midline and sharp and increases with deep breaths but decreases when the patient leans forward. He had a mild respiratory illness a week ago. Other medical history is unremarkable. The patient is a lifetime nonsmoker and has no family history of early-onset heart attack, sudden death, or cardiomyopathy. Blood pressure is 120/70 mm Hg and pulse is 110/min and regular. Which of the following physical examination findings is most expected in this patient?

- A. Friction rub
- B. Kussmaul sign
- C. Pericardial knock
- D. Pulsus paradoxus
- E. S3

Submit

A 32-year-old man comes to the emergency department with chest pain that started earlier in the day. The pain is midline and sharp and increases with deep breaths but decreases when the patient leans forward. He had a mild respiratory illness a week ago. Other medical history is unremarkable. The patient is a lifetime nonsmoker and has no family history of early-onset heart attack, sudden death, or cardiomyopathy. Blood pressure is 120/70 mm Hg and pulse is 110/min and regular. Which of the following physical examination findings is most expected in this patient?

- ✓ A. Friction rub (81%)
- B. Kussmaul sign (5%)
- C. Pericardial knock (3%)
- D. Pulsus paradoxus (7%)
- E. S3 (1%)

Omitted
Correct answer
A

81%
Answered correctly

13 secs
Time Spent

03/29/2020
Last Updated

Explanation

The chest pain of **acute pericarditis** is sharp and pleuritic and characteristically **decreases** when the patient sits and **leans forward**, which decreases pressure on the parietal pericardium. Fibrinous/serofibrinous pericarditis is the most common type of pericarditis, and a **pericardial friction rub** (described as high pitched, leathery, and scratchy) is the most specific physical finding. Fibrinous pericarditis may be caused by myocardial infarction, rheumatologic disease (eg, systemic lupus erythematosus), uremia, or viral infection. This patient's history of a recent upper respiratory illness suggests a **viral etiology**.

(Choice B) During inspiration, jugular venous pressure normally decreases as blood is pulled into the right side of the heart. Kussmaul sign is a

The chest pain of **acute pericarditis** is sharp and pleuritic and characteristically **decreases** when the patient sits and **leans forward**, which decreases pressure on the parietal pericardium. Fibrinous/serofibrinous pericarditis is the most common type of pericarditis, and a **pericardial friction rub** (described as high pitched, leathery, and scratchy) is the most specific physical finding. Fibrinous pericarditis may be caused by myocardial infarction, rheumatologic disease (eg, systemic lupus erythematosus), uremia, or viral infection. This patient's history of a recent upper respiratory illness suggests a **viral etiology**.

(Choice B) During inspiration, jugular venous pressure normally decreases as blood is pulled into the right side of the heart. Kussmaul sign is a paradoxical increase in jugular venous pressure on inspiration. It occurs because of impaired right-sided diastolic filling in conditions such as constrictive pericarditis, restrictive cardiomyopathy, and tricuspid stenosis. Although constrictive (chronic) pericarditis can result from prolonged pericardial inflammation (over months to years), this patient's presentation is consistent with acute pericarditis, which is not associated with impaired right-sided diastolic filling.

(Choice C) A pericardial knock is a brief, high-frequency, precordial sound heard in early diastole (shortly after S2) in patients with constrictive pericarditis. It occurs earlier than S3 and may be confused with the opening snap of mitral stenosis.

(Choice D) Pulsus paradoxus is a drop in systolic blood pressure >10 mm Hg during inspiration. It represents an exaggeration of the normal reduction in systolic blood pressure during inspiration. It can be seen in cardiac tamponade, constrictive pericarditis, and severe asthma or chronic obstructive pulmonary disease.

(Choice E) An S3 typically results from rapid cessation of diastolic filling into an enlarged ventricle. It is usually associated with heart failure such as occurs with dilated cardiomyopathy, severe mitral regurgitation, or severe aortic regurgitation. A right-sided S3 can occur with right-sided heart failure.

Educational objective:
Acute-onset, sharp, and pleuritic chest pain that decreases with leaning forward is characteristic of acute pericarditis. Fibrinous/serofibrinous pericarditis is the most common form of pericarditis and a pericardial friction rub is the most specific physical finding. Viral pericarditis is often preceded by an upper respiratory infection.

References

- Acute pericarditis.

decreases pressure on the parietal pericardium. Fibrinous/serofibrinous pericarditis is the most common type of pericarditis, and a **pericardial**

Exhibit Display

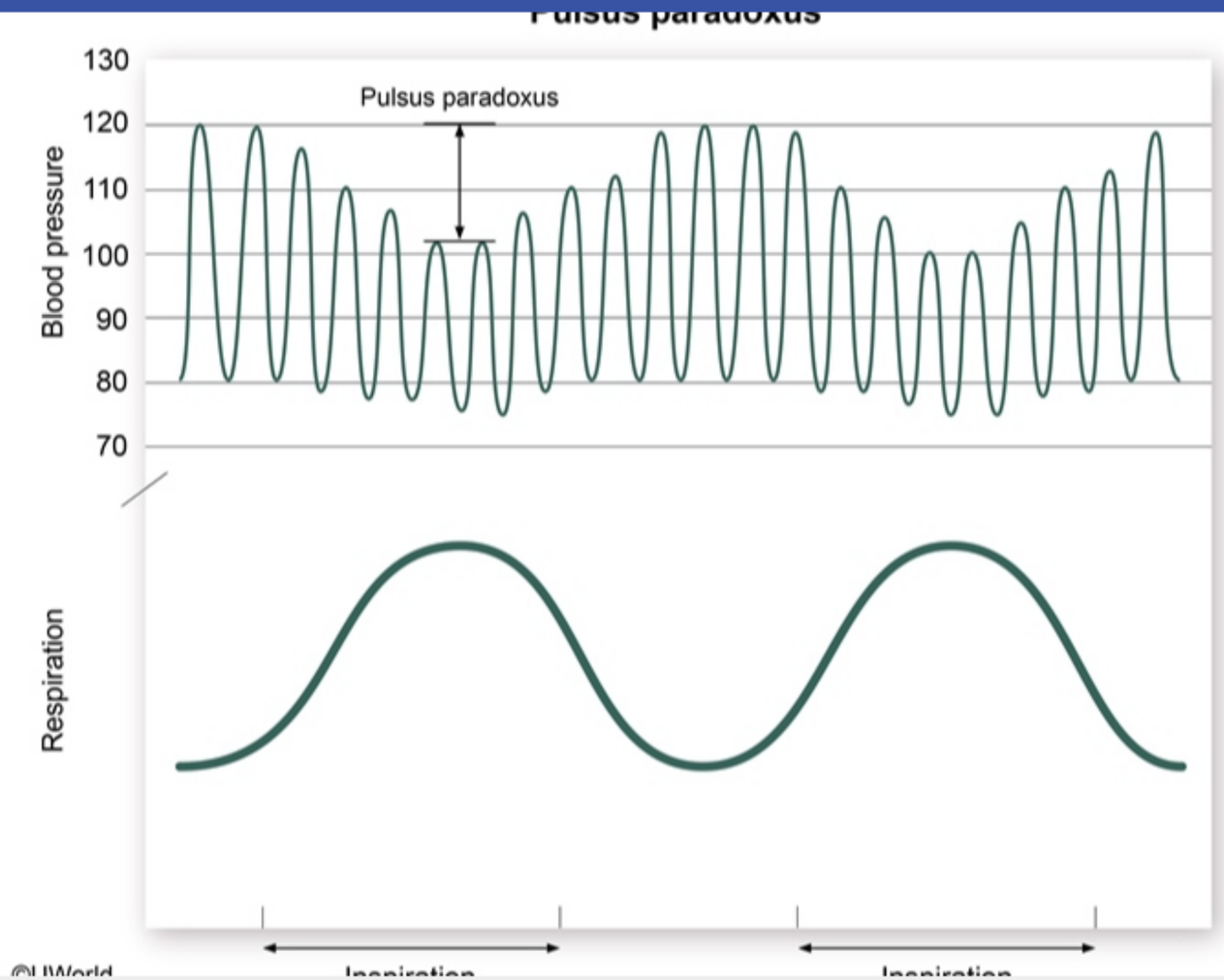

Zoom In | Zoom Out | Reset | Add To New Card | Existing Card

Pathophysiology | Cardiovascular System | Acute pericarditis

decreases pressure on the parietal pericardium. Fibrinous/serofibrinous pericarditis is the most common type of pericarditis, and a **pericardial friction rub** (described as high pitched, leathery, and scratchy) is the most specific physical finding. Fibrinous pericarditis may be caused by myocardial infarction, rheumatologic disease (eg, systemic lupus erythematosus), uremia, or viral infection. This patient's history of a recent upper respiratory illness suggests a **viral etiology**.

(Choice B) During inspiration, jugular venous pressure normally decreases as blood is pulled into the right side of the heart. Kussmaul sign is a paradoxical increase in jugular venous pressure on inspiration. It occurs because of impaired right-sided diastolic filling in conditions such as constrictive pericarditis, restrictive cardiomyopathy, and tricuspid stenosis. Although constrictive (chronic) pericarditis can result from prolonged pericardial inflammation (over months to years), this patient's presentation is consistent with acute pericarditis, which is not associated with impaired right-sided diastolic filling.

(Choice C) A pericardial knock is a brief, high-frequency, precordial sound heard in early diastole (shortly after S2) in patients with constrictive pericarditis. It occurs earlier than S3 and may be confused with the opening snap of mitral stenosis.

(Choice D) Pulsus paradoxus is a drop in systolic blood pressure >10 mm Hg during inspiration. It represents an exaggeration of the normal reduction in systolic blood pressure during inspiration. It can be seen in cardiac tamponade, constrictive pericarditis, and severe asthma or chronic obstructive pulmonary disease.

(Choice E) An S3 typically results from rapid cessation of diastolic filling into an enlarged ventricle. It is usually associated with heart failure such as occurs with dilated cardiomyopathy, severe mitral regurgitation, or severe aortic regurgitation. A right-sided S3 can occur with right-sided heart failure.

Educational objective:
Acute-onset, sharp, and pleuritic chest pain that decreases with leaning forward is characteristic of acute pericarditis. Fibrinous/serofibrinous pericarditis is the most common form of pericarditis and a pericardial friction rub is the most specific physical finding. Viral pericarditis is often preceded by an upper respiratory infection.

References

- Acute pericarditis.

Pathophysiology Cardiovascular System Acute pericarditis

Atherosclerotic lesions of the coronary arteries can limit blood flow to the myocardial regions supplied by the affected vessels. Certain medications can cause a redistribution of blood flow away from the ischemic areas, exacerbating existing myocardial ischemia. Which of the following drug effects is most likely to produce this phenomenon?

A. Coronary arteriolar dilation

B. Decreased myocardial contractility

C. Epicardial vessel dilation

D. Negative chronotropic effect

E. Systemic venous dilation

Submit

Atherosclerotic lesions of the coronary arteries can limit blood flow to the myocardial regions supplied by the affected vessels. Certain medications can cause a redistribution of blood flow away from the ischemic areas, exacerbating existing myocardial ischemia. Which of the following drug effects is most likely to produce this phenomenon?

- ✓ A. Coronary arteriolar dilation (59%)
- B. Decreased myocardial contractility (5%)
- C. Epicardial vessel dilation (11%)
- D. Negative chronotropic effect (4%)
- E. Systemic venous dilation (18%)

Omitted
Correct answer
A

59%
Answered correctly

02 secs
Time Spent

05/29/2020
Last Updated

Explanation



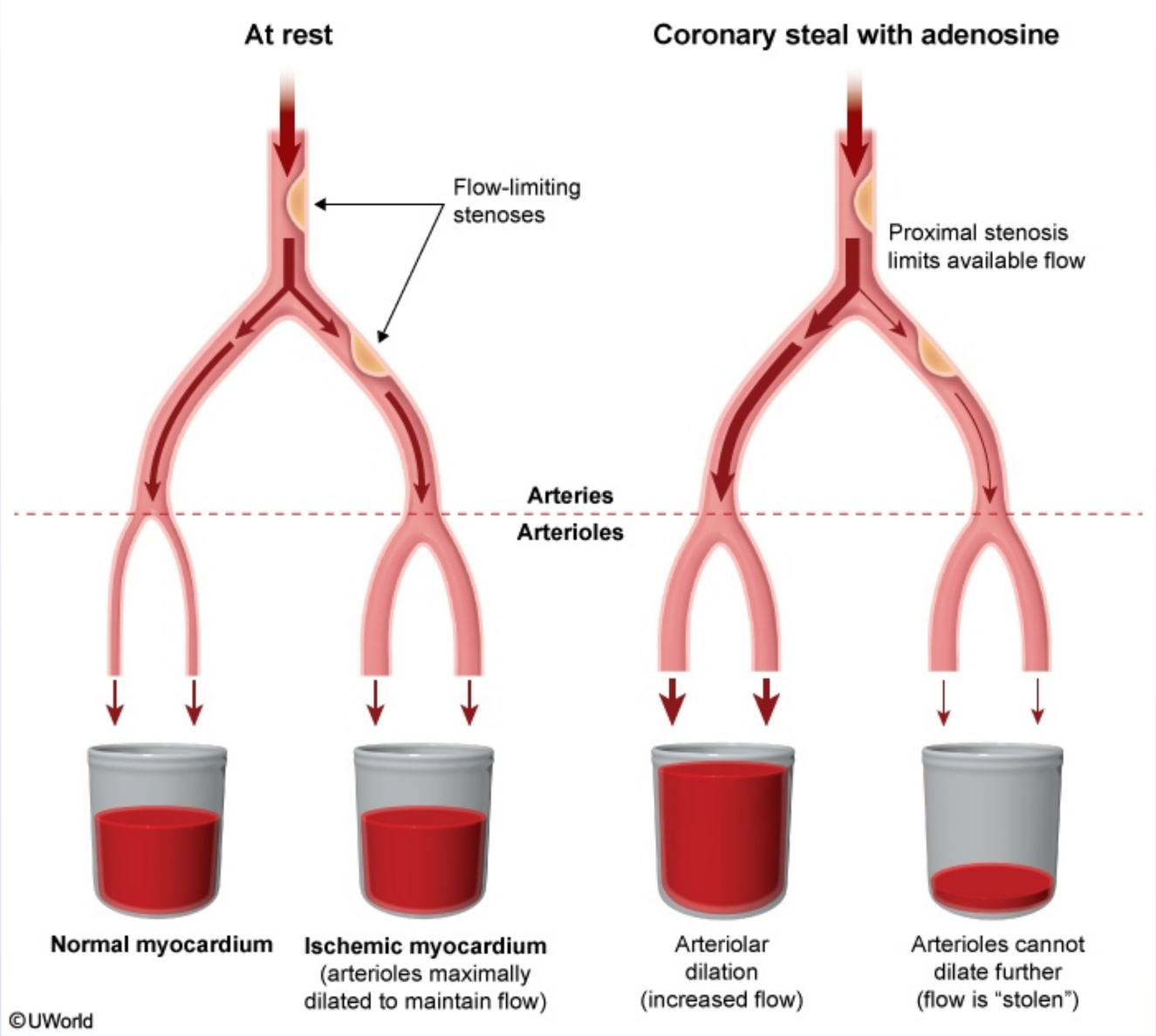
At rest
Coronary steal with adenosine
Flow-limiting stenoses
Proximal stenosis limits available flow
Arteries
Arterioles
Normal myocardium
Ischemic myocardium (arterioles maximally dilated to maintain flow)
Arteriolar dilation (increased flow)
Arterioles cannot dilate further (flow is "stolen")
©UWorld

Hemodynamically significant atherosclerotic lesions (>50% occlusion) reduce the amount of blood supplied by a coronary vessel to the corresponding myocardial territory. In response, the myocardium releases locally acting, endogenous substances (eg, adenosine, nitric oxide) that cause **dilation of coronary arterioles**, leading to a downstream reduction in pressure and recruitment of additional blood flow to that region. Arterioles that supply areas of significantly **ischemic myocardium** can become **maximally dilated** at rest, limiting their capacity to further increase blood flow.

Pharmacologic stress agents (eg, adenosine, dipyridamole) are used during myocardial perfusion imaging to simulate the generalized coronary arteriole dilation caused by exercise to assist in identifying areas of ischemic myocardium. Administration of these drugs will result in no change in blood flow to ischemic myocardium and a significant increase in blood flow to nonischemic myocardium; the amplified relative difference in blood flow allows for easy detection of ischemic myocardial areas.

When recruitment of additional upstream blood flow is limited (eg, due to a proximal atherosclerotic lesion), these drugs can lead to an absolute **decrease in blood flow to ischemic myocardium**, as most of the limited blood supply is redirected toward the newly vasodilated areas of nonischemic myocardium. This redistribution of blood flow is referred to as **coronary steal**, and most commonly occurs in individuals with extensive coronary artery disease.

(Choices B, D, and E) Decreased myocardial contractility, negative chronotropy, and systemic venous dilation (leading to reduced preload) all decrease myocardial oxygen demand through a reduction in cardiac work. These mechanisms act to improve myocardial ischemia globally and will not result in a redistribution of blood flow away from areas of ischemic myocardium.

(Choice C) The epicardial vessels are the large coronary arteries of the heart (eg, right coronary, left circumflex). Although dilation of these large arteries plays a role in increasing myocardial blood flow, coronary blood flow regulation is mostly mediated by the arterioles. Dilation of large coronary arteries would improve global cardiac blood flow and would not trigger coronary steal.

Educational objective:
Increases in resting blood flow to ischemic myocardium are primarily mediated by locally-acting substances (eg, adenosine, nitric oxide) that trigger coronary arteriolar vasodilation. Pharmacologic arteriolar vasodilators (eg, adenosine, dipyridamole) mimic the vasodilation that occurs with exercise and may cause redistribution of blood flow from ischemic to nonischemic areas of myocardium, so-called coronary steal.

References

- Absolute quantitation of coronary steal induced by intravenous dipyridamole.

Pharmacologic stress agents (eg, adenosine, dipyridamole) are used during myocardial perfusion imaging to simulate the generalized coronary arteriole dilation caused by exercise to assist in identifying areas of ischemic myocardium. Administration of these drugs will result in no change in blood flow to ischemic myocardium and a significant increase in blood flow to nonischemic myocardium; the amplified relative difference in blood flow allows for easy detection of ischemic myocardial areas.

When recruitment of additional upstream blood flow is limited (eg, due to a proximal atherosclerotic lesion), these drugs can lead to an absolute **decrease in blood flow to ischemic myocardium**, as most of the limited blood supply is redirected toward the newly vasodilated areas of nonischemic myocardium. This redistribution of blood flow is referred to as **coronary steal**, and most commonly occurs in individuals with extensive coronary artery disease.

(Choices B, D, and E) Decreased myocardial contractility, negative chronotropy, and systemic venous dilation (leading to reduced preload) all decrease myocardial oxygen demand through a reduction in cardiac work. These mechanisms act to improve myocardial ischemia globally and will not result in a redistribution of blood flow away from areas of ischemic myocardium.

(Choice C) The epicardial vessels are the large coronary arteries of the heart (eg, right coronary, left circumflex). Although dilation of these large arteries plays a role in increasing myocardial blood flow, coronary blood flow regulation is mostly mediated by the arterioles. Dilation of large coronary arteries would improve global cardiac blood flow and would not trigger coronary steal.

Educational objective:
Increases in resting blood flow to ischemic myocardium are primarily mediated by locally-acting substances (eg, adenosine, nitric oxide) that trigger coronary arteriolar vasodilation. Pharmacologic arteriolar vasodilators (eg, adenosine, dipyridamole) mimic the vasodilation that occurs with exercise and may cause redistribution of blood flow from ischemic to nonischemic areas of myocardium, so-called coronary steal.

References

- Absolute quantitation of coronary steal induced by intravenous dipyridamole.

Pathophysiology	Cardiovascular System	Coronary blood flow
Subject	System	Topic

Copyright © UWorld. All rights reserved.

Pharmacologic stress agents (eg, adenosine, dipyridamole) are used during myocardial perfusion imaging to simulate the generalized coronary

Exhibit Display

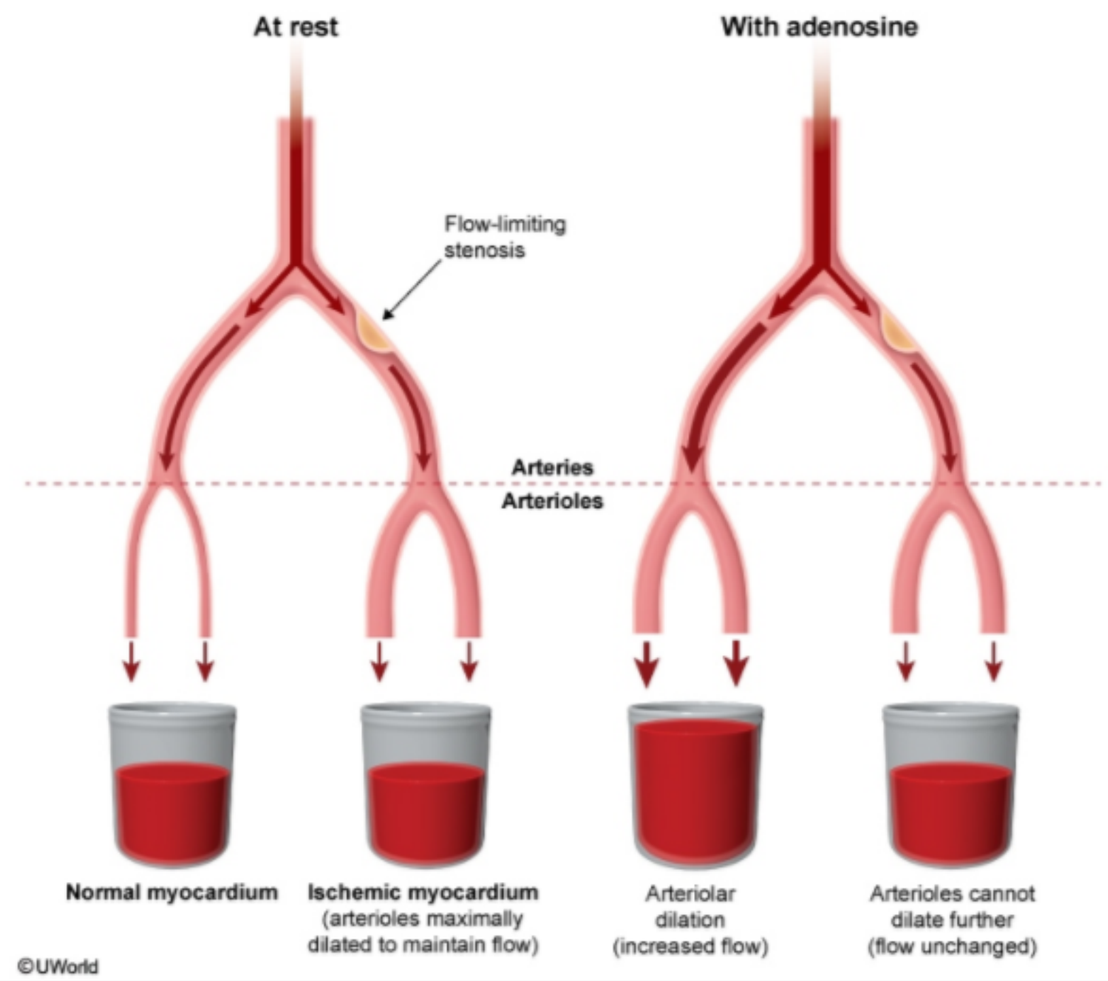

Zoom In | Zoom Out | Reset | Add To New Card | Existing Card

A 63-year-old man comes to the office due to exertional dyspnea that has been progressively worsening over the last 3 weeks. He sleeps in a recliner with his head elevated because he gets short of breath when lying flat in bed. Medical history includes gout, dyslipidemia, and hypertension. Blood pressure is 154/89 mm Hg and pulse is 85/min. Physical examination shows distended jugular veins in the semi-recumbent position. An apical heave is present on cardiac examination. There is pitting edema in the bilateral lower extremities. Levels of which of the following substances will be higher in the pulmonary vein compared to the pulmonary artery in this patient?

A. Aldosterone
B. Angiotensin I
C. Angiotensin II
D. Angiotensinase
E. Angiotensinogen
F. Arginine vasopressin
G. Prostaglandin E1
H. Renin

Submit

A 63-year-old man comes to the office due to exertional dyspnea that has been progressively worsening over the last 3 weeks. He sleeps in a recliner with his head elevated because he gets short of breath when lying flat in bed. Medical history includes gout, dyslipidemia, and hypertension. Blood pressure is 154/89 mm Hg and pulse is 85/min. Physical examination shows distended jugular veins in the semi-recumbent position. An apical heave is present on cardiac examination. There is pitting edema in the bilateral lower extremities. Levels of which of the following substances will be higher in the pulmonary vein compared to the pulmonary artery in this patient?

- A. Aldosterone (1%)
- B. Angiotensin I (13%)
- ✓ C. Angiotensin II (61%)
- D. Angiotensinase (2%)
- E. Angiotensinogen (4%)
- F. Arginine vasopressin (3%)
- G. Prostaglandin E1 (9%)
- H. Renin (3%)

Omitted
Correct answer
C

61%
Answered correctly

02 secs
Time Spent

02/11/2020
Last Updated

Explanation

1
2
3
4
5
6
7
8
9
10
11
12
13
14
15
16
17
18
19
20
21
22
23
24
25
26
27
28
29
30
31

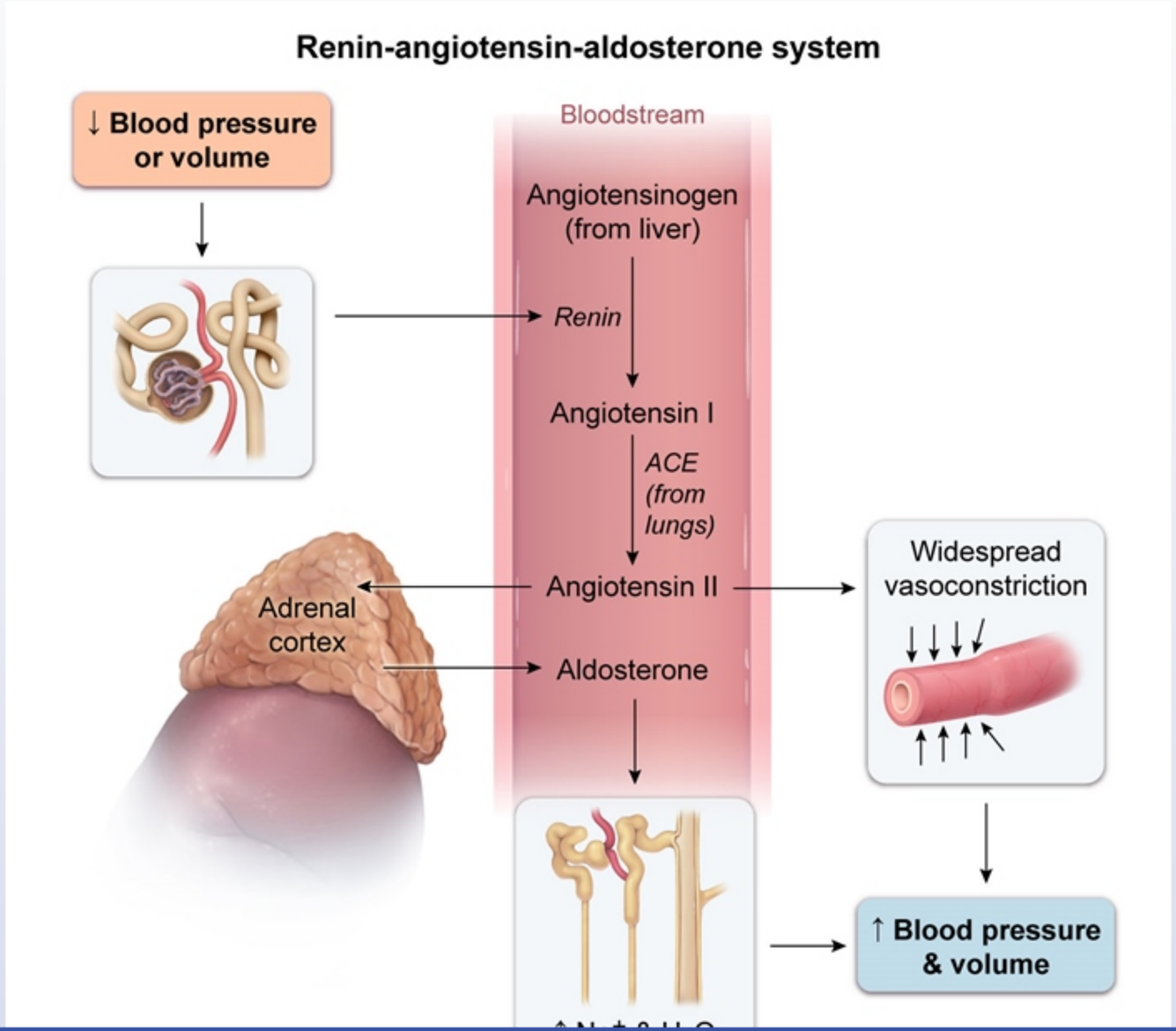

1
2
3
4
5
6
7
8
9
10
11
12
13
14
15
16
17
18
19
20
21
22
23
24
25
26
27
28
29
30
31

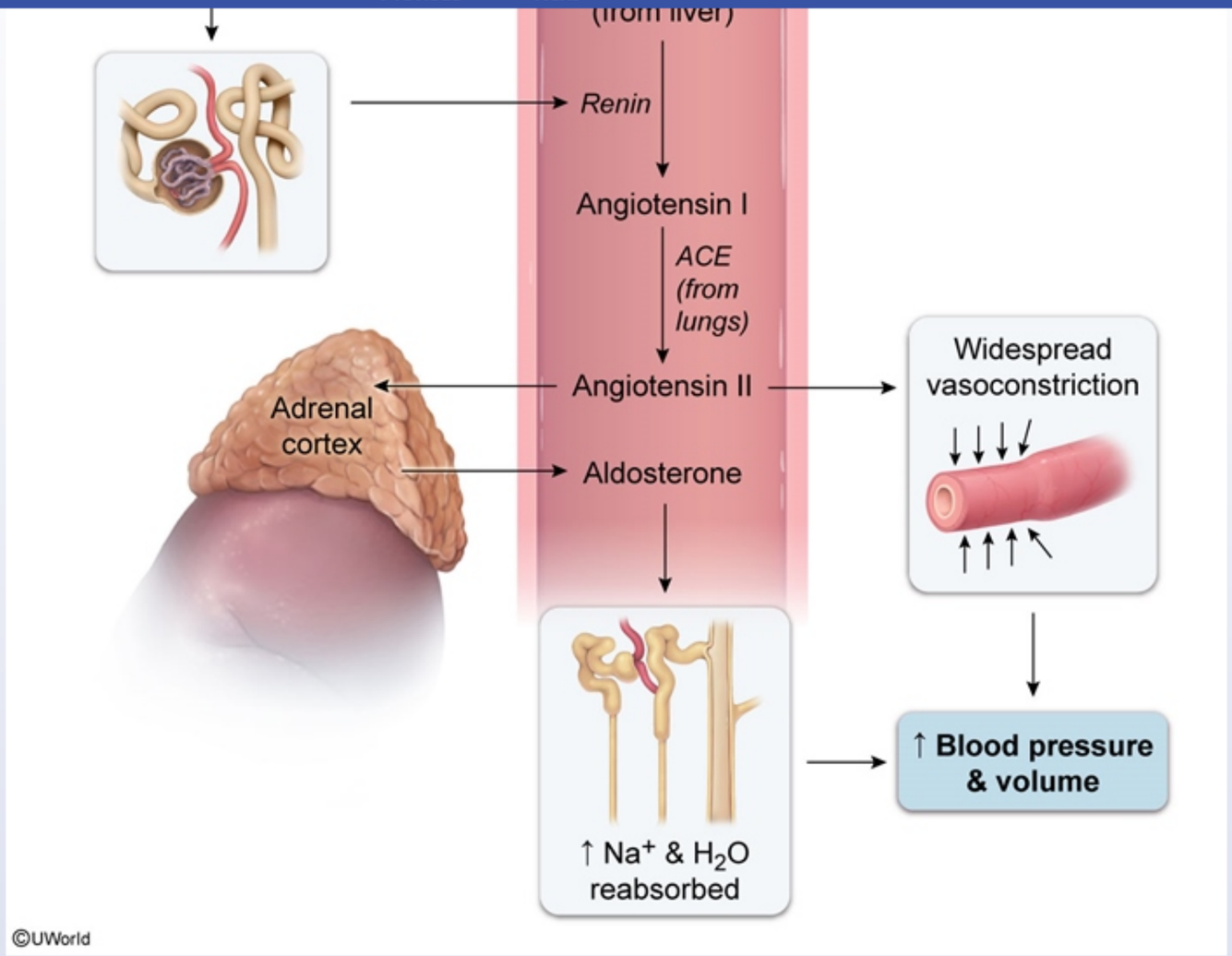

This patient's exertional dyspnea, orthopnea (dyspnea when lying flat), jugular venous distension, cardiac heave, and peripheral edema are consistent with **decompensated heart failure**. The decreased cardiac output in heart failure reduces renal perfusion, which stimulates **renin secretion** by the juxtaglomerular cells of the kidney **(Choice H)** in a maladaptive effort to maintain effective blood volume and organ perfusion.

This patient's exertional dyspnea, orthopnea (dyspnea when lying flat), jugular venous distension, cardiac heave, and peripheral edema are consistent with **decompensated heart failure**. The decreased cardiac output in heart failure reduces renal perfusion, which stimulates **renin secretion** by the juxtaglomerular cells of the kidney **(Choice H)** in a maladaptive effort to maintain effective blood volume and organ perfusion.

Renin acts to convert angiotensinogen (produced by the liver) into angiotensin I in the systemic circulation **(Choices B and E)**. Angiotensin I is then converted to **angiotensin II**, primarily within the **small pulmonary vessels**, by endothelial-bound angiotensin-converting enzyme. Because of the pulmonary location of angiotensin conversion, **levels of angiotensin II are higher in the pulmonary vein** than in the pulmonary artery.

Angiotensin II is a potent vasoconstrictor of the systemic circulation and causes a rise in blood pressure (increased afterload) that worsens cardiac output. It also acts on the adrenal glands to stimulate aldosterone release, causing sodium retention and further worsening of volume overload **(Choice A)**.

(Choice D) The angiotensinases are a group of enzymes found in multiple tissues and are responsible for the breakdown of angiotensin II and other structurally similar enzymes.

(Choice F) Arginine vasopressin (antidiuretic hormone) is released from the posterior pituitary in response to high serum osmolality or decreased arterial blood volume. Because reduced cardiac output causes the body to perceive hypovolemia, antidiuretic hormone secretion is typically increased in heart failure.

(Choice G) Prostaglandins are produced in multiple cell types, including endothelial cells, mast cells, and macrophages. Prostaglandin E1 is a potent vasodilator that maintains patency of the ductus arteriosus and causes afferent arteriolar vasodilation in the kidneys.

Educational objective:
The reduced cardiac output in heart failure leads to decreased renal perfusion and consequent stimulation of the renin-angiotensin-aldosterone system in a maladaptive effort to maintain effective blood volume. Inactive angiotensin I is converted into active angiotensin II by endothelial-bound angiotensin-converting enzyme in the lungs.

References

- Heterogeneous distribution of angiotensin I-converting enzyme (CD143) in the human and rat vascular systems: vessel, organ and species specificity.
- Pulmonary capillary endothelium-bound angiotensin-converting enzyme activity in humans.

This patient's exertional dyspnea, orthopnea (dyspnea when lying flat), jugular venous distension, cardiac heave, and peripheral edema are

Exhibit Display

Juxtaglomerular apparatus

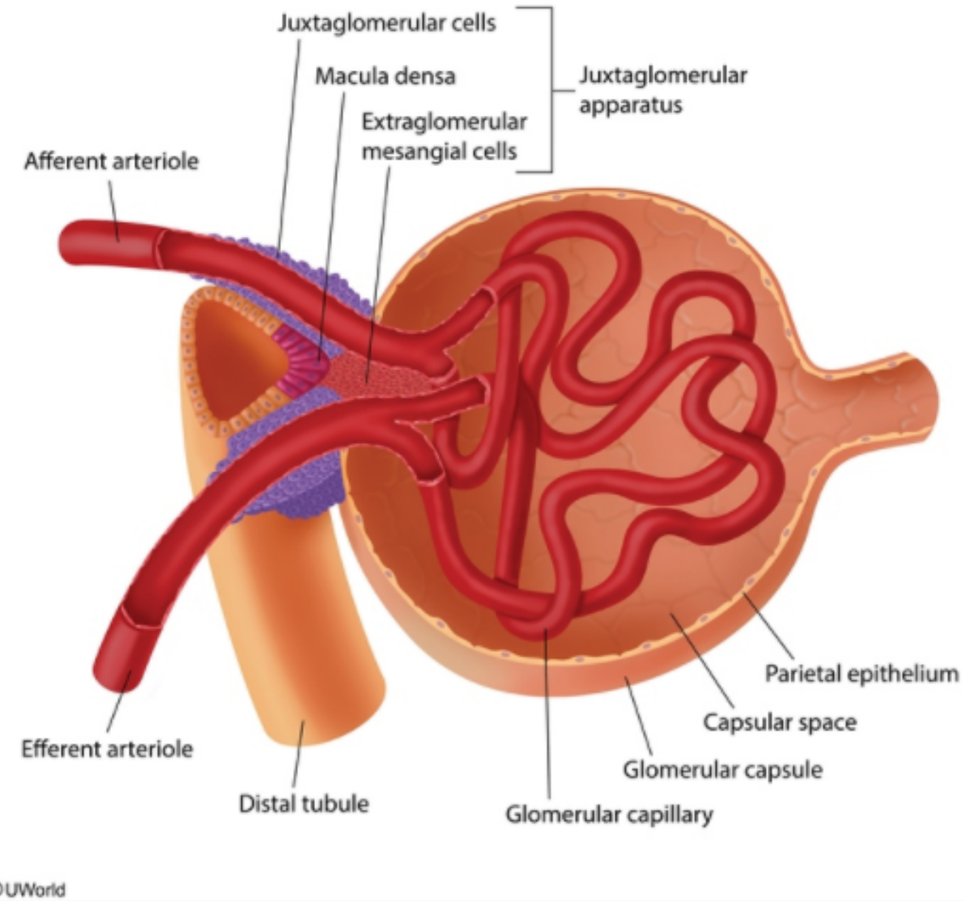

Zoom In | Zoom Out | Reset | Add To New Card | Existing Card

A 62-year-old man comes to the office due to chest pain over the last 6 months. He describes pressure-like pain in the substernal area when walking fast or climbing stairs that gradually subsides when he stops. The patient does not smoke cigarettes or use illicit drugs. He has no family history of heart disease or sudden death. Physical examination shows a mid-systolic murmur at the upper sternum and slow-rising carotid pulses. After initial evaluation, cardiac catheterization is performed and reveals 30% stenosis of the mid-left anterior descending artery. A 50 mm Hg pressure gradient is seen when a catheter is passed across the aortic valve. Which of the following is the most important contributor to this patient's presenting symptoms?

A. Decrease in coronary blood supply due to lipid-rich plaque

B. Decrease in coronary blood supply due to vasospasm

C. Decrease in left ventricular compliance

D. Increase in left ventricular stroke volume

E. Increase in left ventricular wall stress

Submit

A 62-year-old man comes to the office due to chest pain over the last 6 months. He describes pressure-like pain in the substernal area when walking fast or climbing stairs that gradually subsides when he stops. The patient does not smoke cigarettes or use illicit drugs. He has no family history of heart disease or sudden death. Physical examination shows a mid-systolic murmur at the upper sternum and slow-rising carotid pulses. After initial evaluation, cardiac catheterization is performed and reveals 30% stenosis of the mid-left anterior descending artery. A 50 mm Hg pressure gradient is seen when a catheter is passed across the aortic valve. Which of the following is the most important contributor to this patient's presenting symptoms?

A. Decrease in coronary blood supply due to lipid-rich plaque (23%)

B. Decrease in coronary blood supply due to vasospasm (6%)

C. Decrease in left ventricular compliance (17%)

D. Increase in left ventricular stroke volume (5%)

✓ E. Increase in left ventricular wall stress (47%)

Omitted
Correct answer
E

47%
Answered correctly

02 secs
Time Spent

06/13/2020
Last Updated

Explanation

This patient's slow-rising carotid pulses, mid-systolic murmur, and large pressure gradient across the aortic valve are consistent with **severe aortic stenosis** (AS). Patients can remain asymptomatic for long periods but eventually develop classic symptoms of severe AS; dyspnea is typically the first manifestation, followed by **angina**, presyncope or **syncope**, and overt **heart failure**.

The symptoms of severe AS usually occur with exertion, as the capacity to increase stroke volume and cardiac output is limited due to the fixed

This patient's slow-rising carotid pulses, mid-systolic murmur, and large pressure gradient across the aortic valve are consistent with **severe aortic stenosis** (AS). Patients can remain asymptomatic for long periods but eventually develop classic symptoms of severe AS; dyspnea is typically the first manifestation, followed by **angina**, presyncope or **syncope**, and overt **heart failure**.

The symptoms of severe AS usually occur with exertion, as the capacity to increase stroke volume and cardiac output is limited due to the fixed left ventricular outflow obstruction **(Choice D)**. This outflow obstruction also leads to higher chamber pressures and **increased wall stress** during systole and diastole. The rise in systolic wall stress **increases myocardial oxygen demand** while the increased diastolic wall stress reduces the coronary perfusion pressure gradient, leading to decreased myocardial perfusion. Increased left ventricular mass due to concentric hypertrophy further increases myocardial oxygen demand and contributes to anginal symptoms.

(Choice A) Reduced coronary blood supply due to flow-limiting atherosclerotic plaque can cause angina in patients with obstructive coronary artery disease. Stenosis >70% is typically necessary for anginal symptoms to develop; this patient's 30% stenosis is not clinically significant. Angina often occurs in severe AS in the absence of coronary artery disease.

(Choice B) Decreased coronary blood supply due to vasospasm is seen in patients with vasospastic (Prinzmetal) angina. Coronary vasospasm typically affects relatively young patients (age <50) and is not related to the angina that occurs with severe AS.

(Choice C) Decreased left ventricular compliance occurs over time in AS due to the prolonged high-pressure load created by the stenotic valve. This can result in heart failure (eg, fatigue, dyspnea) due to diastolic dysfunction, but would be less likely to induce angina symptoms.

Educational objective:
Angina often occurs in aortic stenosis even in the absence of obstructive coronary artery disease. It results from increased myocardial oxygen demand due to an increase in left ventricular mass (ie, concentric hypertrophy) and ventricular wall stress.

References

- Angina pectoris in patients with aortic stenosis and normal coronary arteries. Mechanisms and pathophysiological concepts.

Pathophysiology	Cardiovascular System	Aortic stenosis
Subject	System	Topic

Copyright © UWorld. All rights reserved.

1
2
3
4
5
6
7
8
9
10
11
12
13
14
15
16
17
18
19
20
21
22
23
24
25
26
27
28
29
30
31

Exhibit Display

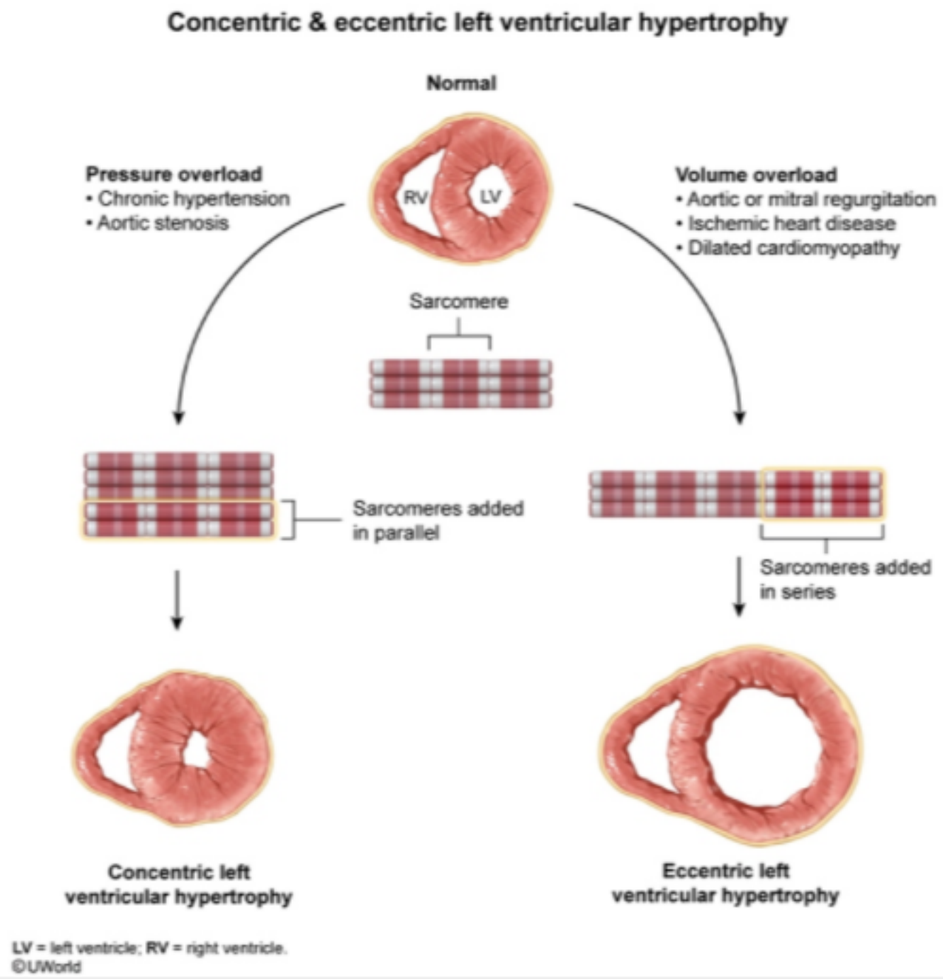

Zoom In Zoom Out Reset Add To Flash Card

Copyright © UWorld. All rights reserved.

A 22-year-old man comes to the office for an exercise evaluation. He is an avid long-distance runner. One of his team members was disqualified recently due to health issues, which made him worried about his health. He has no medical history and does not take any medications or illicit drugs. His maternal grandfather died suddenly at age 40. Blood pressure is 125/75 mm Hg and pulse is 55/min. Transthoracic echocardiogram results are as follows:

Left atrium	mildly enlarged
Left ventricular (LV) cavity size	small
LV septal thickness	increased
LV posterior wall thickness	normal
LV mass	increased
LV ejection fraction	74%

The right ventricle appears normal and there are no valvular lesions. Which of the following best explains this patient's echocardiogram findings?

- A. Anabolic steroid abuse
- B. Cardiac adaptation
- C. Hypertrophic cardiomyopathy
- D. Premature coronary artery disease
- E. Subclinical viral myocarditis

Submit

A 22-year-old man comes to the office for an exercise evaluation. He is an avid long-distance runner. One of his team members was disqualified recently due to health issues, which made him worried about his health. He has no medical history and does not take any medications or illicit drugs. His maternal grandfather died suddenly at age 40. Blood pressure is 125/75 mm Hg and pulse is 55/min. Transthoracic echocardiogram results are as follows:

Left atrium	mildly enlarged
Left ventricular (LV) cavity size	small
LV septal thickness	increased
LV posterior wall thickness	normal
LV mass	increased
LV ejection fraction	74%

The right ventricle appears normal and there are no valvular lesions. Which of the following best explains this patient's echocardiogram findings?

- A. Anabolic steroid abuse (1%)
- B. Cardiac adaptation (16%)
- ✓ C. Hypertrophic cardiomyopathy (81%)
- D. Premature coronary artery disease (0%)
- E. Subclinical viral myocarditis (0%)

Omitted
Correct answer
C

81%
Answered correctly

03 secs
Time Spent

05/28/2020
Last Updated

This patient most likely has **hypertrophic cardiomyopathy** (HCM). Recognition of HCM is important because it is one of the most common causes of sudden cardiac death (SCD) in young adults. Although patients may experience exertional dyspnea, chest pain, lightheadedness, or syncope, they are often asymptomatic. The condition is typically inherited in an autosomal dominant pattern, and patients will often have a **family history** of HCM or unexplained SCD.

Echocardiographic findings consistent with HCM include:

- Overall increase in left ventricular (LV) mass
- **Reduced LV cavity size** (leading to impaired diastolic function)
- **Asymmetric** increase in **LV wall thickness** predominantly affecting the **septum**
- Normal or **increased LV ejection fraction**
- Left atrial enlargement (secondary to increased LV end-diastolic pressure)

Another characteristic of HCM is a **poorly developed coronary capillary network** in hypertrophied regions with evidence of chronic ischemia (ie, fibrosis, scarring).

(Choice A) Anabolic steroid abuse can cause pathologic concentric LV hypertrophy, characterized by reduced diastolic function and poor coronary vascularization. However, uniform ventricular wall thickening would be expected.

(Choice B) Athlete's heart involves physiologic cardiac adaptations that improve cardiac function in response to high-level endurance training. There is typically predominant eccentric hypertrophy with enlarged LV cavity size and a small degree of concentric hypertrophy with uniformly increased LV wall thickness. The changes of athlete's heart must be differentiated from those associated with pathologic disease; this patient's reduced LV cavity size and localized septal wall thickening suggest underlying pathology due to HCM.

(Choice D) Severe coronary artery disease can lead to ischemic cardiomyopathy, which typically manifests as a dilated cardiomyopathy with an enlarged LV cavity and thin LV walls with impaired systolic function.

(Choice E) Viral myocarditis may sometimes lead to dilated cardiomyopathy with eccentric hypertrophy and impaired LV systolic function. Subclinical disease is typically quite mild and resolves without sequelae.

Educational objective:
Patients with hypertrophic cardiomyopathy (HCM) may be asymptomatic and often have a family history of HCM or sudden cardiac death.

- **Reduced LV cavity size** (leading to impaired diastolic function)
- **Asymmetric** increase in **LV wall thickness** predominantly affecting the **septum**
- Normal or **increased LV ejection fraction**
- Left atrial enlargement (secondary to increased LV end-diastolic pressure)

Another characteristic of HCM is a **poorly developed coronary capillary network** in hypertrophied regions with evidence of chronic ischemia (ie, fibrosis, scarring).

(Choice A) Anabolic steroid abuse can cause pathologic concentric LV hypertrophy, characterized by reduced diastolic function and poor coronary vascularization. However, uniform ventricular wall thickening would be expected.

(Choice B) Athlete's heart involves physiologic cardiac adaptations that improve cardiac function in response to high-level endurance training. There is typically predominant eccentric hypertrophy with enlarged LV cavity size and a small degree of concentric hypertrophy with uniformly increased LV wall thickness. The changes of athlete's heart must be differentiated from those associated with pathologic disease; this patient's reduced LV cavity size and localized septal wall thickening suggest underlying pathology due to HCM.

(Choice D) Severe coronary artery disease can lead to ischemic cardiomyopathy, which typically manifests as a dilated cardiomyopathy with an enlarged LV cavity and thin LV walls with impaired systolic function.

(Choice E) Viral myocarditis may sometimes lead to dilated cardiomyopathy with eccentric hypertrophy and impaired LV systolic function. Subclinical disease is typically quite mild and resolves without sequelae.

Educational objective:
Patients with hypertrophic cardiomyopathy (HCM) may be asymptomatic and often have a family history of HCM or sudden cardiac death. Findings consistent with HCM include an overall increase in left ventricular (LV) mass, reduced LV cavity size with impaired diastolic function, LV hypertrophy predominantly affecting the septum, and normal or increased LV ejection fraction.

Pathophysiology	Cardiovascular System	Hypertrophic cardiomyopathy
Subject	System	Topic

Copyright © UWorld. All rights reserved.

A 34-year-old woman is being evaluated for fatigue and progressive exertional dyspnea. She goes mountain biking with friends a few times a month and recently noticed that she has to stop and rest more frequently when traveling uphill. The patient has no significant medical history and takes no medications. She occasionally drinks alcohol but does not use tobacco or illicit drugs. Her father died of a myocardial infarction at age 72. Lung auscultation is normal. An echocardiogram shows an enlarged coronary sinus. Which of the following is the most likely cause of the observed finding in this patient?

- A. Aortic dissection
- B. Coronary artery disease
- C. Hypertrophic cardiomyopathy
- D. Pericardial effusion
- E. Pulmonary hypertension

Submit

A 34-year-old woman is being evaluated for fatigue and progressive exertional dyspnea. She goes mountain biking with friends a few times a month and recently noticed that she has to stop and rest more frequently when traveling uphill. The patient has no significant medical history and takes no medications. She occasionally drinks alcohol but does not use tobacco or illicit drugs. Her father died of a myocardial infarction at age 72. Lung auscultation is normal. An echocardiogram shows an enlarged coronary sinus. Which of the following is the most likely cause of the observed finding in this patient?

- A. Aortic dissection (2%)
- B. Coronary artery disease (16%)
- C. Hypertrophic cardiomyopathy (23%)
- D. Pericardial effusion (5%)
- ✓ E. Pulmonary hypertension (53%)

Omitted
Correct answer
E

53%
Answered correctly

02 secs
Time Spent

03/22/2020
Last Updated

Explanation

Most of the venous drainage from the myocardium traverses the **coronary sinus** (CS), which delivers deoxygenated blood to the right atrium. The CS runs transversely in the left atrioventricular groove on the posterior aspect of the heart, and opens into the right atrium between the inferior vena cava and tricuspid valve at the CS orifice. Because the CS communicates freely with the right atrium, it will become dilated by any factor that causes dilation of the right atrium. The most common cause of **coronary sinus dilation** evident on echocardiography is **elevated right-sided heart pressure** secondary to **pulmonary hypertension**. CS dilation also occurs in patients with anomalous venous drainage into the CS,

Most of the venous drainage from the myocardium traverses the **coronary sinus** (CS), which delivers deoxygenated blood to the right atrium. The CS runs transversely in the left atrioventricular groove on the posterior aspect of the heart, and opens into the right atrium between the inferior vena cava and tricuspid valve at the CS orifice. Because the CS communicates freely with the right atrium, it will become dilated by any factor that causes dilation of the right atrium. The most common cause of **coronary sinus dilation** evident on echocardiography is **elevated right-sided heart pressure** secondary to **pulmonary hypertension**. CS dilation also occurs in patients with anomalous venous drainage into the CS, including persistent left superior vena cava and total anomalous pulmonary venous return.

(Choice A) Aortic dissection can occur in patients with severe hypertension. Such patients might have elevated left heart pressures, but elevated right-sided heart pressures with dilation of the CS would be unlikely.

(Choice B) The presence of asymptomatic coronary artery disease usually does not change the size of the CS. Long-standing left ventricular systolic dysfunction due to prior myocardial infarction and ischemic cardiomyopathy can lead to secondary pulmonary hypertension, with the possibility of CS dilation over time.

(Choice C) Hypertrophic cardiomyopathy usually manifests as asymmetric septal hypertrophy with or without left ventricular outflow tract obstruction. CS dilation should not occur unless there is superimposed biventricular heart failure.

(Choice D) Pericardial effusion can cause extrinsic compression of the CS.

Educational objective:
The coronary sinus communicates freely with the right atrium and will become dilated secondary to any factor that causes increased right atrial pressure. The most common cause is pulmonary hypertension, leading to elevated right heart pressures.

References

- Dilation of the coronary sinus on echocardiogram: Prevalence and significance in patients with chronic pulmonary hypertension.

Pathophysiology	Cardiovascular System	Coronary blood flow
Subject	System	Topic

Copyright © UWorld. All rights reserved.

1 2 3 4 5 6 7 8 9 10 11 12 13 14 15 16 17 18 19 20 21 22 23 24 25 26 27 28 29 30 31

A 63-year-old man comes to the emergency department due to progressive dyspnea and fatigue. Over the last week, he has not been able to lie flat due to difficulty breathing and has had to sleep in a sitting position. He had an anterior myocardial infarction 6 months ago and has not been compliant with his medication regimen since that time. Medical history is also significant for hypertension. The patient is an ex-smoker with a 30-pack-year history. He does not drink alcohol. His father died of a heart attack at age 60. Blood pressure is 170/100 mm Hg, and pulse is 100/min and regular. Oxygen saturation is 90% on room air. He is afebrile. Auscultation reveals crackles at the lung bases, an S3 gallop, and a II/VI holosystolic murmur over the apex. The patient is admitted to the hospital, and after treatment with diuretics and vasodilators his condition improves significantly. Three days later there are no appreciable gallops or murmurs on cardiac examination. Which of the following best explains the murmur heard at the time of the initial examination?

A. Heavily calcified mitral annulus

B. Increased flow velocity through the aortic valve

C. Ruptured chordae tendineae

D. Secondary mitral regurgitation

E. Thickened and deformed mitral valve cusps

Submit

A 63-year-old man comes to the emergency department due to progressive dyspnea and fatigue. Over the last week, he has not been able to lie flat due to difficulty breathing and has had to sleep in a sitting position. He had an anterior myocardial infarction 6 months ago and has not been compliant with his medication regimen since that time. Medical history is also significant for hypertension. The patient is an ex-smoker with a 30-pack-year history. He does not drink alcohol. His father died of a heart attack at age 60. Blood pressure is 170/100 mm Hg, and pulse is 100/min and regular. Oxygen saturation is 90% on room air. He is afebrile. Auscultation reveals crackles at the lung bases, an S3 gallop, and a II/VI holosystolic murmur over the apex. The patient is admitted to the hospital, and after treatment with diuretics and vasodilators his condition improves significantly. Three days later there are no appreciable gallops or murmurs on cardiac examination. Which of the following best explains the murmur heard at the time of the initial examination?

- A. Heavily calcified mitral annulus (1%)
- B. Increased flow velocity through the aortic valve (12%)
- C. Ruptured chordae tendineae (7%)
- ✓ D. Secondary mitral regurgitation (75%)
- E. Thickened and deformed mitral valve cusps (3%)

Omitted
Correct answer
D

75%
Answered correctly

02 secs
Time Spent

02/24/2020
Last Updated

Explanation

Normal	Functional mitral valve regurgitation

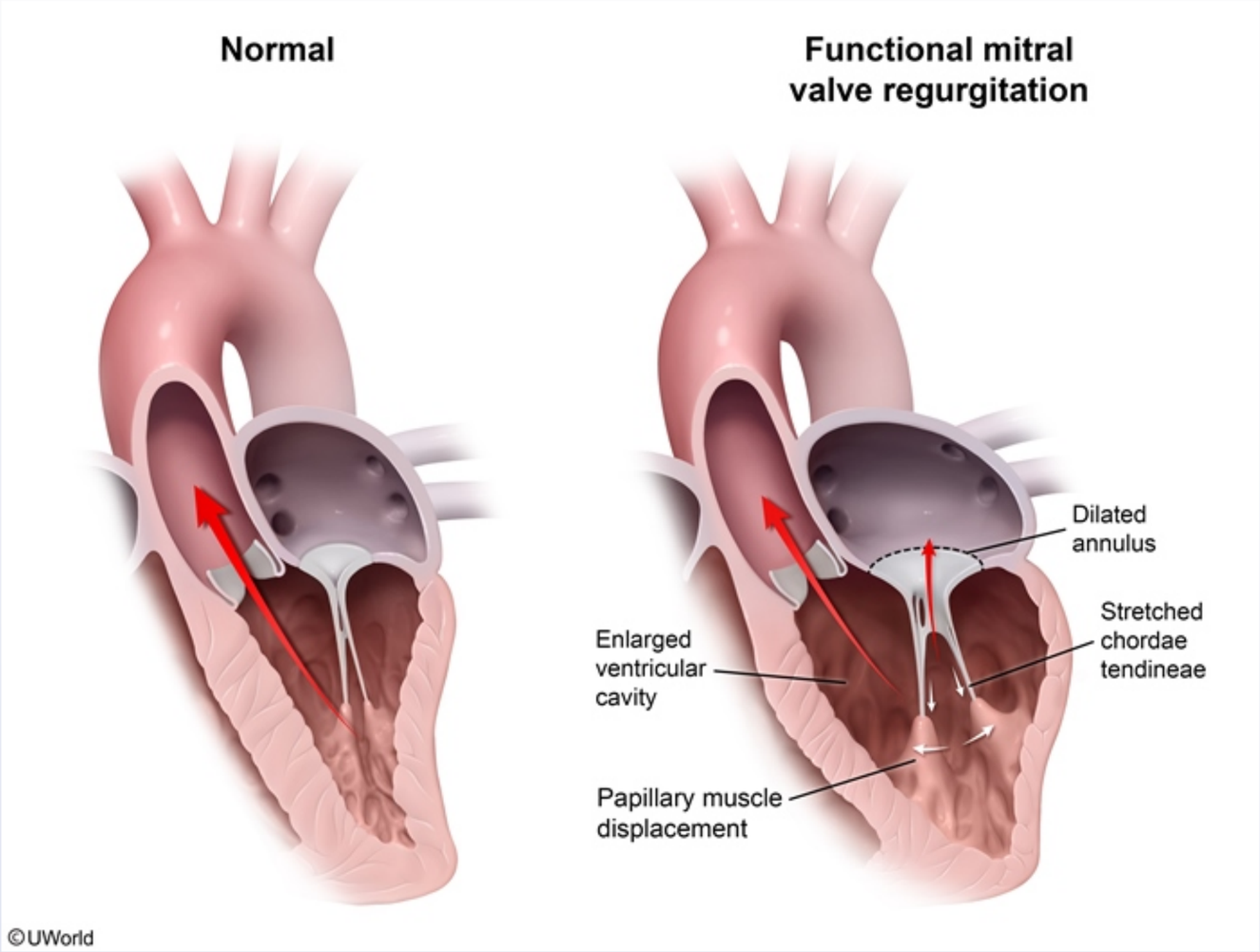

This patient's presentation with fatigue, progressive dyspnea, orthopnea, pulmonary crackles, and an S3 heart sound is consistent with **decompensated heart failure**. Appropriate treatment with diuretics and vasodilators resulted in symptomatic improvement and disappearance of the apical holosystolic murmur, which was most likely due to **secondary (functional) mitral valve regurgitation** (MR).

©UWorld

This patient's presentation with fatigue, progressive dyspnea, orthopnea, pulmonary crackles, and an S3 heart sound is consistent with **decompensated heart failure**. Appropriate treatment with diuretics and vasodilators resulted in symptomatic improvement and disappearance of the apical holosystolic murmur, which was most likely due to **secondary (functional) mitral valve regurgitation** (MR).

Whereas primary MR is caused by an intrinsic defect of the mitral valve apparatus (eg, cleft in a valve cusp, myxomatous degeneration of the chordae tendineae), secondary MR occurs due to other factors. Decompensated heart failure is a common cause of secondary MR because it leads to an increase in left ventricular end-diastolic volume (LVEDV), or preload, with **dilation of the mitral valve annulus** (the tissue on which the mitral valve cusps are mounted) and taut stretching of the chordae tendineae. The dilated annulus and **restricted movement of the chordae tendineae** can cause insufficient closure of an intrinsically normal mitral valve, resulting in MR. Systemic hypertension can also contribute to secondary MR by favoring relatively lower-resistance regurgitant flow.

Treatment with diuretics to reduce LVEDV and vasodilators to reduce blood pressure can lead to resolution of heart failure-induced MR.

(Choice A) Calcification of the mitral valve annulus may occur with aging, and can be accelerated by hypertension or advanced kidney disease. It is usually an incidental finding that does not affect mitral valve function.

(Choice B) Increased flow velocity through the aortic valve occurs with aortic valve stenosis. The resulting murmur is crescendo-decrescendo and best heard at the right second intercostal space (rather than holosystolic and best heard at the apex).

(Choice C) Chordae tendineae rupture is a potential cause of primary MR that can occur in the setting of bacterial endocarditis, connective tissue disease (eg, Marfan syndrome), or acute myocardial infarction. The resulting murmur does not resolve with diuretics and vasodilators; surgical repair is typically required.

(Choice E) Thickened and deformed mitral valve cusps can occur in rheumatic heart disease and are a potential cause of primary MR. Such a murmur does not resolve with treatment of decompensated heart failure. In addition, mitral stenosis (evidenced by an opening snap and mid-diastolic rumble) is more likely than MR to occur with rheumatic heart disease.

Educational objective:
Decompensated heart failure is a common cause of secondary (functional) mitral valve regurgitation. Increased left ventricular end-diastolic volume causes dilation of the mitral valve annulus and restricted movement of the chordae tendineae with subsequent regurgitation. Treatment

©UWorld

Exhibit Display

0:00

This patient's presentatior
decompensated heart fa e of
the apical holosystolic mu

Whereas primary MR is ca
chordae tendineae), secor
leads to an increase in lef h
the mitral valve cusps are **dae**
tendineae can cause insu
secondary MR by favoring

Treatment with diuretics to

(Choice A) Calcification c e.
It is usually an incidental f

(Choice B) Increased flo
and best heard at the righ

(Choice C) Chordae tenc sue
disease (eg, Marfan syndr
repair is typically required

(Choice E) Thickened an a
murmur does not resolve
diastolic rumble) is more li

Educational objective:
Decompensated heart failure is a common cause of secondary (functional) mitral valve regurgitation. Increased left ventricular end-diastolic volume causes dilation of the mitral valve annulus and restricted movement of the chordae tendineae with subsequent regurgitation. Treatment

tendineae can cause insufficient closure of an intrinsically normal mitral valve, resulting in MR. Systemic hypertension can also contribute to secondary MR by favoring relatively lower-resistance regurgitant flow.

Treatment with diuretics to reduce LVEDV and vasodilators to reduce blood pressure can lead to resolution of heart failure-induced MR.

(Choice A) Calcification of the mitral valve annulus may occur with aging, and can be accelerated by hypertension or advanced kidney disease. It is usually an incidental finding that does not affect mitral valve function.

(Choice B) Increased flow velocity through the aortic valve occurs with aortic valve stenosis. The resulting murmur is crescendo-decrescendo and best heard at the right second intercostal space (rather than holosystolic and best heard at the apex).

(Choice C) Chordae tendineae rupture is a potential cause of primary MR that can occur in the setting of bacterial endocarditis, connective tissue disease (eg, Marfan syndrome), or acute myocardial infarction. The resulting murmur does not resolve with diuretics and vasodilators; surgical repair is typically required.

(Choice E) Thickened and deformed mitral valve cusps can occur in rheumatic heart disease and are a potential cause of primary MR. Such a murmur does not resolve with treatment of decompensated heart failure. In addition, mitral stenosis (evidenced by an opening snap and mid-diastolic rumble) is more likely than MR to occur with rheumatic heart disease.

Educational objective:
Decompensated heart failure is a common cause of secondary (functional) mitral valve regurgitation. Increased left ventricular end-diastolic volume causes dilation of the mitral valve annulus and restricted movement of the chordae tendineae with subsequent regurgitation. Treatment with diuretics and vasodilators can improve heart failure-induced MR.

References

- Functional mitral regurgitation.

Pathophysiology	Cardiovascular System	Mitral regurgitation
Subject	System	Topic

Copyright © UWorld. All rights reserved.

A 66-year-old man with diabetes mellitus is brought to the hospital due to sudden-onset chest pain and nausea. Blood pressure is 70/60 mm Hg and pulse is 60/min. Lungs are clear on auscultation. ECG shows ST-segment elevation in leads II, III, and aVF. Chest x-ray is unremarkable. The patient is diagnosed with an inferior wall myocardial infarction. Emergent cardiac catheterization reveals complete occlusion of the proximal right coronary artery. He is persistently hypotensive in the cardiac catheterization laboratory. Which of the following hemodynamic findings is most likely to be observed in this patient?

	Cardiac output	Pulmonary capillary wedge pressure	Central venous pressure
A.	↓	↓	↑
B.	↓	↑	↑
C.	↑	↑	↓
D.	↓	↑	↓
E.	↑	↓	↓

Submit

A 66-year-old man with diabetes mellitus is brought to the hospital due to sudden-onset chest pain and nausea. Blood pressure is 70/60 mm Hg and pulse is 60/min. Lungs are clear on auscultation. ECG shows ST-segment elevation in leads II, III, and aVF. Chest x-ray is unremarkable. The patient is diagnosed with an inferior wall myocardial infarction. Emergent cardiac catheterization reveals complete occlusion of the proximal right coronary artery. He is persistently hypotensive in the cardiac catheterization laboratory. Which of the following hemodynamic findings is most likely to be observed in this patient?

	Cardiac output	Pulmonary capillary wedge pressure	Central venous pressure
✓ A. (39%)	↓	↓	↑
B. (40%)	↓	↑	↑
C. (1%)	↑	↑	↓
D. (17%)	↓	↑	↓
E. (1%)	↑	↓	↓

Omitted
Correct answer
A

39%
Answered correctly

02 secs
Time Spent

02/22/2020
Last Updated

Explanation

Explanation

This patient is in cardiogenic shock after suffering an **inferior wall myocardial infarction**. The inferior wall of the left ventricle (LV) is supplied by the posterior descending artery, which arises off the dominant right coronary artery. Because the right coronary artery also gives off marginal branches that supply most of the right ventricle (RV), inferior wall myocardial infarction is often associated with **right ventricular infarction**. Right-sided heart failure typically presents with hypotension and distended jugular veins, but the lungs are clear unless significant left-sided heart failure is also present. This patient's **lack of crackles** on lung auscultation and **absence of pulmonary edema** on chest x-ray is indicative of **isolated RV dysfunction**.

Right ventricular infarction decreases RV stroke volume, which in turn leads to **diminished** LV filling and **cardiac output** despite preserved LV systolic function, resulting in hypotension and shock. Because left-sided filling pressures are reduced, **pulmonary capillary wedge pressure** (PCWP) also **decreases** as it reflects left atrial pressure. In addition, patients have **elevated central venous pressure** due to impaired forward flow and backup of blood into the systemic venous system.

(Choices B and D) LV anterior wall infarcts (eg, due to left anterior descending artery occlusion) are more likely than inferior wall infarcts to cause LV systolic dysfunction, resulting in decreased cardiac output, elevated left-sided filling pressures (eg, increased PCWP), and cardiogenic pulmonary edema. Initially, central venous pressure may be normal; however, persistently high left-sided pressures may lead to right-sided heart failure, resulting in elevated central venous pressure.

(Choice E) Increased cardiac output with decreased PCWP and central venous pressure is characteristic of distributive shock due to sepsis.

Educational objective:
The dominant right coronary artery perfuses both the inferior wall of the left ventricle and the majority of the right ventricle. Proximal occlusion can cause right ventricular myocardial infarction, which presents with hypotension (reduced cardiac output) and distended jugular veins (elevated central venous pressures). The lungs will be clear on auscultation and x-ray (lack of pulmonary edema) unless concomitant left-sided heart failure is also present.

References

- Acute right ventricular infarction.
- Right ventricular myocardial infarction: from pathophysiology to prognosis.

Explanation

Exhibit Display

Right dominant coronary artery circulation

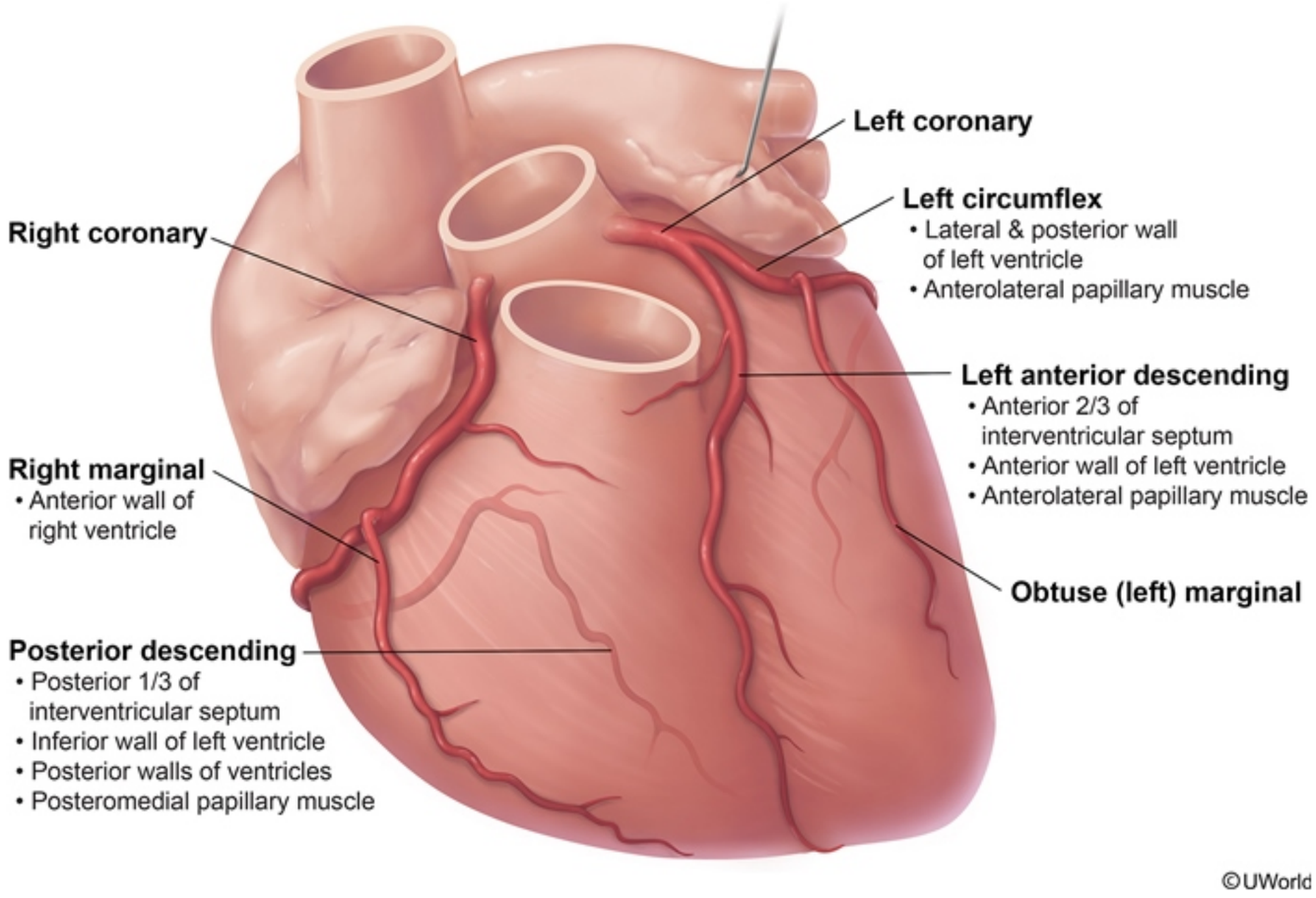

Zoom In | Zoom Out | Reset | Add To New Card | Existing Card

This item has associated media that may require the use of headphones. Please ensure your system/speaker volume is set to an audible level.

An 11-year-old boy is brought to the office for a routine checkup prior to enrollment at summer camp. The patient and his mother report no health concerns. Family history is significant for his father passing away suddenly from heart problems 2 years ago. The patient is in the 75th and 80th percentiles for height and weight, respectively. Vital signs are normal. Physical examination shows a well-appearing child. The lungs are clear to auscultation. Cardiac auscultation findings at the lower left sternal border are provided in the media exhibit. The auscultatory abnormality intensifies with the handgrip exercise. Which of the following is the most likely diagnosis?

Play Media

A. Aortic regurgitation
B. Aortic stenosis
C. Atrial septal defect
D. Hypertrophic cardiomyopathy
E. Patent ductus arteriosus
F. Ventricular septal defect

Submit

This item has associated media that may require the use of headphones. Please ensure your system/speaker volume is set to an audible level.

An 11-year-old boy is brought to the office for a routine checkup prior to enrollment at summer camp. The patient and his mother report no health concerns. Family history is significant for his father passing away suddenly from heart problems 2 years ago. The patient is in the 75th and 80th percentiles for height and weight, respectively. Vital signs are normal. Physical examination shows a well-appearing child. The lungs are clear to auscultation. Cardiac auscultation findings at the lower left sternal border are provided in the media exhibit. The auscultatory abnormality intensifies with the handgrip exercise. Which of the following is the most likely diagnosis?

Play Media

A. Aortic regurgitation (12%)
B. Aortic stenosis (6%)
C. Atrial septal defect (3%)
D. Hypertrophic cardiomyopathy (23%)
E. Patent ductus arteriosus (7%)
✓ F. Ventricular septal defect (46%)

Omitted
Correct answer
F

46%
Answered correctly

02 secs
Time Spent

01/27/2020
Last Updated

Explanation

Auscultation of murmurs			
Maneuver	**Change in cardiac parameters**	**Murmurs that increase**	**Murmurs that decrease**
Inspiration	↑ Venous return to right heart ↓ Venous return to left heart	Most right-sided murmurs	Most left-sided murmurs
Valsalva strain phase	↓ Preload	MVP & HCM (↓ LV volume)	Most other murmurs (↓ flow through stenotic or regurgitant valve)
Abrupt standing			
Squatting	↑ Preload ↑ Afterload	Most other murmurs (↑ flow through stenotic or regurgitant valve)	MVP & HCM (↑ LV volume)
Passive leg raise	↑ Preload		
Handgrip	↑ Afterload	AR, MR & VSD (↑ LV & aortic pressure)	HCM (↑ LV volume) AS (↓ transvalvular pressure gradient)

AR = aortic regurgitation; **AS** = aortic stenosis; **HCM** = hypertrophic cardiomyopathy; **LV** = left ventricular; **MR** = mitral regurgitation; **MVP** = mitral valve prolapse; **VSD** = ventricular septal defect.

The presentation of a **ventricular septal defect** (VSD) depends on its size. Large defects result in high-volume shunting of blood across the VSD, leading to a low interventricular pressure gradient and a soft or absent murmur. Excess blood flow may produce symptoms of heart failure in infancy (eg, difficulty feeding, tachypnea, failure to thrive). In contrast, **small defects** allow only a small amount of blood to flow across the VSD:

The presentation of a **ventricular septal defect** (VSD) depends on its size. Large defects result in high-volume shunting of blood across the VSD, leading to a low interventricular pressure gradient and a soft or absent murmur. Excess blood flow may produce symptoms of heart failure in infancy (eg, difficulty feeding, tachypnea, failure to thrive). In contrast, **small defects** allow only a small amount of blood to flow across the VSD; most patients are **asymptomatic** and have **loud murmurs** that are detected incidentally on auscultation.

In this asymptomatic patient, a harsh holosystolic murmur heard at the mid to lower **left sternal border** is indicative of blood flow through a small, hemodynamically insignificant VSD. The **handgrip maneuver** increases systemic vascular resistance and therefore increases afterload. This impedance to forward flow of blood causes increased flow from left to right across the VSD, resulting in **murmur accentuation**. A normal chest x-ray, ECG, and precordial activity (ie, no right ventricular heave or displaced point of maximum impulse) are expected due to the hemodynamic insignificance.

(Choice A) Aortic regurgitation results in an early diastolic murmur that is best heard along the left sternal border when due to valvular disease. Although this murmur is accentuated by maneuvers that increase afterload (eg, handgrip), the murmur heard in the audio clip is a systolic murmur.

(Choice B) Aortic stenosis results in a systolic crescendo-decrescendo murmur best heard at the base of the heart with radiation to the neck. The murmur of aortic stenosis *decreases* with the handgrip exercise due to increased afterload decreasing the transvalvular gradient.

(Choice C) An atrial septal defect can cause a wide, fixed-split S2 and a systolic ejection murmur that is best heard at the upper left sternal border due to increased flow across the pulmonic valve.

(Choice D) Hypertrophic cardiomyopathy causes a systolic ejection murmur best heard at the lower left sternal border. However, the handgrip maneuver *decreases murmur intensity* due to reduced outflow tract obstruction. Although hypertrophic cardiomyopathy can cause sudden cardiac death, this patient's family history of sudden cardiac death is likely coincidental (ie, probably due to acute coronary syndrome).

(Choice E) A patent ductus arteriosus produces a continuous flow murmur best heard in the left subclavicular region. The ductus normally closes after birth to form the ligamentum arteriosum.

Educational objective:
A ventricular septal defect (VSD) is associated with a low-pitched, holosystolic murmur at the mid to lower left sternal border. It accentuates during maneuvers that increase afterload (eg, handgrip maneuver). A small VSD is usually asymptomatic and produces a louder murmur due to higher interventricular pressure gradient.

1
2
3
4
5
6
7
8
9
10
11
12
13
14
15
16
17
18
19
20
21
22
23
24
25
26
27
28
29
30
31

Exhibit Display

Ventricular septal defect

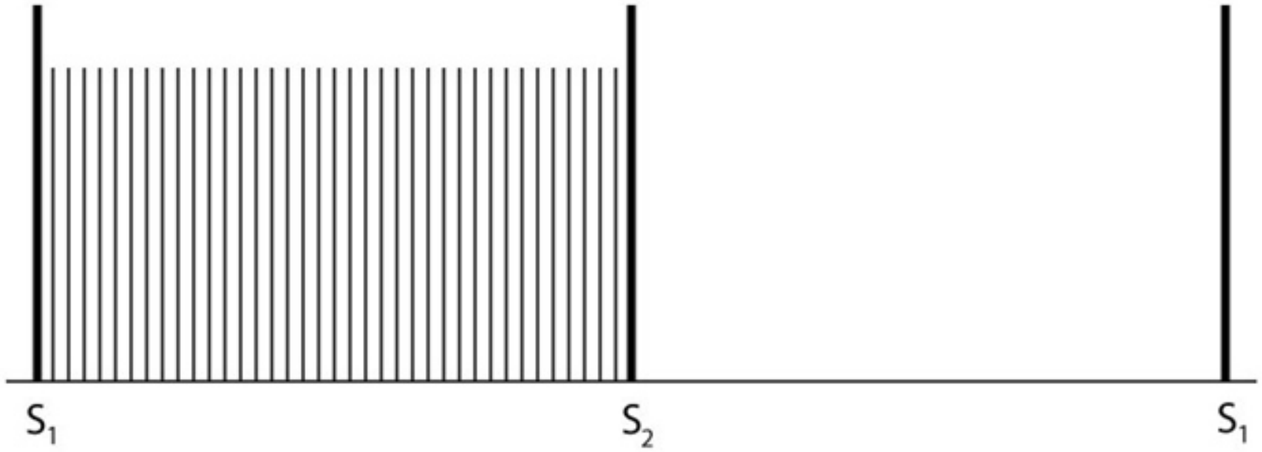

©UWorld

Zoom In | Zoom Out | Reset | Add To New Card | Existing Card

higher interventricular pressure gradient.

1 2 3 4 5 6 7 8 9 10 11 12 13 14 15 16 17 18 19 20 21 22 23 24 25 26 27 28 29 30 31

Exhibit Display

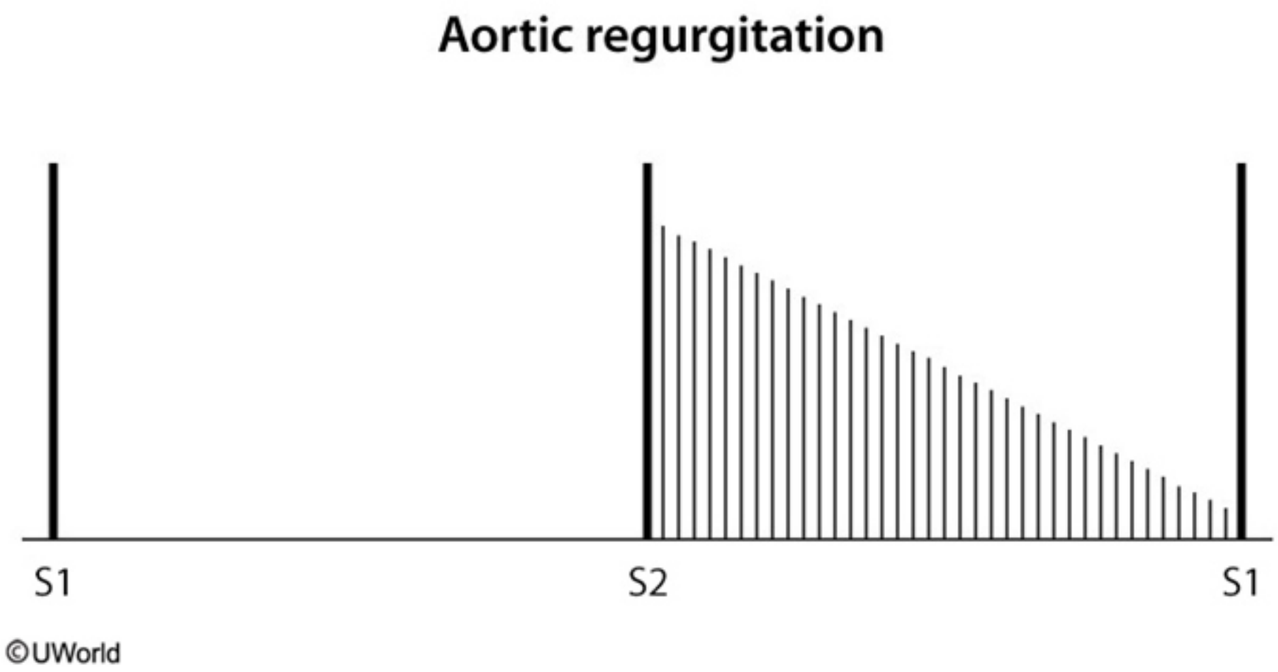

Zoom In | Zoom Out | Reset | Add To New Card | Existing Card

higher interventricular pressure gradient.

1 2 3 4 5 6 7 8 9 10 11 12 13 14 15 16 17 18 19 20 21 22 23 24 25 26 27 28 29 30 31

Exhibit Display

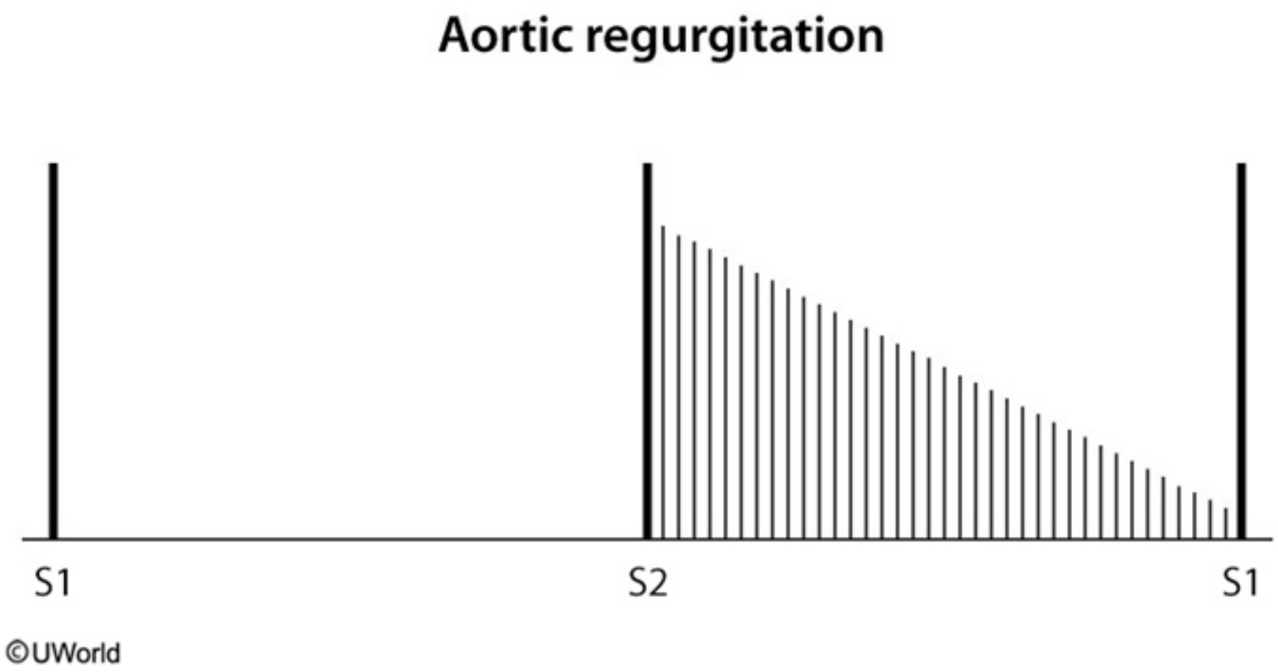

Zoom In | Zoom Out | Reset | Add To New Card | Existing Card

higher interventricular pressure gradient.

1 2 3 4 5 6 7 8 9 10 11 12 13 14 15 16 17 18 19 20 21 22 23 24 25 26 27 28 29 30 31

Exhibit Display

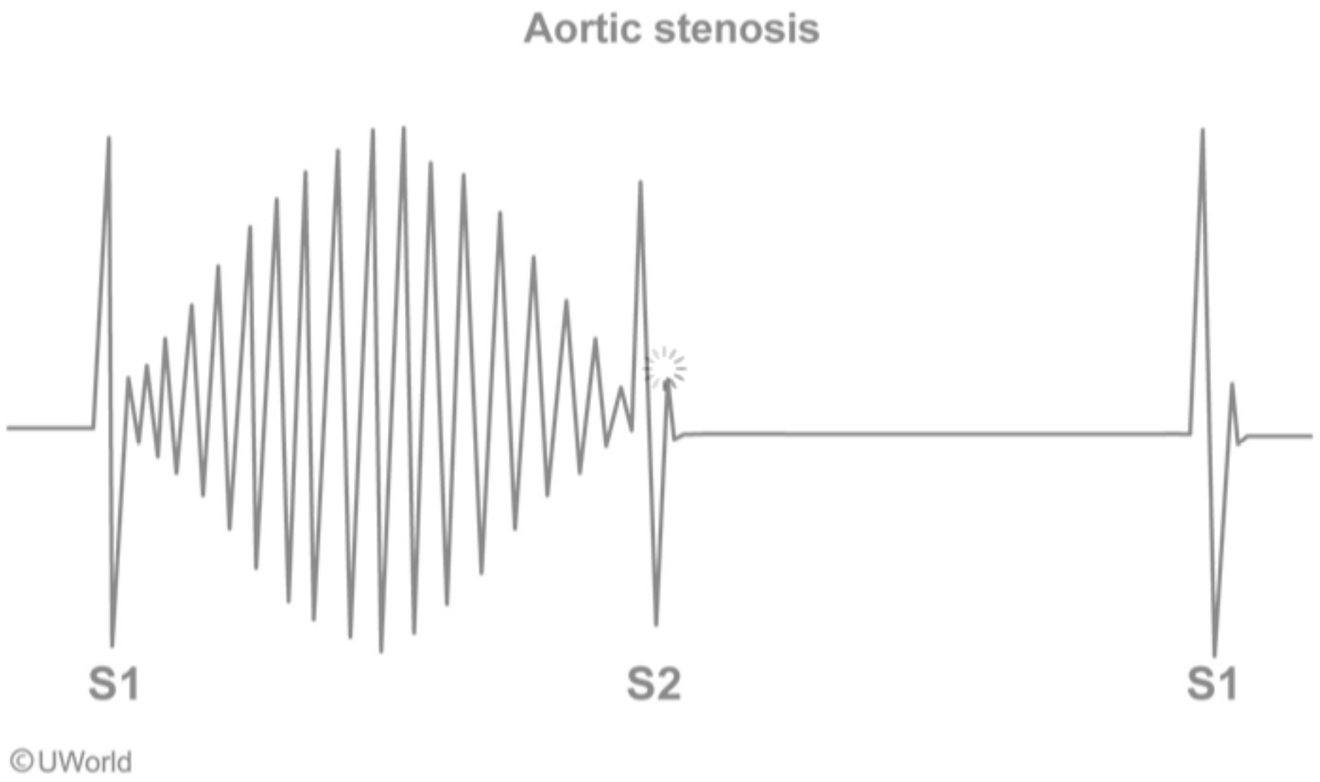

Zoom In | Zoom Out | Reset | Add To New Card | Existing Card

higher interventricular pressure gradient.

1 2 3 4 5 6 7 8 9 10 11 12 13 14 15 16 17 18 19 20 21 22 23 24 25 26 27 28 29 30 31

Exhibit Display

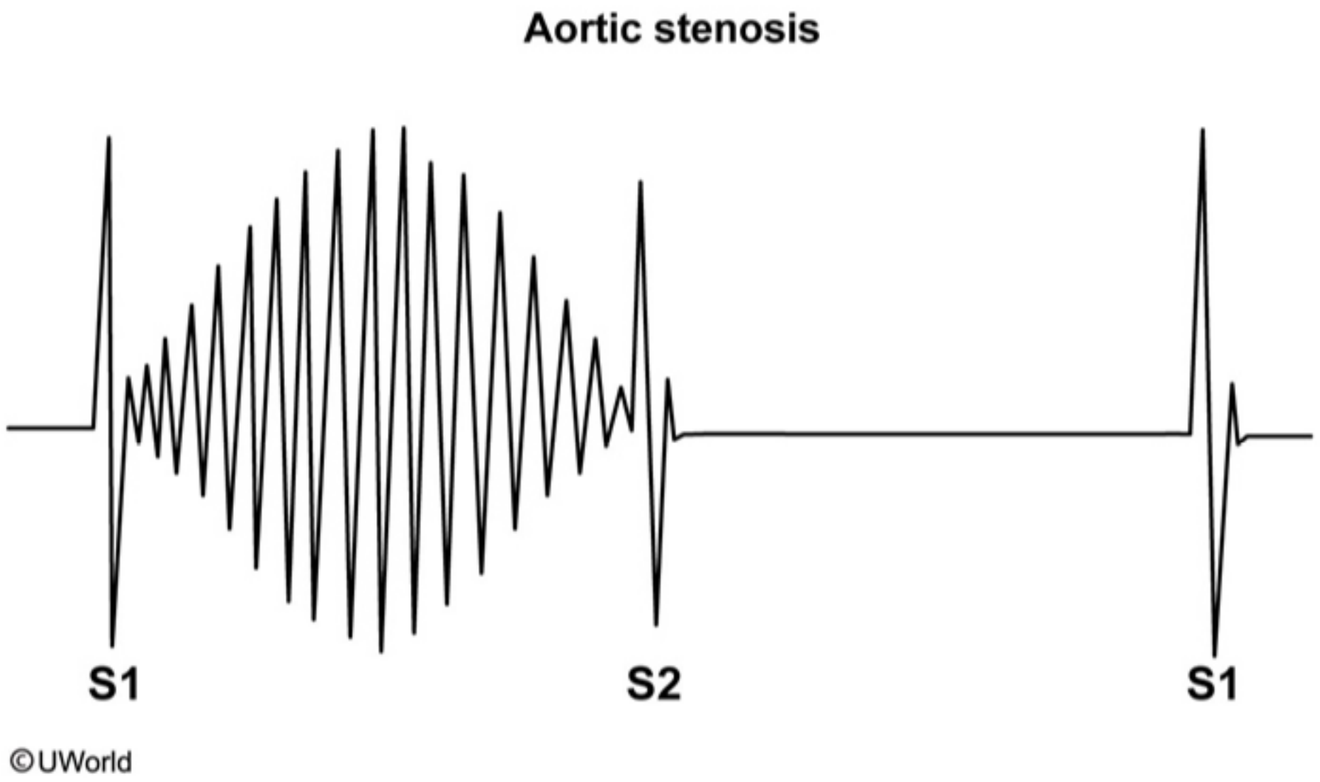

Zoom In Zoom Out Reset Add To New Card | Existing Card

higher interventricular pressure gradient.

1
2
3
4
5
6
7
8
9
10
11
12
13
14
15
16
17
18
19
20
21
22
23
24
25
26
27
28
29
30
31

Exhibit Display

Atrial septal defect

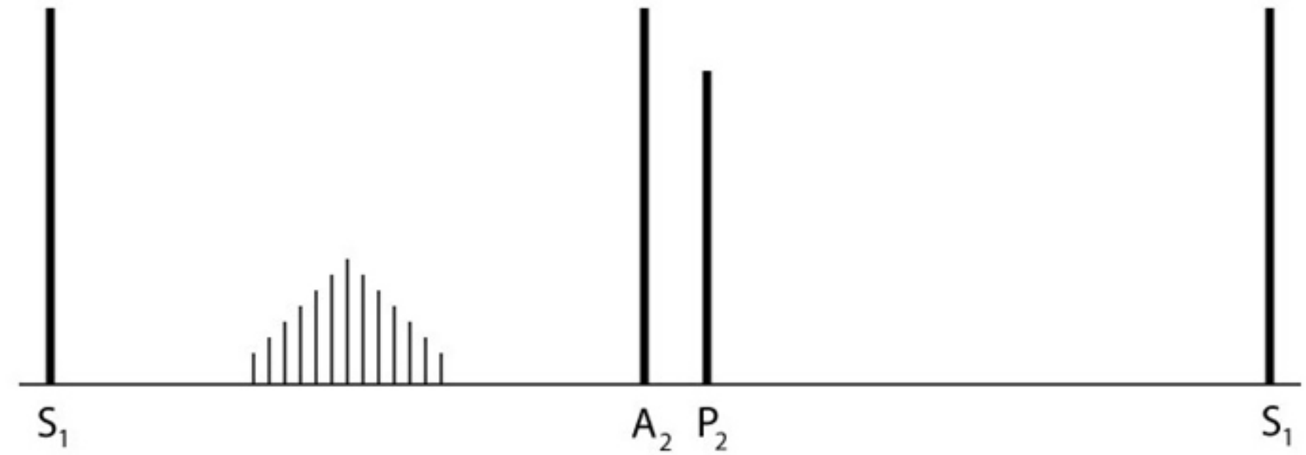

© USMLEWorld, LLC

Zoom In | Zoom Out | Reset | Add To New Card | Existing Card

higher interventricular pressure gradient.

1
2
3
4
5
6
7
8
9
10
11
12
13
14
15
16
17
18
19
20
21
22
23
24
25
26
27
28
29
30
31

Exhibit Display

Atrial septal defect

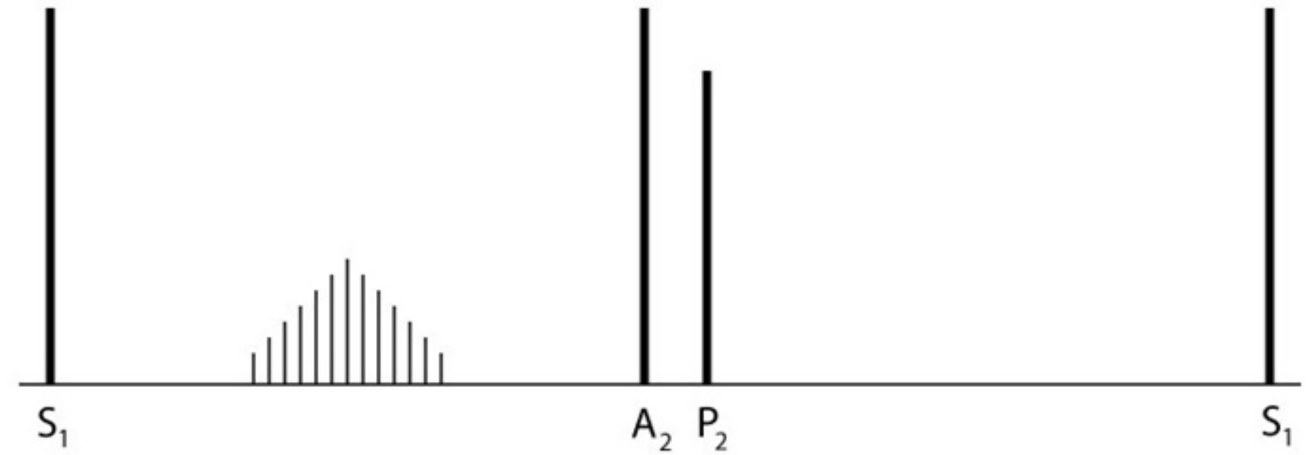

© USMLEWorld, LLC

Zoom In | Zoom Out | Reset | Add To New Card | Existing Card

higher interventricular pressure gradient.

1
2
3
4
5
6
7
8
9
10
11
12
13
14
15
16
17
18
19
20
21
22
23
24
25
26
27
28
29
30
31

Exhibit Display

Atrial septal defect

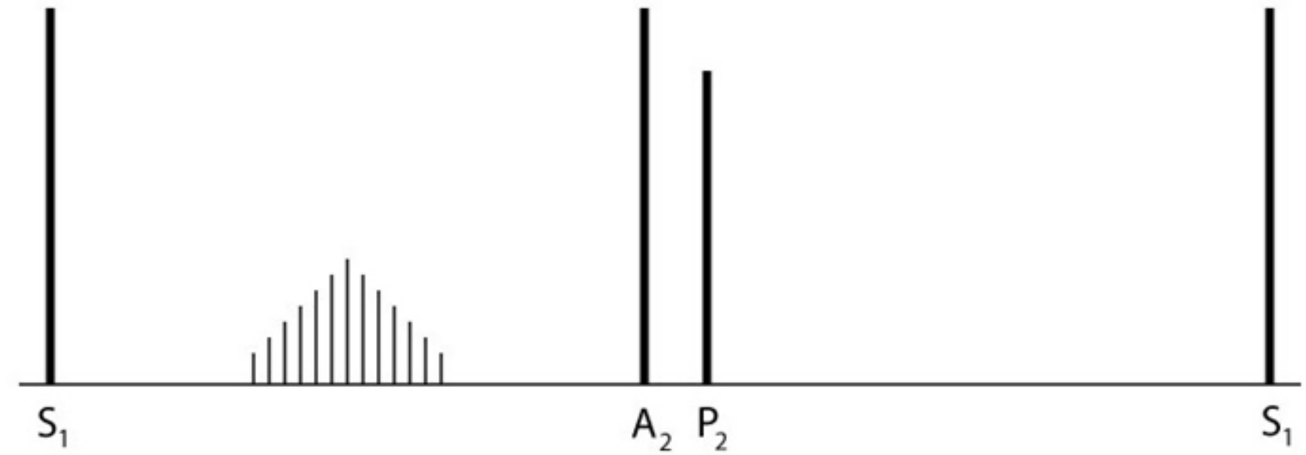

© USMLEWorld, LLC

Zoom In | Zoom Out | Reset | Add To New Card | Existing Card

higher interventricular pressure gradient.

1
2
3
4
5
6
7
8
9
10
11
12
13
14
15
16
17
18
19
20
21
22
23
24
25
26
27
28
29
30
31

Exhibit Display

Patent ductus arteriosis

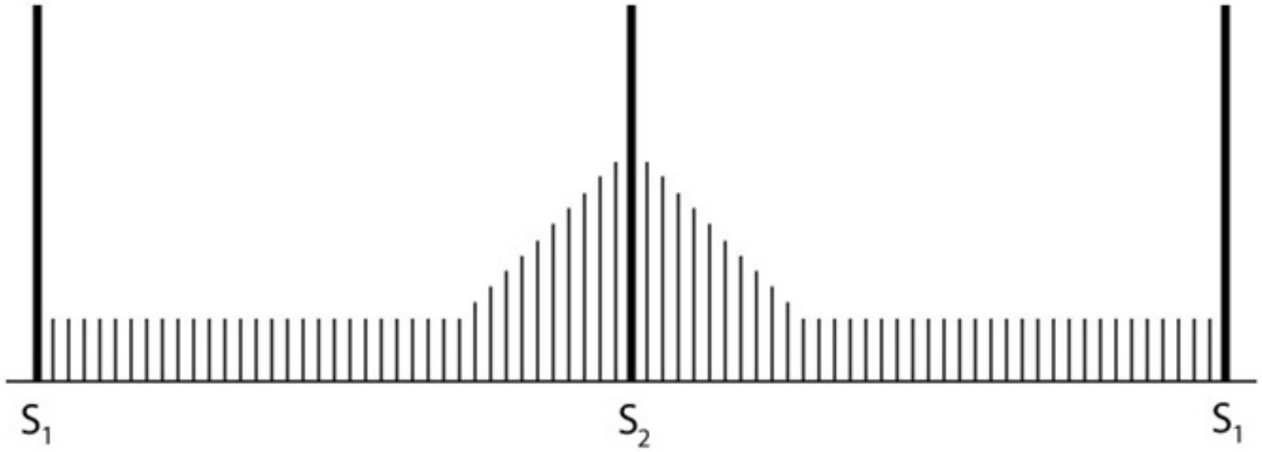

© USMLEWorld, LLC

Zoom In | Zoom Out | Reset | Add To New Card | Existing Card

higher interventricular pressure gradient.

ray, ECG, and precordial activity (ie, no right ventricular heave or displaced point of maximum impulse) are expected due to the hemodynamic insignificance.

(Choice A) Aortic regurgitation results in an early diastolic murmur that is best heard along the left sternal border when due to valvular disease. Although this murmur is accentuated by maneuvers that increase afterload (eg, handgrip), the murmur heard in the audio clip is a systolic murmur.

(Choice B) Aortic stenosis results in a systolic crescendo-decrescendo murmur best heard at the base of the heart with radiation to the neck. The murmur of aortic stenosis *decreases* with the handgrip exercise due to increased afterload decreasing the transvalvular gradient.

(Choice C) An atrial septal defect can cause a wide, fixed-split S2 and a systolic ejection murmur that is best heard at the upper left sternal border due to increased flow across the pulmonic valve.

(Choice D) Hypertrophic cardiomyopathy causes a systolic ejection murmur best heard at the lower left sternal border. However, the handgrip maneuver *decreases murmur intensity* due to reduced outflow tract obstruction. Although hypertrophic cardiomyopathy can cause sudden cardiac death, this patient's family history of sudden cardiac death is likely coincidental (ie, probably due to acute coronary syndrome).

(Choice E) A patent ductus arteriosus produces a continuous flow murmur best heard in the left subclavicular region. The ductus normally closes after birth to form the ligamentum arteriosum.

Educational objective:
A ventricular septal defect (VSD) is associated with a low-pitched, holosystolic murmur at the mid to lower left sternal border. It accentuates during maneuvers that increase afterload (eg, handgrip maneuver). A small VSD is usually asymptomatic and produces a louder murmur due to higher interventricular pressure gradient.

References

- Evaluation and management of heart murmurs in children.

Pathophysiology	Cardiovascular System	Ventricular septal defect
Subject	System	Topic

Copyright © UWorld. All rights reserved.

1
2
3
4
5
6
7
8
9
10
11
12
13
14
15
16
17
18
19
20
21
22
23
24
25
26
27
28
29
30
31

A 33-year-old woman who recently immigrated to the United States is brought to the emergency department with severe shortness of breath and hemoptysis. Physical examination reveals a diastolic murmur. Chest x-ray shows severe pulmonary vascular congestion and edema. She is admitted to the hospital, treated with diuretics, and begins to feel better. However, during her hospitalization, she develops right-sided hemiparesis. Which of the following additional findings in this patient would be most suggestive of combined disease involving the mitral and aortic valves rather than exclusive mitral involvement?

- A. Increased left ventricular diastolic pressure
- B. Increased pulmonary artery pressure
- C. Increased pulmonary capillary wedge pressure
- D. Reduced pulmonary vascular compliance
- E. Right ventricular dilation
- F. Tricuspid regurgitation

Submit

1 2 3 4 5 6 7 8 9 10 11 12 13 14 15 16 17 18 19 20 21 22 23 24 25 26 27 28 29 30 31

A 33-year-old woman who recently immigrated to the United States is brought to the emergency department with severe shortness of breath and hemoptysis. Physical examination reveals a diastolic murmur. Chest x-ray shows severe pulmonary vascular congestion and edema. She is admitted to the hospital, treated with diuretics, and begins to feel better. However, during her hospitalization, she develops right-sided hemiparesis. Which of the following additional findings in this patient would be most suggestive of combined disease involving the mitral and aortic valves rather than exclusive mitral involvement?

- ✓ A. Increased left ventricular diastolic pressure (74%)
- B. Increased pulmonary artery pressure (3%)
- C. Increased pulmonary capillary wedge pressure (13%)
- D. Reduced pulmonary vascular compliance (2%)
- E. Right ventricular dilation (4%)
- F. Tricuspid regurgitation (1%)

Omitted
Correct answer
A

74%
Answered correctly

02 secs
Time Spent

04/08/2020
Last Updated

Explanation

Hemodynamic consequences of mitral stenosis

Stenotic mitral valve

1
2
3
4
5
6
7
8
9
10
11
12
13
14
15
16
17
18
19
20
21
22
23
24
25
26
27
28
29
30
31

Hemodynamic consequences of mitral stenosis

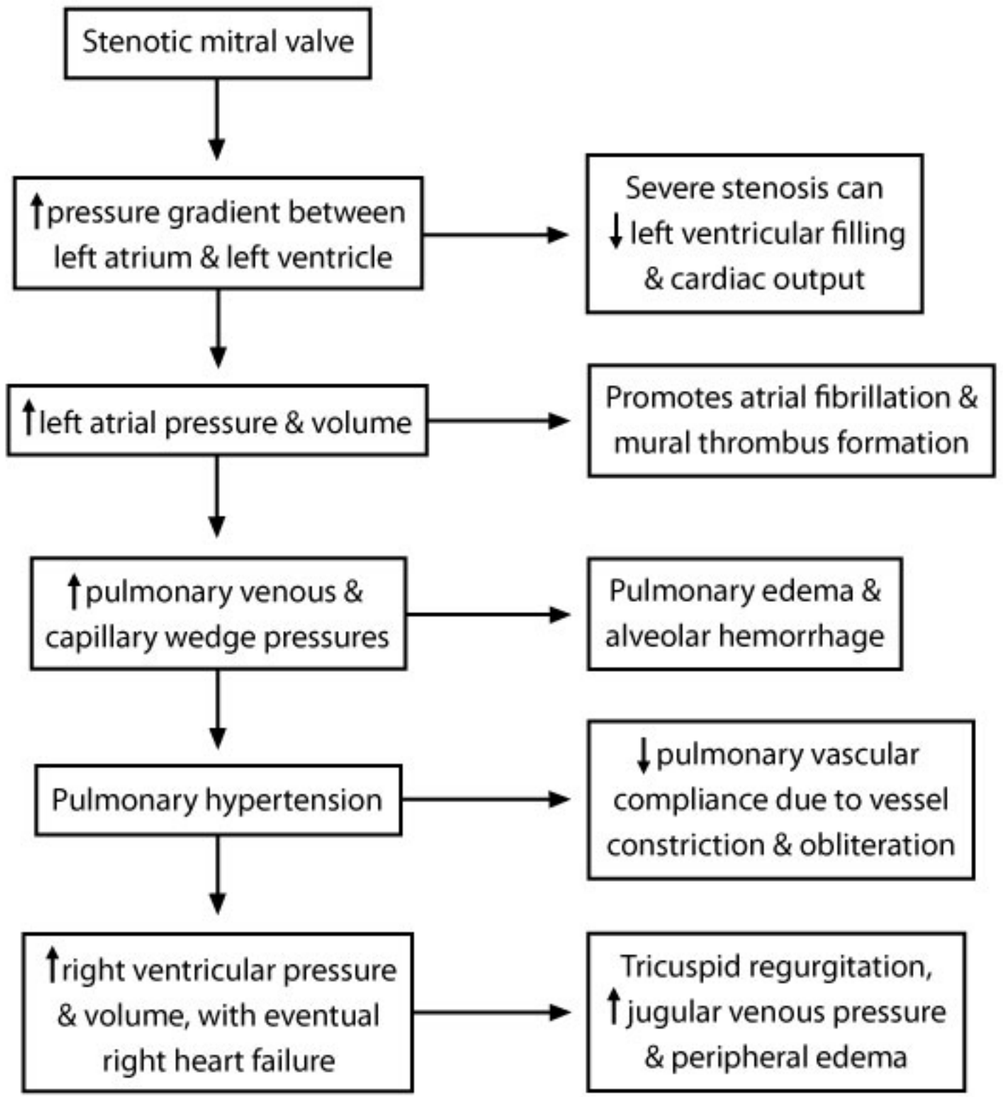

© USMLEWorld, LLC

This patient's physical examination findings are suggestive of **mitral stenosis** (MS). In isolated MS, cardiac and pulmonary pressures proximal to the stenotic mitral valve are markedly elevated. However, diastolic pressure in the left ventricle (LV) is usually near normal or even decreased with severe stenosis. **Increased LV diastolic pressure** in a patient with MS suggests concomitant **aortic valve dysfunction**.

Rheumatic heart disease almost always affects the mitral valve, but both the mitral and aortic valves are affected in about 25% of cases. Aortic valve involvement typically involves combined aortic stenosis and regurgitation, both of which can increase LV diastolic pressure. Rheumatic deformation of the aortic valve can also predispose to infective endocarditis even when the valve is functionally normal. This patient's right-sided **hemiparesis** is most likely due to **embolism**, which could have originated from an atrial mural thrombus secondary to atrial dilation from MS or an endocarditis-related valvular vegetation (less likely).

(Choices B and D) Severe, isolated MS can cause increased pulmonary artery pressure (pulmonary hypertension) via backward transmission of elevated pulmonary capillary wedge pressure. Longstanding pulmonary hypertension can result in reduced pulmonary vascular compliance due to endothelial remodelling and capillary obliteration.

(Choice C) Pulmonary capillary wedge pressure (an estimate of left atrial pressure) will increase with any significant left-sided valvular pathology (ie, both isolated MS and combined aortic and mitral valve disease).

(Choices E and F) Right ventricular dilatation can occur in MS when the resulting pulmonary hypertension is severe enough to cause right heart failure. Tricuspid regurgitation can occur as a complication of right ventricular dilatation.

Educational objective:
Isolated mitral stenosis causes elevated upstream pressures in the left atrium and pulmonary veins and arteries. Left ventricular end diastolic pressure (LVEDP) is normal or decreased due to obstruction of blood flow through the stenotic valve. An elevated LVEDP suggests additional downstream pathology (eg, aortic valve disease, left ventricular failure).

Pathophysiology	Cardiovascular System	Mitral stenosis
Subject	System	Topic

Copyright © UWorld. All rights reserved.

The following vignette applies to the next **2** items. The items in the set must be answered in sequential order. Once you click **Proceed to Next Item**, you will not be able to add or change an answer.

A 34-year-old Russian immigrant comes to the physician with a 2-month history of exertional dyspnea and progressive lower extremity swelling. He also reports abdominal distension and decreased appetite. The patient has gained 4.5 kg (10 lbs) over the last 2 months. Past medical history is significant for hypertension and recurrent lung infections requiring prolonged antibiotic therapy. He has no history of coronary artery disease. The patient has smoked a pack of cigarettes daily for the past 15 years. He undergoes noninvasive cardiac testing followed by cardiac catheterization. A jugular venous pressure tracing is shown on the slide below.

Item 1 of 2

The waveform indicated by the arrow most likely corresponds to which of the following?

- A. Atrial contraction
- B. Carotid pulse upstroke
- C. Isovolumetric ventricular contraction
- D. Tricuspid valve closure
- E. Tricuspid valve opening

Submit

1
2
3
4
5
6
7
8
9
10
11
12
13
14
15
16
17
18
19
20
21
22
23
24
25
26
27
28
29
30
31

Exhibit Display

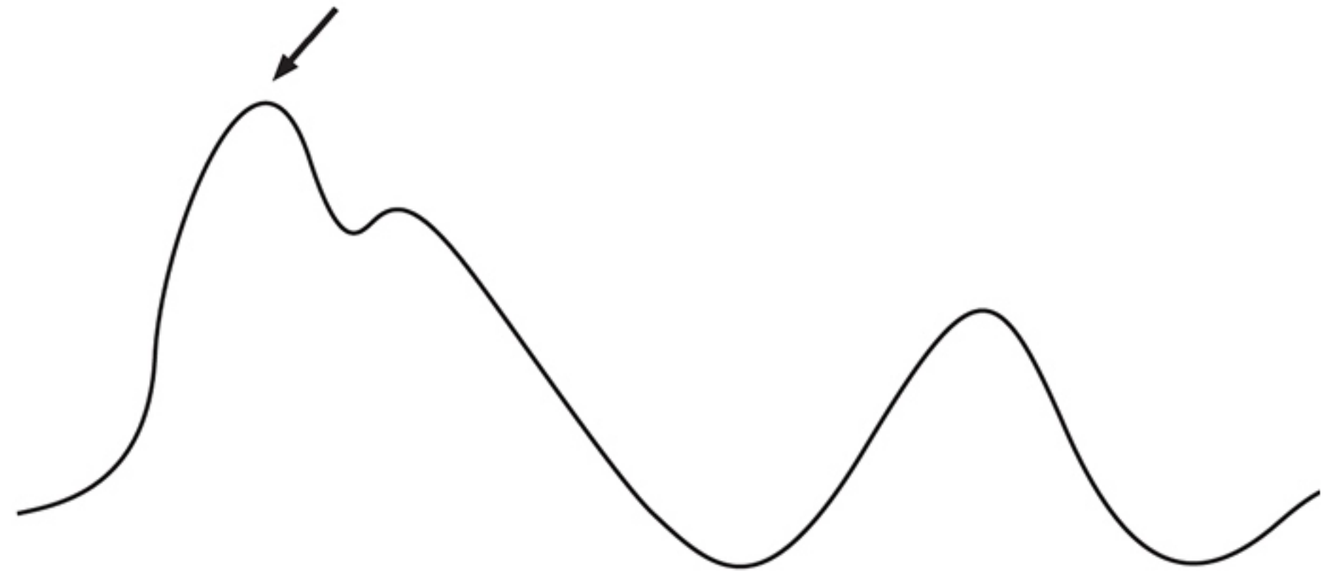

©UWorld

Zoom In Zoom Out Reset Add To New Card | Existing Card

1
2
3
4
5
6
7
8
9
10
11
12
13
14
15
16
17
18
19
20
21
22
23
24
25
26
27
28
29
30
31

The following vignette applies to the next **2** items. The items in the set must be answered in sequential order. Once you click **Proceed to Next Item**, you will not be able to add or change an answer.

A 34-year-old Russian immigrant comes to the physician with a 2-month history of exertional dyspnea and progressive lower extremity swelling. He also reports abdominal distension and decreased appetite. The patient has gained 4.5 kg (10 lbs) over the last 2 months. Past medical history is significant for hypertension and recurrent lung infections requiring prolonged antibiotic therapy. He has no history of coronary artery disease. The patient has smoked a pack of cigarettes daily for the past 15 years. He undergoes noninvasive cardiac testing followed by cardiac catheterization. A jugular venous pressure tracing is shown on the slide below.

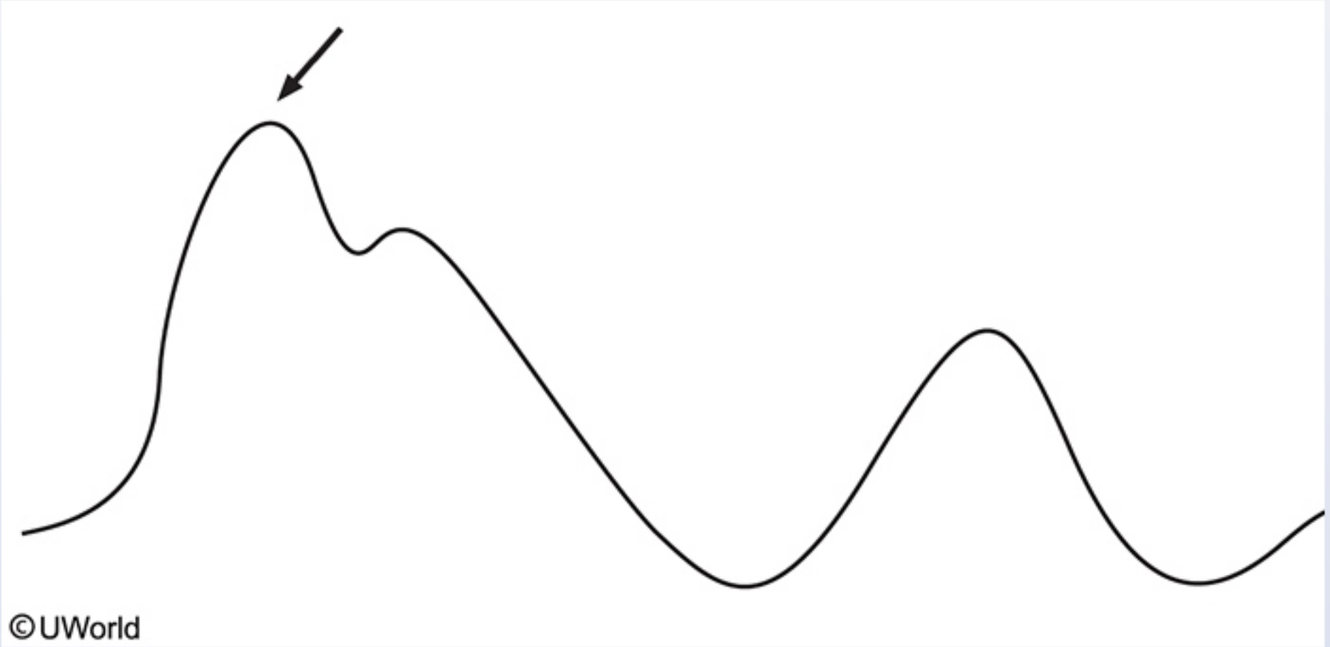

Item 1 of 2

The waveform indicated by the arrow most likely corresponds to which of the following?

1 2 3 4 5 6 7 8 9 10 11 12 13 14 15 16 17 18 19 20 21 22 23 24 25 26 27 28 29 30 31

Item 1 of 2

The waveform indicated by the arrow most likely corresponds to which of the following?

- ✓ A. Atrial contraction (72%)
- B. Carotid pulse upstroke (4%)
- C. Isovolumetric ventricular contraction (6%)
- D. Tricuspid valve closure (8%)
- E. Tricuspid valve opening (7%)

Omitted
Correct answer
A

72%
Answered correctly

02 secs
Time Spent

06/21/2020
Last Updated

Explanation



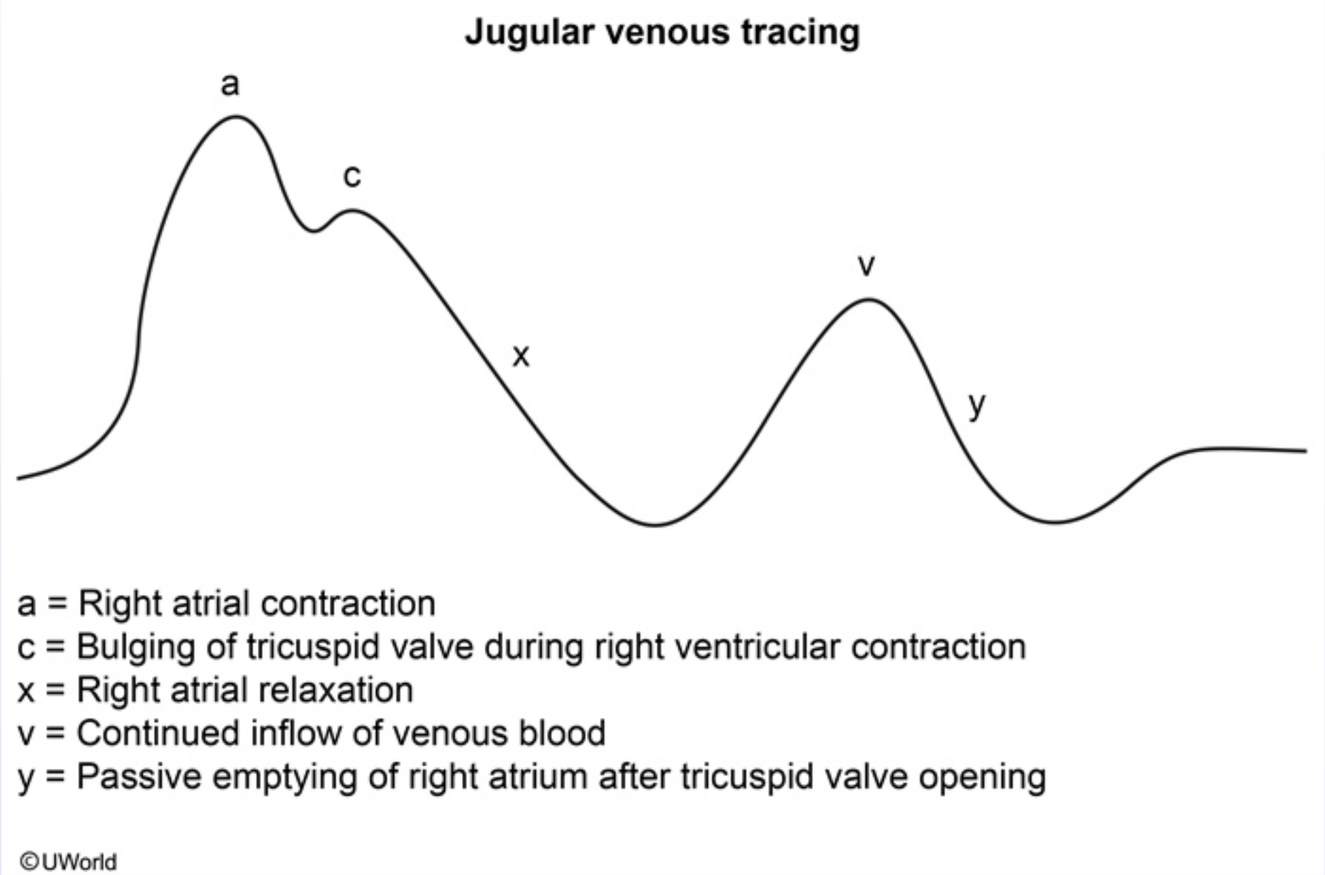

A normal jugular venous pulse wave tracing has 3 positive waves (a, c, and v) and 2 negative waves (x and y descent). The **a wave** (indicated by the arrow on the diagram above) is generated by **atrial contraction**, the c wave is caused by bulging of the tricuspid valve into the right atrium in early systole, and the v wave reflects the passive increase in pressure and volume of the right atrium as it fills in late systole and early diastole. The troughs of the jugular venous pulse are known as the x-descent and the y-descent. The x-descent is primarily caused by relaxation of the right atrium. The y-descent represents the abrupt decrease in right atrial pressure during early diastole after the tricuspid valve opens and the right ventricle begins to passively fill.

a = Right atrial contraction
c = Bulging of tricuspid valve during right ventricular contraction
x = Right atrial relaxation
v = Continued inflow of venous blood
y = Passive emptying of right atrium after tricuspid valve opening

©UWorld

A normal jugular venous pulse wave tracing has 3 positive waves (a, c, and v) and 2 negative waves (x and y descent). The **a wave** (indicated by the arrow on the diagram above) is generated by **atrial contraction**, the c wave is caused by bulging of the tricuspid valve into the right atrium in early systole, and the v wave reflects the passive increase in pressure and volume of the right atrium as it fills in late systole and early diastole. The troughs of the jugular venous pulse are known as the x-descent and the y-descent. The x-descent is primarily caused by relaxation of the right atrium. The y-descent represents the abrupt decrease in right atrial pressure during early diastole after the tricuspid valve opens and the right ventricle begins to passively fill.

Educational objective:
On jugular venous pressure tracings, the first peak is the a wave, which is generated by atrial contraction. This is notably absent in patients with atrial fibrillation.

Pathophysiology	Cardiovascular System	Hemodynamic monitoring
Subject	System	Topic

Copyright © UWorld. All rights reserved.

1
2
3
4
5
6
7
8
9
10
11
12
13
14
15
16
17
18
19
20
21
22
23
24
25
26
27
28
29
30
31

Item 2 of 2

The patient is admitted to the hospital for further workup and treatment. After initial evaluation, a CT scan of the chest is obtained, an image of which is shown on the slide below.

Which of the following is the most likely diagnosis?

A. Aortic dissection

B. Constrictive pericarditis

C. Hypertrophic cardiomyopathy

D. Ischemic heart disease

E. Viral myocarditis

Submit

1
2
3
4
5
6
7
8
9
10
11
12
13
14
15
16
17
18
19
20
21
22
23
24
25
26
27
28
29
30
31

Item 2 of 2

The patient is admitted to the hospital for further workup and treatment. After initial evaluation, a CT scan of the chest is obtained, an image of which is shown on the slide below.

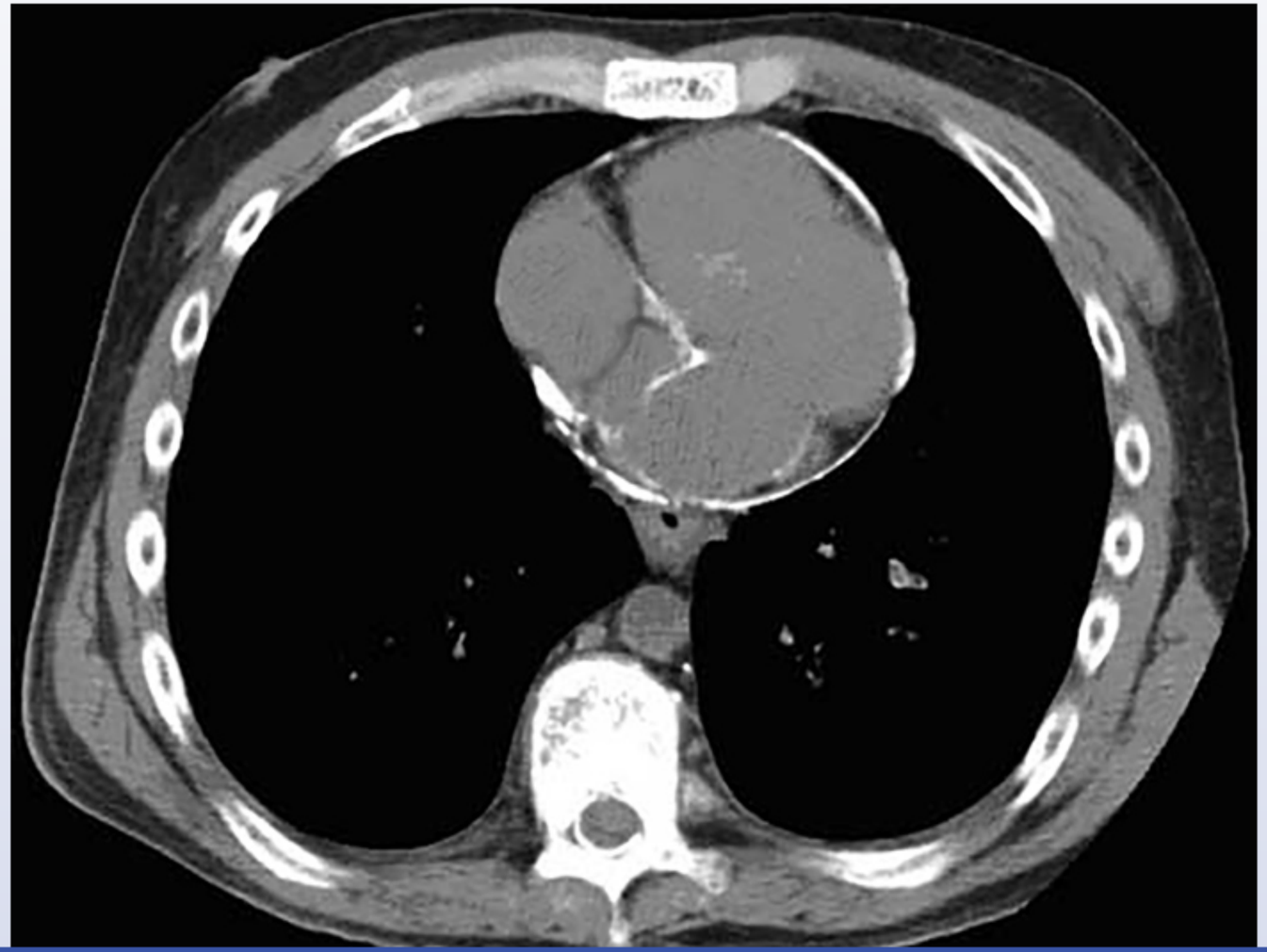

1
2
3
4
5
6
7
8
9
10
11
12
13
14
15
16
17
18
19
20
21
22
23
24
25
26
27
28
29
30
31

Which of the following is the most likely diagnosis?

- A. Aortic dissection
- B. Constrictive pericarditis
- C. Hypertrophic cardiomyopathy
- D. Ischemic heart disease
- E. Viral myocarditis

Submit

1
2
3
4
5
6
7
8
9
10
11
12
13
14
15
16
17
18
19
20
21
22
23
24
25
26
27
28
29
30
31

Which of the following is the most likely diagnosis?

- A. Aortic dissection (4%)
- ✓ B. Constrictive pericarditis (59%)
- C. Hypertrophic cardiomyopathy (27%)
- D. Ischemic heart disease (2%)
- E. Viral myocarditis (6%)

Omitted
Correct answer

59%
Answered correctly

07 secs
Time Spent

06/21/2020
Last Updated

1
2
3
4
5
6
7
8
9
10
11
12
13
14
15
16
17
18
19
20
21
22
23
24
25
26
27
28
29
30
31

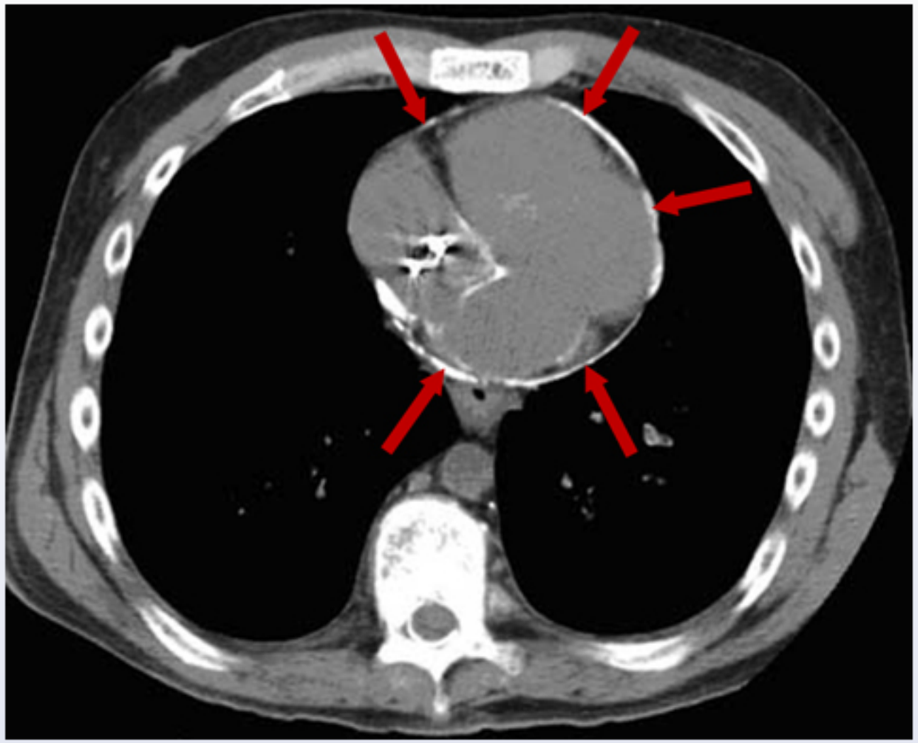

The above CT image shows thickening and calcification of the pericardium suggestive of constrictive pericarditis. Although the pericardium is normally only 1-2 mm thick, it can range in thickness from 4-20 mm in patients with constrictive pericarditis. Patients with this condition typically have slowly progressive dyspnea, chronic edema, and ascites. A rapid y-descent that becomes both deeper and steeper during inspiration is often observed on the jugular venous pressure tracing. Possible causes include radiation therapy to the chest, cardiac surgery, and tuberculosis (which is possibly the cause in this patient who is an immigrant from an endemic region).

(Choice A) An aortic dissection causes sudden chest pain that radiates to the back. Chest radiographs often show widening of the mediastinum, and a double aortic lumen would be seen on a CT scan of the chest.

(Choice C) Hypertrophic cardiomyopathy also presents with dyspnea and changes in the jugular venous pressure, specifically a prominent a wave. CT may show thickening of the interventricular septum but would not show thickening or calcification of the pericardium.

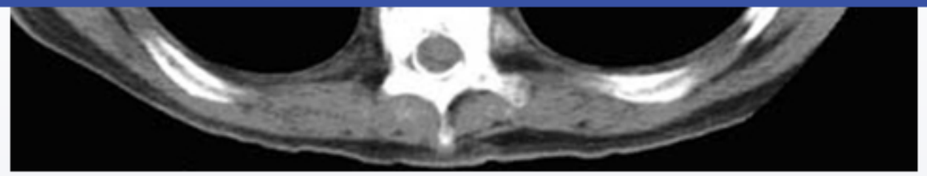

The above CT image shows thickening and calcification of the pericardium suggestive of constrictive pericarditis. Although the pericardium is normally only 1-2 mm thick, it can range in thickness from 4-20 mm in patients with constrictive pericarditis. Patients with this condition typically have slowly progressive dyspnea, chronic edema, and ascites. A rapid y-descent that becomes both deeper and steeper during inspiration is often observed on the jugular venous pressure tracing. Possible causes include radiation therapy to the chest, cardiac surgery, and tuberculosis (which is possibly the cause in this patient who is an immigrant from an endemic region).

(Choice A) An aortic dissection causes sudden chest pain that radiates to the back. Chest radiographs often show widening of the mediastinum, and a double aortic lumen would be seen on a CT scan of the chest.

(Choice C) Hypertrophic cardiomyopathy also presents with dyspnea and changes in the jugular venous pressure, specifically a prominent a wave. CT may show thickening of the interventricular septum but would not show thickening or calcification of the pericardium.

(Choice D) Ischemic heart disease classically causes pressure like substernal chest pain that radiates to the left shoulder, and calcifications in the coronary arteries and aorta are often seen on CT.

(Choice E) Patients with viral myocarditis have a variable clinical presentation ranging from asymptomatic to severe chest pain and cardiogenic shock. Pericardial thickening is not a feature of this condition.

Educational objective:
Calcification and thickening of the pericardium are common features of constrictive pericarditis on CT. Clinical findings include slowly progressive dyspnea, peripheral edema, and ascites.

Pathophysiology	Cardiovascular System	Constrictive pericarditis
Subject	System	Topic

Copyright © UWorld. All rights reserved.

1
2
3
4
5
6
7
8
9
10
11
12
13
14
15
16
17
18
19
20
21
22
23
24
25
26
27
28
29
30
31

Exhibit Display

Aortic dissection

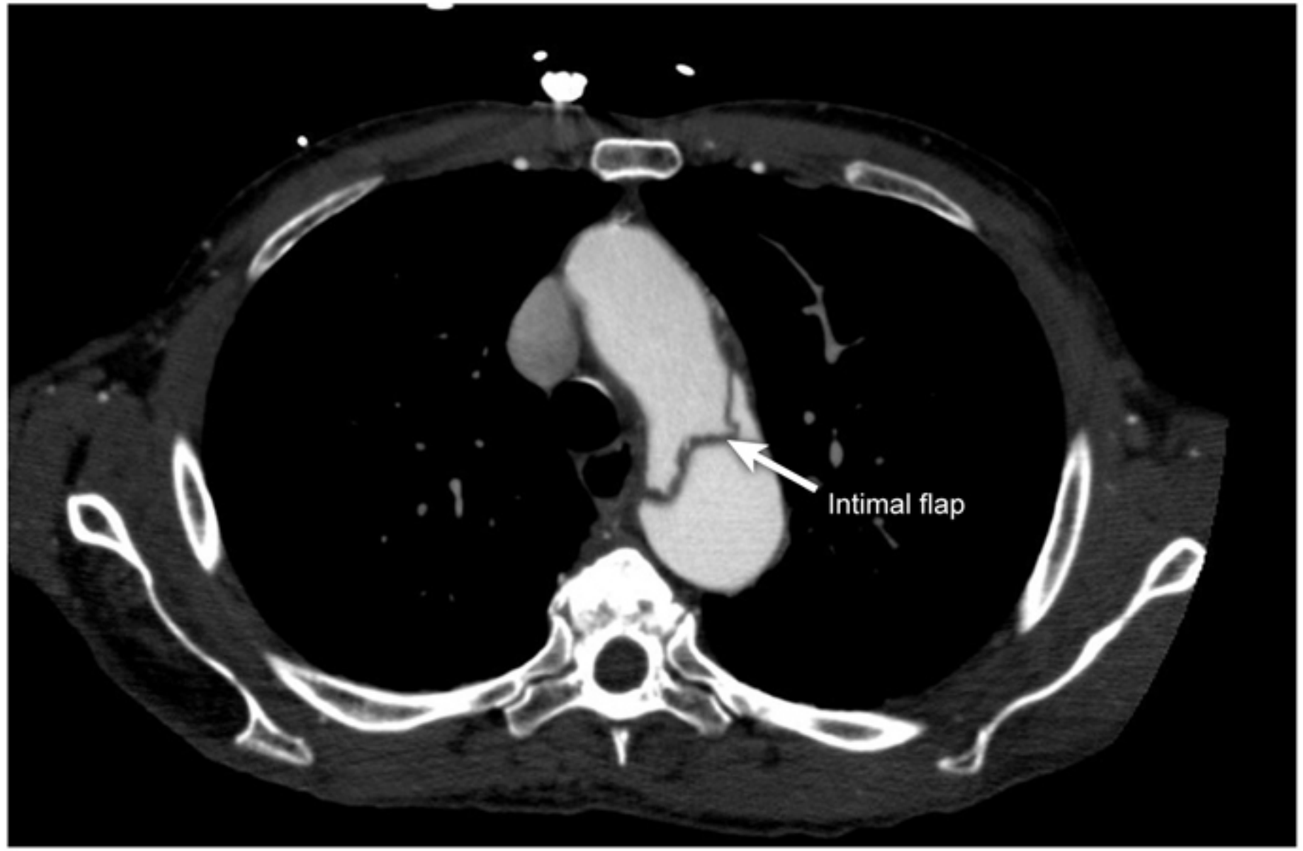

©UWorld

Zoom In | Zoom Out | Reset | Add To New Card | Existing Card

1
2
3
4
5
6
7
8
9
10
11
12
13
14
15
16
17
18
19
20
21
22
23
24
25
26
27
28
29
30
31

A 54-year-old woman comes to the office due to exertional dyspnea and fatigue. The patient gets short of breath while walking to a store 2 blocks away from her home. She also has trouble breathing at night and sleeps with 2 or 3 pillows to prop her up. She has had occasional palpitations but no chest pain. The patient takes no medications on a regular basis, and does not use tobacco, alcohol, or illicit drugs. After initial evaluation, she is scheduled for a left heart catheterization, the findings of which are shown below.

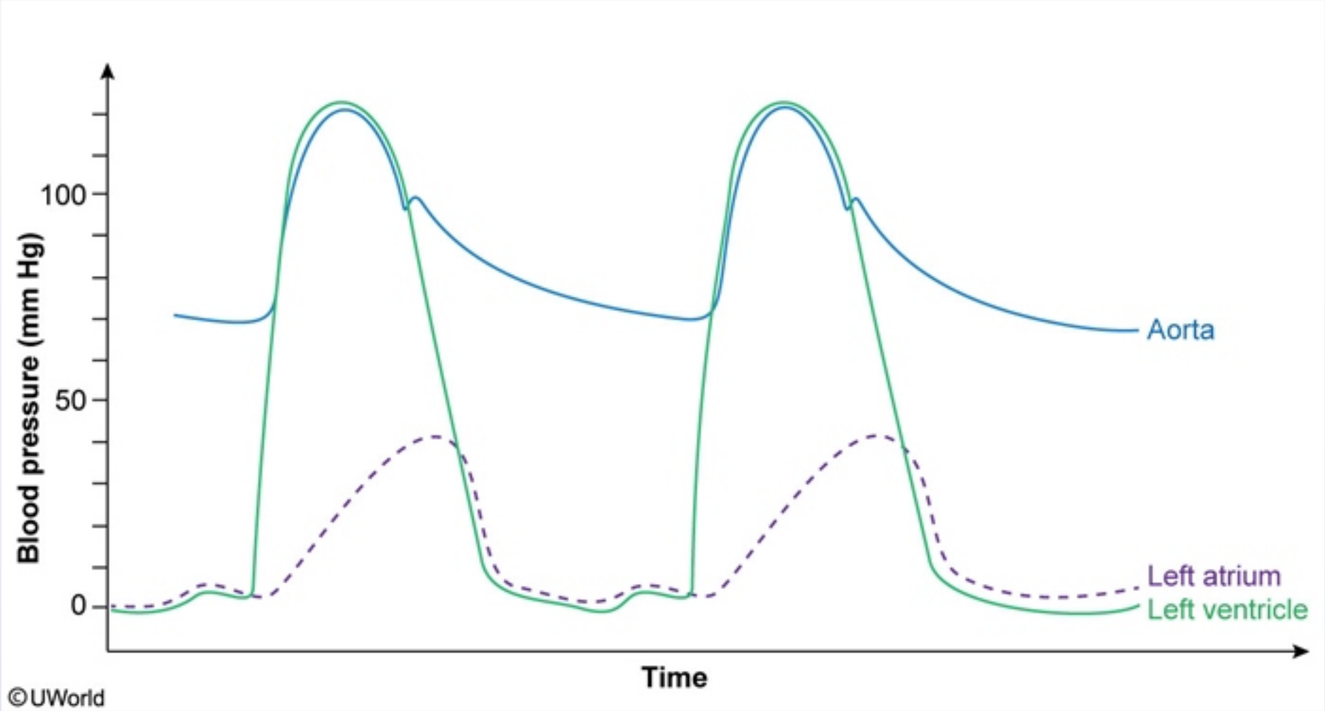

Which of the following is the most likely diagnosis?

A. Aortic regurgitation

B. Aortic stenosis

C. Mitral regurgitation

1
2
3
4
5
6
7
8
9
10
11
12
13
14
15
16
17
18
19
20
21
22
23
24
25
26
27
28
29
30
31

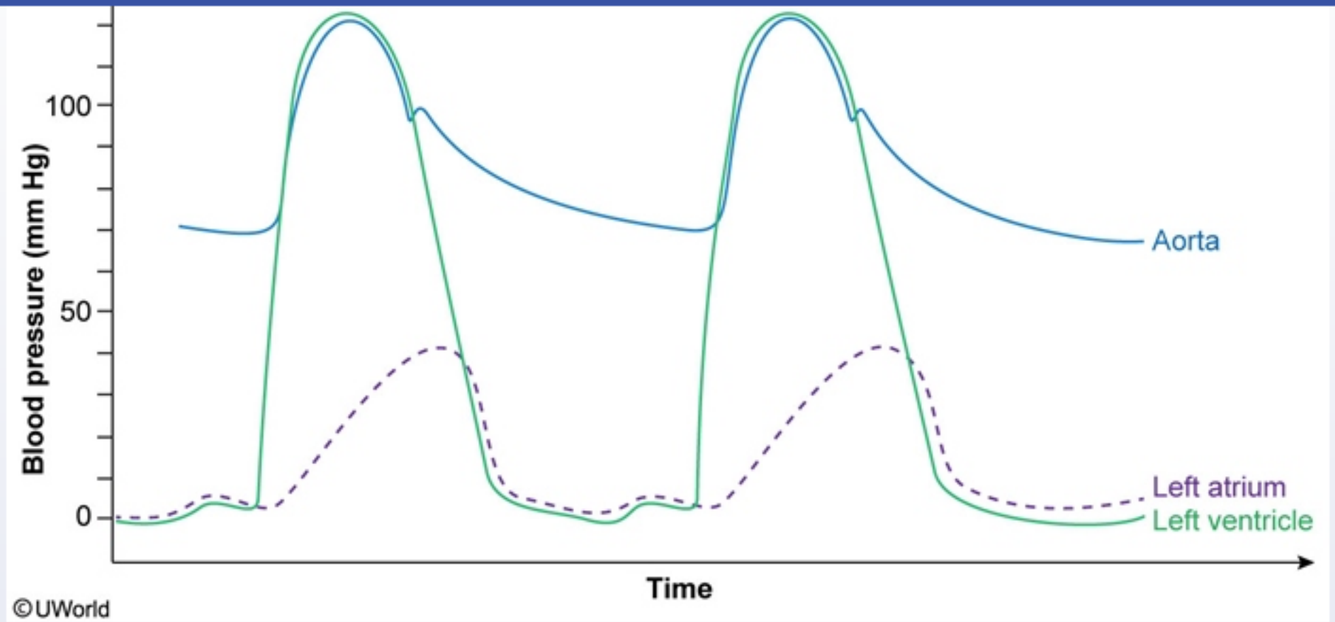

Which of the following is the most likely diagnosis?

- A. Aortic regurgitation
- B. Aortic stenosis
- C. Mitral regurgitation
- D. Mitral stenosis
- E. Tricuspid regurgitation

Submit

1
2
3
4
5
6
7
8
9
10
11
12
13
14
15
16
17
18
19
20
21
22
23
24
25
26
27
28
29
30
31

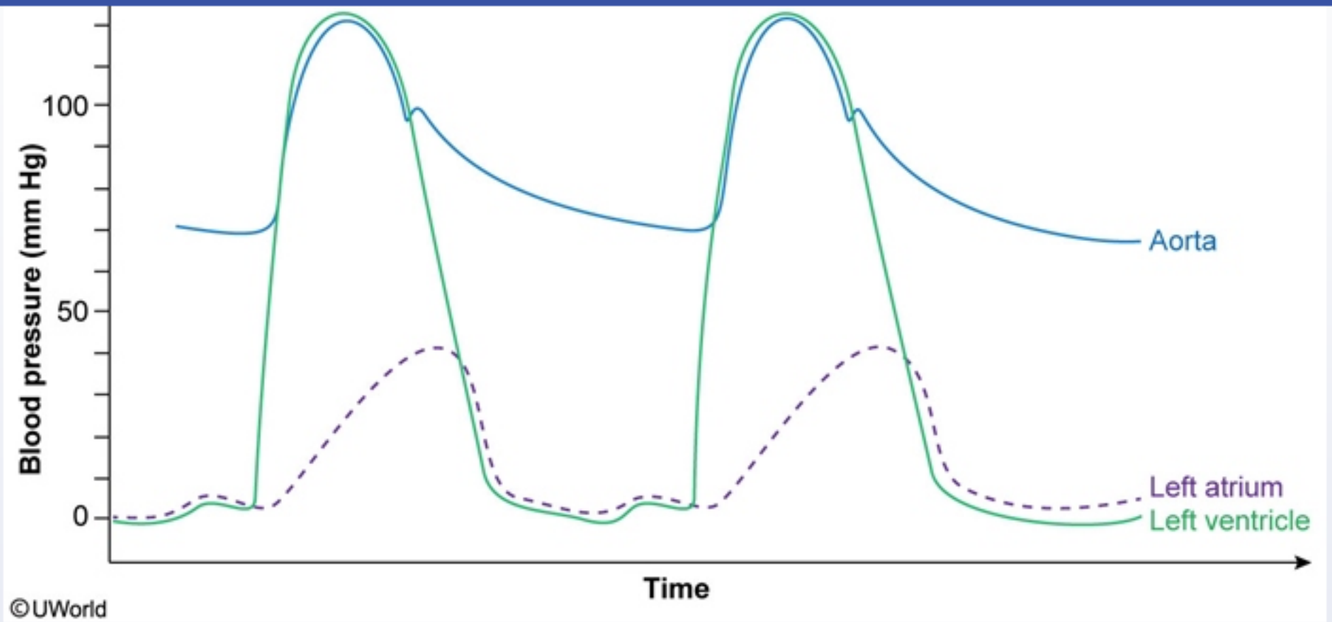

Which of the following is the most likely diagnosis?

- A. Aortic regurgitation (6%)
- B. Aortic stenosis (5%)
- ✓ C. Mitral regurgitation (66%)
- D. Mitral stenosis (19%)
- E. Tricuspid regurgitation (1%)

Omitted
Correct answer

66%
Answered correctly

05 secs
Time Spent

03/07/2020
Last Updated

1
2
3
4
5
6
7
8
9
10
11
12
13
14
15
16
17
18
19
20
21
22
23
24
25
26
27
28
29
30
31

Normal

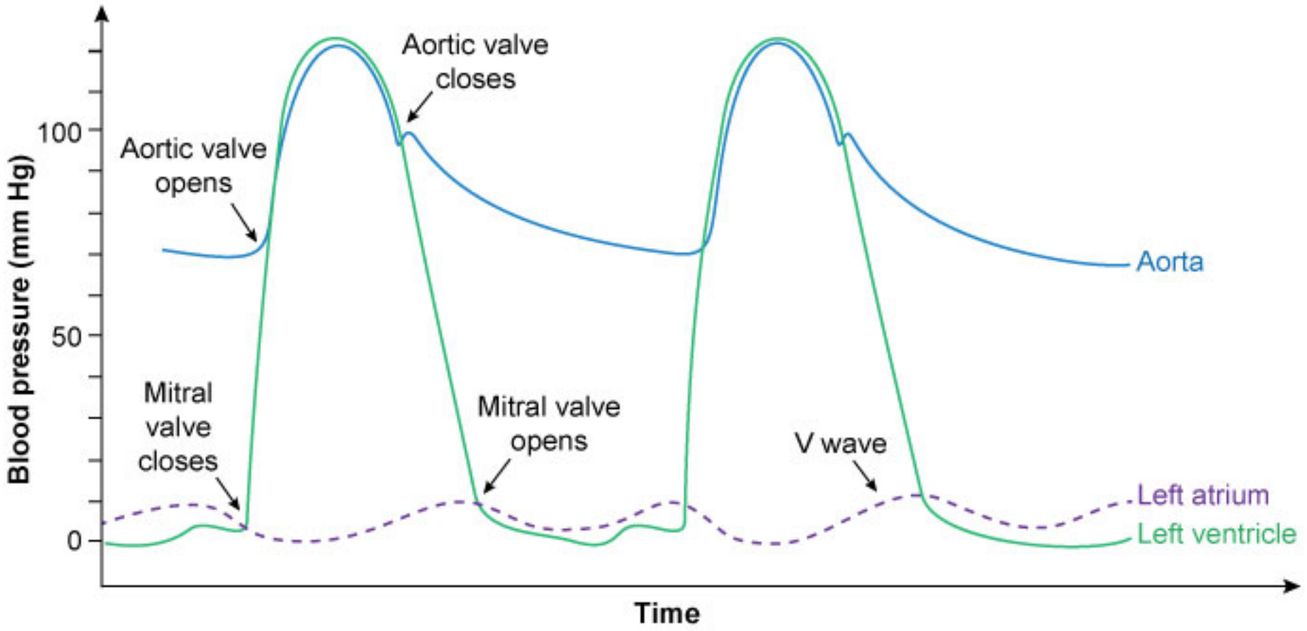

Mitral regurgitation

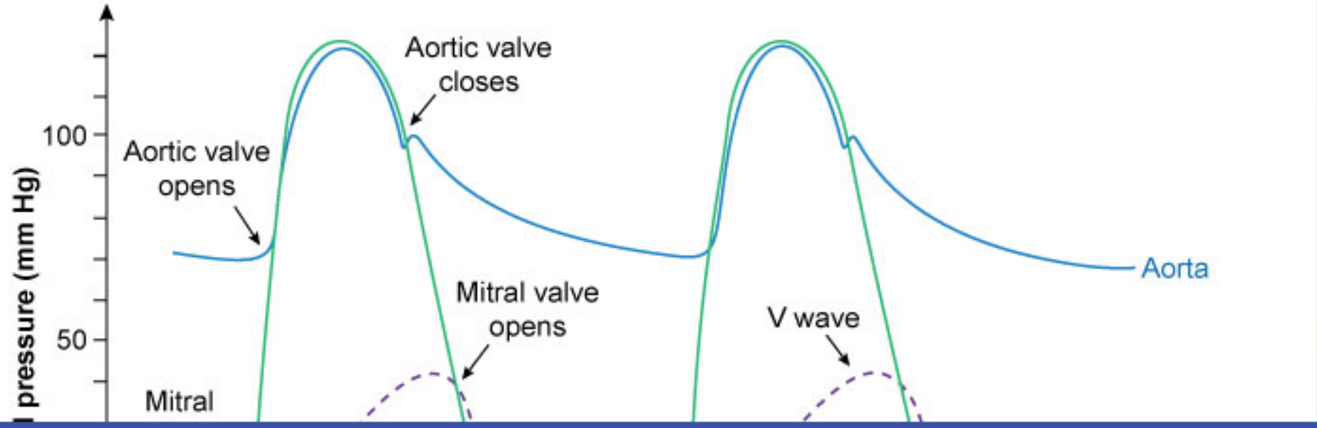

1
2
3
4
5
6
7
8
9
10
11
12
13
14
15
16
17
18
19
20
21
22
23
24
25
26
27
28
29
30
31

Normal

Exhibit Display

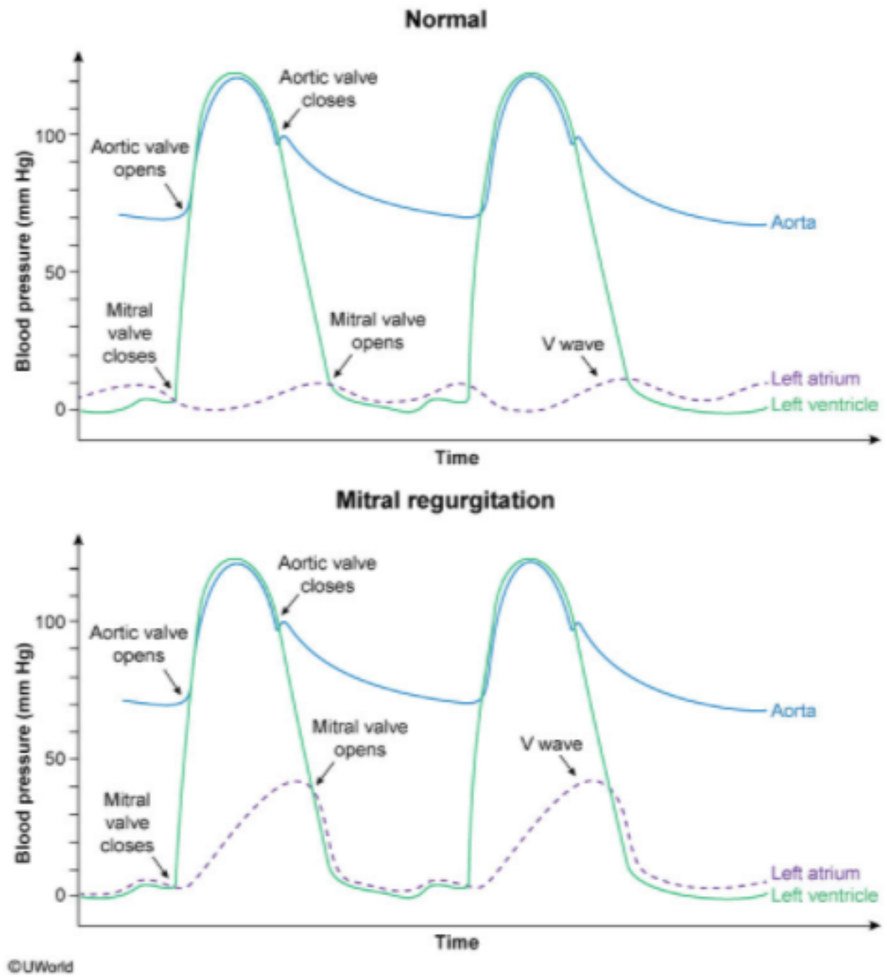

Zoom In | Zoom Out | Reset | Add To New Card | Existing Card

Mitral

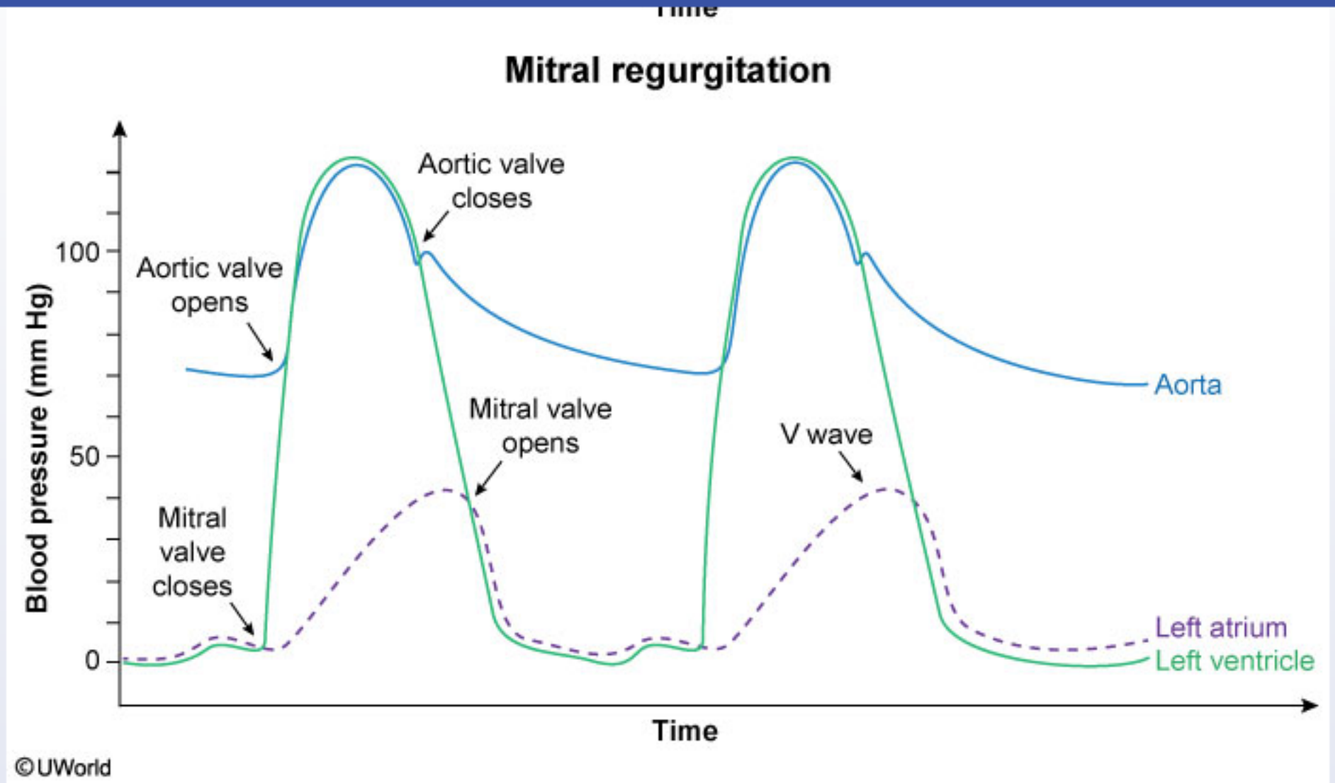

This patient's left heart catheterization shows pressure tracings consistent with **mitral regurgitation** (MR). In the cardiac cycle, passive filling of the left atrium with blood from the pulmonary veins (atrial diastole) occurs essentially in sync with left ventricular (LV) systole. Left atrial pressure gradually increases to approximately 10 mm Hg in the normal heart with a characteristic "V wave" created at the end of passive filling. However, in the setting of MR, an incompetent mitral valve allows backflow of blood from the left ventricle during ventricular systole, leading to markedly **elevated left atrial pressure** during this time. This creates an **early and large V wave**, the characteristic pressure tracing finding in patients with MR.

The elevated left atrial pressure in MR leads to atrial dilation and often precipitates atrial fibrillation, symptomatically manifesting with palpitations. Over time, decompensated heart failure, evidenced by dyspnea and orthopnea in this patient, can also occur.

(Choice A) In aortic regurgitation, backflow of blood from the aorta into the left ventricle during diastole results in rapid loss of aortic pressure and

©UWorld

This patient's left heart catheterization shows pressure tracings consistent with **mitral regurgitation** (MR). In the cardiac cycle, passive filling of the left atrium with blood from the pulmonary veins (atrial diastole) occurs essentially in sync with left ventricular (LV) systole. Left atrial pressure gradually increases to approximately 10 mm Hg in the normal heart with a characteristic "V wave" created at the end of passive filling. However, in the setting of MR, an incompetent mitral valve allows backflow of blood from the left ventricle during ventricular systole, leading to markedly **elevated left atrial pressure** during this time. This creates an **early and large V wave**, the characteristic pressure tracing finding in patients with MR.

The elevated left atrial pressure in MR leads to atrial dilation and often precipitates atrial fibrillation, symptomatically manifesting with palpitations. Over time, decompensated heart failure, evidenced by dyspnea and orthopnea in this patient, can also occur.

(Choice A) In aortic regurgitation, backflow of blood from the aorta into the left ventricle during diastole results in rapid loss of aortic pressure and elevated LV end-diastolic volume with a compensatory increase in LV stroke volume. Pressure tracings show loss of the aortic dicrotic notch (normally seen around aortic valve closure), rapid decline of aortic pressure during diastole, and elevated peak LV and aortic systolic pressures. There is also early closure of the mitral valve due to elevated LV diastolic pressure.

(Choice B) Aortic stenosis causes obstruction of LV outflow resulting in discordance of LV and aortic systolic pressure. Pressure tracings characteristically show peak LV systolic pressure significantly higher than aortic systolic pressure.

(Choice D) Mitral stenosis causes elevated left atrial pressures throughout the cardiac cycle with peak atrial pressure occurring at the time of atrial kick, just before the mitral valve closes at the end of ventricular diastole.

(Choice E) Tricuspid regurgitation causes an early and large V wave on right atrial pressure tracing, similar to that seen on left atrial pressure tracing in the setting of MR. Left-sided pressure tracings (left atrial, left ventricular, aortic) are minimally affected in tricuspid regurgitation.

Educational objective:
Left ventricular systole corresponds to the time of passive filling of the left atrium (atrial diastole). Mitral valve regurgitation leads to markedly elevated left atrial pressure during this period, creating the characteristic early and large V wave on left atrial pressure tracing.

Pathophysiology	Cardiovascular System	Mitral regurgitation
Subject	System	Topic

©UWorld

Exhibit Display

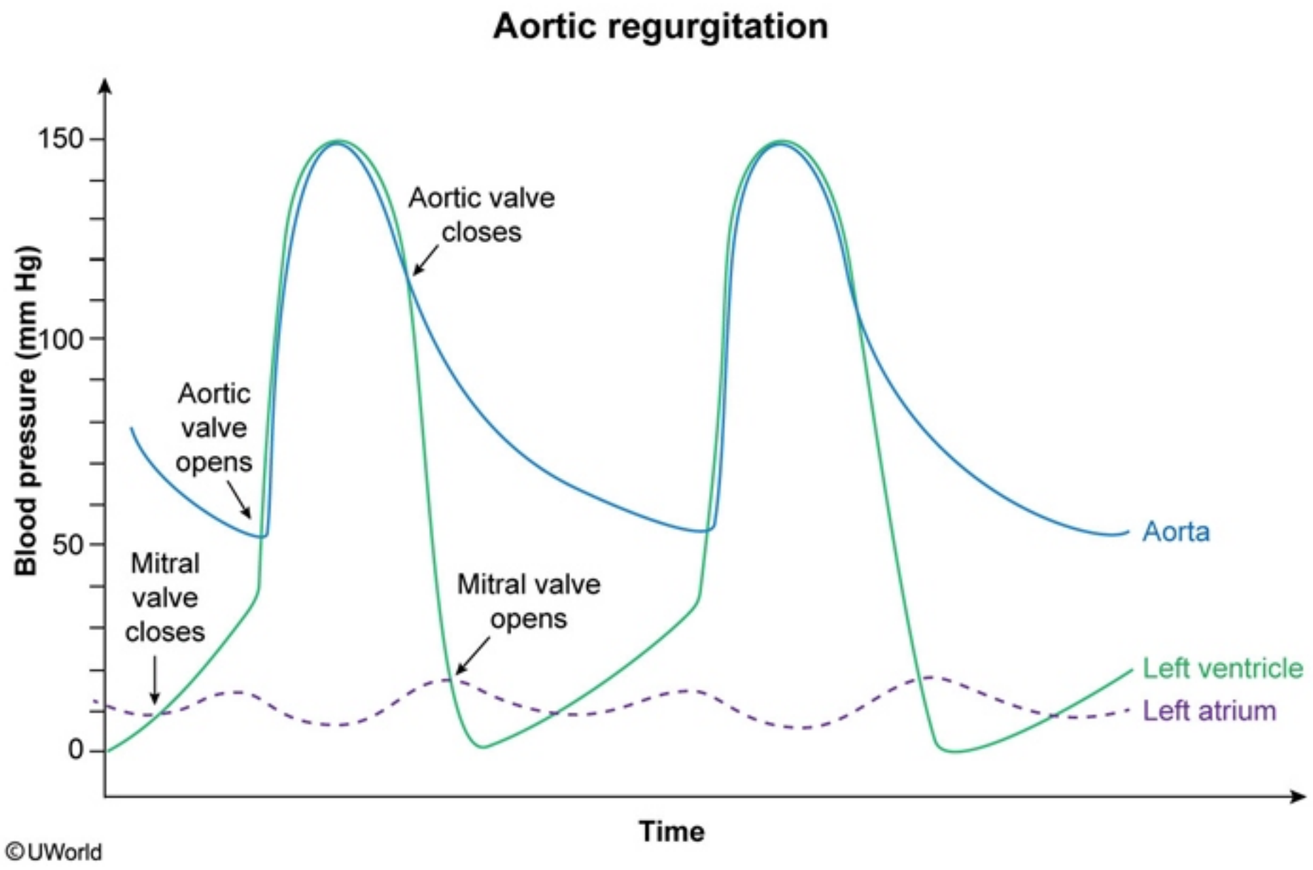

Zoom In | Zoom Out | Reset | Add To New Card | Existing Card

Subject System Topic

©UWorld

Exhibit Display

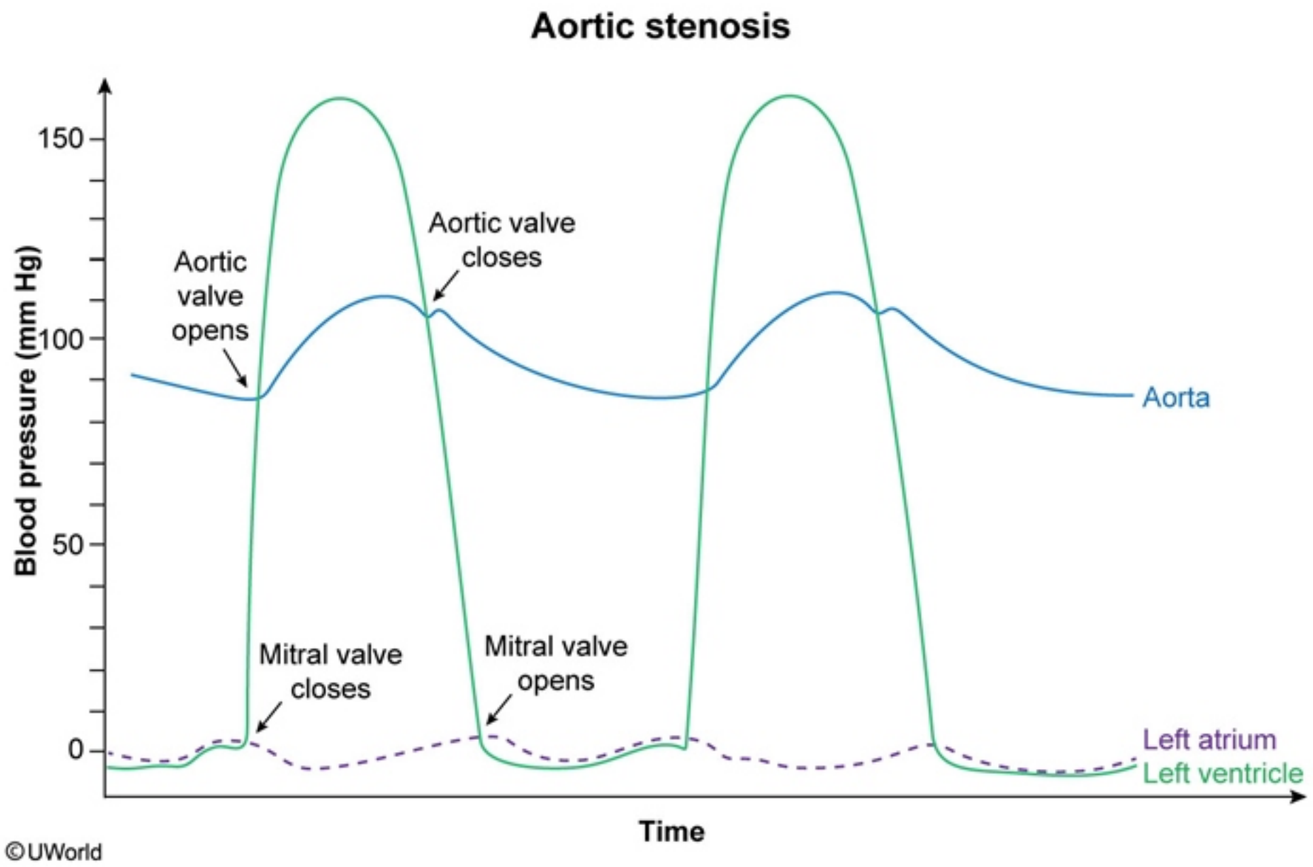

Zoom In | Zoom Out | Reset | Add To New Card | Existing Card

Subject System Topic

©UWorld

Exhibit Display

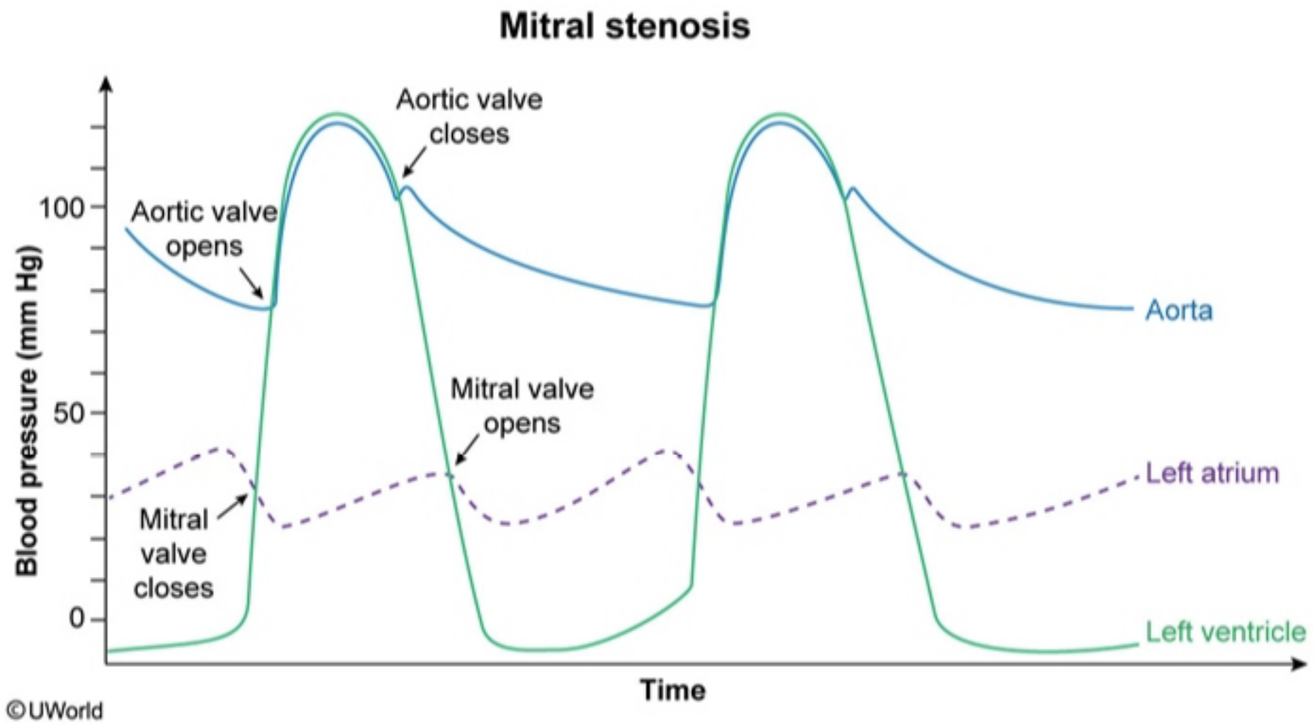

Zoom In | Zoom Out | Reset | Add To New Card | Existing Card

Subject System Topic

1
2
3
4
5
6
7
8
9
10
11
12
13
14
15
16
17
18
19
20
21
22
23
24
25
26
27
28
29
30
31

A 63-year-old man comes to the emergency department due to increasing dyspnea. He was unable to mow his lawn the previous day due to shortness of breath. The patient has a history of hypertension and a 20-pack-year smoking history. He is retired and traveled to Hawaii 2 months ago. Blood pressure is 160/86 mm Hg, pulse is 94/min, and respirations are 24/min; oxygen saturation is 94% on room air. Physical examination reveals bilateral lung crackles and occasional wheezes. Laboratory testing reveals elevated brain natriuretic peptide levels. Which of the following is the primary trigger for the release of this substance in this patient?

A. Activation of alveolar juxtacapillary receptors
B. Decrease in renal perfusion pressure
C. Decrease in vena cava blood return
D. Focal myocardial necrosis
E. Increase in ventricular wall stress
F. Stretching of aortic baroreceptors

Submit

A 63-year-old man comes to the emergency department due to increasing dyspnea. He was unable to mow his lawn the previous day due to shortness of breath. The patient has a history of hypertension and a 20-pack-year smoking history. He is retired and traveled to Hawaii 2 months ago. Blood pressure is 160/86 mm Hg, pulse is 94/min, and respirations are 24/min; oxygen saturation is 94% on room air. Physical examination reveals bilateral lung crackles and occasional wheezes. Laboratory testing reveals elevated brain natriuretic peptide levels. Which of the following is the primary trigger for the release of this substance in this patient?

- A. Activation of alveolar juxtacapillary receptors (1%)
- B. Decrease in renal perfusion pressure (3%)
- C. Decrease in vena cava blood return (2%)
- D. Focal myocardial necrosis (0%)
- ✓ E. Increase in ventricular wall stress (75%)
- F. Stretching of aortic baroreceptors (16%)

Omitted
Correct answer
E

75%
Answered correctly

02 secs
Time Spent

02/14/2020
Last Updated

Explanation

In addition to their contractile and electrical conduction properties, **cardiomyocytes** possess endocrine capabilities to help regulate blood volume. Volume overload leads to stretching and **increased wall stress** of the ventricular walls. In response, the ventricular myocardium releases **brain natriuretic peptide** (BNP); similarly, the atrial myocardium releases atrial natriuretic peptide (ANP) in response to atrial stretching. These natriuretic peptides stimulate both venous and arterial **vasodilation** to decrease cardiac preload and afterload and reduce strain on the

1
2
3
4
5
6
7
8
9
10
11
12
13
14
15
16
17
18
19
20
21
22
23
24
25
26
27
28
29
30
31

In addition to their contractile and electrical conduction properties, **cardiomyocytes** possess endocrine capabilities to help regulate blood volume. Volume overload leads to stretching and **increased wall stress** of the ventricular walls. In response, the ventricular myocardium releases **brain natriuretic peptide** (BNP); similarly, the atrial myocardium releases atrial natriuretic peptide (ANP) in response to atrial stretching. These natriuretic peptides stimulate both venous and arterial **vasodilation** to decrease cardiac preload and afterload and reduce strain on the myocardium. In addition, ANP and BNP stimulate salt and water excretion by the kidneys to facilitate **diuresis**.

Clinically, BNP has diagnostic utility in patients with shortness of breath of unknown cause. For patients in whom the serum BNP level is not elevated, shortness of breath is unlikely to be due to heart failure.

(Choice A) Alveolar juxtacapillary receptors increase respiratory rate in response to pathologic alveolar processes (eg, pulmonary edema, pneumonia).

(Choice B) Decreased renal perfusion pressure triggers the juxtaglomerular apparatus to release renin; activation of the renin-angiotensin-aldosterone system stimulates vasoconstriction and fluid retention, opposing the effects of natriuretic peptides.

(Choice C) Decrease in vena cava blood return reduces preload and leads to a consequent reduction in cardiac output. The reduced cardiac output is sensed by carotid baroreceptors, and an increase in sympathetic drive is triggered to stimulate vasoconstriction and increased heart rate and contractility.

(Choice D) Focal myocardial necrosis causes release of troponin into the bloodstream, which acts as a sensitive marker of myocardial damage. BNP levels often increase during myocardial infarction; however, this increase is likely secondary to ventricular dysfunction leading to volume overload and myocardial stretch.

(Choice F) Elevated blood pressure causes stretching of aortic baroreceptors, which triggers a reduction in sympathetic drive to alleviate vasoconstriction and reduce myocardial contractility.

Educational objective:
The ventricular myocardium secretes brain natriuretic peptide (BNP) in response to the ventricular stretch and strain that typically occurs with volume overload. BNP, along with atrial natriuretic peptide secreted by the atrial myocardium, stimulates vasodilation and salt and water excretion to help relieve volume overload.

myocardium. In addition, ANP and BNP stimulate salt and water excretion by the kidneys to facilitate **diuresis**.

Clinically, BNP has diagnostic utility in patients with shortness of breath of unknown cause. For patients in whom the serum BNP level is not elevated, shortness of breath is unlikely to be due to heart failure.

(Choice A) Alveolar juxtacapillary receptors increase respiratory rate in response to pathologic alveolar processes (eg, pulmonary edema, pneumonia).

(Choice B) Decreased renal perfusion pressure triggers the juxtaglomerular apparatus to release renin; activation of the renin-angiotensin-aldosterone system stimulates vasoconstriction and fluid retention, opposing the effects of natriuretic peptides.

(Choice C) Decrease in vena cava blood return reduces preload and leads to a consequent reduction in cardiac output. The reduced cardiac output is sensed by carotid baroreceptors, and an increase in sympathetic drive is triggered to stimulate vasoconstriction and increased heart rate and contractility.

(Choice D) Focal myocardial necrosis causes release of troponin into the bloodstream, which acts as a sensitive marker of myocardial damage. BNP levels often increase during myocardial infarction; however, this increase is likely secondary to ventricular dysfunction leading to volume overload and myocardial stretch.

(Choice F) Elevated blood pressure causes stretching of aortic baroreceptors, which triggers a reduction in sympathetic drive to alleviate vasoconstriction and reduce myocardial contractility.

Educational objective:
The ventricular myocardium secretes brain natriuretic peptide (BNP) in response to the ventricular stretch and strain that typically occurs with volume overload. BNP, along with atrial natriuretic peptide secreted by the atrial myocardium, stimulates vasodilation and salt and water excretion to help relieve volume overload.

Pathophysiology	Cardiovascular System	Chronic heart failure
Subject	System	Topic

Copyright © UWorld. All rights reserved.

1
2
3
4
5
6
7
8
9
10
11
12
13
14
15
16
17
18
19
20
21
22
23
24
25
26
27
28
29
30
31

A 25-year-old man with an insignificant medical history was playing soccer when he suddenly collapsed. Despite all attempts to save his life, he died. Autopsy is performed. Gross examination of the heart reveals a weight of 580 g (normal: <350). The cut surface of the heart is shown in the image.

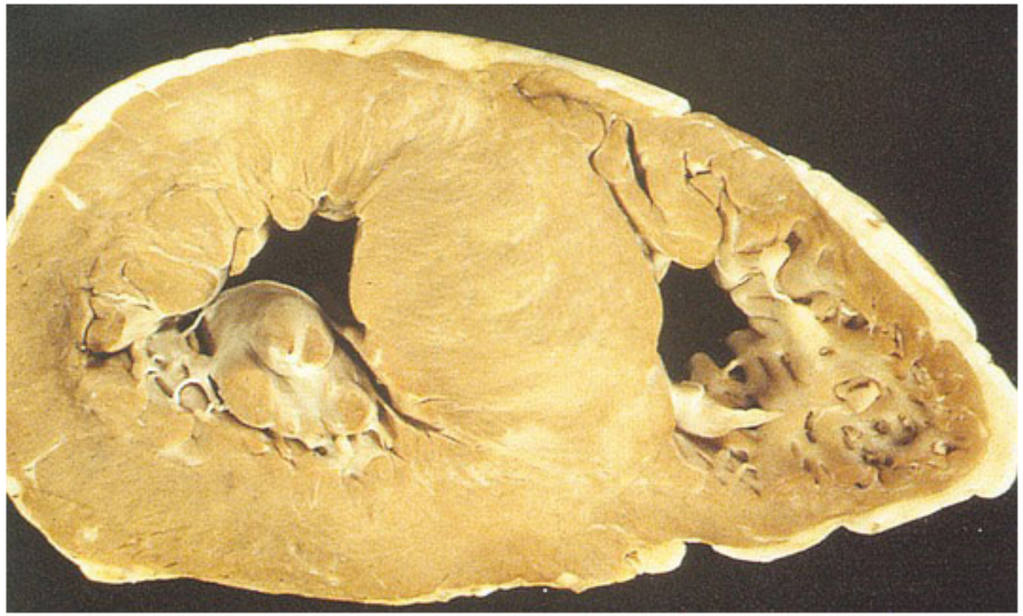

Displayed with permission from Springer Healthcare Ltd. © Copyright 1998 by Current Medicine

If this patient had a preparticipation sports screening, cardiac auscultation would have likely revealed a murmur that increases in intensity after which of the following?

- A. Passive leg raising
- B. Phenylephrine infusion
- C. Squatting

1
2
3
4
5
6
7
8
9
10
11
12
13
14
15
16
17
18
19
20
21
22
23
24
25
26
27
28
29
30
31

Displayed with permission from Springer Healthcare Ltd. © Copyright 1998 by Current Medicine

If this patient had a preparticipation sports screening, cardiac auscultation would have likely revealed a murmur that increases in intensity after which of the following?

- A. Passive leg raising
- B. Phenylephrine infusion
- C. Squatting
- D. Sudden standing
- E. Sustained hand grip

Submit

1
2
3
4
5
6
7
8
9
10
11
12
13
14
15
16
17
18
19
20
21
22
23
24
25
26
27
28
29
30
31

Displayed with permission from Springer Healthcare Ltd. © Copyright 1998 by Current Medicine

If this patient had a preparticipation sports screening, cardiac auscultation would have likely revealed a murmur that increases in intensity after which of the following?

- A. Passive leg raising (5%)
- B. Phenylephrine infusion (1%)
- C. Squatting (12%)
- ✓ D. Sudden standing (68%)
- E. Sustained hand grip (11%)

Omitted
Correct answer

68%
Answered correctly

07 secs
Time Spent

03/16/2020
Last Updated

Effect of maneuvers on hypertrophic cardiomyopathy			
	Physiologic effect	**Left ventricular blood volume**	**Murmur intensity**
Valsalva (strain phase)	↓ Preload	↓	↑
Abrupt standing			
Nitroglycerin administration			
Sustained hand grip	↑ Afterload	↑	↓
Squatting	↑ Afterload & preload		
Passive leg raise	↑ Preload		

This patient's heart shows asymmetric ventricular septal hypertrophy, a finding characteristic of **hypertrophic cardiomyopathy** (HCM). Dynamic left ventricular outflow tract (LVOT) obstruction is common in HCM and creates a harsh crescendo-decrescendo, **systolic ejection murmur** that is best heard along the lower left sternal border.

Maneuvers or conditions that **decrease LV preload** (eg, abrupt standing, Valsalva strain phase, dehydration) or **decrease LV afterload** (eg, administration of an arterial vasodilator) decrease LV blood volume to worsen LVOT obstruction and **increase the intensity** of the HCM murmur. In contrast, maneuvers or conditions that increase LV preload (eg, passive leg raising, squatting) or increase LV afterload (eg, infusion of an arterial vasoconstrictor like the alpha-1 agonist phenylephrine, sustained handgrip) increase LV blood volume to alleviate LVOT obstruction and decrease the intensity of the HCM murmur **(Choices A, B, C, and E)**.

Passive leg raise	↑ Preload		

This patient's heart shows asymmetric ventricular septal hypertrophy, a finding characteristic of **hypertrophic cardiomyopathy** (HCM). Dynamic left ventricular outflow tract (LVOT) obstruction is common in HCM and creates a harsh crescendo-decrescendo, **systolic ejection murmur** that is best heard along the lower left sternal border.

Maneuvers or conditions that **decrease LV preload** (eg, abrupt standing, Valsalva strain phase, dehydration) or **decrease LV afterload** (eg, administration of an arterial vasodilator) decrease LV blood volume to worsen LVOT obstruction and **increase the intensity** of the HCM murmur. In contrast, maneuvers or conditions that increase LV preload (eg, passive leg raising, squatting) or increase LV afterload (eg, infusion of an arterial vasoconstrictor like the alpha-1 agonist phenylephrine, sustained handgrip) increase LV blood volume to alleviate LVOT obstruction and decrease the intensity of the HCM murmur **(Choices A, B, C, and E)**.

The murmur of HCM is best differentiated from that of aortic stenosis by maneuvers that affect LV preload. Unlike HCM, the intensity of the aortic stenosis murmur correlates directly with LV preload. Increases in LV preload increase the pressure gradient across the aortic valve and increase the intensity of the murmur, whereas decreases in LV preload decrease the intensity of the murmur. Changes in afterload have the same effect on the murmurs of HCM and aortic stenosis, but for different reasons. In HCM, increased afterload increases LV blood volume to relieve LVOT obstruction and decrease the intensity of the murmur. In aortic stenosis, increased afterload decreases the pressure gradient across the aortic valve to decrease the intensity of the murmur.

Educational objective:
Hypertrophic cardiomyopathy (HCM) is characterized by asymmetric ventricular septal hypertrophy and dynamic left ventricular outflow tract (LVOT) obstruction. Decreases in LV blood volume, via maneuvers or conditions that decrease preload (eg, abrupt standing, Valsalva strain phase) or afterload, worsen LVOT obstruction and increase the intensity of the HCM murmur.

Pathophysiology	Cardiovascular System	Hypertrophic cardiomyopathy
Subject	System	Topic

Copyright © UWorld. All rights reserved.

1
2
3
4
5
6
7
8
9
10
11
12
13
14
15
16
17
18
19
20
21
22
23
24
25
26
27
28
29
30
31

Passive

Exhibit Display

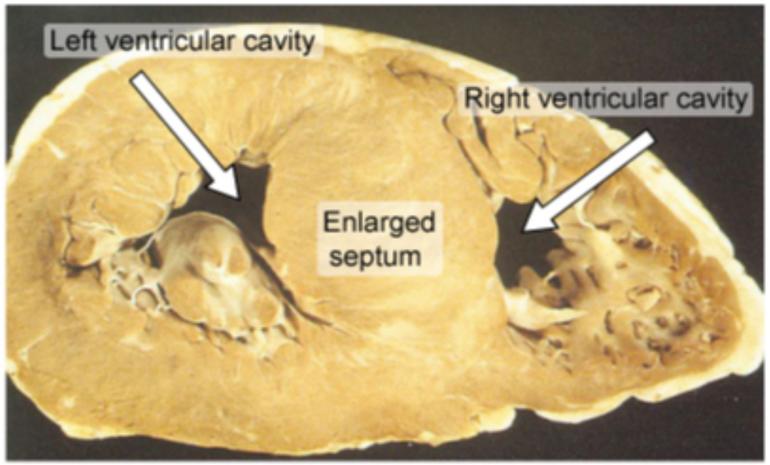

Displayed with permission from Springer Healthcare Ltd. © Copyright 1998 by Current Medicine

Zoom In | Zoom Out | Reset | Add To New Card | Existing Card

Passive leg raise	↑ Preload

This patient's heart shows mic
left ventricular outflow trac at is
best heard along the lowe

Maneuvers or conditions
administration of an arteri ur.
In contrast, maneuvers or
arterial vasoconstrictor lik d
decrease the intensity of t

The murmur of HCM is be rtic
stenosis murmur correlate se
the intensity of the murmu t on
the murmurs of HCM and
obstruction and decrease
valve to decrease the inte

Educational objective:
Hypertrophic cardiomyopa
(LVOT) obstruction. Decr
phase) or afterload, worse

Pathophysiology C
Subject Sy

Exhibit Display

UWorld

Hypertrophic cardiomyopathy

0:00 / 1:22

Copyright © UWorld. All rights reserved.

1
2
3
4
5
6
7
8
9
10
11
12
13
14
15
16
17
18
19
20
21
22
23
24
25
26
27
28
29
30
31

A 45-year-old woman who recently immigrated to the United States is hospitalized with exertional dyspnea and fatigue. She has no significant past medical history and takes no medications. The patient's blood pressure is 110/80 mm Hg and heart rate is 90/min and regular. After cardiopulmonary examination, the physician suspects mitral stenosis. Which of the following is the most useful measure for assessing the degree of mitral stenosis?

- A. A2-to-opening snap time interval
- B. Audible S3
- C. Audible S4
- D. Diastolic murmur intensity
- E. Presystolic accentuation of the murmur

Submit

1 2 3 4 5 6 7 8 9 10 11 12 13 14 15 16 17 18 19 20 21 22 23 24 25 26 27 28 29 30 31

A 45-year-old woman who recently immigrated to the United States is hospitalized with exertional dyspnea and fatigue. She has no significant past medical history and takes no medications. The patient's blood pressure is 110/80 mm Hg and heart rate is 90/min and regular. After cardiopulmonary examination, the physician suspects mitral stenosis. Which of the following is the most useful measure for assessing the degree of mitral stenosis?

- ✓ A. A2-to-opening snap time interval (63%)
- B. Audible S3 (6%)
- C. Audible S4 (3%)
- D. Diastolic murmur intensity (22%)
- E. Presystolic accentuation of the murmur (4%)

Omitted
Correct answer
A

63%
Answered correctly

02 secs
Time Spent

05/23/2020
Last Updated

Explanation



1
2
3
4
5
6
7
8
9
10
11
12
13
14
15
16
17
18
19
20
21
22
23
24
25
26
27
28
29
30
31

Mitral stenosis - mild

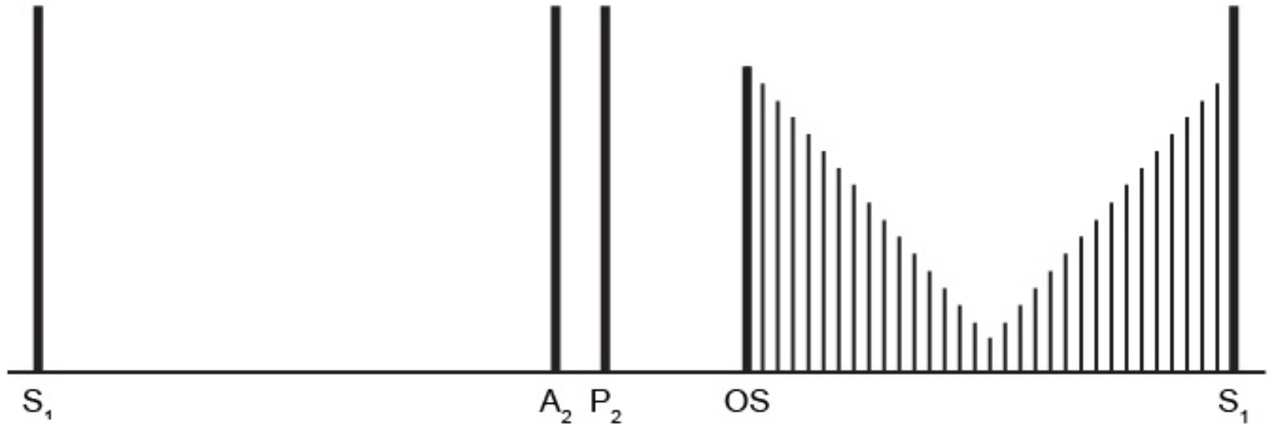

©UWorld

Mitral stenosis - severe

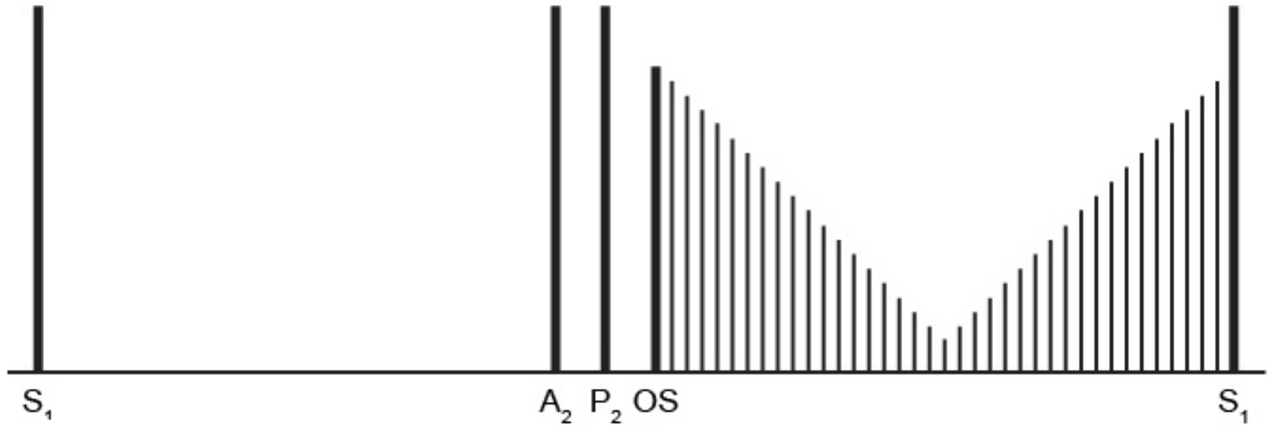

©UWorld

©UWorld

On auscultation, the best indicator of mitral stenosis (MS) severity is the length of time between S2 (specifically the A2 component, caused by aortic valve closure) and the opening snap (OS). The OS occurs due to abrupt tensing of the valve leaflets as the mitral valve reaches its maximum diameter during forceful opening. As MS worsens, left atrial pressures increase due to impaired movement of blood into the left ventricle. Higher pressure causes the valve to open more forcefully; as a result, the A2-OS interval becomes shorter as left atrial pressure increases. The current standard for diagnosis and determination of MS severity is measurement of mean transvalvular pressure gradients via 2-D Doppler echocardiography.

(Choices B and C) Left-sided S3 and/or S4 gallops are generally absent in MS, since left ventricular filling is normal or decreased. When MS is severe enough to produce pulmonary hypertension, patients may develop right-sided heart failure. As a result, a right-sided S3 and/or S4 can occur. However, these right-sided gallops arise only in severe, end-stage MS and are not useful for differentiating between mild and moderate MS.

(Choice D) Diastolic rumble intensity in MS does not correlate well with stenosis severity. This is due to murmur intensity being dependent on both the transvalvular pressure gradient and the amount of blood flowing through the valve. In very severe stenosis, the diastolic murmur may be completely absent due to greatly reduced flow across the valve.

(Choice E) Presystolic accentuation of the MS murmur occurs due to increased transvalvular flow associated with left atrial contraction. This accentuation is heard across a wide range of MS severity. More significant than the degree of presystolic accentuation is its presence or absence. When MS becomes severe enough to precipitate atrial fibrillation, presystolic accentuation of the MS murmur disappears.

Educational objective:
The best and most reliable auscultatory indicator of the degree of mitral stenosis is the A2-OS interval. A shorter interval indicates more severe stenosis. Other auscultatory findings can include a diastolic rumbling murmur with presystolic accentuation due to left-atrial contraction.

Pathophysiology	Cardiovascular System	Mitral stenosis
Subject	System	Topic

Copyright © UWorld. All rights reserved.

1
2
3
4
5
6
7
8
9
10
11
12
13
14
15
16
17
18
19
20
21
22
23
24
25
26
27
28
29
30
31

A 65-year-old Caucasian male presents to the ER with sudden onset of right-sided calf and foot pain. His past medical history is significant for hypertension, type II diabetes mellitus, atrial fibrillation and stable angina. Physical examination reveals paleness of the right leg and diminished right popliteal pulse. Immediate angiography is ordered that reveals an obstructive thrombus in the right common femoral artery. The thrombus extraction is followed by a rapid surge of serum creatine kinase level, which is best explained by:

- A. Cellular swelling
- B. Cell membrane damage
- C. Glutathione peroxidase production
- D. Mitochondrial vacuolization
- E. Nuclear shrinkage

Submit

A 65-year-old Caucasian male presents to the ER with sudden onset of right-sided calf and foot pain. His past medical history is significant for hypertension, type II diabetes mellitus, atrial fibrillation and stable angina. Physical examination reveals paleness of the right leg and diminished right popliteal pulse. Immediate angiography is ordered that reveals an obstructive thrombus in the right common femoral artery. The thrombus extraction is followed by a rapid surge of serum creatine kinase level, which is best explained by:

- A. Cellular swelling (6%)
- ✓ B. Cell membrane damage (70%)
- C. Glutathione peroxidase production (10%)
- D. Mitochondrial vacuolization (10%)
- E. Nuclear shrinkage (1%)

Omitted
Correct answer
B

70%
Answered correctly

01 sec
Time Spent

02/03/2020
Last Updated

Explanation

Ischemia is characterized by the reduction of blood flow, usually as a result of mechanical obstruction within the arterial system (eg, thrombus). If the flow of blood to the ischemic tissue is restored in a timely manner, those cells that were reversibly injured will typically recover. Sometimes, however, the cells within the damaged tissue will paradoxically die at an accelerated pace through apoptosis or necrosis after resumption of blood flow. This process is termed reperfusion injury, and is thought to occur secondary to one or more of the following mechanisms: 1) oxygen free radical generation by parenchymal cells, endothelial cells, and leukocytes; 2) severe, irreversible mitochondrial damage described as "mitochondrial permeability transition"; 3) inflammation, which attracts circulating neutrophils that cause additional injury; and 4) activation of the

Explanation

Ischemia is characterized by the reduction of blood flow, usually as a result of mechanical obstruction within the arterial system (eg, thrombus). If the flow of blood to the ischemic tissue is restored in a timely manner, those cells that were reversibly injured will typically recover. Sometimes, however, the cells within the damaged tissue will paradoxically die at an accelerated pace through apoptosis or necrosis after resumption of blood flow. This process is termed reperfusion injury, and is thought to occur secondary to one or more of the following mechanisms: 1) oxygen free radical generation by parenchymal cells, endothelial cells, and leukocytes; 2) severe, irreversible mitochondrial damage described as "mitochondrial permeability transition"; 3) inflammation, which attracts circulating neutrophils that cause additional injury; and 4) activation of the complement pathway, causing cell injury and further inflammation. When the cells within heart, brain, or skeletal muscle are injured, the enzyme creatine kinase leaks across the damaged cell membrane and into circulation (as seen in this patient).

(Choice A) Cellular swelling arises secondary to changes in ion concentration and the influx of water. This state is considered a hallmark of reversible injury, and is not directly associated with the leakage of intracellular proteins such as creatine kinase.

(Choice C) Glutathione peroxidase actually reduces cellular injury by catalyzing free radical breakdown. The presence of this enzyme is not responsible for the release of creatine kinase.

(Choice D) Mitochondrial vacuolization reduces the cellular capacity for ATP generation and is associated with irreversible injury. Creatine kinase release is not directly associated with this mitochondrial change, however.

(Choice E) Nuclear shrinkage (pyknosis), fragmentation, and dissolution characterize irreversible injury of the cell. Creatine kinase release is not directly associated with such nuclear changes, however.

Educational Objective:
Reperfusion injury is thought to occur secondary to oxygen free radical generation, mitochondrial damage, and inflammation.

Pathophysiology	Cardiovascular System	Peripheral vascular disease
Subject	System	Topic

Copyright © UWorld. All rights reserved.

1
2
3
4
5
6
7
8
9
10
11
12
13
14
15
16
17
18
19
20
21
22
23
24
25
26
27
28
29
30
31

A 75-year-old man is brought to the emergency department by paramedics following a high-speed motor vehicle accident. Several attempts are made to resuscitate him but are unsuccessful. The patient had no significant past medical history and took no medications. He was known to be in good health and tolerant of moderate levels of physical activity. Electrocardiogram findings at his last office visit showed no abnormalities. At autopsy, heavy calcifications of the aortic valve are seen. Which of the following most likely preceded the aortic valve changes observed in this patient?

- A. Cell necrosis
- B. Extracellular amyloid deposition
- C. Hypercalcemia
- D. Intracellular hemosiderin accumulation
- E. Pathologic cell hypertrophy

Submit

A 75-year-old man is brought to the emergency department by paramedics following a high-speed motor vehicle accident. Several attempts are made to resuscitate him but are unsuccessful. The patient had no significant past medical history and took no medications. He was known to be in good health and tolerant of moderate levels of physical activity. Electrocardiogram findings at his last office visit showed no abnormalities. At autopsy, heavy calcifications of the aortic valve are seen. Which of the following most likely preceded the aortic valve changes observed in this patient?

- ✓ A. Cell necrosis (35%)
- B. Extracellular amyloid deposition (27%)
- C. Hypercalcemia (14%)
- D. Intracellular hemosiderin accumulation (11%)
- E. Pathologic cell hypertrophy (10%)

Omitted
Correct answer
A

35%
Answered correctly

02 secs
Time Spent

01/17/2020
Last Updated

Explanation

This patient's aortic valve calcifications most likely represent **dystrophic calcification** affecting an aging aortic valve. Dystrophic calcification is considered a hallmark of cell injury and death, occurring in all types of **necrosis** (eg, coagulative, fat, caseous, liquefactive) in the setting of **normal calcium levels**. Grossly, dystrophic calcium deposits are seen as fine, gritty, white granules or clumps. On hematoxylin and eosin staining, these deposits typically appear as dark-purple, sharp-edged aggregates. Deposits that develop lamellated outer layers are described as psammoma bodies.

This patient's aortic valve calcifications most likely represent **dystrophic calcification** affecting an aging aortic valve. Dystrophic calcification is considered a hallmark of cell injury and death, occurring in all types of **necrosis** (eg, coagulative, fat, caseous, liquefactive) in the setting of **normal calcium levels**. Grossly, dystrophic calcium deposits are seen as fine, gritty, white granules or clumps. On hematoxylin and eosin staining, these deposits typically appear as dark-purple, sharp-edged aggregates. Deposits that develop lamellated outer layers are described as psammoma bodies.

Dystrophic calcification in aged (or damaged) cardiac valves is thought to be the result of endothelial and fibroblast death secondary to **chronic hemodynamic stress** (can be accentuated by valvular abnormalities) or atherosclerotic inflammation. Subsequent release of cellular degradation products into the valvular interstitium then promotes calcification and thickening of the valve leaflets and annulus. These changes are often benign in elderly adults (**aortic sclerosis**); however, over time, progressive valvular stiffening can lead to outflow obstruction (**calcific aortic stenosis**).

(Choice B) Extracellular amyloid deposition occurs in patients with amyloidosis. Amyloidosis can cause restrictive cardiomyopathy and heart failure, but it is not directly associated with calcification of the aortic valve.

(Choice C) Hypercalcemia is associated with metastatic calcification affecting normal tissues and organs. In this process, calcium deposition typically occurs in more alkaline tissues involved in acid excretion, such as kidneys, lungs, systemic arteries, and gastric mucosa.

(Choice D) Intracellular hemosiderin accumulation is common in patients who have hemolytic anemia or who undergo frequent blood transfusions. It is not directly associated with calcification of the aortic valve.

(Choice E) Pathologic cell hypertrophy of left ventricular cardiomyocytes (ie, left ventricular hypertrophy) can occur as the result of severe aortic stenosis.

Educational objective:
Dystrophic calcification occurs in damaged or necrotic tissue in the setting of normal calcium levels; metastatic calcification occurs in normal tissue in the setting of hypercalcemia.

References

- Pathogenetic mechanism of senile calcific aortic stenosis: the role of apoptosis.

Pathophysiology Cardiovascular System Aging

1
2
3
4
5
6
7
8
9
10
11
12
13
14
15
16
17
18
19
20
21
22
23
24
25
26
27
28
29
30
31

This patient's aortic valve calcifications most likely represent **dystrophic calcification** affecting an aging aortic valve. Dystrophic calcification is

Exhibit Display

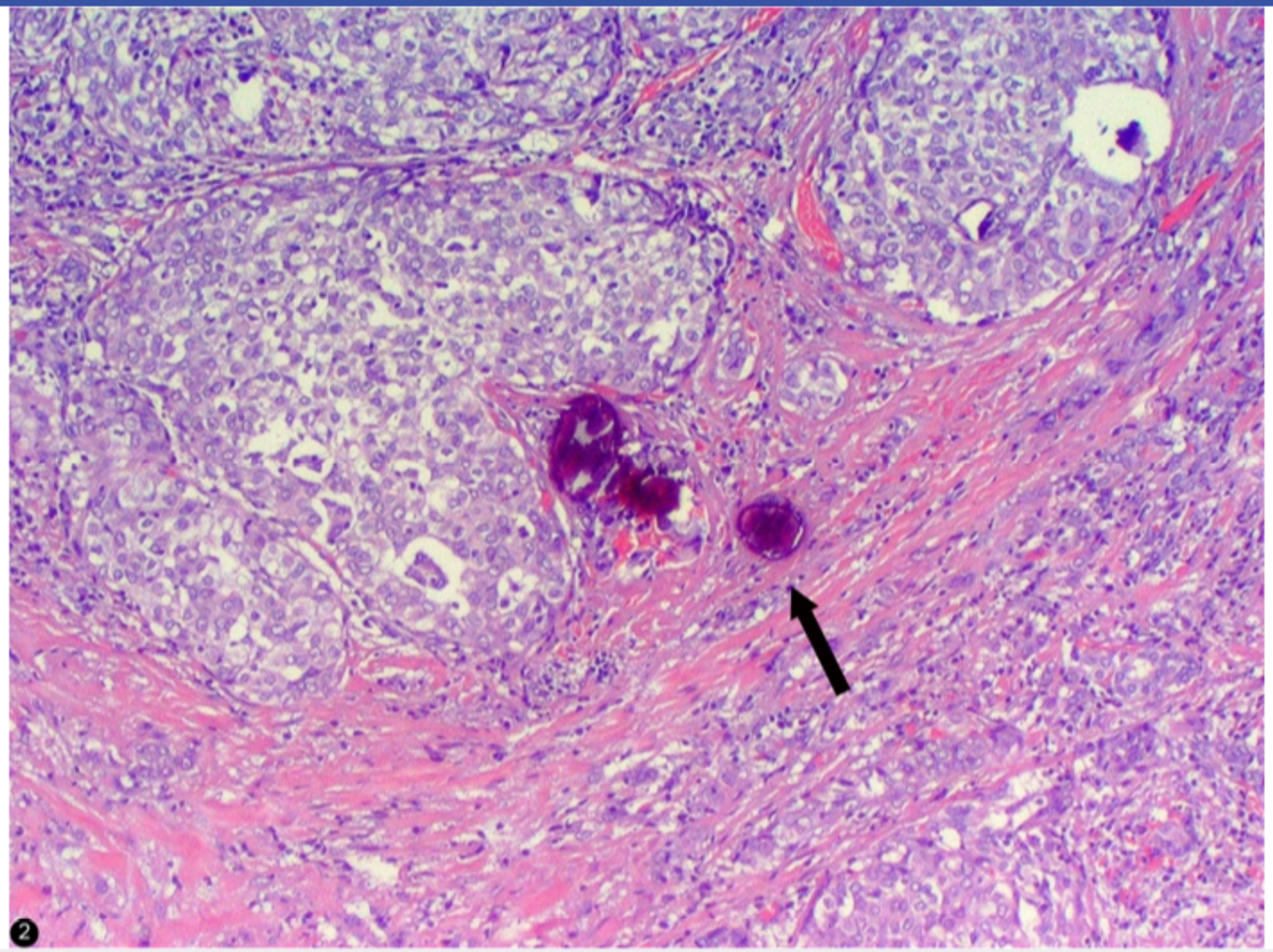

Zoom In | Zoom Out | Reset | Add To New Card | Existing Card

Pathophysiology | Cardiovascular System | Aging

1
2
3
4
5
6
7
8
9
10
11
12
13
14
15
16
17
18
19
20
21
22
23
24
25
26
27
28
29
30
31

A 46-year-old woman comes to the emergency department due to progressive dyspnea over the last 2 days. The patient's exercise tolerance has decreased dramatically and she had to sleep in a sitting position last night. She has no history of cardiovascular disease. The patient does not use tobacco or alcohol. Family history is unremarkable. Blood pressure is 110/65 mm Hg and pulse is 105/min and regular. The apical impulse is hyperdynamic. Cardiac auscultation reveals a diminished S1 and an apical holosystolic murmur radiating to the axilla. Diffuse pulmonary crackles are heard bilaterally. There is no peripheral edema. ECG shows sinus tachycardia but is otherwise unremarkable. Which of the following would most likely increase the ratio of forward flow volume to regurgitant flow volume in this patient?

- A. Decreasing heart rate
- B. Decreasing systemic vascular resistance
- C. Decreasing venous return to the left ventricle
- D. Increasing left ventricular contractility
- E. Increasing venous return to the left ventricle

Submit

1 2 3 4 5 6 7 8 9 10 11 12 13 14 15 16 17 18 19 20 21 22 23 24 25 26 27 28 29 30 31

A 46-year-old woman comes to the emergency department due to progressive dyspnea over the last 2 days. The patient's exercise tolerance has decreased dramatically and she had to sleep in a sitting position last night. She has no history of cardiovascular disease. The patient does not use tobacco or alcohol. Family history is unremarkable. Blood pressure is 110/65 mm Hg and pulse is 105/min and regular. The apical impulse is hyperdynamic. Cardiac auscultation reveals a diminished S1 and an apical holosystolic murmur radiating to the axilla. Diffuse pulmonary crackles are heard bilaterally. There is no peripheral edema. ECG shows sinus tachycardia but is otherwise unremarkable. Which of the following would most likely increase the ratio of forward flow volume to regurgitant flow volume in this patient?

- A. Decreasing heart rate (4%)
- ✓ B. Decreasing systemic vascular resistance (67%)
- C. Decreasing venous return to the left ventricle (9%)
- D. Increasing left ventricular contractility (10%)
- E. Increasing venous return to the left ventricle (8%)

Omitted
Correct answer
B

67%
Answered correctly

03 secs
Time Spent

03/15/2020
Last Updated

Explanation

Effect of blood pressure reduction on mitral regurgitation

1
2
3
4
5
6
7
8
9
10
11
12
13
14
15
16
17
18
19
20
21
22
23
24
25
26
27
28
29
30
31

Effect of blood pressure reduction on mitral regurgitation

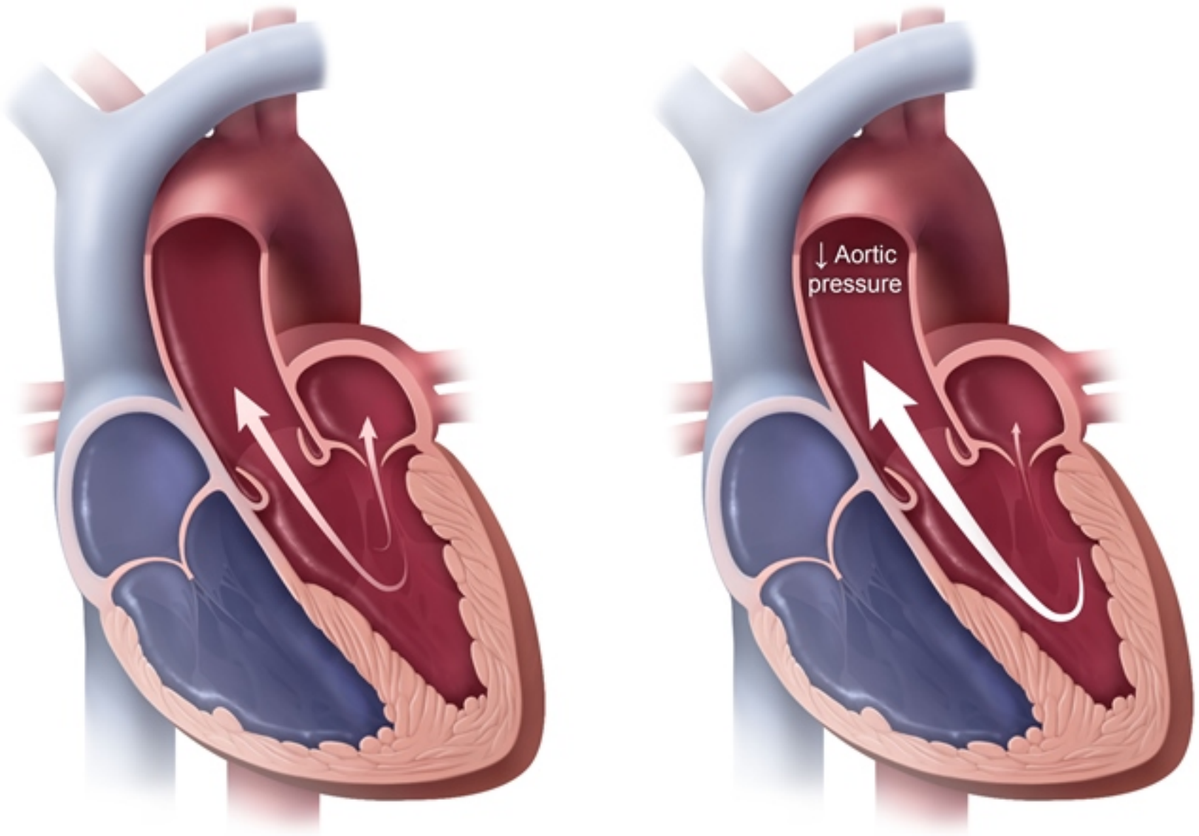

©UWorld

This patient's dyspnea, orthopnea, and crackles on lung auscultation are consistent with decompensated left-sided heart failure; the **apical holosystolic murmur** radiating to the axilla suggests **mitral regurgitation** (MR) as a contributing factor. In patients with MR, some of the blood in the left ventricle is pumped forward through the aortic valve (forward stroke volume), and some is forced backward through the incompetent mitral valve (regurgitant stroke volume). The amount of blood flowing down each pathway is determined by the relative contribution of the

©UWorld

This patient's dyspnea, orthopnea, and crackles on lung auscultation are consistent with decompensated left-sided heart failure; the **apical holosystolic murmur** radiating to the axilla suggests **mitral regurgitation** (MR) as a contributing factor. In patients with MR, some of the blood in the left ventricle is pumped forward through the aortic valve (forward stroke volume), and some is forced backward through the incompetent mitral valve (regurgitant stroke volume). The amount of blood flowing down each pathway is determined by the relative contribution of the resistance of each pathway to the total **left ventricular afterload**:

- Resistance to **forward flow** is primarily determined by the pressure in the aorta (systolic blood pressure)
- Resistance to **regurgitant flow** is determined by the mitral valve orifice size during systole and the degree of left atrial compliance. In chronic MR, the left atrium becomes more compliant and the lower left atrial pressures facilitate greater regurgitant flow.

Left atrial pressure remains relatively constant over the short term, but aortic pressure can vary significantly with changes in **systemic vascular resistance**. A reduction in systemic vascular resistance leads to reduced systemic blood pressure and an **increase in the ratio of forward to regurgitant blood flow**. Pharmacologic vasodilators (eg, nitroprusside) therefore help to increase forward cardiac output and reduce pulmonary congestion in patients with MR.

(Choices A and E) A decrease in heart rate leads to an increase in venous return to the left ventricle (preload) due to increased diastolic filling time. This causes an absolute increase in both forward and regurgitant blood flow (stroke volume increases in accordance with the Frank-Starling mechanism), but the ratio of forward to regurgitant flow is unlikely to significantly change.

(Choice C) A reduction in venous return to the left ventricle decreases stroke volume with absolute reductions in both forward and regurgitant flow, but is unlikely to significantly affect the ratio of forward to regurgitant flow.

(Choice D) An increase in left ventricular contractility increases stroke volume and leads to an increase in both forward and regurgitant blood flow. However again, as the relative resistance of each pathway is unchanged, the ratio of forward to regurgitant blood flow remains essentially the same.

Educational objective:
In patients with mitral regurgitation, left ventricular afterload is determined by the balance of resistance between forward flow (aortic pressure) and regurgitant flow (left atrial pressure). A reduction in systemic vascular resistance increases the ratio of forward to regurgitant blood flow and improves cardiac output.

1 2 3 4 5 6 7 8 9 10 11 12 13 14 15 16 17 18 19 20 21 22 23 24 25 26 27 28 29 30 31

- Resistance to **forward flow** is primarily determined by the pressure in the aorta (systolic blood pressure)
- Resistance to **regurgitant flow** is determined by the mitral valve orifice size during systole and the degree of left atrial compliance. In chronic MR, the left atrium becomes more compliant and the lower left atrial pressures facilitate greater regurgitant flow.

Left atrial pressure remains relatively constant over the short term, but aortic pressure can vary significantly with changes in **systemic vascular resistance**. A reduction in systemic vascular resistance leads to reduced systemic blood pressure and an **increase in the ratio of forward to regurgitant blood flow**. Pharmacologic vasodilators (eg, nitroprusside) therefore help to increase forward cardiac output and reduce pulmonary congestion in patients with MR.

(Choices A and E) A decrease in heart rate leads to an increase in venous return to the left ventricle (preload) due to increased diastolic filling time. This causes an absolute increase in both forward and regurgitant blood flow (stroke volume increases in accordance with the Frank-Starling mechanism), but the ratio of forward to regurgitant flow is unlikely to significantly change.

(Choice C) A reduction in venous return to the left ventricle decreases stroke volume with absolute reductions in both forward and regurgitant flow, but is unlikely to significantly affect the ratio of forward to regurgitant flow.

(Choice D) An increase in left ventricular contractility increases stroke volume and leads to an increase in both forward and regurgitant blood flow. However again, as the relative resistance of each pathway is unchanged, the ratio of forward to regurgitant blood flow remains essentially the same.

Educational objective:
In patients with mitral regurgitation, left ventricular afterload is determined by the balance of resistance between forward flow (aortic pressure) and regurgitant flow (left atrial pressure). A reduction in systemic vascular resistance increases the ratio of forward to regurgitant blood flow and improves cardiac output.

Pathophysiology	Cardiovascular System	Mitral regurgitation
Subject	System	Topic

Copyright © UWorld. All rights reserved.

1
2
3
4
5
6
7
8
9
10
11
12
13
14
15
16
17
18
19
20
21
22
23
24
25
26
27
28
29
30
31

A 12-year-old Caucasian male is found to have a wide, fixed splitting of the second heart sound (S2) on routine physical examination. He denies any symptoms. If present, the congenital heart disease in this patient may require surgical repair to prevent irreversible changes in the:

- A. Right ventricle
- B. Right atrium
- C. Left ventricle
- D. Left atrium
- E. Pulmonary vessels
- F. Coronary vessels

Submit

A 12-year-old Caucasian male is found to have a wide, fixed splitting of the second heart sound (S2) on routine physical examination. He denies any symptoms. If present, the congenital heart disease in this patient may require surgical repair to prevent irreversible changes in the:

- A. Right ventricle (24%)
- B. Right atrium (18%)
- C. Left ventricle (10%)
- D. Left atrium (6%)
- ✓ E. Pulmonary vessels (39%)
- F. Coronary vessels (0%)

Omitted
Correct answer
E

39%
Answered correctly

02 secs
Time Spent

02/03/2020
Last Updated

Explanation

Wide, fixed splitting of S2 that does not vary with respiration is a characteristic auscultatory finding of an atrial septal defect (ASD). ASD creates a left-to-right shunt because of the high pressure in the left atrium. The result is increased blood flow through the pulmonary artery. The muscular pulmonary arteries may develop laminated medial hypertrophy that can become so severe over time as to increase the pulmonary vascular resistance above the total systemic vascular resistance. At this point, the original left-to-right intracardiac shunt reverses, and flow becomes right-to-left. This switch to right-to-left shunting manifests as late-onset cyanosis, with clubbing and polycythemia. Eisenmenger syndrome is the name for reversal of shunt flow through a congenital cardiac defect that occurs as a result of chronic pulmonary hypertension. Over time, the pulmonary

1
2
3
4
5
6
7
8
9
10
11
12
13
14
15
16
17
18
19
20
21
22
23
24
25
26
27
28
29
30
31

Explanation

Wide, fixed splitting of S2 that does not vary with respiration is a characteristic auscultatory finding of an atrial septal defect (ASD). ASD creates a left-to-right shunt because of the high pressure in the left atrium. The result is increased blood flow through the pulmonary artery. The muscular pulmonary arteries may develop laminated medial hypertrophy that can become so severe over time as to increase the pulmonary vascular resistance above the total systemic vascular resistance. At this point, the original left-to-right intracardiac shunt reverses, and flow becomes right-to-left. This switch to right-to-left shunting manifests as late-onset cyanosis, with clubbing and polycythemia. Eisenmenger syndrome is the name for reversal of shunt flow through a congenital cardiac defect that occurs as a result of chronic pulmonary hypertension. Over time, the pulmonary vascular sclerosis becomes irreversible and closure of the cardiac septal defect can no longer be hemodynamically tolerated by the right ventricle.

(Choices A and B) Pulmonary hypertension produced by an ASD could result in right ventricular hypertrophy and right atrial enlargement. However, these changes are not necessarily irreversible. If the pulmonary hypertension is corrected, the right heart can revert to a more normal morphology.

(Choices C and D) Left ventricular failure is uncommon in patients with ASD. Left atrial enlargement can be present due to volume overload, but the main changes are in the right side of the heart.

Educational Objective:
Wide, fixed splitting of the second heart sound is a characteristic auscultatory finding in patients with ASD. A hemodynamically significant ASD can produce chronic pulmonary hypertension as a result of left-to-right intracardiac shunting. Eisenmenger syndrome is the late-onset reversal of a left-to-right shunt due to pulmonary vascular sclerosis resulting from chronic pulmonary hypertension. Closure of the ASD may be required to prevent irreversible pulmonary vascular sclerosis and a permanent Eisenmenger syndrome.

Pathophysiology	Cardiovascular System	Atrial septal defect
Subject	System	Topic

Copyright © UWorld. All rights reserved.

1
2
3
4
5
6
7
8
9
10
11
12
13
14
15
16
17
18
19
20
21
22
23
24
25
26
27
28
29
30
31

A 56-year-old man comes to the emergency department due to progressively worsening dyspnea. The patient can walk only a few blocks before becoming short of breath. He also finds it difficult to sleep lying flat and requires 3 pillows to prop himself upright when sleeping. Other medical problems include long-standing hypertension, for which he occasionally takes his prescribed antihypertensive medication. The patient does not use tobacco, alcohol, or illicit drugs. Blood pressure is 170/100 mm Hg, and pulse is 80/min and regular. Physical examination reveals bilateral basilar lung crackles, jugular venous distension, and bilateral lower extremity edema. Chest x-ray reveals cardiomegaly and hilar prominence. ECG shows left ventricular hypertrophy. Echocardiogram shows elevated pressures in the pulmonary artery. Which of the following is the most likely underlying cause of the observed echocardiographic finding in this patient?

A. Hypoxia-induced pulmonary vasoconstriction

B. Increased pulmonary arterial blood flow

C. Increased pulmonary venous pressure

D. Inflammatory pulmonary vascular disease

E. Obliteration of the pulmonary vascular bed

F. Thrombotic obstruction of the pulmonary arterial tree

Submit

1 2 3 4 5 6 7 8 9 10 11 12 13 14 15 16 17 18 19 20 21 22 23 24 25 26 27 28 29 30 31

A 56-year-old man comes to the emergency department due to progressively worsening dyspnea. The patient can walk only a few blocks before becoming short of breath. He also finds it difficult to sleep lying flat and requires 3 pillows to prop himself upright when sleeping. Other medical problems include long-standing hypertension, for which he occasionally takes his prescribed antihypertensive medication. The patient does not use tobacco, alcohol, or illicit drugs. Blood pressure is 170/100 mm Hg, and pulse is 80/min and regular. Physical examination reveals bilateral basilar lung crackles, jugular venous distension, and bilateral lower extremity edema. Chest x-ray reveals cardiomegaly and hilar prominence. ECG shows left ventricular hypertrophy. Echocardiogram shows elevated pressures in the pulmonary artery. Which of the following is the most likely underlying cause of the observed echocardiographic finding in this patient?

- A. Hypoxia-induced pulmonary vasoconstriction (11%)
- B. Increased pulmonary arterial blood flow (9%)
- ✓ C. Increased pulmonary venous pressure (71%)
- D. Inflammatory pulmonary vascular disease (1%)
- E. Obliteration of the pulmonary vascular bed (4%)
- F. Thrombotic obstruction of the pulmonary arterial tree (1%)

Omitted
Correct answer
C

71%
Answered correctly

02 secs
Time Spent

02/22/2020
Last Updated

Explanation

Pulmonary hypertension due to left-sided heart failure

1
2
3
4
5
6
7
8
9
10
11
12
13
14
15
16
17
18
19
20
21
22
23
24
25
26
27
28
29
30
31

Pulmonary hypertension due to left-sided heart failure

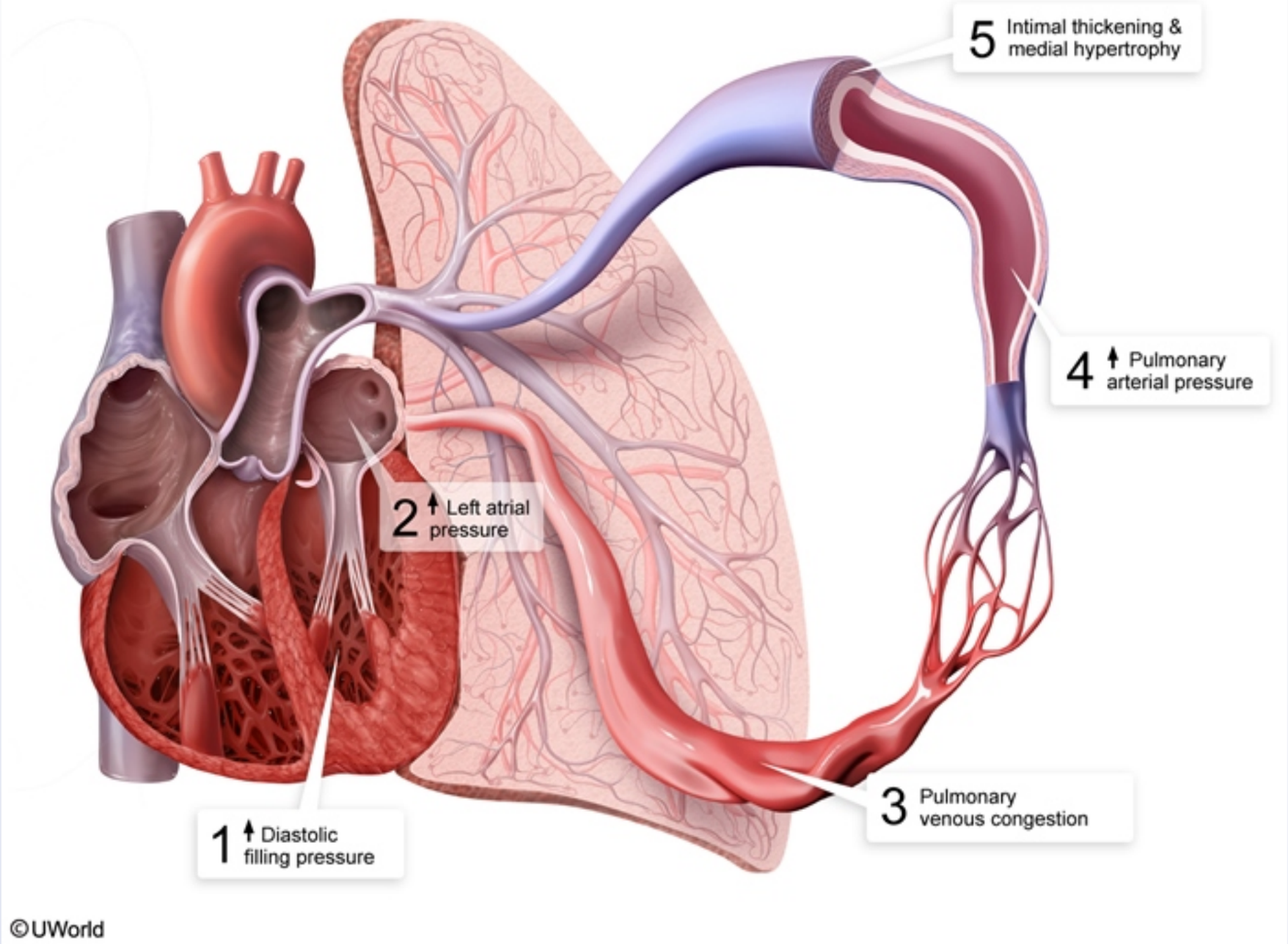

This patient with dyspnea, orthopnea, and pulmonary crackles has **left-sided heart failure** (LHF) most likely due to long-standing, poorly controlled hypertension. Hypertensive heart disease typically manifests as heart failure due to concentric left ventricular (LV) hypertrophy and consequent LV diastolic dysfunction. LHF of any cause (eg, LV systolic dysfunction, valvular dysfunction) will result in **higher diastolic filling**

This patient with dyspnea, orthopnea, and pulmonary crackles has **left-sided heart failure** (LHF) most likely due to long-standing, poorly controlled hypertension. Hypertensive heart disease typically manifests as heart failure due to concentric left ventricular (LV) hypertrophy and consequent LV diastolic dysfunction. LHF of any cause (eg, LV systolic dysfunction, valvular dysfunction) will result in **higher diastolic filling pressures**. This increase in pressure is **transmitted backward** to the left atrium and pulmonary veins, resulting in **pulmonary venous congestion** and consequent elevations in pulmonary capillary and pulmonary arterial pressure. The resulting **pulmonary hypertension** (PH) can lead to right-sided heart failure with jugular venous distension and peripheral edema.

Over time, **remodeling** of the pulmonary vasculature occurs with increased smooth muscle cell proliferation (medial hypertrophy) and collagen deposition (intimal thickening and fibrosis). The remodeling is less extensive than in (primary) pulmonary arterial hypertension; therefore, the PH is at least partially reversible with treatment of the LHF.

(Choices A and E) Hypoxia-induced vasoconstriction and emphysematous obliteration of the vasculature underlie PH that occurs secondary to chronic obstructive pulmonary disease. Although there is a small component of hypoxia-induced pulmonary vasoconstriction in LHF, pulmonary venous congestion is the major cause of PH.

(Choice B) Congenital heart disease that causes left-to-right shunting (eg, ventricular septal defect, atrial septal defect) can lead to PH via an increase in pulmonary arterial blood flow. In LHF, PH occurs due to backwards transmission of pressure from increased pulmonary venous blood volume; pulmonary arterial blood flow remains the same or decreases as LHF worsens.

(Choice D) Inflammatory large-vessel vasculitis (ie, Takayasu arteritis, giant cell arteritis) can sometimes involve the pulmonary arteries and cause PH. However, pulmonary vascular inflammation does not play a role in PH occurring secondary to LHF.

(Choice F) Thrombotic obstruction of the pulmonary arterial tree occurs in acute pulmonary embolism, and some patients can develop chronic thromboembolic PH despite receiving appropriate anticoagulation therapy. However, this patient has no history of thromboembolic disease, and his orthopnea and crackles are more suggestive of PH due to LHF.

Educational objective:
Left-sided heart failure can cause secondary pulmonary hypertension via elevated left-sided diastolic filling pressures transmitting backward to the pulmonary veins, resulting in pulmonary venous congestion. Over time, pulmonary arterial remodeling (medial hypertrophy and intimal thickening with fibrosis) can occur, but not to the extent that occurs in (primary) pulmonary arterial hypertension.

References

Over time, **remodeling** of the pulmonary vasculature occurs with increased smooth muscle cell proliferation (medial hypertrophy) and collagen deposition (intimal thickening and fibrosis). The remodeling is less extensive than in (primary) pulmonary arterial hypertension; therefore, the PH is at least partially reversible with treatment of the LHF.

(Choices A and E) Hypoxia-induced vasoconstriction and emphysematous obliteration of the vasculature underlie PH that occurs secondary to chronic obstructive pulmonary disease. Although there is a small component of hypoxia-induced pulmonary vasoconstriction in LHF, pulmonary venous congestion is the major cause of PH.

(Choice B) Congenital heart disease that causes left-to-right shunting (eg, ventricular septal defect, atrial septal defect) can lead to PH via an increase in pulmonary arterial blood flow. In LHF, PH occurs due to backwards transmission of pressure from increased pulmonary venous blood volume; pulmonary arterial blood flow remains the same or decreases as LHF worsens.

(Choice D) Inflammatory large-vessel vasculitis (ie, Takayasu arteritis, giant cell arteritis) can sometimes involve the pulmonary arteries and cause PH. However, pulmonary vascular inflammation does not play a role in PH occurring secondary to LHF.

(Choice F) Thrombotic obstruction of the pulmonary arterial tree occurs in acute pulmonary embolism, and some patients can develop chronic thromboembolic PH despite receiving appropriate anticoagulation therapy. However, this patient has no history of thromboembolic disease, and his orthopnea and crackles are more suggestive of PH due to LHF.

Educational objective:
Left-sided heart failure can cause secondary pulmonary hypertension via elevated left-sided diastolic filling pressures transmitting backward to the pulmonary veins, resulting in pulmonary venous congestion. Over time, pulmonary arterial remodeling (medial hypertrophy and intimal thickening with fibrosis) can occur, but not to the extent that occurs in (primary) pulmonary arterial hypertension.

References

- Pulmonary hypertension in left heart disease.

Pathophysiology	Cardiovascular System	Pulmonary Arterial Hypertension
Subject	System	Topic

Copyright © UWorld. All rights reserved.

1
2
3
4
5
6
7
8
9
10
11
12
13
14
15
16
17
18
19
20
21
22
23
24
25
26
27
28
29
30
31

A 34-year-old man comes to the office due to heart palpitations that are particularly prominent at night. With moderate exertion he also experiences head-pounding accompanied by involuntary head-bobbing. The patient recently emigrated from Southeast Asia and remembers being diagnosed with a heart murmur years before, but he cannot recall the type of murmur and has never received any treatment. He has no other medical conditions and takes no medications. He does not use tobacco, alcohol, or illicit drugs. The patient's father has coronary artery disease and his mother has type 2 diabetes mellitus. Based on this patient's history, which of the following findings is most likely to be present on further evaluation?

A. Impaired left ventricular contractility

B. Left ventricular outflow obstruction

C. Restricted left ventricular filling

D. Systolic and diastolic hypertension

E. Widening of the pulse pressure

Submit

A 34-year-old man comes to the office due to heart palpitations that are particularly prominent at night. With moderate exertion he also experiences head-pounding accompanied by involuntary head-bobbing. The patient recently emigrated from Southeast Asia and remembers being diagnosed with a heart murmur years before, but he cannot recall the type of murmur and has never received any treatment. He has no other medical conditions and takes no medications. He does not use tobacco, alcohol, or illicit drugs. The patient's father has coronary artery disease and his mother has type 2 diabetes mellitus. Based on this patient's history, which of the following findings is most likely to be present on further evaluation?

A. Impaired left ventricular contractility (2%)

B. Left ventricular outflow obstruction (9%)

C. Restricted left ventricular filling (5%)

D. Systolic and diastolic hypertension (2%)

✓ E. Widening of the pulse pressure (79%)

Omitted
Correct answer
E

79%
Answered correctly

02 secs
Time Spent

04/23/2020
Last Updated

Explanation

Chronic aortic regurgitation	
Common etiologies	• Congenital bicuspid aortic valve • Postinflammatory (eg, rheumatic heart disease, endocarditis)

Chronic aortic regurgitation	
Common etiologies	• Congenital bicuspid aortic valve • Postinflammatory (eg, rheumatic heart disease, endocarditis) • Aortic root dilation (eg, Marfan syndrome, syphilis)
Pathophysiology	• Backflow from aorta into LV → ↑ LV end-diastolic volume • LV initially compensates with eccentric hypertrophy → ↑ SV & CO • Eventual LV dysfunction → ↓ SV & CO → heart failure
Clinical findings	• Decrescendo diastolic murmur • Widened pulse pressure (↑SBP & ↓DBP) • Rapid rise-rapid fall ("water-hammer") pulsation • Abrupt carotid distension & collapse, "pistol-shot" femoral pulses

CO = cardiac output; DBP = diastolic blood pressure; LV = left ventricle; SBP = systolic blood pressure; SV = stroke volume.

This patient has a number of clinical findings that are characteristic of **chronic aortic regurgitation** (AR). Failure of the aortic valve to tightly seal off the aorta from the left ventricle at the end of systole leads to rapid loss of aortic pressure and an overall **decrease in diastolic blood pressure**. In addition, the left ventricle undergoes eccentric hypertrophy to initially compensate for an increase in left ventricular end-diastolic volume, which leads to increased stroke volume and cardiac output. Because pulse pressure (the difference between diastolic and systolic blood pressure) is proportional to stroke volume, the compensatory **increased stroke volume** on top of reduced diastolic pressure causes the characteristic **widened pulse pressure** seen with AR.

This high-amplitude pulsation with rapid diastolic collapse is responsible for the unusual pulsation findings in AR. Forceful pulsations in the intracranial arteries can cause **head bobbing** with each heart beat (de Musset sign), and patients may experience **palpitations** due to forceful left ventricular contraction. In addition, physical examination can show abrupt distension and collapse of the carotid arteries (Corrigan sign) and peripheral arteries ("water-hammer" pulse), and reveal "pistol-shot" femoral pulses (Traube sign) on auscultation.

(Choice A) Impaired left ventricular contractility occurs later in the course of AR and eventually leads to heart failure. Because head-bobbing and

This patient has a number of clinical findings that are characteristic of **chronic aortic regurgitation** (AR). Failure of the aortic valve to tightly seal off the aorta from the left ventricle at the end of systole leads to rapid loss of aortic pressure and an overall **decrease in diastolic blood pressure**. In addition, the left ventricle undergoes eccentric hypertrophy to initially compensate for an increase in left ventricular end-diastolic volume, which leads to increased stroke volume and cardiac output. Because pulse pressure (the difference between diastolic and systolic blood pressure) is proportional to stroke volume, the compensatory **increased stroke volume** on top of reduced diastolic pressure causes the characteristic **widened pulse pressure** seen with AR.

This high-amplitude pulsation with rapid diastolic collapse is responsible for the unusual pulsation findings in AR. Forceful pulsations in the intracranial arteries can cause **head bobbing** with each heart beat (de Musset sign), and patients may experience **palpitations** due to forceful left ventricular contraction. In addition, physical examination can show abrupt distension and collapse of the carotid arteries (Corrigan sign) and peripheral arteries ("water-hammer" pulse), and reveal "pistol-shot" femoral pulses (Traube sign) on auscultation.

(Choice A) Impaired left ventricular contractility occurs later in the course of AR and eventually leads to heart failure. Because head-bobbing and other characteristic findings in AR are due to increased stroke volume and high-amplitude, rapid rise-rapid fall pulsation, these findings are less prominent once impaired left ventricular contractility (and decreased stroke volume) sets in.

(Choices B and C) Left ventricular outflow tract obstruction, such as occurs with aortic stenosis, leads to reduced stroke volume and characteristic weak and delayed pulses (pulsus parvus et tardus). Restriction of left ventricular filling, as occurs in mitral stenosis, also reduces stroke volume due to reduced left ventricular end-diastolic volume (reduced preload). Clinical findings associated with high-amplitude pulsation will not be present with reduced stroke volume.

(Choice D) Combined systolic and diastolic hypertension is not necessarily accompanied by widened pulse pressure; the signs of high amplitude, rapid rise-rapid fall pulsation are more characteristic of chronic AR.

Educational objective:
Chronic aortic regurgitation (AR) causes a reduction in diastolic blood pressure and a compensatory increase in left ventricular stroke volume. These changes create a high-amplitude, rapid rise-rapid fall pulsation (ie, widened pulse pressure) and the other characteristic findings of AR (eg, head bobbing, "pistol-shot" femoral pulses).

Pathophysiology Cardiovascular System Aortic regurgitation

This patient has a number of clinical findings that are characteristic of **chronic aortic regurgitation** (AR). Failure of the aortic valve to tightly seal

Exhibit Display

Pathophysiology of chronic aortic regurgitation

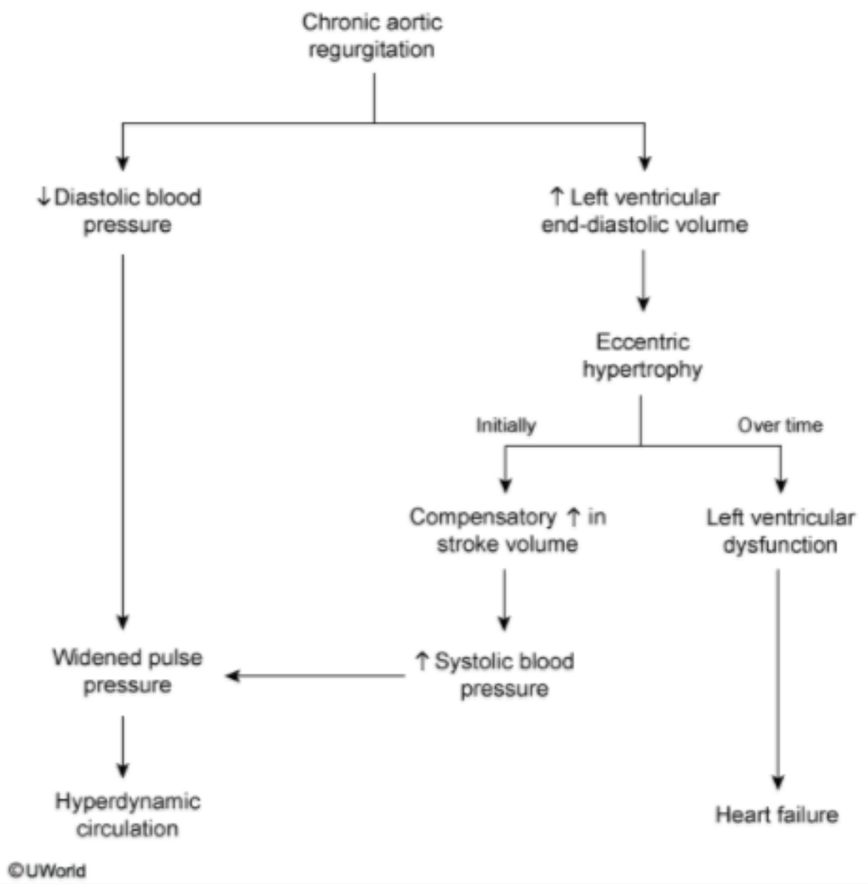

Zoom In | Zoom Out | Reset | Add To New Card | Existing Card

Pathophysiology | Cardiovascular System | Aortic regurgitation

off the aorta from the left ventricle at the end of systole leads to rapid loss of aortic pressure and an overall **decrease in diastolic blood pressure**. In addition, the left ventricle undergoes eccentric hypertrophy to initially compensate for an increase in left ventricular end-diastolic volume, which leads to increased stroke volume and cardiac output. Because pulse pressure (the difference between diastolic and systolic blood pressure) is proportional to stroke volume, the compensatory **increased stroke volume** on top of reduced diastolic pressure causes the characteristic **widened pulse pressure** seen with AR.

This high-amplitude pulsation with rapid diastolic collapse is responsible for the unusual pulsation findings in AR. Forceful pulsations in the intracranial arteries can cause **head bobbing** with each heart beat (de Musset sign), and patients may experience **palpitations** due to forceful left ventricular contraction. In addition, physical examination can show abrupt distension and collapse of the carotid arteries (Corrigan sign) and peripheral arteries ("water-hammer" pulse), and reveal "pistol-shot" femoral pulses (Traube sign) on auscultation.

(Choice A) Impaired left ventricular contractility occurs later in the course of AR and eventually leads to heart failure. Because head-bobbing and other characteristic findings in AR are due to increased stroke volume and high-amplitude, rapid rise-rapid fall pulsation, these findings are less prominent once impaired left ventricular contractility (and decreased stroke volume) sets in.

(Choices B and C) Left ventricular outflow tract obstruction, such as occurs with aortic stenosis, leads to reduced stroke volume and characteristic weak and delayed pulses (pulsus parvus et tardus). Restriction of left ventricular filling, as occurs in mitral stenosis, also reduces stroke volume due to reduced left ventricular end-diastolic volume (reduced preload). Clinical findings associated with high-amplitude pulsation will not be present with reduced stroke volume.

(Choice D) Combined systolic and diastolic hypertension is not necessarily accompanied by widened pulse pressure; the signs of high amplitude, rapid rise-rapid fall pulsation are more characteristic of chronic AR.

Educational objective:
Chronic aortic regurgitation (AR) causes a reduction in diastolic blood pressure and a compensatory increase in left ventricular stroke volume. These changes create a high-amplitude, rapid rise-rapid fall pulsation (ie, widened pulse pressure) and the other characteristic findings of AR (eg, head bobbing, "pistol-shot" femoral pulses).

Pathophysiology	Cardiovascular System	Aortic regurgitation
Subject	System	Topic

1
2
3
4
5
6
7
8
9
10
11
12
13
14
15
16
17
18
19
20
21
22
23
24
25
26
27
28
29
30
31

A group of researchers is studying population-based screening interventions to reduce mortality from abdominal aortic aneurysm. This disorder develops primarily in elderly patients and is often asymptomatic until an acute rupture event, which is frequently fatal. Screening of high-risk patients for abdominal aortic aneurysm is found to reduce mortality. Which of the following risk factor combinations would likely define the highest-risk group for screening purposes?

- A. Diabetes, smoking
- B. Female, hyperlipidemia
- C. Female, hypertension
- D. Hyperlipidemia, hypertension
- E. Male, diabetes
- F. Male, smoking

Submit

1
2
3
4
5
6
7
8
9
10
11
12
13
14
15
16
17
18
19
20
21
22
23
24
25
26
27
28
29
30
31

A group of researchers is studying population-based screening interventions to reduce mortality from abdominal aortic aneurysm. This disorder develops primarily in elderly patients and is often asymptomatic until an acute rupture event, which is frequently fatal. Screening of high-risk patients for abdominal aortic aneurysm is found to reduce mortality. Which of the following risk factor combinations would likely define the highest-risk group for screening purposes?

- A. Diabetes, smoking (12%)
- B. Female, hyperlipidemia (0%)
- C. Female, hypertension (2%)
- D. Hyperlipidemia, hypertension (36%)
- E. Male, diabetes (1%)
- ✓ F. Male, smoking (47%)

Omitted
Correct answer
F

47%
Answered correctly

02 secs
Time Spent

01/30/2020
Last Updated

Explanation

1
2
3
4
5
6
7
8
9
10
11
12
13
14
15
16
17
18
19
20
21
22
23
24
25
26
27
28
29
30
31

Focal dilation of the abdominal aorta >50% above normal (or >3 cm in diameter) is termed **abdominal aortic aneurysm** (AAA). AAA formation involves **transmural inflammation** of the aortic wall with subsequent apoptosis of smooth muscle cells and degradation of matrix proteins (eg, elastin, collagen). This causes progressive thinning of the aortic wall with secondary expansion of the lumen due to chronic hemodynamic stress. AAA is generally asymptomatic until aneurysm rupture, which typically presents with acute abdominal pain and hypotension; mortality of AAA rupture is 75%-90%.

Major **risk factors** for development of AAA include:

- Age >65
- **Smoking** (up to 15-fold risk increase)
- **Male sex**

Smoking appears to be associated with increased inflammatory infiltrates and formation of reactive oxygen species (eg, superoxide anion) in the aortic wall. In light of this, screening for AAA with ultrasonography is recommended for men age 65-75 who have ever smoked. The risk of rupture increases with aneurysm diameter, and surgical or endovascular repair is considered for aneurysms ≥5.5 cm in diameter.

(Choices A and E) Although diabetes mellitus increases the risk for atherosclerotic cardiovascular disease, the risk of AAA is lower in patients with diabetes, possibly due to the effects of glycosylation of matrix proteins in the aortic wall.

(Choices B and C) Female sex is associated with a lower risk of AAA, and the benefit of screening in women (including in women who smoke) has not been shown to outweigh the risks of overdiagnosis and potential treatment complications.

(Choice D) Hypertension is associated with an increased risk of aneurysm rupture, but the relation to aneurysm incidence and expansion is less clear. Although there is a broad coincidence of AAA and atherosclerosis, studies on an epidemiologic link between hyperlipidemia and AAA are mixed.

Educational objective:
Abdominal aortic aneurysm is focal dilation of the abdominal aorta >50% above normal (or >3 cm in diameter). It is generally asymptomatic until aneurysm rupture, which is frequently fatal. Risk factors include age >65, smoking, and male sex.

Pathophysiology Cardiovascular System Aortic aneurysm

AAA is generally asymptomatic until aneurysm rupture, which typically presents with acute abdominal pain and hypotension; mortality of AAA rupture is 75%-90%.

Major **risk factors** for development of AAA include:

- Age >65
- **Smoking** (up to 15-fold risk increase)
- **Male sex**

Smoking appears to be associated with increased inflammatory infiltrates and formation of reactive oxygen species (eg, superoxide anion) in the aortic wall. In light of this, screening for AAA with ultrasonography is recommended for men age 65-75 who have ever smoked. The risk of rupture increases with aneurysm diameter, and surgical or endovascular repair is considered for aneurysms ≥5.5 cm in diameter.

(Choices A and E) Although diabetes mellitus increases the risk for atherosclerotic cardiovascular disease, the risk of AAA is lower in patients with diabetes, possibly due to the effects of glycosylation of matrix proteins in the aortic wall.

(Choices B and C) Female sex is associated with a lower risk of AAA, and the benefit of screening in women (including in women who smoke) has not been shown to outweigh the risks of overdiagnosis and potential treatment complications.

(Choice D) Hypertension is associated with an increased risk of aneurysm rupture, but the relation to aneurysm incidence and expansion is less clear. Although there is a broad coincidence of AAA and atherosclerosis, studies on an epidemiologic link between hyperlipidemia and AAA are mixed.

Educational objective:
Abdominal aortic aneurysm is focal dilation of the abdominal aorta >50% above normal (or >3 cm in diameter). It is generally asymptomatic until aneurysm rupture, which is frequently fatal. Risk factors include age >65, smoking, and male sex.

Pathophysiology	Cardiovascular System	Aortic aneurysm
Subject	System	Topic

Copyright © UWorld. All rights reserved.

1
2
3
4
5
6
7
8
9
10
11
12
13
14
15
16
17
18
19
20
21
22
23
24
25
26
27
28
29
30
31

A 64-year-old woman who was discharged from the hospital 4 days ago comes to the emergency department due to chest tightness and severe shortness of breath. During evaluation, the patient becomes unresponsive and goes into cardiac arrest. Despite appropriate lifesaving measures, there is no return of spontaneous circulation and she is pronounced dead. Autopsy examination is performed, and the myocardial findings are shown in the image below (RV = right ventricle; LAD = left anterior descending coronary artery).

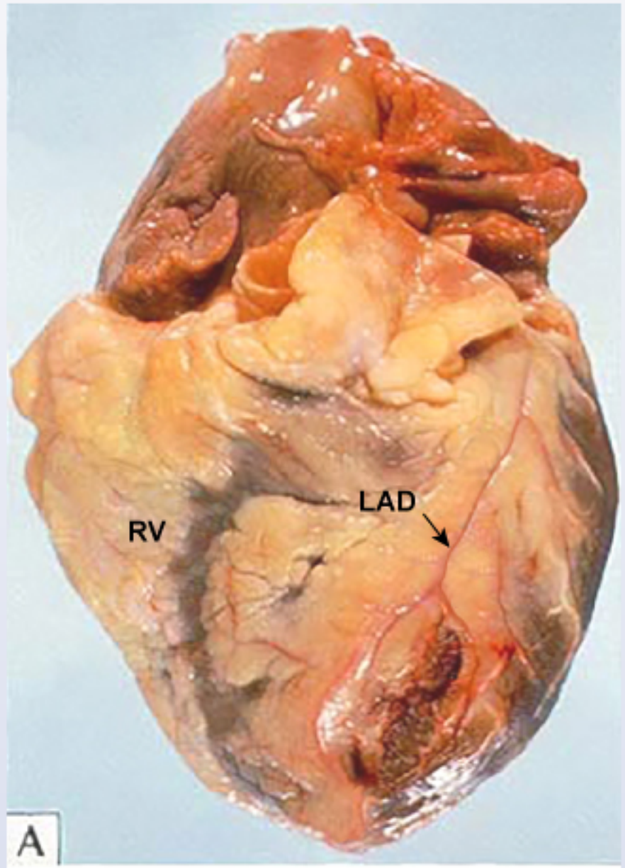

Displayed with permission from Springer Healthcare Ltd.
© Copyright 1995, 2005 by Current Medicine

1
2
3
4
5
6
7
8
9
10
11
12
13
14
15
16
17
18
19
20
21
22
23
24
25
26
27
28
29
30
31

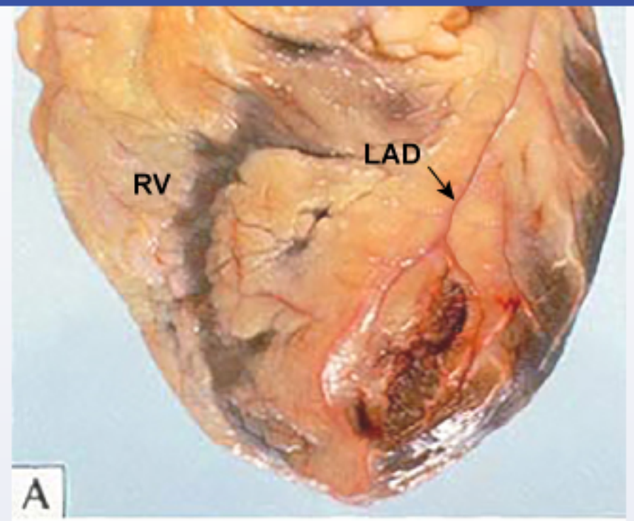

Displayed with permission from Springer Healthcare Ltd.
© Copyright 1995, 2005 by Current Medicine

Which of the following most likely predisposed this patient to the observed cardiac findings?

- A. Coronary atherosclerosis
- B. Prolonged alcohol consumption
- C. Recent viral infection
- D. Recurrent bacterial pharyngitis
- E. Repeated blood transfusions

Submit

1
2
3
4
5
6
7
8
9
10
11
12
13
14
15
16
17
18
19
20
21
22
23
24
25
26
27
28
29
30
31

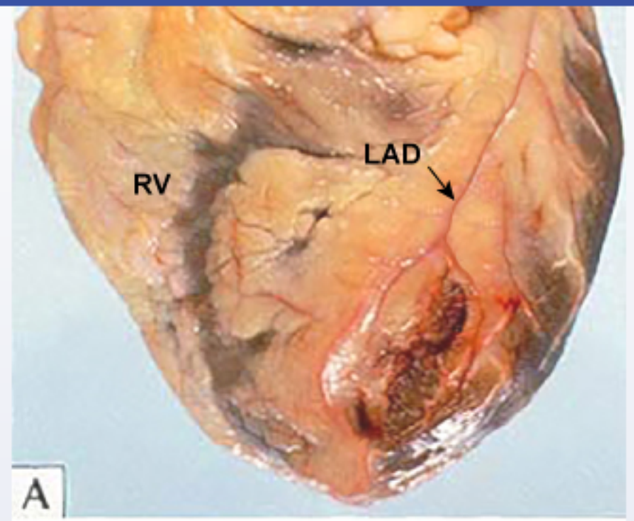

Displayed with permission from Springer Healthcare Ltd.
© Copyright 1995, 2005 by Current Medicine

Which of the following most likely predisposed this patient to the observed cardiac findings?

- ✓ A. Coronary atherosclerosis (90%)
- B. Prolonged alcohol consumption (2%)
- C. Recent viral infection (4%)
- D. Recurrent bacterial pharyngitis (1%)
- E. Repeated blood transfusions (1%)

Omitted
Correct answer

90%
Answered correctly

06 secs
Time Spent

02/02/2020
Last Updated

1
2
3
4
5
6
7
8
9
10
11
12
13
14
15
16
17
18
19
20
21
22
23
24
25
26
27
28
29
30
31

Mechanical complications of acute myocardial infarction		
Complication	**Time frame**	**Clinical findings**
Right ventricular failure	Acute	• Hypotension • Clear lungs • Kussmaul sign
Papillary muscle rupture	Acute or within 3-5 days	• Severe MR with flail leaflet • New holosystolic murmur • Severe pulmonary edema
Interventricular septal rupture	Acute or within 3-5 days	• Chest pain • New holosystolic murmur • Biventricular failure, shock • Step up in O_2 level from RA to RV
Ventricular free-wall rupture	Within 5 days or up to 2 weeks	• Chest pain • Tamponade, shock • Distant heart sounds
Left ventricular aneurysm	Within several months	• Subacute heart failure • Stable angina

MR = mitral regurgitation; **RA** = right atrium; **RV** = right ventricle.

This patient's autopsy reveals a slitlike tear in the anterior left ventricular (LV) wall that is consistent with **LV free-wall rupture**, an uncommon but devastating mechanical complication of **transmural myocardial infarction** (MI) that occurs **within 5 days** or **up to 2 weeks** following the event. She likely had significant **coronary atherosclerosis** and experienced a transmural (ST-segment elevation) MI during her previous hospitalization.

Following MI, the infarcted myocardium becomes akinetic and does not move with the remaining healthy myocardium, creating additional shear

MR = mitral regurgitation; RA = right atrium; RV = right ventricle.

This patient's autopsy reveals a slitlike tear in the anterior left ventricular (LV) wall that is consistent with **LV free-wall rupture**, an uncommon but devastating mechanical complication of **transmural myocardial infarction** (MI) that occurs **within 5 days** or **up to 2 weeks** following the event. She likely had significant **coronary atherosclerosis** and experienced a transmural (ST-segment elevation) MI during her previous hospitalization.

Following MI, the infarcted myocardium becomes akinetic and does not move with the remaining healthy myocardium, creating additional shear stress on the myocardial wall. Coagulative necrosis and enzymatic lysis of connective tissue also weaken the myocardial wall to the extent that it may be unable to contain the high LV pressures. If rupture occurs, it leads to abrupt filling of the pericardial space with blood and rapid development of **cardiac tamponade**. Patients can experience chest pain and shortness of breath followed by hypotension and shock that can rapidly progress to **cardiac arrest**.

(Choices B, C, and E) Prolonged alcohol consumption, recent viral infection, and repeated blood transfusions (ie, iron overload) are all potential causes of dilated cardiomyopathy. Dilated cardiomyopathy can lead to cardiac arrest and death via generation of a malignant arrhythmia (ie, ventricular tachycardia or fibrillation); however, autopsy is expected to reveal an enlarged heart with eccentric hypertrophy of the LV and no tears in the myocardium.

(Choice D) Recurrent bacterial pharyngitis can lead to recurrent episodes of rheumatic fever, which can cause inflammatory damage to both the myocardium and valvular endocardium. Death most commonly results from decompensated heart failure caused by valvular dysfunction; gross findings on autopsy are expected to show an enlarged heart with degenerated valves.

Educational objective:
Left ventricular (LV) free-wall rupture is an uncommon but devastating mechanical complication of transmural myocardial infarction that occurs within 5 days or up to 2 weeks following the event. Rupture leads to cardiac tamponade that causes hypotension and shock with rapid progression to cardiac arrest. Autopsy typically reveals a slitlike tear at the site of infarction in the LV wall.

Pathophysiology	Cardiovascular System	Myocardial infarction
Subject	System	Topic

Copyright © UWorld. All rights reserved.

MR = mitral regurgitation; RA = right atrium; RV = right ventricle.

Exhibit Display

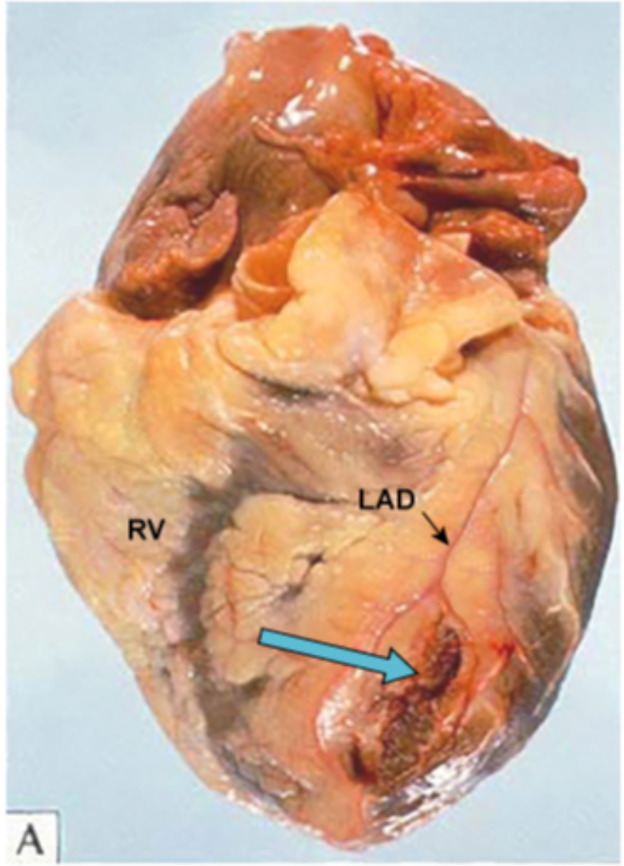

Displayed with permission from Springer Healthcare Ltd.
© Copyright 1995, 2005 by Current Medicine

Zoom In | Zoom Out | Reset | Add To New Card | Existing Card

1
2
3
4
5
6
7
8
9
10
11
12
13
14
15
16
17
18
19
20
21
22
23
24
25
26
27
28
29
30
31

A 32-year-old woman comes to the office due to progressive exertional dyspnea and easy fatigability. She immigrated to the United States from India several years ago and reports a history of rheumatic fever during her childhood. Cardiac auscultation reveals a diastolic high-frequency sound and a rumbling diastolic murmur heard best in the left fifth intercostal space at the midclavicular line. Cardiac catheterization is performed for hemodynamic evaluation, and the results are represented below. Timing of the high-frequency sound heard during cardiac auscultation of this patient best corresponds to which of the following letters?

A. A
B. B
C. C
D. D
E. E

Submit

1
2
3
4
5
6
7
8
9
10
11
12
13
14
15
16
17
18
19
20
21
22
23
24
25
26
27
28
29
30
31

A 32-year-old woman comes to the office due to progressive exertional dyspnea and easy fatigability. She immigrated to the United States from India several years ago and reports a history of rheumatic fever during her childhood. Cardiac auscultation reveals a diastolic high-frequency sound and a rumbling diastolic murmur heard best in the left fifth intercostal space at the midclavicular line. Cardiac catheterization is performed for hemodynamic evaluation, and the results are represented below. Timing of the high-frequency sound heard during cardiac auscultation of this patient best corresponds to which of the following letters?

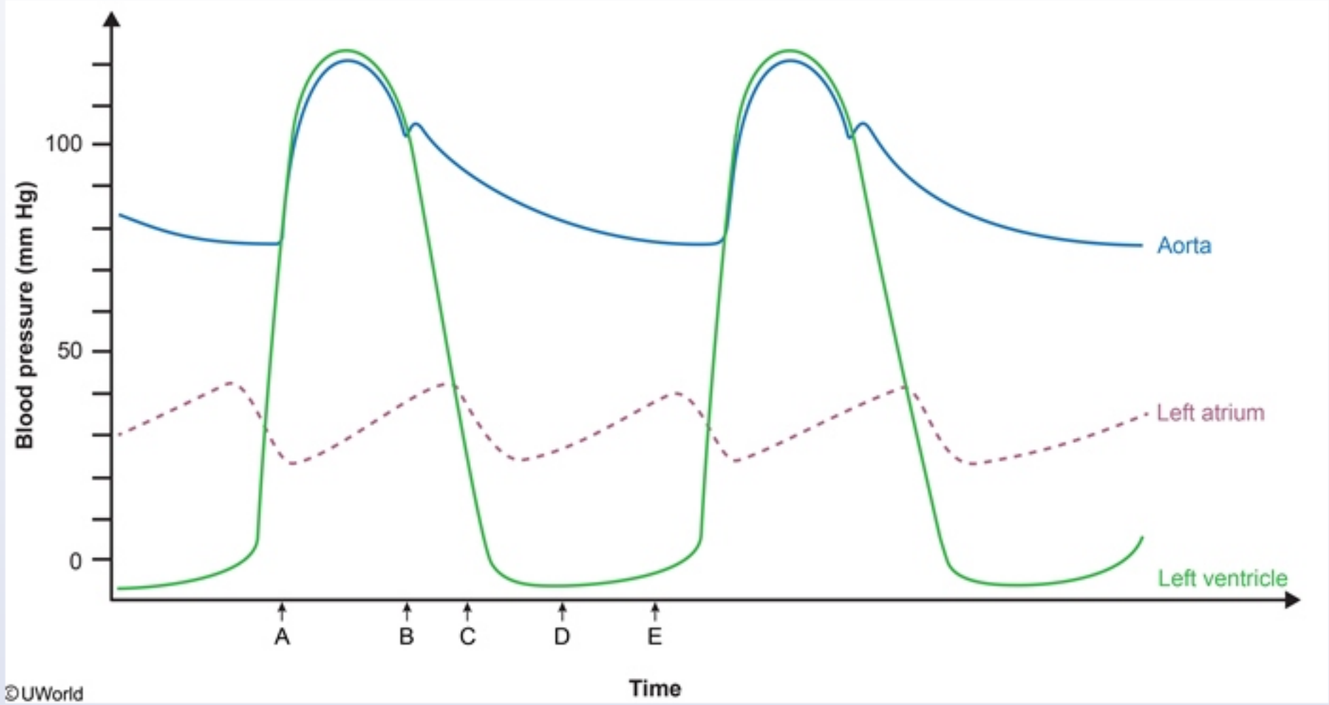

A. A

B. B

C. C

1
2
3
4
5
6
7
8
9
10
11
12
13
14
15
16
17
18
19
20
21
22
23
24
25
26
27
28
29
30
31

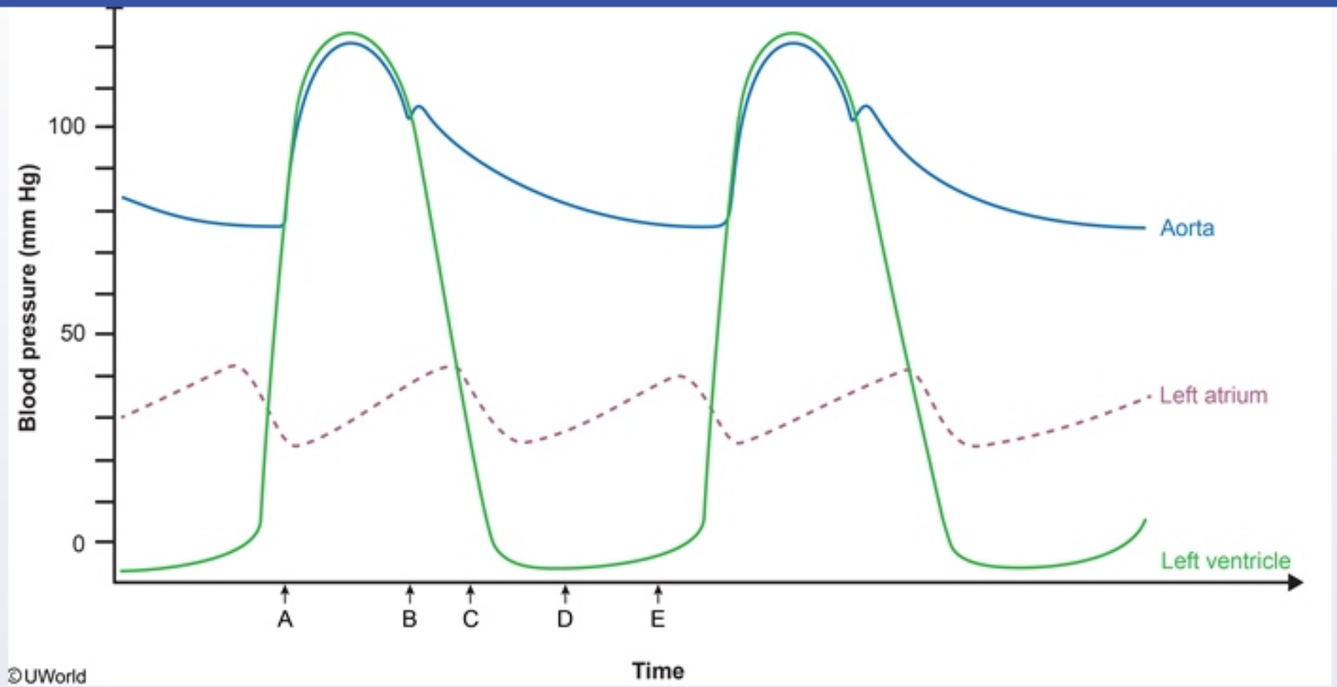

A. A

B. B

C. C

D. D

E. E

Submit

1
2
3
4
5
6
7
8
9
10
11
12
13
14
15
16
17
18
19
20
21
22
23
24
25
26
27
28
29
30
31

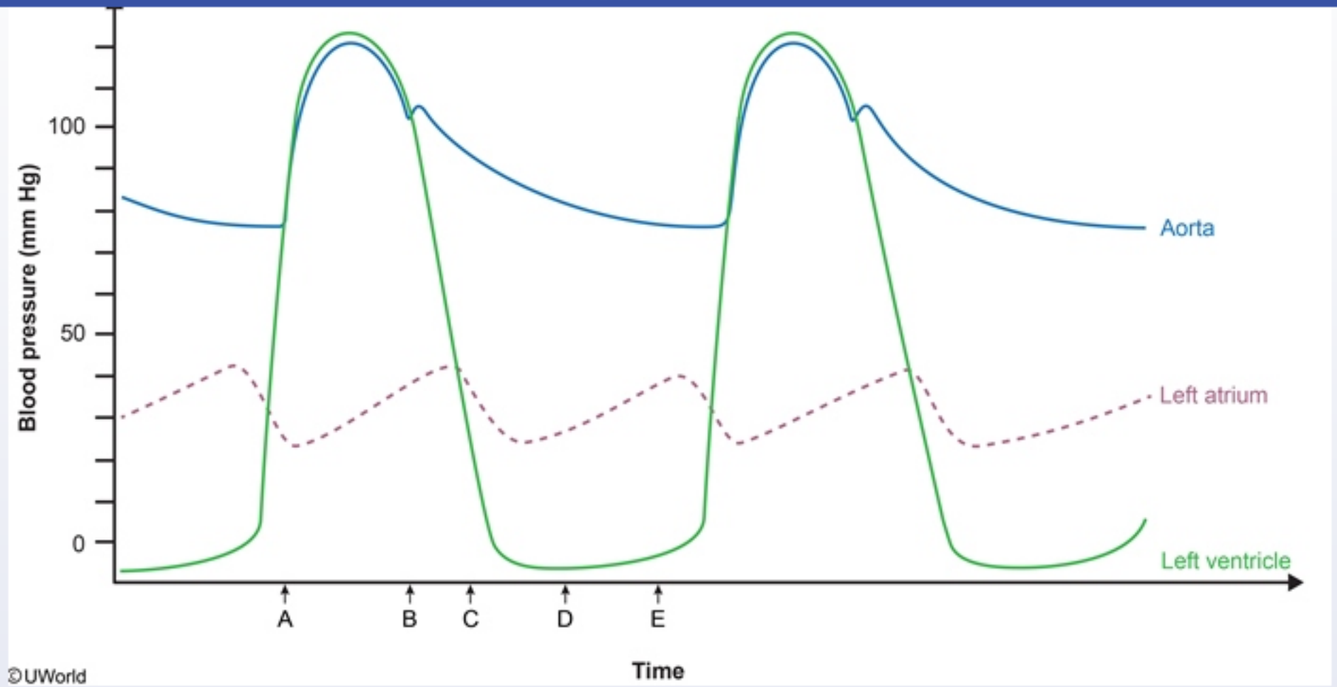

A. A (11%)

B. B (7%)

✓ C. C (43%)

D. D (24%)

E. E (13%)

Omitted
Correct answer

43%
Answered correctly

05 secs
Time Spent

05/13/2020
Last Updated

1
2
3
4
5
6
7
8
9
10
11
12
13
14
15
16
17
18
19
20
21
22
23
24
25
26
27
28
29
30
31

Mitral stenosis

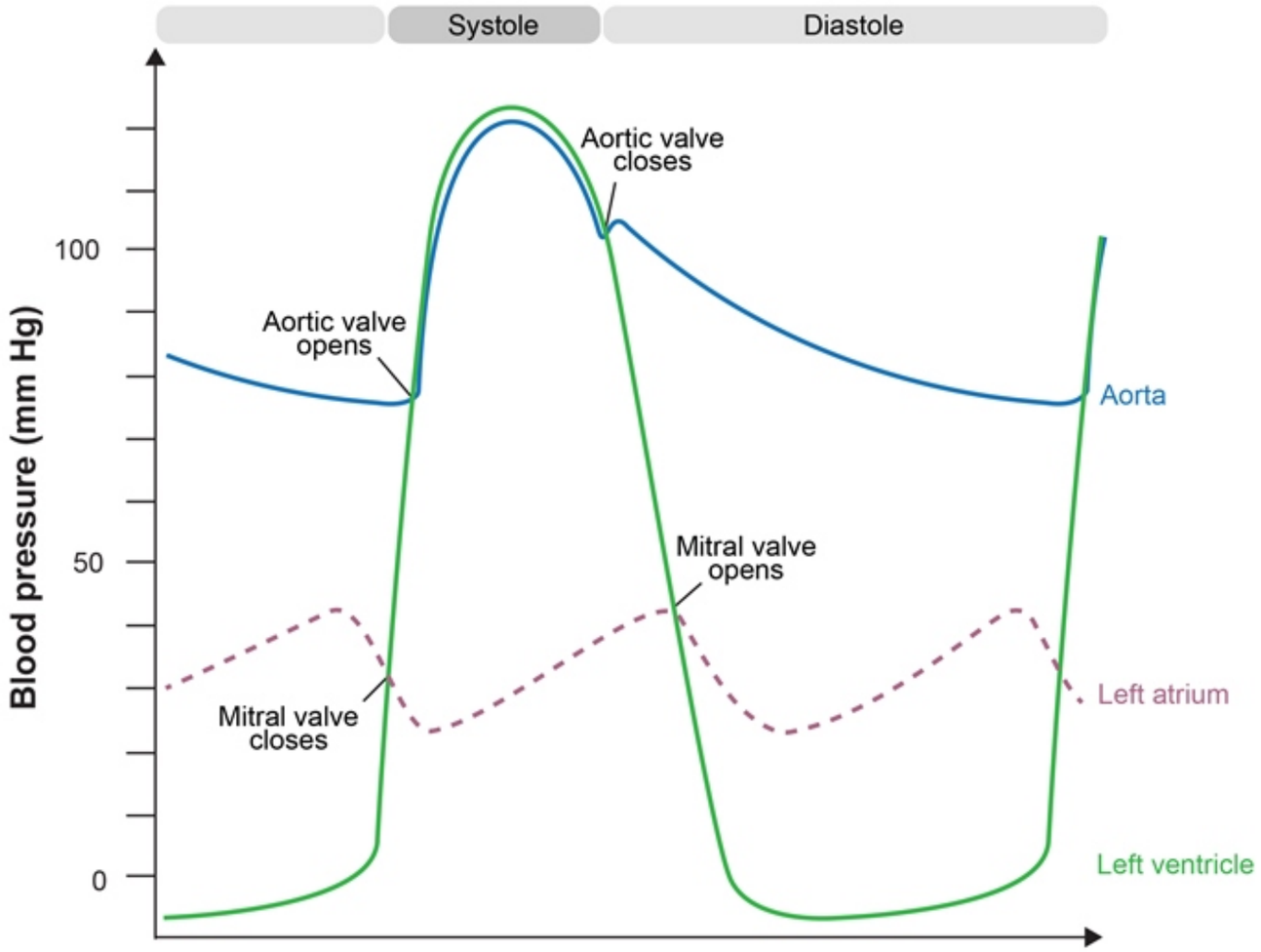

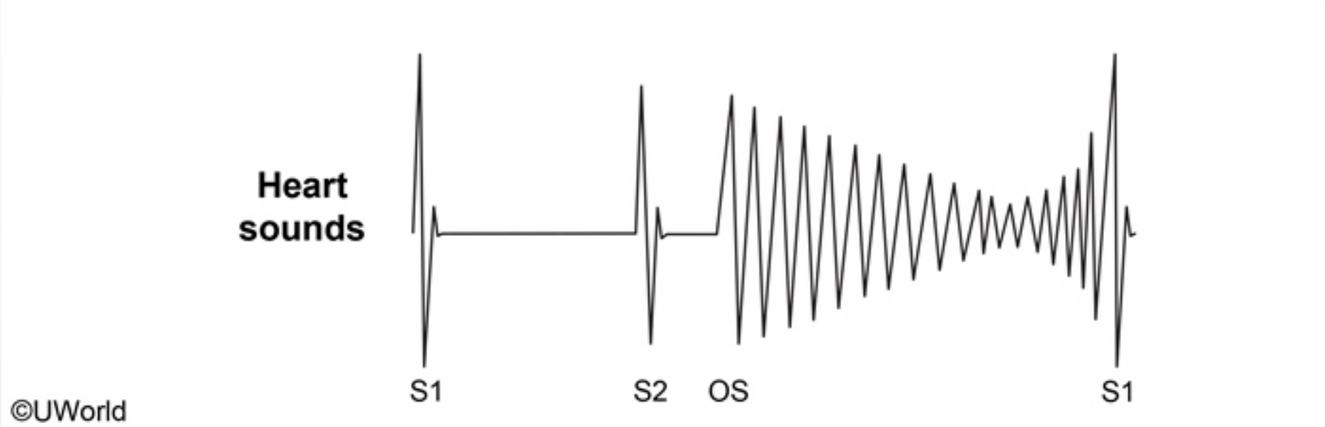

This patient with a history of rheumatic fever now presenting with exertional dyspnea and a diastolic murmur at the cardiac apex most likely has **mitral stenosis**. In comparison to normal tracings, hemodynamic tracings in patients with mitral stenosis typically reveal an elevated pressure gradient between the left atrial and left ventricular end-diastolic pressure.

Classic physical examination findings include a loud first heart sound (S1), an early diastolic high-frequency **opening snap** after the second heart sound (S2), and a low-pitched **diastolic rumble**. These findings are best heard at the **cardiac apex** using the bell of the stethoscope with the patient lying on the left side in held expiration.

Left ventricular pressure falls rapidly during isovolumetric relaxation. The opening snap is caused by the sudden opening of the mitral valve leaflets when the left ventricular diastolic pressure falls below the left atrial pressure at the beginning of diastole. As mitral stenosis becomes more severe, the opening snap occurs earlier after S2.

(Choice A) This point corresponds to the opening of the aortic valve at the end of isovolumetric ventricular contraction in early systole when the left ventricular pressure exceeds the central aortic pressure. This correlates with the timing of an aortic ejection murmur that may be heard in patients with aortic stenosis (eg, due to a calcified bicuspid aortic valve).

(Choice B) This point corresponds to the closure of the aortic valve at the end of systole, producing the aortic component of S2. The aortic valve closes as soon as left ventricular pressure drops below the aortic pressure.

(Choice D) This is a random point in diastole when the mitral valve is already maximally open and there is passive filling of the left ventricular

This patient with a history of rheumatic fever now presenting with exertional dyspnea and a diastolic murmur at the cardiac apex most likely has **mitral stenosis**. In comparison to normal tracings, hemodynamic tracings in patients with mitral stenosis typically reveal an elevated pressure gradient between the left atrial and left ventricular end-diastolic pressure.

Classic physical examination findings include a loud first heart sound (S1), an early diastolic high-frequency **opening snap** after the second heart sound (S2), and a low-pitched **diastolic rumble**. These findings are best heard at the **cardiac apex** using the bell of the stethoscope with the patient lying on the left side in held expiration.

Left ventricular pressure falls rapidly during isovolumetric relaxation. The opening snap is caused by the sudden opening of the mitral valve leaflets when the left ventricular diastolic pressure falls below the left atrial pressure at the beginning of diastole. As mitral stenosis becomes more severe, the opening snap occurs earlier after S2.

(Choice A) This point corresponds to the opening of the aortic valve at the end of isovolumetric ventricular contraction in early systole when the left ventricular pressure exceeds the central aortic pressure. This correlates with the timing of an aortic ejection murmur that may be heard in patients with aortic stenosis (eg, due to a calcified bicuspid aortic valve).

(Choice B) This point corresponds to the closure of the aortic valve at the end of systole, producing the aortic component of S2. The aortic valve closes as soon as left ventricular pressure drops below the aortic pressure.

(Choice D) This is a random point in diastole when the mitral valve is already maximally open and there is passive filling of the left ventricular cavity (diastasis). In patients with mitral stenosis, the elevated pressure gradient between the left atrium and left ventricle during diastole causes the mid-diastolic rumble.

(Choice E) This point roughly corresponds to the onset of atrial contraction during late ventricular diastole. In patients in sinus rhythm, atrial contraction causes an increase in the intensity of the diastolic murmur just before S1, a phenomenon termed "presystolic accentuation."

Educational objective:
Cardiac auscultation in patients with mitral stenosis reveals a loud first heart sound, an early diastolic opening snap after the second heart sound, and a low-pitched diastolic rumble best heard at the cardiac apex. The opening snap is caused by the sudden opening of the mitral valve leaflets when the left ventricular pressure falls below the left atrial pressure at the beginning of diastole.

References

- Mitral stenosis

1 2 3 4 5 6 7 8 9 10 11 12 13 14 15 16 17 18 19 20 21 22 23 24 25 26 27 28 29 30 31

Left ventricular pressure falls rapidly during isovolumetric relaxation. The opening snap is caused by the sudden opening of the mitral valve leaflets when the left ventricular diastolic pressure falls below the left atrial pressure at the beginning of diastole. As mitral stenosis becomes more severe, the opening snap occurs earlier after S2.

(Choice A) This point corresponds to the opening of the aortic valve at the end of isovolumetric ventricular contraction in early systole when the left ventricular pressure exceeds the central aortic pressure. This correlates with the timing of an aortic ejection murmur that may be heard in patients with aortic stenosis (eg, due to a calcified bicuspid aortic valve).

(Choice B) This point corresponds to the closure of the aortic valve at the end of systole, producing the aortic component of S2. The aortic valve closes as soon as left ventricular pressure drops below the aortic pressure.

(Choice D) This is a random point in diastole when the mitral valve is already maximally open and there is passive filling of the left ventricular cavity (diastasis). In patients with mitral stenosis, the elevated pressure gradient between the left atrium and left ventricle during diastole causes the mid-diastolic rumble.

(Choice E) This point roughly corresponds to the onset of atrial contraction during late ventricular diastole. In patients in sinus rhythm, atrial contraction causes an increase in the intensity of the diastolic murmur just before S1, a phenomenon termed "presystolic accentuation."

Educational objective:
Cardiac auscultation in patients with mitral stenosis reveals a loud first heart sound, an early diastolic opening snap after the second heart sound, and a low-pitched diastolic rumble best heard at the cardiac apex. The opening snap is caused by the sudden opening of the mitral valve leaflets when the left ventricular pressure falls below the left atrial pressure at the beginning of diastole.

References

- Mitral stenosis.

Pathophysiology	Cardiovascular System	Mitral stenosis
Subject	System	Topic

Copyright © UWorld. All rights reserved.

Mitral valve closes

Exhibit Display

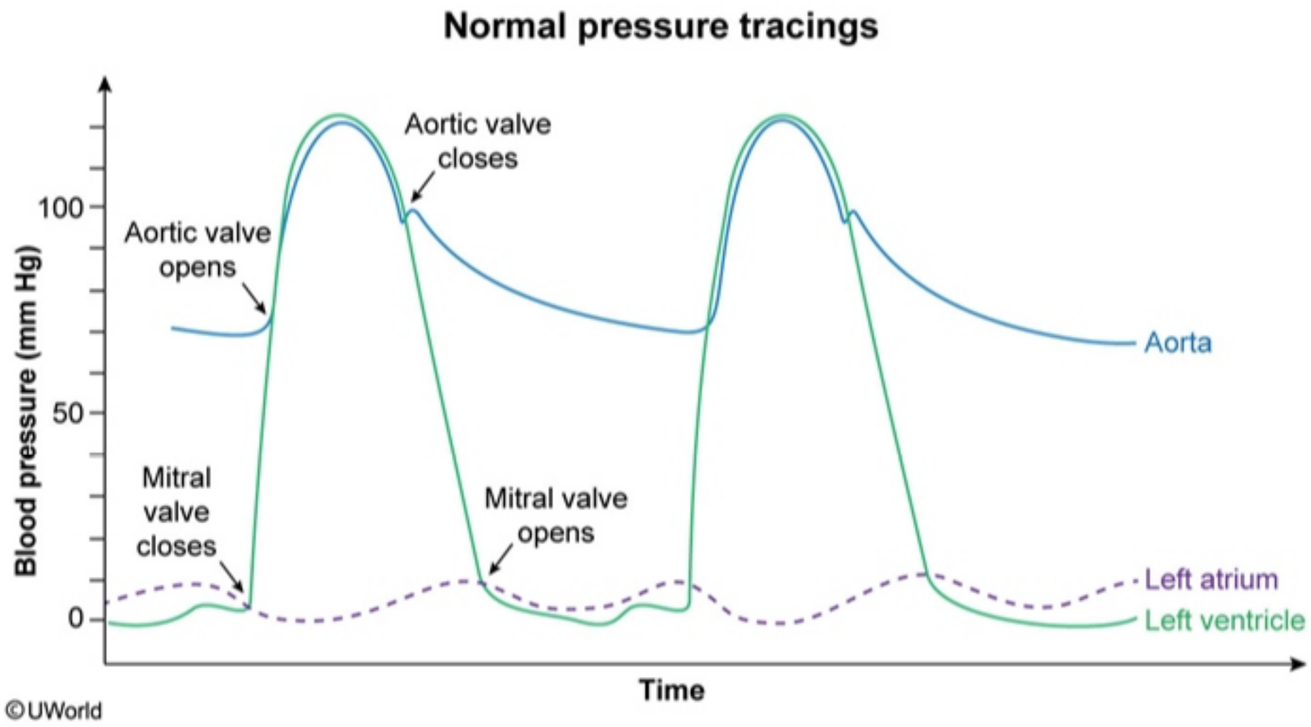

Zoom In | Zoom Out | Reset | Add To New Card | Existing Card

(Choice A) This point corresponds to the opening of the aortic valve at the end of isovolumetric ventricular contraction in early systole when the

1
2
3
4
5
6
7
8
9
10
11
12
13
14
15
16
17
18
19
20
21
22
23
24
25
26
27
28
29
30
31

Cellular physiologists are investigating the mechanisms of contraction cessation in cardiomyocytes in response to ischemic injury. In an animal experiment, the left anterior descending coronary artery is ligated at time 0, and changes in ATP levels within the affected myocardial cells are recorded. At which point on the graph does the affected portion of the myocardium stop contracting?

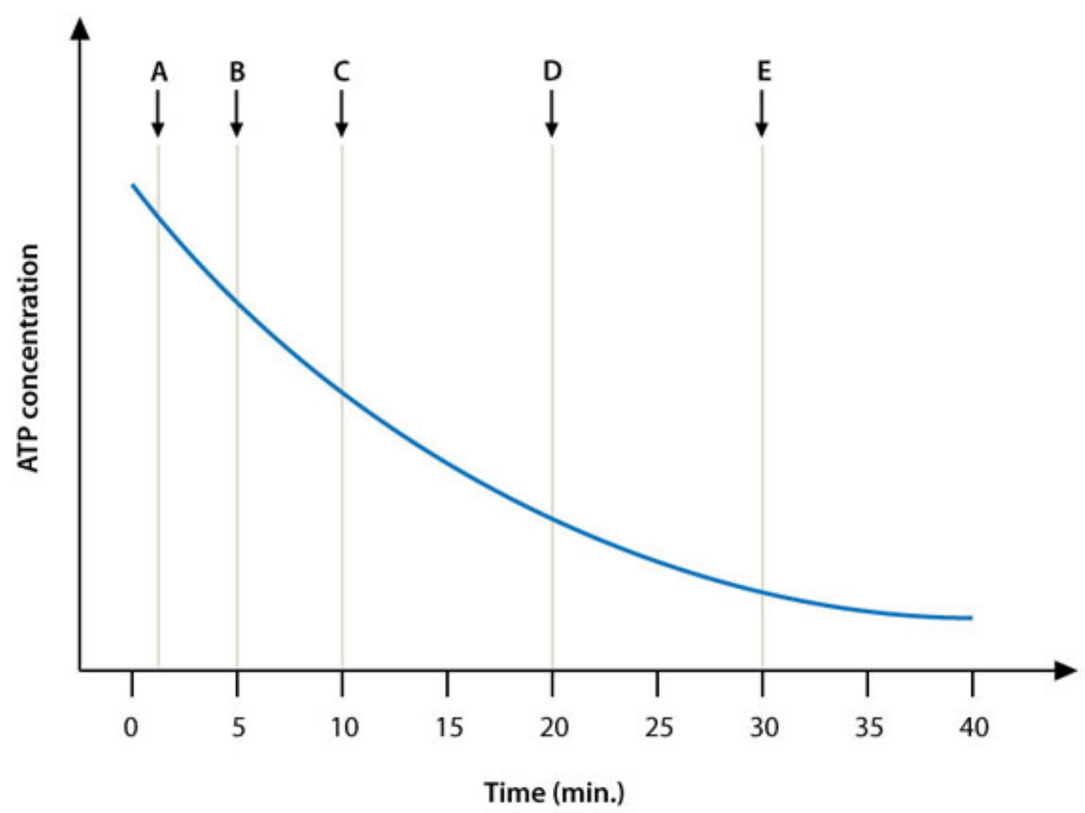

A. A

B. B

C. C

1
2
3
4
5
6
7
8
9
10
11
12
13
14
15
16
17
18
19
20
21
22
23
24
25
26
27
28
29
30
31

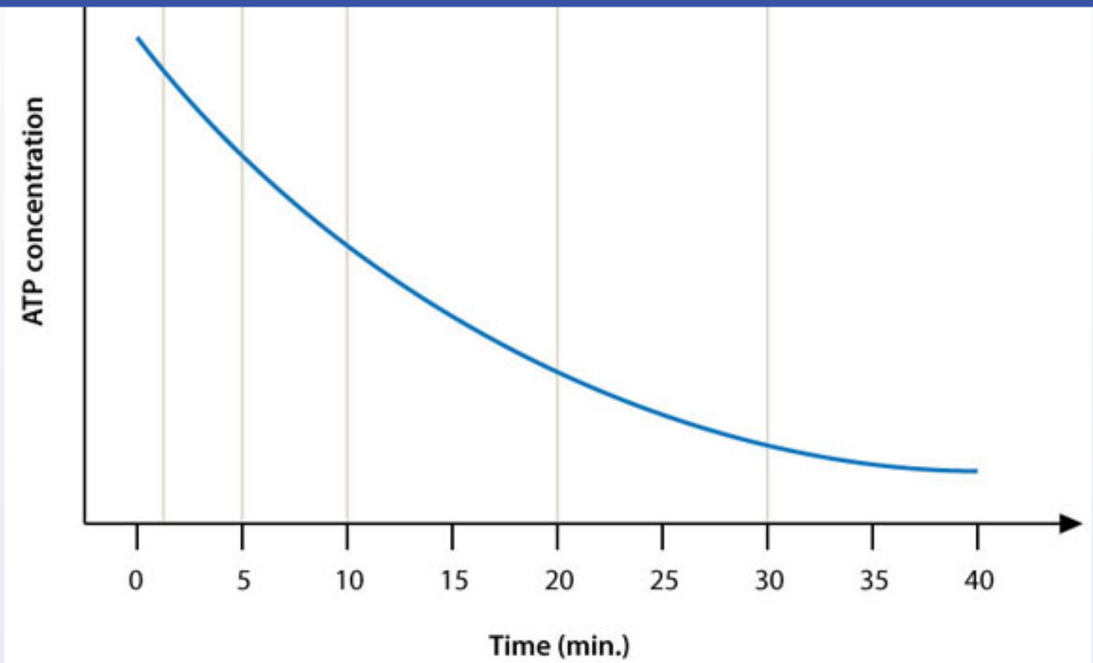

A. A

B. B

C. C

D. D

E. E

Submit

1
2
3
4
5
6
7
8
9
10
11
12
13
14
15
16
17
18
19
20
21
22
23
24
25
26
27
28
29
30
31

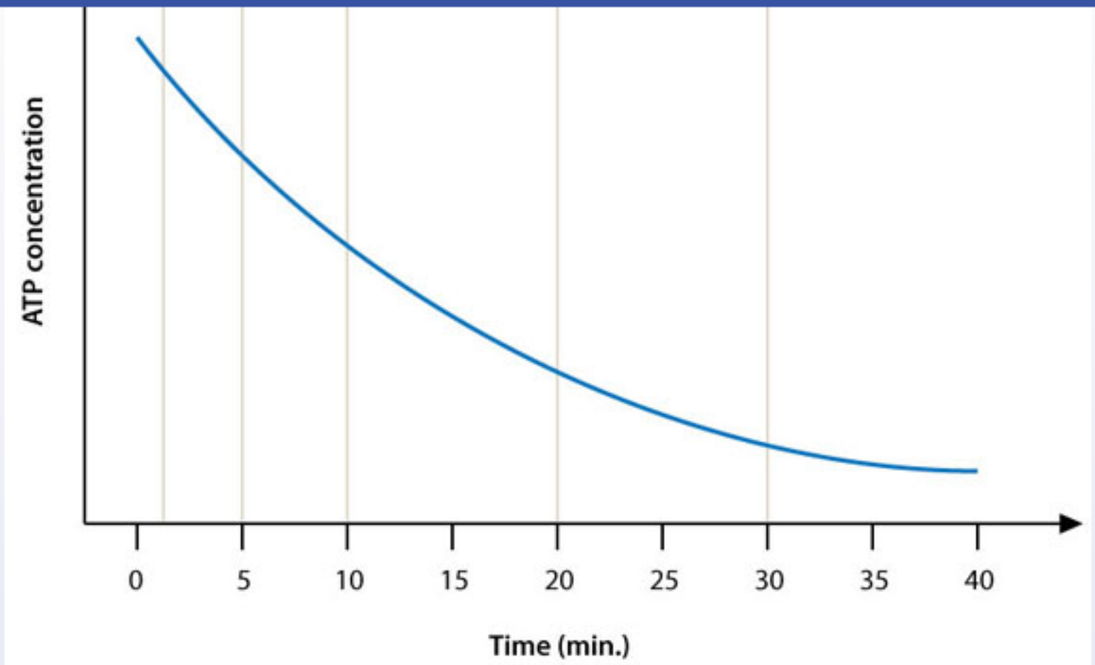

- ✓ A. A (25%)
- B. B (11%)
- C. C (13%)
- D. D (25%)
- E. E (24%)

Omitted
Correct answer

25%
Answered correctly

06 secs
Time Spent

06/14/2020
Last Updated

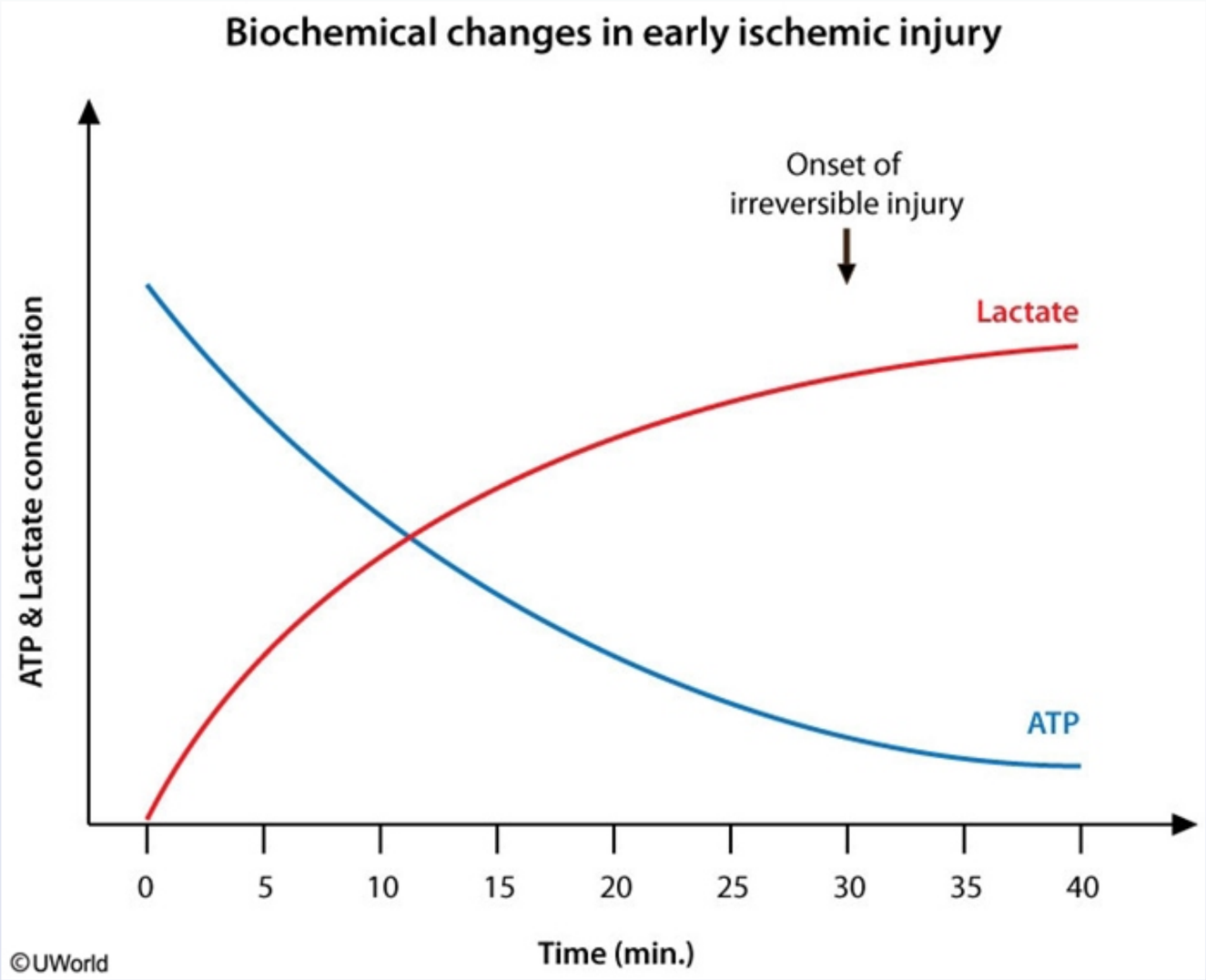

The major early biochemical consequence of total myocardial ischemia is cessation of aerobic glycolysis and initiation of anaerobic glycolysis. This transition occurs within seconds and results in inadequate production of high-energy phosphates (eg, ATP and creatine phosphate) and the

The major early biochemical consequence of total myocardial ischemia is cessation of aerobic glycolysis and initiation of anaerobic glycolysis. This transition occurs within seconds and results in inadequate production of high-energy phosphates (eg, ATP and creatine phosphate) and the accumulation of deleterious metabolites, including lactate. Although total ATP levels remain relatively normal during the first few minutes of ischemia, ATP is rapidly depleted from areas of the cell with high metabolic demand, such as the cytosol surrounding the contraction fibers and electrolyte transport pumps. The depletion of ATP in critical cellular areas and the accumulation of toxins result in loss of contractility within about 60 seconds of total myocardial ischemia **(Choice A)**.

As ischemia persists, ATP levels within the affected cardiac myocytes continue to fall while lactate levels continue to rise. When ischemia lasts less than 30 minutes, loss of contractile function is reversible. However, on restoration of blood flow, full myocardial contractility is not immediately restored. Instead, there is prolonged dysfunction of the myocardium (myocardial stunning), with contractility gradually returning to normal over the next several hours to days. Increasing durations of ischemia prolong the time that the myocardium remains stunned.

Under hypoxic conditions, ATP within cardiomyocytes is degraded to ADP, AMP, and eventually adenosine. Adenosine is able to cross the cell membrane and function as a vasodilator when coronary blood flow is insufficient to meet myocardial demand. However, persistent ischemia can lead to depletion of massive amounts of adenosine. After 30 minutes of total myocardial ischemia, about half of the cellular adenine stores are lost. At this point, failure of cellular homeostasis is inevitable and ischemic injury becomes irreversible **(Choice E)**.

Educational objective:
Loss of cardiomyocyte contractility occurs within 60 seconds after the onset of total ischemia. When ischemia lasts less than 30 minutes, restoration of blood flow leads to reversible contractile dysfunction (myocardial stunning), with contractility gradually returning to normal over the next several hours to days. However, after about 30 minutes of total ischemia, ischemic injury becomes irreversible.

Pathophysiology	Cardiovascular System	Myocardial infarction
Subject	System	Topic

Copyright © UWorld. All rights reserved.

1
2
3
4
5
6
7
8
9
10
11
12
13
14
15
16
17
18
19
20
21
22
23
24
25
26
27
28
29
30
31

This item has associated media that may require the use of headphones. Please ensure your system/speaker volume is set to an audible level.

A 23-year-old female immigrant from Cambodia complains of exertional dyspnea. She has an occasional dry cough, but denies any chest pain, palpitations, or syncope. She had bilateral knee swelling as a child. Cardiac auscultation over the apex can be heard below. Which of the following is the most likely cause of this patient's complaints?

Play Media

A. Ascending aortic aneurysm
B. Atrial septal defect
C. Bicuspid aortic valve
D. Mitral regurgitation
E. Mitral stenosis

Submit

This item has associated media that may require the use of headphones. Please ensure your system/speaker volume is set to an audible level.

A 23-year-old female immigrant from Cambodia complains of exertional dyspnea. She has an occasional dry cough, but denies any chest pain, palpitations, or syncope. She had bilateral knee swelling as a child. Cardiac auscultation over the apex can be heard below. Which of the following is the most likely cause of this patient's complaints?

Play Media

A. Ascending aortic aneurysm (0%)
B. Atrial septal defect (4%)
C. Bicuspid aortic valve (6%)
✓ D. Mitral regurgitation (63%)
E. Mitral stenosis (24%)

Omitted
Correct answer
D

63%
Answered correctly

03 secs
Time Spent

05/13/2020
Last Updated

Explanation

The auscultatory findings heard above are classic for mitral regurgitation (MR), which is characteristically described as a blowing, holosystolic murmur heard best over the cardiac apex with radiation to the axilla. Given the remaining history for this patient (including the knee swelling she had as a child), it is most likely that her MR is a result of rheumatic heart disease. Although uncommon in developed countries, rheumatic heart

The auscultatory findings heard above are classic for mitral regurgitation (MR), which is characteristically described as a blowing, holosystolic murmur heard best over the cardiac apex with radiation to the axilla. Given the remaining history for this patient (including the knee swelling she had as a child), it is most likely that her MR is a result of rheumatic heart disease. Although uncommon in developed countries, rheumatic heart disease is still a prominent disease in the rest of the world, including Cambodia as in this case. Patients afflicted with rheumatic heart disease in these countries almost always have significant mitral valve disease. Rheumatic mitral valve disease typically presents as MR within the first few decades of life. Mitral stenosis can also occur in rheumatic heart disease, and patients presenting with such are generally middle-aged. In older patients, mixed mitral disease (stenosis and regurgitation) becomes increasingly frequent.

(Choice A) Patients with an ascending aortic aneurysm may develop aortic regurgitation secondary to aortic root dilatation. Aortic regurgitation results in an early diastolic murmur as opposed to the systolic murmur in this case.

(Choice B) Although many patients with an atrial septal defect (ASD) do not have an audible murmur, those with an increased left-to-right shunt across the ASD may have a systolic ejection murmur from increased flow across the pulmonary valve. This patient's murmur and history is much more suggestive of MR.

(Choice C) A bicuspid aortic valve is commonly associated with aortic stenosis, which classically causes a mid-systolic ejection murmur best heard over the right second intercostal space with radiation to the neck.

(Choice E) As opposed to the holosystolic murmur caused by MR, mitral stenosis would result in an opening snap at the beginning of diastole with a low-pitched, mid-diastolic rumbling murmur heard best at the cardiac apex.

Educational objective:
Mitral regurgitation results in a blowing, holosystolic murmur heard best over the cardiac apex with radiation to the axilla. Rheumatic heart disease is a very common cause of mitral regurgitation in underdeveloped countries.

Pathophysiology	Cardiovascular System	Mitral regurgitation
Subject	System	Topic

Copyright © UWorld. All rights reserved.

1
2
3
4
5
6
7
8
9
10
11
12
13
14
15
16
17
18
19
20
21
22
23
24
25
26
27
28
29
30
31

A 72-year-old man is hospitalized due to fatigue, orthopnea, and exertional dyspnea. The patient takes no medications and has not seen a physician in many years. He is a lifelong nonsmoker. His blood pressure is 110/60 mm Hg and pulse is 64/min. Examination reveals bibasilar crackles, elevated jugular venous pressure, and bilateral lower extremity pitting edema. His left ventricular end-diastolic pressure-volume is shown in the graph below (purple curve).

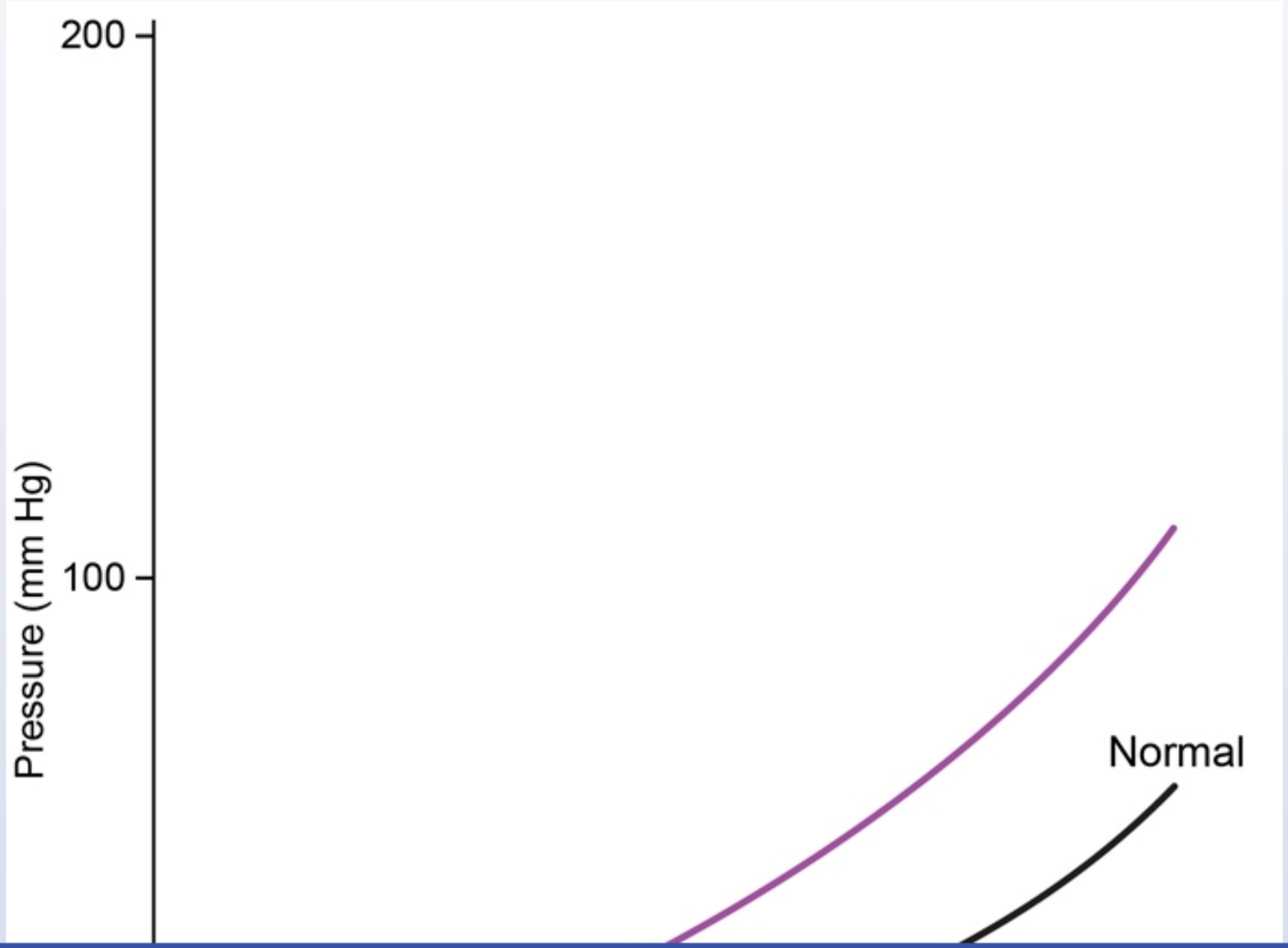

1
2
3
4
5
6
7
8
9
10
11
12
13
14
15
16
17
18
19
20
21
22
23
24
25
26
27
28
29
30
31

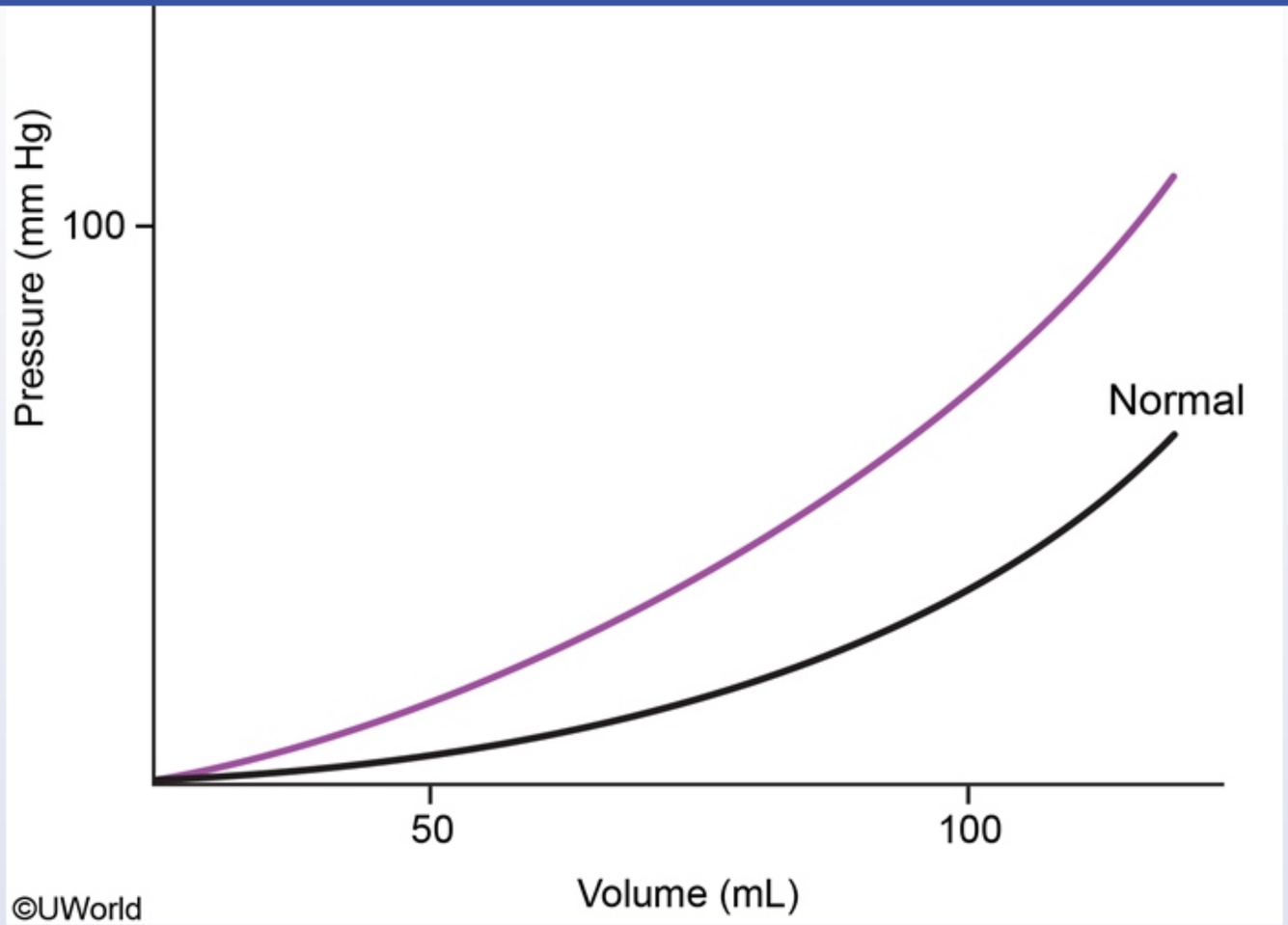

Which of the following is the most likely cause of this patient's condition?

A. Alcoholic cardiomyopathy

B. High-dose doxorubicin therapy

C. Selenium deficiency

1
2
3
4
5
6
7
8
9
10
11
12
13
14
15
16
17
18
19
20
21
22
23
24
25
26
27
28
29
30
31

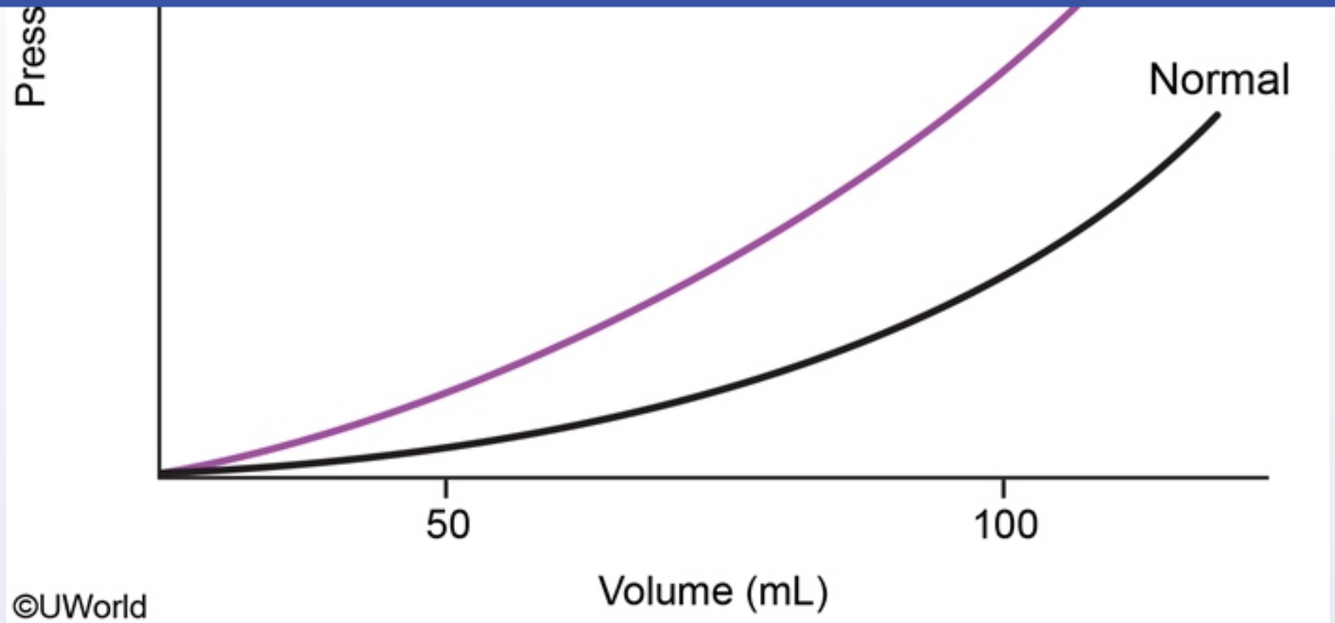

Which of the following is the most likely cause of this patient's condition?

- A. Alcoholic cardiomyopathy
- B. High-dose doxorubicin therapy
- C. Selenium deficiency
- D. Transthyretin deposition
- E. Viral myocarditis

Submit

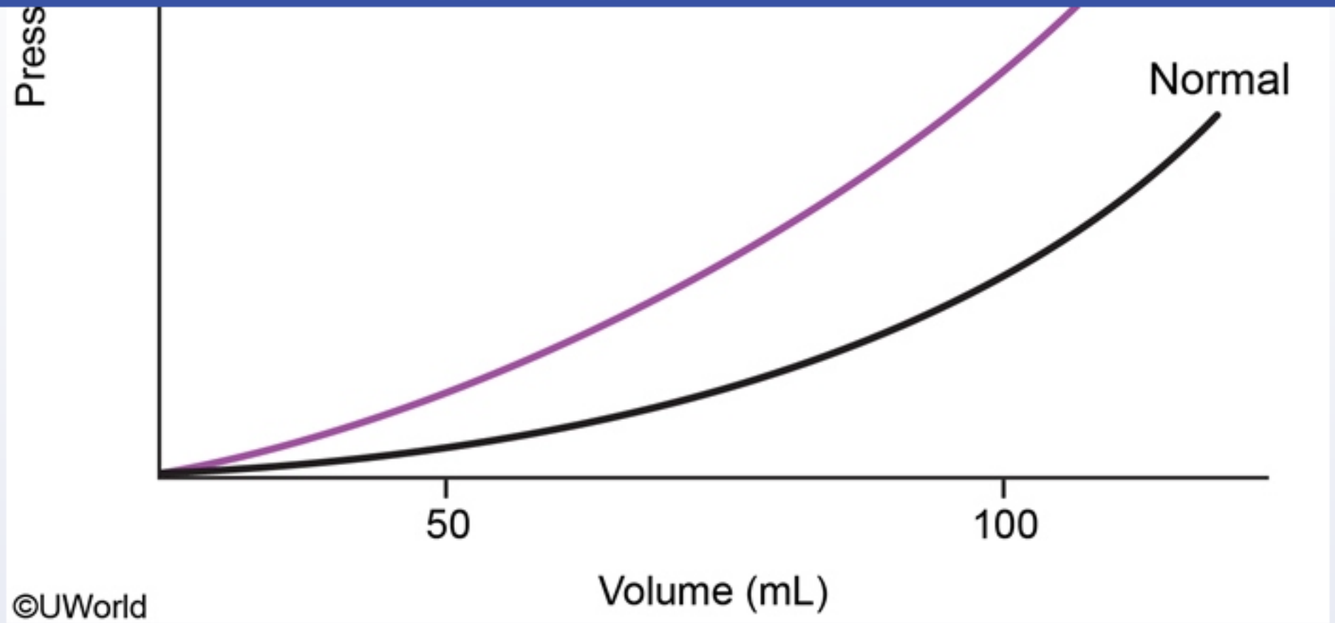

Which of the following is the most likely cause of this patient's condition?

- A. Alcoholic cardiomyopathy (21%)
- B. High-dose doxorubicin therapy (11%)
- C. Selenium deficiency (3%)
- ✓ D. Transthyretin deposition (48%)
- E. Viral myocarditis (14%)

Omitted
Correct answer

48%
Answered correctly

08 secs
Time Spent

03/18/2020
Last Updated

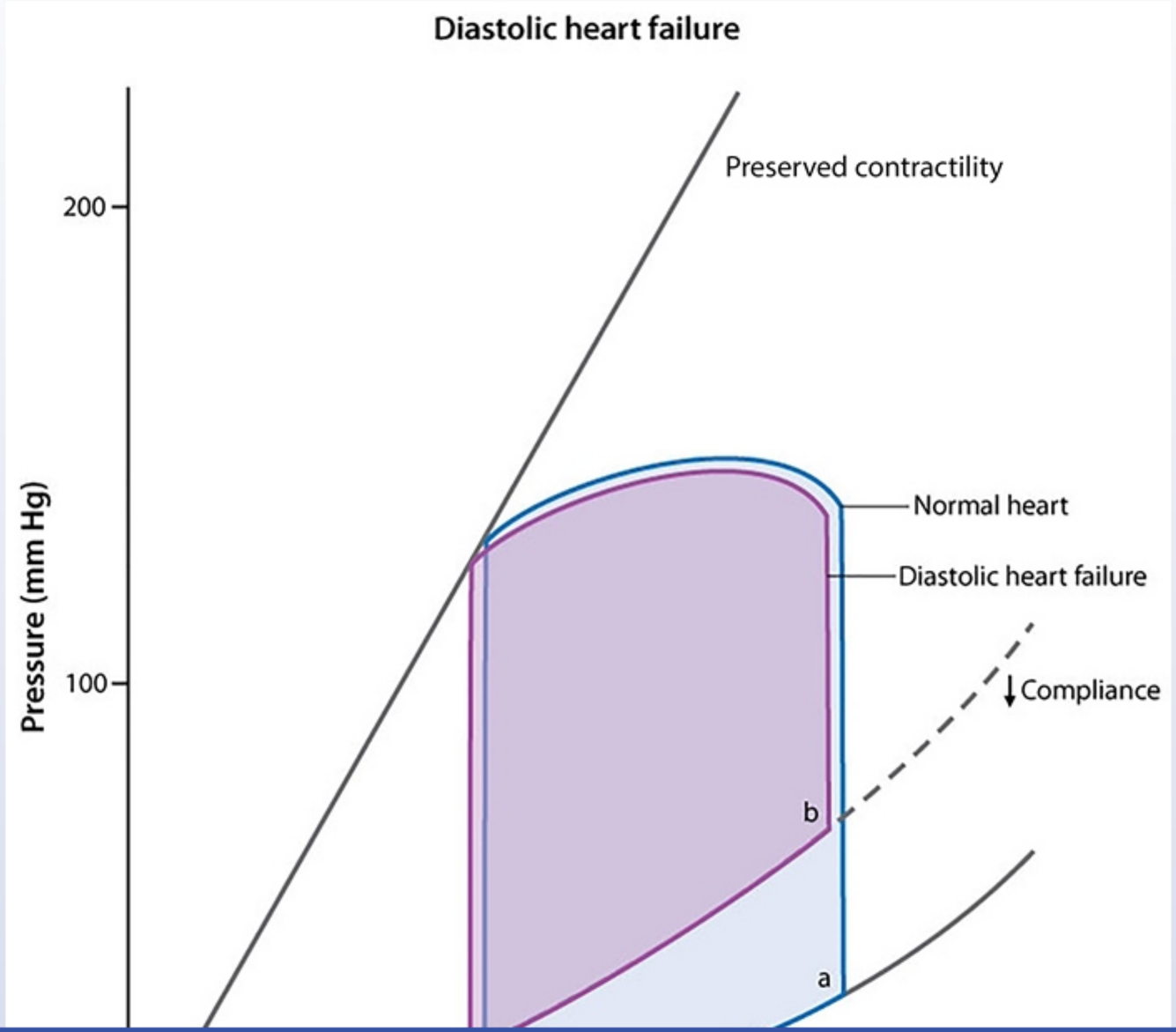
Diastolic heart failure
Preserved contractility
200
100
Pressure (mm Hg)
Normal heart
Diastolic heart failure
Compliance
b
a

1
2
3
4
5
6
7
8
9
10
11
12
13
14
15
16
17
18
19
20
21
22
23
24
25
26
27
28
29
30
31

Diastolic heart failure

Exhibit Display

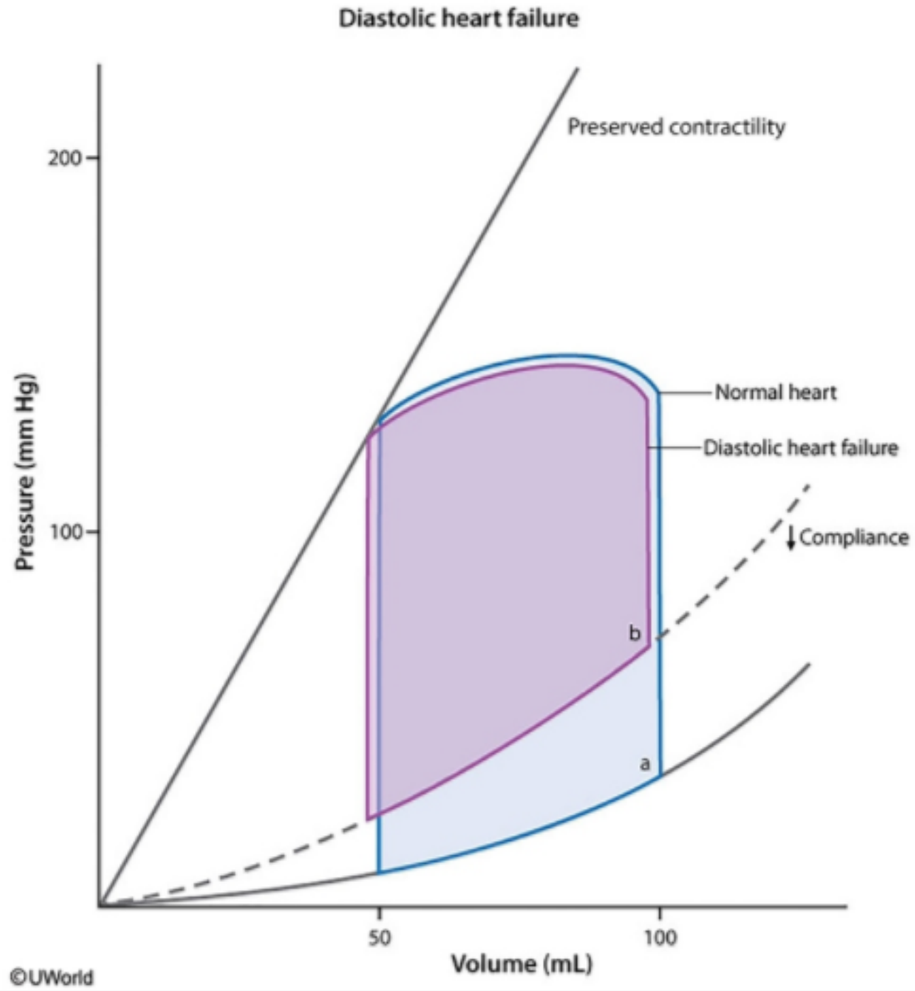

Zoom In | Zoom Out | Reset | Add To New Card | Existing Card

1
2
3
4
5
6
7
8
9
10
11
12
13
14
15
16
17
18
19
20
21
22
23
24
25
26
27
28
29
30
31

This presentation (exertional dyspnea, orthopnea, bibasilar crackles, elevated jugular venous pressure, and lower extremity edema) is consistent with **decompensated congestive heart failure** (CHF). The left ventricular (LV) diastolic pressure-volume curve (purple curve in graph above) shows **reduced LV compliance**, indicating that **diastolic dysfunction** is the main contributing factor of the patient's CHF.

LV diastolic pressure is determined by the blood volume in the LV cavity and compliance of the left ventricle. Conditions that decrease compliance lead to increased LV end-diastolic (LVED) pressures at the same LVED volumes. This causes a shift in the pressure-volume curve that goes upward and to the left. Higher LV filling pressures are transmitted back to pulmonary vasculature, leading to pulmonary edema. Impaired right ventricular filling or neurohormonal activation from low cardiac output is responsible for the peripheral edema and elevated jugular venous pressure.

Restrictive cardiomyopathy (idiopathic or infiltrative disorders [eg, amyloidosis, sarcoidosis, hemochromatosis]) is an important cause of diastolic heart failure, also known as heart failure with preserved ejection fraction. **Transthyretin** (TTR), a protein tetramer produced in the liver, acts as a carrier of thyroxine and retinol. Mutations in the TTR gene can increase the tendency of TTR to misfold, producing an **amyloid protein** that infiltrates the myocardium (**infiltrative cardiomyopathy**).

(Choices A, B, C, and E) Alcoholic cardiomyopathy, doxorubicin therapy, selenium deficiency, and viral myocarditis can all lead to dilated cardiomyopathy with LV systolic dysfunction. Systolic heart failure is typically characterized by increased LV volume and shifting of the pressure-volume curve to the right due to thinning of the ventricular wall (increased compliance).

Educational objective:
Diastolic heart failure (DHF) is caused by decreased ventricular compliance and is characterized by normal left ventricular (LV) ejection fraction, normal LV end-diastolic volume, and elevated LV filling pressures. Hypertension, obesity, and infiltrative disorders (eg, transthyretin-related amyloidosis, sarcoidosis) are important causes of DHF.

References

- Cardiac transthyretin amyloidosis.
- Cardiac amyloidosis: Where are we today?

Pathophysiology	Cardiovascular System	Restrictive cardiomyopathy
Subject	System	Topic

1
2
3
4
5
6
7
8
9
10
11
12
13
14
15
16
17
18
19
20
21
22
23
24
25
26
27
28
29
30
31

A 16-year-old previously healthy boy is brought to the office due to palpitations. He was watching a documentary at a movie theater when his heart suddenly began to race and he became lightheaded. The patient says that he has felt "rapid heartbeats" in the past and thought that they were due to stress from school exams, but he has never had associated lightheadedness before. He has no chest pain or dyspnea. Physical examination is within normal limits. ECG strip is shown in the exhibit. Which of the following is most likely to be seen in this patient?

A. Atrioventricular conduction tract bypassing the atrioventricular node

B. Cardiac myocyte degeneration below the level of the atrioventricular node

C. Ectopic atrial foci that serve as the dominant pacemaker

D. Prolonged repolarization due to myocyte ion channel abnormality

E. Rapid electrical impulses originating in the pulmonary veins

Submit

1
2
3
4
5
6
7
8
9
10
11
12
13
14
15
16
17
18
19
20
21
22
23
24
25
26
27
28
29
30
31

Exhibit Display

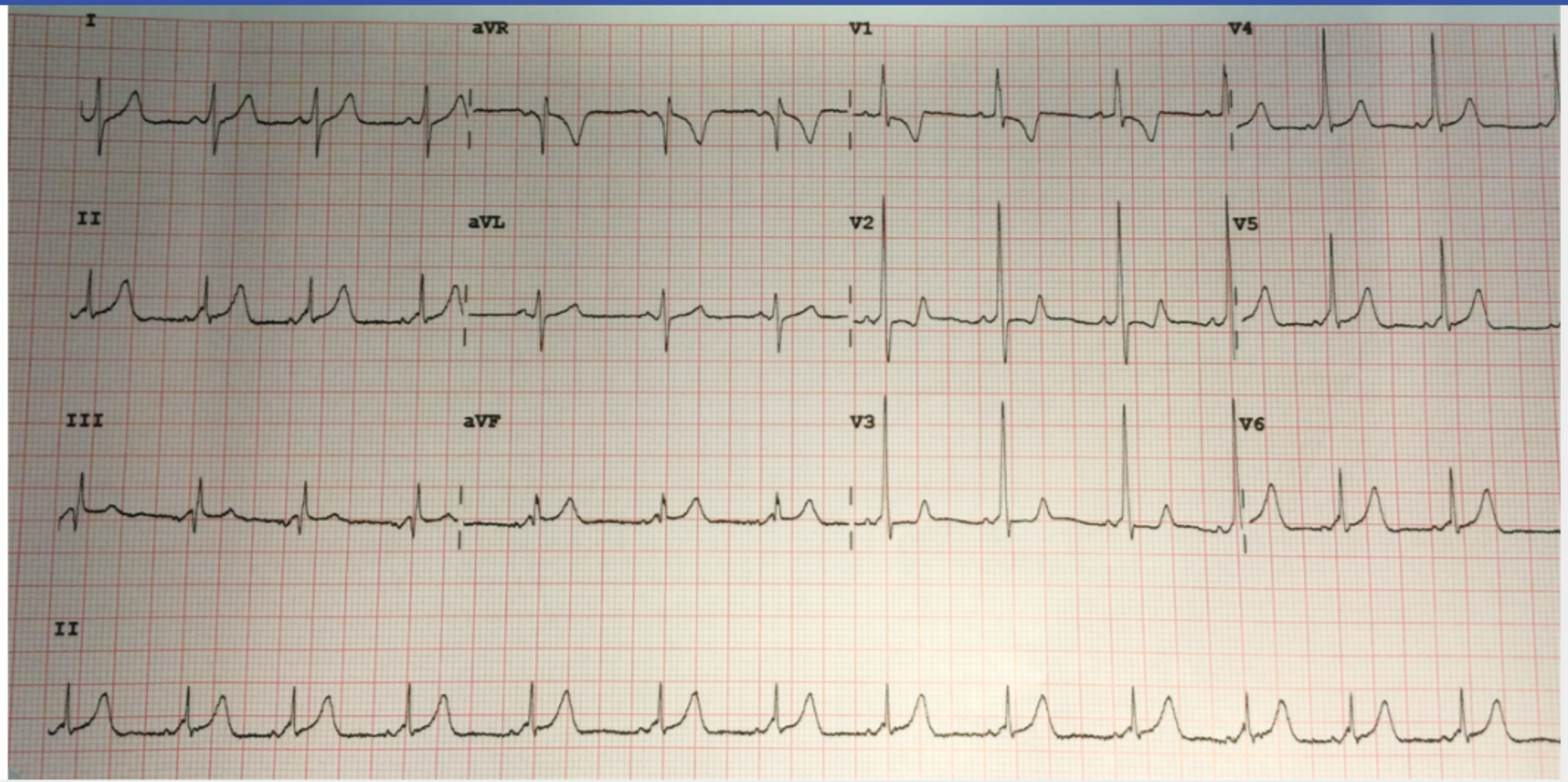

Zoom In | Zoom Out | Reset | Add To New Card | Existing Card

1 2 3 4 5 6 7 8 9 10 11 12 13 14 15 16 17 18 19 20 21 22 23 24 25 26 27 28 29 30 31

A 16-year-old previously healthy boy is brought to the office due to palpitations. He was watching a documentary at a movie theater when his heart suddenly began to race and he became lightheaded. The patient says that he has felt "rapid heartbeats" in the past and thought that they were due to stress from school exams, but he has never had associated lightheadedness before. He has no chest pain or dyspnea. Physical examination is within normal limits. ECG strip is shown in the exhibit. Which of the following is most likely to be seen in this patient?

- ✓ A. Atrioventricular conduction tract bypassing the atrioventricular node (72%)
- B. Cardiac myocyte degeneration below the level of the atrioventricular node (1%)
- C. Ectopic atrial foci that serve as the dominant pacemaker (7%)
- D. Prolonged repolarization due to myocyte ion channel abnormality (15%)
- E. Rapid electrical impulses originating in the pulmonary veins (1%)

Omitted
Correct answer
A

72%
Answered correctly

11 secs
Time Spent

05/08/2020
Last Updated

Explanation

1
2
3
4
5
6
7
8
9
10
11
12
13
14
15
16
17
18
19
20
21
22
23
24
25
26
27
28
29
30
31

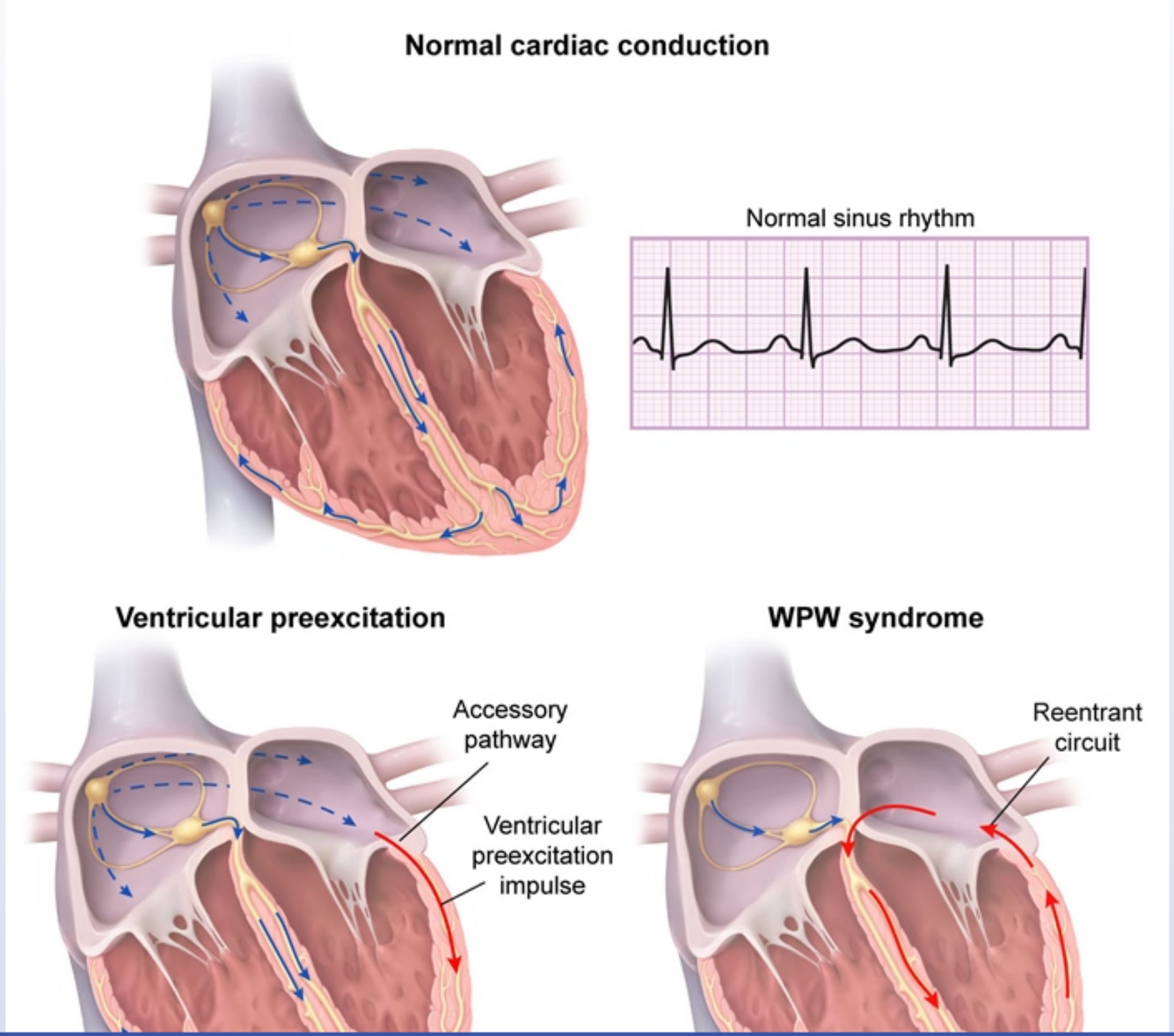

1
2
3
4
5
6
7
8
9
10
11
12
13
14
15
16
17
18
19
20
21
22
23
24
25
26
27
28
29
30
31

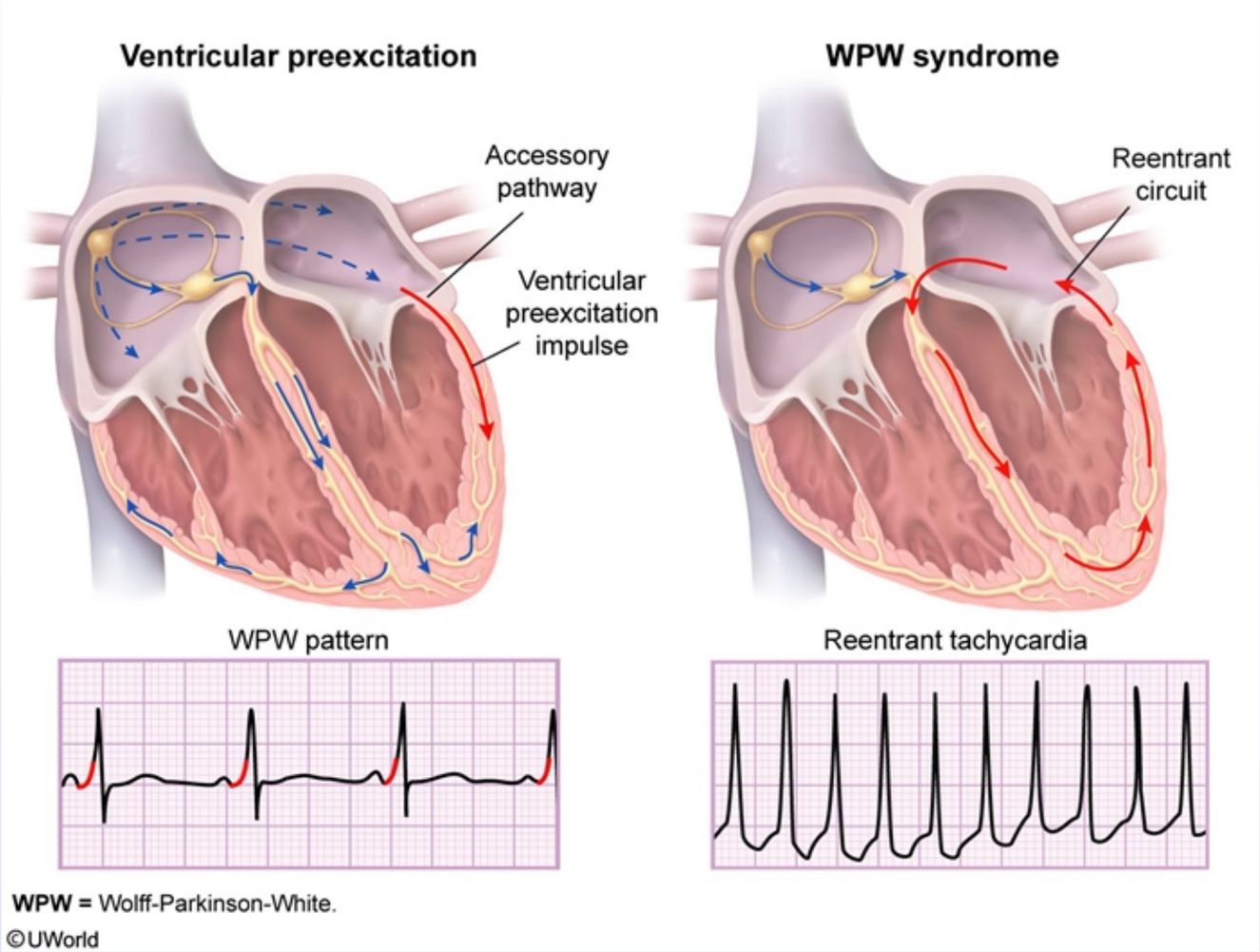

This patient's ECG demonstrates **Wolff-Parkinson-White (WPW) pattern**. The pattern is caused by an **accessory conduction pathway** (also known as an accessory bypass tract or a bundle of Kent) that directly connects the atria to the ventricles and allows electrical impulses to bypass the atrioventricular node, causing **preexcitation** (early excitation) of the ventricles. This preexcitation creates the characteristic triad of ECG findings that constitutes WPW pattern:

©UWorld

This patient's ECG demonstrates **Wolff-Parkinson-White (WPW) pattern**. The pattern is caused by an **accessory conduction pathway** (also known as an accessory bypass tract or a bundle of Kent) that directly connects the atria to the ventricles and allows electrical impulses to bypass the atrioventricular node, causing **preexcitation** (early excitation) of the ventricles. This preexcitation creates the characteristic triad of ECG findings that constitutes WPW pattern:

- Shortened PR interval
- Widening of the QRS interval
- Slurred and broad initial upstroke of the QRS complex, referred to as a **delta wave**

Many patients with WPW pattern on ECG are asymptomatic; however, some develop symptomatic cardiac arrhythmias. **WPW syndrome** is the combination of WPW pattern on ECG and the presence of symptomatic arrhythmia. **Atrioventricular reentrant tachycardia** (AVRT), a type of paroxysmal supraventricular tachycardia that occurs due to reentry of electrical impulses through the accessory conduction pathway, is the most common associated arrhythmia and can manifest with intermittent palpitations, sensation of a racing heart, and lightheadedness or syncope.

(Choice B) Cardiac myocyte degeneration below the level of the atrioventricular node leads to variable degrees of conduction block and presents with slow heart rate.

(Choice C) Patients with wandering atrial pacemaker or ectopic atrial rhythm have ectopic atrial foci that replace the sinus node as the dominant pacemaker; P waves of varying morphology are seen on ECG. This patient has normal, uniform P waves suggesting normal sinus node function.

(Choice D) Long QT syndrome (LQTS) is a disorder of ventricular repolarization characterized by a prolonged QT interval on ECG. Congenital LQTS is due to a mutation in the genes encoding for cardiac sodium or potassium channels.

(Choice E) Atrial fibrillation is most often triggered by rapid electrical impulses originating in the pulmonary veins, and is characterized by an irregularly irregular rhythm and the absence of P waves.

Educational objective:
Wolff-Parkinson-White (WPW) pattern is characterized by a shortened PR interval, widening of the QRS complex, and slurred initial upstroke of the QRS complex (delta wave). It is caused by an accessory pathway that bypasses the atrioventricular node, causing preexcitation of the ventricles. Patients with WPW pattern can develop symptomatic arrhythmia (eg, atrioventricular reentrant tachycardia) due to reentry of electrical impulses through the accessory conduction pathway.

©UWorld

Exhibit Display

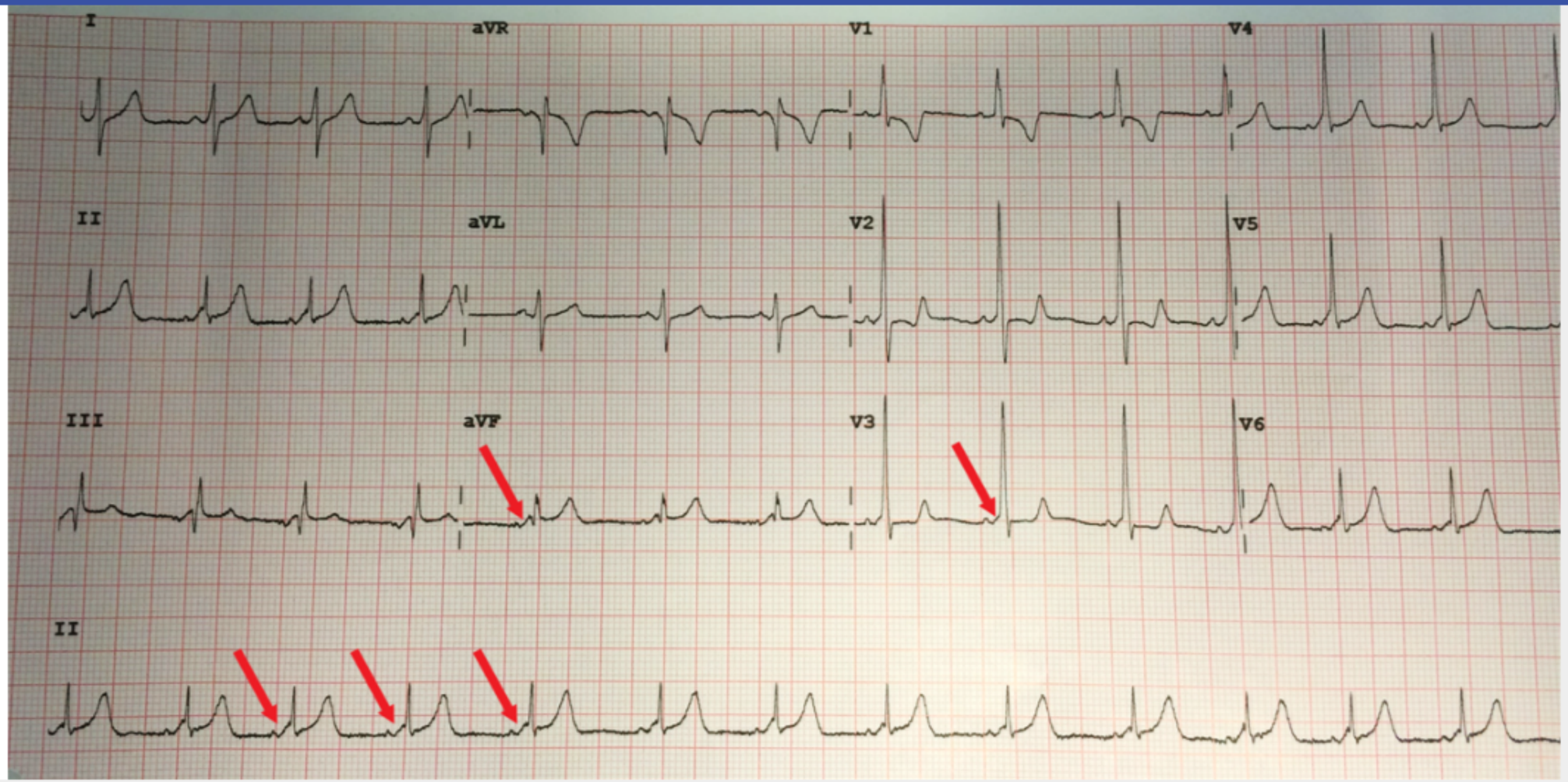

Zoom In | Zoom Out | Reset | Add To New Card | Existing Card

impulses through the accessory conduction pathway.

©UWorld

Exhibit Display

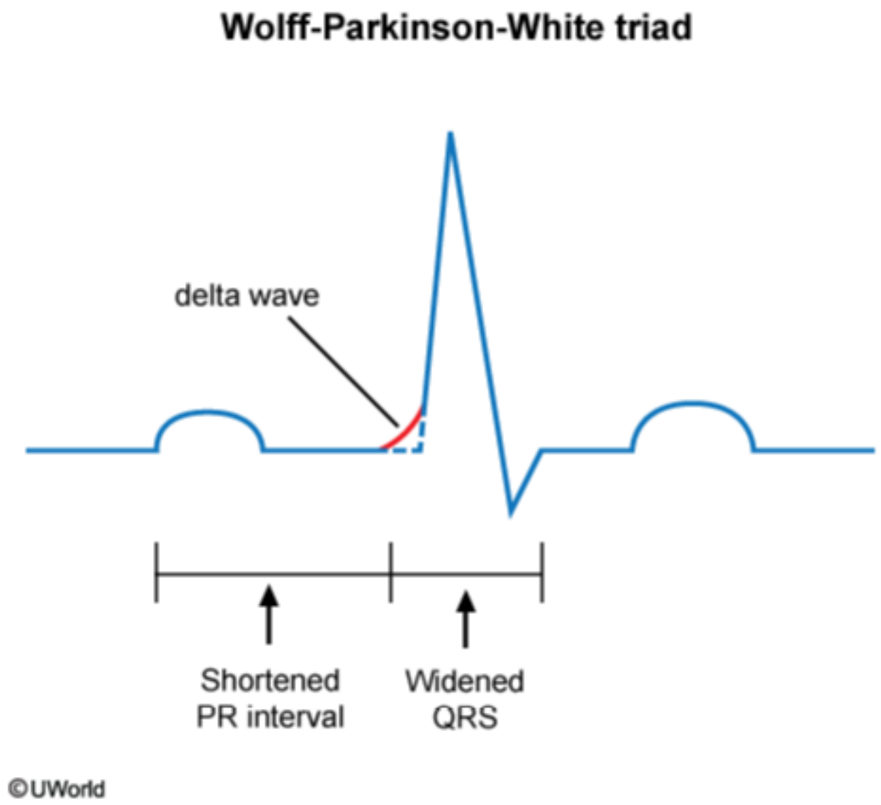

Zoom In Zoom Out Reset Add To New Card | Existing Card

impulses through the accessory conduction pathway.

- Shortened PR interval
- Widening of the QRS interval
- Slurred and broad initial upstroke of the QRS complex, referred to as a **delta wave**

Many patients with WPW pattern on ECG are asymptomatic; however, some develop symptomatic cardiac arrhythmias. **WPW syndrome** is the combination of WPW pattern on ECG and the presence of symptomatic arrhythmia. **Atrioventricular reentrant tachycardia** (AVRT), a type of paroxysmal supraventricular tachycardia that occurs due to reentry of electrical impulses through the accessory conduction pathway, is the most common associated arrhythmia and can manifest with intermittent palpitations, sensation of a racing heart, and lightheadedness or syncope.

(Choice B) Cardiac myocyte degeneration below the level of the atrioventricular node leads to variable degrees of conduction block and presents with slow heart rate.

(Choice C) Patients with wandering atrial pacemaker or ectopic atrial rhythm have ectopic atrial foci that replace the sinus node as the dominant pacemaker; P waves of varying morphology are seen on ECG. This patient has normal, uniform P waves suggesting normal sinus node function.

(Choice D) Long QT syndrome (LQTS) is a disorder of ventricular repolarization characterized by a prolonged QT interval on ECG. Congenital LQTS is due to a mutation in the genes encoding for cardiac sodium or potassium channels.

(Choice E) Atrial fibrillation is most often triggered by rapid electrical impulses originating in the pulmonary veins, and is characterized by an irregularly irregular rhythm and the absence of P waves.

Educational objective:
Wolff-Parkinson-White (WPW) pattern is characterized by a shortened PR interval, widening of the QRS complex, and slurred initial upstroke of the QRS complex (delta wave). It is caused by an accessory pathway that bypasses the atrioventricular node, causing preexcitation of the ventricles. Patients with WPW pattern can develop symptomatic arrhythmia (eg, atrioventricular reentrant tachycardia) due to reentry of electrical impulses through the accessory conduction pathway.

Pathophysiology	Cardiovascular System	Wolff parkinson white syndrome
Subject	System	Topic

Copyright © UWorld. All rights reserved.

A 24-year-old man comes to the office for an exercise evaluation. He is an avid long-distance runner. One of his team members recently died suddenly in his sleep, which made the patient worried about his health. He has no medical history, takes no medications, and does not use illicit drugs. His maternal grandfather had a heart attack at age 40 and underwent coronary artery bypass surgery. Blood pressure is 122/70 mm Hg and pulse is 49/min. Transthoracic echocardiogram shows the following:

Left atrium	mildly enlarged
Left ventricular (LV) cavity size	mildly increased
LV wall thickness	borderline increased uniformly
LV mass	increased
LV ejection fraction	69%

The right ventricle appears normal, and there are no valvular lesions. Which of the following best explains this patient's echocardiogram findings?

A. Anabolic steroid abuse
B. Cardiac adaptation
C. Hypertrophic cardiomyopathy
D. Premature coronary artery disease
E. Subclinical viral myocarditis

Submit

1 2 3 4 5 6 7 8 9 10 11 12 13 14 15 16 17 18 19 20 21 22 23 24 25 26 27 28 29 30 31

A 24-year-old man comes to the office for an exercise evaluation. He is an avid long-distance runner. One of his team members recently died suddenly in his sleep, which made the patient worried about his health. He has no medical history, takes no medications, and does not use illicit drugs. His maternal grandfather had a heart attack at age 40 and underwent coronary artery bypass surgery. Blood pressure is 122/70 mm Hg and pulse is 49/min. Transthoracic echocardiogram shows the following:

Left atrium	mildly enlarged
Left ventricular (LV) cavity size	mildly increased
LV wall thickness	borderline increased uniformly
LV mass	increased
LV ejection fraction	69%

The right ventricle appears normal, and there are no valvular lesions. Which of the following best explains this patient's echocardiogram findings?

A. Anabolic steroid abuse (2%)
✓ B. Cardiac adaptation (78%)
C. Hypertrophic cardiomyopathy (16%)
D. Premature coronary artery disease (0%)
E. Subclinical viral myocarditis (0%)

Omitted
Correct answer
B

78%
Answered correctly

02 secs
Time Spent

01/26/2020
Last Updated

Explanation

This patient's echocardiogram findings are consistent with **athlete's heart** (ie, the physiologic cardiac adaptations that occur in highly trained athletes). **Endurance exercise** (eg, long-distance running) mostly increases the volume load on the heart (increased cardiac output) with a smaller component of increased pressure load (increased afterload). As a result, the heart predominantly undergoes eccentric hypertrophy (**cavity enlargement** improves diastolic function) with some degree of concentric hypertrophy (wall thickening increases systolic function). There is also **enhanced coronary capillary development** and a **decreased resting heart rate** due to improved efficiency of cardiac pumping.

Because these **physiologic changes improve cardiac function**, athlete's heart is not associated with an increased risk of cardiovascular morbidity or mortality. However, it is imperative that the changes of athlete's heart are differentiated from similar cardiac anomalies that may reflect serious underlying pathology that could increase the risk of sudden cardiac death (eg, hypertrophic cardiomyopathy). Findings that favor the presence of hypertrophic cardiomyopathy **(Choice C)** include LV hypertrophy predominantly affecting the septum, LV hypertrophy with reduced LV cavity size, impaired diastolic function, and a poorly developed coronary capillary network.

(Choice A) Anabolic steroid abuse can cause pathologic concentric LV hypertrophy, characterized by reduced diastolic function and poor coronary vascularization.

(Choice D) Severe coronary artery disease can lead to ischemic cardiomyopathy, which typically manifests as dilated cardiomyopathy with an enlarged LV cavity but thin LV walls with impaired systolic function.

(Choice E) Viral myocarditis may sometimes lead to dilated cardiomyopathy with eccentric hypertrophy and impaired LV systolic function. Subclinical disease is typically quite mild and resolves without sequelae.

Educational objective:
Athlete's heart refers to physiologic cardiac adaptations that improve cardiac function in response to high-level endurance training. There is predominant eccentric hypertrophy with a smaller component of concentric hypertrophy, leading to an overall increase in left ventricular (LV) mass, enlarged LV cavity size, increased LV wall thickness, and decreased resting heart rate.

References

- Athlete's heart.

1
2
3
4
5
6
7
8
9
10
11
12
13
14
15
16
17
18
19
20
21
22
23
24
25
26
27
28
29
30
31

Exhibit Display

Concentric & eccentric left ventricular hypertrophy

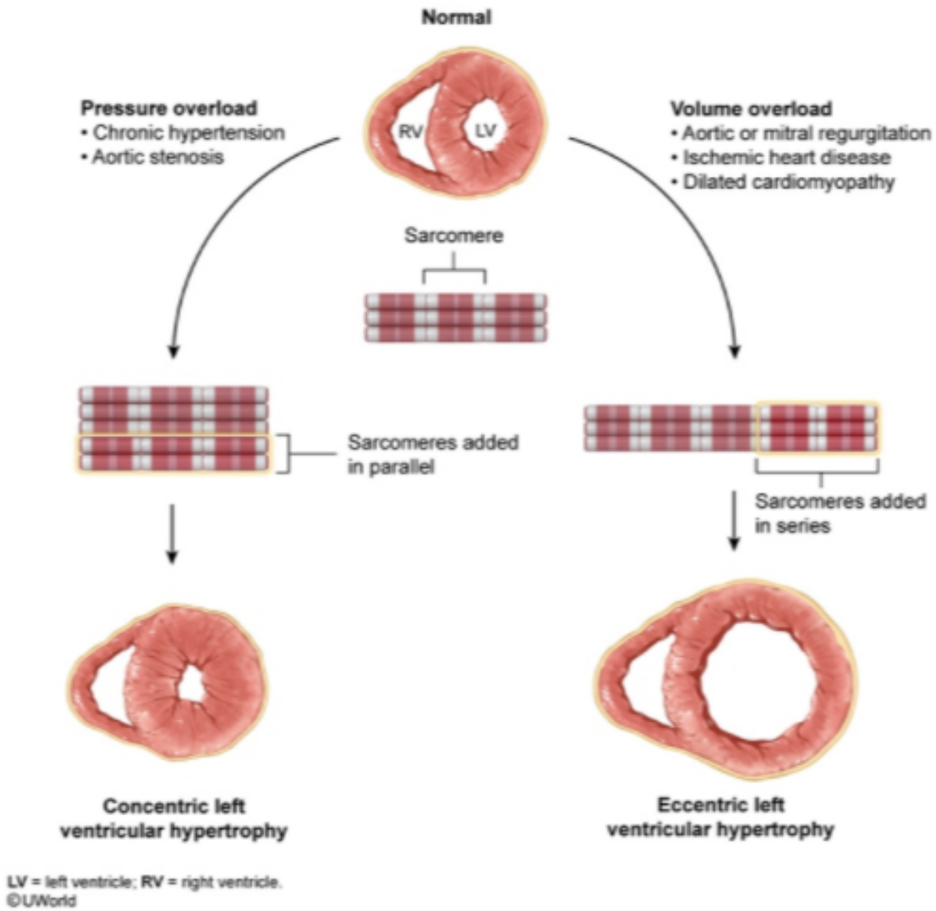

Zoom In | Zoom Out | Reset | Add To New Card | Existing Card

5
6
7
8
9
10
11
12
13
14
15
16
17
18
19
20
21
22
23
24
25
26
27
28
29
30
31
32
33
34
35

A 19-year-old man comes to the office due to difficulty seeing and blurred vision, which have worsened slowly over the past year. He is a second-year college student pursuing a degree in biochemistry. His grades are excellent, but he is concerned about the effect his poor vision has had on his classes this semester. The patient is also an avid swimmer. He weighs 71 kg (156.5 lb) and is 195 cm (6 ft 5 in) tall. Physical examination shows the findings seen in the exhibits. This patient is most likely to die from which of the following conditions?

A. Aortic disease

B. Liver disease

C. Myocardial infarction

D. Overwhelming infection

E. Renal failure

Submit

5
6
7
8
9
10
11
12
13
14
15
16
17
18
19
20
21
22
23
24
25
26
27
28
29
30
31
32
33
34
35

A 19-year-old man comes to the office due to difficulty seeing and blurred vision, which have worsened slowly over the past year. He is a second-year college student pursuing a degree in biochemistry. His grades are excellent, but he is concerned about the effect his poor vision has had on his classes this semester. The patient is also an avid swimmer. He weighs 71 kg (156.5 lb) and is 195 cm (6 ft 5 in) tall. Physical examination shows the findings seen in the exhibits. This patient is most likely to die from which of the following conditions?

- ✓ A. Aortic disease (88%)
- B. Liver disease (2%)
- C. Myocardial infarction (6%)
- D. Overwhelming infection (1%)
- E. Renal failure (1%)

Omitted
Correct answer
A

88%
Answered correctly

02 secs
Time Spent

01/20/2020
Last Updated

Explanation

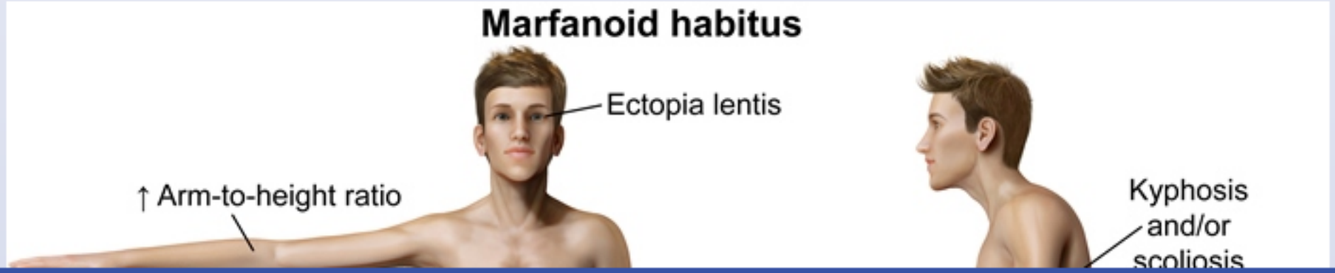

5
6
7
8
9
10
11
12
13
14
15
16
17
18
19
20
21
22
23
24
25
26
27
28
29
30
31
32
33
34
35

Exhibit Display

Exhibit 1 Exhibit 2

Zoom In Zoom Out Reset Add To New Card | Existing Card

5
6
7
8
9
10
11
12
13
14
15
16
17
18
19
20
21
22
23
24
25
26
27
28
29
30
31
32
33
34
35

Exhibit Display

Exhibit 1 Exhibit 2

Zoom In Zoom Out Reset Add To New Card | Existing Card

5
6
7
8
9
10
11
12
13
14
15
16
17
18
19
20
21
22
23
24
25
26
27
28
29
30
31
32
33
34
35

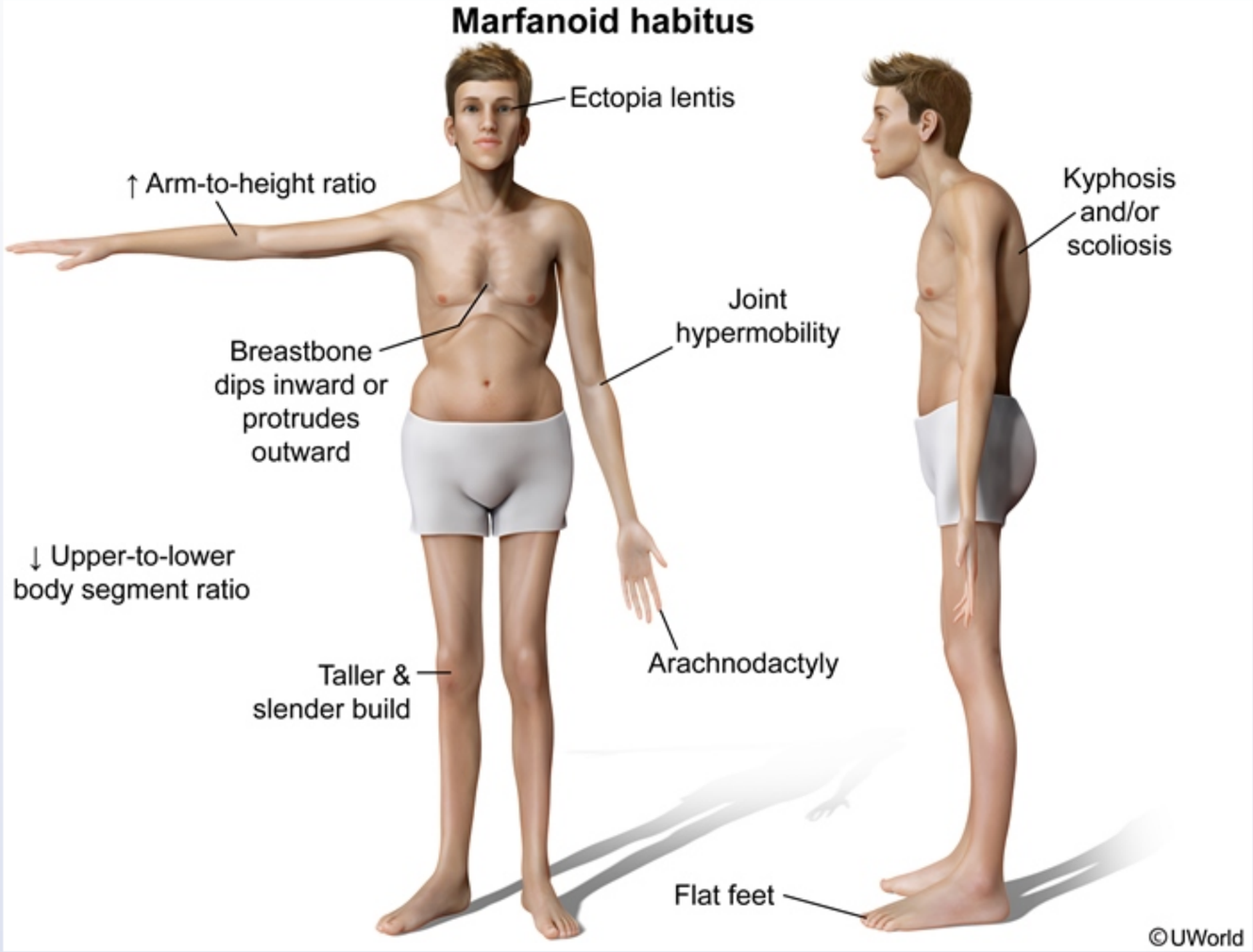

Marfan syndrome (MFS) is one of the most common inherited connective tissue disorders. This condition is caused by a genetic defect in the glycoprotein **fibrillin-1** and results in abnormalities in the skeleton (eg, long extremities, scoliosis, pectus excavatum), eyes (eg, ectopia lentis), and cardiovascular system (eg, aortic root disease).

5
6
7
8
9
10
11
12
13
14
15
16
17
18
19
20
21
22
23
24
25
26
27
28
29
30
31
32
33
34
35

Marfan syndrome (MFS) is one of the most common inherited connective tissue disorders. This condition is caused by a genetic defect in the glycoprotein **fibrillin-1** and results in abnormalities in the skeleton (eg, long extremities, scoliosis, pectus excavatum), eyes (eg, ectopia lentis), and cardiovascular system (eg, aortic root disease).

The 2 most common cardiac abnormalities seen in MFS patients are **mitral valve prolapse** and **cystic medial degeneration of the aorta**. In more than 75% of MFS patients, cystic medial degeneration of the aorta results in aneurysmal dilation. If untreated, this can cause **aortic dissection**, the most common cause of death in MFS patients. The second most common cause of death is cardiac failure secondary to mitral valve prolapse and/or aortic regurgitation. For these reasons, MFS patients should be followed regularly by a cardiologist.

(Choices B, D, and E) With careful cardiovascular management, patients with MFS can have a normal life expectancy. MFS patients are not at increased risk for any of these other conditions.

(Choice C) Although homocystinuria is also associated with a marfanoid body habitus, distinguishing features of homocystinuria include intellectual disability and increased risk of thrombotic events (eg, myocardial infarction, stroke). However, this patient has no intellectual dysfunction.

Educational objective:
Cardiovascular lesions are the most life-threatening complications associated with Marfan syndrome. Early-onset cystic medial degeneration of the aorta predisposes to aortic dissection, the most common cause of death in these patients.

Pathophysiology	Cardiovascular System	Marfan syndrome
Subject	System	Topic

Copyright © UWorld. All rights reserved.

5
6
7
8
9
10
11
12
13
14
15
16
17
18
19
20
21
22
23
24
25
26
27
28
29
30
31
32
33
34
35

A previously healthy 15-year-old girl is brought to the emergency department due to respiratory distress and continuous cough after eating at a buffet in a local restaurant. Blood pressure is 80/40 mm Hg, pulse is 130/min, and respirations are 32/min. She is in marked respiratory distress but is able to speak. Diffuse wheezing and erythematous skin rash are present. Which of the following hemodynamic changes are most likely present in this patient?

	Central venous pressure	Pulmonary capillary wedge pressure	Systemic vascular resistance
A.	Decreased	Decreased	Decreased
B.	Decreased	Decreased	Increased
C.	Increased	Decreased	Increased
D.	Increased	Increased	Decreased
E.	Increased	Increased	Increased

Submit

5
6
7
8
9
10
11
12
13
14
15
16
17
18
19
20
21
22
23
24
25
26
27
28
29
30
31
32
33
34
35

A previously healthy 15-year-old girl is brought to the emergency department due to respiratory distress and continuous cough after eating at a buffet in a local restaurant. Blood pressure is 80/40 mm Hg, pulse is 130/min, and respirations are 32/min. She is in marked respiratory distress but is able to speak. Diffuse wheezing and erythematous skin rash are present. Which of the following hemodynamic changes are most likely present in this patient?

	Central venous pressure	Pulmonary capillary wedge pressure	Systemic vascular resistance
✓ A. (65%)	Decreased	Decreased	Decreased
B. (9%)	Decreased	Decreased	Increased
C. (6%)	Increased	Decreased	Increased
D. (12%)	Increased	Increased	Decreased
E. (5%)	Increased	Increased	Increased

Omitted
Correct answer
A

65%
Answered correctly

03 secs
Time Spent

05/12/2020
Last Updated

Explanation

Hemodynamic measurements in shock				
Parameter	**Hypovolemic shock**	**Cardiogenic shock**	**Obstructive shock**	**Distributive shock**
CVP (right-sided preload)	↓	↑	↑	↓
PCWP (left-sided preload)	↓	↑	↓*	↓
Cardiac index (LV output)	↓	↓	↓	↑**
SVR (afterload)	↑	↑	↑	↓
SvO_2	↓	↓	↓	↑**

*In tamponade, left-sided preload is decreased, but measured PCWP is paradoxically increased due to external compression by pericardial fluid.
**Cardiac index and SvO_2 are usually decreased in neurogenic shock due to impaired sympathetic reflexes.
CVP = central venous pressure; **LV** = left ventricular; **PCWP** = pulmonary capillary wedge pressure; **SvO_2** = mixed venous oxygen saturation; **SVR** = systemic vascular resistance.

This patient with respiratory distress, wheezing, and erythematous skin rash following food exposure likely has anaphylaxis; her severe hypotension and tachycardia indicate **anaphylactic shock**.

This patient with respiratory distress, wheezing, and erythematous skin rash following food exposure likely has anaphylaxis; her severe hypotension and tachycardia indicate **anaphylactic shock**.

The primary disturbance in distributive shock (eg, septic shock, anaphylactic shock) is profound **peripheral vasodilation** which, in anaphylactic shock, results from widespread IgE-mediated release of inflammatory mediators (eg, histamine). This has the following effects:

- Arteriolar vasodilation causes **decreased systemic vascular resistance** (SVR) and consequent **hypotension**.
- Venular vasodilation causes **decreased central venous pressure** (CVP) and reduces venous return to the right atrium **(Choice D)**.
- The vasculature becomes leaky, resulting in loss of intravascular volume that further contributes to both hypotension and decreased CVP.

With reduced venous return to the right atrium, there is reduced right ventricular output and reduced blood delivery to the left atrium and left ventricle. This leads to **decreased pulmonary capillary wedge pressure** (PCWP), a reflection of left atrial pressure. Despite the reduced left ventricular preload, cardiac output is commonly normal or increased in early distributive shock due to both the large decrease in SVR and a baroreceptor reflex–mediated increase in heart rate (ie, tachycardia). The increased cardiac output leads to increased mixed venous oxygen saturation due to rapid blood transit through the peripheral capillaries and incomplete oxygen uptake by the tissues.

(Choice B) Hypovolemic shock involves massive intravascular volume depletion, leading to decreased CVP and PCWP. SVR is reflexively increased in response to reduced cardiac output and hypotension.

(Choice C) Obstructive shock most commonly involves an obstruction to blood flow between the right atrium and the pulmonary capillaries (eg, pulmonary embolism). CVP is increased, PCWP is decreased, and there is a reflexive increase in SVR.

(Choice E) Cardiogenic shock results from left ventricular failure. PCWP and CVP are increased due to backward transmission of increased pressure, and there is a reflexive increase in SVR.

Educational objective:
Anaphylaxis can cause distributive shock due to widespread release of inflammatory mediators (eg, histamine) that leads to massive peripheral vasodilation. Arteriolar vasodilation decreases systemic vascular resistance to cause hypotension, and venular vasodilation decreases central venous pressure and pulmonary capillary wedge pressure. Cardiac output is often increased in early distributive shock due to reduced SVR and a baroreceptor reflex–mediated increase in heart rate.

This patient with respiratory distress, wheezing, and erythematous skin rash following food exposure likely has anaphylaxis; her severe

Exhibit Display

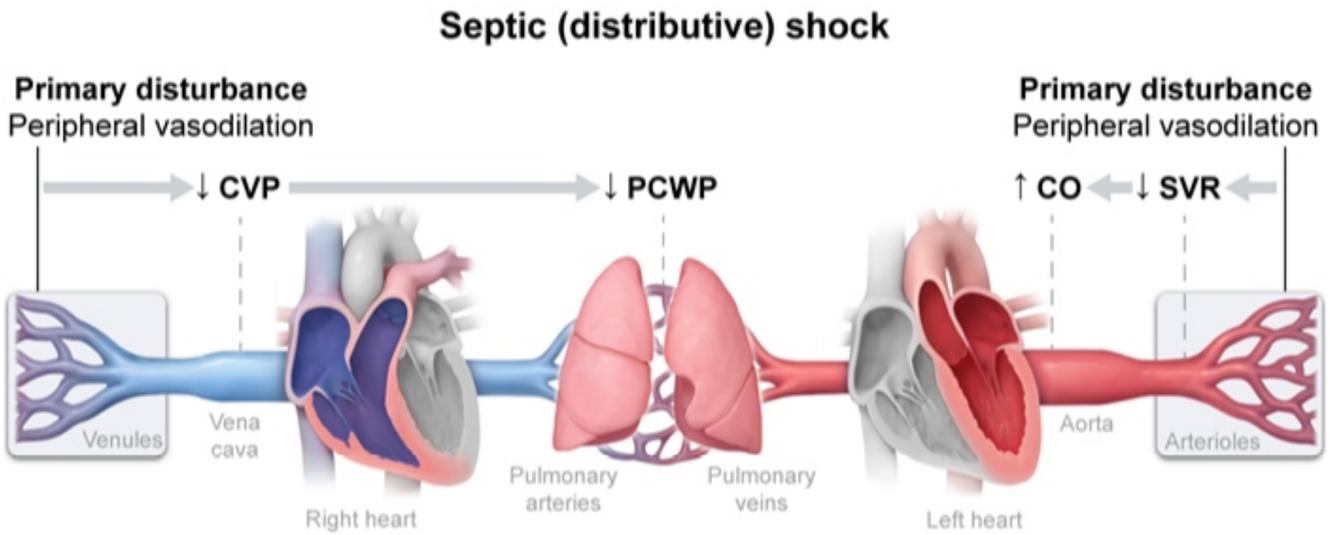

CO = cardiac output; **CVP** = central venous pressure;
PCWP = pulmonary capillary wedge pressure; **SVR** = systemic vascular resistance.

©UWorld

Zoom In Zoom Out Reset Add To Flash Card

This patient with respiratory distress, wheezing, and erythematous skin rash following food exposure likely has anaphylaxis; her severe

Exhibit Display

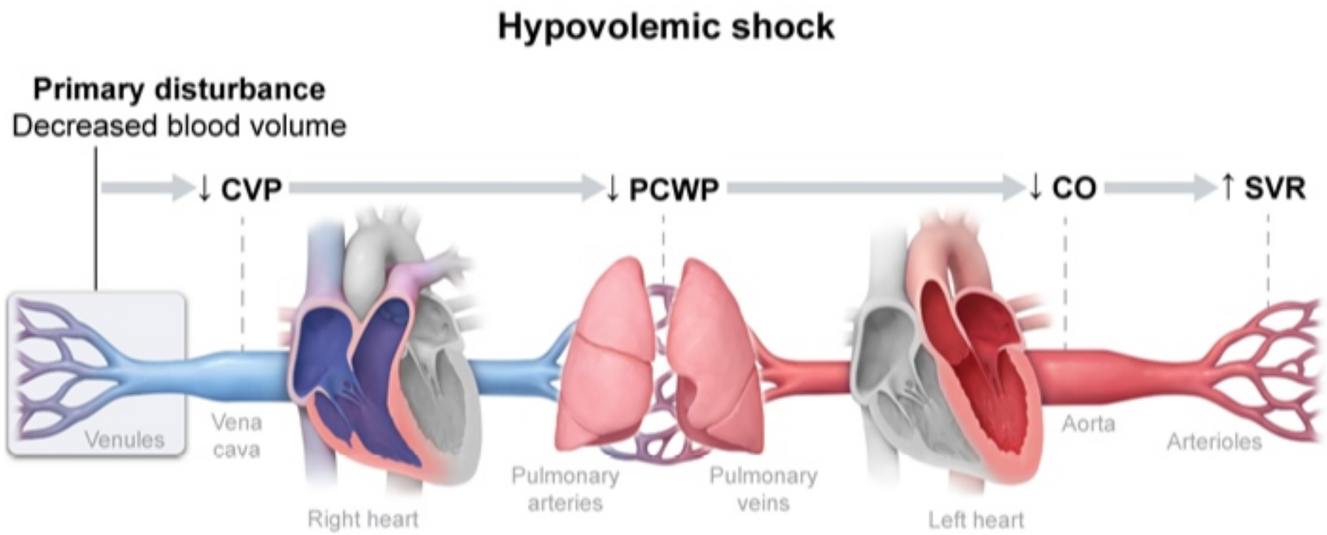

CO = cardiac output; **CVP** = central venous pressure;
PCWP = pulmonary capillary wedge pressure; **SVR** = systemic vascular resistance.

©UWorld

Zoom In Zoom Out Reset Add To Flash Card

This patient with respiratory distress, wheezing, and erythematous skin rash following food exposure likely has anaphylaxis; her severe

Exhibit Display

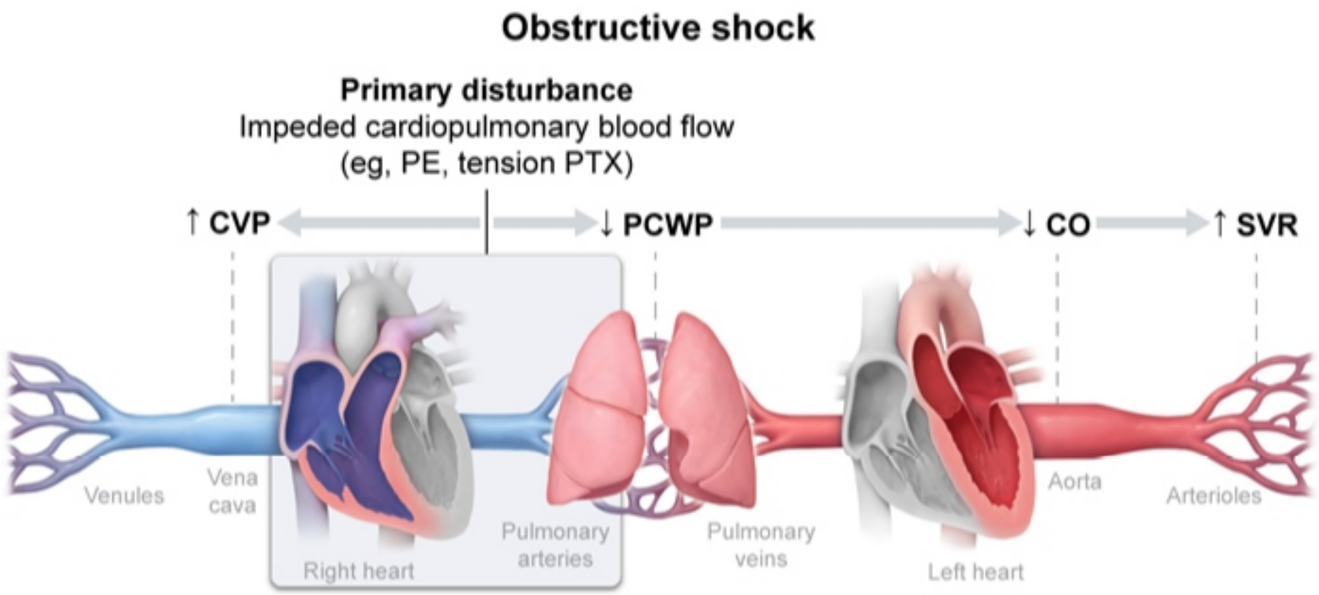

CO = cardiac output; **CVP** = central venous pressure; **PCWP** = pulmonary capillary wedge pressure; **PE** = pulmonary embolism; **PTX** = pneumothorax; **SVR** = systemic vascular resistance.

©UWorld

Zoom In Zoom Out Reset Add To Flash Card

This patient with respiratory distress, wheezing, and erythematous skin rash following food exposure likely has anaphylaxis; her severe

Exhibit Display

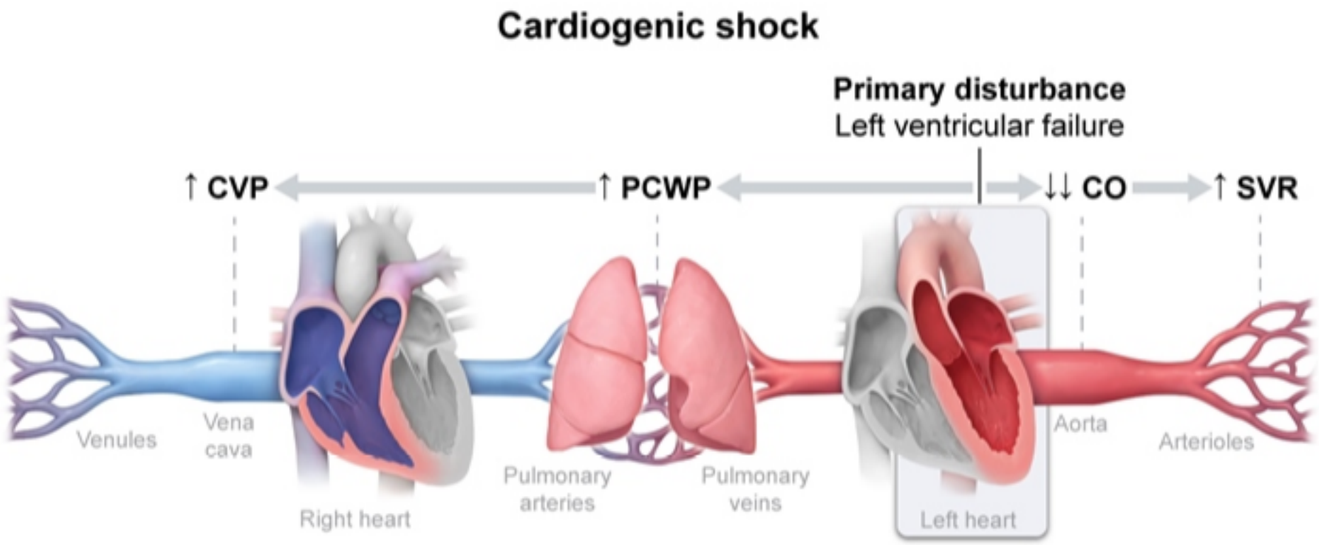

CO = cardiac output; **CVP** = central venous pressure;
PCWP = pulmonary capillary wedge pressure; **SVR** = systemic vascular resistance.

©UWorld

Zoom In Zoom Out Reset Add To Flash Card

An 82-year-old woman comes to the office due to fatigue, abdominal discomfort, and lower extremity swelling. She also occasionally feels an uncomfortable pulsation in her neck. Six weeks ago, the patient underwent pacemaker implantation due to sick sinus syndrome. Episodes of lightheadedness that she had experienced before the procedure have now resolved. The patient is afebrile, and other vital signs are normal. Physical examination reveals bilateral, lower extremity edema and a tender, pulsatile liver. The lungs are clear on auscultation. The pacemaker implantation site has healed normally. Complete blood count is normal. What is the most likely diagnosis?

A. Aortic valve regurgitation
B. Constrictive pericarditis
C. Infective endocarditis
D. Pulmonic valve regurgitation
E. Tricuspid valve regurgitation

Submit

5
6
7
8
9
10
11
12
13
14
15
16
17
18
19
20
21
22
23
24
25
26
27
28
29
30
31
32
33
34
35

An 82-year-old woman comes to the office due to fatigue, abdominal discomfort, and lower extremity swelling. She also occasionally feels an uncomfortable pulsation in her neck. Six weeks ago, the patient underwent pacemaker implantation due to sick sinus syndrome. Episodes of lightheadedness that she had experienced before the procedure have now resolved. The patient is afebrile, and other vital signs are normal. Physical examination reveals bilateral, lower extremity edema and a tender, pulsatile liver. The lungs are clear on auscultation. The pacemaker implantation site has healed normally. Complete blood count is normal. What is the most likely diagnosis?

A. Aortic valve regurgitation (15%)
B. Constrictive pericarditis (13%)
C. Infective endocarditis (3%)
D. Pulmonic valve regurgitation (6%)
✓ E. Tricuspid valve regurgitation (60%)

Omitted
Correct answer
E

60%
Answered correctly

02 secs
Time Spent

02/09/2020
Last Updated

Explanation

Dual chamber pacemaker

5
6
7
8
9
10
11
12
13
14
15
16
17
18
19
20
21
22
23
24
25
26
27
28
29
30
31
32
33
34
35

Dual chamber pacemaker

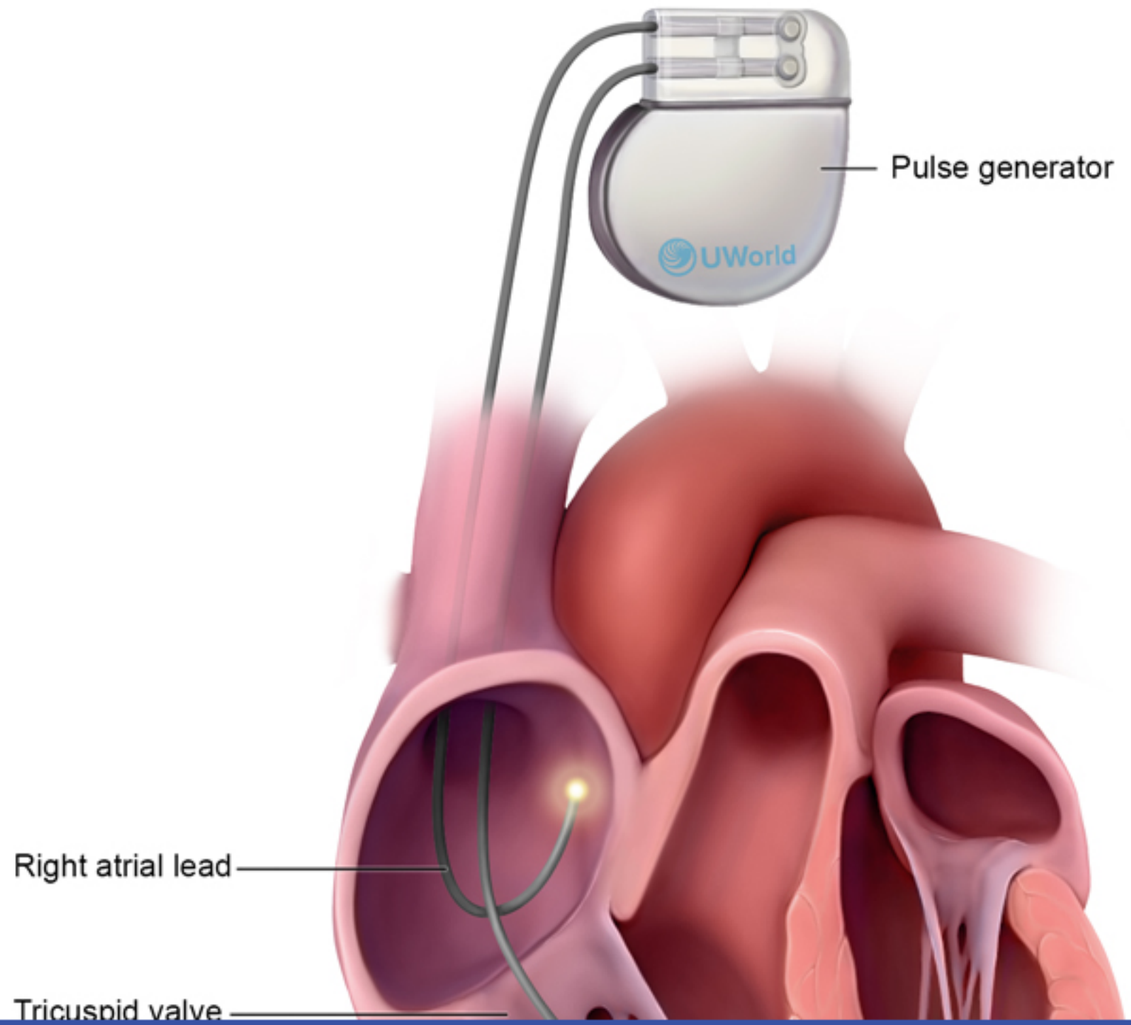

5
6
7
8
9
10
11
12
13
14
15
16
17
18
19
20
21
22
23
24
25
26
27
28
29
30
31
32
33
34
35

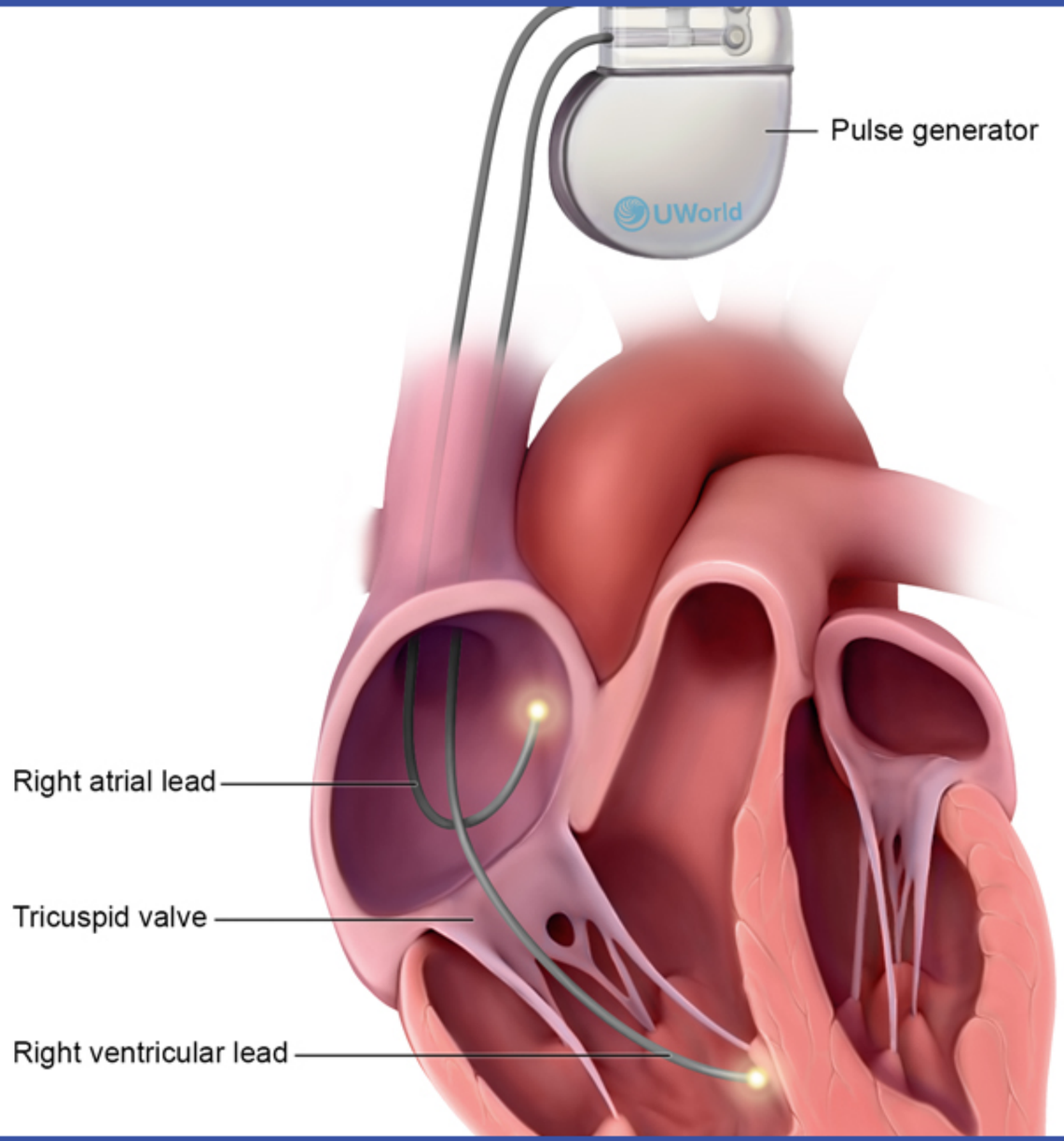

5
6
7
8
9
10
11
12
13
14
15
16
17
18
19
20
21
22
23
24
25
26
27
28
29
30
31
32
33
34
35

This patient likely has **tricuspid valve regurgitation** (TR) due to an adverse effect of her permanent pacemaker. The right ventricular lead of an **implantable pacemaker or cardioverter-defibrillator** passes through the superior vena cava into the right atrium and then through the tricuspid valve orifice to terminate on the endocardium of the right ventricle. Damage to the tricuspid valve leaflets or inadequate leaflet coaptation can sometimes occur, leading to severe TR in some patients.

Severe TR typically presents with **right-sided heart failure**. Patients can have **distended jugular veins**, pulsatile and **tender hepatomegaly**, abdominal distension with **ascites**, and **lower extremity edema**. The lungs are clear on auscultation in the absence of concomitant left-sided heart disease. Cardiac examination typically reveals a **holosystolic murmur** best heard at the left lower sternal border; the murmur intensifies with maneuvers that increase right ventricular preload (eg, deep inspiration, leg raise).

(Choice A) Causes of aortic valve regurgitation include rheumatic heart disease and aortic root dilation. Severe disease can lead to left-sided heart failure; however, pulmonary edema with crackles on lung auscultation would be expected.

(Choice B) Constrictive pericarditis can result from chronic pericardial inflammation in the setting of infection or rheumatologic disease. It typically manifests with signs and symptoms of right-sided heart failure; however, the relationship between this patient's heart failure symptoms and recent pacemaker placement makes TR more likely.

(Choice C) Infective endocarditis may affect the tricuspid valve and lead to TR; however, tricuspid involvement typically develops in patients with a history of injection drug use. In addition, this patient's lack of fever makes infective endocarditis unlikely.

(Choice D) Severe pulmonic valve regurgitation can lead to right-sided heart failure. Causes of pulmonic valve regurgitation include rheumatic heart disease and carcinoid syndrome, but it is not associated with pacemaker placement as pacemaker leads do not cross the pulmonic valve.

Educational objective:
Severe tricuspid valve regurgitation (TR) can lead to right-sided heart failure, evidenced by jugular venous distension, hepatomegaly, lower extremity edema, and the absence of pulmonary edema. Permanent pacemaker placement can cause TR because the right ventricular lead passes through the tricuspid valve orifice and can disrupt valve closure.

Pathophysiology	Cardiovascular System	Tricuspid regurgitation
Subject	System	Topic

5
6
7
8
9
10
11
12
13
14
15
16
17
18
19
20
21
22
23
24
25
26
27
28
29
30
31
32
33
34
35

A 68-year-old woman comes to the office due to a month-long history of worsening fatigue, shortness of breath, and dry cough. The patient has symptoms that worsen with exertion and when lying flat. She has had no chest pain, palpitations, or lightheadedness. The patient has a history of hypertension and breast cancer that is in remission after surgery and doxorubicin-based chemotherapy 15 years ago. She does not use tobacco, alcohol, or illicit drugs. Blood pressure is 110/62 mm Hg and pulse is 94/min. Physical examination shows crackles at the lung bases and bilateral pedal edema. Which of the following sets of findings are most likely present in this patient?

	Right Atrial Pressure	Left Ventricular End-Diastolic Pressure
A.	Decreased	Decreased
B.	Decreased	Increased
C.	Increased	Decreased
D.	Increased	Increased
E.	Increased	No change
F.	No change	Increased

Submit

A 68-year-old woman comes to the office due to a month-long history of worsening fatigue, shortness of breath, and dry cough. The patient has symptoms that worsen with exertion and when lying flat. She has had no chest pain, palpitations, or lightheadedness. The patient has a history of hypertension and breast cancer that is in remission after surgery and doxorubicin-based chemotherapy 15 years ago. She does not use tobacco, alcohol, or illicit drugs. Blood pressure is 110/62 mm Hg and pulse is 94/min. Physical examination shows crackles at the lung bases and bilateral pedal edema. Which of the following sets of findings are most likely present in this patient?

	Right Atrial Pressure	Left Ventricular End-Diastolic Pressure
A. (5%)	Decreased	Decreased
B. (5%)	Decreased	Increased
C. (16%)	Increased	Decreased
✓ D. (58%)	Increased	Increased
E. (7%)	Increased	No change
F. (6%)	No change	Increased

Omitted
Correct answer
D

58%
Answered correctly

03 secs
Time Spent

03/17/2020
Last Updated

Explanation

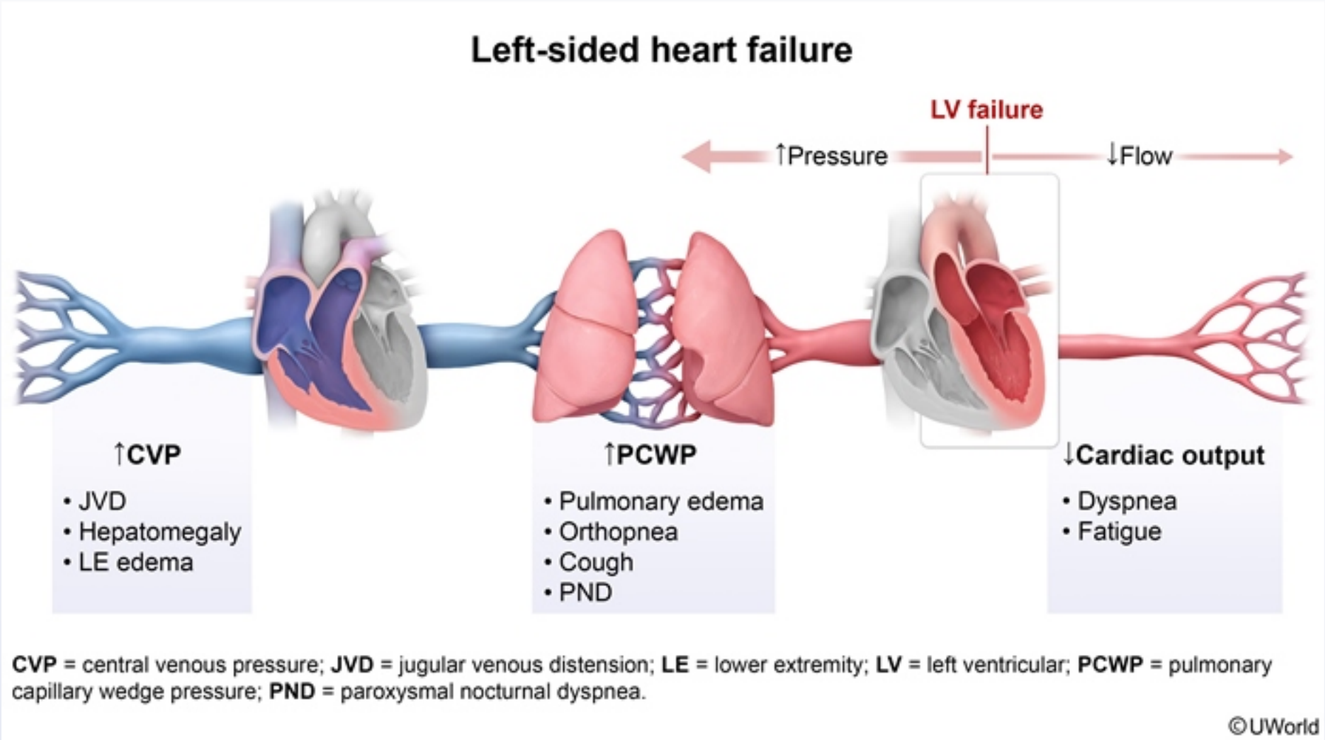

This patient with fatigue, dyspnea on exertion, orthopnea, cough, and lower extremity swelling is in **acute decompensated heart failure**. Anthracycline chemotherapeutic agents (eg, **doxorubicin**) are a common cause of dilated cardiomyopathy and can precipitate symptomatic heart failure that presents years after exposure.

Dilated cardiomyopathy results from a direct insult to cardiomyocytes that impairs their contractile function. There is an increase in left ventricular volume that is initially compensated for by the Frank-Starling mechanism and later by eccentric hypertrophy to maintain cardiac output. However, overwhelming wall stress eventually leads to marked impairment in myocardial contractile function, **reduced cardiac output**, and symptomatic decompensated heart failure. The **elevated left ventricular end-diastolic pressure** (LVEDP) is transmitted backward to the pulmonary veins and capillaries, leading to pulmonary edema (evidenced by crackles on lung auscultation).

This patient with fatigue, dyspnea on exertion, orthopnea, cough, and lower extremity swelling is in **acute decompensated heart failure**. Anthracycline chemotherapeutic agents (eg, **doxorubicin**) are a common cause of dilated cardiomyopathy and can precipitate symptomatic heart failure that presents years after exposure.

Dilated cardiomyopathy results from a direct insult to cardiomyocytes that impairs their contractile function. There is an increase in left ventricular volume that is initially compensated for by the Frank-Starling mechanism and later by eccentric hypertrophy to maintain cardiac output. However, overwhelming wall stress eventually leads to marked impairment in myocardial contractile function, **reduced cardiac output**, and symptomatic decompensated heart failure. The **elevated left ventricular end-diastolic pressure** (LVEDP) is transmitted backward to the pulmonary veins and capillaries, leading to pulmonary edema (evidenced by crackles on lung auscultation).

Patients with **advanced heart failure** also develop **elevated right atrial pressure** (RAP). RAP is representative of central venous pressure and elevation is indicative of underlying volume overload and possible right-sided heart failure (which most commonly occurs secondary to left-sided heart failure due to backward transmission of elevated pressure overloading the right ventricle). In addition, since the underlying insult in dilated cardiomyopathy often directly affects the right ventricular myocardium, concomitant right ventricular failure is particularly likely in these individuals.

(Choice A) Decreased RAP and LVEDP can occur in the setting of intravascular volume depletion.

(Choices B and F) Increased LVEDP with normal or decreased RAP can occur early in the course of left-sided heart failure (eg, due to prolonged systemic hypertension). However, by the time overt signs of volume overload develop (eg, peripheral and pulmonary edema), RAP is invariably elevated.

(Choices C and E) Increased RAP with normal or decreased LVEDP suggests right-sided heart failure in the absence of left-sided heart failure, as can occur with pulmonary arterial hypertension or hypoxic lung disease (eg, interstitial lung disease). Right ventricular output is impaired, causing reduced blood flow through the lungs to the left atrium (low or normal left-sided pressures). In contrast, this patient's pulmonary crackles are indicative of increased left-sided pressures.

Educational objective:
Patients with decompensated heart failure have elevated left ventricular end-diastolic pressure and decreased cardiac output that is most often primarily due to left ventricular dysfunction. Right atrial pressure (ie, central venous pressure) is also elevated in advanced heart failure due to volume overload; right-sided heart failure (most often occuring secondary to left-sided failure) can also contribute to elevated right atrial pressure.

Anthracycline chemotherapeutic agents (eg, **doxorubicin**) are a common cause of dilated cardiomyopathy and can precipitate symptomatic heart

Exhibit Display

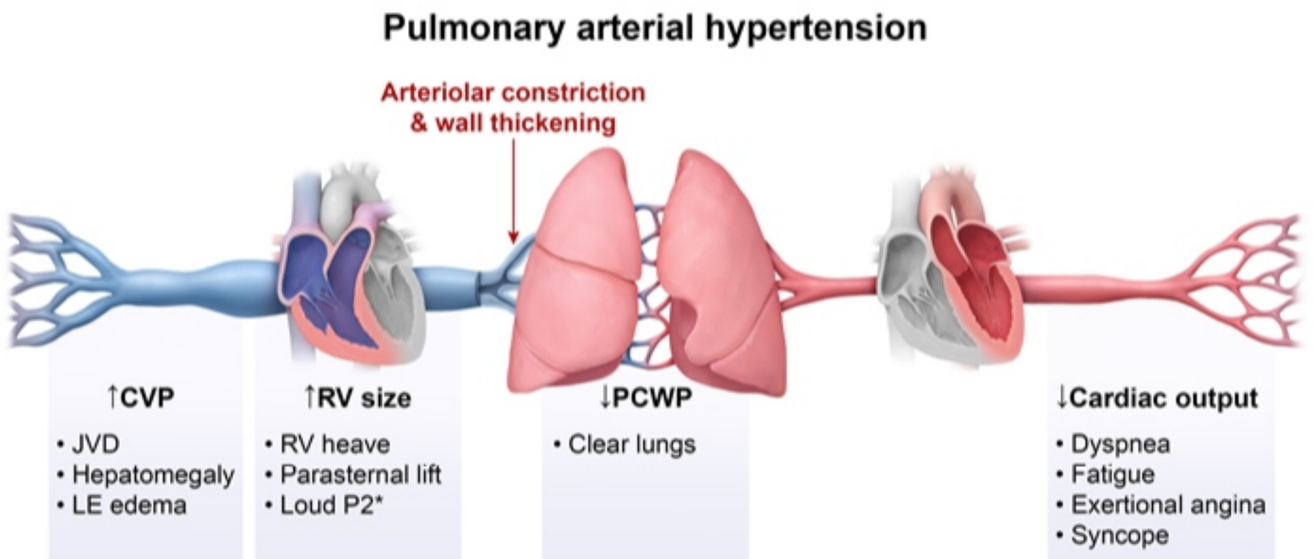

Zoom In Zoom Out Reset Add To New Card | Existing Card

Pathophysiology Cardiovascular System Acute heart failure

5
6
7
8
9
10
11
12
13
14
15
16
17
18
19
20
21
22
23
24
25
26
27
28
29
30
31
32
33
34
35

A 52-year-old man comes to the office due to a 2-week history of progressive fatigue and exertional dyspnea. The patient is a postal delivery worker and reports that he gets short of breath after walking a few blocks. He has not had chest pain or palpitations. The patient does not use tobacco, alcohol, or illicit drugs. Cardiac auscultation reveals a murmur that is best heard when the patient sits up and leans forward. He brings to the office the report from a recent cardiac catheterization (graph shown below). This patient's murmur would most likely be loudest at which of the following time points on the graph?

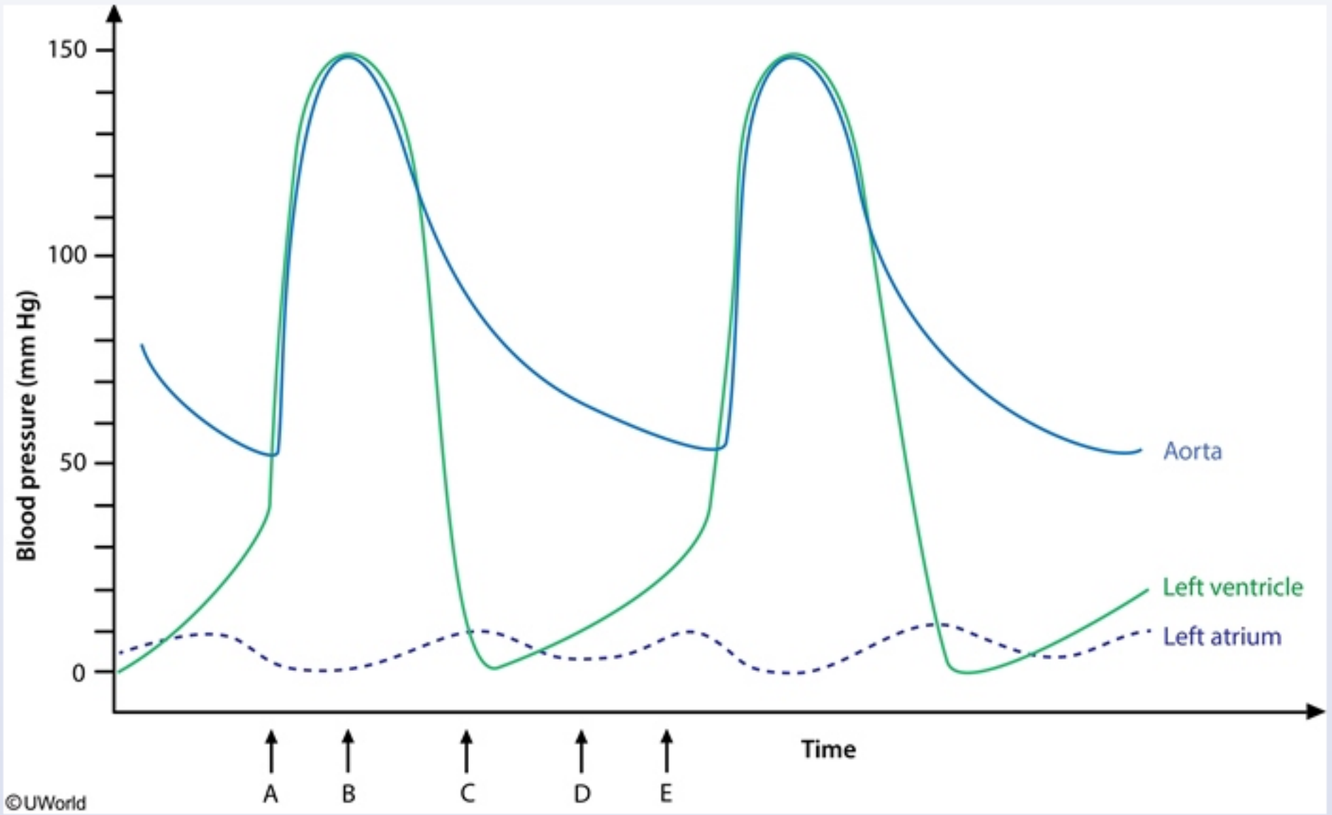

A. A

B. B

5
6
7
8
9
10
11
12
13
14
15
16
17
18
19
20
21
22
23
24
25
26
27
28
29
30
31
32
33
34
35

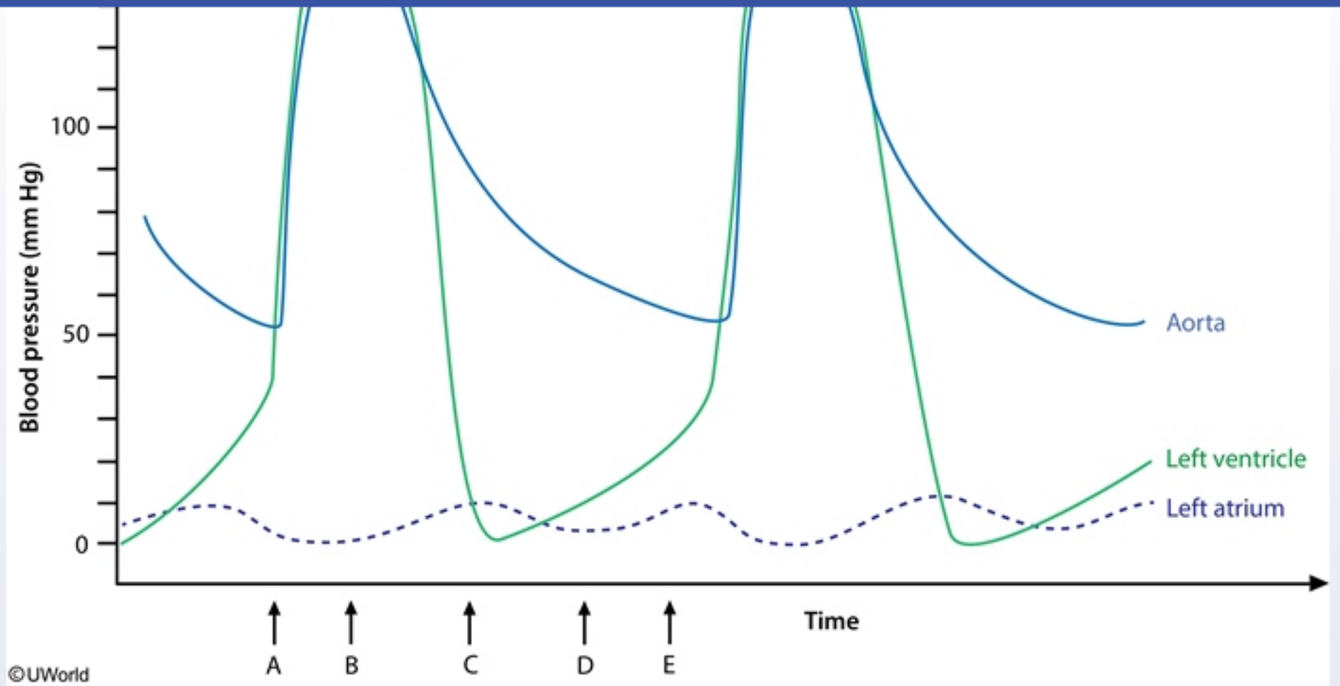

A. A

B. B

C. C

D. D

E. E

Submit

5
6
7
8
9
10
11
12
13
14
15
16
17
18
19
20
21
22
23
24
25
26
27
28
29
30
31
32
33
34
35

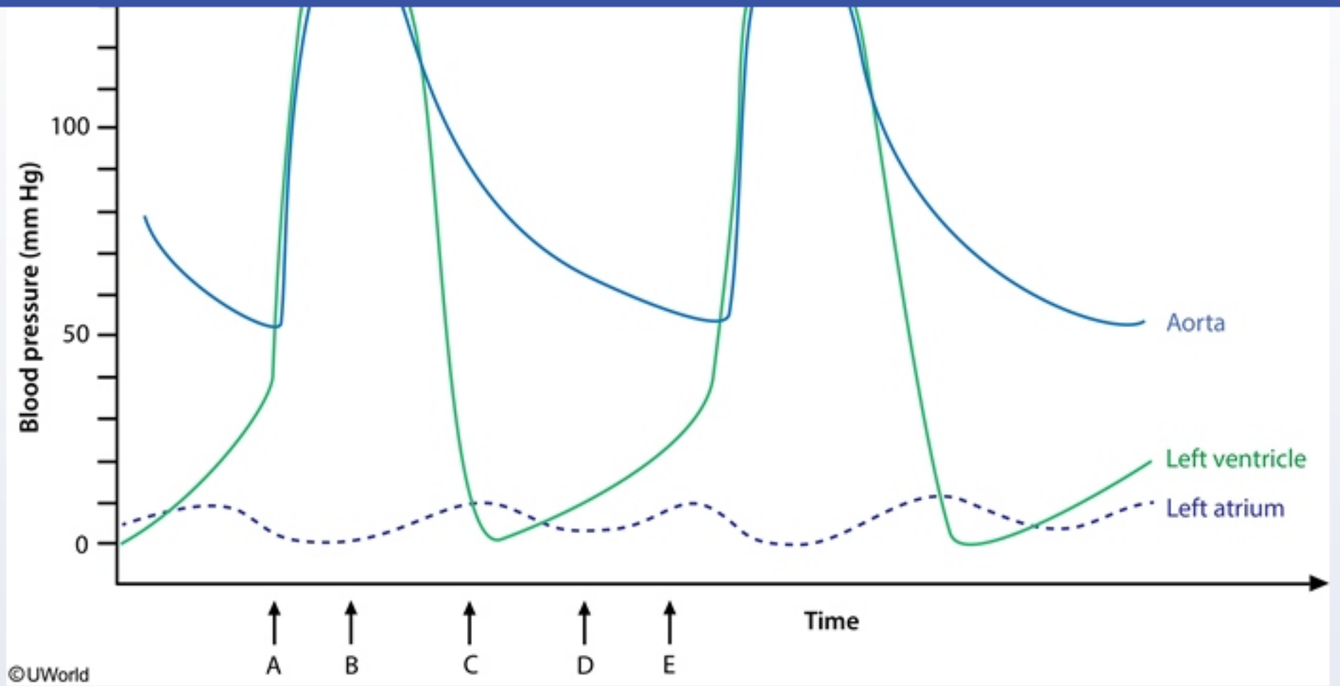

A. A (14%)

B. B (25%)

✓ C. C (47%)

D. D (9%)

E. E (3%)

Omitted
Correct answer

47%
Answered correctly

06 secs
Time Spent

04/20/2020
Last Updated

5
6
7
8
9
10
11
12
13
14
15
16
17
18
19
20
21
22
23
24
25
26
27
28
29
30
31
32
33
34
35

Normal

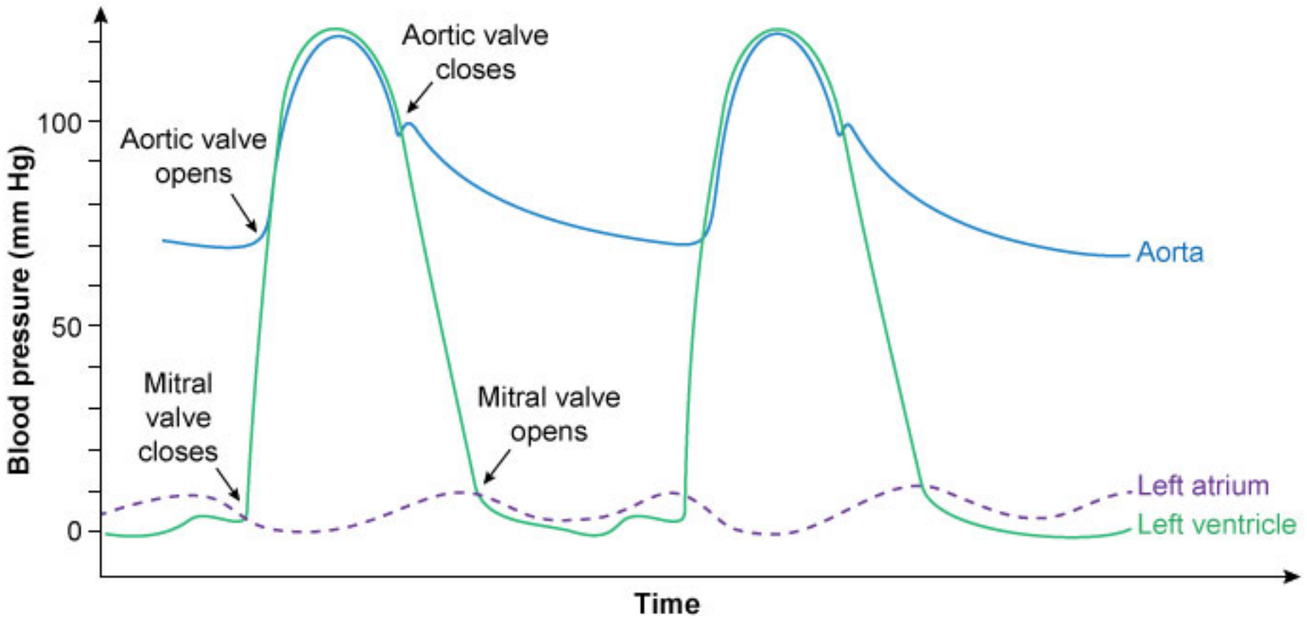

Aortic regurgitation

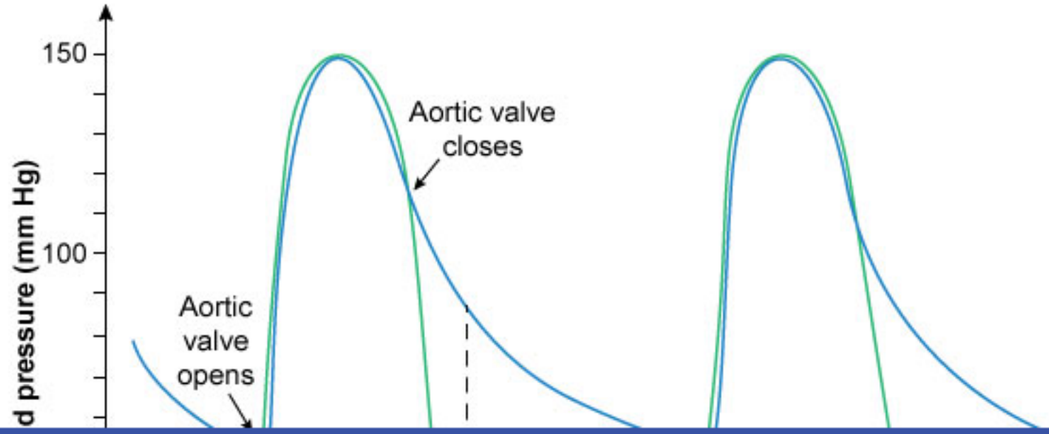

5
6
7
8
9
10
11
12
13
14
15
16
17
18
19
20
21
22
23
24
25
26
27
28
29
30
31
32
33
34
35

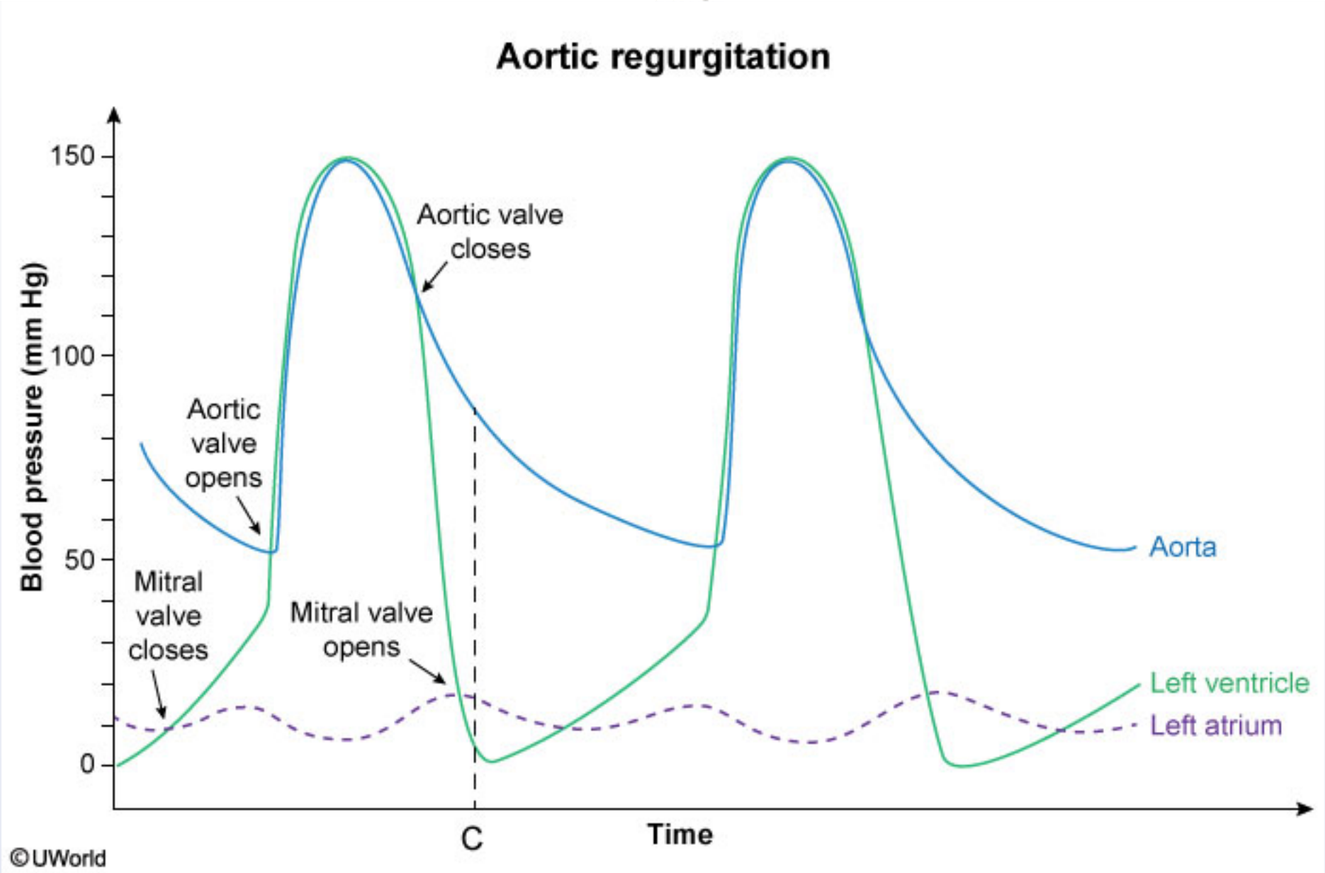

This patient's cardiac catheterization shows a hemodynamic profile consistent with **aortic regurgitation** (AR); the characteristic decrescendo diastolic murmur is best heard with the patient leaning forward. The **peak intensity** of the murmur occurs **just after aortic valve closure** when the pressure gradient between the aorta and the left ventricle is maximal (point C). This pressure gradient falls progressively during diastole as blood regurgitates into the left ventricle, accounting for the **decrescendo** nature of the murmur.

Notable changes to the pressure tracings that occur in AR include:

- **Loss of the aortic dicrotic notch**: On the normal aortic pressure tracing the dicrotic notch is created by a small and abrupt increase in aortic pressure as blood is ejected in the aorta by closure of the aortic valve. However, with an incompetent aortic valve there is immediate

This patient's cardiac catheterization shows a hemodynamic profile consistent with **aortic regurgitation** (AR); the characteristic decrescendo diastolic murmur is best heard with the patient leaning forward. The **peak intensity** of the murmur occurs **just after aortic valve closure** when the pressure gradient between the aorta and the left ventricle is maximal (point C). This pressure gradient falls progressively during diastole as blood regurgitates into the left ventricle, accounting for the **decrescendo** nature of the murmur.

Notable changes to the pressure tracings that occur in AR include:

- **Loss of the aortic dicrotic notch**: On the normal aortic pressure tracing the dicrotic notch is created by a small and abrupt increase in aortic pressure as blood is secured in the aorta by closure of the aortic valve. However, with an incompetent aortic valve there is immediate backflow of blood into the left ventricle, resulting in loss of pressure in the aorta and disappearance of the dicrotic notch.
- **Steep diastolic decline of aortic pressure**: Aortic diastolic pressure declines more rapidly than normal as blood regurgitates into the left ventricle and nadirs at a lower than normal level.
- **High-peaking left ventricular and aortic systolic pressures**: The left ventricle attempts to compensate for regurgitant backflow by increasing stroke volume, resulting in higher systolic blood pressures, which combined with low aortic diastolic pressure leads to a **wide pulse pressure**.

(Choice A) This point corresponds to the start of left ventricular contraction, just after mitral valve closure and just prior to the opening of the aortic valve; it would mark the onset of the holosystolic murmur of mitral regurgitation.

(Choice B) This is the peak systolic pressure produced by the left ventricle during systole; the peak intensity of the crescendo-decrescendo murmur of aortic stenosis is heard here.

(Choice D) This point corresponds to mid-diastole. The murmur of AR is likely heard here as well, but at a lower intensity given the relatively lower pressure gradient between the aorta and left ventricle. The low-pitch rumble of mitral stenosis would also be heard at this time.

(Choice E) This point marks the onset of left atrial contraction (atrial kick) just before closure of the mitral valve. Accentuation of a mitral stenosis murmur may be heard at this time (presystolic accentuation).

Educational objective:
Aortic regurgitation causes a decrescendo diastolic murmur with maximal intensity occurring just after closure of the aortic valve, when the pressure gradient between the aorta and left ventricle is the highest. The pressure tracing for aortic regurgitation is characterized by loss of the aortic dicrotic notch, steep diastolic decline in aortic pressure, and high-peaking systolic pressures.

backflow of blood into the left ventricle, resulting in loss of pressure in the aorta and disappearance of the dicrotic notch.

- **Steep diastolic decline of aortic pressure**: Aortic diastolic pressure declines more rapidly than normal as blood regurgitates into the left ventricle and nadirs at a lower than normal level.
- **High-peaking left ventricular and aortic systolic pressures**: The left ventricle attempts to compensate for regurgitant backflow by increasing stroke volume, resulting in higher systolic blood pressures, which combined with low aortic diastolic pressure leads to a **wide pulse pressure**.

(Choice A) This point corresponds to the start of left ventricular contraction, just after mitral valve closure and just prior to the opening of the aortic valve; it would mark the onset of the holosystolic murmur of mitral regurgitation.

(Choice B) This is the peak systolic pressure produced by the left ventricle during systole; the peak intensity of the crescendo-decrescendo murmur of aortic stenosis is heard here.

(Choice D) This point corresponds to mid-diastole. The murmur of AR is likely heard here as well, but at a lower intensity given the relatively lower pressure gradient between the aorta and left ventricle. The low-pitch rumble of mitral stenosis would also be heard at this time.

(Choice E) This point marks the onset of left atrial contraction (atrial kick) just before closure of the mitral valve. Accentuation of a mitral stenosis murmur may be heard at this time (presystolic accentuation).

Educational objective:
Aortic regurgitation causes a decrescendo diastolic murmur with maximal intensity occurring just after closure of the aortic valve, when the pressure gradient between the aorta and left ventricle is the highest. The pressure tracing for aortic regurgitation is characterized by loss of the aortic dicrotic notch, steep diastolic decline in aortic pressure, and high-peaking systolic pressures.

References

- The rational clinical examination. Does this patient have aortic regurgitation?

Pathophysiology	Cardiovascular System	Aortic regurgitation
Subject	System	Topic

Copyright © UWorld. All rights reserved.

A 21-year-old man comes to the office due to multiple episodes of syncope. The patient has no chest discomfort or dyspnea. He has no known medical problems and does not use tobacco, alcohol, or illicit drugs. The patient is a computer analyst and leads a mostly sedentary lifestyle. He reports that several family members have died of sudden cardiac death. Genetic analysis reveals an ion channel defect. Due to the defect, cardiac cells show decreased outward potassium flow and resultant prolongation of the action potential. Which of the following is the most likely consequence of this patient's disease?

- A. Abnormal anatomic communication between cardiac chambers
- B. Asymmetric hypertrophy of the left ventricle
- C. Ischemic myocardial necrosis followed by scarring
- D. Left ventricular dilation and systolic dysfunction
- E. Ventricular tachycardia and sudden death

Submit

1
2
3
4
5
6
7
8
9
10
11
12
13
14
15
16
17
18
19
20
21
22
23
24
25
26
27
28
29

A 21-year-old man comes to the office due to multiple episodes of syncope. The patient has no chest discomfort or dyspnea. He has no known medical problems and does not use tobacco, alcohol, or illicit drugs. The patient is a computer analyst and leads a mostly sedentary lifestyle. He reports that several family members have died of sudden cardiac death. Genetic analysis reveals an ion channel defect. Due to the defect, cardiac cells show decreased outward potassium flow and resultant prolongation of the action potential. Which of the following is the most likely consequence of this patient's disease?

A. Abnormal anatomic communication between cardiac chambers

B. Asymmetric hypertrophy of the left ventricle

C. Ischemic myocardial necrosis followed by scarring

D. Left ventricular dilation and systolic dysfunction

E. Ventricular tachycardia and sudden death

Submit

A 21-year-old man comes to the office due to multiple episodes of syncope. The patient has no chest discomfort or dyspnea. He has no known medical problems and does not use tobacco, alcohol, or illicit drugs. The patient is a computer analyst and leads a mostly sedentary lifestyle. He reports that several family members have died of sudden cardiac death. Genetic analysis reveals an ion channel defect. Due to the defect, cardiac cells show decreased outward potassium flow and resultant prolongation of the action potential. Which of the following is the most likely consequence of this patient's disease?

- A. Abnormal anatomic communication between cardiac chambers (6%)
- B. Asymmetric hypertrophy of the left ventricle (7%)
- C. Ischemic myocardial necrosis followed by scarring (1%)
- D. Left ventricular dilation and systolic dysfunction (9%)
- ✓ E. Ventricular tachycardia and sudden death (74%)

Omitted
Correct answer
E

74%
Answered correctly

21 secs
Time Spent

03/10/2020
Last Updated

Explanation

1 2 3 4 5 6 7 8 9 10 11 12 13 14 15 16 17 18 19 20 21 22 23 24 25 26 27 28 29

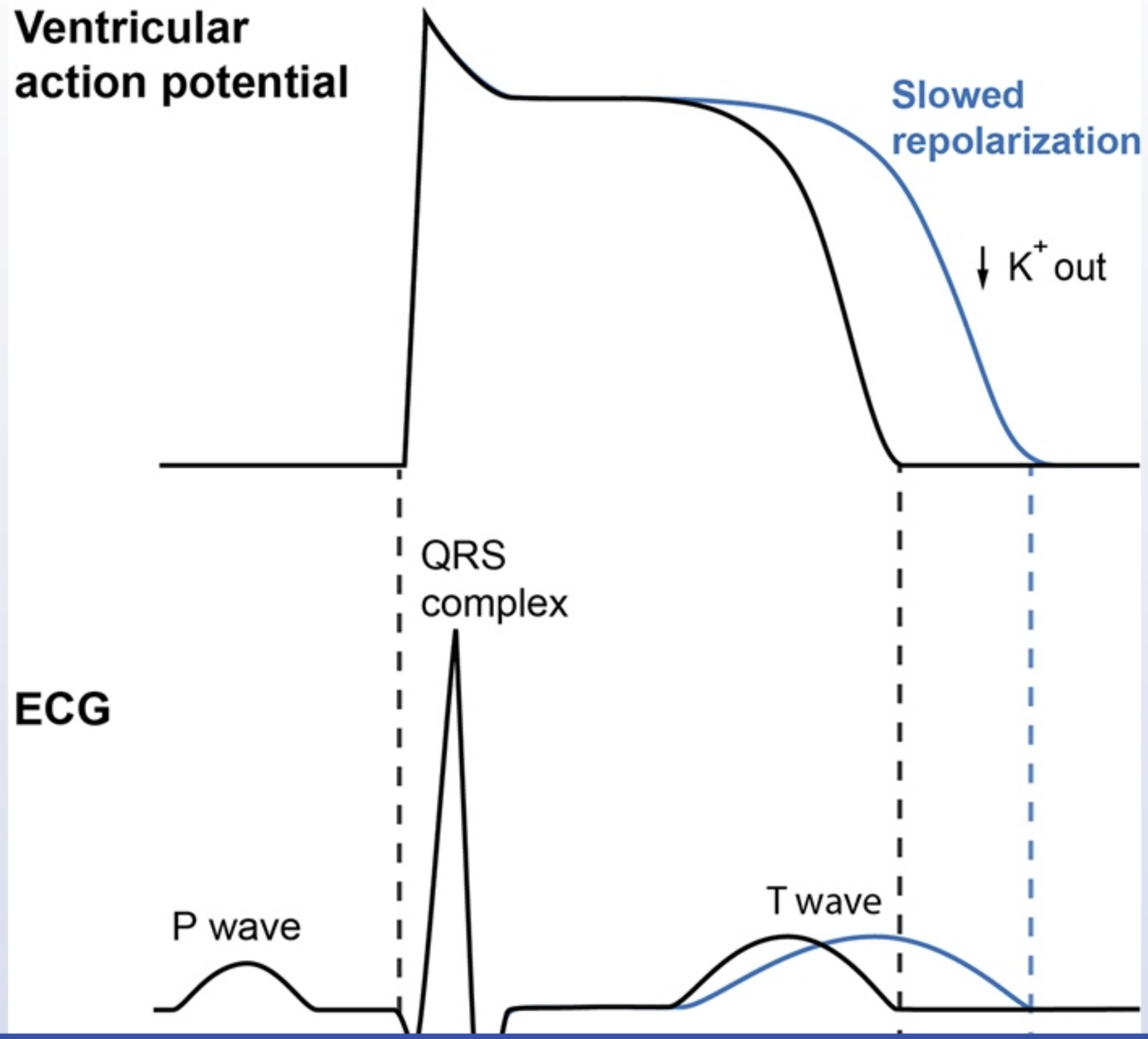

1 2 3 4 5 6 7 8 9 10 11 12 13 14 15 16 17 18 19 20 21 22 23 24 25 26 27 28 29

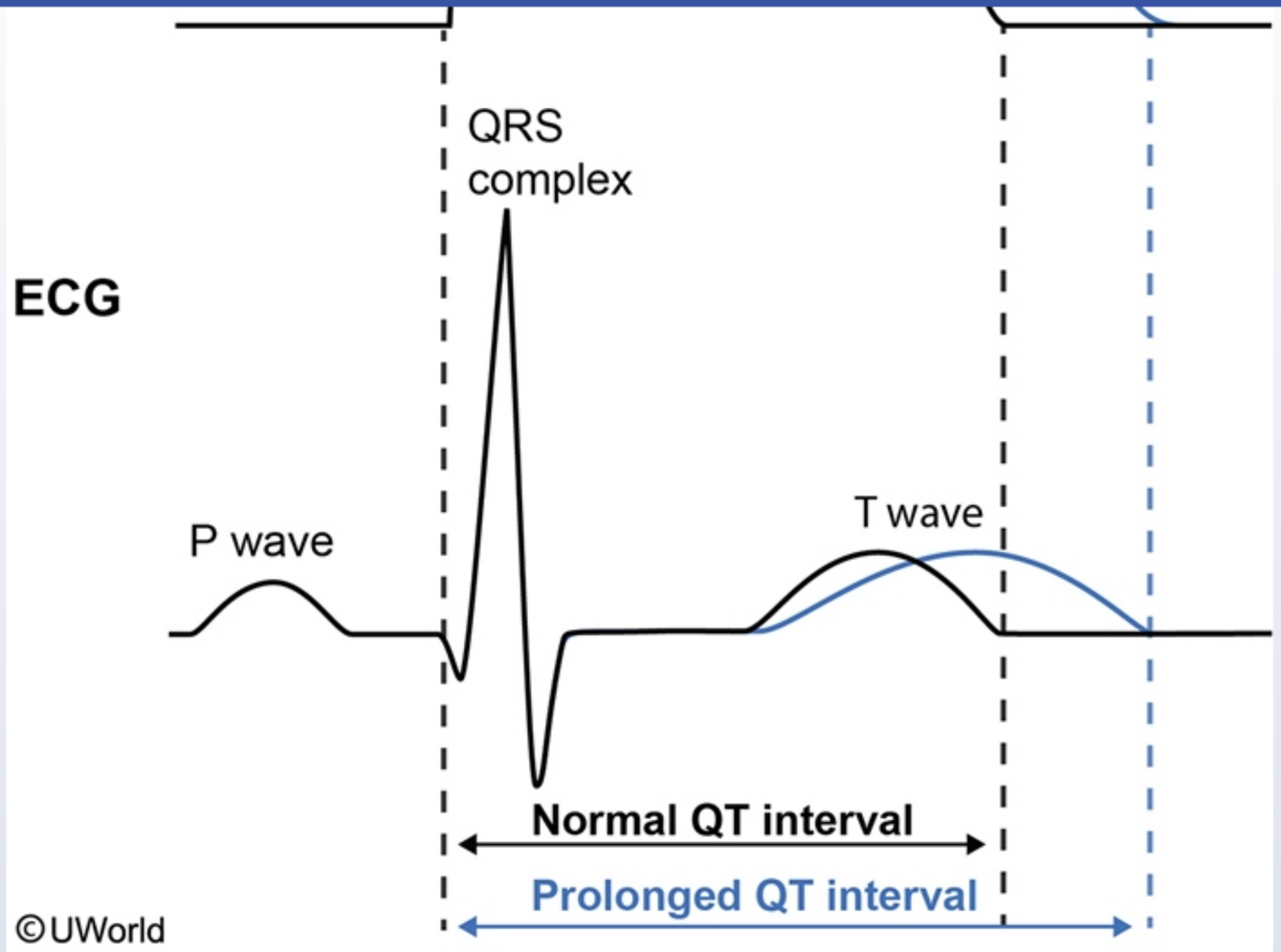

This patient's recurrent syncope, family history of sudden death, and ion channel defect (decreased outward potassium flow with prolonged action potential) is suggestive of **congenital long QT syndrome** (LQTS). There are several genetic mutations described in patients with congenital LQTS. The 2 most common forms (LQT type 1 and LQT type 2) are due to genetic **mutations in K+ channel** proteins that contribute to the outward-rectifying potassium current.

1
2
3
4
5
6
7
8
9
10
11
12
13
14
15
16
17
18
19
20
21
22
23
24
25
26
27
28
29

Exhibit Display

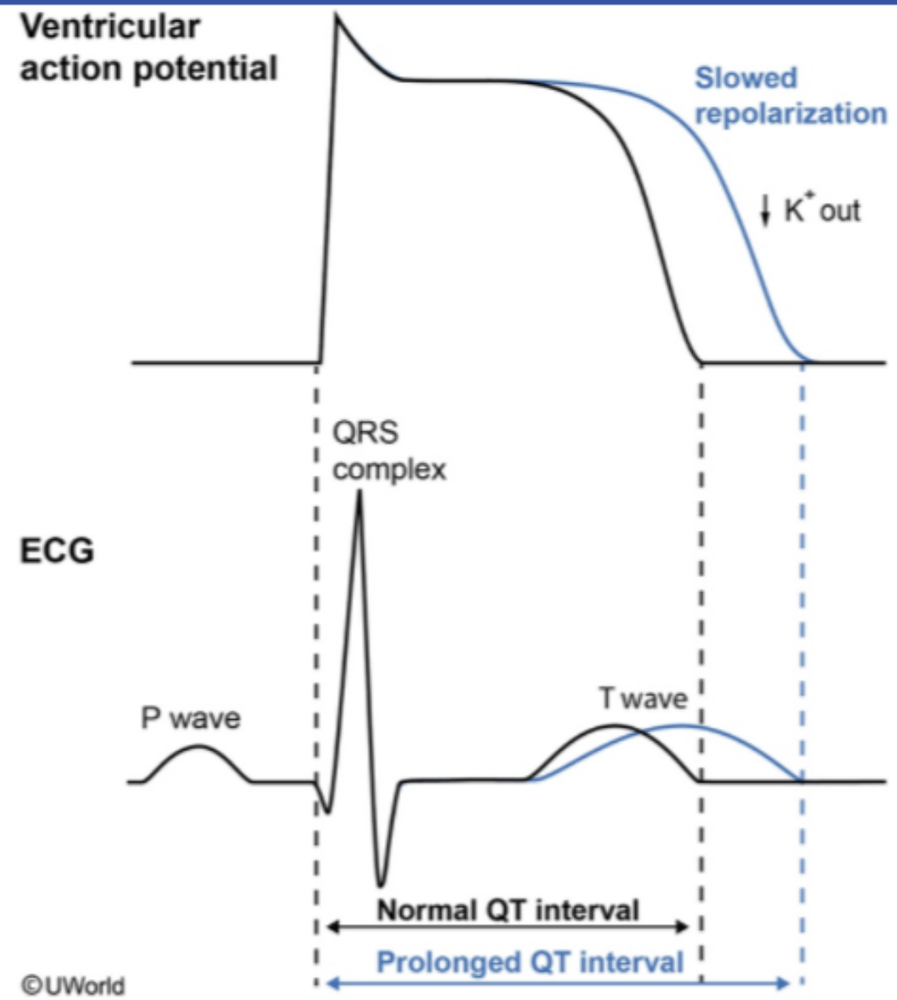

Zoom In Zoom Out Reset Add To New Card | Existing Card

This patient's recurrent syncope, family history of sudden death, and ion channel defect (decreased outward potassium flow with prolonged action potential) is suggestive of **congenital long QT syndrome** (LQTS). There are several genetic mutations described in patients with congenital LQTS. The 2 most common forms (LQT type 1 and LQT type 2) are due to genetic **mutations in K+ channel** proteins that contribute to the outward-rectifying potassium current.

Phase 3 (repolarization) of the myocardial action potential occurs due to time-dependent inactivation of the L-type (long-lasting, large-conductance) Ca^{2+} channels (which reduces inward current) along with activation of the voltage-gated delayed rectifier K^+ channels (which increases outward current). This net increase in outward transmembrane current is responsible for ventricular repolarization. **Decreased outward potassium** flow due to K^+ channel mutations leads to prolongation of action potential duration and QT interval. Prolongation of QT interval predisposes to the development of life-threatening ventricular arrhythmias (eg, torsades de pointes), which can present as recurrent palpitations, **syncope**, **seizures**, or **sudden cardiac death**.

(Choice A) Abnormal anatomic communication between cardiac chambers presents in patients with atrial septal defects, ventricular septal defects, or patent ductus arteriosus. These disorders are not associated with any genetic defects in ion channels.

(Choice B) Asymmetric hypertrophy of the left ventricle occurs in patients with hypertrophic cardiomyopathy, an autosomal dominant disorder caused by mutations in sarcomere genes. The 2 most common mutations involve the cardiac myosin-binding protein C gene and cardiac beta-myosin heavy chain gene.

(Choice C) Ischemic myocardial necrosis and scarring occur in myocardial infarction and often lead to left ventricular systolic dysfunction. Patients with scarred myocardium are also at increased risk for developing ventricular arrhythmias; however, these arrhythmias would not be associated with an ion channel defect.

(Choice D) Dilated cardiomyopathy is characterized by left ventricle dilation and systolic dysfunction. Several genetic mutations involving the sarcomere structure and function have been identified in patients with familial dilated cardiomyopathy. However, abnormal transmembrane K^+ currents are not known to be directly involved in the pathophysiology.

Educational objective:
Congenital long QT syndrome is most often caused by genetic mutations in a K^+ channel protein that contributes to the outward-rectifying potassium current. A decrease in the outward K^+ current leads to prolongation of action potential duration and QT interval. This prolongation predisposes to the development of life-threatening ventricular arrhythmias (eg, torsades de pointes) that can cause palpitations, syncope,

outward-rectifying potassium current.

Phase 3 (repolarization) of the myocardial action potential occurs due to time-dependent inactivation of the L-type (long-lasting, large-conductance) Ca^{2+} channels (which reduces inward current) along with activation of the voltage-gated delayed rectifier K^+ channels (which increases outward current). This net increase in outward transmembrane current is responsible for ventricular repolarization. **Decreased outward potassium** flow due to K^+ channel mutations leads to prolongation of action potential duration and QT interval. Prolongation of QT interval predisposes to the development of life-threatening ventricular arrhythmias (eg, torsades de pointes), which can present as recurrent palpitations, **syncope**, **seizures**, or **sudden cardiac death**.

(Choice A) Abnormal anatomic communication between cardiac chambers presents in patients with atrial septal defects, ventricular septal defects, or patent ductus arteriosus. These disorders are not associated with any genetic defects in ion channels.

(Choice B) Asymmetric hypertrophy of the left ventricle occurs in patients with hypertrophic cardiomyopathy, an autosomal dominant disorder caused by mutations in sarcomere genes. The 2 most common mutations involve the cardiac myosin-binding protein C gene and cardiac beta-myosin heavy chain gene.

(Choice C) Ischemic myocardial necrosis and scarring occur in myocardial infarction and often lead to left ventricular systolic dysfunction. Patients with scarred myocardium are also at increased risk for developing ventricular arrhythmias; however, these arrhythmias would not be associated with an ion channel defect.

(Choice D) Dilated cardiomyopathy is characterized by left ventricle dilation and systolic dysfunction. Several genetic mutations involving the sarcomere structure and function have been identified in patients with familial dilated cardiomyopathy. However, abnormal transmembrane K^+ currents are not known to be directly involved in the pathophysiology.

Educational objective:
Congenital long QT syndrome is most often caused by genetic mutations in a K^+ channel protein that contributes to the outward-rectifying potassium current. A decrease in the outward K^+ current leads to prolongation of action potential duration and QT interval. This prolongation predisposes to the development of life-threatening ventricular arrhythmias (eg, torsades de pointes) that can cause palpitations, syncope, seizures, or sudden cardiac death.

Pathology Cardiovascular System Long QT syndrome

1
2
3
4
5
6
7
8
9
10
11
12
13
14
15
16
17
18
19
20
21
22
23
24
25
26
27
28
29

Exhibit Display

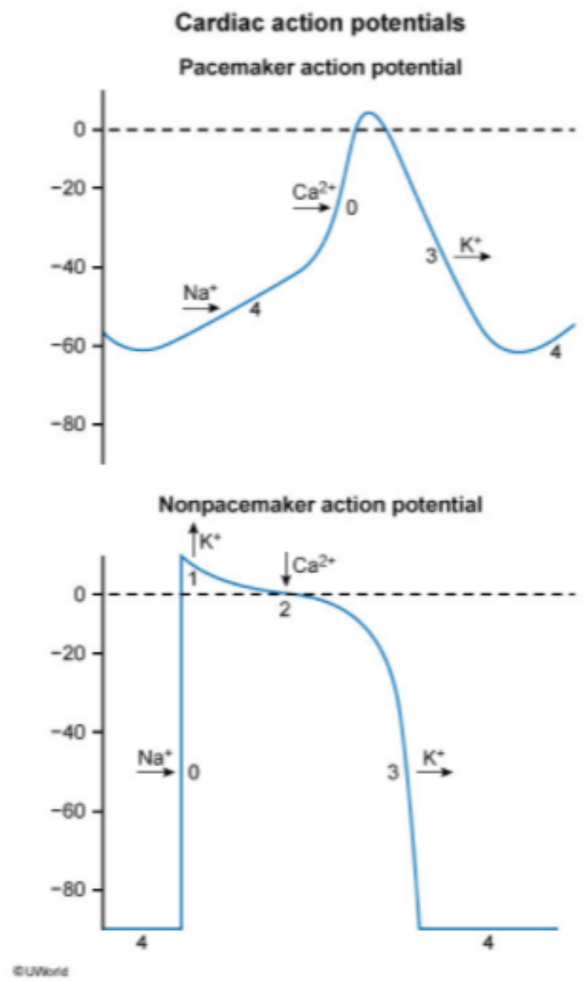

Zoom In Zoom Out Reset Add To New Card | Existing Card

Patients with scarred myocardium are also at increased risk for developing ventricular arrhythmias; however, these arrhythmias would not be

outward-rectifying potassium current.

Exhibit Display

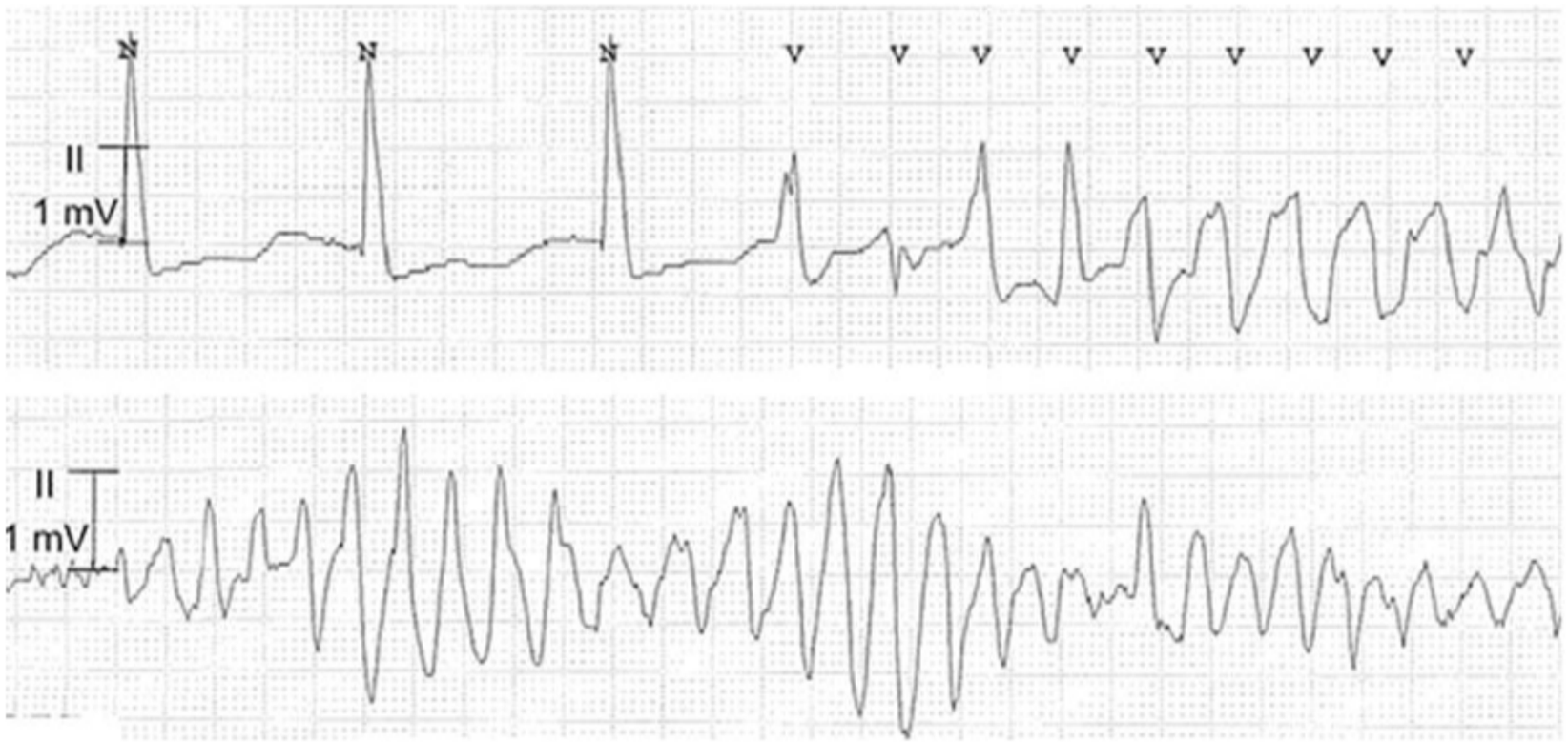

Zoom In | Zoom Out | Reset | Add To New Card | Existing Card

Pathology | Cardiovascular System | Long QT syndrome

increases outward current). This net increase in outward transmembrane current is responsible for ventricular repolarization. **Decreased outward potassium** flow due to K^+ channel mutations leads to prolongation of action potential duration and QT interval. Prolongation of QT interval predisposes to the development of life-threatening ventricular arrhythmias (eg, torsades de pointes), which can present as recurrent palpitations, **syncope**, **seizures**, or **sudden cardiac death**.

(Choice A) Abnormal anatomic communication between cardiac chambers presents in patients with atrial septal defects, ventricular septal defects, or patent ductus arteriosus. These disorders are not associated with any genetic defects in ion channels.

(Choice B) Asymmetric hypertrophy of the left ventricle occurs in patients with hypertrophic cardiomyopathy, an autosomal dominant disorder caused by mutations in sarcomere genes. The 2 most common mutations involve the cardiac myosin-binding protein C gene and cardiac beta-myosin heavy chain gene.

(Choice C) Ischemic myocardial necrosis and scarring occur in myocardial infarction and often lead to left ventricular systolic dysfunction. Patients with scarred myocardium are also at increased risk for developing ventricular arrhythmias; however, these arrhythmias would not be associated with an ion channel defect.

(Choice D) Dilated cardiomyopathy is characterized by left ventricle dilation and systolic dysfunction. Several genetic mutations involving the sarcomere structure and function have been identified in patients with familial dilated cardiomyopathy. However, abnormal transmembrane K^+ currents are not known to be directly involved in the pathophysiology.

Educational objective:
Congenital long QT syndrome is most often caused by genetic mutations in a K^+ channel protein that contributes to the outward-rectifying potassium current. A decrease in the outward K^+ current leads to prolongation of action potential duration and QT interval. This prolongation predisposes to the development of life-threatening ventricular arrhythmias (eg, torsades de pointes) that can cause palpitations, syncope, seizures, or sudden cardiac death.

Pathology	Cardiovascular System	Long QT syndrome
Subject	System	Topic

Copyright © UWorld. All rights reserved.

A 34-year-old woman is evaluated in the emergency department due to 1-day of chest and left shoulder pain. The patient describes the pain as constant and worse in certain positions. A month ago, she was treated for a skin rash and joint pain. Her medical history is otherwise unremarkable. She is a lifetime nonsmoker and does not use alcohol or illicit drugs. Her father has hypertension and had a stroke at age 64. Temperature is 37.5 C (99.5 F), blood pressure is 122/70 mm Hg, and pulse is 97/min and regular. A triphasic, scratchy sound is heard over the left sternal border with the patient sitting up. The lungs are clear on auscultation. ECG shows sinus rhythm with ST-segment elevation in all leads except avR and V1. Which of the following is the most likely diagnosis?

A. Eosinophilic myocarditis

B. Fibrinous pericarditis

C. Hemorrhagic pericarditis

D. Nonbacterial endocarditis

E. Purulent pericarditis

Submit

A 34-year-old woman is evaluated in the emergency department due to 1-day of chest and left shoulder pain. The patient describes the pain as constant and worse in certain positions. A month ago, she was treated for a skin rash and joint pain. Her medical history is otherwise unremarkable. She is a lifetime nonsmoker and does not use alcohol or illicit drugs. Her father has hypertension and had a stroke at age 64. Temperature is 37.5 C (99.5 F), blood pressure is 122/70 mm Hg, and pulse is 97/min and regular. A triphasic, scratchy sound is heard over the left sternal border with the patient sitting up. The lungs are clear on auscultation. ECG shows sinus rhythm with ST-segment elevation in all leads except avR and V1. Which of the following is the most likely diagnosis?

- A. Eosinophilic myocarditis (7%)
- ✓ B. Fibrinous pericarditis (67%)
- C. Hemorrhagic pericarditis (2%)
- D. Nonbacterial endocarditis (11%)
- E. Purulent pericarditis (11%)

Omitted
Correct answer
B

67%
Answered correctly

02 secs
Time Spent

05/23/2020
Last Updated

Explanation

Acute pericarditis	
	• Viral or idiopathic • Autoimmune disease (eg, SLE)

1
2
3
4
5
6
7
8
9
10
11
12
13
14
15
16
17
18
19
20
21
22
23
24
25
26
27
28
29

Acute pericarditis	

Etiology	• Viral or idiopathic
	• Autoimmune disease (eg, SLE)
	• Uremia (acute or chronic renal failure)
	• Post myocardial infarction
	  ◦ Early: peri-infarction pericarditis
	  ◦ Late: Dressler syndrome

Clinical features & diagnosis	• Pleuritic chest pain (↓ when sitting up) ± fever • Pericardial friction rub • ECG: diffuse ST elevation • Pericardial effusion on echocardiogram

SLE = systemic lupus erythematosus.

This patient with pleuritic-type chest pain radiating to the shoulder and a recent history of skin rash and joint pain likely has acute **fibrinous pericarditis** due to **systemic lupus erythematosus**. Fibrinous pericarditis is the most common type of pericarditis and consists of pericardial inflammation with serous fluid and **fibrin-containing exudate** in the pericardial space.

Patients typically have pleuritic (sharp, worse with breathing or movement) anterior chest pain that can radiate to the left shoulder or posteriorly to the bilateral scapulae. Fibrin deposition causes roughening of the visceral and parietal pericardium, often heard as a **triphasic friction rub** (occurring during atrial systole, ventricular systole, and early ventricular diastole) on cardiac auscultation; however, the rub can be absent if significant pericardial effusion is present. ECG typically shows **diffuse ST elevation** due to inflammation of the ventricular myocardium.

Other causes of fibrinous pericarditis include viral infection, myocardial infarction, uremia, and other rheumatologic disease (eg, rheumatoid arthritis). If acute fibrinous pericarditis goes without treatment, chronic constrictive pericarditis can develop in some patients.

(Choice A) Eosinophilic myocarditis can occur with malignancy, parasitic infection, or drug hypersensitivity and often presents with symptoms of heart failure. A friction rub on cardiac auscultation is not expected.

This patient with pleuritic-type chest pain radiating to the shoulder and a recent history of skin rash and joint pain likely has acute **fibrinous pericarditis** due to **systemic lupus erythematosus**. Fibrinous pericarditis is the most common type of pericarditis and consists of pericardial inflammation with serous fluid and **fibrin-containing exudate** in the pericardial space.

Patients typically have pleuritic (sharp, worse with breathing or movement) anterior chest pain that can radiate to the left shoulder or posteriorly to the bilateral scapulae. Fibrin deposition causes roughening of the visceral and parietal pericardium, often heard as a **triphasic friction rub** (occurring during atrial systole, ventricular systole, and early ventricular diastole) on cardiac auscultation; however, the rub can be absent if significant pericardial effusion is present. ECG typically shows **diffuse ST elevation** due to inflammation of the ventricular myocardium.

Other causes of fibrinous pericarditis include viral infection, myocardial infarction, uremia, and other rheumatologic disease (eg, rheumatoid arthritis). If acute fibrinous pericarditis goes without treatment, chronic constrictive pericarditis can develop in some patients.

(Choice A) Eosinophilic myocarditis can occur with malignancy, parasitic infection, or drug hypersensitivity and often presents with symptoms of heart failure. A friction rub on cardiac auscultation is not expected.

(Choices C and E) Hemorrhagic and purulent pericarditis are both less common than fibrinous pericarditis. Hemorrhagic pericarditis consists of blood mixed with fibrinous exudate; it most commonly occurs in the setting of malignancy but may also occur due to tuberculosis, following cardiac surgery, or in patients with underlying coagulopathy. Purulent pericarditis results from active bacterial infection (eg, *Staphylococcus aureus*, *Streptococcus* species) in the pericardial space, which may occur due to hematogenous spread or direct extension of pneumonia or endocarditis.

(Choice D) Nonbacterial endocarditis can occur in systemic lupus erythematosus and involves deposition of sterile, platelet-rich thrombi on the mitral or aortic valve. It would not explain a friction rub or diffuse ST elevation on ECG.

Educational objective:
Fibrinous pericarditis is the most common type of pericarditis and is characterized by pericardial inflammation with a serous, fibrin-containing exudate in the pericardial space. Pleuritic chest pain and a triphasic friction rub are frequently seen. Common causes include viral infection, myocardial infarction, uremia, and rheumatologic disease (eg, systemic lupus erythematosus, rheumatoid arthritis).

References

- Acute pericarditis.

Pathology Cardiovascular System Acute pericarditis

Patients typically have pleuritic (sharp, worse with breathing or movement) anterior chest pain that can radiate to the left shoulder or posteriorly to the bilateral scapulae. Fibrin deposition causes roughening of the visceral and parietal pericardium, often heard as a **triphasic friction rub** (occurring during atrial systole, ventricular systole, and early ventricular diastole) on cardiac auscultation; however, the rub can be absent if significant pericardial effusion is present. ECG typically shows **diffuse ST elevation** due to inflammation of the ventricular myocardium.

Other causes of fibrinous pericarditis include viral infection, myocardial infarction, uremia, and other rheumatologic disease (eg, rheumatoid arthritis). If acute fibrinous pericarditis goes without treatment, chronic constrictive pericarditis can develop in some patients.

(Choice A) Eosinophilic myocarditis can occur with malignancy, parasitic infection, or drug hypersensitivity and often presents with symptoms of heart failure. A friction rub on cardiac auscultation is not expected.

(Choices C and E) Hemorrhagic and purulent pericarditis are both less common than fibrinous pericarditis. Hemorrhagic pericarditis consists of blood mixed with fibrinous exudate; it most commonly occurs in the setting of malignancy but may also occur due to tuberculosis, following cardiac surgery, or in patients with underlying coagulopathy. Purulent pericarditis results from active bacterial infection (eg, *Staphylococcus aureus*, *Streptococcus* species) in the pericardial space, which may occur due to hematogenous spread or direct extension of pneumonia or endocarditis.

(Choice D) Nonbacterial endocarditis can occur in systemic lupus erythematosus and involves deposition of sterile, platelet-rich thrombi on the mitral or aortic valve. It would not explain a friction rub or diffuse ST elevation on ECG.

Educational objective:
Fibrinous pericarditis is the most common type of pericarditis and is characterized by pericardial inflammation with a serous, fibrin-containing exudate in the pericardial space. Pleuritic chest pain and a triphasic friction rub are frequently seen. Common causes include viral infection, myocardial infarction, uremia, and rheumatologic disease (eg, systemic lupus erythematosus, rheumatoid arthritis).

References

- Acute pericarditis.

Pathology	Cardiovascular System	Acute pericarditis
Subject	System	Topic

Copyright © UWorld. All rights reserved.

Patients typically have pleuritic (sharp, worse with breathing or movement) anterior chest pain that can radiate to the left shoulder or posteriorly to

Exhibit Display

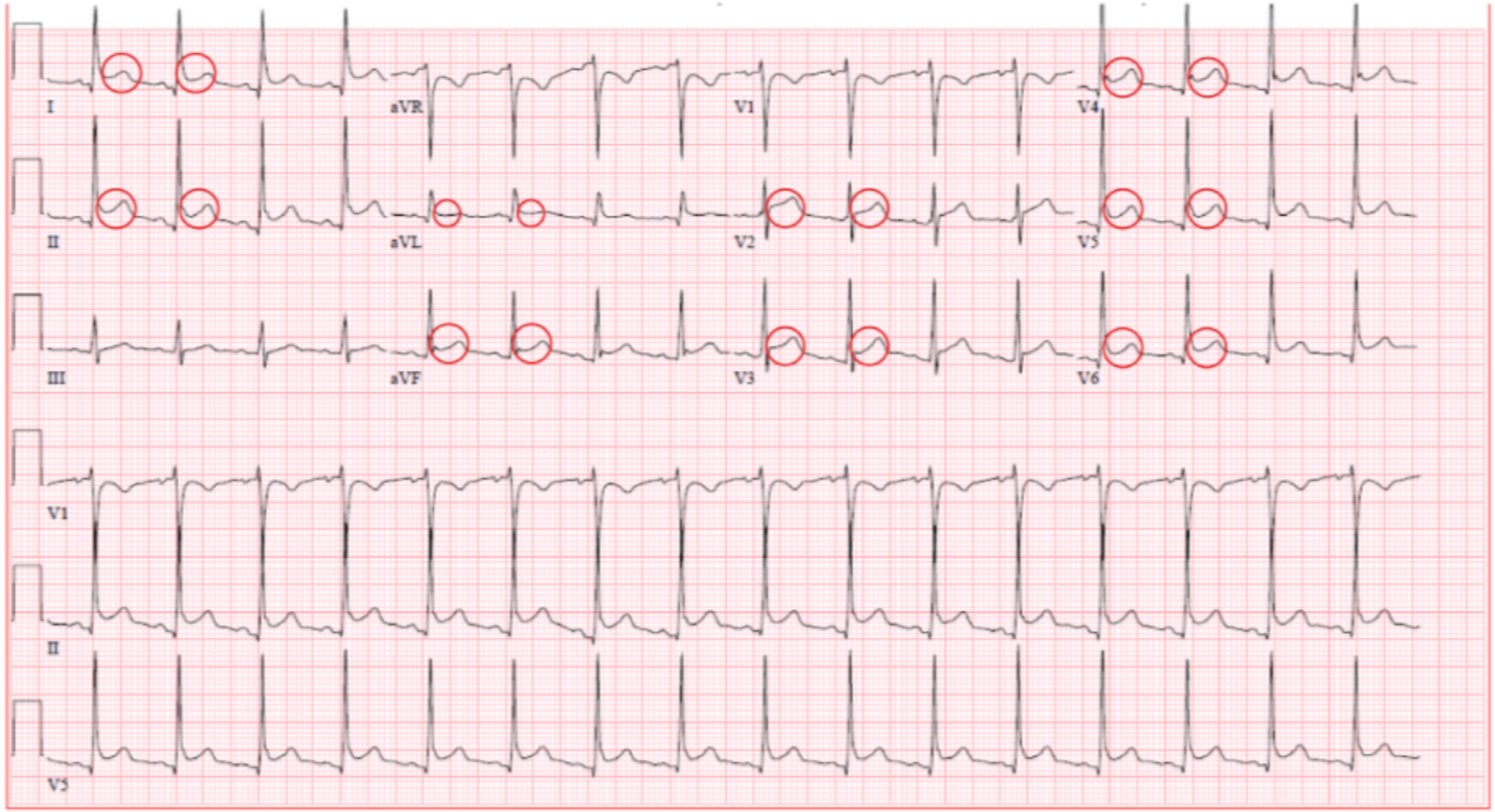

Zoom In | Zoom Out | Reset | Add To New Card | Existing Card

Patients typically have pleuritic (sharp, worse with breathing or movement) anterior chest pain that can radiate to the left shoulder or posteriorly to

Exhibit Display

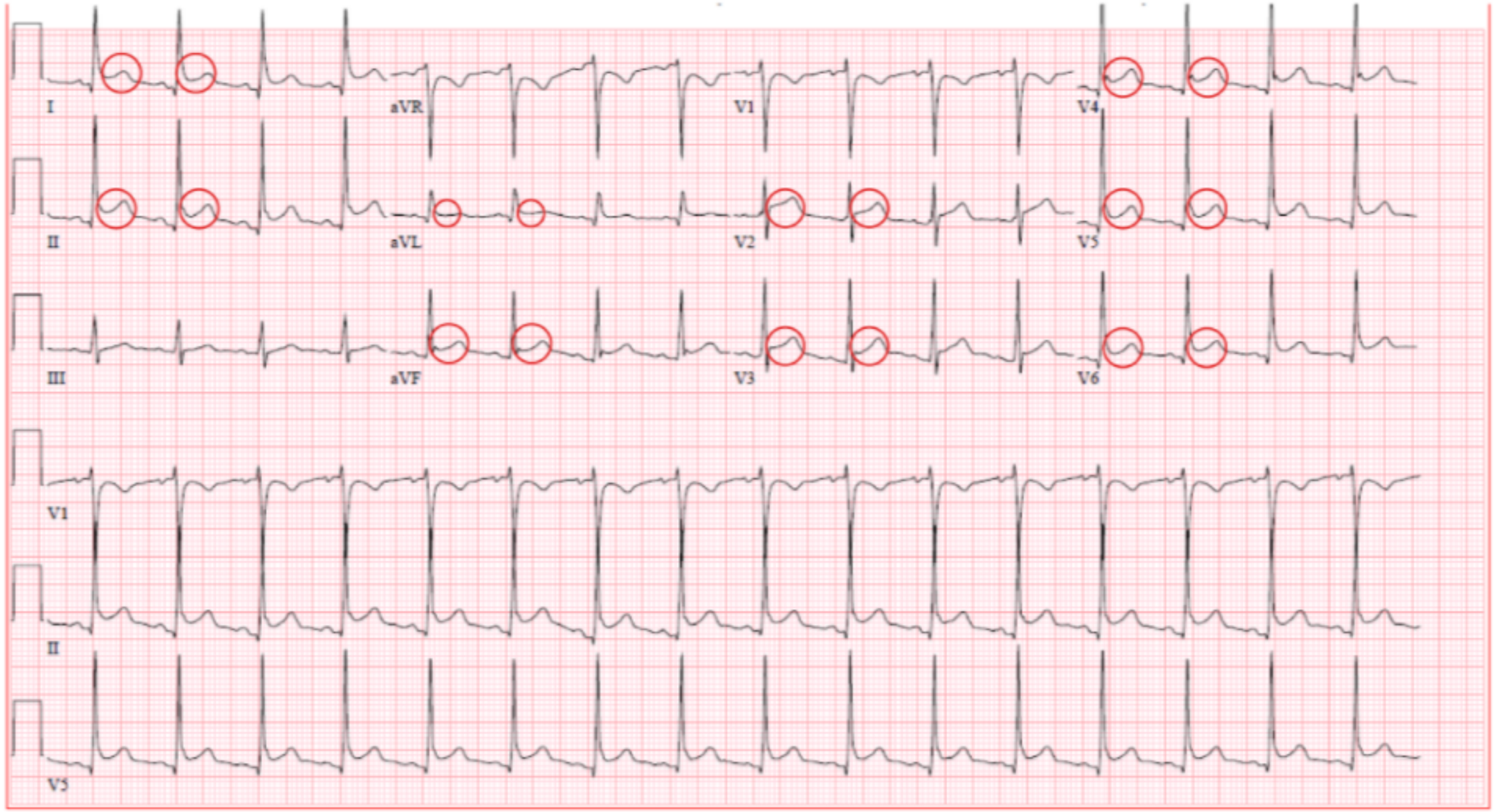

Zoom In | Zoom Out | Reset | Add To New Card | Existing Card

Patients typically have pleuritic (sharp, worse with breathing or movement) anterior chest pain that can radiate to the left shoulder or posteriorly to

Exhibit Display

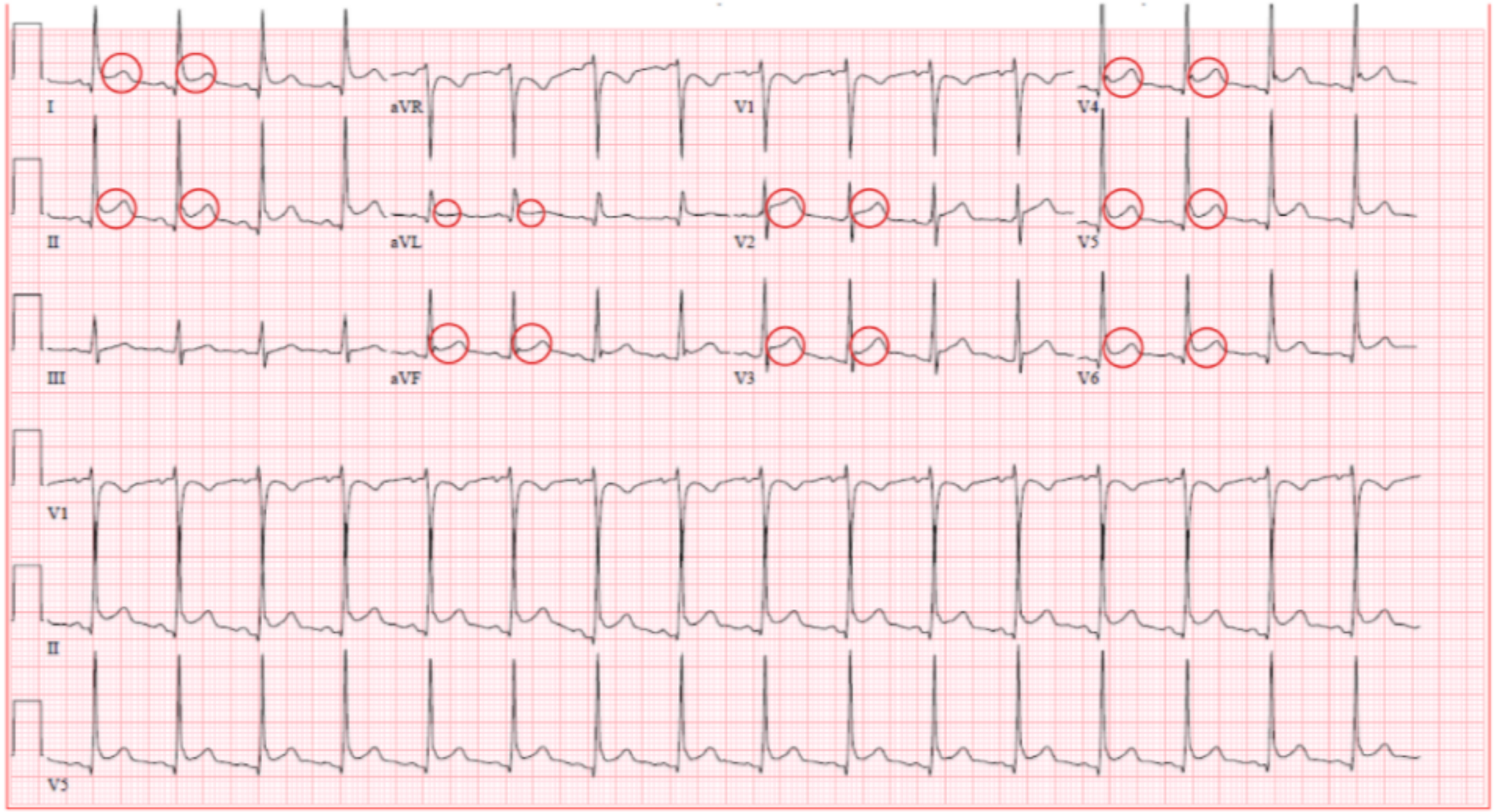

Zoom In | Zoom Out | Reset | Add To New Card | Existing Card

A 62-year-old man dies suddenly in his sleep. The patient had a history of type 2 diabetes mellitus and hypertension, and he smoked a pack of cigarettes daily for 25 years. His adherence to medical care was poor. Autopsy is performed, and a histologic section of his left ventricular myocardium is shown below:

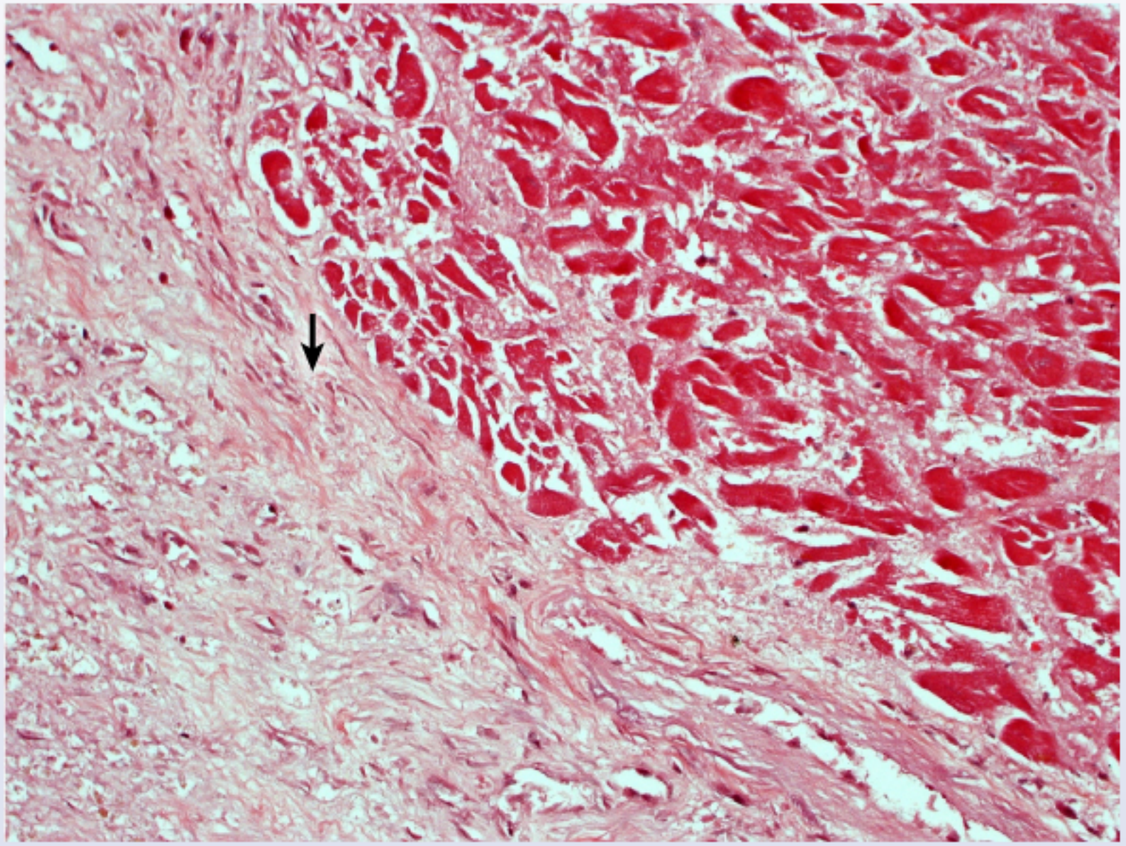

Which of the following directly promotes the formation of the tissue indicated by the arrow?

A. Endothelium-derived relaxing factor

B. Interferon-beta

1
2
3
4
5
6
7
8
9
10
11
12
13
14
15
16
17
18
19
20
21
22
23
24
25
26
27
28
29

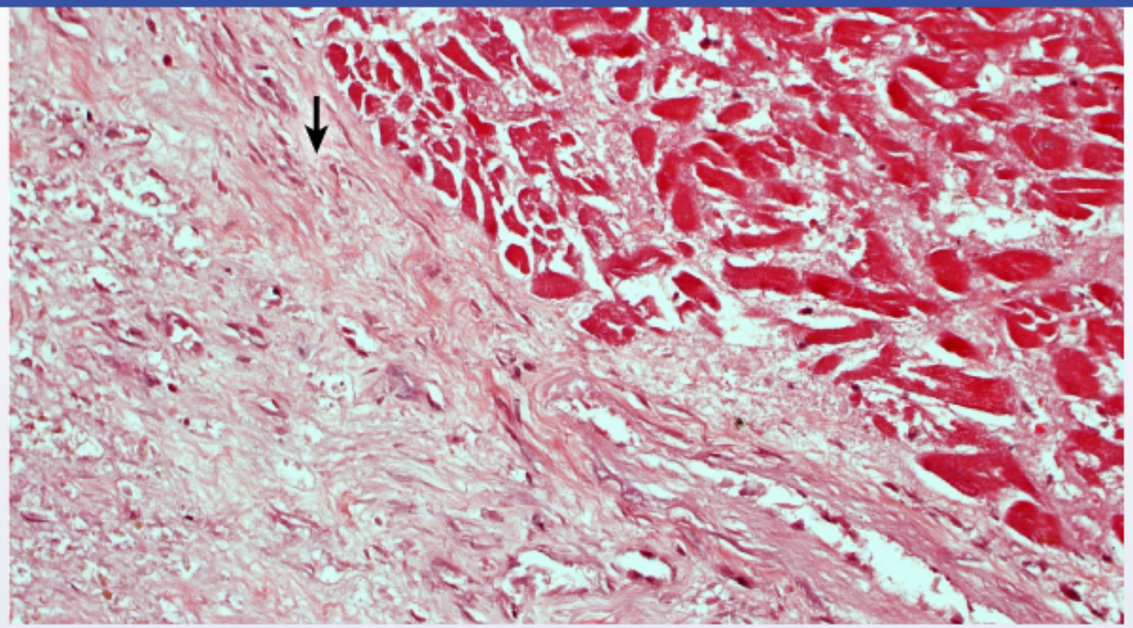

Which of the following directly promotes the formation of the tissue indicated by the arrow?

A. Endothelium-derived relaxing factor

B. Interferon-beta

C. Interleukin-8

D. Transforming growth factor-beta

E. Tumor necrosis factor-alpha

Submit

1
2
3
4
5
6
7
8
9
10
11
12
13
14
15
16
17
18
19
20
21
22
23
24
25
26
27
28
29

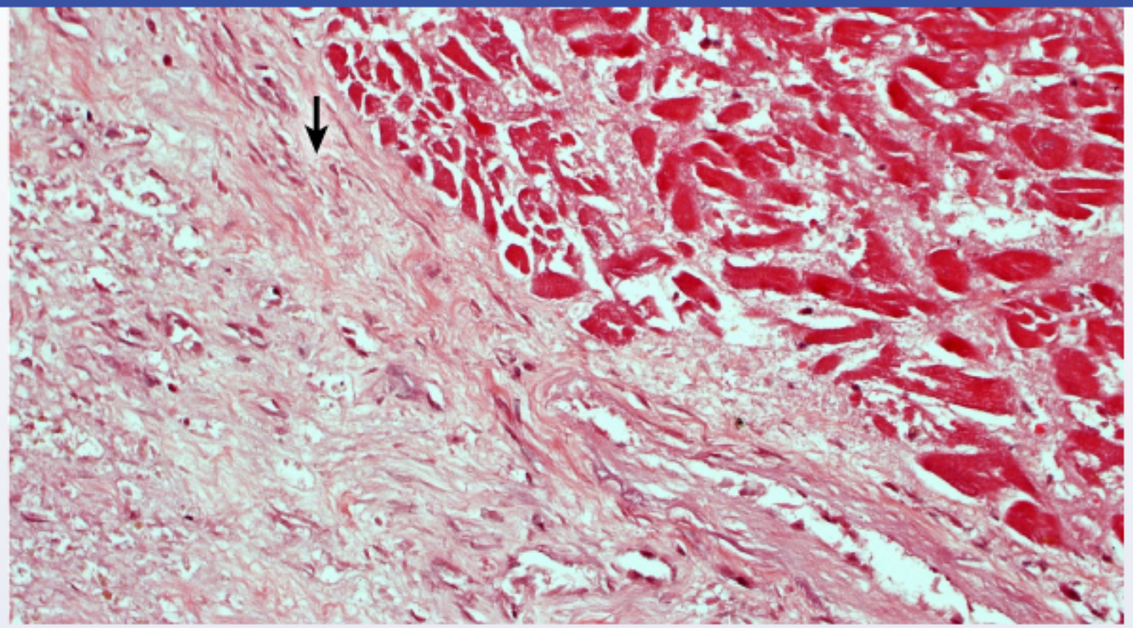

Which of the following directly promotes the formation of the tissue indicated by the arrow?

A. Endothelium-derived relaxing factor

B. Interferon-beta

C. Interleukin-8

D. Transforming growth factor-beta

E. Tumor necrosis factor-alpha

Submit

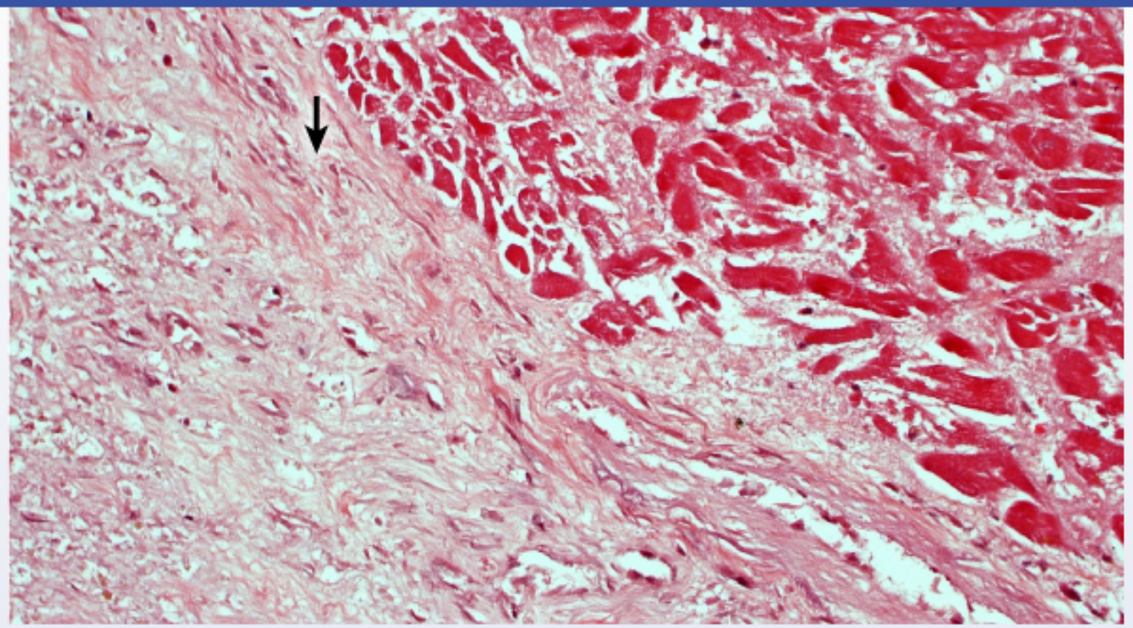

Which of the following directly promotes the formation of the tissue indicated by the arrow?

- A. Endothelium-derived relaxing factor (3%)
- B. Interferon-beta (1%)
- C. Interleukin-8 (2%)
- ✓ D. Transforming growth factor-beta (81%)
- E. Tumor necrosis factor-alpha (10%)

Omitted
Correct answer

81%
Answered correctly

23 secs
Time Spent

03/24/2020
Last Updated

1
2
3
4
5
6
7
8
9
10
11
12
13
14
15
16
17
18
19
20
21
22
23
24
25
26
27
28
29

Resolved myocardial infarcts

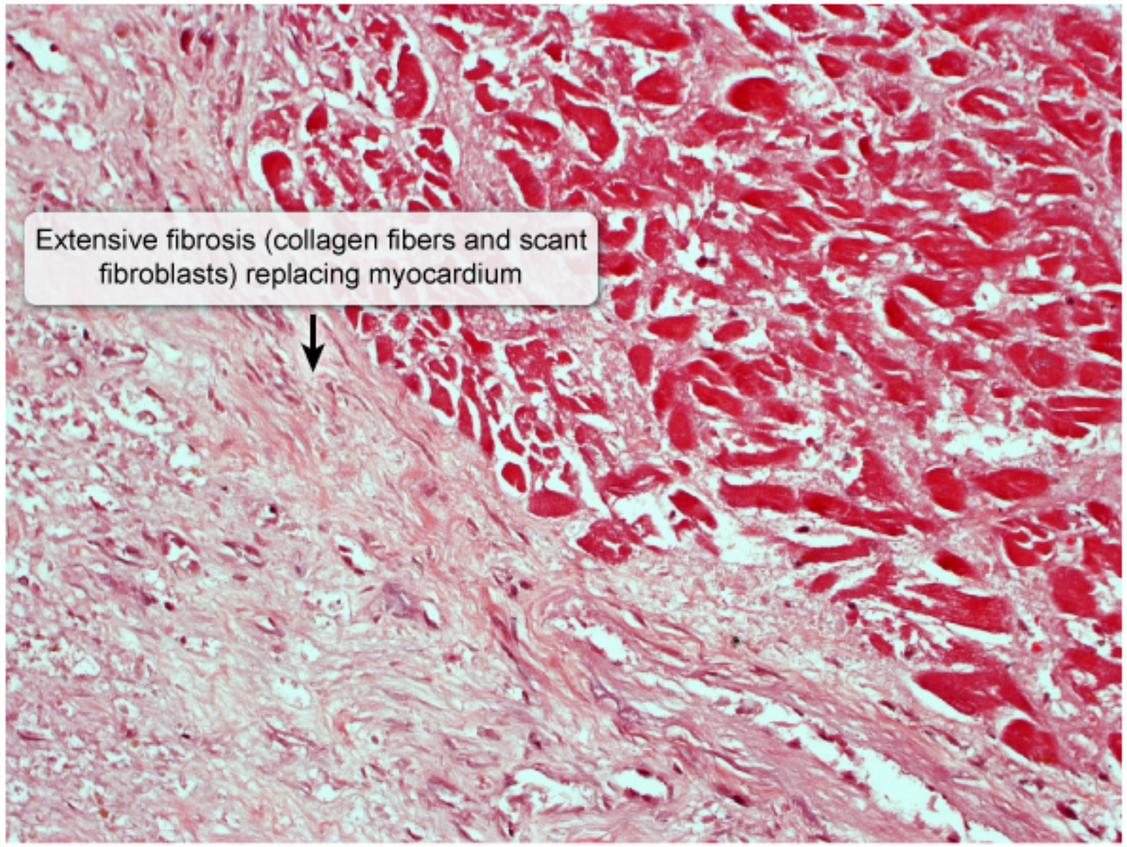

©UWorld

This patient's autopsy shows a large area of **fibrosis** replacing myocardium, consistent with scar tissue from a resolved **myocardial infarction** (MI). Myocardial tissue damage due to ischemia initiates a series of changes that are analogous to cutaneous wound healing:

- Inflammation: Hours to days post-MI, neutrophils and macrophages remove necrotic tissue and release cytokines and growth factors that

©UWorld

This patient's autopsy shows a large area of **fibrosis** replacing myocardium, consistent with scar tissue from a resolved **myocardial infarction** (MI). Myocardial tissue damage due to ischemia initiates a series of changes that are analogous to cutaneous wound healing:

- Inflammation: Hours to days post-MI, neutrophils and macrophages remove necrotic tissue and release cytokines and growth factors that initiate tissue proliferation.
- Proliferation: Days to weeks post-MI, **transforming growth factor-beta (TGF-β)** and other anti-inflammatory cytokines downregulate the inflammatory response and stimulate **fibroblast** migration and proliferation, causing extensive type I and III collagen deposition.
- Remodeling: Weeks to months post-MI, TGF-β also stimulates production of matrix metalloproteinases (MMPs) that facilitate collagen remodeling (ie, fiber rearrangement) and crosslinking to form dense **scar tissue**.

Because cardiac myocytes are terminally differentiated and do not proliferate to a significant degree in response to injury, areas of extensive myocardial fibrosis do not regain the electrical properties of normal myocardium. Therefore, patients with large scars from previous MIs are at increased risk of **sudden death** due to arrhythmia.

(Choice A) Endothelium-derived relaxing factor (ie, nitric oxide), causes vasodilation via stimulation of vascular smooth muscle relaxation. Although local synthesis of nitric oxide is increased post-MI, it contributes to reperfusion rather than fibrosis at the site of injury.

(Choice B) Interferon-beta (IFN-β) is released by a variety of cells, including macrophages, and functions as an anti-inflammatory cytokine that reduces the formation of fibrotic tissue.

(Choices C and E) Interleukin-8 and tumor necrosis factor-alpha (TNF-α) are proinflammatory cytokines that stimulate the recruitment and activation of other immune cells (eg, neutrophils). However, neither directly promotes fibrosis in a healing wound.

Educational objective:
After myocardial infarction, transforming growth factor-beta (TGF-β) reduces inflammation and promotes tissue remodeling due to fibroblast proliferation and collagen deposition, resulting in fibrosis in the area damaged by ischemia. Abnormal myocardium at the scar border can predispose patients to sudden death as a result of arrhythmia.

Pathology Cardiovascular System Myocardial infarction

- Inflammation: Hours to days post-MI, neutrophils and macrophages remove necrotic tissue and release cytokines and growth factors that initiate tissue proliferation.
- Proliferation: Days to weeks post-MI, **transforming growth factor-beta (TGF-β)** and other anti-inflammatory cytokines downregulate the inflammatory response and stimulate **fibroblast** migration and proliferation, causing extensive type I and III collagen deposition.
- Remodeling: Weeks to months post-MI, TGF-β also stimulates production of matrix metalloproteinases (MMPs) that facilitate collagen remodeling (ie, fiber rearrangement) and crosslinking to form dense **scar tissue**.

Because cardiac myocytes are terminally differentiated and do not proliferate to a significant degree in response to injury, areas of extensive myocardial fibrosis do not regain the electrical properties of normal myocardium. Therefore, patients with large scars from previous MIs are at increased risk of **sudden death** due to arrhythmia.

(Choice A) Endothelium-derived relaxing factor (ie, nitric oxide), causes vasodilation via stimulation of vascular smooth muscle relaxation. Although local synthesis of nitric oxide is increased post-MI, it contributes to reperfusion rather than fibrosis at the site of injury.

(Choice B) Interferon-beta (IFN-β) is released by a variety of cells, including macrophages, and functions as an anti-inflammatory cytokine that reduces the formation of fibrotic tissue.

(Choices C and E) Interleukin-8 and tumor necrosis factor-alpha (TNF-α) are proinflammatory cytokines that stimulate the recruitment and activation of other immune cells (eg, neutrophils). However, neither directly promotes fibrosis in a healing wound.

Educational objective:
After myocardial infarction, transforming growth factor-beta (TGF-β) reduces inflammation and promotes tissue remodeling due to fibroblast proliferation and collagen deposition, resulting in fibrosis in the area damaged by ischemia. Abnormal myocardium at the scar border can predispose patients to sudden death as a result of arrhythmia.

Pathology	Cardiovascular System	Myocardial infarction
Subject	System	Topic

Copyright © UWorld. All rights reserved.

Exhibit Display

Time after myocardial infarction	Predominant light microscopic changes
0-4 hours	• No visible change
4-12 hours	• Wavy fibers with narrow, elongated myocytes
12-24 hours	• Myocyte hypereosinophilia with pyknotic (shrunken) nuclei
1-3 days	• Coagulation necrosis (loss of nuclei & striations) • Prominent neutrophilic infiltrate
3-7 days	• Disintegration of dead neutrophils & myofibers • Macrophage infiltration at border areas
7-10 days	• Robust phagocytosis of dead cells by macrophages • Beginning formation of granulation tissue at margins
10-14 days	• Well-developed granulation tissue with neovascularization
2 weeks-2 months	• Progressive collagen deposition & scar formation

Add To Flash Card

This patient's autopsy sho
(MI). Myocardial tissue da

- Inflammation: Hour
initiate tissue prolife
- Proliferation: Days
inflammatory respor
- Remodeling: Week
remodeling (ie, fiber

Because cardiac myocyte
myocardial fibrosis do not
increased risk of **sudden**

(Choice A) Endothelium-
Although local synthesis c

(Choice B) Interferon-bet
reduces the formation of fi

(Choices C and E) Interleukin-8 and tumor necrosis factor-alpha (TNF-α) are proinflammatory cytokines that stimulate the recruitment and activation of other immune cells (eg, neutrophils). However, neither directly promotes fibrosis in a healing wound.

1
2
3
4
5
6
7
8
9
10
11
12
13
14
15
16
17
18
19
20
21
22
23
24
25
26
27
28
29

A 66-year-old man comes to the office for a routine visit. He has a history of hypertension and osteoarthritis. The patient has smoked a pack of cigarettes daily for 40 years and occasionally drinks 1 or 2 glasses of wine but does not use illicit drugs. Blood pressure is 142/82 mm Hg and pulse is 80/min. Cardiopulmonary examination is normal. There is a pulsating, central abdominal mass on physical examination. Which of the following pathologic conditions is the most likely underlying cause of this patient's abnormal findings?

A. Chronic transmural inflammation
B. Cystic medial necrosis
C. Focal intimal tear
D. Malignant endothelial proliferation
E. Microbial infection of aortic wall
F. Vasa vasorum endarteritis

Submit

A 66-year-old man comes to the office for a routine visit. He has a history of hypertension and osteoarthritis. The patient has smoked a pack of cigarettes daily for 40 years and occasionally drinks 1 or 2 glasses of wine but does not use illicit drugs. Blood pressure is 142/82 mm Hg and pulse is 80/min. Cardiopulmonary examination is normal. There is a pulsating, central abdominal mass on physical examination. Which of the following pathologic conditions is the most likely underlying cause of this patient's abnormal findings?

- ✓ A. Chronic transmural inflammation (22%)
- B. Cystic medial necrosis (29%)
- C. Focal intimal tear (28%)
- D. Malignant endothelial proliferation (4%)
- E. Microbial infection of aortic wall (1%)
- F. Vasa vasorum endarteritis (13%)

Omitted
Correct answer
A

22%
Answered correctly

02 secs
Time Spent

03/18/2020
Last Updated

Explanation

This patient's pulsating, central abdominal mass most likely represents an **abdominal aortic aneurysm** (AAA), which is a focal dilation of the abdominal aorta that typically occurs **below** the renal arteries.

AAA is associated with several risk factors (eg, age >60, smoking, hypertension, male sex, family history) that lead to oxidative stress, vascular smooth muscle apoptosis, and **chronic transmural inflammation** of the aorta. Inflammatory cells (particularly macrophages) release matrix metalloproteinases and elastases that degrade extracellular matrix components (eg, elastin, collagen), leading to weakening and **progressive**

1
2
3
4
5
6
7
8
9
10
11
12
13
14
15
16
17
18
19
20
21
22
23
24
25
26
27
28
29

This patient's pulsating, central abdominal mass most likely represents an **abdominal aortic aneurysm** (AAA), which is a focal dilation of the abdominal aorta that typically occurs **below** the renal arteries.

AAA is associated with several risk factors (eg, age >60, smoking, hypertension, male sex, family history) that lead to oxidative stress, vascular smooth muscle apoptosis, and **chronic transmural inflammation** of the aorta. Inflammatory cells (particularly macrophages) release matrix metalloproteinases and elastases that degrade extracellular matrix components (eg, elastin, collagen), leading to weakening and **progressive expansion** of the aortic wall. Furthermore, ischemia of the tunica media may play a role as the infrarenal abdominal aorta has a tenuous vasa vasorum, and atherosclerotic thickening of the intimal layer increases the diffusion distance for oxygen.

(Choice B) Cystic medial necrosis is characterized by loss of smooth muscle, collagen, and elastic tissue with formation of cystic mucoid spaces in the aortic media. Patients with Marfan syndrome develop cystic medial degeneration of the aortic root at a young age, predisposing them to ascending aortic aneurysm and dissection.

(Choice C) An intimal tear in the aortic wall is the primary event involved in the pathophysiology of aortic dissection. Patients typically present with tearing chest pain that radiates to the back. Proximal dissections involving the ascending aorta can cause unequal blood pressure in the arms, aortic valve regurgitation (eg, diastolic decrescendo murmur at the right sternal border), and cardiac tamponade.

(Choice D) Malignant endothelial proliferation is characteristic of angiosarcoma, a neoplasm that arises from blood or lymphatic vessels in the subcutaneous tissue and most frequently affects the scalp and face.

(Choice E) Microbial infection (usually bacterial) can cause localized dilation of an artery due to destruction of the vessel wall. Trauma, bacteremic seeding, or septic emboli (mycotic aneurysm) can cause infected aneurysms, which typically present with painful, pulsatile masses and systemic signs such as fever and malaise.

(Choice F) Vasa vasorum endarteritis ("endarteritis obliterans") in the thoracic aorta is thought to be the mechanism by which syphilis causes thoracic aortic aneurysm.

Educational objective:
Abdominal aortic aneurysm is associated with risk factors (eg, age >60, smoking, hypertension, male sex, family history) that lead to chronic transmural inflammation and extracellular matrix degradation within the wall of the aorta. This leads to weakening and progressive expansion of the aortic wall, resulting in aneurysm formation, typically below the renal arteries.

(Choice B) Cystic medial necrosis is characterized by loss of smooth muscle, collagen, and elastic tissue with formation of cystic mucoid spaces in the aortic media. Patients with Marfan syndrome develop cystic medial degeneration of the aortic root at a young age, predisposing them to ascending aortic aneurysm and dissection.

(Choice C) An intimal tear in the aortic wall is the primary event involved in the pathophysiology of aortic dissection. Patients typically present with tearing chest pain that radiates to the back. Proximal dissections involving the ascending aorta can cause unequal blood pressure in the arms, aortic valve regurgitation (eg, diastolic decrescendo murmur at the right sternal border), and cardiac tamponade.

(Choice D) Malignant endothelial proliferation is characteristic of angiosarcoma, a neoplasm that arises from blood or lymphatic vessels in the subcutaneous tissue and most frequently affects the scalp and face.

(Choice E) Microbial infection (usually bacterial) can cause localized dilation of an artery due to destruction of the vessel wall. Trauma, bacteremic seeding, or septic emboli (mycotic aneurysm) can cause infected aneurysms, which typically present with painful, pulsatile masses and systemic signs such as fever and malaise.

(Choice F) Vasa vasorum endarteritis ("endarteritis obliterans") in the thoracic aorta is thought to be the mechanism by which syphilis causes thoracic aortic aneurysm.

Educational objective:
Abdominal aortic aneurysm is associated with risk factors (eg, age >60, smoking, hypertension, male sex, family history) that lead to chronic transmural inflammation and extracellular matrix degradation within the wall of the aorta. This leads to weakening and progressive expansion of the aortic wall, resulting in aneurysm formation, typically below the renal arteries.

References

- Understanding the pathogenesis of abdominal aortic aneurysms.

Pathology	Cardiovascular System	Aortic aneurysm
Subject	System	Topic

Copyright © UWorld. All rights reserved.

A 56-year-old man is admitted to a tertiary care center after being involved in a high-speed motor vehicle accident. The patient was thrown from his vehicle and suffered severe head trauma along with multiple fractures involving his ribs and extremities. Despite aggressive treatment, he dies the following day from massive cerebral edema and brainstem herniation. Autopsy shows the following heart findings:

Left atrium: enlarged
Left ventricular myocardial mass: increased
Left ventricular wall thickness: increased

The structural changes observed in this patient's heart are most likely associated with which of the following conditions?

- A. Atrial septal defect
- B. Long-standing hypertension
- C. Mitral insufficiency
- D. Mitral stenosis
- E. Normal aging
- F. Recent myocardial infarction
- G. Wolff-Parkinson-White syndrome

Submit

A 56-year-old man is admitted to a tertiary care center after being involved in a high-speed motor vehicle accident. The patient was thrown from his vehicle and suffered severe head trauma along with multiple fractures involving his ribs and extremities. Despite aggressive treatment, he dies the following day from massive cerebral edema and brainstem herniation. Autopsy shows the following heart findings:

Left atrium: enlarged
Left ventricular myocardial mass: increased
Left ventricular wall thickness: increased

The structural changes observed in this patient's heart are most likely associated with which of the following conditions?

- A. Atrial septal defect (1%)
- ✓ B. Long-standing hypertension (65%)
- C. Mitral insufficiency (22%)
- D. Mitral stenosis (6%)
- E. Normal aging (2%)
- F. Recent myocardial infarction (0%)
- G. Wolff-Parkinson-White syndrome (0%)

Omitted
Correct answer
B

65%
Answered correctly

02 secs
Time Spent

04/12/2020
Last Updated

Explanation

1
2
3
4
5
6
7
8
9
10
11
12
13
14
15
16
17
18
19
20
21
22
23
24
25
26
27
28
29

Concentric & eccentric left ventricular hypertrophy

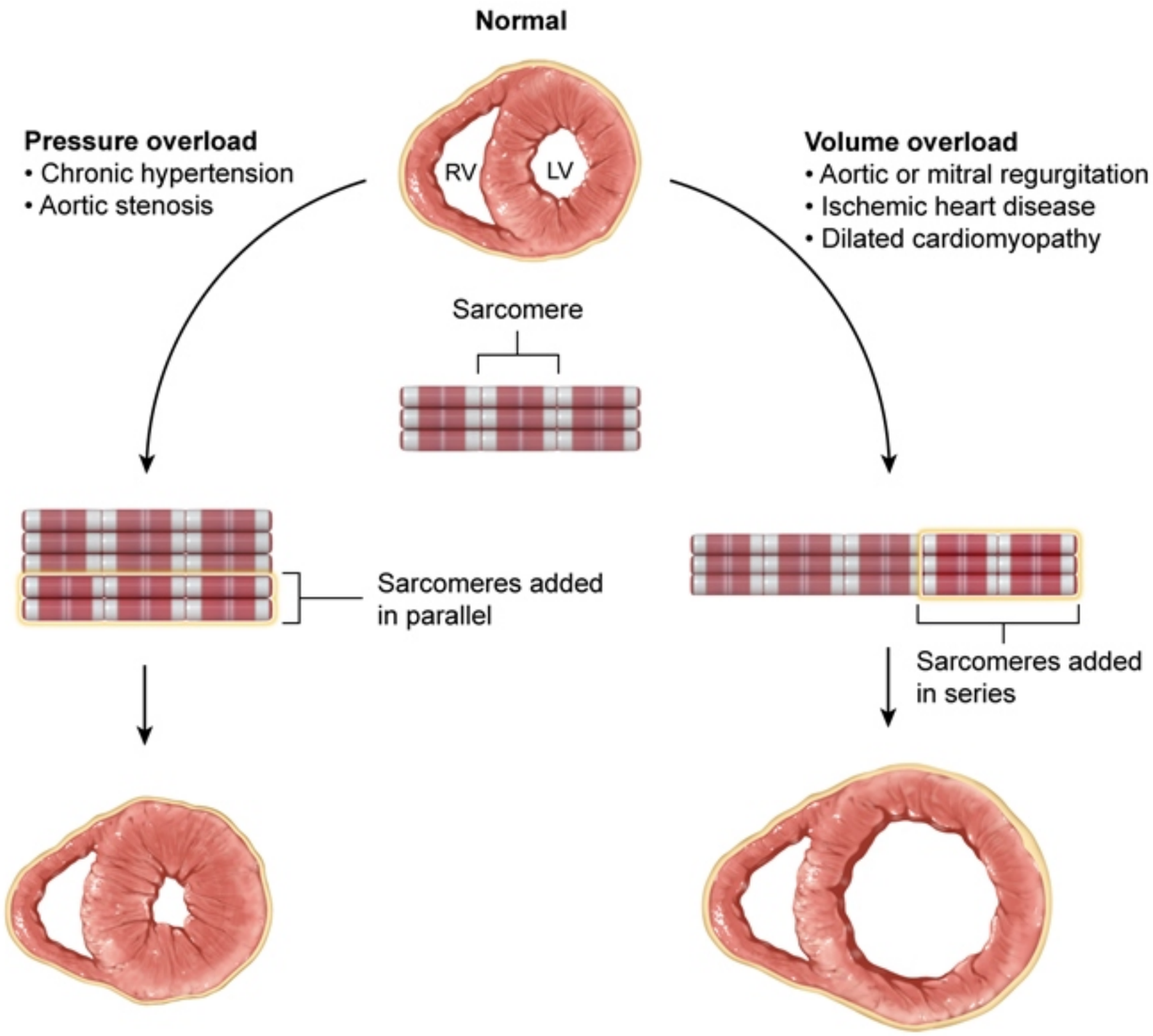

1
2
3
4
5
6
7
8
9
10
11
12
13
14
15
16
17
18
19
20
21
22
23
24
25
26
27
28
29

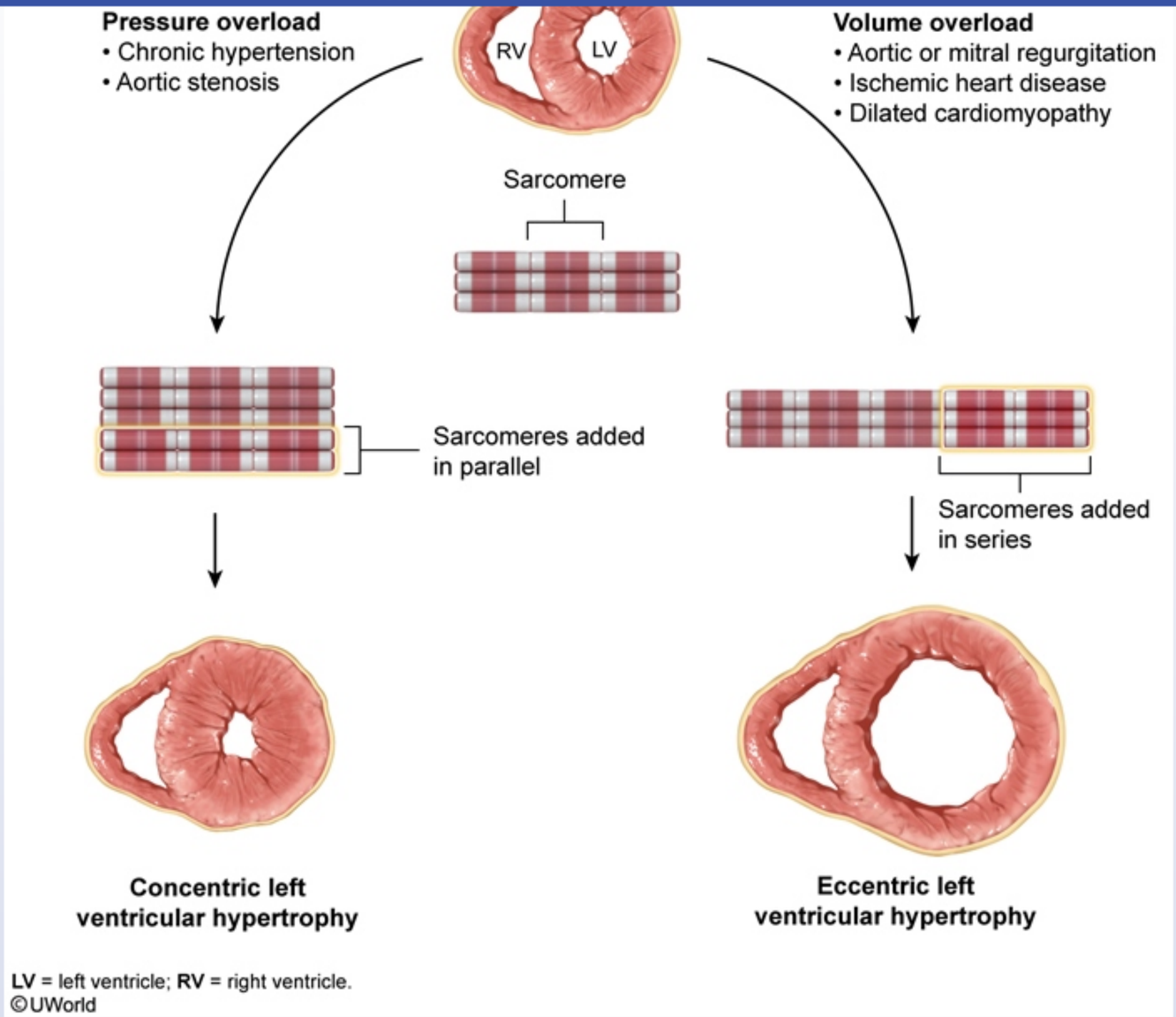

The autopsy findings of this patient's left ventricle (LV) are consistent with **concentric hypertrophy** most likely due to chronic hypertension.

1
2
3
4
5
6
7
8
9
10
11
12
13
14
15
16
17
18
19
20
21
22
23
24
25
26
27
28
29

Exhibit Display

Concentric & eccentric left ventricular hypertrophy

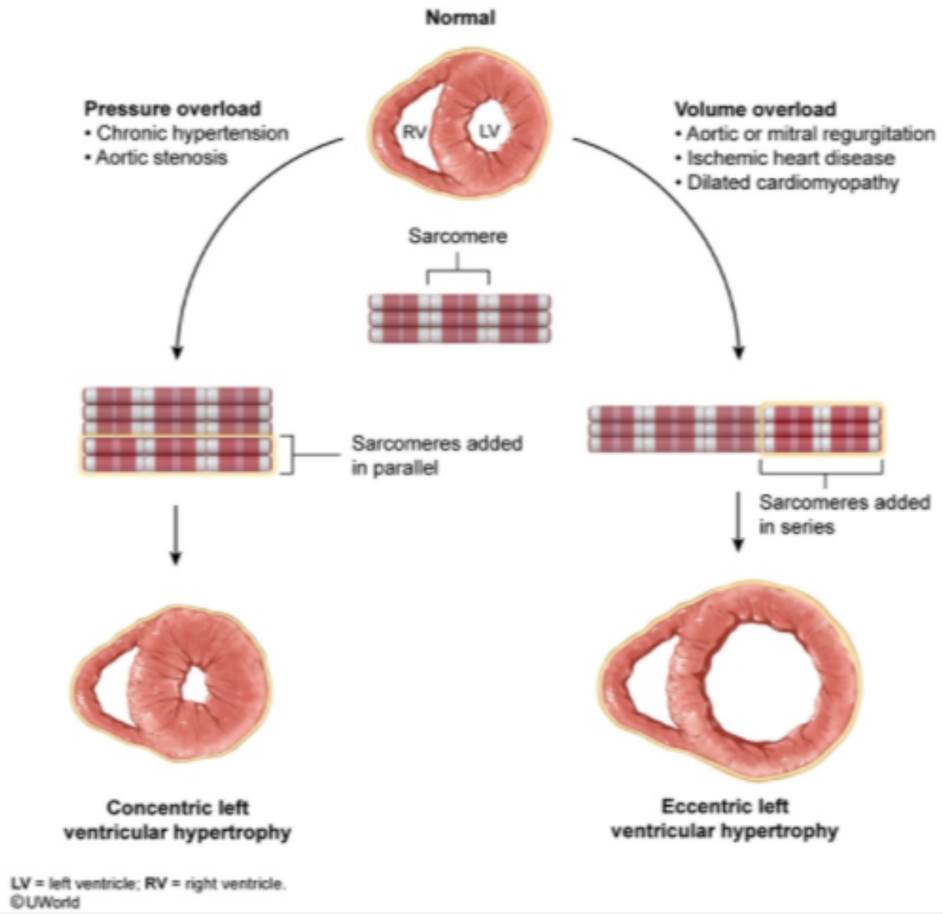

Zoom In | Zoom Out | Reset | Add To New Card | Existing Card

LV = left ventricle; RV = right ventricle.
©UWorld

The autopsy findings of this patient's left ventricle (LV) are consistent with **concentric hypertrophy** most likely due to chronic hypertension.

LV hypertrophy is generally defined as an increase in the left ventricular mass due to **increased wall thickness** (concentric) or cavity size (eccentric). Concentric hypertrophy is characterized by **uniform** thickening of the ventricular wall with the outer dimensions of the ventricle remaining almost unchanged, resulting in a narrowed ventricular cavity size. It is due to chronic elevation of ventricular pressures during systole, which is usually caused by **long-standing hypertension** or aortic stenosis (**increased LV afterload**). Patients may develop diastolic dysfunction with left atrial enlargement and congestive heart failure due to impaired ventricular compliance and filling.

(Choice A) An atrial septal defect causes a shunting of blood flow from the left to right atrium. This typically results in volume overload of the right ventricle, producing right atrial enlargement and eccentric (dilated) right ventricular hypertrophy.

(Choice C) Mitral insufficiency causes LV volume overload as regurgitant flow through the mitral valve during systole increases the amount of blood returning to the LV during diastole. The net structural consequence of mitral insufficiency is enlargement of the LV cavity and eccentric hypertrophy.

(Choice D) Mitral stenosis leads to left atrial enlargement due to elevated pressure in the left atrium. The LV cavity is typically small/normal in size with normal wall thickness due to restriction of blood flow across the mitral valve.

(Choice E) Aging is associated with a decrease in LV chamber size, predominantly through shortening of the apex-to-base dimension accompanied by a leftward bowing of the lower interventricular (sigmoid) septum. The aortic valve may also become calcified, resulting in aortic stenosis; however, structural cardiac changes due to aging are generally not prominent before age 65.

(Choice F) The ventricular remodeling that occurs after an acute myocardial infarction involves expansion, thinning, and fibrous healing of the infarcted zone of myocardium. Regional dysfunction of the infarcted myocardium causes volume overload for the remaining viable myocardium. The net result is usually eccentric hypertrophy, with enlargement of the LV cavity.

(Choice G) Patients with Wolff-Parkinson-White syndrome have an accessory pathway that bypasses the atrioventricular node and directly connects the atria and ventricles. This results in ventricular preexcitation and the development of tachyarrhythmias. The LV usually appears grossly normal.

Educational objective:
Concentric hypertrophy is characterized by uniform thickening of the ventricular wall and narrowing of the ventricular cavity due to increased

(Choice C) Mitral insufficiency causes LV volume overload as regurgitant flow through the mitral valve during systole increases the amount of blood returning to the LV during diastole. The net structural consequence of mitral insufficiency is enlargement of the LV cavity and eccentric hypertrophy.

(Choice D) Mitral stenosis leads to left atrial enlargement due to elevated pressure in the left atrium. The LV cavity is typically small/normal in size with normal wall thickness due to restriction of blood flow across the mitral valve.

(Choice E) Aging is associated with a decrease in LV chamber size, predominantly through shortening of the apex-to-base dimension accompanied by a leftward bowing of the lower interventricular (sigmoid) septum. The aortic valve may also become calcified, resulting in aortic stenosis; however, structural cardiac changes due to aging are generally not prominent before age 65.

(Choice F) The ventricular remodeling that occurs after an acute myocardial infarction involves expansion, thinning, and fibrous healing of the infarcted zone of myocardium. Regional dysfunction of the infarcted myocardium causes volume overload for the remaining viable myocardium. The net result is usually eccentric hypertrophy, with enlargement of the LV cavity.

(Choice G) Patients with Wolff-Parkinson-White syndrome have an accessory pathway that bypasses the atrioventricular node and directly connects the atria and ventricles. This results in ventricular preexcitation and the development of tachyarrhythmias. The LV usually appears grossly normal.

Educational objective:
Concentric hypertrophy is characterized by uniform thickening of the ventricular wall and narrowing of the ventricular cavity due to increased afterload (eg, chronic hypertension, aortic stenosis). Eccentric hypertrophy is characterized by reduced ventricular wall thickness with an associated increase in chamber size due to volume overload.

References

- The progression of hypertensive heart disease.

Pathology	Cardiovascular System	Primary hypertension
Subject	System	Topic

Copyright © UWorld. All rights reserved.

A 37-year-old man is found unresponsive under a tree during a thunderstorm. He is not breathing when paramedics arrive on the scene. On examination, his pupils are fixed and dilated. Several cutaneous erythematous marks in a fern-leaf pattern are seen on his lower extremities. Second-degree burns are present on both arms. Cardiopulmonary resuscitation is started; however, the patient does not respond and is pronounced dead on arrival at the hospital. Which of the following is most likely to be the primary cause of his death?

- A. Cardiac arrhythmia
- B. Extensive deep-tissue burns
- C. Intracranial hemorrhage
- D. Myocardial contusion
- E. Pulmonary barotrauma

Submit

A 37-year-old man is found unresponsive under a tree during a thunderstorm. He is not breathing when paramedics arrive on the scene. On examination, his pupils are fixed and dilated. Several cutaneous erythematous marks in a fern-leaf pattern are seen on his lower extremities. Second-degree burns are present on both arms. Cardiopulmonary resuscitation is started; however, the patient does not respond and is pronounced dead on arrival at the hospital. Which of the following is most likely to be the primary cause of his death?

- ✓ A. Cardiac arrhythmia (83%)
- B. Extensive deep-tissue burns (5%)
- C. Intracranial hemorrhage (6%)
- D. Myocardial contusion (2%)
- E. Pulmonary barotrauma (1%)

Omitted
Correct answer
A

83%
Answered correctly

03 secs
Time Spent

03/01/2020
Last Updated

Explanation

Lightning-related complications	
Organ system	**Complications**
Cardiac	Cardiac arrest, arrhythmias

1
2
3
4
5
6
7
8
9
10
11
12
13
14
15
16
17
18
19
20
21
22
23
24
25
26
27
28
29

Lightning-related complications	
Organ system	**Complications**
Cardiac	Cardiac arrest, arrhythmias
Neurologic	Peripheral nerve damage, seizures, confusion, respiratory arrest, autonomic dysfunction
Dermatologic	Lichtenberg figures (pathognomonic of lightning strike), burns
Musculoskeletal	Rhabdomyolysis, bone fractures, compartment syndrome
Other	Cataracts (late sequelae), ruptured tympanic membranes, curling ulcers

©UWorld

The finding of an unconscious person on wet ground or under trees during a thunderstorm suggests a lightning injury. This patient's Lichtenberg figures (erythematous cutaneous marks in a fern-leaf pattern) and second-degree burns confirm the suspicion. Although lightning injuries are rare, they are associated with a 25% fatality rate, and more than 70% of survivors have long-lasting complications. Two-thirds of lightning-related deaths occur within the first hour following injury; the most common causes are fatal arrhythmias and respiratory failure. A comprehensive and thorough physical examination should always be performed on lightning strike victims as injury patterns are widely variable and skin findings can significantly underestimate the extent of internal injury.

(Choice B) Superficial burns are common in lightning injury. In contrast, deep-tissue burns are relatively rare due to the short duration of

©UWorld

The finding of an unconscious person on wet ground or under trees during a thunderstorm suggests a lightning injury. This patient's Lichtenberg figures (erythematous cutaneous marks in a fern-leaf pattern) and second-degree burns confirm the suspicion. Although lightning injuries are rare, they are associated with a 25% fatality rate, and more than 70% of survivors have long-lasting complications. Two-thirds of lightning-related deaths occur within the first hour following injury; the most common causes are fatal arrhythmias and respiratory failure. A comprehensive and thorough physical examination should always be performed on lightning strike victims as injury patterns are widely variable and skin findings can significantly underestimate the extent of internal injury.

(Choice B) Superficial burns are common in lightning injury. In contrast, deep-tissue burns are relatively rare due to the short duration of electrical contact and the "flashover effect," the tendency of lightning to travel over the skin surface and discharge to the ground. This effect is responsible for the formation of Lichtenberg figures.

(Choice C) Intracranial hemorrhage only rarely occurs following lightning injury. Lightning strikes can damage the autonomic system and cause fixed and dilated or asymmetric pupils. These signs may not accurately reflect the extent of neurologic injury and should not be a reason to stop resuscitation.

(Choices D and E) Lightning induces rapid heating of the surrounding air, generating shock waves that can travel through the body and cause mechanical trauma. As a result, patients should be thoroughly assessed for skeletal fractures. Myocardial contusion and pulmonary barotrauma occur less frequently and would be extremely rare causes of death.

Educational objective:
Although lightning injuries are rare, they are associated with a 25% fatality rate. Two-thirds of lightning-related deaths occur within the first hour after injury, with fatal arrhythmias and respiratory failure as the most common causes. Patients with minor cutaneous involvement may still have major internal injury after lightning strikes and high-voltage electrical contact.

References

- Emergent care of lightning and electrical injuries.

Pathology	Cardiovascular System	Electrical injury
Subject	System	Topic

1
2
3
4
5
6
7
8
9
10
11
12
13
14
15
16
17
18
19
20
21
22
23
24
25
26
27
28
29

A 53-year-old woman comes to the office due to progressive distension and tightness in her right lower extremity for the past year. She has had no shortness of breath, fever, or skin rash. The patient was diagnosed with melanoma of the right thigh approximately 2 years ago and underwent surgical resection. Two of her inguinal lymph nodes tested positive for metastasis, and she subsequently underwent inguinal lymphadenectomy and received adjuvant therapy. Recent imaging revealed no evidence of recurrent malignancy. The patient's medical history also includes hypertension and hyperlipidemia. Vital signs are within normal limits. Physical examination shows clear lungs and normal heart sounds without murmurs or gallops. No jugular venous distension is present. The right lower extremity is significantly larger in diameter than the left. Edema is present up to the thigh, with mild skin indentation after application of pressure. The skin overlying the involved area is thickened and dry. Laboratory testing, including complete blood count, serum metabolic panel, and urinalysis, is within normal limits. Treatment of this patient's symptoms should include which of the following strategies?

A. Blockade of estrogen receptors

B. Compression to increase lymphatic flow

C. Dissolution of intravascular thrombus

D. Inhibition of vascular endothelial growth factor

E. Reduction of intravascular volume

Submit

A 53-year-old woman comes to the office due to progressive distension and tightness in her right lower extremity for the past year. She has had no shortness of breath, fever, or skin rash. The patient was diagnosed with melanoma of the right thigh approximately 2 years ago and underwent surgical resection. Two of her inguinal lymph nodes tested positive for metastasis, and she subsequently underwent inguinal lymphadenectomy and received adjuvant therapy. Recent imaging revealed no evidence of recurrent malignancy. The patient's medical history also includes hypertension and hyperlipidemia. Vital signs are within normal limits. Physical examination shows clear lungs and normal heart sounds without murmurs or gallops. No jugular venous distension is present. The right lower extremity is significantly larger in diameter than the left. Edema is present up to the thigh, with mild skin indentation after application of pressure. The skin overlying the involved area is thickened and dry. Laboratory testing, including complete blood count, serum metabolic panel, and urinalysis, is within normal limits. Treatment of this patient's symptoms should include which of the following strategies?

- A. Blockade of estrogen receptors (0%)
- ✓ B. Compression to increase lymphatic flow (73%)
- C. Dissolution of intravascular thrombus (11%)
- D. Inhibition of vascular endothelial growth factor (5%)
- E. Reduction of intravascular volume (7%)

Omitted
Correct answer
B

73%
Answered correctly

02 secs
Time Spent

04/15/2020
Last Updated

Explanation

Chronic lymphedema

Chronic lymphedema	
Etiology	• Physical disruption of lymphatic drainage ◦ Lymphadenectomy, radiation ◦ Malignant obstruction ◦ Chronic inflammation (eg, recurrent cellulitis) ◦ Parasitic infection (eg, filariasis) ◦ Congenital (eg, Turner syndrome)
Clinical presentation	• Swelling, heaviness, discomfort • Early: soft skin, pitting edema • Late: firm, dry & thickened skin; nonpitting edema
Treatment	• Weight loss, limb elevation • Compression bandages & physiotherapy • Diuretics contraindicated

This patient with chronic swelling and thickened skin of the right leg most likely has **chronic lymphedema**. Lymphedema can be congenital, but it most commonly results from an acquired **disruption of lymphatic drainage** that allows for accumulation of lymphatic fluid in the interstitial tissue. Malignancy and its treatment (eg, radiation, **lymphadenectomy**) are frequent underlying causes; other causes include chronic inflammation (eg, recurrent cellulitis, connective tissue disease) and parasitic infection (ie, filariasis due to *Wuchereria bancrofti*). Obesity is often a strong contributing factor.

Lymphedema usually presents with swelling, heaviness, and discomfort in one or more extremities. In early disease, the edema is pitting and the skin remains soft. However, over time there is progressive **deposition of subcutaneous collagen** and adipose tissue, which leads to firm, dry, and **thickened skin** and **nonpitting edema**. Treatment is difficult and typically involves conservative management to increase lymphatic drainage via **compression bandages** or physiotherapy (ie, manual lymphatic drainage).

(Choice A) Selective estrogen receptor modulators (eg, tamoxifen) block estrogen receptors in breast tissue and can be useful in treating breast cancer. Breast cancer may present with upper extremity lymphedema, but lower extremity lymphedema would be extremely unusual.

This patient with chronic swelling and thickened skin of the right leg most likely has **chronic lymphedema**. Lymphedema can be congenital, but it most commonly results from an acquired **disruption of lymphatic drainage** that allows for accumulation of lymphatic fluid in the interstitial tissue. Malignancy and its treatment (eg, radiation, **lymphadenectomy**) are frequent underlying causes; other causes include chronic inflammation (eg, recurrent cellulitis, connective tissue disease) and parasitic infection (ie, filariasis due to *Wuchereria bancrofti*). Obesity is often a strong contributing factor.

Lymphedema usually presents with swelling, heaviness, and discomfort in one or more extremities. In early disease, the edema is pitting and the skin remains soft. However, over time there is progressive **deposition of subcutaneous collagen** and adipose tissue, which leads to firm, dry, and **thickened skin** and **nonpitting edema**. Treatment is difficult and typically involves conservative management to increase lymphatic drainage via **compression bandages** or physiotherapy (ie, manual lymphatic drainage).

(Choice A) Selective estrogen receptor modulators (eg, tamoxifen) block estrogen receptors in breast tissue and can be useful in treating breast cancer. Breast cancer may present with upper extremity lymphedema, but lower extremity lymphedema would be extremely unusual.

(Choice C) Anticoagulants (eg, heparin) facilitate dissolution of acute deep venous thrombosis (DVT); however, acute DVT is less likely without active malignancy and would not explain this patient's year-long duration of symptoms.

(Choice D) Inhibition of vascular endothelial growth factor is useful in the treatment of lymphangiosarcoma, which is a rare complication of lymphedema. Lymphangiosarcoma typically presents as purple maculopapular skin lesions, which are not present in this patient.

(Choice E) Diuretics reduce intravascular volume and are useful in treating lower extremity edema that results from elevated venous hydrostatic pressure in true volume overloaded states (eg, heart failure, cirrhosis). However, they are ineffective and contraindicated for lymphedema because lymphedematous fluid cannot be easily mobilized from the interstitial space into the vasculature. When used for lymphedema, diuretics are likely to cause intravascular volume depletion and consequent acute kidney injury.

Educational objective:
Chronic lymphedema is most commonly caused by an acquired disruption of lymphatic drainage (eg, due to malignancy or lymphadenectomy), and typically presents with swelling and thickened skin in one or more extremities. Treatment is usually conservative and involves compression bandages and physiotherapy; diuretics are ineffective and contraindicated.

References

Lymphedema usually presents with swelling, heaviness, and discomfort in one or more extremities. In early disease, the edema is pitting and the skin remains soft. However, over time there is progressive **deposition of subcutaneous collagen** and adipose tissue, which leads to firm, dry, and **thickened skin** and **nonpitting edema**. Treatment is difficult and typically involves conservative management to increase lymphatic drainage via **compression bandages** or physiotherapy (ie, manual lymphatic drainage).

(Choice A) Selective estrogen receptor modulators (eg, tamoxifen) block estrogen receptors in breast tissue and can be useful in treating breast cancer. Breast cancer may present with upper extremity lymphedema, but lower extremity lymphedema would be extremely unusual.

(Choice C) Anticoagulants (eg, heparin) facilitate dissolution of acute deep venous thrombosis (DVT); however, acute DVT is less likely without active malignancy and would not explain this patient's year-long duration of symptoms.

(Choice D) Inhibition of vascular endothelial growth factor is useful in the treatment of lymphangiosarcoma, which is a rare complication of lymphedema. Lymphangiosarcoma typically presents as purple maculopapular skin lesions, which are not present in this patient.

(Choice E) Diuretics reduce intravascular volume and are useful in treating lower extremity edema that results from elevated venous hydrostatic pressure in true volume overloaded states (eg, heart failure, cirrhosis). However, they are ineffective and contraindicated for lymphedema because lymphedematous fluid cannot be easily mobilized from the interstitial space into the vasculature. When used for lymphedema, diuretics are likely to cause intravascular volume depletion and consequent acute kidney injury.

Educational objective:
Chronic lymphedema is most commonly caused by an acquired disruption of lymphatic drainage (eg, due to malignancy or lymphadenectomy), and typically presents with swelling and thickened skin in one or more extremities. Treatment is usually conservative and involves compression bandages and physiotherapy; diuretics are ineffective and contraindicated.

References

- Lymphedema: a primer on the identification and management of a chronic condition in oncologic treatment.

Pathology	Cardiovascular System	Lymphedema
Subject	System	Topic

Copyright © UWorld. All rights reserved.

Lymphedema usually presents with swelling, heaviness, and discomfort in one or more extremities. In early disease, the edema is pitting and the skin remains soft. However, over time there is progressive **deposition of subcutaneous collagen** and adipose tissue, which leads to firm, dry, and **thickened skin** and **nonpitting edema**. Treatment is difficult and typically involves conservative management to increase lymphatic drainage via **compression bandages** or physiotherapy (ie, manual lymphatic drainage).

(Choice A) Selective estrogen receptor modulators (eg, tamoxifen) block estrogen receptors in breast tissue and can be useful in treating breast cancer. Breast cancer may present with upper extremity lymphedema, but lower extremity lymphedema would be extremely unusual.

(Choice C) Anticoagulants (eg, heparin) facilitate dissolution of acute deep venous thrombosis (DVT); however, acute DVT is less likely without active malignancy and would not explain this patient's year-long duration of symptoms.

(Choice D) Inhibition of vascular endothelial growth factor is useful in the treatment of lymphangiosarcoma, which is a rare complication of lymphedema. Lymphangiosarcoma typically presents as purple maculopapular skin lesions, which are not present in this patient.

(Choice E) Diuretics reduce intravascular volume and are useful in treating lower extremity edema that results from elevated venous hydrostatic pressure in true volume overloaded states (eg, heart failure, cirrhosis). However, they are ineffective and contraindicated for lymphedema because lymphedematous fluid cannot be easily mobilized from the interstitial space into the vasculature. When used for lymphedema, diuretics are likely to cause intravascular volume depletion and consequent acute kidney injury.

Educational objective:
Chronic lymphedema is most commonly caused by an acquired disruption of lymphatic drainage (eg, due to malignancy or lymphadenectomy), and typically presents with swelling and thickened skin in one or more extremities. Treatment is usually conservative and involves compression bandages and physiotherapy; diuretics are ineffective and contraindicated.

References

- Lymphedema: a primer on the identification and management of a chronic condition in oncologic treatment.

Pathology	Cardiovascular System	Lymphedema
Subject	System	Topic

Copyright © UWorld. All rights reserved.

1
2
3
4
5
6
7
8
9
10
11
12
13
14
15
16
17
18
19
20
21
22
23
24
25
26
27
28
29

A 78-year-old female is brought to the ER because of altered mental status of recent onset and difficulty walking. She has a history of Parkinsonism and has had difficulty walking lately. She lives alone and has had a few falls recently. Her BP is 180/100 mm Hg and pulse is 68/min. Her CT scan of the head is shown below.

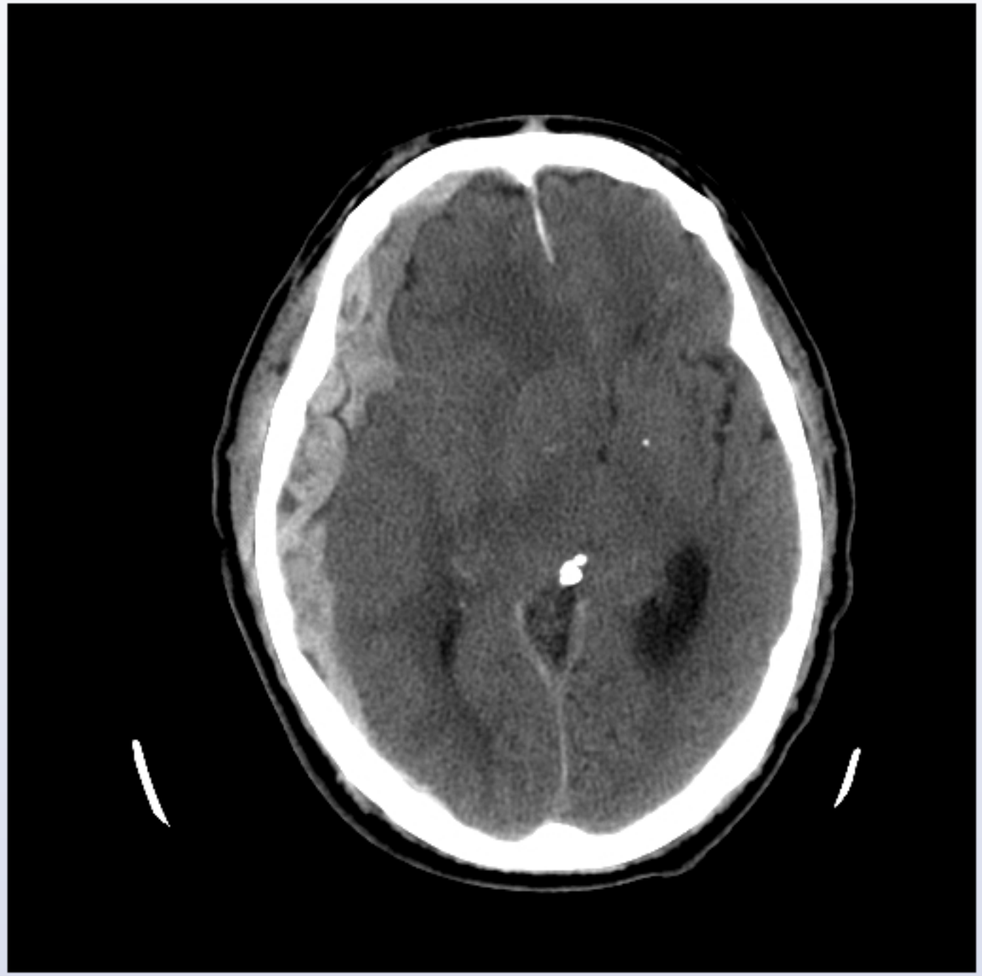

Which of the following is the most likely cause of her symptoms?

1
2
3
4
5
6
7
8
9
10
11
12
13
14
15
16
17
18
19
20
21
22
23
24
25
26
27
28
29

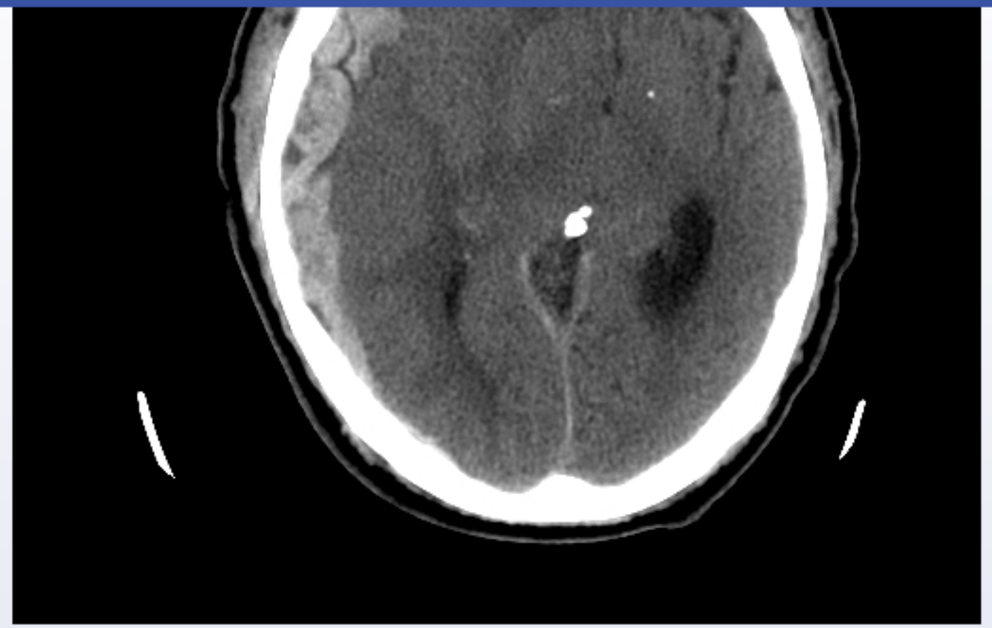

Which of the following is the most likely cause of her symptoms?

- A. Rupture of middle meningeal artery
- B. Rupture of cortical bridging veins
- C. Rupture of lateral striate arteries
- D. Rupture of berry aneurysm
- E. Rupture of posterior communicating artery

Submit

1
2
3
4
5
6
7
8
9
10
11
12
13
14
15
16
17
18
19
20
21
22
23
24
25
26
27
28
29

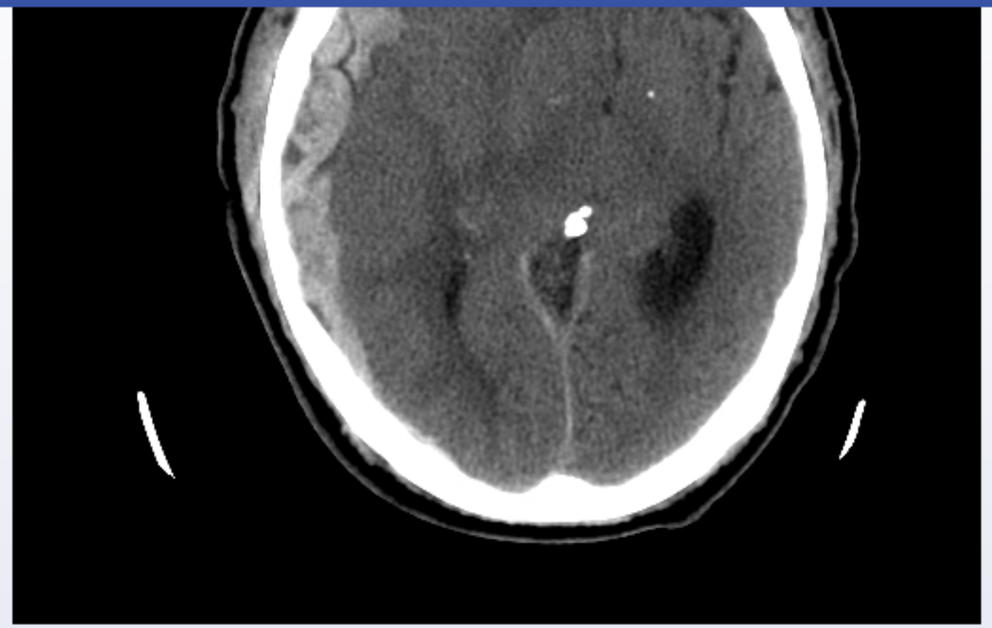

Which of the following is the most likely cause of her symptoms?

A. Rupture of middle meningeal artery (16%)

✓ B. Rupture of cortical bridging veins (76%)

C. Rupture of lateral striate arteries (2%)

D. Rupture of berry aneurysm (2%)

E. Rupture of posterior communicating artery (1%)

Omitted
Correct answer

76%
Answered correctly

08 secs
Time Spent

06/11/2020
Last Updated

1
2
3
4
5
6
7
8
9
10
11
12
13
14
15
16
17
18
19
20
21
22
23
24
25
26
27
28
29

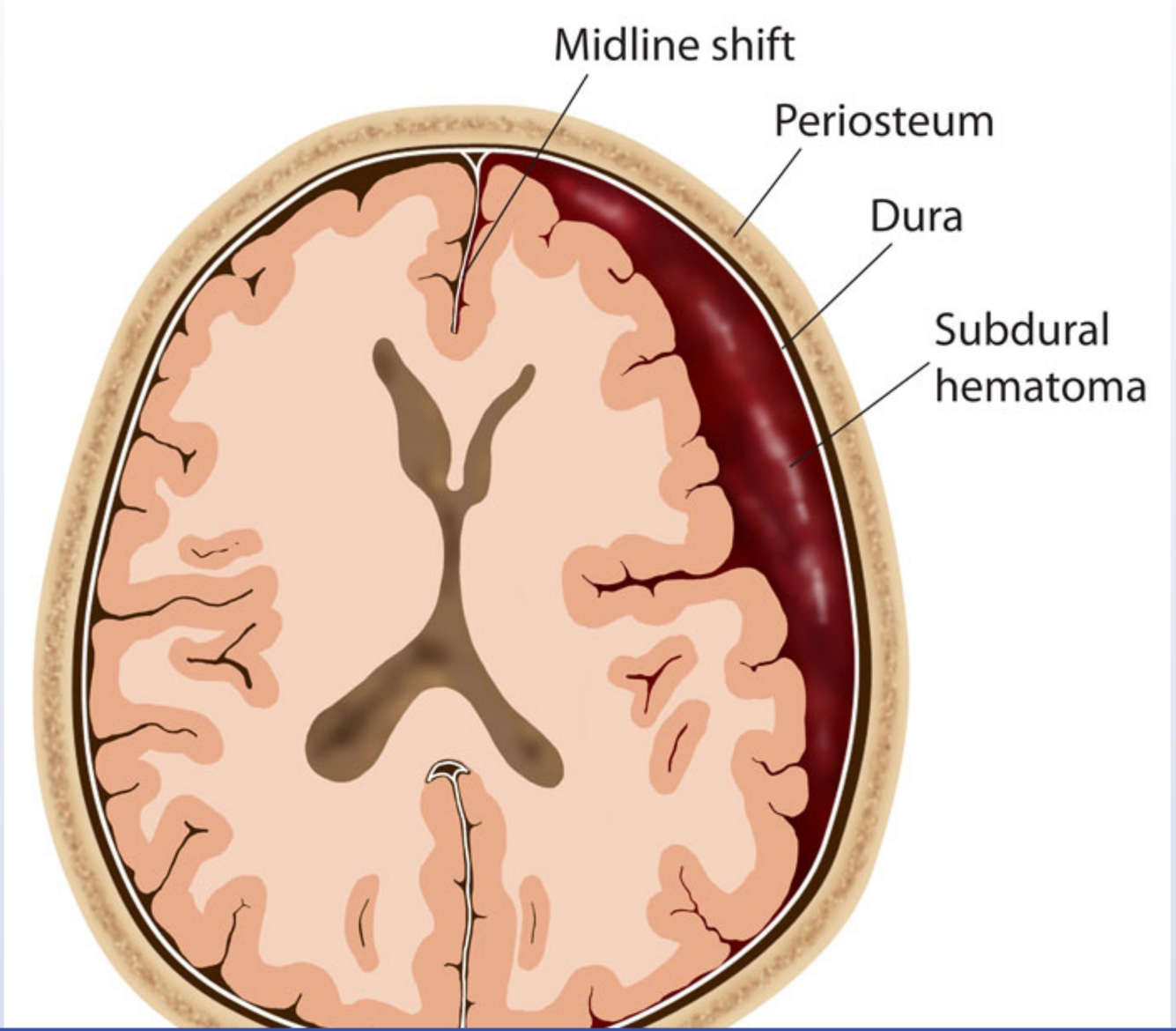

1
2
3
4
5
6
7
8
9
10
11
12
13
14
15
16
17
18
19
20
21
22
23
24
25
26
27
28
29

This patient has suffered a subdural hematoma, an accumulation of blood between the dura mater and arachnoid. The blood comes from the bridging cortical veins which carry blood from the cortex to the venous sinuses. They can rupture as a result of acceleration-deceleration injury. As the hematoma expands, it raises the intracranial pressure and compresses the brain. Venous bleeding is relatively slow, which explains the **gradual onset of symptoms** in subdural hematoma. Patients complain of gradually worsening headache and display a slow decline in mental function. On CT scan, subdural hematoma is seen as a **crescent-shaped** mass.

Subdural hematoma often occurs in elderly individuals after a minor trauma. This increased incidence is explained by age-related brain atrophy. As the distance from the skull to the brain surface increases, cortical bridging veins are under more tension and rupture more easily. In elderly patients, subdural bleeding is called a "great imitator" due to its subtle and variable presentation. It may present as gait abnormalities, seizures, somnolence, confusion and memory loss. These patients may go undiagnosed for weeks.

(Choice A) Rupture of the middle meningeal artery causes epidural hemorrhage. Its clinical presentation is characterized by a "lucid interval", followed by loss of consciousness. A biconvex hematoma is seen on CT scan.

(Choice C) The lateral striate arteries arise from the middle cerebral arteries. They are also called the penetrating branches. These vessels supply the internal capsule and the basal ganglia, and often rupture in hypertensive strokes.

(Choices D and E) The posterior communicating artery is the second most common site of rupture of berry aneurysms in the circle of Willis (anterior communicating artery is the most common site). This results in subarachnoid bleeding. It manifests with a severe headache that may be described as "the worst headache of my life". Fever and nuchal rigidity are commonly present.

Educational objective:
Subdural hematoma occurs due to the rupture of cortical bridging veins. In young patients, it results from a fall or motor vehicle accident, and manifests with gradual onset of headache and confusion. In elderly patients it may occur after a minor trauma and present with a variety of neurologic symptoms. You should know how to recognize this on CT scan.

Pathology	Cardiovascular System	Subdural hematoma
Subject	System	Topic

Copyright © UWorld. All rights reserved.

1
2
3
4
5
6
7
8
9
10
11
12
13
14
15
16
17
18
19
20
21
22
23
24
25
26
27
28
29

A 24-year-old man is evaluated after an episode of syncope. He was out jogging when he felt lightheaded and passed out, but he did not sustain any head injury. The patient has had 2 similar episodes of lightheadedness while jogging over the last year, but this was the first time he passed out. He considers himself in good health and has no other medical problems. The patient does not use tobacco, alcohol, or illicit drugs. His father died suddenly at age 30. On physical examination, he has a harsh systolic murmur. Transthoracic echocardiography shows asymmetric interventricular septal hypertrophy. The patient's symptoms are most likely explained by left ventricular outflow obstruction created by which of the following structures?

A. Aortic valve cusp and interventricular septum
B. Aortic valve cusp and papillary muscle
C. Aortic valve cusps
D. Ascending aorta and interventricular septum
E. Mitral valve leaflet and interventricular septum

Submit

1
2
3
4
5
6
7
8
9
10
11
12
13
14
15
16
17
18
19
20
21
22
23
24
25
26
27
28
29

A 24-year-old man is evaluated after an episode of syncope. He was out jogging when he felt lightheaded and passed out, but he did not sustain any head injury. The patient has had 2 similar episodes of lightheadedness while jogging over the last year, but this was the first time he passed out. He considers himself in good health and has no other medical problems. The patient does not use tobacco, alcohol, or illicit drugs. His father died suddenly at age 30. On physical examination, he has a harsh systolic murmur. Transthoracic echocardiography shows asymmetric interventricular septal hypertrophy. The patient's symptoms are most likely explained by left ventricular outflow obstruction created by which of the following structures?

A. Aortic valve cusp and interventricular septum (39%)

B. Aortic valve cusp and papillary muscle (3%)

C. Aortic valve cusps (6%)

D. Ascending aorta and interventricular septum (5%)

✓ E. Mitral valve leaflet and interventricular septum (43%)

Omitted
Correct answer
E

43%
Answered correctly

02 secs
Time Spent

03/31/2020
Last Updated

Explanation

1
2
3
4
5
6
7
8
9
10
11
12
13
14
15
16
17
18
19
20
21
22
23
24
25
26
27
28
29

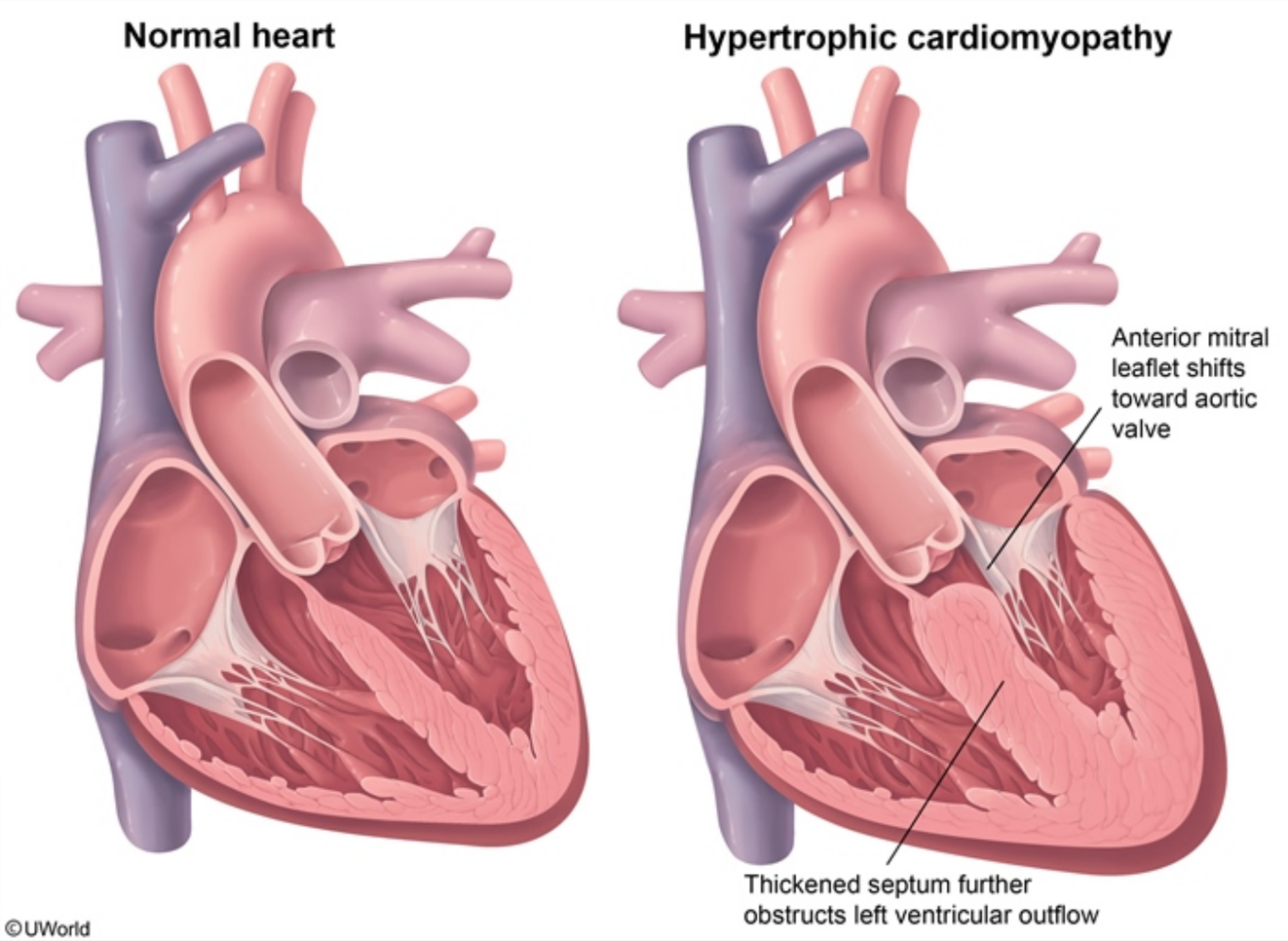

This patient's presentation suggests **hypertrophic cardiomyopathy** (HCM), an autosomal dominant disorder resulting from mutations in cardiac sarcomere proteins. HCM is characterized by asymmetric ventricular septal hypertrophy and variable, dynamic **left ventricular outflow tract (LVOT) obstruction**. Systolic anterior motion of the **mitral valve** toward the **interventricular septum** can cause eccentric mitral regurgitation and exacerbate LVOT obstruction.

This patient's presentation suggests **hypertrophic cardiomyopathy** (HCM), an autosomal dominant disorder resulting from mutations in cardiac sarcomere proteins. HCM is characterized by asymmetric ventricular septal hypertrophy and variable, dynamic **left ventricular outflow tract (LVOT) obstruction**. Systolic anterior motion of the **mitral valve** toward the **interventricular septum** can cause eccentric mitral regurgitation and exacerbate LVOT obstruction.

Many patients are asymptomatic and may be diagnosed with an abnormal ECG or murmur during routine evaluation. They can also present with exertional dyspnea, chest pain, fatigue, palpitations, dizziness, syncope, or sudden cardiac death (due to ventricular arrhythmias). Examination often reveals a harsh crescendo-decrescendo systolic murmur at the apex and left lower sternal border, which changes in intensity with physiologic maneuvers.

(Choices A, B, and D) It would be anatomically unlikely for an aortic cusp and the interventricular septum and/or papillary muscles to create LVOT obstruction. In a similar fashion, malposition of the ascending aorta in relation to the interventricular septum is not the mechanism of obstruction in patients with HCM.

(Choice C) Aortic stenosis (AS) can present with a systolic murmur and exertional syncope. Calcification of the congenital bicuspid aortic valve can cause AS, but symptoms usually occur later in life. Furthermore, AS is not usually associated with asymmetric septal hypertrophy.

Educational objective:
In patients with hypertrophic cardiomyopathy, dynamic left ventricular outflow tract obstruction is due to abnormal systolic anterior motion of the anterior leaflet of the mitral valve toward a hypertrophied interventricular septum.

References

- Hypertrophic cardiomyopathy is predominantly a disease of left ventricular outflow tract obstruction.

Pathology	Cardiovascular System	Hypertrophic cardiomyopathy
Subject	System	Topic

Copyright © UWorld. All rights reserved.

©UWorld

Thickened septum further obstructs left ventricular outflow

This patient's presentatior ac
sarcomere proteins. HCM
(LVOT) obstruction. Sys and
exacerbate LVOT obstruct

Many patients are asympt ith
exertional dyspnea, chest n
often reveals a harsh cres
physiologic maneuvers.

(Choices A, B, and D) It
LVOT obstruction. In a sir
obstruction in patients with

(Choice C) Aortic stenosi ve
can cause AS, but sympto

Educational objective:
In patients with hypertroph e
anterior leaflet of the mitra

References

- Hypertrophic cardiomy

Pathology — Subject
Cardiova — System

Exhibit Display

Effect of maneuvers on hypertrophic cardiomyopathy

	Physiologic effect	Left ventricular blood volume	Murmur intensity
Valsalva (strain phase)	↓ Preload	↓	↑
Abrupt standing			
Nitroglycerin administration			
Sustained hand grip	↑ Afterload	↑	↓
Squatting	↑ Afterload & preload		
Passive leg raise	↑ Preload		

Add To New Card | Existing Card

Copyright © UWorld. All rights reserved.

1
2
3
4
5
6
7
8
9
10
11
12
13
14
15
16
17
18
19
20
21
22
23
24
25
26
27
28
29

A 10-year-old immigrant from Eastern Europe is brought to the office due to exertional dyspnea and fatigability. The boy tires easily when walking and cannot keep up with his peers at the playground. According to his parents, he was diagnosed with a congenital heart disease in infancy, for which they refused treatment. They cannot recall the details of his diagnosis. The patient also has had occasional respiratory infections throughout childhood that have not required hospitalization. He takes a daily multivitamin and no medications. He has received only a few childhood vaccinations based on parental preference. The patient has no family history of heart disease. Physical examination shows toe cyanosis and clubbing but no finger abnormalities. All extremity pulses are full and equal. Which of the following is the most likely diagnosis?

A. Coarctation of the aorta
B. Patent ductus arteriosus
C. Primum-type atrial septal defect
D. Secundum-type atrial septal defect
E. Tetralogy of Fallot
F. Ventricular septal defect

Submit

A 10-year-old immigrant from Eastern Europe is brought to the office due to exertional dyspnea and fatigability. The boy tires easily when walking and cannot keep up with his peers at the playground. According to his parents, he was diagnosed with a congenital heart disease in infancy, for which they refused treatment. They cannot recall the details of his diagnosis. The patient also has had occasional respiratory infections throughout childhood that have not required hospitalization. He takes a daily multivitamin and no medications. He has received only a few childhood vaccinations based on parental preference. The patient has no family history of heart disease. Physical examination shows toe cyanosis and clubbing but no finger abnormalities. All extremity pulses are full and equal. Which of the following is the most likely diagnosis?

- A. Coarctation of the aorta (17%)
- ✓ B. Patent ductus arteriosus (31%)
- C. Primum-type atrial septal defect (2%)
- D. Secundum-type atrial septal defect (5%)
- E. Tetralogy of Fallot (20%)
- F. Ventricular septal defect (21%)

Omitted
Correct answer
B

31%
Answered correctly

02 secs
Time Spent

07/03/2020
Last Updated

Explanation

Patent ductus arteriosus

1
2
3
4
5
6
7
8
9
10
11
12
13
14
15
16
17
18
19
20
21
22
23
24
25
26
27
28
29

Patent ductus arteriosus

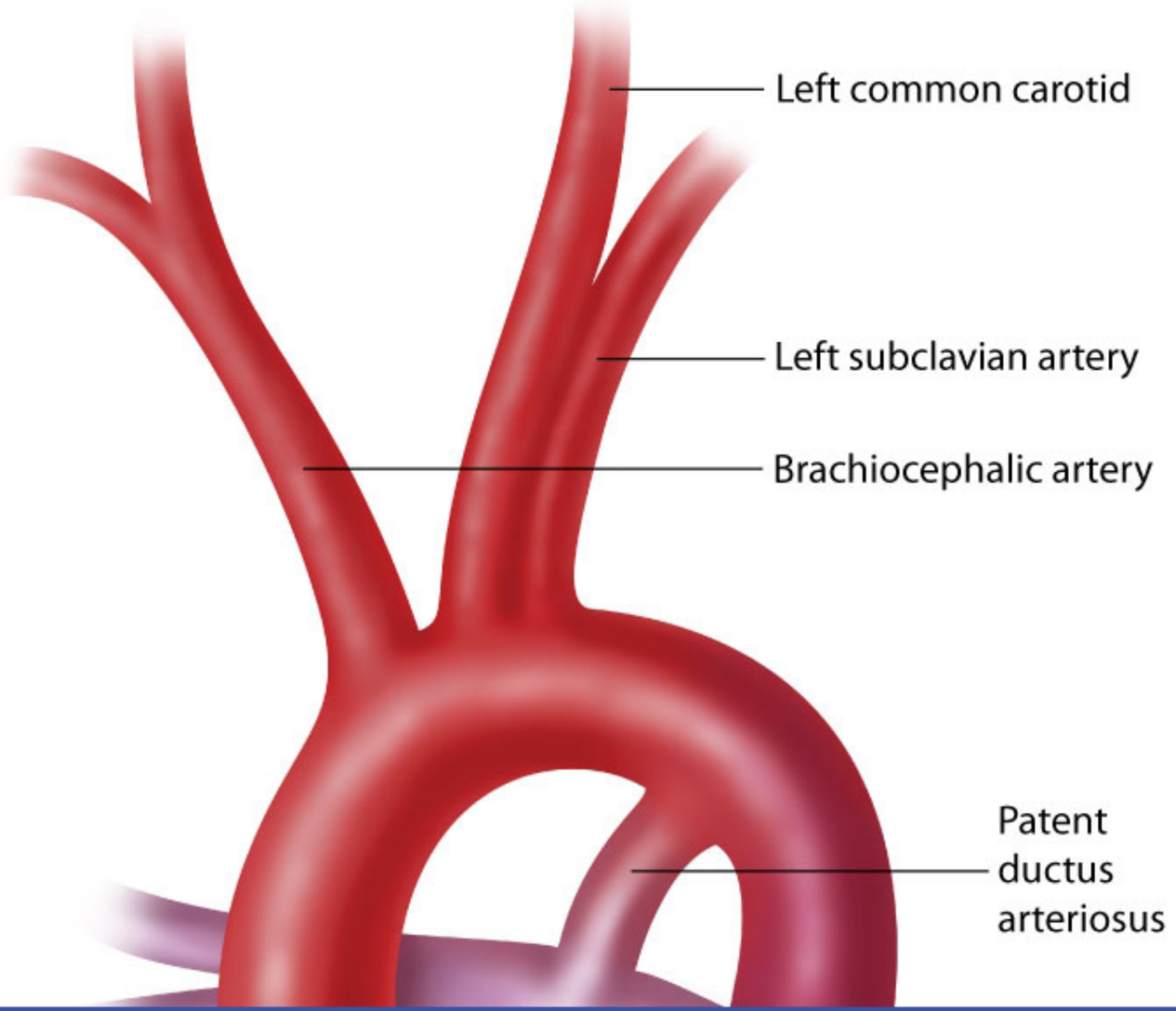

1
2
3
4
5
6
7
8
9
10
11
12
13
14
15
16
17
18
19
20
21
22
23
24
25
26
27
28
29

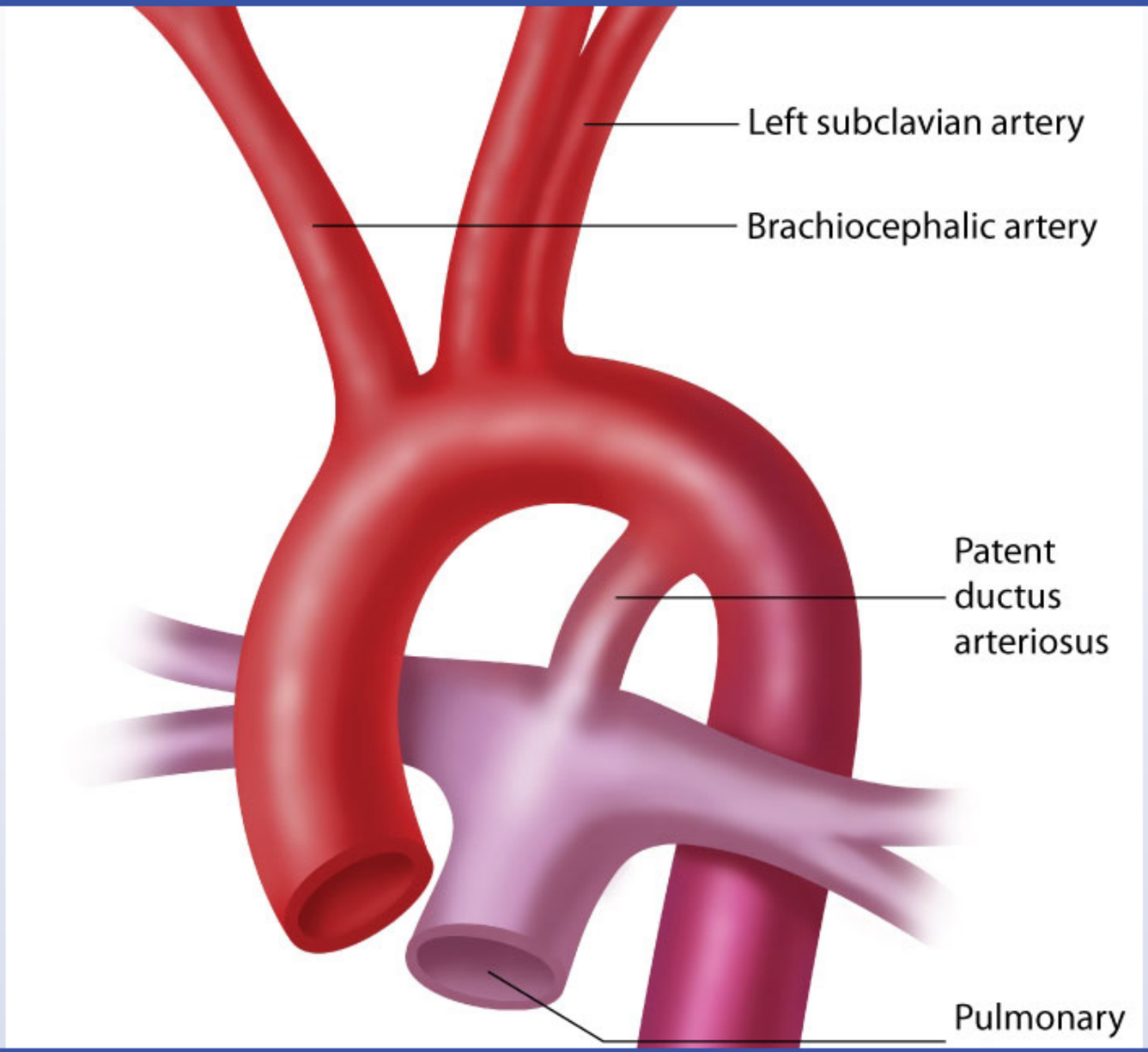

1
2
3
4
5
6
7
8
9
10
11
12
13
14
15
16
17
18
19
20
21
22
23
24
25
26
27
28
29

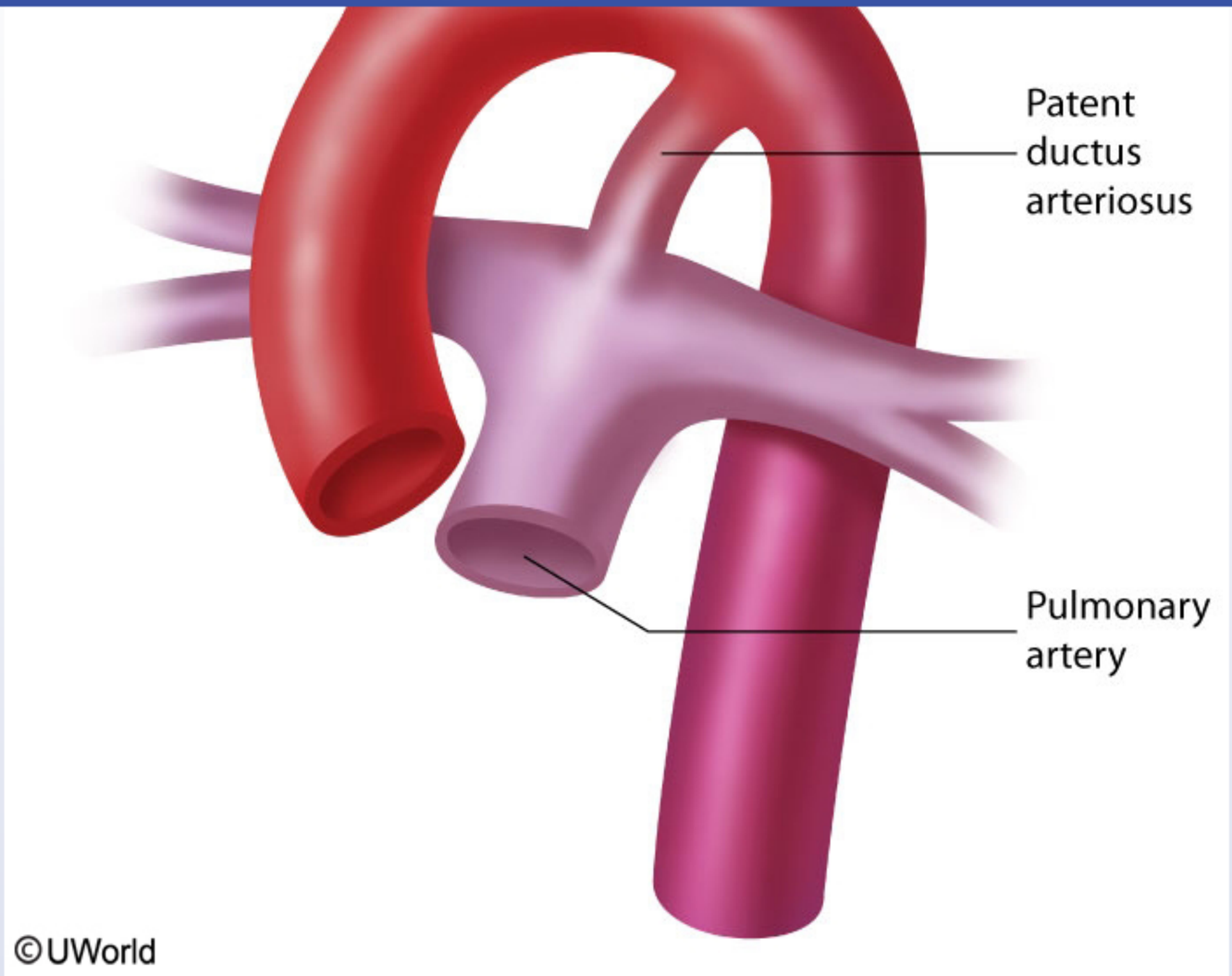

Patent ductus arteriosus (PDA) is a vascular connection between the main pulmonary artery and the aorta that normally obliterates after birth. Clinical features vary depending on the size. Small PDAs are characterized by a **continuous, machinelike murmur** (left-to-right shunting) with no significant symptoms. Large PDAs can present anytime during childhood with progressive pulmonary hypertension and reversal of the shunt to

Patent ductus arteriosus (PDA) is a vascular connection between the main pulmonary artery and the aorta that normally obliterates after birth. Clinical features vary depending on the size. Small PDAs are characterized by a **continuous, machinelike murmur** (left-to-right shunting) with no significant symptoms. Large PDAs can present anytime during childhood with progressive pulmonary hypertension and reversal of the shunt to right-to-left. The characteristic continuous murmur decreases as the pulmonary pressure rises and ultimately disappears. Typical consequences include **heart failure** (eg, shortness of breath, fatigability), and cyanosis **(Eisenmenger syndrome)**. The cyanosis and clubbing are most pronounced in the lower extremities **(differential cyanosis and clubbing)** because the PDA delivers unoxygenated blood distal to the left subclavian artery.

(Choice A) Coarctation of the aorta is most commonly located in the juxtaductal region just distal to the left subclavian artery. It typically presents in children and adults as a blood pressure discrepancy and pulse delay between the upper and lower extremities. In neonates, severe coarctation can present with heart failure, especially once the ductal tissue collapses. If the ductus arteriosus remains patent, deoxygenated blood can bypass the coarctation and cause differential cyanosis in infancy. However, infants with severe coarctation are unlikely to survive without surgical correction.

(Choices C, D, and F) Atrial and ventricular septal defects initially are accompanied by left-to-right intracardiac shunting and are therefore acyanotic at birth. Large septal defects are at risk for shunt reversal and Eisenmenger syndrome. However, the arterial oxygen desaturation and cyanosis affect the upper and lower body equally.

(Choice E) Tetralogy of Fallot is generally characterized by whole-body cyanosis at birth as the result of right-to-left shunting across the ventricular septal defect. The right-to-left shunt is intracardiac, and therefore cyanosis typically involves the whole body.

Educational objective:
Differential clubbing and cyanosis without blood pressure or pulse discrepancy are pathognomonic for a large patent ductus arteriosus complicated by Eisenmenger syndrome (reversal of shunt flow from left-to-right to right-to-left). Severe coarctation of the aorta can cause lower extremity cyanosis. Right-to-left shunting in patients with large septal defects and tetralogy of Fallot results in whole-body cyanosis.

References

- Differential clubbing and cyanosis: classic signs of patent ductus arteriosus with Eisenmenger syndrome.
- Differential clubbing and cyanosis: a pathognomonic finding in cardiology.
- Images in clinical medicine. Differential clubbing and cyanosis.

1
2
3
4
5
6
7
8
9
10
11
12
13
14
15
16
17
18
19
20
21
22
23
24
25
26
27
28
29

Patent ductus arteriosus (PDA) is a vascular connection between the main pulmonary artery and the aorta that normally obliterates after birth.

Exhibit Display

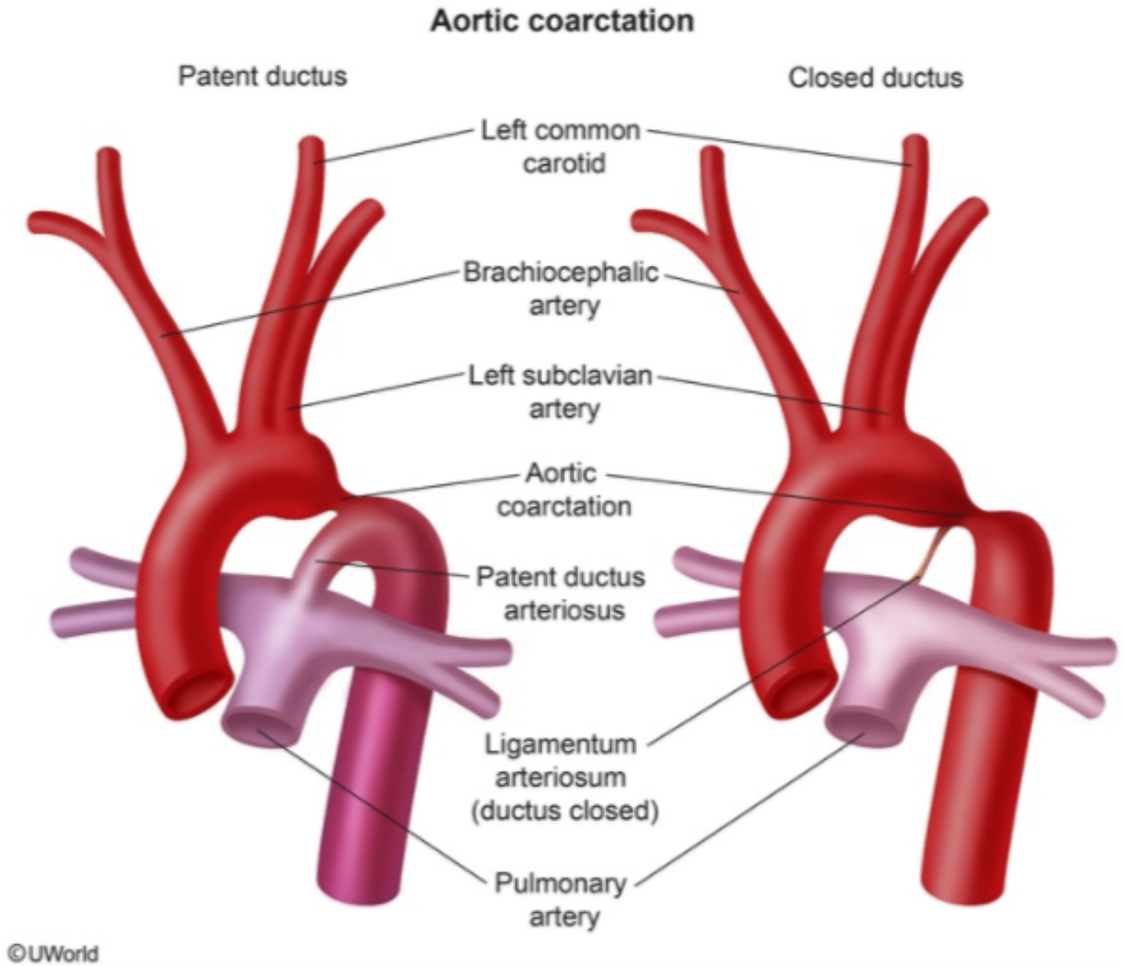

Zoom In | Zoom Out | Reset | Add To New Card | Existing Card

- Images in clinical medicine. Differential clubbing and cyanosis

1
2
3
4
5
6
7
8
9
10
11
12
13
14
15
16
17
18
19
20
21
22
23
24
25
26
27
28
29

Patent ductus arteriosus (PDA) is a vascular connection between the main pulmonary artery and the aorta that normally obliterates after birth.

Exhibit Display

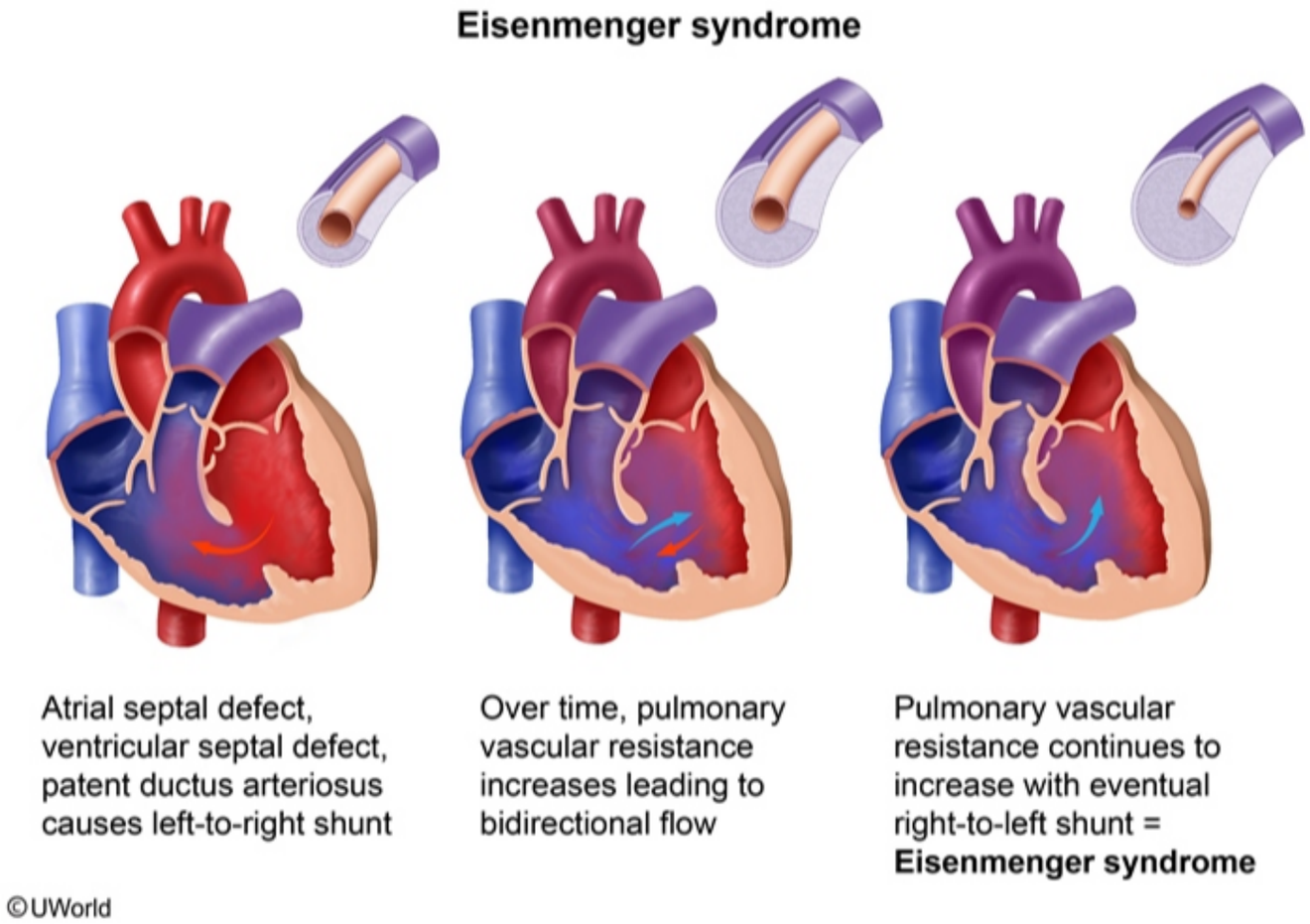

Zoom In | Zoom Out | Reset | Add To New Card | Existing Card

- Images in clinical medicine. Differential clubbing and cyanosis

1
2
3
4
5
6
7
8
9
10
11
12
13
14
15
16
17
18
19
20
21
22
23
24
25
26
27
28
29

Patent ductus arteriosus (PDA) is a vascular connection between the main pulmonary artery and the aorta that normally obliterates after birth.

Exhibit Display

Tetralogy of Fallot

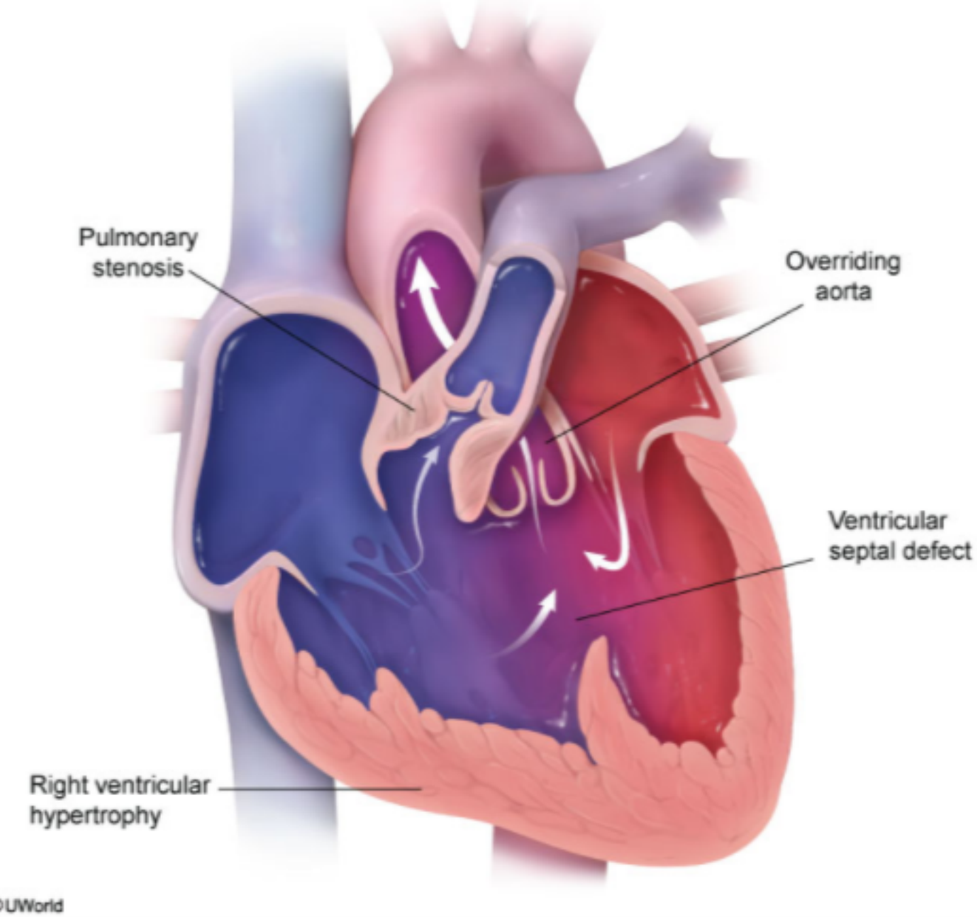

Zoom In | Zoom Out | Reset | Add To New Card | Existing Card

- Images in clinical medicine. Differential clubbing and cyanosis

1
2
3
4
5
6
7
8
9
10
11
12
13
14
15
16
17
18
19
20
21
22
23
24
25
26
27
28
29

A 69-year-old man comes to the clinic due to a squeezing pressure in his midline chest and neck that occurs when walking. He has a history of hypertension and type 2 diabetes mellitus. The patient is an ex-smoker with a 20-pack-year history. Coronary angiography shows extensive atherosclerosis and near-total occlusion of the left anterior descending artery. Further testing shows normal resting left ventricular ejection fraction with no regional wall motion abnormalities. The absence of myocardial necrosis and scarring despite vessel occlusion in this patient can be best explained by which of the following features of the occluding plaque?

- A. Active peripheral inflammation
- B. High calcium content
- C. Lipid-rich core
- D. Ostial location
- E. Slow growth rate
- F. Thin fibrous cap

Submit

1
2
3
4
5
6
7
8
9
10
11
12
13
14
15
16
17
18
19
20
21
22
23
24
25
26
27
28
29

A 69-year-old man comes to the clinic due to a squeezing pressure in his midline chest and neck that occurs when walking. He has a history of hypertension and type 2 diabetes mellitus. The patient is an ex-smoker with a 20-pack-year history. Coronary angiography shows extensive atherosclerosis and near-total occlusion of the left anterior descending artery. Further testing shows normal resting left ventricular ejection fraction with no regional wall motion abnormalities. The absence of myocardial necrosis and scarring despite vessel occlusion in this patient can be best explained by which of the following features of the occluding plaque?

- A. Active peripheral inflammation (2%)
- B. High calcium content (4%)
- C. Lipid-rich core (6%)
- D. Ostial location (7%)
- ✓ E. Slow growth rate (62%)
- F. Thin fibrous cap (16%)

Omitted
Correct answer
E

62%
Answered correctly

02 secs
Time Spent

04/25/2020
Last Updated

Explanation

1
2
3
4
5
6
7
8
9
10
11
12
13
14
15
16
17
18
19
20
21
22
23
24
25
26
27
28
29

Coronary collateral circulation

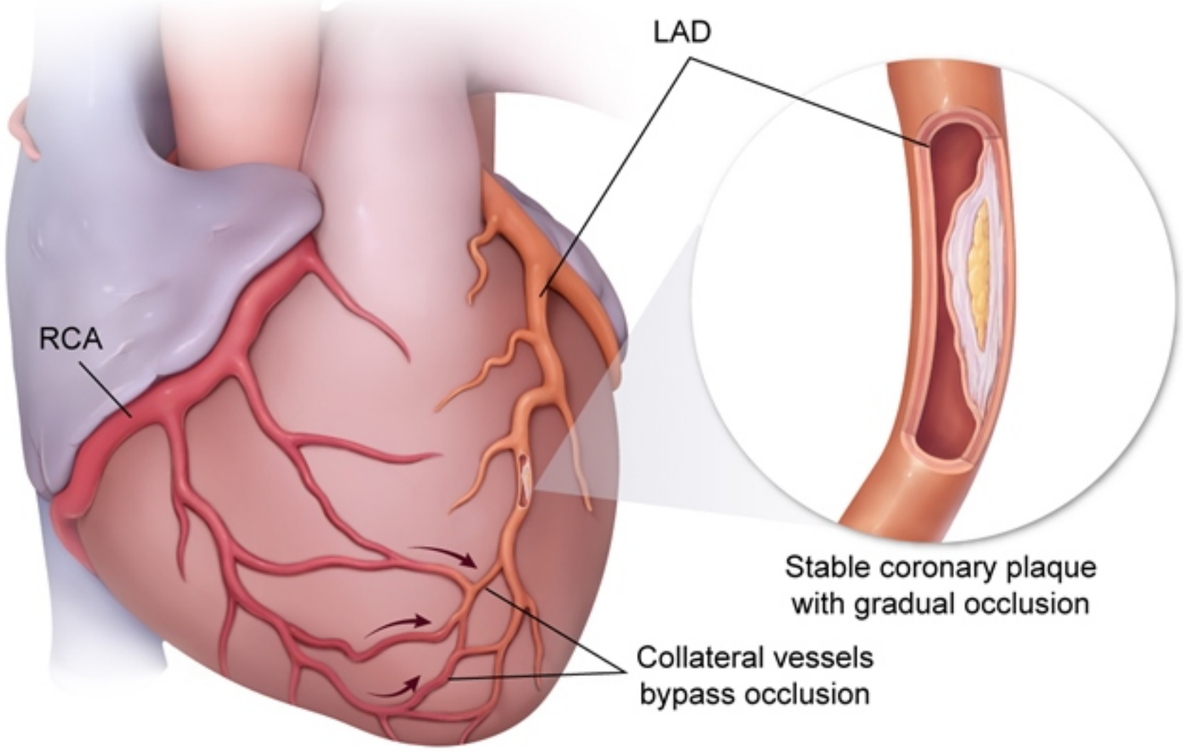

1
2
3
4
5
6
7
8
9
10
11
12
13
14
15
16
17
18
19
20
21
22
23
24
25
26
27
28
29

Exhibit Display

Coronary collateral circulation

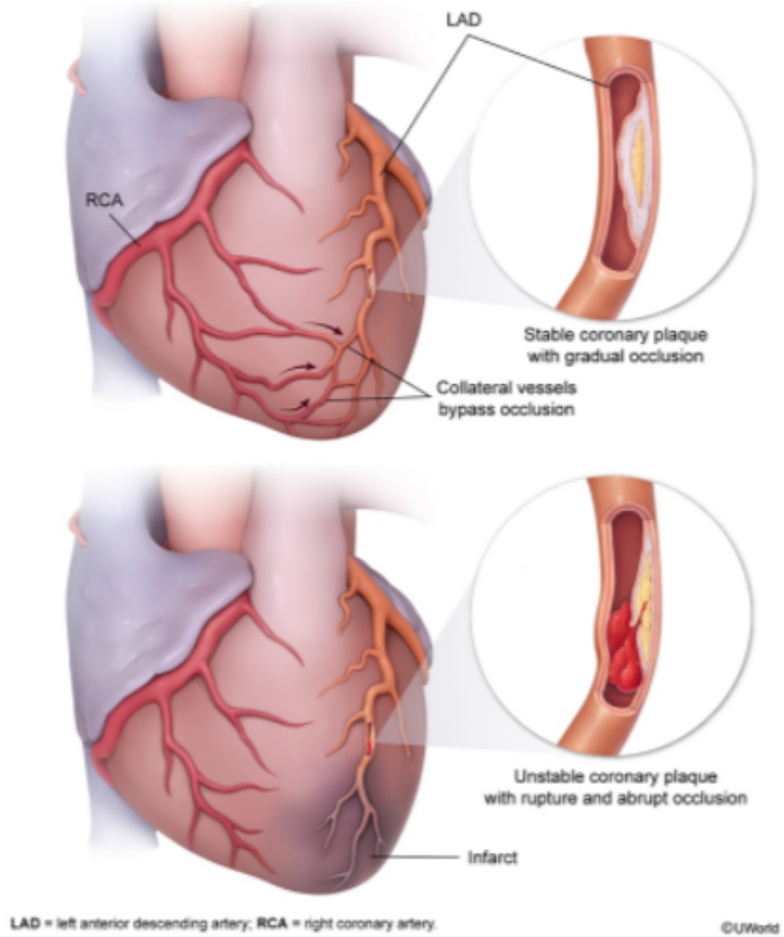

Zoom In | Zoom Out | Reset | Add To New Card | Existing Card

1 2 3 4 5 6 7 8 9 10 11 12 13 14 15 16 17 18 19 20 21 22 23 24 25 26 27 28 29

LAD = left anterior descending artery; RCA = right coronary artery.

©UWorld

In response to progressive reductions in blood flow caused by atherosclerotic coronary artery disease, **ischemic myocardium** may release growth factors (eg, vascular endothelial growth factor) to stimulate the formation and maturation of **collateral vessels**. In this patient, the **slow development** of a **stable atherosclerotic plaque** in the left anterior descending artery (LAD) likely allowed collateral vessels from the right coronary artery to supply the ischemic myocardium located distal to the LAD occlusion. Because there is low hydrostatic pressure distal to the LAD occlusion, a pressure gradient is created that facilitates blood flow through the small collateral vessels.

An **unstable atherosclerotic plaque** is less likely to allow the development of viable collateral vessels, as it is more likely to rupture before it becomes large enough to cause significant chronic ischemia; rupture leads to overlying thrombus and **abrupt arterial occlusion** with acute myocardial ischemia/**infarction** and cellular necrosis. The rapid development of ischemia allows insufficient time for collateral vessels to develop and mature.

(Choices A, C, and F) Atherosclerotic plaques with active inflammation (containing activated macrophages that secrete metalloproteinases and degrade collagen), high core concentration of lipids, and/or a thin fibrous cap are unstable and more likely to rupture. All of these properties are less likely in an atherosclerotic lesion that has grown to create near-total occlusion without rupturing.

(Choice B) The total coronary artery calcium content correlates with the total atherosclerotic plaque burden, and calcium scoring by cardiac CT scan is sometimes used to estimate the severity of coronary artery disease. However, the calcium content of an individual plaque does not correlate with its stability or likelihood of rupture.

(Choice D) Ostial atherosclerotic plaques (those located at a branch point of 2 arteries) are more likely to occlude blood flow to multiple areas of myocardium, thereby limiting the availability of nearby well-perfused arteries from which viable collateral vessels can develop.

Educational objective:
Gradually developing myocardial ischemia encourages the formation and maturation of collateral vessels and is most likely to occur in the setting of a slow-growing, stable atherosclerotic plaque. An unstable atherosclerotic plaque (eg, that with active inflammation, a lipid-rich core, and/or a thin fibrous cap) is more likely to rupture, resulting in the abrupt onset of ischemia/infarction that precludes the development of viable collateral vessels.

References

- Importance of angina for development of collateral circulation.

1
2
3
4
5
6
7
8
9
10
11
12
13
14
15
16
17
18
19
20
21
22
23
24
25
26
27
28
29

A 54-year-old man comes to the emergency department due to worsening shortness of breath for the last 3 days. His symptoms initially occurred with exertion but are now present at rest. The patient could not sleep last night because of a suffocating cough each time he tried to lie down. He considers himself generally healthy and states, "I've never had to see a doctor for any problems." Family history is remarkable for asthma and hypertension. Blood pressure is 162/86 mm Hg, pulse is 92/min, and respirations are 26/min. An x-ray of the chest is shown in the exhibit. Which of the following is the most likely diagnosis?

A. Acute decompensated heart failure
B. Acute respiratory distress syndrome
C. Idiopathic pulmonary fibrosis
D. Obstructive pulmonary disease
E. Pulmonary arterial hypertension
F. Tension pneumothorax

Submit

A 54-year-old man comes to the emergency department due to worsening shortness of breath for the last 3 days. His symptoms initially occurred with exertion but are now present at rest. The patient could not sleep last night because of a suffocating cough each time he tried to lie down. He considers himself generally healthy and states, "I've never had to see a doctor for any problems." Family history is remarkable for asthma and hypertension. Blood pressure is 162/86 mm Hg, pulse is 92/min, and respirations are 26/min. An x-ray of the chest is shown in the exhibit. Which of the following is the most likely diagnosis?

- ✓ A. Acute decompensated heart failure (76%)
- B. Acute respiratory distress syndrome (6%)
- C. Idiopathic pulmonary fibrosis (4%)
- D. Obstructive pulmonary disease (2%)
- E. Pulmonary arterial hypertension (9%)
- F. Tension pneumothorax (1%)

Omitted
Correct answer
A

76%
Answered correctly

02 secs
Time Spent

03/09/2020
Last Updated

Explanation

This patient has progressive dyspnea and orthopnea (cough when lying down), along with chest x-ray findings of prominent pulmonary vessels, patchy **bilateral airspace opacities** (red arrows), blunting of the costophrenic angles (**pleural effusions** [yellow arrows]), and a **fissure sign** (created by fluid trapped between the right upper and middle lobe [blue arrow]). These findings are consistent with **acute decompensated heart**

1
2
3
4
5
6
7
8
9
10
11
12
13
14
15
16
17
18
19
20
21
22
23
24
25
26
27
28
29

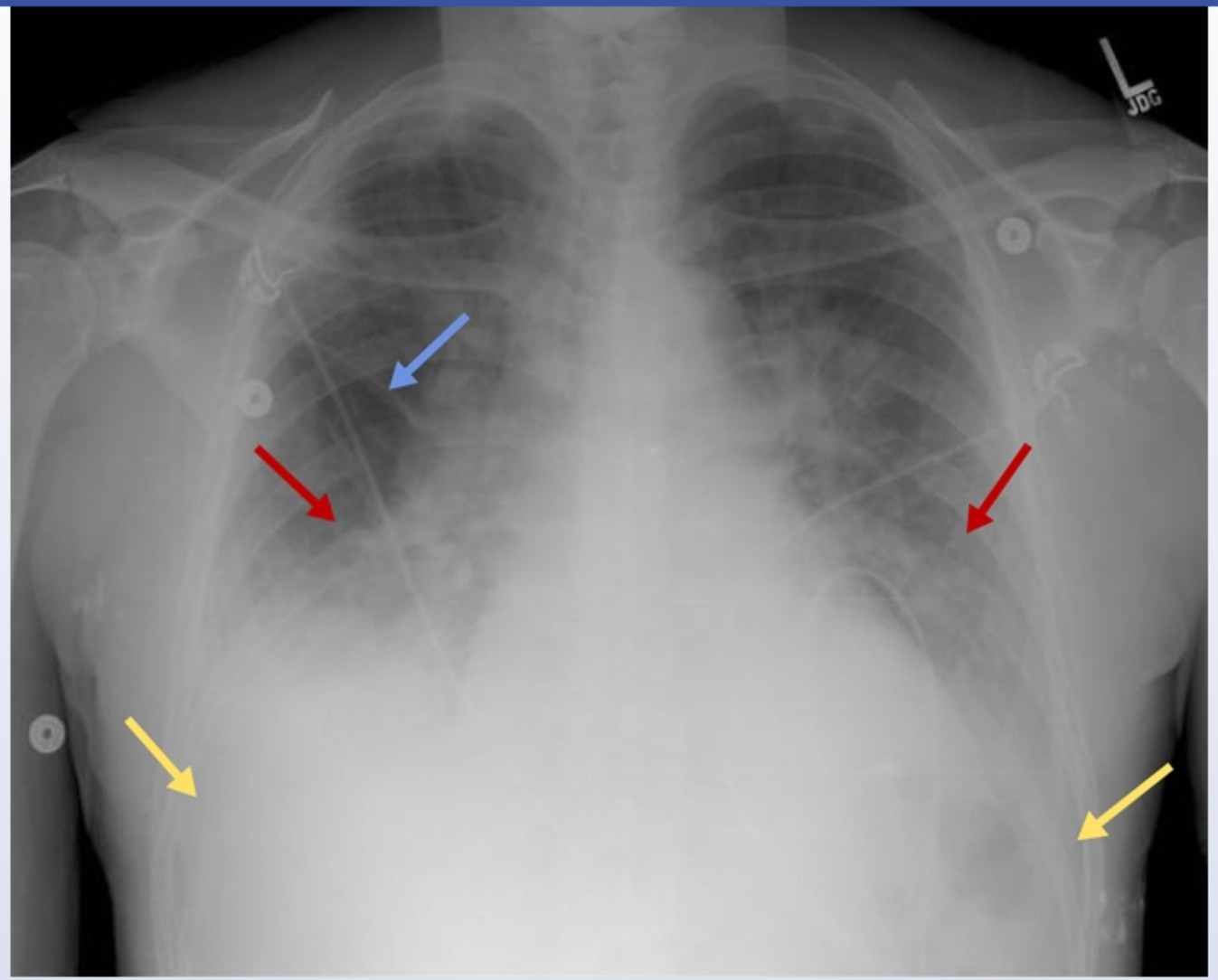

This patient has progressive dyspnea and orthopnea (cough when lying down), along with chest x-ray findings of prominent pulmonary vessels, patchy **bilateral airspace opacities** (red arrows), blunting of the costophrenic angles (**pleural effusions** [yellow arrows]), and a **fissure sign** (created by fluid trapped between the right upper and middle lobe [blue arrow]). These findings are consistent with **acute decompensated heart**

1
2
3
4
5
6
7
8
9
10
11
12
13
14
15
16
17
18
19
20
21
22
23
24
25
26
27
28
29

This patient has progressive dyspnea and orthopnea (cough when lying down), along with chest x-ray findings of prominent pulmonary vessels, patchy **bilateral airspace opacities** (red arrows), blunting of the costophrenic angles (**pleural effusions** [yellow arrows]), and a **fissure sign** (created by fluid trapped between the right upper and middle lobe [blue arrow]). These findings are consistent with **acute decompensated heart failure** (ADHF) due to left ventricular systolic or diastolic dysfunction. In ADHF, increased atrial and ventricular filling pressures are transmitted to the pulmonary vasculature, causing fluid transudation into pulmonary interstitial and alveolar spaces (**cardiogenic pulmonary edema**). The chest x-ray may also show Kerley B lines—short, horizontal lines perpendicular to the pleural surface that represent edema of the interlobular septa. Cardiomegaly (cardiac-to-thoracic width ratio >50%) is also common in heart failure, but it is difficult to assess on anteroposterior view due to magnification of the heart.

(Choice B) Acute respiratory distress syndrome (ARDS), or noncardiogenic pulmonary edema, results from endothelial injury and pulmonary capillary fluid leakage; it is typically preceded by a precipitating event such as aspiration, sepsis, pneumonia, or trauma. The appearance on chest x-ray is similar to ADHF, but ADHF is more likely in this patient without a recent inciting event for ARDS.

(Choice C) The chest x-ray in idiopathic interstitial fibrosis shows diffuse, reticular opacities typically associated with decreased lung volumes. Most patients have slowly progressive dyspnea and a nonproductive cough.

(Choice D) Obstructive pulmonary diseases (eg, chronic obstructive pulmonary disease) are associated with hyperinflated lungs and a flattened diaphragm. Asthma is an exception as the chest x-ray is typically normal between exacerbations.

(Choice E) The chest x-ray in pulmonary arterial hypertension reveals enlargement of the pulmonary arteries and right ventricle and absence of pulmonary edema.

(Choice F) On chest x-ray, pneumothorax is demonstrated by a white, visceral pleural line with an absence of peripheral pulmonary markings. The mediastinum is often shifted away from the affected side in tension pneumothorax.

Educational objective:
The chest x-ray in acute decompensated heart failure typically shows prominent pulmonary vessels; patchy, bilateral airspace opacification; and blunting of the costophrenic angles due to pleural effusions.

References

- Diagnostic value of B-Type natriuretic peptide and chest radiographic findings in patients with acute dyspnea.

1
2
3
4
5
6
7
8
9
10
11
12
13
14
15
16
17
18
19
20
21
22
23
24
25
26
27
28
29

Exhibit Display

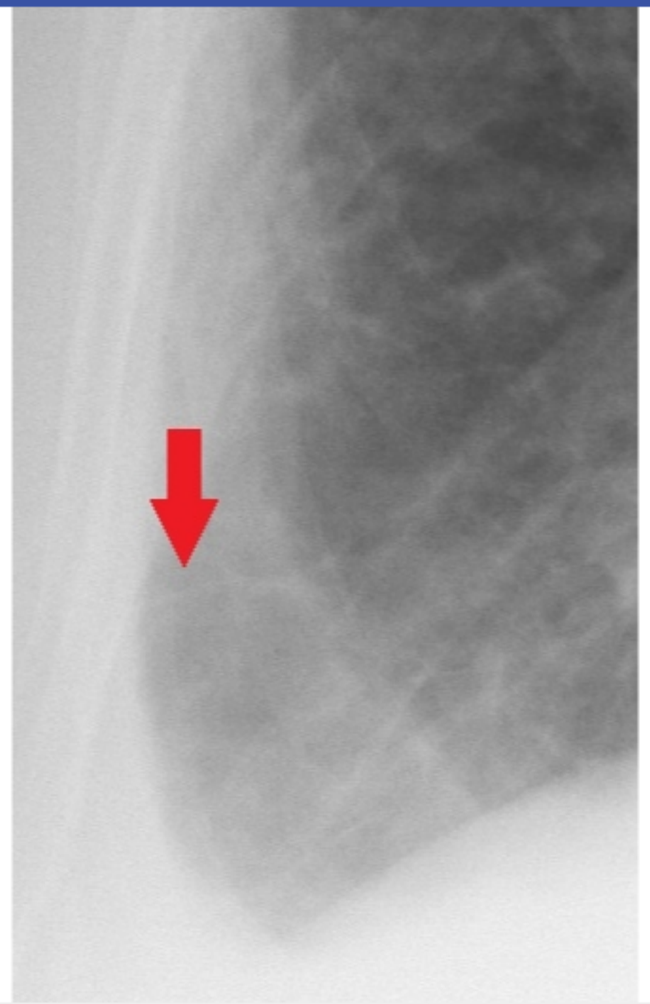

Zoom In Zoom Out Reset Add To New Card | Existing Card

- Diagnostic value of B-Type natriuretic peptide and chest radiographic findings in patients with acute dyspnea.

1
2
3
4
5
6
7
8
9
10
11
12
13
14
15
16
17
18
19
20
21
22
23
24
25
26
27
28
29

Exhibit Display

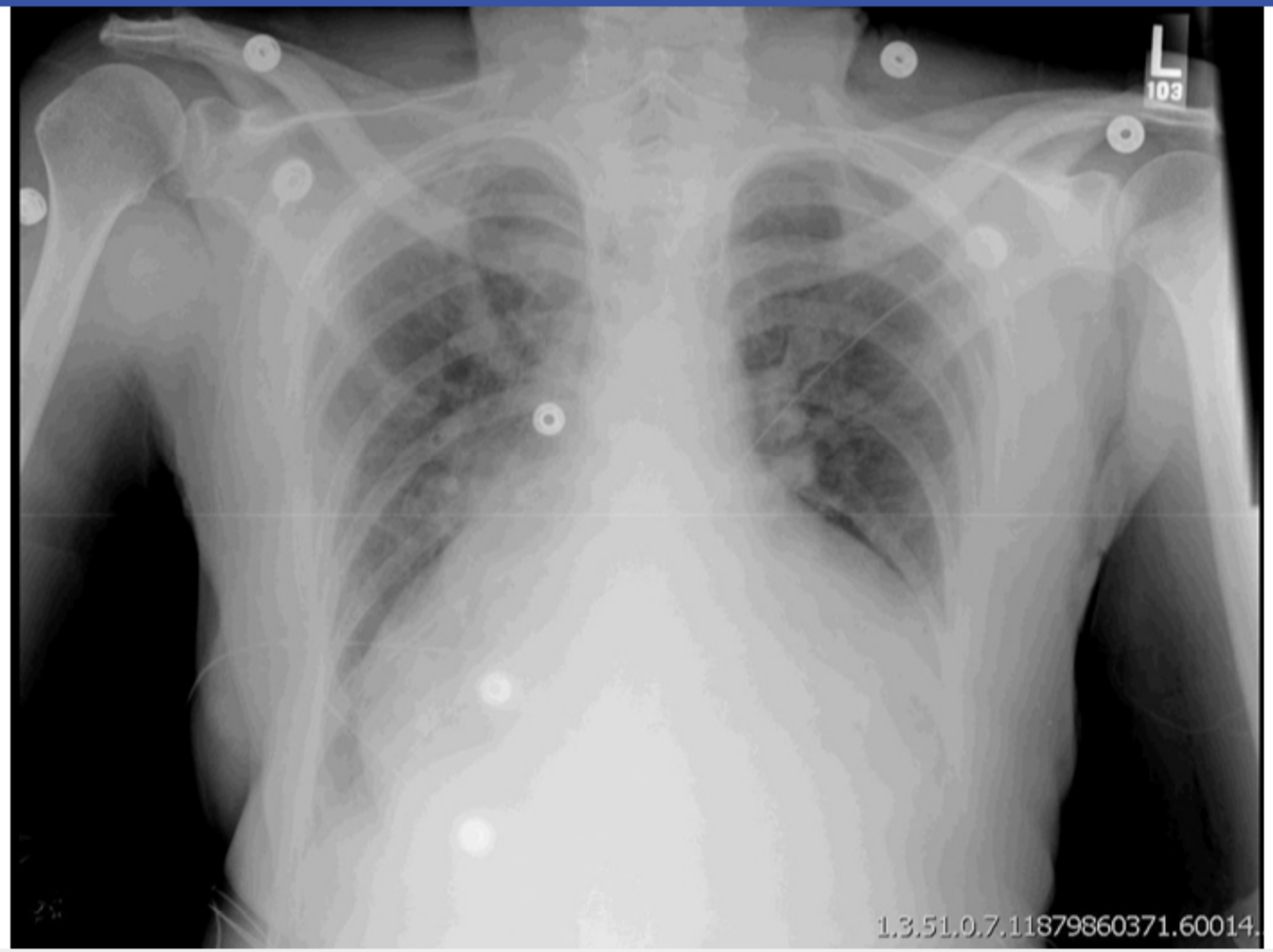

Zoom In Zoom Out Reset Add To New Card | Existing Card

- Diagnostic value of B-Type natriuretic peptide and chest radiographic findings in patients with acute dyspnea.

1
2
3
4
5
6
7
8
9
10
11
12
13
14
15
16
17
18
19
20
21
22
23
24
25
26
27
28
29

Exhibit Display

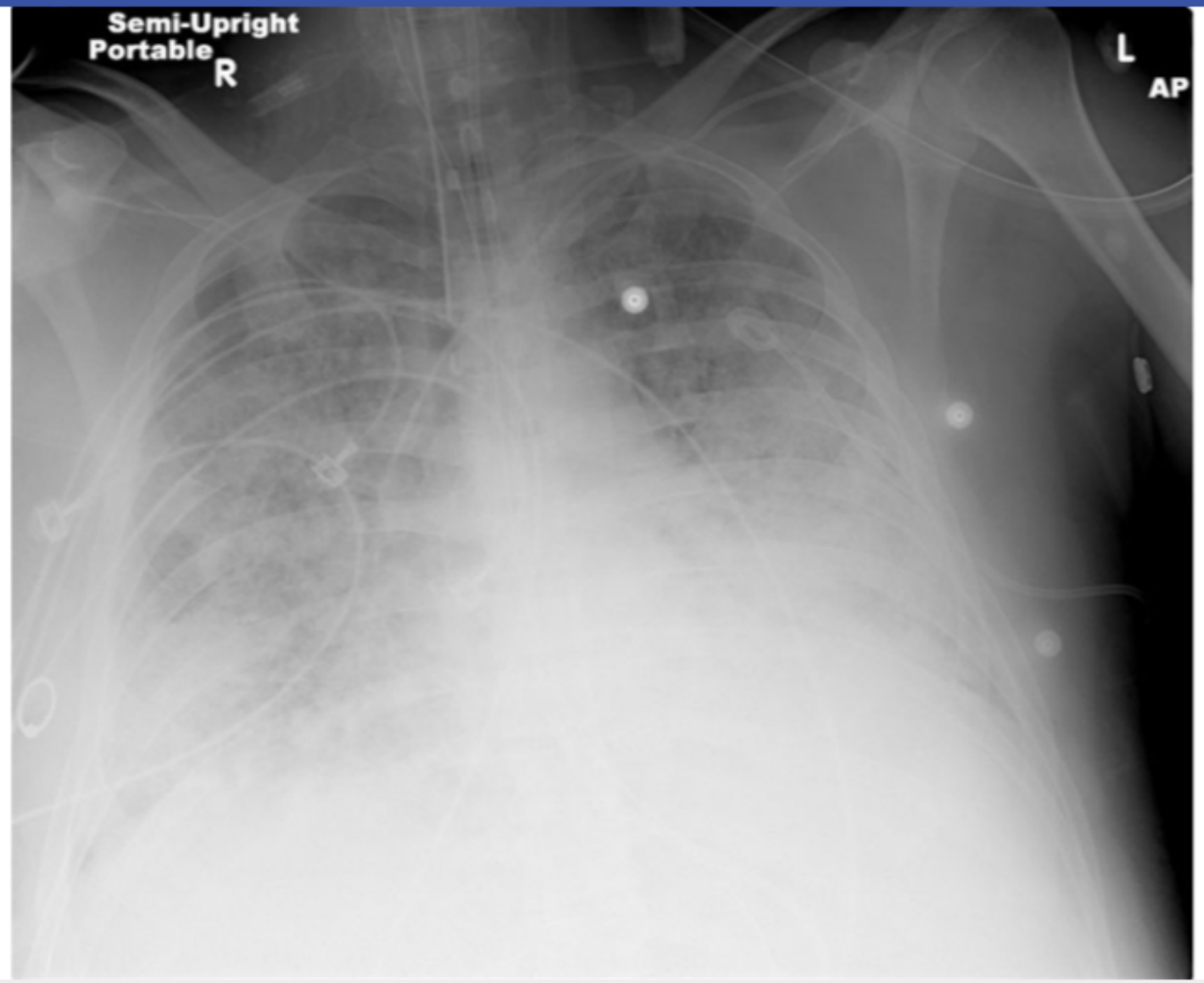

Zoom In Zoom Out Reset Add To New Card | Existing Card

- Diagnostic value of B-Type natriuretic peptide and chest radiographic findings in patients with acute dyspnea.

1
2
3
4
5
6
7
8
9
10
11
12
13
14
15
16
17
18
19
20
21
22
23
24
25
26
27
28
29

Exhibit Display

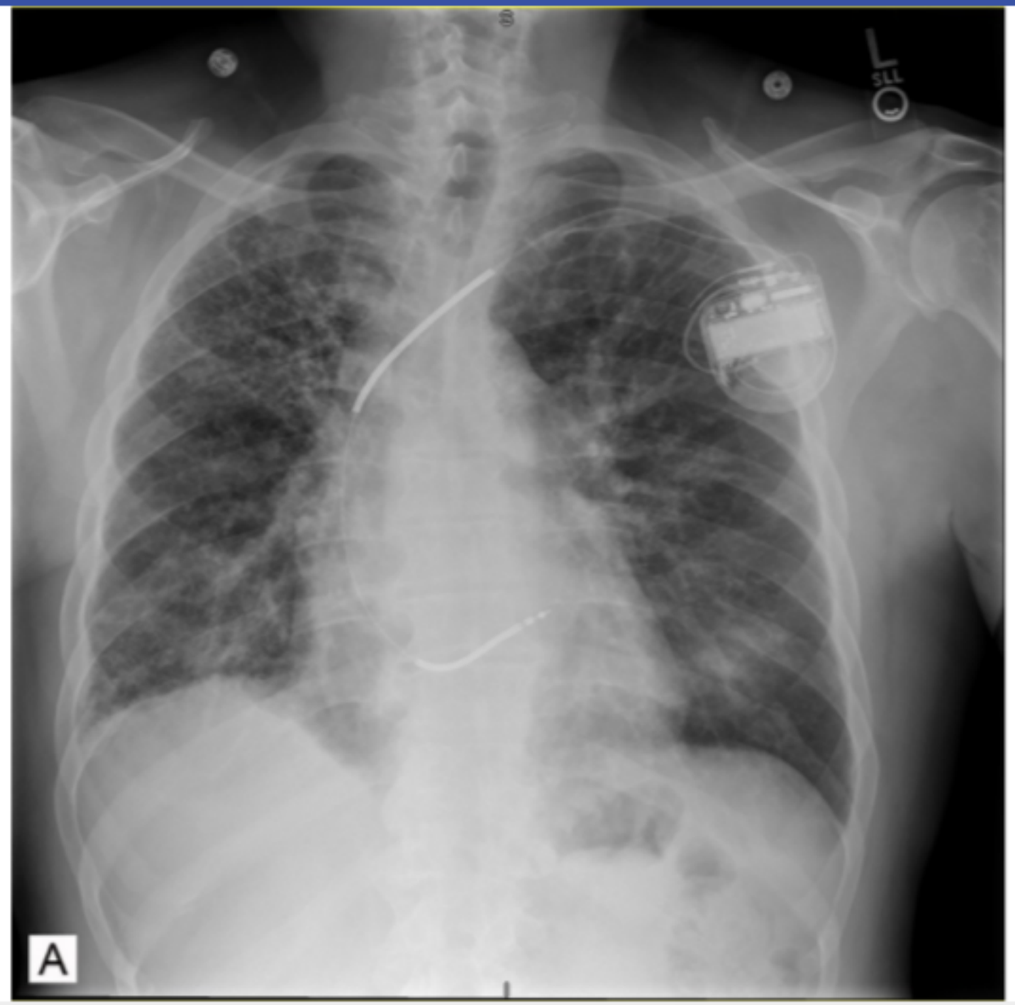

Zoom In Zoom Out Reset Add To New Card | Existing Card

- Diagnostic value of B-Type natriuretic peptide and chest radiographic findings in patients with acute dyspnea.

1
2
3
4
5
6
7
8
9
10
11
12
13
14
15
16
17
18
19
20
21
22
23
24
25
26
27
28
29

Exhibit Display

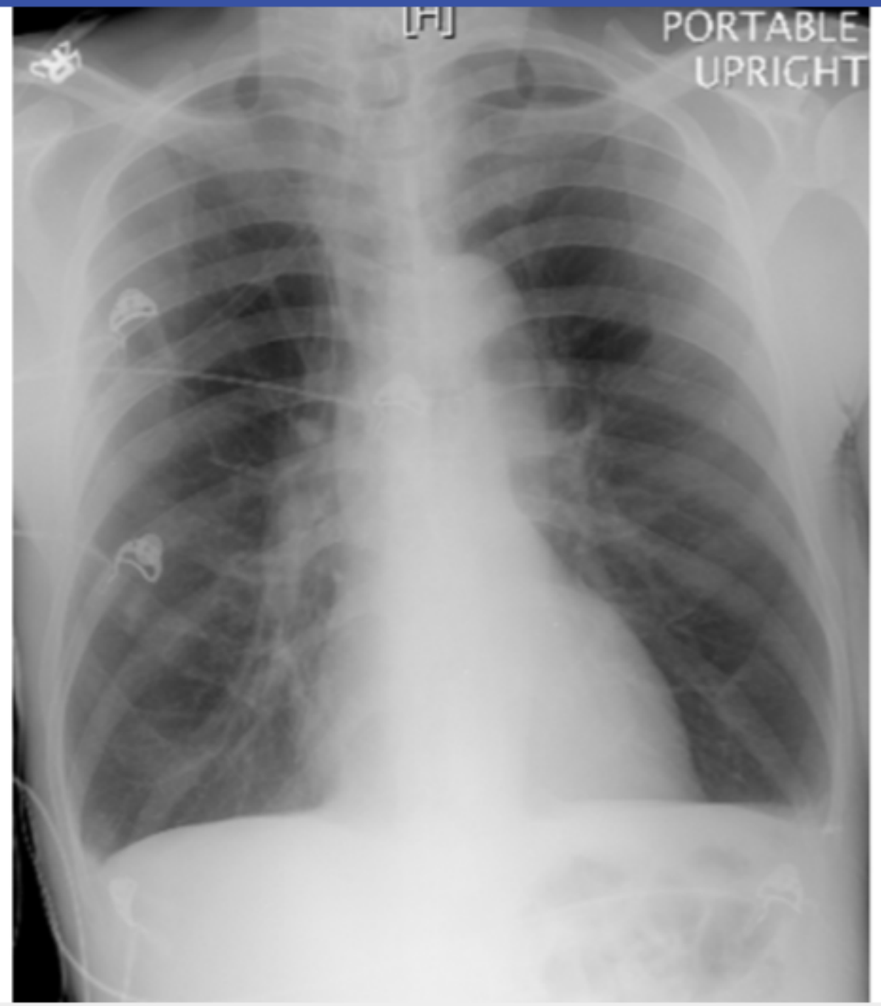

Zoom In Zoom Out Reset Add To New Card | Existing Card

- Diagnostic value of B-Type natriuretic peptide and chest radiographic findings in patients with acute dyspnea.

1
2
3
4
5
6
7
8
9
10
11
12
13
14
15
16
17
18
19
20
21
22
23
24
25
26
27
28
29

Exhibit Display

Pulmonary hypertension

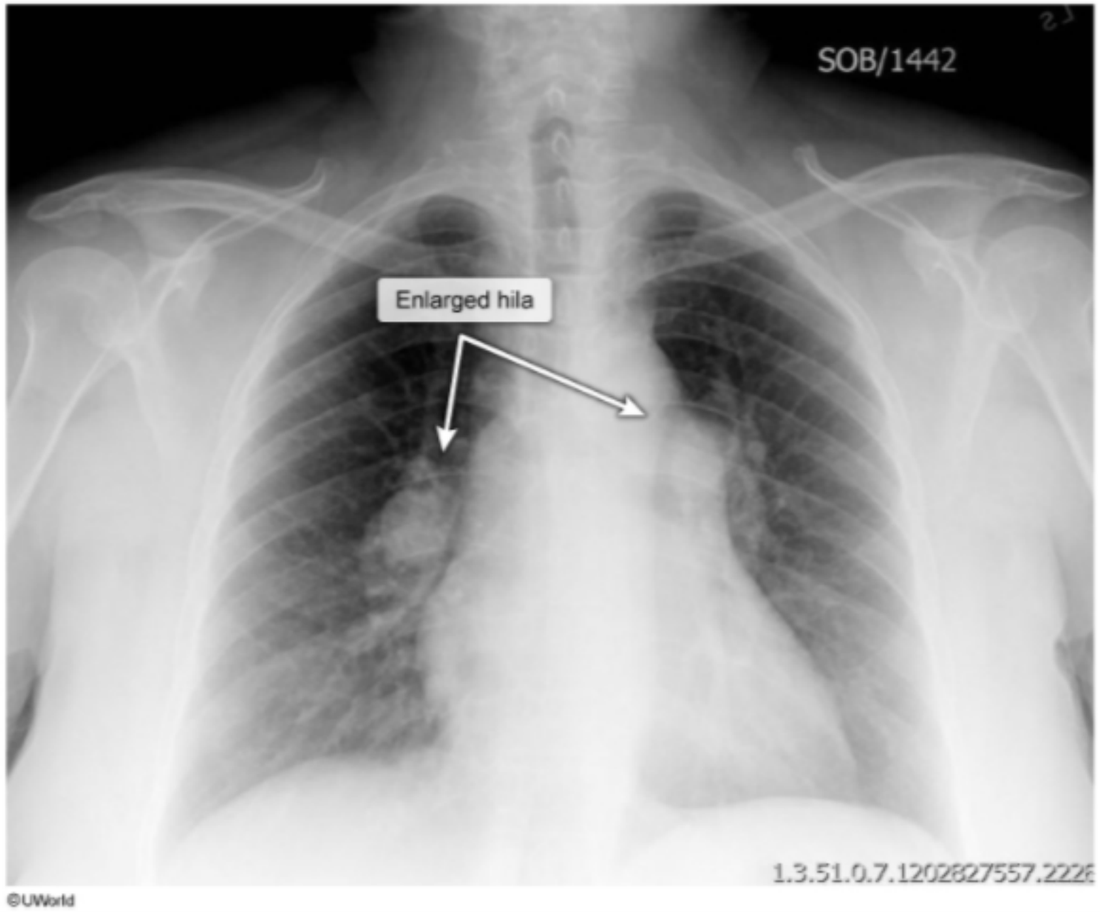

Zoom In | Zoom Out | Reset | Add To New Card | Existing Card

- Diagnostic value of B-Type natriuretic peptide and chest radiographic findings in patients with acute dyspnea.

1
2
3
4
5
6
7
8
9
10
11
12
13
14
15
16
17
18
19
20
21
22
23
24
25
26
27
28
29

Exhibit Display

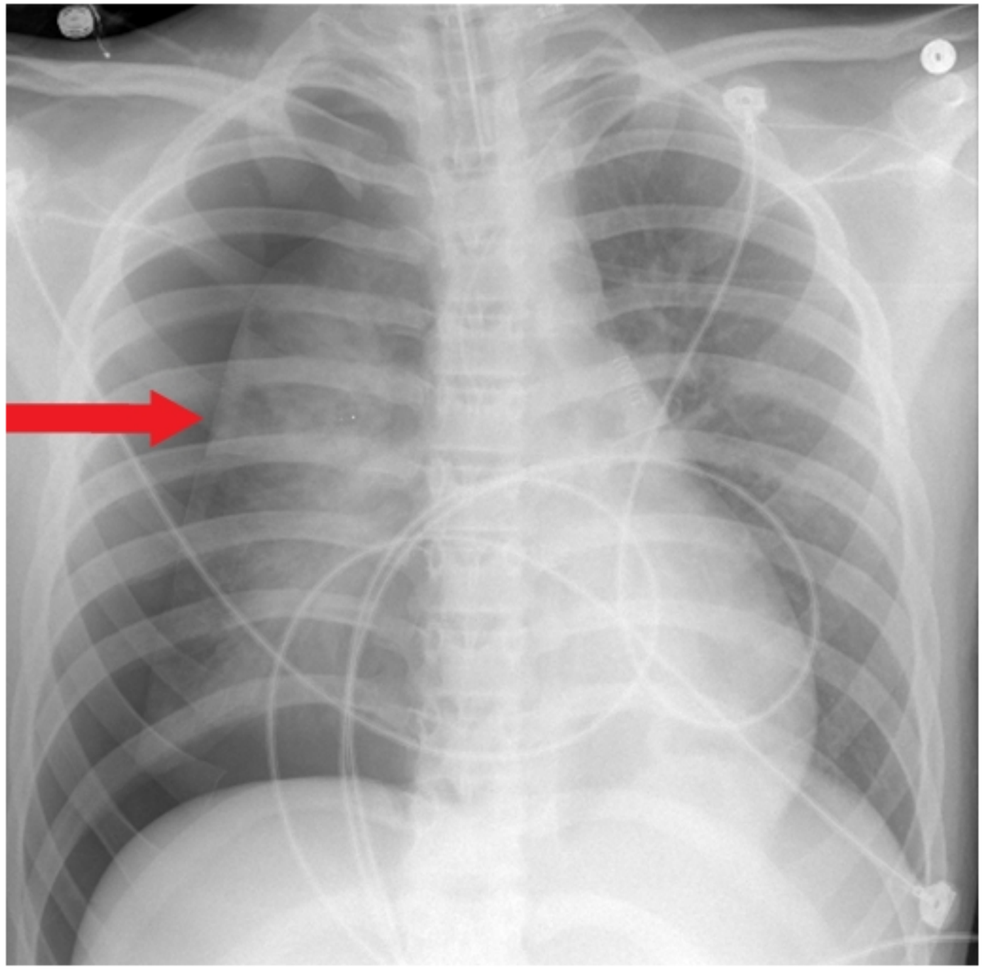

Zoom In Zoom Out Reset Add To New Card | Existing Card

- Diagnostic value of B-Type natriuretic peptide and chest radiographic findings in patients with acute dyspnea.

x-ray may also show Kerley B lines—short, horizontal lines perpendicular to the pleural surface that represent edema of the interlobular septa. Cardiomegaly (cardiac-to-thoracic width ratio >50%) is also common in heart failure, but it is difficult to assess on anteroposterior view due to magnification of the heart.

(Choice B) Acute respiratory distress syndrome (ARDS), or noncardiogenic pulmonary edema, results from endothelial injury and pulmonary capillary fluid leakage; it is typically preceded by a precipitating event such as aspiration, sepsis, pneumonia, or trauma. The appearance on chest x-ray is similar to ADHF, but ADHF is more likely in this patient without a recent inciting event for ARDS.

(Choice C) The chest x-ray in idiopathic interstitial fibrosis shows diffuse, reticular opacities typically associated with decreased lung volumes. Most patients have slowly progressive dyspnea and a nonproductive cough.

(Choice D) Obstructive pulmonary diseases (eg, chronic obstructive pulmonary disease) are associated with hyperinflated lungs and a flattened diaphragm. Asthma is an exception as the chest x-ray is typically normal between exacerbations.

(Choice E) The chest x-ray in pulmonary arterial hypertension reveals enlargement of the pulmonary arteries and right ventricle and absence of pulmonary edema.

(Choice F) On chest x-ray, pneumothorax is demonstrated by a white, visceral pleural line with an absence of peripheral pulmonary markings. The mediastinum is often shifted away from the affected side in tension pneumothorax.

Educational objective:
The chest x-ray in acute decompensated heart failure typically shows prominent pulmonary vessels; patchy, bilateral airspace opacification; and blunting of the costophrenic angles due to pleural effusions.

References

- Diagnostic value of B-Type natriuretic peptide and chest radiographic findings in patients with acute dyspnea.

Pathology	Cardiovascular System	Acute heart failure
Subject	System	Topic

Copyright © UWorld. All rights reserved.

1
2
3
4
5
6
7
8
9
10
11
12
13
14
15
16
17
18
19
20
21
22
23
24
25
26
27
28
29

A 32-year-old man dies suddenly in his sleep. An autopsy is performed and the heart is examined for signs of structural cardiac disease. The heart shows a left ventricle with a large area of apical thinning composed of fibrotic scar tissue. The mid and basal left ventricular segments show normal myocardial thickness. The coronary arteries show no evidence of obstructive atherosclerosis. The right ventricle appears normal in size. No apparent valve damage is present. Dilation and wall-thickening of the esophagus is also noted. Which of the following factors in this patient's medical history would be most helpful in determining the cause of death?

A. Alcohol consumption
B. Areas of residence
C. Childhood vaccinations
D. Family history of cardiomyopathy
E. Occupational chemical exposure

Submit

1
2
3
4
5
6
7
8
9
10
11
12
13
14
15
16
17
18
19
20
21
22
23
24
25
26
27
28
29

A 32-year-old man dies suddenly in his sleep. An autopsy is performed and the heart is examined for signs of structural cardiac disease. The heart shows a left ventricle with a large area of apical thinning composed of fibrotic scar tissue. The mid and basal left ventricular segments show normal myocardial thickness. The coronary arteries show no evidence of obstructive atherosclerosis. The right ventricle appears normal in size. No apparent valve damage is present. Dilation and wall-thickening of the esophagus is also noted. Which of the following factors in this patient's medical history would be most helpful in determining the cause of death?

- A. Alcohol consumption (18%)
- ✓ B. Areas of residence (51%)
- C. Childhood vaccinations (6%)
- D. Family history of cardiomyopathy (15%)
- E. Occupational chemical exposure (8%)

Omitted
Correct answer
B

51%
Answered correctly

02 secs
Time Spent

02/20/2020
Last Updated

Explanation

Chagas disease	
Epidemiology	• Caused by protozoan *Trypanosoma cruzi* • Vector: triatomine ("kissing") bug • Endemic in Central & South America

Chagas disease	
Epidemiology	• Caused by protozoan *Trypanosoma cruzi* • Vector: triatomine ("kissing") bug • Endemic in Central & South America
Cardiac manifestations	• Dilated cardiomyopathy with biventricular failure • Apical wall thinning with aneurysm ± mural thrombus • Ventricular arrhythmias
Gastrointestinal manifestations	• Megaesophagus (secondary achalasia) • Megacolon

This man with a large area of localized cardiac apical wall thinning likely died of chronic **Chagas cardiomyopathy**. Chagas disease is caused by infection with the protozoan *Trypanosoma cruzi*, which is transmitted by the triatomine "kissing" bug (Reduviid family) found throughout the Americas as far north as the southern United States. Infection is rare in developed regions, but the disease is endemic throughout **Central and South America** where widespread open-air and thatched-roof housing exposes individuals to routine contact with the triatomine vector.

Years following initial infection, some individuals develop serious end-organ damage affecting the cardiac, gastrointestinal, and/or central nervous systems. Cardiac disease results from a chronic parasite-induced and immune-mediated myocarditis that leads to **dilated cardiomyopathy** (DCM). Chronic Chagas cardiomyopathy is relatively unique among DCMs in that there is characteristically localized **apical wall thinning** with the development of a large apical **aneurysm**. In addition to impairing ventricular systolic function, the aneurysm can harbor **mural thrombus** that may systemically embolize and cause stroke. Damage to the cardiac conduction system can also trigger **ventricular arrhythmias** (eg, ventricular tachycardia, ventricular fibrillation) that can lead to sudden cardiac death (the likely cause of death in this man).

The **gastrointestinal manifestations** of Chagas disease involve destruction of the myenteric plexus, which can lead to progressive dilation and dysfunction of the esophagus and, less commonly, the colon.

(Choices A, C, D, and E) Excessive alcohol consumption can lead to DCM. Measles, mumps, and rubella are typically vaccinated against in childhood and are potential causes of viral DCM. Genetic mutations of the gene encoding for the cardiac sarcomere protein titin can lead to familial DCM. Miners and metal workers who are exposed to high levels of cobalt can develop DCM. These DCMs typically involve diffuse left

	• Megacolon

This man with a large area of localized cardiac apical wall thinning likely died of chronic **Chagas cardiomyopathy**. Chagas disease is caused by infection with the protozoan *Trypanosoma cruzi*, which is transmitted by the triatomine "kissing" bug (Reduviid family) found throughout the Americas as far north as the southern United States. Infection is rare in developed regions, but the disease is endemic throughout **Central and South America** where widespread open-air and thatched-roof housing exposes individuals to routine contact with the triatomine vector.

Years following initial infection, some individuals develop serious end-organ damage affecting the cardiac, gastrointestinal, and/or central nervous systems. Cardiac disease results from a chronic parasite-induced and immune-mediated myocarditis that leads to **dilated cardiomyopathy** (DCM). Chronic Chagas cardiomyopathy is relatively unique among DCMs in that there is characteristically localized **apical wall thinning** with the development of a large apical **aneurysm**. In addition to impairing ventricular systolic function, the aneurysm can harbor **mural thrombus** that may systemically embolize and cause stroke. Damage to the cardiac conduction system can also trigger **ventricular arrhythmias** (eg, ventricular tachycardia, ventricular fibrillation) that can lead to sudden cardiac death (the likely cause of death in this man).

The **gastrointestinal manifestations** of Chagas disease involve destruction of the myenteric plexus, which can lead to progressive dilation and dysfunction of the esophagus and, less commonly, the colon.

(Choices A, C, D, and E) Excessive alcohol consumption can lead to DCM. Measles, mumps, and rubella are typically vaccinated against in childhood and are potential causes of viral DCM. Genetic mutations of the gene encoding for the cardiac sarcomere protein titin can lead to familial DCM. Miners and metal workers who are exposed to high levels of cobalt can develop DCM. These DCMs typically involve diffuse left ventricular wall thinning, unlike the characteristic localized apical wall thinning and aneurysm development that occurs in chronic Chagas cardiomyopathy. DCM due to ischemic heart disease may sometimes involve localized wall thinning with aneurysm development, but it is unlikely in this young man with no evidence of atherosclerotic coronary artery disease. Esophageal enlargement is also not expected with these other etiologies of DCM.

Educational objective:
Chagas disease is endemic to Central and South America and can lead to chronic Chagas cardiomyopathy, a dilated cardiomyopathy. Unlike the diffuse ventricular wall thinning that occurs in most dilated cardiomyopathies, chronic Chagas cardiomyopathy is characterized by localized apical wall thinning with large apical aneurysm development.

References

Chagas cardiomyopathy in Latin America: review

1
2
3
4
5
6
7
8
9
10
11
12
13
14
15
16
17
18
19
20
21
22
23
24
25
26
27
28
29

- Megacolon

Exhibit Display

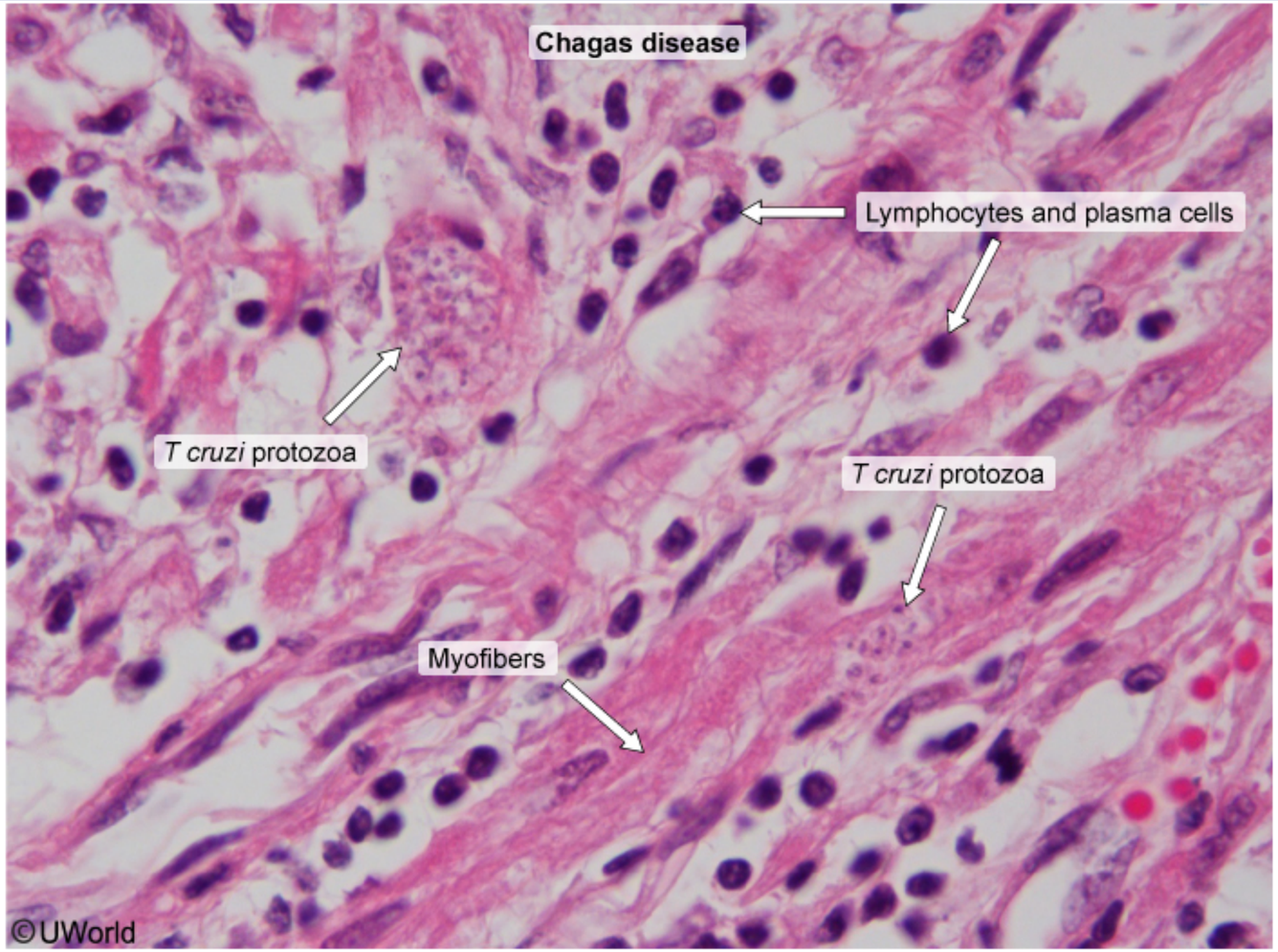

Zoom In
Zoom Out
Reset
Add To Flash Card

1
2
3
4
5
6
7
8
9
10
11
12
13
14
15
16
17
18
19
20
21
22
23
24
25
26
27
28
29

A 56-year-old man comes to the clinic for a routine checkup. Medical history includes hypertension, type 2 diabetes mellitus, hyperlipidemia, and mild intermittent asthma. The patient currently takes no medications and has not seen a physician in 7 years. He reports feeling well. Blood pressure is 152/101 mm Hg and pulse is 87/min. Waist circumference is 110 cm (43 in). Laboratory results are as follows:

Low-density lipoprotein	161 mg/dL
Fasting blood glucose	201 mg/dL
Hemoglobin A1c	7.4%

Which of the following vascular beds is most likely to carry the highest atherosclerotic burden in this patient?

A. Coronary arteries
B. Internal thoracic arteries
C. Mesenteric arteries
D. Popliteal arteries
E. Renal arteries

Submit

A 56-year-old man comes to the clinic for a routine checkup. Medical history includes hypertension, type 2 diabetes mellitus, hyperlipidemia, and mild intermittent asthma. The patient currently takes no medications and has not seen a physician in 7 years. He reports feeling well. Blood pressure is 152/101 mm Hg and pulse is 87/min. Waist circumference is 110 cm (43 in). Laboratory results are as follows:

Low-density lipoprotein	161 mg/dL
Fasting blood glucose	201 mg/dL
Hemoglobin A1c	7.4%

Which of the following vascular beds is most likely to carry the highest atherosclerotic burden in this patient?

- ✓ A. Coronary arteries (64%)
- B. Internal thoracic arteries (3%)
- C. Mesenteric arteries (5%)
- D. Popliteal arteries (8%)
- E. Renal arteries (18%)

Omitted
Correct answer
A

64%
Answered correctly

02 secs
Time Spent

05/01/2020
Last Updated

Explanation

This patient has multiple risk factors (eg, hypertension, diabetes mellitus, hyperlipidemia) that contribute to **atherosclerosis**. Atherosclerosis is a

This patient has multiple risk factors (eg, hypertension, diabetes mellitus, hyperlipidemia) that contribute to **atherosclerosis**. Atherosclerosis is a pathophysiologic process that begins in childhood with the development of focal intimal thickening due to accumulation of lipid-laden macrophages and extracellular matrix ("fatty streaks"). With advancing age, fatty streaks transition into atherosclerotic plaques, such as fibrous cap atheromas and fibrous plaques. More advanced lesions develop a lipid-rich necrotic core and areas of calcification.

Atherosclerosis is a chronic disease of the arterial walls and involves all major vascular beds. The most susceptible vascular regions involve bends and branch points that encourage **turbulent blood flow**, which disrupts vascular wall integrity and leads to endothelial cell dysfunction. Turbulent blood flow also leads to decreased shear stress on the vascular walls and prolonged endothelial contact with cholesterol particles.

The hemodynamics of the **lower abdominal aorta** and the **coronary arteries** make these vascular beds the most susceptible to atherosclerosis of all the major vascular beds in the body. In fact, atherosclerotic lesions (eg, intimal thickening, fatty streaks) occur in these vessels as early as the second decade of life.

(Choice B) The internal thoracic arteries (previously known as the internal mammary arteries) are relatively resistant to developing atherosclerosis and are often used as conduits in patients undergoing coronary artery bypass grafting.

(Choices C and E) The mesenteric and renal arteries are susceptible to developing atherosclerosis; however, the burden of disease tends to be less severe than in the coronary circulation.

(Choice D) Along with the carotid arteries, the popliteal arteries are among the most susceptible to atherosclerosis in the body. However, these arteries are not as susceptible to atherosclerosis as the aorta and coronary arteries.

Educational objective:
Atherosclerosis is a pathophysiologic process involving endothelial cell dysfunction, and it develops most rapidly in areas with bends and branch points that encourage turbulent blood flow. The lower abdominal aorta and coronary arteries are the vascular beds most susceptible to atherosclerosis; they tend to develop atherosclerosis earliest in life and have the highest overall atherosclerotic burden.

References

- High prevalence of coronary atherosclerosis in asymptomatic teenagers and young adults: evidence from intravascular ultrasound.
- Site specificity of atherosclerosis: site-selective responses to atherosclerotic modulators.

1
2
3
4
5
6
7
8
9
10
11
12
13
14
15
16
17
18
19
20
21
22
23
24
25
26
27
28
29

Atherosclerosis is a chronic disease of the arterial walls and involves all major vascular beds. The most susceptible vascular regions involve bends and branch points that encourage **turbulent blood flow**, which disrupts vascular wall integrity and leads to endothelial cell dysfunction. Turbulent blood flow also leads to decreased shear stress on the vascular walls and prolonged endothelial contact with cholesterol particles.

The hemodynamics of the **lower abdominal aorta** and the **coronary arteries** make these vascular beds the most susceptible to atherosclerosis of all the major vascular beds in the body. In fact, atherosclerotic lesions (eg, intimal thickening, fatty streaks) occur in these vessels as early as the second decade of life.

(Choice B) The internal thoracic arteries (previously known as the internal mammary arteries) are relatively resistant to developing atherosclerosis and are often used as conduits in patients undergoing coronary artery bypass grafting.

(Choices C and E) The mesenteric and renal arteries are susceptible to developing atherosclerosis; however, the burden of disease tends to be less severe than in the coronary circulation.

(Choice D) Along with the carotid arteries, the popliteal arteries are among the most susceptible to atherosclerosis in the body. However, these arteries are not as susceptible to atherosclerosis as the aorta and coronary arteries.

Educational objective:
Atherosclerosis is a pathophysiologic process involving endothelial cell dysfunction, and it develops most rapidly in areas with bends and branch points that encourage turbulent blood flow. The lower abdominal aorta and coronary arteries are the vascular beds most susceptible to atherosclerosis; they tend to develop atherosclerosis earliest in life and have the highest overall atherosclerotic burden.

References

- High prevalence of coronary atherosclerosis in asymptomatic teenagers and young adults: evidence from intravascular ultrasound.
- Site specificity of atherosclerosis: site-selective responses to atherosclerotic modulators.

Pathology	Cardiovascular System	Atherosclerosis
Subject	System	Topic

Copyright © UWorld. All rights reserved.

1
2
3
4
5
6
7
8
9
10
11
12
13
14
15
16
17
18
19
20
21
22
23
24
25
26
27
28
29

A 35-year-old primigravid woman comes to the clinic during the second trimester. The patient reports that she has had some tiredness, which she attributes to pregnancy. She takes 1 nap during the day. She has no chest pain, cough, or lower extremity swelling. As a child, the patient was told that she has a murmur but does not know any details and says that she has felt well until recently. On physical examination, a 3/6 midsystolic murmur is heard at the left upper sternal border and S2 is widely split. Which of the following is the most likely diagnosis?

A. Benign flow murmur
B. Bicuspid aortic valve
C. Hypertrophic cardiomyopathy
D. Pulmonic stenosis
E. Ventricular septal defect

Submit

1
2
3
4
5
6
7
8
9
10
11
12
13
14
15
16
17
18
19
20
21
22
23
24
25
26
27
28
29

A 35-year-old primigravid woman comes to the clinic during the second trimester. The patient reports that she has had some tiredness, which she attributes to pregnancy. She takes 1 nap during the day. She has no chest pain, cough, or lower extremity swelling. As a child, the patient was told that she has a murmur but does not know any details and says that she has felt well until recently. On physical examination, a 3/6 midsystolic murmur is heard at the left upper sternal border and S2 is widely split. Which of the following is the most likely diagnosis?

- A. Benign flow murmur (17%)
- B. Bicuspid aortic valve (7%)
- C. Hypertrophic cardiomyopathy (1%)
- ✓ D. Pulmonic stenosis (62%)
- E. Ventricular septal defect (11%)

Omitted
Correct answer
D

62%
Answered correctly

02 secs
Time Spent

04/03/2020
Last Updated

Explanation

1
2
3
4
5
6
7
8
9
10
11
12
13
14
15
16
17
18
19
20
21
22
23
24
25
26
27
28
29

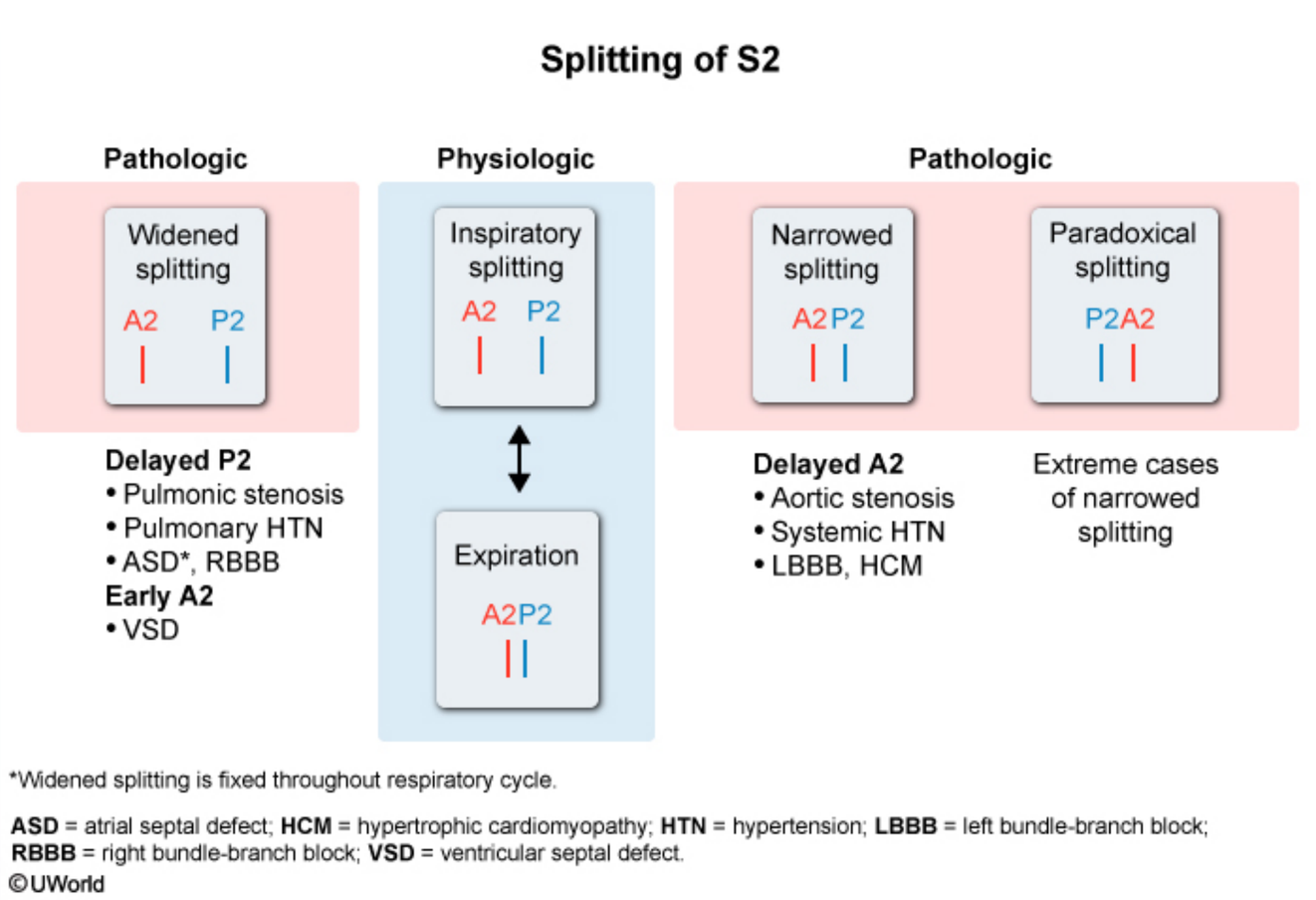

This patient likely has **pulmonic valve stenosis** (PS), which most commonly occurs as an isolated **congenital defect** and rarely occurs as an acquired defect (eg, rheumatic fever, carcinoid syndrome). Severe PS is typically diagnosed early in life due to presentation with right-sided heart failure, but patients with relatively mild PS often remain asymptomatic throughout childhood and develop symptoms (eg, dyspnea, fatigue) in adulthood. The physiologic changes of pregnancy (eg, increased plasma volume) can unmask underlying PS.

Cardiac auscultation in PS reveals a pulmonic **ejection click** followed by a harsh **crescendo-decrescendo systolic murmur** best heard at the

©UWorld

This patient likely has **pulmonic valve stenosis** (PS), which most commonly occurs as an isolated **congenital defect** and rarely occurs as an acquired defect (eg, rheumatic fever, carcinoid syndrome). Severe PS is typically diagnosed early in life due to presentation with right-sided heart failure, but patients with relatively mild PS often remain asymptomatic throughout childhood and develop symptoms (eg, dyspnea, fatigue) in adulthood. The physiologic changes of pregnancy (eg, increased plasma volume) can unmask underlying PS.

Cardiac auscultation in PS reveals a pulmonic **ejection click** followed by a harsh **crescendo-decrescendo systolic murmur** best heard at the left upper sternal border. The stenosis causes the pulmonic valve to close later than usual as it takes longer for the right ventricle to push blood through the narrowed valve. This results in **widened splitting** of the aortic and pulmonic components of S2. Inspiration draws additional blood into the right side of heart, which increases the intensity of the murmur and further widens the splitting of S2.

(Choice A) A benign flow murmur can occur in patients with high cardiac output states (eg, pregnancy) due to increased flow across the aortic and pulmonic valves; however, the murmur is typically low grade (2/6 or less) and abnormal splitting of S2 is not present.

(Choice B) A bicuspid aortic valve is the most common congenital heart defect seen in adults and can lead to aortic stenosis in relatively young patients (eg, those in their 50s). However, aortic stenosis causes delayed closure of the aortic valve, leading to narrowed or even paradoxical splitting of S2.

(Choice C) Hypertrophic cardiomyopathy can cause a systolic murmur that mimics that of aortic stenosis and is best heard at the mid-left sternal border. Splitting of S2 may be narrowed due to prolonged ejection of blood through the aortic valve.

(Choice E) A small- or moderate-sized ventricular septal defect may present in adulthood with symptoms of heart failure. There is typically widened splitting of S2 due to early closure of the aortic valve (less blood is ejected into the aorta because some blood is ejected into the right ventricle). However, a holosystolic murmur best heard at the left lower sternal border is expected.

Educational objective:
Pulmonic valve stenosis causes a crescendo-decrescendo systolic murmur (best heard at the left upper sternal border) and delays closure of the pulmonic valve, resulting in widened splitting of S2. Inspiration increases blood flow to the right side of the heart, causing increased intensity of the murmur and even later closure of the pulmonic valve.

References

- Effect of pulmonary stenosis on pregnancy outcomes—a case-control study

Cardiac auscultation in PS reveals a pulmonic **ejection click** followed by a harsh **crescendo-decrescendo systolic murmur** best heard at the left upper sternal border. The stenosis causes the pulmonic valve to close later than usual as it takes longer for the right ventricle to push blood through the narrowed valve. This results in **widened splitting** of the aortic and pulmonic components of S2. Inspiration draws additional blood into the right side of heart, which increases the intensity of the murmur and further widens the splitting of S2.

(Choice A) A benign flow murmur can occur in patients with high cardiac output states (eg, pregnancy) due to increased flow across the aortic and pulmonic valves; however, the murmur is typically low grade (2/6 or less) and abnormal splitting of S2 is not present.

(Choice B) A bicuspid aortic valve is the most common congenital heart defect seen in adults and can lead to aortic stenosis in relatively young patients (eg, those in their 50s). However, aortic stenosis causes delayed closure of the aortic valve, leading to narrowed or even paradoxical splitting of S2.

(Choice C) Hypertrophic cardiomyopathy can cause a systolic murmur that mimics that of aortic stenosis and is best heard at the mid-left sternal border. Splitting of S2 may be narrowed due to prolonged ejection of blood through the aortic valve.

(Choice E) A small- or moderate-sized ventricular septal defect may present in adulthood with symptoms of heart failure. There is typically widened splitting of S2 due to early closure of the aortic valve (less blood is ejected into the aorta because some blood is ejected into the right ventricle). However, a holosystolic murmur best heard at the left lower sternal border is expected.

Educational objective:
Pulmonic valve stenosis causes a crescendo-decrescendo systolic murmur (best heard at the left upper sternal border) and delays closure of the pulmonic valve, resulting in widened splitting of S2. Inspiration increases blood flow to the right side of the heart, causing increased intensity of the murmur and even later closure of the pulmonic valve.

References

- Effect of pulmonary stenosis on pregnancy outcomes—a case-control study.

Pathology	Cardiovascular System	Pulmonary stenosis
Subject	System	Topic

Copyright © UWorld. All rights reserved.

*Widened splitting is fixed throughout respiratory cycle.

Exhibit Display

Cardiac auscultatory locations

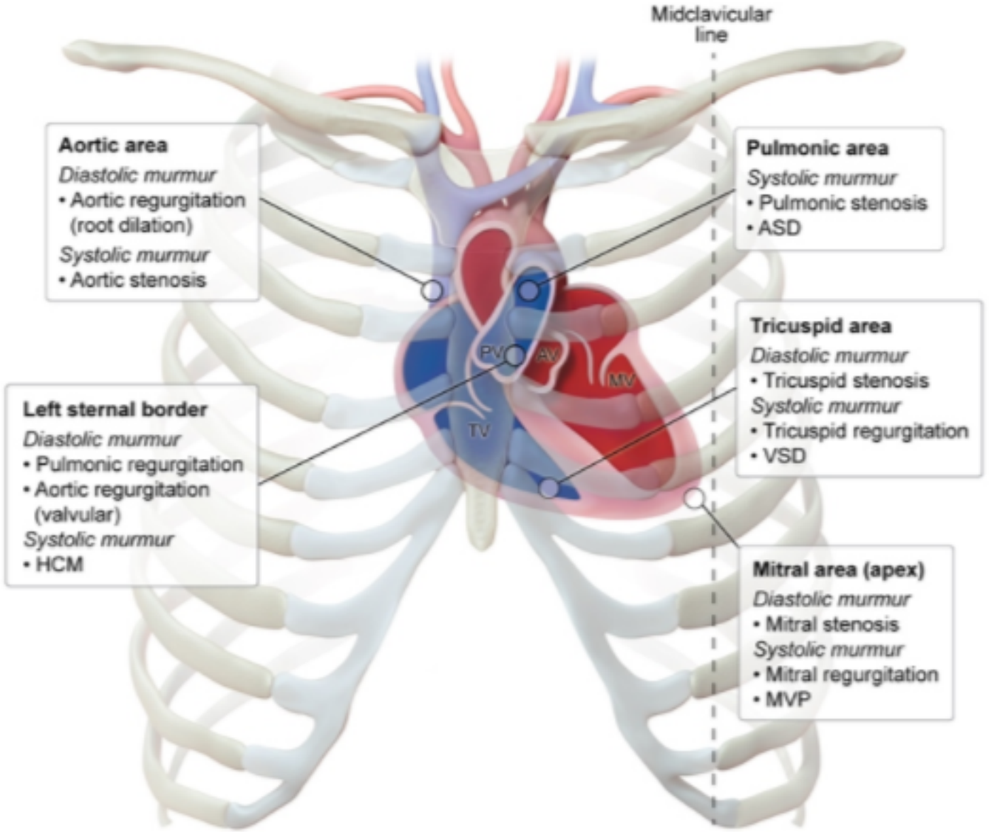

ASD = atrial septal defect; **AV** = aortic valve; **HCM** = hypertrophic cardiomyopathy; **MV** = mitral valve; **MVP** = mitral valve prolapse; **PV** = pulmonic valve; **TV** = tricuspid valve; **VSD** = ventricular septal defect.

©UWorld

Zoom In | Zoom Out | Reset | Add To New Card | Existing Card

pulmonic valve, resulting in widened splitting of S2. Inspiration increases blood flow to the right side of the heart, causing increased intensity of

1
2
3
4
5
6
7
8
9
10
11
12
13
14
15
16
17
18
19
20
21
22
23
24
25
26
27
28
29

*Widened splitting is fixed throughout respiratory cycle.

Exhibit Display

Cardiac murmurs*

Systolic	Aortic stenosis	S1 P2 A2 S1	Crescendo-decrescendo at RUSB, A2 soft & delayed
	Mitral regurgitation	S1 S2 S1	Holosystolic at apex & radiates to axilla
	Hypertrophic cardiomyopathy	S1 S2 S1	Crescendo-decrescendo at mid-left sternal border
	Mitral valve prolapse	S1 Click S2 S1	Midsystolic click followed by late systolic murmur
	Atrial septal defect	S1 A2 P2 S1	Midsystolic with wide & fixed splitting of S2
	Ventricular septal defect	S1 S2 S1	Holsystolic at left sternal border
Diastolic	Aortic regurgitation	S1 S2 S1	Decrescendo at LUSB (valvular), RUSB (aortic root)
	Mitral stenosis	S1 S2 OS S1	Opening snap followed by middiastolic rumble with presystolic accentuation
Continuous	Patent ductus arteriosus	S1 S2 S1	Machine-like in interscapular region (posteriorly)

*Pulmonic and tricuspid valve murmurs are similar in character to their aortic and mitral valve counterparts but with different location of optimal auscultation. These murmurs can be further differentiated from their left-sided counterparts by an increase in intensity with inspiration.
LUSB = left upper sternal border; **RUSB** = right upper sternal border.

©UWorld

Zoom In Zoom Out Reset Add To New Card | Existing Card

pulmonic valve, resulting in widened splitting of S2. Inspiration increases blood flow to the right side of the heart, causing increased intensity of

1 2 3 4 5 6 7 8 9 10 11 12 13 14 15 16 17 18 19 20 21 22 23 24 25 26 27 28 29

*Widened splitting is fixed throughout respiratory cycle.

Exhibit Display

Cardiac murmurs*

Systolic	Aortic stenosis	S1 P2 A2 S1	Crescendo-decrescendo at RUSB, A2 soft & delayed
	Mitral regurgitation	S1 S2 S1	Holosystolic at apex & radiates to axilla
	Hypertrophic cardiomyopathy	S1 S2 S1	Crescendo-decrescendo at mid-left sternal border
	Mitral valve prolapse	S1 Click S2 S1	Midsystolic click followed by late systolic murmur
	Atrial septal defect	S1 A2 P2 S1	Midsystolic with wide & fixed splitting of S2
	Ventricular septal defect	S1 S2 S1	Holsystolic at left sternal border
Diastolic	Aortic regurgitation	S1 S2 S1	Decrescendo at LUSB (valvular), RUSB (aortic root)
	Mitral stenosis	S1 S2 OS S1	Opening snap followed by middiastolic rumble with presystolic accentuation
Continuous	Patent ductus arteriosus	S1 S2 S1	Machine-like in interscapular region (posteriorly)

*Pulmonic and tricuspid valve murmurs are similar in character to their aortic and mitral valve counterparts but with different location of optimal auscultation. These murmurs can be further differentiated from their left-sided counterparts by an increase in intensity with inspiration.
LUSB = left upper sternal border; **RUSB** = right upper sternal border.

Zoom In | Zoom Out | Reset | Add To New Card | Existing Card

pulmonic valve, resulting in widened splitting of S2. Inspiration increases blood flow to the right side of the heart, causing increased intensity of

1
2
3
4
5
6
7
8
9
10
11
12
13
14
15
16
17
18
19
20
21
22
23
24
25
26
27
28
29

The autopsy of a 78-year-old Caucasian male who died of esophageal cancer reveals a small heart without significant coronary artery atherosclerosis. Myocardial cells show prominent intracytoplasmic granules that are tinged yellowish-brown. Which of the following most likely accounts for the observed microscopic changes?

A. Iron overload
B. Tyrosine oxidation
C. Lipid peroxidation
D. Glucose polymerization
E. Protein accumulation
F. Exogenous pigment endocytosis

Submit

1
2
3
4
5
6
7
8
9
10
11
12
13
14
15
16
17
18
19
20
21
22
23
24
25
26
27
28
29

The autopsy of a 78-year-old Caucasian male who died of esophageal cancer reveals a small heart without significant coronary artery atherosclerosis. Myocardial cells show prominent intracytoplasmic granules that are tinged yellowish-brown. Which of the following most likely accounts for the observed microscopic changes?

A. Iron overload (24%)

B. Tyrosine oxidation (2%)

✓ C. Lipid peroxidation (51%)

D. Glucose polymerization (1%)

E. Protein accumulation (10%)

F. Exogenous pigment endocytosis (8%)

Omitted
Correct answer
C

51%
Answered correctly

02 secs
Time Spent

02/03/2020
Last Updated

Explanation

An insoluble pigment composed of lipid polymers and protein-complexed phospholipids, lipofuscin is considered a sign of "wear and tear" or aging. This yellow-brown, finely granular perinuclear pigment is the product of free radical injury and lipid peroxidation. It is commonly seen in the heart and liver of aging or cachectic, malnourished patients.

(Choice A) Iron overload results in the deposition of iron-containing brown pigmented granules called hemosiderin.

1
2
3
4
5
6
7
8
9
10
11
12
13
14
15
16
17
18
19
20
21
22
23
24
25
26
27
28
29

Omitted
Correct answer
C

51%
Answered correctly

02 secs
Time Spent

02/03/2020
Last Updated

Explanation

An insoluble pigment composed of lipid polymers and protein-complexed phospholipids, lipofuscin is considered a sign of "wear and tear" or aging. This yellow-brown, finely granular perinuclear pigment is the product of free radical injury and lipid peroxidation. It is commonly seen in the heart and liver of aging or cachectic, malnourished patients.

(Choice A) Iron overload results in the deposition of iron-containing brown pigmented granules called hemosiderin.

(Choice B) Melanin is an oxidation product of tyrosine metabolism and typically appears as dark brown to black pigmented granules.

(Choice D) Glycogen is a glucose polymerization product and typically appears as clear vacuoles within the cytoplasm.

(Choice E) Hyaline is a form of protein accumulation, typically appearing as a glassy, homogeneous pink deposit.

(Choice F) A common example of exogenous pigment endocytosis occurs when urban-residing individuals inhale carbon or coal dust that is taken up by macrophages within the lung parenchyma ("anthracosis").

Educational Objective:
Lipofuscin is the product of lipid peroxidation, accumulating in aging cells (especially in patients with malnutrition and cachexia).

Pathology	Cardiovascular System	Aging
Subject	System	Topic

Copyright © UWorld. All rights reserved.

1
2
3
4
5
6
7
8
9
10
11
12
13
14
15
16
17
18
19
20
21
22
23
24
25
26
27
28
29

A 16-year-old boy suddenly collapses while jogging and dies despite resuscitation efforts. He has no history of medical problems; however, his family history is significant for an uncle who died suddenly at age 20. Autopsy reveals significant left ventricular hypertrophy predominantly affecting the interventricular septum. There are no valvular abnormalities. Assuming the boy died of an inherited condition, which of the following proteins was most likely affected by the relevant mutation?

A. Beta-myosin heavy chain

B. Dystrophin

C. Fibrillin-1

D. IK membrane potassium channel

E. Transthyretin

Submit

1
2
3
4
5
6
7
8
9
10
11
12
13
14
15
16
17
18
19
20
21
22
23
24
25
26
27
28
29

A 16-year-old boy suddenly collapses while jogging and dies despite resuscitation efforts. He has no history of medical problems; however, his family history is significant for an uncle who died suddenly at age 20. Autopsy reveals significant left ventricular hypertrophy predominantly affecting the interventricular septum. There are no valvular abnormalities. Assuming the boy died of an inherited condition, which of the following proteins was most likely affected by the relevant mutation?

- ✓ A. Beta-myosin heavy chain (81%)
- B. Dystrophin (5%)
- C. Fibrillin-1 (6%)
- D. IK membrane potassium channel (2%)
- E. Transthyretin (4%)

Omitted
Correct answer
A

81%
Answered correctly

02 secs
Time Spent

03/10/2020
Last Updated

Explanation

This presentation - sudden cardiac death (SCD) in a young patient with a family history of SCD and autopsy findings of asymmetric septal hypertrophy - is suggestive of **hypertrophic cardiomyopathy** (HCM). HCM is an **autosomal dominant** genetic disorder of the cardiac myocytes caused by mutations in one of several **sarcomere genes** encoding the myocardial contractile proteins. Common mutations include single-point missense mutations in the genes for **beta-myosin heavy chain** and **myosin-binding protein C**.

(Choice B) Mutations in the dystrophin gene are responsible for X-linked familial dilated cardiomyopathy. Dystrophin mutations are also found in the common skeletal myopathies (Duchenne and Becker muscular dystrophy), which are both associated with cardiac involvement.

This presentation - sudden cardiac death (SCD) in a young patient with a family history of SCD and autopsy findings of asymmetric septal hypertrophy - is suggestive of **hypertrophic cardiomyopathy** (HCM). HCM is an **autosomal dominant** genetic disorder of the cardiac myocytes caused by mutations in one of several **sarcomere genes** encoding the myocardial contractile proteins. Common mutations include single-point missense mutations in the genes for **beta-myosin heavy chain** and **myosin-binding protein C**.

(Choice B) Mutations in the dystrophin gene are responsible for X-linked familial dilated cardiomyopathy. Dystrophin mutations are also found in the common skeletal myopathies (Duchenne and Becker muscular dystrophy), which are both associated with cardiac involvement.

(Choice C) Marfan syndrome is an autosomal dominant defect of the glycoprotein fibrillin-1 in the connective tissue that causes abnormalities in the skeleton (eg, disproportionately long extremities, pectus deformity, scoliosis), eyes (lens dislocation), and cardiovascular system (eg, aortic root dilation, aortic regurgitation).

(Choice D) Genetic mutations in cardiac K^+ channel proteins are seen in patients with congenital long QT syndrome (LQTS). A decrease in repolarizing potassium current leads to prolongation of the QT interval, which predisposes to development of polymorphic ventricular tachycardia (torsades de pointes) and sudden cardiac death. However, septal hypertrophy is not a feature of congenital LQTS.

(Choice E) Mutations in the transthyretin gene are responsible for a hereditary form of cardiac amyloidosis. Amyloid deposition in the myocardium results in infiltrative cardiomyopathy, which typically presents in adults with progressive dyspnea, peripheral edema, and ascites.

Educational objective:
Hypertrophic cardiomyopathy is characterized by asymmetric (eg, septal) left ventricular hypertrophy that can result in sudden cardiac death. Autosomal dominant mutations affecting the cardiac sarcomere genes (eg, cardiac beta-myosin heavy chain gene and myosin-binding protein C gene) are responsible for the majority of cases.

References

- The molecular genetic basis for hypertrophic cardiomyopathy.
- Genetics of hypertrophic cardiomyopathy after 20 years: clinical perspectives.

Pathology	Cardiovascular System	Hypertrophic cardiomyopathy
Subject	System	Topic

1
2
3
4
5
6
7
8
9
10
11
12
13
14
15
16
17
18
19
20
21
22
23
24
25
26
27
28
29

A 35-year-old man is evaluated for progressive fatigue and shortness of breath. Recently, he has noticed bilateral leg swelling and abdominal distension despite overall weight loss. He does not use tobacco, alcohol, or illicit drugs. Despite treatment, the patient dies several weeks later. Autopsy reveals significant endocardial thickening with dense fibrous deposits around the tricuspid and pulmonary valves as well as moderate pulmonary valve stenosis. The left-sided cardiac chambers and valves are normal. Measuring the levels of which of the following substances would have helped in diagnosing this patient?

A. Plasma cortisol
B. Plasma homocysteine
C. Plasma phenylalanine
D. Urinary 5-hydroxyindoleacetic acid
E. Urinary porphobilinogen
F. Urinary vanillylmandelic acid

Submit

1
2
3
4
5
6
7
8
9
10
11
12
13
14
15
16
17
18
19
20
21
22
23
24
25
26
27
28
29

A 35-year-old man is evaluated for progressive fatigue and shortness of breath. Recently, he has noticed bilateral leg swelling and abdominal distension despite overall weight loss. He does not use tobacco, alcohol, or illicit drugs. Despite treatment, the patient dies several weeks later. Autopsy reveals significant endocardial thickening with dense fibrous deposits around the tricuspid and pulmonary valves as well as moderate pulmonary valve stenosis. The left-sided cardiac chambers and valves are normal. Measuring the levels of which of the following substances would have helped in diagnosing this patient?

A. Plasma cortisol
B. Plasma homocysteine
C. Plasma phenylalanine
D. Urinary 5-hydroxyindoleacetic acid
E. Urinary porphobilinogen
F. Urinary vanillylmandelic acid

Submit

1
2
3
4
5
6
7
8
9
10
11
12
13
14
15
16
17
18
19
20
21
22
23
24
25
26
27
28
29

A 35-year-old man is evaluated for progressive fatigue and shortness of breath. Recently, he has noticed bilateral leg swelling and abdominal distension despite overall weight loss. He does not use tobacco, alcohol, or illicit drugs. Despite treatment, the patient dies several weeks later. Autopsy reveals significant endocardial thickening with dense fibrous deposits around the tricuspid and pulmonary valves as well as moderate pulmonary valve stenosis. The left-sided cardiac chambers and valves are normal. Measuring the levels of which of the following substances would have helped in diagnosing this patient?

- A. Plasma cortisol (6%)
- B. Plasma homocysteine (17%)
- C. Plasma phenylalanine (2%)
- ✓ D. Urinary 5-hydroxyindoleacetic acid (57%)
- E. Urinary porphobilinogen (6%)
- F. Urinary vanillylmandelic acid (9%)

Omitted
Correct answer
D

57%
Answered correctly

03 secs
Time Spent

03/15/2020
Last Updated

Explanation

Features of carcinoid syndrome	
	• Skin: **Flushing**, telangiectasias, cyanosis

Features of carcinoid syndrome	
Clinical manifestations	• Skin: **Flushing**, telangiectasias, cyanosis • Gastrointestinal: **Watery diarrhea**, cramping • Pulmonary: **Bronchospasm**, dyspnea, wheezing • Cardiac: Valvular fibrous plaques (right > left)
Diagnosis	• Elevated 24-hour urinary excretion of **5-HIAA** • CT/MRI of abdomen & pelvis to localize tumor
Treatment	• Octreotide for symptomatic patients • Surgery for liver metastases

5-HIAA = 5-hydroxyindoleacetic acid.

©UWorld

The autopsy findings - endocardial thickening and fibrosis of tricuspid and pulmonary valves - are characteristic of **carcinoid heart disease**. Carcinoids are well-differentiated neuroendocrine tumors found most commonly in the distal small intestine and proximal colon, with a strong propensity for metastasis to the liver. These tumors secrete several products (including histamine, serotonin, and vasoactive intestinal peptide) that are metabolized in the liver. In patients with liver metastasis, these hormones are released directly into the systemic circulation, leading to carcinoid syndrome.

Carcinoid heart disease is caused by excessive secretion of **serotonin**, which stimulates fibroblast growth and fibrogenesis. Pathognomonic plaque-like **deposits of fibrous tissue** occur most commonly on the **endocardium**, leading to **tricuspid regurgitation**, pulmonic valvulopathy, and right-sided heart failure (eg, ascites, peripheral edema). Endocardial fibrosis and thickening are generally limited to the right heart as vasoactive products are inactivated distally by pulmonary vascular endothelial monoamine oxidase.

5-hydroxyindoleacetic acid (5-HIAA) is an end product of serotonin metabolism, and elevated 24-hour urinary 5-HIAA levels are helpful in diagnosing suspected carcinoid syndrome.

1
2
3
4
5
6
7
8
9
10
11
12
13
14
15
16
17
18
19
20
21
22
23
24
25
26
27
28
29

The autopsy findings - endocardial thickening and fibrosis of tricuspid and pulmonary valves - are characteristic of **carcinoid heart disease**. Carcinoids are well-differentiated neuroendocrine tumors found most commonly in the distal small intestine and proximal colon, with a strong propensity for metastasis to the liver. These tumors secrete several products (including histamine, serotonin, and vasoactive intestinal peptide) that are metabolized in the liver. In patients with liver metastasis, these hormones are released directly into the systemic circulation, leading to carcinoid syndrome.

Carcinoid heart disease is caused by excessive secretion of **serotonin**, which stimulates fibroblast growth and fibrogenesis. Pathognomonic plaque-like **deposits of fibrous tissue** occur most commonly on the **endocardium**, leading to **tricuspid regurgitation**, pulmonic valvulopathy, and right-sided heart failure (eg, ascites, peripheral edema). Endocardial fibrosis and thickening are generally limited to the right heart as vasoactive products are inactivated distally by pulmonary vascular endothelial monoamine oxidase.

5-hydroxyindoleacetic acid (5-HIAA) is an end product of serotonin metabolism, and elevated 24-hour urinary 5-HIAA levels are helpful in diagnosing suspected carcinoid syndrome.

(Choice A) Measurement of plasma cortisol levels is used for diagnosing adrenal insufficiency and Cushing syndrome.

(Choice B) Inherited or acquired elevation of plasma homocysteine levels may contribute to arterial and venous thrombosis and to the development of atherosclerosis.

(Choice C) Plasma phenylalanine may be elevated in patients with phenylalanine hydroxylase deficiency (phenylketonuria), resulting in central nervous system damage/intellectual disability.

(Choice E) Urinary porphobilinogen may be elevated in the porphyrias, which are caused by deficiencies of the heme synthesis enzymes. The porphyrias may produce cutaneous lesions, skin photosensitivity, or attacks of abdominal pain and neurological disturbances (acute intermittent porphyria).

(Choice F) Vanillylmandelic acid is a byproduct of norepinephrine and epinephrine, and can be used to detect neuroblastoma and other tumors of neural crest origin.

Educational objective:
Carcinoid syndrome typically presents with episodic flushing, secretory diarrhea, and wheezing. It can lead to pathognomonic plaque-like deposits of fibrous tissue on the right-sided endocardium, causing tricuspid regurgitation and right-sided heart failure. Elevated 24-hour urinary 5-hydroxyindoleacetic acid can confirm the diagnosis.

vasoactive products are inactivated distally by pulmonary vascular endothelial monoamine oxidase.

5-hydroxyindoleacetic acid (5-HIAA) is an end product of serotonin metabolism, and elevated 24-hour urinary 5-HIAA levels are helpful in diagnosing suspected carcinoid syndrome.

(Choice A) Measurement of plasma cortisol levels is used for diagnosing adrenal insufficiency and Cushing syndrome.

(Choice B) Inherited or acquired elevation of plasma homocysteine levels may contribute to arterial and venous thrombosis and to the development of atherosclerosis.

(Choice C) Plasma phenylalanine may be elevated in patients with phenylalanine hydroxylase deficiency (phenylketonuria), resulting in central nervous system damage/intellectual disability.

(Choice E) Urinary porphobilinogen may be elevated in the porphyrias, which are caused by deficiencies of the heme synthesis enzymes. The porphyrias may produce cutaneous lesions, skin photosensitivity, or attacks of abdominal pain and neurological disturbances (acute intermittent porphyria).

(Choice F) Vanillylmandelic acid is a byproduct of norepinephrine and epinephrine, and can be used to detect neuroblastoma and other tumors of neural crest origin.

Educational objective:
Carcinoid syndrome typically presents with episodic flushing, secretory diarrhea, and wheezing. It can lead to pathognomonic plaque-like deposits of fibrous tissue on the right-sided endocardium, causing tricuspid regurgitation and right-sided heart failure. Elevated 24-hour urinary 5-hydroxyindoleacetic acid can confirm the diagnosis.

References

- Prediction of prognosis by echocardiography in patients with midgut carcinoid syndrome.

Pathology	Cardiovascular System	Carcinoid tumors
Subject	System	Topic

Copyright © UWorld. All rights reserved.

1
2
3
4
5
6
7
8
9
10
11
12
13
14
15
16
17
18
19
20
21
22
23
24
25
26
27
28
29

A 36-year-old woman is brought to the emergency department with sudden-onset right side weakness and speech difficulty. During the last 3 weeks, the patient has experienced progressive fatigue, malaise, and low-grade fevers. Despite the symptoms, she did not seek medical attention and did not take any medications. She had a dental extraction 5 weeks ago, which was uncomplicated. The patient has never previously been significantly ill or hospitalized. She works as a receptionist at a legal firm and has never traveled outside the United States. She does not use tobacco, alcohol, or illicit drugs. The patient is admitted to the hospital, but despite adequate resuscitative measures, she dies 2 hours later. Gross autopsy shows large, friable irregular masses attached to the atrial surface of a valve. Which of the following underlying conditions most likely predisposed this patient to developing these cardiac changes?

A. Atrial septal defect

B. Coronary artery disease

C. Hypertrophic cardiomyopathy

D. Mitral annular calcification

E. Regurgitant mitral valve prolapse

Submit

1
2
3
4
5
6
7
8
9
10
11
12
13
14
15
16
17
18
19
20
21
22
23
24
25
26
27
28
29

A 36-year-old woman is brought to the emergency department with sudden-onset right side weakness and speech difficulty. During the last 3 weeks, the patient has experienced progressive fatigue, malaise, and low-grade fevers. Despite the symptoms, she did not seek medical attention and did not take any medications. She had a dental extraction 5 weeks ago, which was uncomplicated. The patient has never previously been significantly ill or hospitalized. She works as a receptionist at a legal firm and has never traveled outside the United States. She does not use tobacco, alcohol, or illicit drugs. The patient is admitted to the hospital, but despite adequate resuscitative measures, she dies 2 hours later. Gross autopsy shows large, friable irregular masses attached to the atrial surface of a valve. Which of the following underlying conditions most likely predisposed this patient to developing these cardiac changes?

- A. Atrial septal defect (9%)
- B. Coronary artery disease (0%)
- C. Hypertrophic cardiomyopathy (0%)
- D. Mitral annular calcification (29%)
- ✓ E. Regurgitant mitral valve prolapse (58%)

Omitted
Correct answer
E

58%
Answered correctly

01 sec
Time Spent

04/14/2020
Last Updated

Explanation

This patient had **subacute infective endocarditis (IE)** complicated by an **embolic stroke**. The large, friable irregular masses seen on autopsy are most likely vegetations and are the most probable source of this patient's left middle cerebral artery embolus (eg, right-sided weakness, speech difficulty).

This patient had **subacute infective endocarditis (IE)** complicated by an **embolic stroke**. The large, friable irregular masses seen on autopsy are most likely vegetations and are the most probable source of this patient's left middle cerebral artery embolus (eg, right-sided weakness, speech difficulty).

The mitral valve is the valve most frequently affected by IE. **Mitral valve prolapse (MVP)** is the most common underlying valvular disease predisposing to the development of IE in **developed countries**, particularly when it is associated with coexistent **mitral regurgitation**. Microscopic deposits of platelets and fibrin occur spontaneously in individuals with valvular disease secondary to endocardial injury from turbulent blood flow. These deposits then become colonized by microorganisms (eg, viridans streptococci) during episodes of bacteremia (eg, following dental extraction).

In **developing countries**, the most common acquired heart disease leading to IE development is **rheumatic heart disease** (RHD). RHD is a late (10-20 years) complication of acute rheumatic fever (eg, migratory arthritis, carditis/valvulitis, erythema marginatum). RHD was historically considered a frequent predisposing factor for IE; however, MVP, valvular sclerosis, and mechanical valves are now more common causes in developed nations due to the recognition and treatment of group A streptococcal pharyngitis.

(Choice A) Congenital heart lesions that predispose to increased risk of IE include bicuspid aortic valve, ventricular septal defects, patent ductus arteriosus, and unrepaired tetralogy of Fallot. Isolated atrial septal defects are not commonly associated with an increased risk of IE, likely due to the low-pressure differential between the atria and the absence of high-velocity intracardiac flow jets that can damage the endocardium.

(Choice B) Coronary heart disease can cause ischemic papillary muscle dysfunction with resultant mitral regurgitation. However, the clinical presentation and autopsy findings in this patient are most consistent with MVP and IE.

(Choice C) IE is a rare complication of hypertrophic cardiomyopathy and is almost always seen in patients with outflow obstruction. Hypertrophic cardiomyopathy is characterized by asymmetric ventricular hypertrophy leading to reduced left ventricular cavity size.

(Choice D) Mitral annular calcification refers to degeneration and progressive calcium deposition involving the fibrous annulus of the mitral valve. Mitral annular calcification is usually seen in older adults (age >60), and the annulus is not a common location for IE.

Educational objective:
Mitral valve prolapse with regurgitation is the most common predisposing condition for native valve infective endocarditis (IE) in developed nations. Rheumatic heart disease remains a frequent cause of IE in developing nations.

blood flow. These deposits then become colonized by microorganisms (eg, viridans streptococci) during episodes of bacteremia (eg, following dental extraction).

In **developing countries**, the most common acquired heart disease leading to IE development is **rheumatic heart disease** (RHD). RHD is a late (10-20 years) complication of acute rheumatic fever (eg, migratory arthritis, carditis/valvulitis, erythema marginatum). RHD was historically considered a frequent predisposing factor for IE; however, MVP, valvular sclerosis, and mechanical valves are now more common causes in developed nations due to the recognition and treatment of group A streptococcal pharyngitis.

(Choice A) Congenital heart lesions that predispose to increased risk of IE include bicuspid aortic valve, ventricular septal defects, patent ductus arteriosus, and unrepaired tetralogy of Fallot. Isolated atrial septal defects are not commonly associated with an increased risk of IE, likely due to the low-pressure differential between the atria and the absence of high-velocity intracardiac flow jets that can damage the endocardium.

(Choice B) Coronary heart disease can cause ischemic papillary muscle dysfunction with resultant mitral regurgitation. However, the clinical presentation and autopsy findings in this patient are most consistent with MVP and IE.

(Choice C) IE is a rare complication of hypertrophic cardiomyopathy and is almost always seen in patients with outflow obstruction. Hypertrophic cardiomyopathy is characterized by asymmetric ventricular hypertrophy leading to reduced left ventricular cavity size.

(Choice D) Mitral annular calcification refers to degeneration and progressive calcium deposition involving the fibrous annulus of the mitral valve. Mitral annular calcification is usually seen in older adults (age >60), and the annulus is not a common location for IE.

Educational objective:
Mitral valve prolapse with regurgitation is the most common predisposing condition for native valve infective endocarditis (IE) in developed nations. Rheumatic heart disease remains a frequent cause of IE in developing nations.

References

- Incidence and predictors of infective endocarditis in mitral valve prolapse: a population-based study.
- The worldwide epidemiology of acute rheumatic fever and rheumatic heart disease.

Pathology	Cardiovascular System	Endocarditis
Subject	System	Topic

blood flow. These deposits then become colonized by microorganisms (eg, viridans streptococci) during episodes of bacteremia (eg, following

Exhibit Display

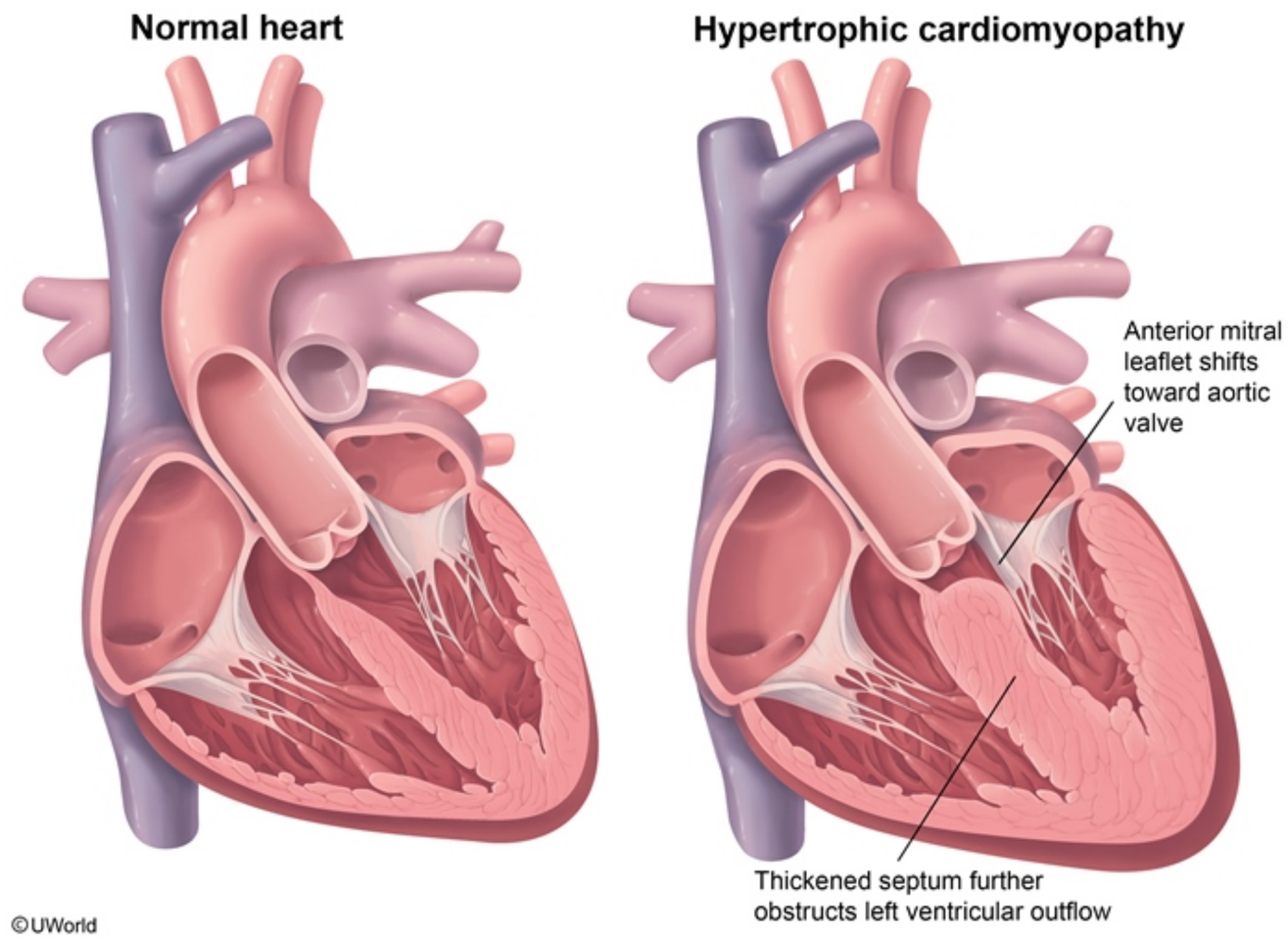

Zoom In | Zoom Out | Reset | Add To New Card | Existing Card

1 2 3 4 5 6 7 8 9 10 11 12 13 14 15 16 17 18 19 20 21 22 23 24 25 26 27 28 29

1
2
3
4
5
6
7
8
9
10
11
12
13
14
15
16
17
18
19
20
21
22
23
24
25
26
27
28
29

A 56-year-old man comes to the emergency department with acute, severe chest pain. His electrocardiogram is within normal limits. Contrast-enhanced computed tomography of his chest is shown below.

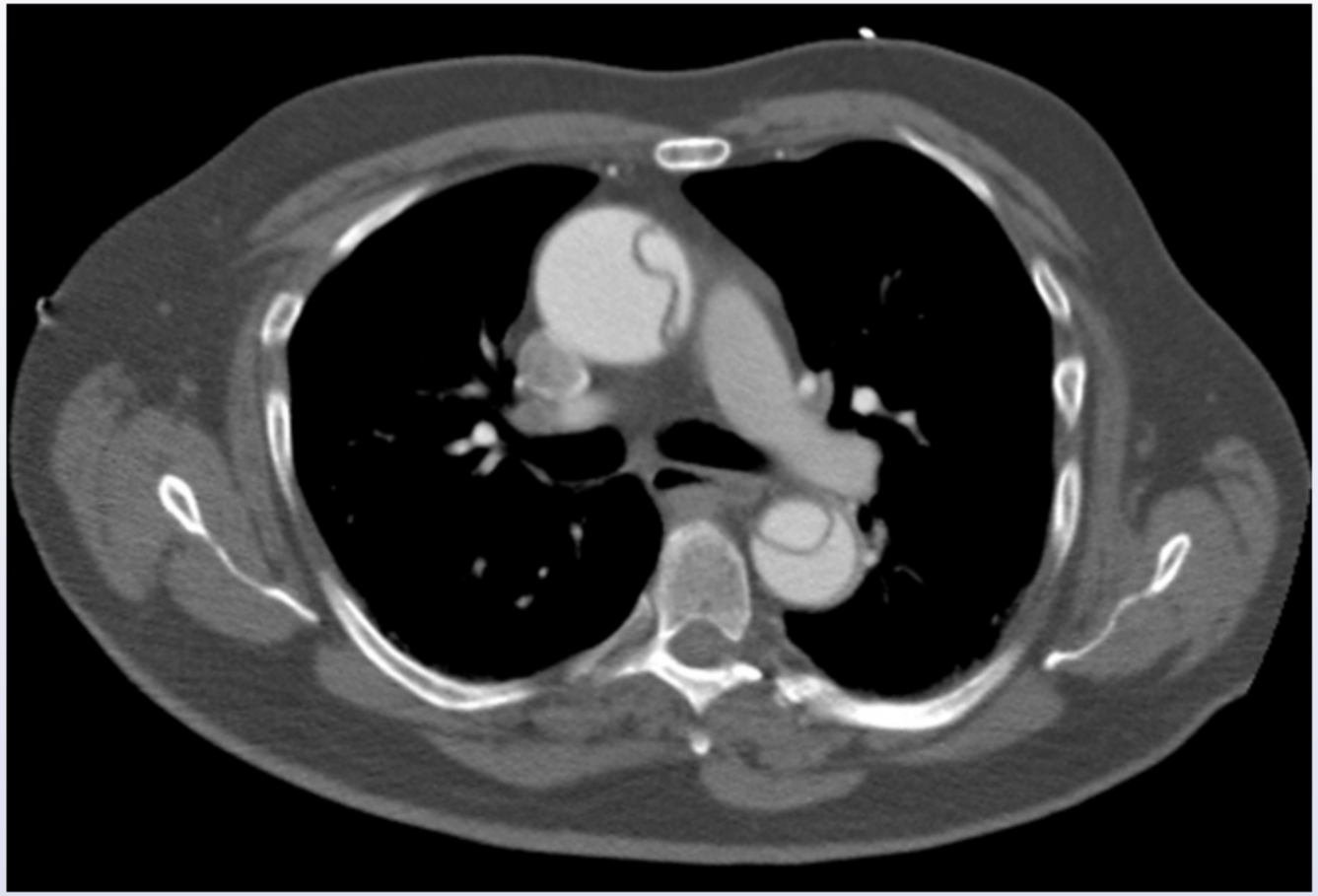

Which of the following is the single most important risk factor for this patient's current condition?

A. Diabetes mellitus

1
2
3
4
5
6
7
8
9
10
11
12
13
14
15
16
17
18
19
20
21
22
23
24
25
26
27
28
29

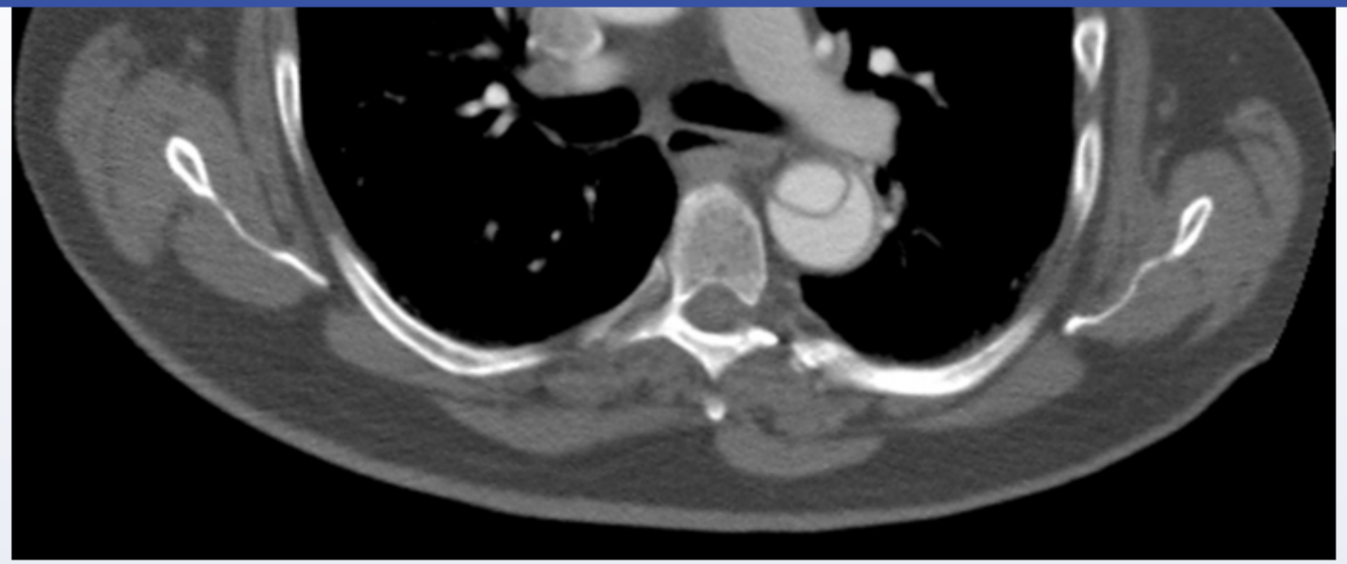

Which of the following is the single most important risk factor for this patient's current condition?

A. Diabetes mellitus

B. High cholesterol

C. Hypertension

D. Limited physical activity

E. Smoking

F. Spirochete infection

Submit

1
2
3
4
5
6
7
8
9
10
11
12
13
14
15
16
17
18
19
20
21
22
23
24
25
26
27
28
29

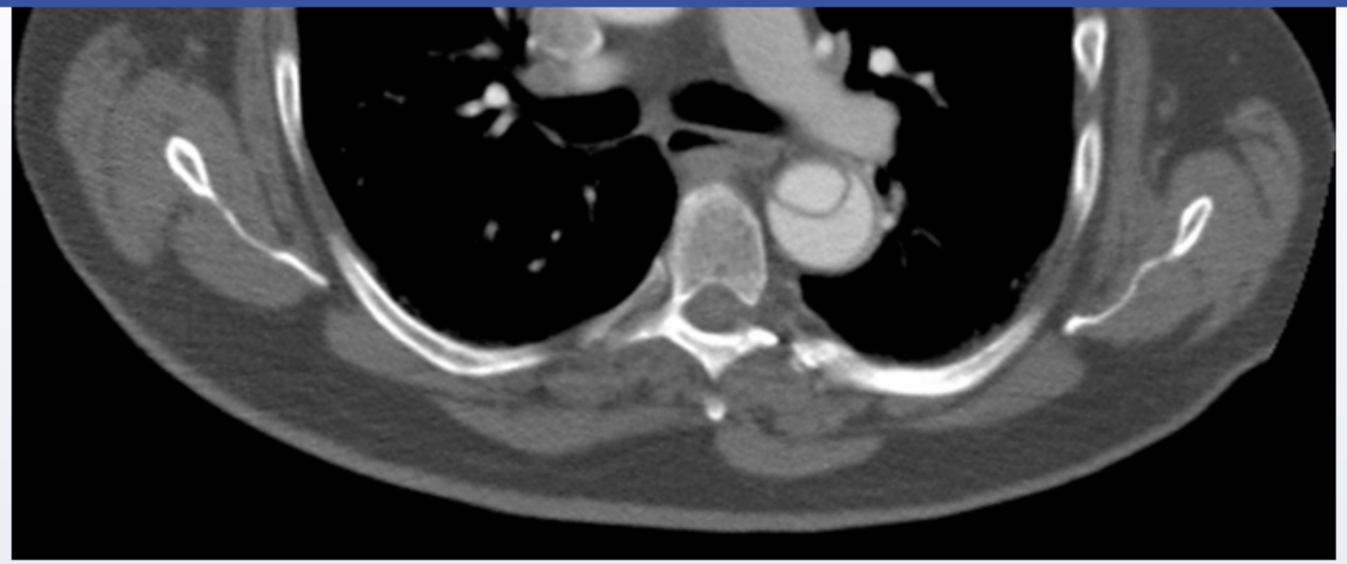

Which of the following is the single most important risk factor for this patient's current condition?

- A. Diabetes mellitus (1%)
- B. High cholesterol (6%)
- ✓ C. Hypertension (64%)
- D. Limited physical activity (2%)
- E. Smoking (15%)
- F. Spirochete infection (9%)

Omitted
Correct answer

64%
Answered correctly

07 secs
Time Spent

04/05/2020
Last Updated

1
2
3
4
5
6
7
8
9
10
11
12
13
14
15
16
17
18
19
20
21
22
23
24
25
26
27
28
29

Aortic dissection

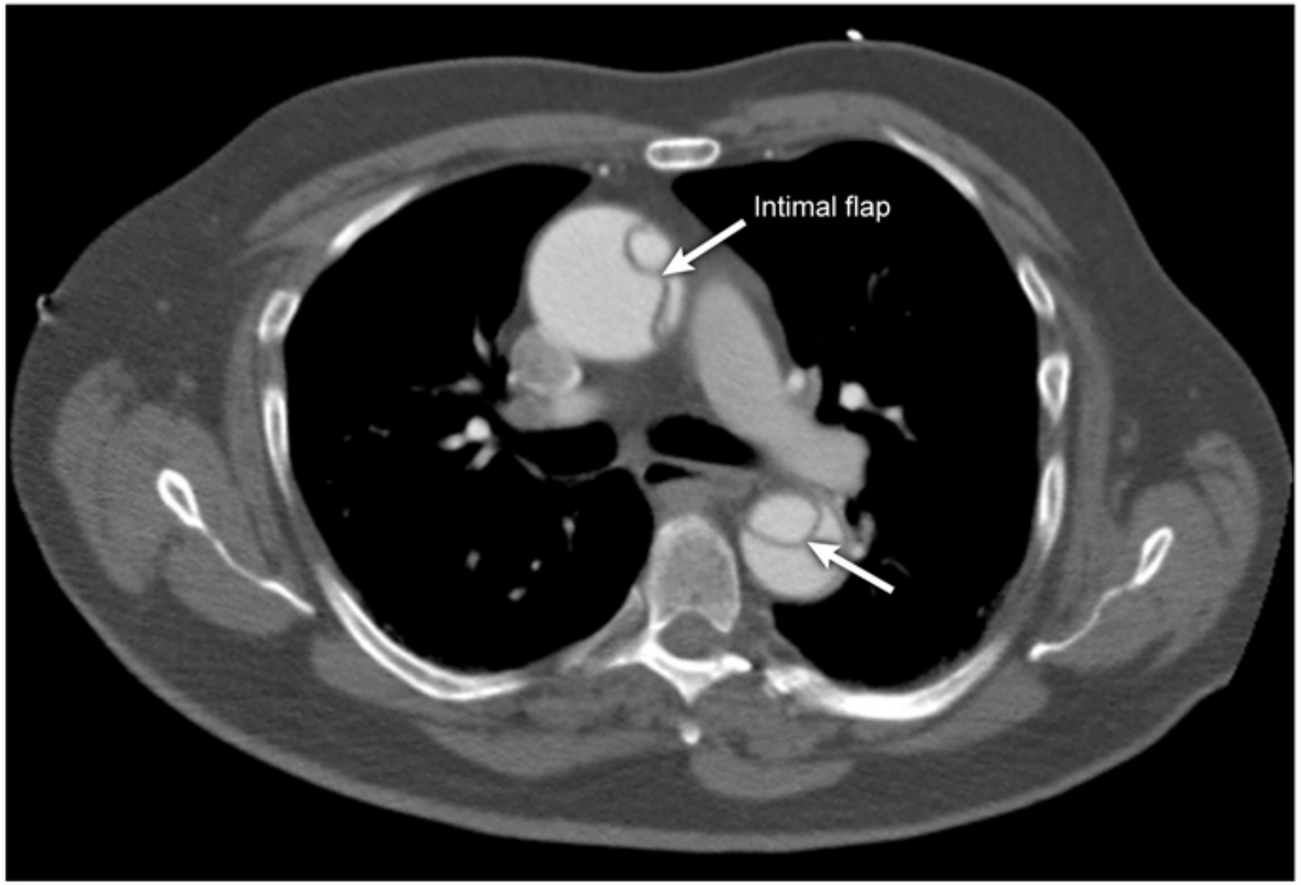

©UWorld

This patient's chest CT scan reveals a widened, ascending thoracic aorta with a nonenhancing septum dividing the lumen of the ascending and descending aorta. The "septum" is actually the tunica intima of the aorta, which has been torn from the remainder of the aortic wall. A tear in the tunica intima is thought to be the primary event in the process leading to aortic dissection. As more and more blood is forced through the tear, an intramural hematoma begins to develop between the intimal flap and medial wall, creating a false lumen. The dissection can extend both proximally toward the heart and distally, sometimes extending all the way to the iliac and femoral arteries. **Hypertension** is the single most

This patient's chest CT scan reveals a widened, ascending thoracic aorta with a nonenhancing septum dividing the lumen of the ascending and descending aorta. The "septum" is actually the tunica intima of the aorta, which has been torn from the remainder of the aortic wall. A tear in the tunica intima is thought to be the primary event in the process leading to aortic dissection. As more and more blood is forced through the tear, an intramural hematoma begins to develop between the intimal flap and medial wall, creating a false lumen. The dissection can extend both proximally toward the heart and distally, sometimes extending all the way to the iliac and femoral arteries. **Hypertension** is the single most important risk factor for the development of intimal tears leading to **aortic dissection.** Cystic medial degeneration, which may be seen in connective tissue diseases such as Marfan syndrome, also predisposes patients (especially younger ones) to aortic dissection.

(Choice A) Diabetes mellitus is an important risk factor for the development of atherosclerosis and hypertension. It can increase the relative risk of aortic dissection by promoting hypertension, which is the single most important risk factor for aortic dissection.

(Choice B) High cholesterol is a risk factor for atherosclerosis. Atherosclerosis predisposes more to **aortic aneurysm** formation (especially abdominal aortic aneurysms) than to aortic dissection.

(Choice D) A sedentary lifestyle is a risk factor for cardiovascular disease (eg, stroke, myocardial infarction) but does not appear to be directly linked to aortic dissection.

(Choice E) Smoking contributes significantly to the risk of atherosclerosis and thromboangiitis obliterans (Buerger disease). Thromboangiitis obliterans is a vasculitis of medium and small arteries, principally the tibial and radial arteries.

(Choice F) Tertiary syphilis can result in spirochetal endarteritis that affects the vasa vasorum within the adventitia of the ascending thoracic aorta. This weakens the aortic wall and predisposes infected patients to ascending aortic aneurysms. Aortic dissection is only rarely caused by syphilitic aneurysms.

Educational objective:
Hypertension is the single most important risk factor for the development of intimal tears leading to aortic dissection. Hypertension, smoking, diabetes mellitus, and hypercholesterolemia are all major risk factors for atherosclerosis, which predisposes more to aortic aneurysm formation than aortic dissection.

Pathology	Cardiovascular System	Aortic dissection
Subject	System	Topic

tunica intima is thought to be the primary event in the process leading to aortic dissection. As more and more blood is forced through the tear, an intramural hematoma begins to develop between the intimal flap and medial wall, creating a false lumen. The dissection can extend both proximally toward the heart and distally, sometimes extending all the way to the iliac and femoral arteries. **Hypertension** is the single most important risk factor for the development of intimal tears leading to **aortic dissection.** Cystic medial degeneration, which may be seen in connective tissue diseases such as Marfan syndrome, also predisposes patients (especially younger ones) to aortic dissection.

(Choice A) Diabetes mellitus is an important risk factor for the development of atherosclerosis and hypertension. It can increase the relative risk of aortic dissection by promoting hypertension, which is the single most important risk factor for aortic dissection.

(Choice B) High cholesterol is a risk factor for atherosclerosis. Atherosclerosis predisposes more to **aortic aneurysm** formation (especially abdominal aortic aneurysms) than to aortic dissection.

(Choice D) A sedentary lifestyle is a risk factor for cardiovascular disease (eg, stroke, myocardial infarction) but does not appear to be directly linked to aortic dissection.

(Choice E) Smoking contributes significantly to the risk of atherosclerosis and thromboangiitis obliterans (Buerger disease). Thromboangiitis obliterans is a vasculitis of medium and small arteries, principally the tibial and radial arteries.

(Choice F) Tertiary syphilis can result in spirochetal endarteritis that affects the vasa vasorum within the adventitia of the ascending thoracic aorta. This weakens the aortic wall and predisposes infected patients to ascending aortic aneurysms. Aortic dissection is only rarely caused by syphilitic aneurysms.

Educational objective:
Hypertension is the single most important risk factor for the development of intimal tears leading to aortic dissection. Hypertension, smoking, diabetes mellitus, and hypercholesterolemia are all major risk factors for atherosclerosis, which predisposes more to aortic aneurysm formation than aortic dissection.

Pathology	Cardiovascular System	Aortic dissection
Subject	System	Topic

Copyright © UWorld. All rights reserved.

1
2
3
4
5
6
7
8
9
10
11
12
13
14
15
16
17
18
19
20
21
22
23
24
25
26
27
28
29

A 10-year-old boy is brought to the physician by his parents due to restlessness and involuntary jerking. He takes no medications and his vaccinations are up-to-date. His parents do not recall any recent injuries or illnesses other than a sore throat 3 months ago. On examination, the patient has rapid, irregular jerking movements involving his face, arms, and legs. This patient is at greatest risk for developing which of the following conditions?

A. Deforming polyarthritis

B. Early dementia

C. Parkinson disease

D. Renal failure

E. Valvular heart disease

Submit

1
2
3
4
5
6
7
8
9
10
11
12
13
14
15
16
17
18
19
20
21
22
23
24
25
26
27
28
29

A 10-year-old boy is brought to the physician by his parents due to restlessness and involuntary jerking. He takes no medications and his vaccinations are up-to-date. His parents do not recall any recent injuries or illnesses other than a sore throat 3 months ago. On examination, the patient has rapid, irregular jerking movements involving his face, arms, and legs. This patient is at greatest risk for developing which of the following conditions?

A. Deforming polyarthritis (4%)
B. Early dementia (9%)
C. Parkinson disease (3%)
D. Renal failure (8%)
✓ E. Valvular heart disease (75%)

Omitted
Correct answer
E

75%
Answered correctly

02 secs
Time Spent

06/27/2020
Last Updated

Explanation

Acute rheumatic fever	
Epidemiology	• Endemic in developing countries
Pathogenesis	• Occurs 2-4 weeks after acute group A streptococcal pharyngitis • Molecular mimicry: Anti-streptococcal antibodies attack cardiac & neuronal antigens

Acute rheumatic fever	
Epidemiology	• Endemic in developing countries
Pathogenesis	• Occurs 2-4 weeks after acute group A streptococcal pharyngitis • Molecular mimicry: Anti-streptococcal antibodies attack cardiac & neuronal antigens

Clinical features	• Acute/subacute
	  ◦ Migratory arthritis
	  ◦ Pancarditis (mitral regurgitation)
	  ◦ Sydenham chorea
	• Chronic
	  ◦ Mitral stenosis

Prevention	• Prompt treatment of streptococcal pharyngitis with penicillin

This patient's **restlessness and purposeless jerking movements** 3 months after having a **sore throat** are consistent with **Sydenham chorea**, a hyperkinetic extrapyramidal movement disorder that is the most common acquired chorea of childhood. Sydenham chorea is a neurologic manifestation of **acute rheumatic fever** that occurs 1-8 months after group A β-hemolytic streptococcal infection. It is caused by a delayed onset autoimmune reaction involving anti-streptococcal antibodies that cross-react with the **basal ganglia**. Because Sydenham chorea is a manifestation of acute rheumatic fever, patients with this disorder are at risk for **chronic rheumatic heart disease**.

(Choice A) Although migratory polyarthritis is an early manifestation of acute rheumatic fever, it is generally transient and rarely, if ever, deforming.

(Choice B) Early-onset Alzheimer dementia is associated with Down syndrome (trisomy 21). Increased expression of the amyloid precursor protein gene located on chromosome 21 is thought to be the cause.

(Choice C) Parkinson disease is an extrapyramidal hypokinetic movement disorder consisting of tremor, rigidity, akinesia, and postural instability. Jerking extremity movements are generally not seen in Parkinson disease, except in cases of levodopa overdose.

This patient's **restlessness and purposeless jerking movements** 3 months after having a **sore throat** are consistent with **Sydenham chorea**, a hyperkinetic extrapyramidal movement disorder that is the most common acquired chorea of childhood. Sydenham chorea is a neurologic manifestation of **acute rheumatic fever** that occurs 1-8 months after group A β-hemolytic streptococcal infection. It is caused by a delayed onset autoimmune reaction involving anti-streptococcal antibodies that cross-react with the **basal ganglia**. Because Sydenham chorea is a manifestation of acute rheumatic fever, patients with this disorder are at risk for **chronic rheumatic heart disease**.

(Choice A) Although migratory polyarthritis is an early manifestation of acute rheumatic fever, it is generally transient and rarely, if ever, deforming.

(Choice B) Early-onset Alzheimer dementia is associated with Down syndrome (trisomy 21). Increased expression of the amyloid precursor protein gene located on chromosome 21 is thought to be the cause.

(Choice C) Parkinson disease is an extrapyramidal hypokinetic movement disorder consisting of tremor, rigidity, akinesia, and postural instability. Jerking extremity movements are generally not seen in Parkinson disease, except in cases of levodopa overdose.

(Choice D) Poststreptococcal glomerulonephritis occurs following infection with specific nephritogenic strains of group A *Streptococcus*. However, the nephritis manifests within 1-6 weeks and is typically self-limited. Renal failure is not part of the clinical syndrome associated with acute rheumatic fever.

Educational objective:
Sydenham chorea presents with involuntary, rapid, irregular jerking movements involving the face, arms, and legs. It occurs months after group A streptococcal infection and is one of the major clinical manifestations of acute rheumatic fever. Patients with this condition carry a high risk of chronic valvular disease.

References

- Diagnostic criteria of acute rheumatic fever.

Pathology	Cardiovascular System	Rheumatic fever
Subject	System	Topic

Copyright © UWorld. All rights reserved.

1
2
3
4
5
6
7
8
9
10
11
12
13
14
15
16
17
18
19
20
21
22
23
24
25
26
27
28
29

A 38-year-old man dies suddenly at his workplace and cannot be resuscitated. He had experienced chest discomfort, shortness of breath, and fatigue in the week preceding the event. The man was overweight but otherwise had no significant medical history. He had no established primary care physician. He did not use alcohol, tobacco, or illicit drugs. Both parents are alive and healthy; a maternal uncle reportedly died of a heart attack at age 50. Autopsy was performed and myocardial findings are shown in the slide below.

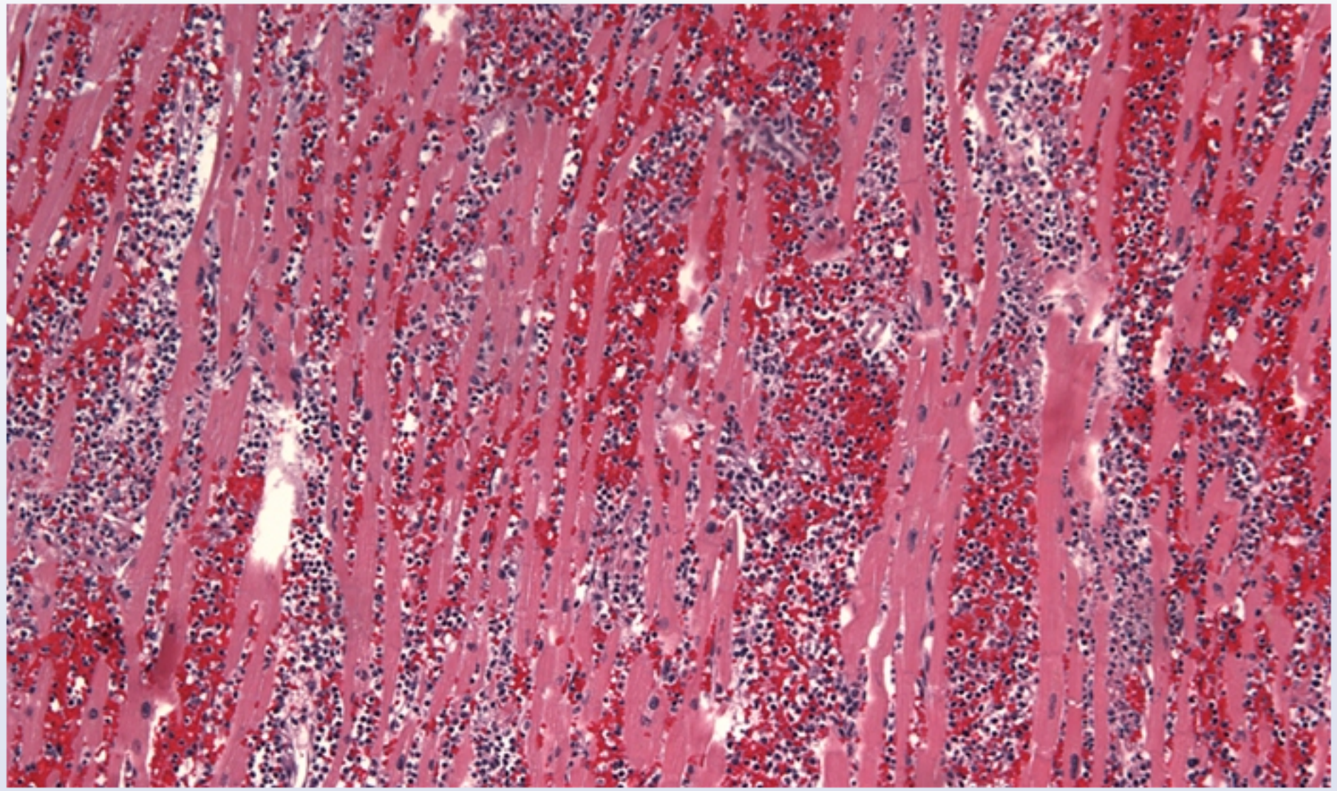

1
2
3
4
5
6
7
8
9
10
11
12
13
14
15
16
17
18
19
20
21
22
23
24
25
26
27
28
29

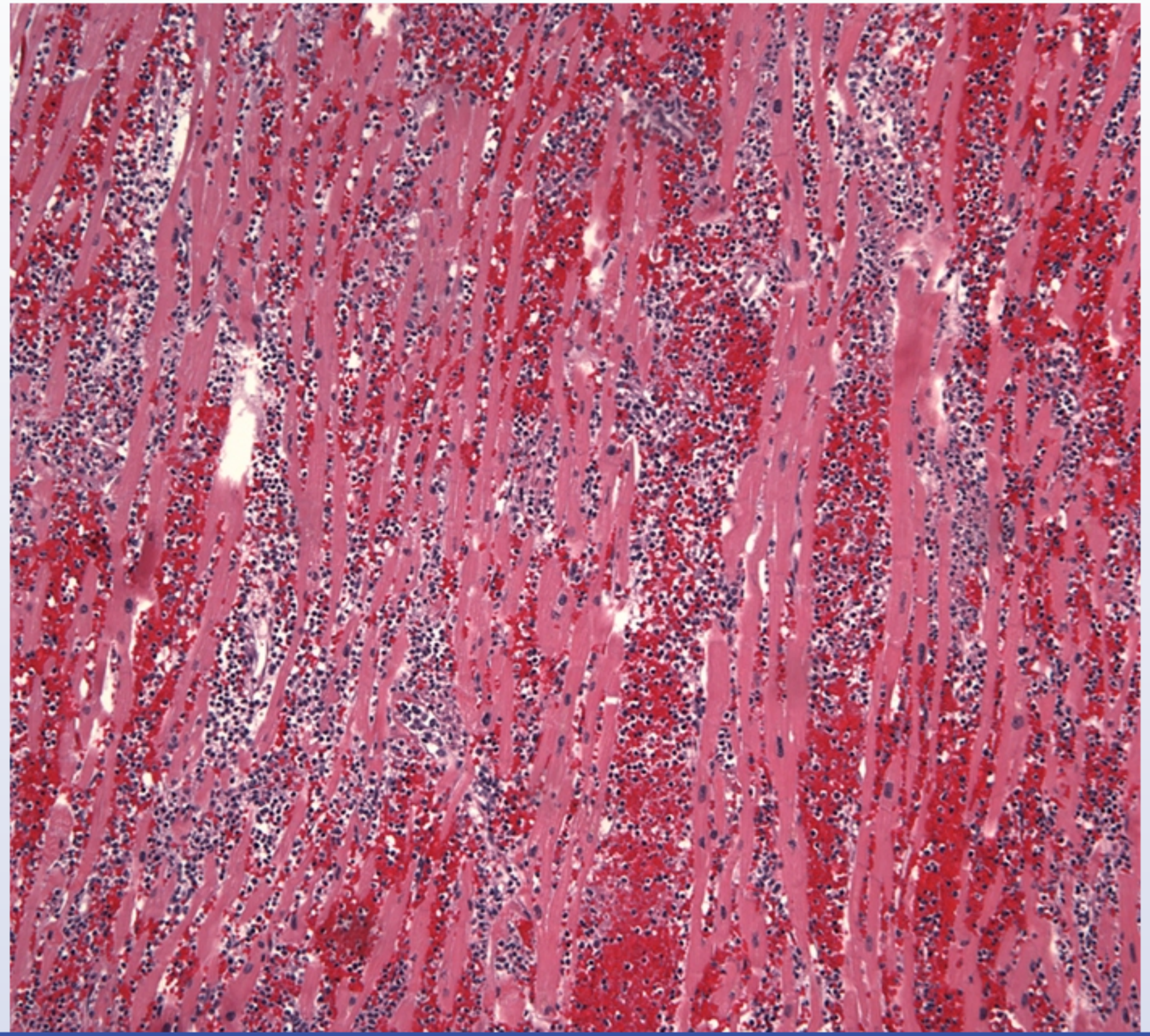

1
2
3
4
5
6
7
8
9
10
11
12
13
14
15
16
17
18
19
20
21
22
23
24
25
26
27
28
29

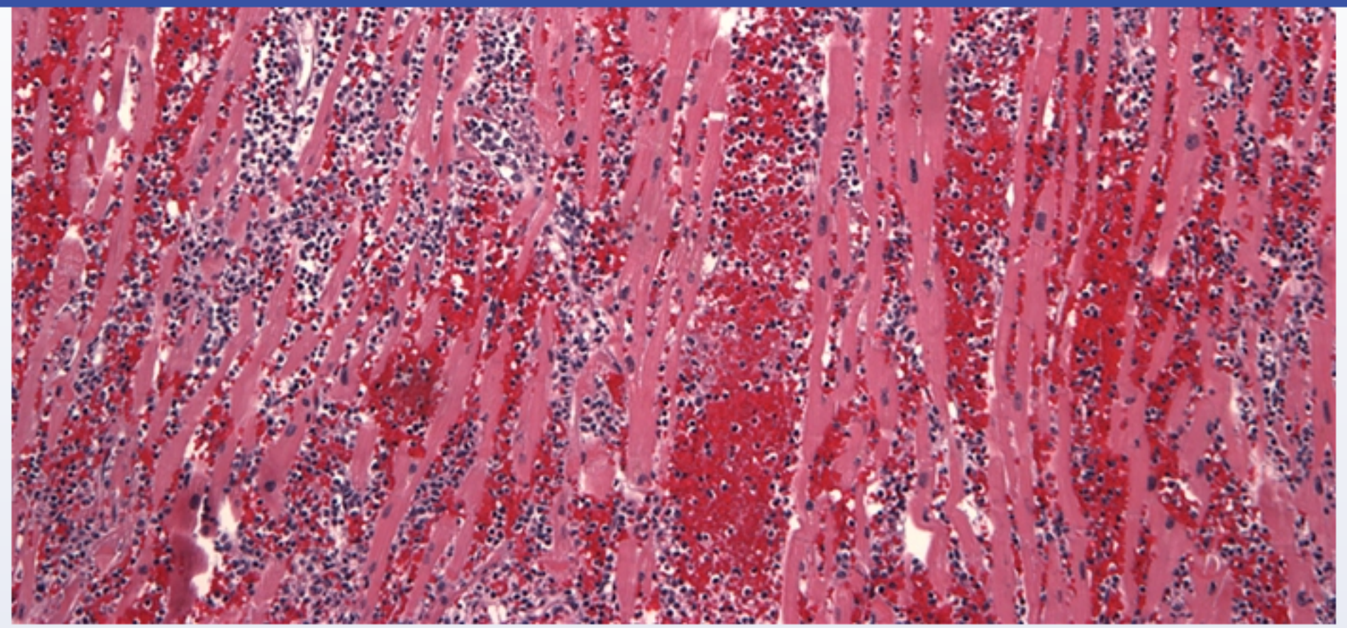

Which of the following is the most likely diagnosis?

- A. Acute myocarditis
- B. Cardiac amyloidosis
- C. Congenital long QT syndrome
- D. Early-onset coronary artery disease
- E. Hypertrophic cardiomyopathy

Submit

1
2
3
4
5
6
7
8
9
10
11
12
13
14
15
16
17
18
19
20
21
22
23
24
25
26
27
28
29

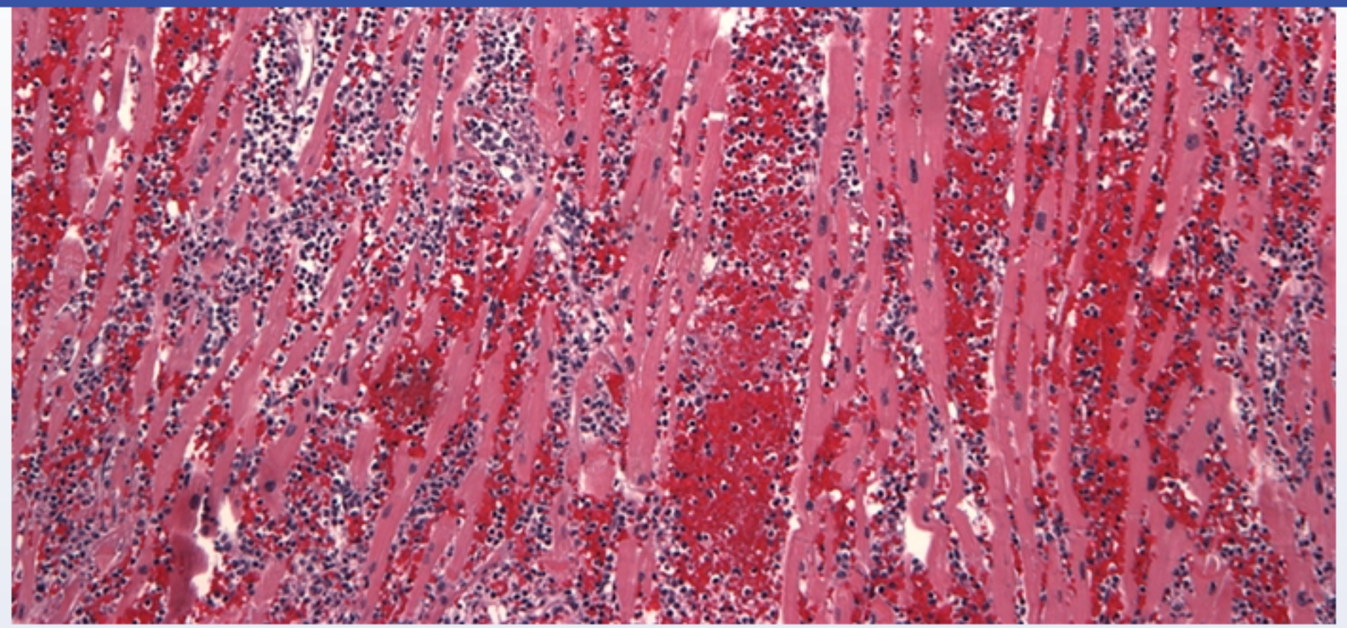

Which of the following is the most likely diagnosis?

- ✓ A. Acute myocarditis (68%)
- B. Cardiac amyloidosis (10%)
- C. Congenital long QT syndrome (2%)
- D. Early-onset coronary artery disease (8%)
- E. Hypertrophic cardiomyopathy (9%)

Omitted
Correct answer

68%
Answered correctly

08 secs
Time Spent

03/16/2020
Last Updated

1
2
3
4
5
6
7
8
9
10
11
12
13
14
15
16
17
18
19
20
21
22
23
24
25
26
27
28
29

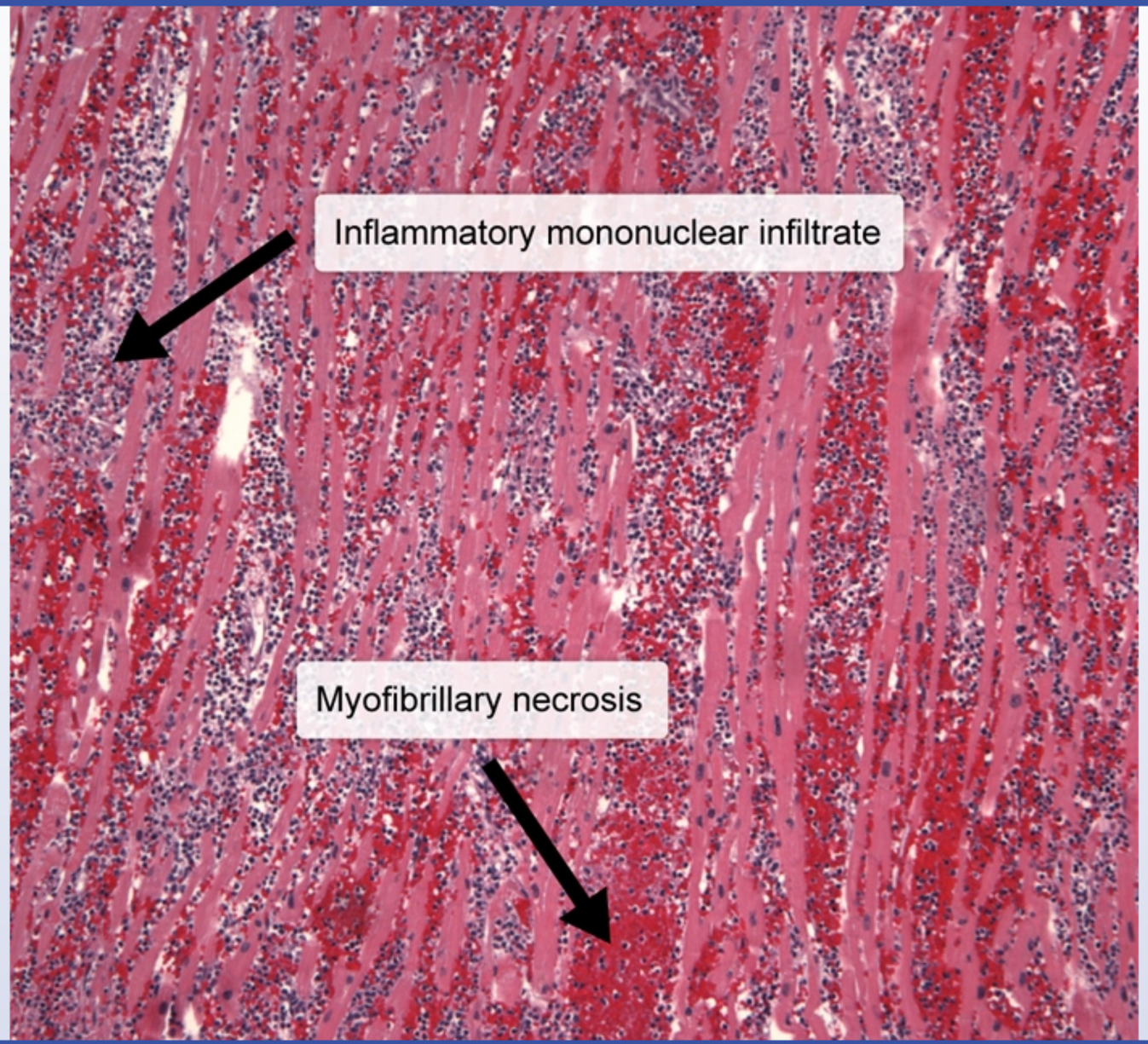

This patient likely died from **acute myocarditis**, a condition most often caused by **viral infection**. Numerous viruses, including coxsackievirus, adenovirus, influenza, and HIV have been implicated. Histopathology typically shows **myofibrillary necrosis** accompanied by inflammatory **mononuclear cell infiltrate** consisting of lymphocytes and some macrophages. Other less common etiologies of acute myocarditis, including bacterial, parasitic, and rheumatologic, often have similar histologic appearance but may demonstrate additional findings (eg, granulomas in mycobacterial disease, visible organisms in parasitic disease).

The clinical presentation of acute myocarditis can vary significantly; many patients remain asymptomatic with subclinical infection, but some experience severe complications including decompensated **heart failure** (eg, dyspnea, fatigue, peripheral edema) due to **dilated cardiomyopathy**. Ventricular arrhythmias leading to **sudden cardiac death** (SCD) can also occur.

(Choice B) Cardiac amyloidosis involves deposition of abnormal proteins in myocardial tissue and typically manifests as restrictive cardiomyopathy initially. SCD can occur, but histopathology demonstrates pink amorphous material (amyloid) surrounding normal-appearing cardiomyocytes.

(Choice C) Congenital long QT syndrome can trigger ventricular arrhythmias and lead to SCD; however, histopathology is generally unremarkable and would not demonstrate myocardial necrosis with inflammatory infiltrate.

(Choice D) Coronary artery disease can lead to SCD due to acute myocardial infarction or ventricular arrhythmia triggered by chronic ischemic heart disease. However, this patient's relatively young age and 1 week of preceding exertional symptoms make acute myocarditis a more likely diagnosis.

(Choice E) Hypertrophic cardiomyopathy is characterized by cardiac myofibrillary disarray and interstitial fibrosis that can predispose to ventricular arrhythmia and SCD. An inflammatory infiltrate is not expected.

Educational objective:
Acute myocarditis is most commonly caused by a viral infection (eg, coxsackievirus, adenovirus, influenza). It often resolves without noticeable symptoms, but patients can develop serious complications, including decompensated heart failure due to dilated cardiomyopathy or sudden cardiac death due to ventricular arrhythmia. Histopathology typically demonstrates myofibrillary necrosis with inflammatory mononuclear infiltrate.

Pathology Cardiovascular System Myocarditis

1
2
3
4
5
6
7
8
9
10
11
12
13
14
15
16
17
18
19
20
21
22
23
24
25
26
27
28
29

Exhibit Display

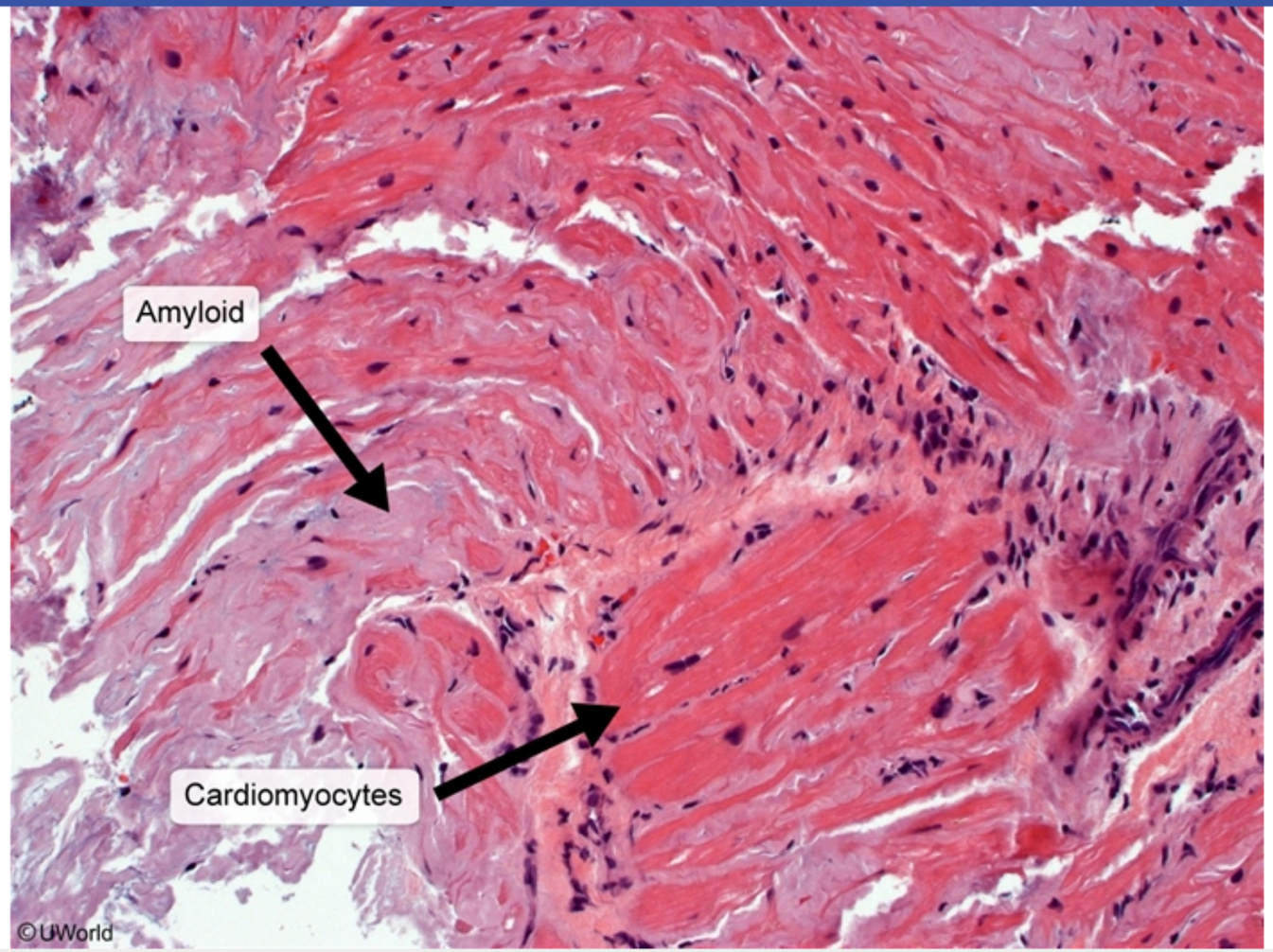

Zoom In | Zoom Out | Reset | Add To New Card | Existing Card

Pathology | Cardiovascular System | Myocarditis

1
2
3
4
5
6
7
8
9
10
11
12
13
14
15
16
17
18
19
20
21
22
23
24
25
26
27
28
29

Exhibit Display

Acute myocardial infarction

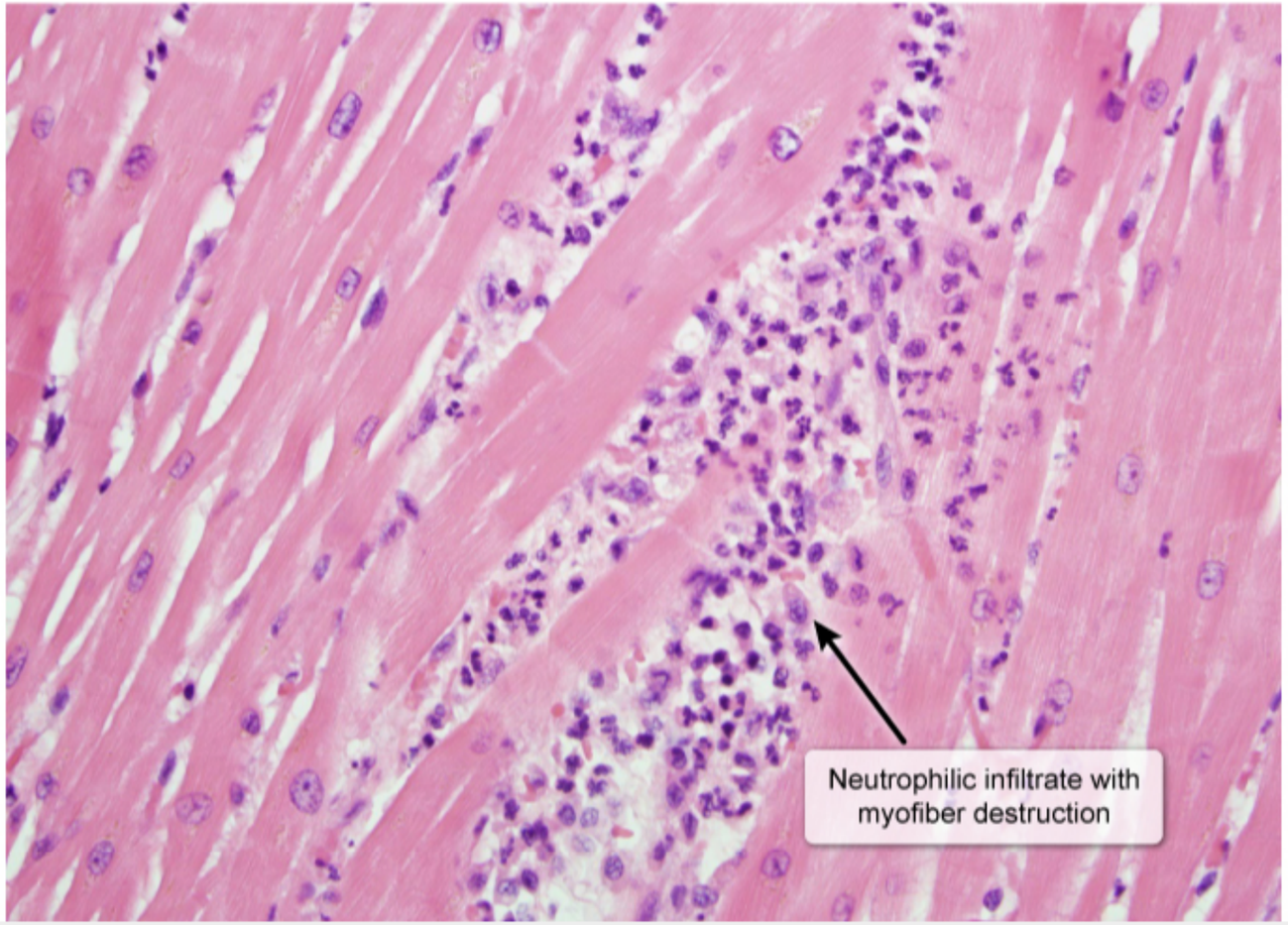

Zoom In | Zoom Out | Reset | Add To New Card | Existing Card

1
2
3
4
5
6
7
8
9
10
11
12
13
14
15
16
17
18
19
20
21
22
23
24
25
26
27
28
29

Exhibit Display

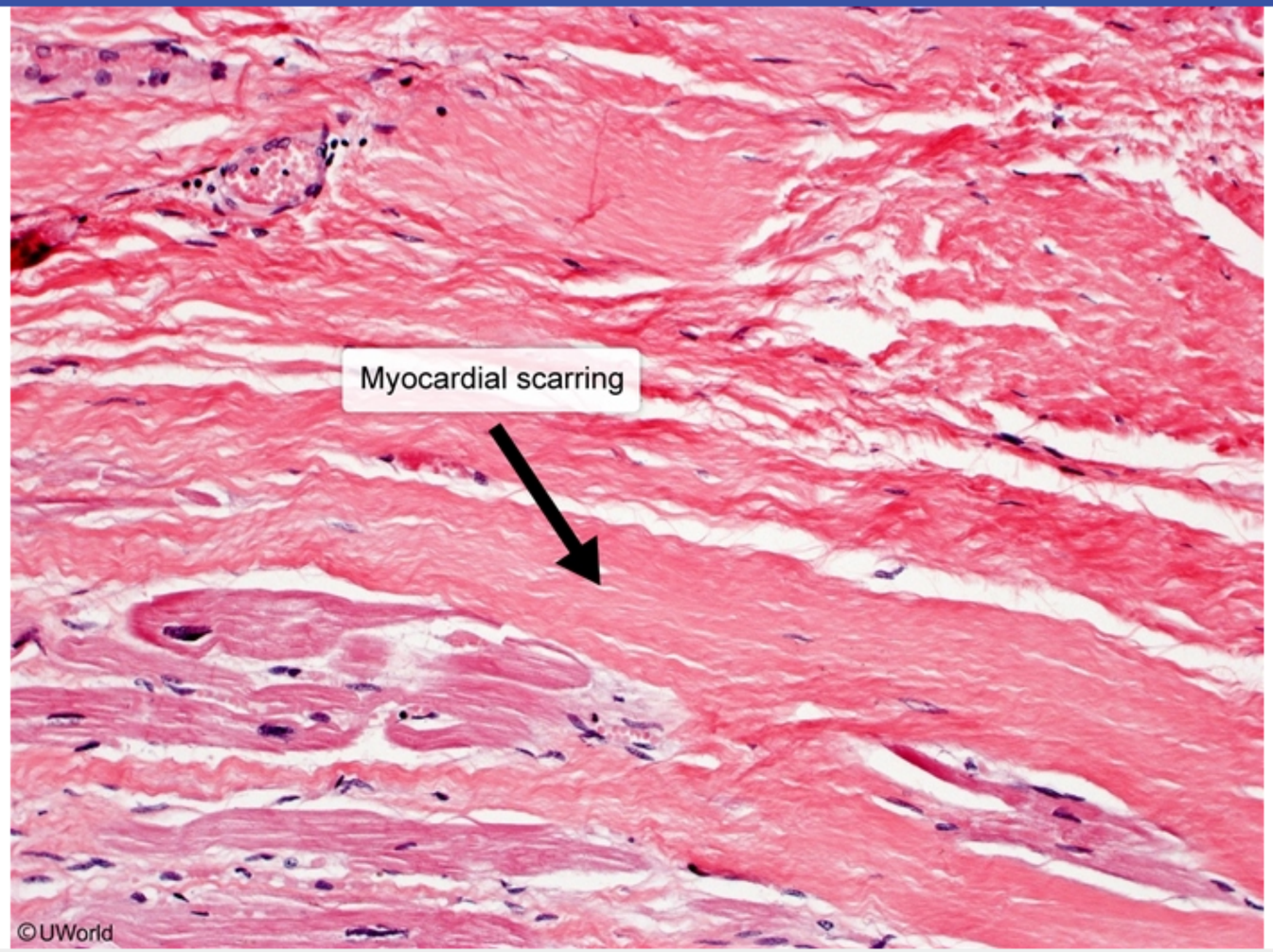

Zoom In | Zoom Out | Reset | Add To New Card | Existing Card

Pathology | Cardiovascular System | Myocarditis

1
2
3
4
5
6
7
8
9
10
11
12
13
14
15
16
17
18
19
20
21
22
23
24
25
26
27
28
29

Exhibit Display

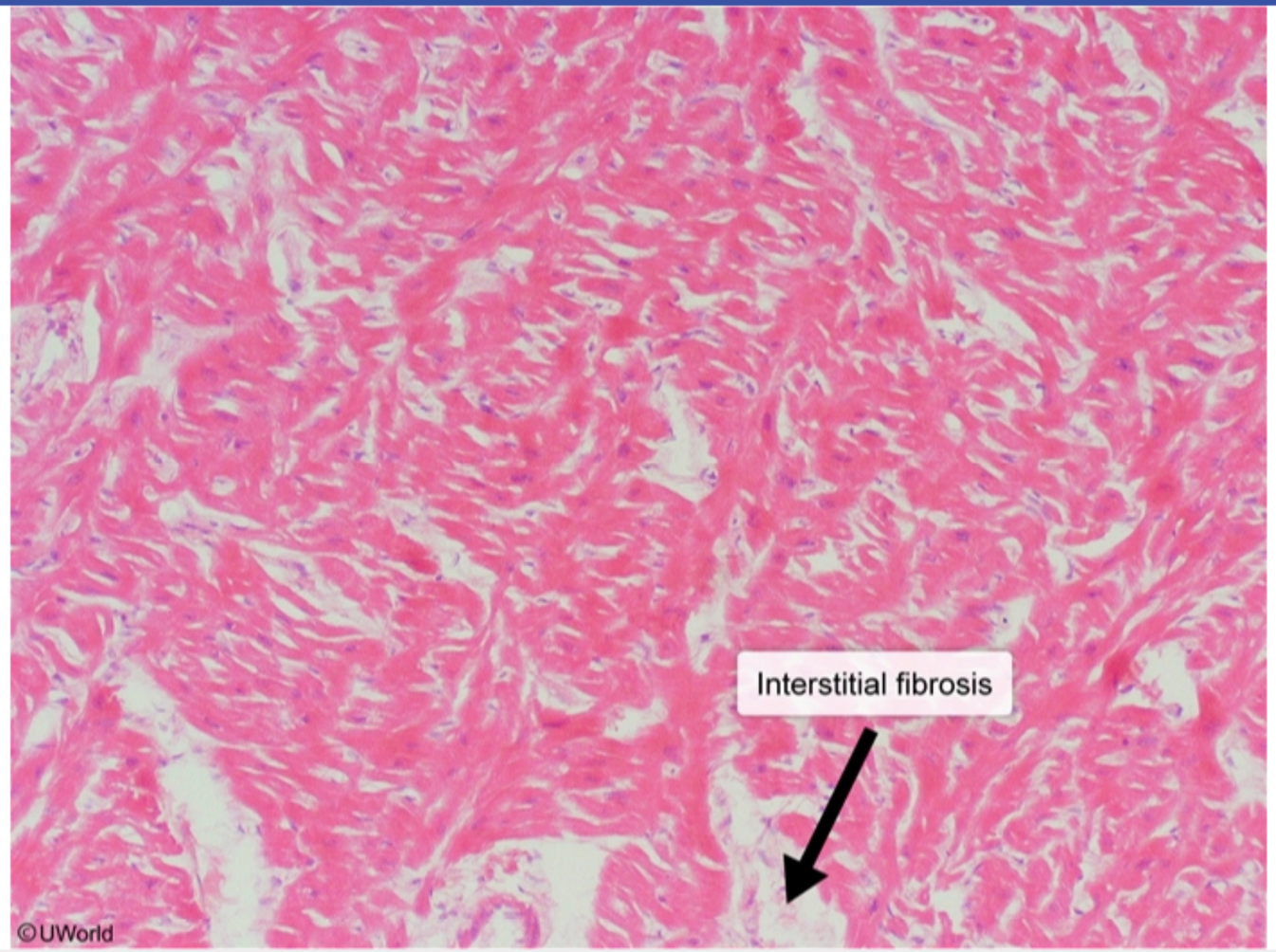

Zoom In | Zoom Out | Reset | Add To New Card | Existing Card

Pathology | Cardiovascular System | Myocarditis

1
2
3
4
5
6
7
8
9
10
11
12
13
14
15
16
17
18
19
20
21
22
23
24
25
26
27
28
29

An 80-year-old man is brought to the hospital due to increasing chest pain. Over the past 6 weeks, he has had dry cough, dysphagia, and a change in voice quality. The patient has a long history of hypertension. He is an ex-smoker with a 35-pack-year history. On physical examination, the patient appears anxious, pale, and diaphoretic. Blood pressure is 80/60 mm Hg, pulse is 120/min, and respirations are 20/min. While being evaluated in the emergency department, he develops cardiac arrest with pulseless electrical activity and cannot be resuscitated. Autopsy is most likely to show which of the following findings?

A. Fat globules in the pulmonary vasculature

B. Left ventricular free-wall rupture

C. Longitudinal tear in the esophagus

D. Ruptured pulmonary bleb

E. Ruptured thoracic aortic aneurysm

Submit

1
2
3
4
5
6
7
8
9
10
11
12
13
14
15
16
17
18
19
20
21
22
23
24
25
26
27
28
29

An 80-year-old man is brought to the hospital due to increasing chest pain. Over the past 6 weeks, he has had dry cough, dysphagia, and a change in voice quality. The patient has a long history of hypertension. He is an ex-smoker with a 35-pack-year history. On physical examination, the patient appears anxious, pale, and diaphoretic. Blood pressure is 80/60 mm Hg, pulse is 120/min, and respirations are 20/min. While being evaluated in the emergency department, he develops cardiac arrest with pulseless electrical activity and cannot be resuscitated. Autopsy is most likely to show which of the following findings?

A. Fat globules in the pulmonary vasculature (2%)
B. Left ventricular free-wall rupture (15%)
C. Longitudinal tear in the esophagus (7%)
D. Ruptured pulmonary bleb (5%)
✓ E. Ruptured thoracic aortic aneurysm (68%)

Omitted
Correct answer
E

68%
Answered correctly

28 secs
Time Spent

04/13/2020
Last Updated

Explanation

Thoracic aortic aneurysm	
Risk factors	• Advanced age (>60) • Smoking, hypertension, family history • Connective tissue disease (eg, Marfan syndrome)

Thoracic aortic aneurysm	
Risk factors	• Advanced age (>60) • Smoking, hypertension, family history • Connective tissue disease (eg, Marfan syndrome)

Clinical presentation	• Majority involve ascending aorta
	• Usually asymptomatic
	• Expansion:
	  ◦ Vague chest/back pain
	  ◦ Compression of structures (eg, hoarseness, dysphagia)
	• Rupture/dissection:
	  ◦ Severe pain, hemodynamic instability

Imaging	• CXR: wide mediastinum, large aortic knob, tracheal deviation

CXR = chest x-ray.

Thoracic aortic aneurysm (TAA) can involve the ascending or descending aorta above the diaphragm. It is usually asymptomatic until it grows large enough to encroach on nearby structures or cause rupture. This patient likely experienced progressive TAA expansion with symptomatic **compression** of **surrounding structures**, followed by acute rupture that led to shock and cardiac arrest.

TAA usually results from age-related degenerative changes in the medial layer of the aorta; these changes are likely accelerated by risk factors, including dyslipidemia, hypertension, tobacco use, and family history. Connective tissue diseases such as Marfan or Ehlers-Danlos syndrome also increase the risk.

The most common symptomatic presentation of TAA is pain, which is typically localized to the chest and back. If the TAA impinges upon the **esophagus**, it can also cause dysphagia. Similarly, compression of the **left recurrent laryngeal nerve** or left vagus nerve results in hoarseness, whereas compression of the **phrenic nerve** can cause hemidiaphragmatic paralysis. Respiratory manifestations, including wheeze, cough, hemoptysis, and dyspnea may occur due to **tracheobronchial obstruction**. Other complications include heart failure due to aortic valve

1 2 3 4 5 6 7 8 9 10 11 12 13 14 15 16 17 18 19 20 21 22 23 24 25 26 27 28 29

Thoracic aortic aneurysm (TAA) can involve the ascending or descending aorta above the diaphragm. It is usually asymptomatic until it grows large enough to encroach on nearby structures or cause rupture. This patient likely experienced progressive TAA expansion with symptomatic **compression** of **surrounding structures**, followed by acute rupture that led to shock and cardiac arrest.

TAA usually results from age-related degenerative changes in the medial layer of the aorta; these changes are likely accelerated by risk factors, including dyslipidemia, hypertension, tobacco use, and family history. Connective tissue diseases such as Marfan or Ehlers-Danlos syndrome also increase the risk.

The most common symptomatic presentation of TAA is pain, which is typically localized to the chest and back. If the TAA impinges upon the **esophagus**, it can also cause dysphagia. Similarly, compression of the **left recurrent laryngeal nerve** or left vagus nerve results in hoarseness, whereas compression of the **phrenic nerve** can cause hemidiaphragmatic paralysis. Respiratory manifestations, including wheeze, cough, hemoptysis, and dyspnea may occur due to **tracheobronchial obstruction**. Other complications include heart failure due to aortic valve regurgitation and superior vena cava syndrome from venous compression and occlusion.

Chest x-ray may suggest the diagnosis of TAA, demonstrating a widened mediastinum, enlarged aortic knob, and tracheal deviation.

(Choice A) Pulmonary fat embolism most commonly results in acute dyspnea, tachypnea, and hypoxemia. Patients commonly develop neurologic abnormalities and a petechial rash, both of which this patient lacks.

(Choice B) Ventricular free-wall rupture is a life-threatening complication of ST elevation myocardial infarction that typically occurs 5 days to 2 weeks after the event. It can also result in shock and cardiac arrest, but it would not explain this patient's subacute cough, voice change, or dysphagia.

(Choice C) Patients with a Mallory-Weiss tear have hematemesis and epigastric or back pain. These esophageal tears are usually preceded by episodes of nonbloody vomiting or retching.

(Choice D) Spontaneous pneumothorax results from the rupture of a pulmonary bleb and can occur with or without a preceding history of lung disease. Most patients describe acute chest pain and dyspnea. Although it can rarely progress to a tension pneumothorax with obstructive shock, such a condition would not explain this patient's subacute symptoms.

Educational objective:
Thoracic aortic aneurysms are usually asymptomatic until they grow large enough to compress surrounding structures or cause rupture. The most common symptomatic presentation is chest or back pain, but compression of nearby structures can cause dysphagia, hoarseness, cough, or

The most common symptomatic presentation of TAA is pain, which is typically localized to the chest and back. If the TAA impinges upon the **esophagus**, it can also cause dysphagia. Similarly, compression of the **left recurrent laryngeal nerve** or left vagus nerve results in hoarseness, whereas compression of the **phrenic nerve** can cause hemidiaphragmatic paralysis. Respiratory manifestations, including wheeze, cough, hemoptysis, and dyspnea may occur due to **tracheobronchial obstruction**. Other complications include heart failure due to aortic valve regurgitation and superior vena cava syndrome from venous compression and occlusion.

Chest x-ray may suggest the diagnosis of TAA, demonstrating a widened mediastinum, enlarged aortic knob, and tracheal deviation.

(Choice A) Pulmonary fat embolism most commonly results in acute dyspnea, tachypnea, and hypoxemia. Patients commonly develop neurologic abnormalities and a petechial rash, both of which this patient lacks.

(Choice B) Ventricular free-wall rupture is a life-threatening complication of ST elevation myocardial infarction that typically occurs 5 days to 2 weeks after the event. It can also result in shock and cardiac arrest, but it would not explain this patient's subacute cough, voice change, or dysphagia.

(Choice C) Patients with a Mallory-Weiss tear have hematemesis and epigastric or back pain. These esophageal tears are usually preceded by episodes of nonbloody vomiting or retching.

(Choice D) Spontaneous pneumothorax results from the rupture of a pulmonary bleb and can occur with or without a preceding history of lung disease. Most patients describe acute chest pain and dyspnea. Although it can rarely progress to a tension pneumothorax with obstructive shock, such a condition would not explain this patient's subacute symptoms.

Educational objective:
Thoracic aortic aneurysms are usually asymptomatic until they grow large enough to compress surrounding structures or cause rupture. The most common symptomatic presentation is chest or back pain, but compression of nearby structures can cause dysphagia, hoarseness, cough, or dyspnea.

References

- Thoracic aortic aneurysm: reading the enemy's playbook.
- Management of acute aortic dissection and thoracic aortic rupture.

1
2
3
4
5
6
7
8
9
10
11
12
13
14
15
16
17
18
19
20
21
22
23
24
25
26
27
28
29

The most common symptomatic presentation of TAA is pain, which is typically localized to the chest and back. If the TAA impinges upon the

Exhibit Display

Normal chest x-ray

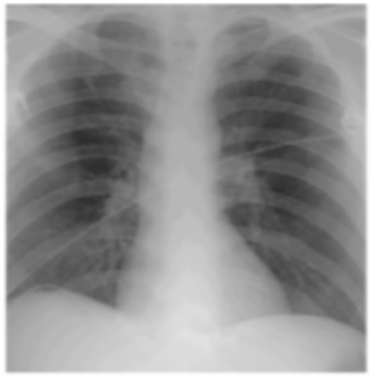

Thoracic aortic aneurysm

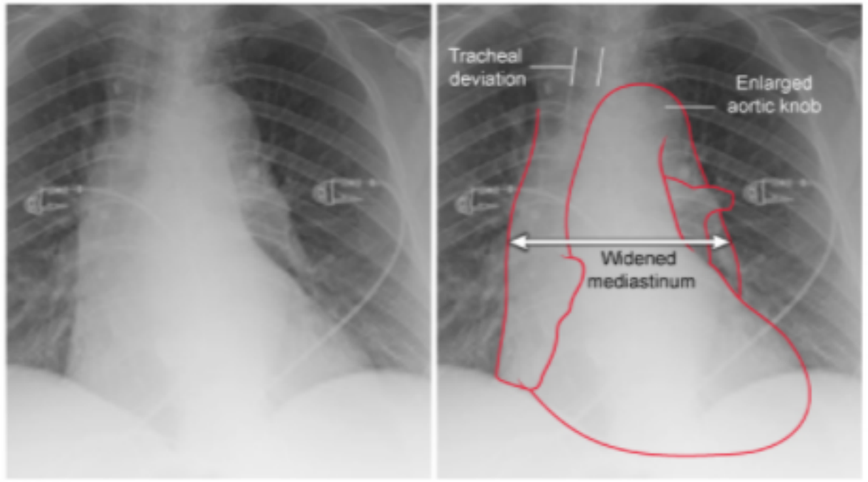

©UWorld

Zoom In | Zoom Out | Reset | Add To New Card | Existing Card

1
2
3
4
5
6
7
8
9
10
11
12
13
14
15
16
17
18
19
20
21
22
23
24
25
26
27
28
29

A 33-year-old, previously healthy woman comes to the emergency department due to sudden-onset shortness of breath and left-sided chest pain. The symptoms began an hour ago while she was doing yard work, and she nearly passed out at symptom onset. The patient takes no medications or supplements other than ibuprofen for occasional headaches. She does not use tobacco, alcohol, or illicit drugs. Temperature is 37.1 C (98.8 F), blood pressure is 84/58 mm Hg, pulse is 122/min, and respirations are 24/min. Pulse oximetry is 86% on room air. On physical examination, the patient is in moderate distress. The jugular veins are distended. Heart sounds are rapid and regular with no murmurs. Lungs are clear to auscultation bilaterally with no crackles or wheezes. Arterial blood gas results are pH 7.52, $PaCO_2$ 28 mm Hg, and PaO_2 54 mm Hg. Which of the following is most likely to be seen on bedside echocardiography?

A. Enlarged left ventricular cavity
B. Enlarged right ventricular cavity
C. Left atrial enlargement
D. Left ventricular wall thickening
E. Right ventricular wall thickening

Submit

1
2
3
4
5
6
7
8
9
10
11
12
13
14
15
16
17
18
19
20
21
22
23
24
25
26
27
28
29

A 33-year-old, previously healthy woman comes to the emergency department due to sudden-onset shortness of breath and left-sided chest pain. The symptoms began an hour ago while she was doing yard work, and she nearly passed out at symptom onset. The patient takes no medications or supplements other than ibuprofen for occasional headaches. She does not use tobacco, alcohol, or illicit drugs. Temperature is 37.1 C (98.8 F), blood pressure is 84/58 mm Hg, pulse is 122/min, and respirations are 24/min. Pulse oximetry is 86% on room air. On physical examination, the patient is in moderate distress. The jugular veins are distended. Heart sounds are rapid and regular with no murmurs. Lungs are clear to auscultation bilaterally with no crackles or wheezes. Arterial blood gas results are pH 7.52, $PaCO_2$ 28 mm Hg, and PaO_2 54 mm Hg. Which of the following is most likely to be seen on bedside echocardiography?

- A. Enlarged left ventricular cavity (6%)
- ✓ B. Enlarged right ventricular cavity (40%)
- C. Left atrial enlargement (7%)
- D. Left ventricular wall thickening (9%)
- E. Right ventricular wall thickening (35%)

Omitted
Correct answer
B

40%
Answered correctly

02 secs
Time Spent

05/06/2020
Last Updated

Explanation

Pathophysiology of massive pulmonary embolism

1
2
3
4
5
6
7
8
9
10
11
12
13
14
15
16
17
18
19
20
21
22
23
24
25
26
27
28
29

Pathophysiology of massive pulmonary embolism

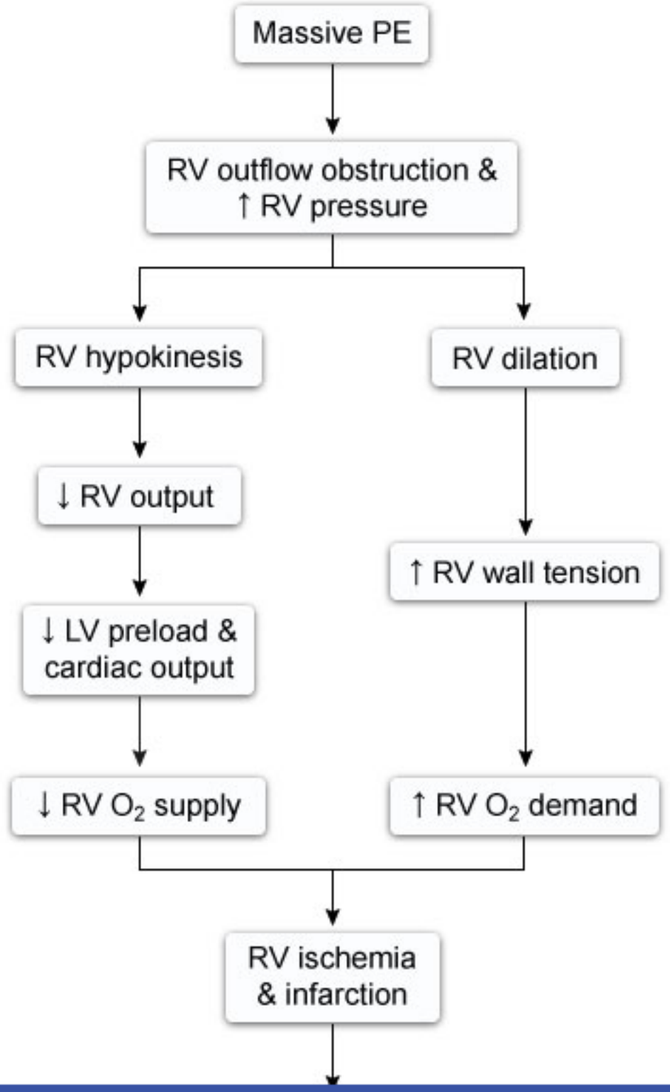

1
2
3
4
5
6
7
8
9
10
11
12
13
14
15
16
17
18
19
20
21
22
23
24
25
26
27
28
29

Exhibit Display

Pathophysiology of massive pulmonary embolism

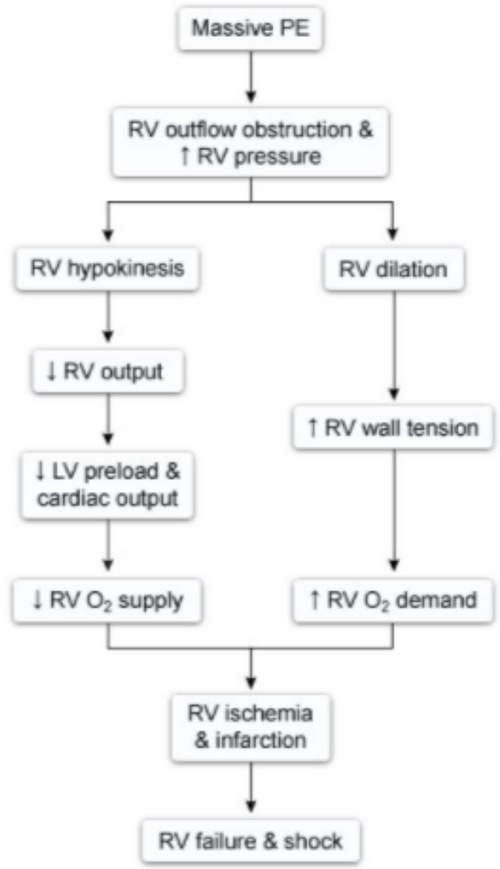

LV = left ventricular; **PE** = pulmonary embolism; **RV** = right ventricular.

©UWorld

Zoom In | Zoom Out | Reset | Add To New Card | Existing Card

1
2
3
4
5
6
7
8
9
10
11
12
13
14
15
16
17
18
19
20
21
22
23
24
25
26
27
28
29

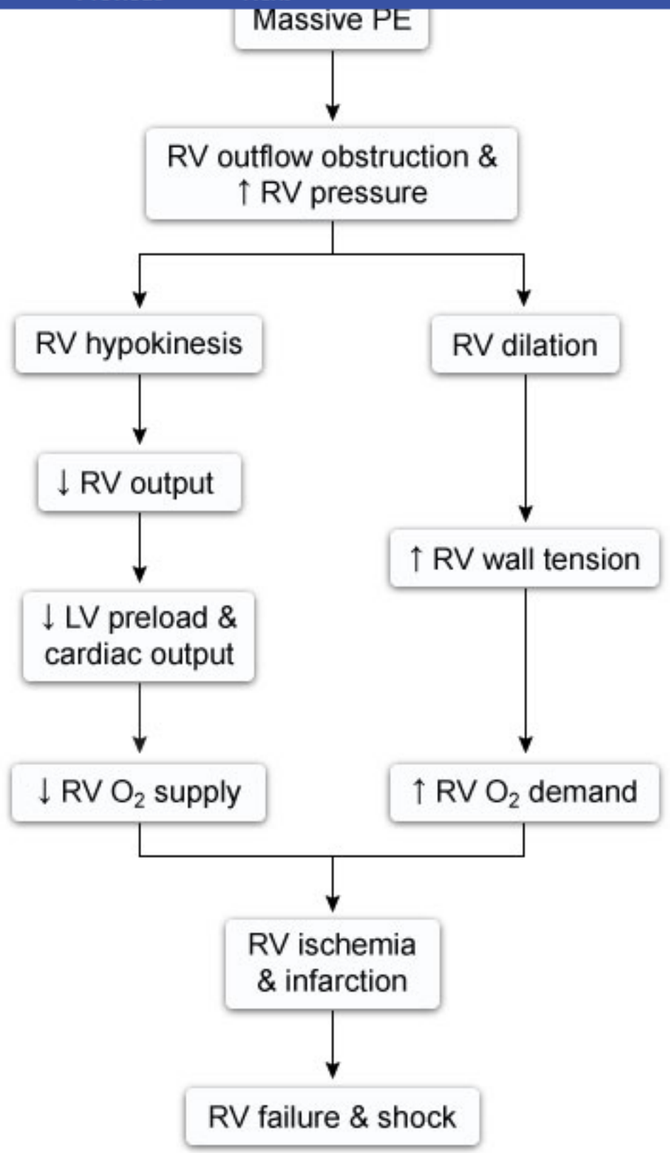

LV = left ventricular; **PE** = pulmonary embolism; **RV** = right ventricular.

©UWorld

1
2
3
4
5
6
7
8
9
10
11
12
13
14
15
16
17
18
19
20
21
22
23
24
25
26
27
28
29

This patient most likely has an **acute pulmonary embolism** (PE). The classic presentation is acute-onset chest pain and shortness of breath that may be accompanied by syncope or near-syncope. Patients usually have tachycardia, tachypnea, jugular venous distension, and clear lungs. Arterial blood gas results typically show hypoxemia and acute respiratory alkalosis due to hyperventilation.

Massive PE can lead to hypotension and obstructive shock. There is a rapid increase in pulmonary arterial resistance that leads to an increase in pulmonary arterial and right ventricular (RV) pressure. The rapid pressure increase causes **RV cavity enlargement** due to increased RV wall tension and cardiac muscle stretching. RV myocardial oxygen demand increases and coronary artery perfusion decreases, leading to a supply/demand mismatch and RV ischemia. Consequent **RV dysfunction** then leads to an inability to pump blood through the pulmonary circulation, resulting in decreased left-sided preload and **decreased cardiac output**. Such RV failure caused by an increase in pulmonary vascular resistance is sometimes called **cor pulmonale**.

(Choice A) An enlarged left ventricular (LV) cavity usually results from eccentric hypertrophy in the setting of chronic volume overload, such as occurs in dilated cardiomyopathy or severe aortic or mitral valve regurgitation. In acute PE, the LV cavity is either normal or somewhat reduced in size due to reduced blood flow coming from the right side of the heart.

(Choice C) Left atrial enlargement is typical of severe mitral stenosis, which usually occurs in the setting of rheumatic heart disease. Undiagnosed mitral stenosis can sometimes present acutely with decompensated heart failure; however, a rumbling diastolic murmur and evidence of pulmonary edema (eg, crackles on lung auscultation) are expected.

(Choice D) LV wall thickening is expected with the concentric hypertrophy that occurs with prolonged systemic hypertension or severe aortic stenosis.

(Choice E) RV wall thickening is seen with the concentric hypertrophy that occurs in patients with chronic pulmonary hypertension. In acute PE, there is no time for compensatory wall thickening to occur in response to the increased pressure load; the rapid increase in pressure causes RV dilation that may be accompanied by RV failure.

Educational objective:
A large, acute pulmonary embolism causes a rapid increase in right ventricular (RV) pressure that leads to RV cavity enlargement and RV dysfunction. Thickening of the RV wall is not seen in acute pulmonary embolism, as there is no time for compensatory hypertrophy to occur in response to the increased pressure load.

1 2 3 4 5 6 7 8 9 10 11 12 13 14 15 16 17 18 19 20 21 22 23 24 25 26 27 28 29

Massive PE can lead to hypotension and obstructive shock. There is a rapid increase in pulmonary arterial resistance that leads to an increase in pulmonary arterial and right ventricular (RV) pressure. The rapid pressure increase causes **RV cavity enlargement** due to increased RV wall tension and cardiac muscle stretching. RV myocardial oxygen demand increases and coronary artery perfusion decreases, leading to a supply/demand mismatch and RV ischemia. Consequent **RV dysfunction** then leads to an inability to pump blood through the pulmonary circulation, resulting in decreased left-sided preload and **decreased cardiac output**. Such RV failure caused by an increase in pulmonary vascular resistance is sometimes called **cor pulmonale**.

(Choice A) An enlarged left ventricular (LV) cavity usually results from eccentric hypertrophy in the setting of chronic volume overload, such as occurs in dilated cardiomyopathy or severe aortic or mitral valve regurgitation. In acute PE, the LV cavity is either normal or somewhat reduced in size due to reduced blood flow coming from the right side of the heart.

(Choice C) Left atrial enlargement is typical of severe mitral stenosis, which usually occurs in the setting of rheumatic heart disease. Undiagnosed mitral stenosis can sometimes present acutely with decompensated heart failure; however, a rumbling diastolic murmur and evidence of pulmonary edema (eg, crackles on lung auscultation) are expected.

(Choice D) LV wall thickening is expected with the concentric hypertrophy that occurs with prolonged systemic hypertension or severe aortic stenosis.

(Choice E) RV wall thickening is seen with the concentric hypertrophy that occurs in patients with chronic pulmonary hypertension. In acute PE, there is no time for compensatory wall thickening to occur in response to the increased pressure load; the rapid increase in pressure causes RV dilation that may be accompanied by RV failure.

Educational objective:
A large, acute pulmonary embolism causes a rapid increase in right ventricular (RV) pressure that leads to RV cavity enlargement and RV dysfunction. Thickening of the RV wall is not seen in acute pulmonary embolism, as there is no time for compensatory hypertrophy to occur in response to the increased pressure load.

Pathology	Cardiovascular System	Pulmonary embolism
Subject	System	Topic

Copyright © UWorld. All rights reserved.

1
2
3
4
5
6
7
8
9
10
11
12
13
14
15
16
17
18
19
20
21
22
23
24
25
26
27
28
29

Massive PE can lead to hypotension and obstructive shock. There is a rapid increase in pulmonary arterial resistance that leads to an increase in

Exhibit Display

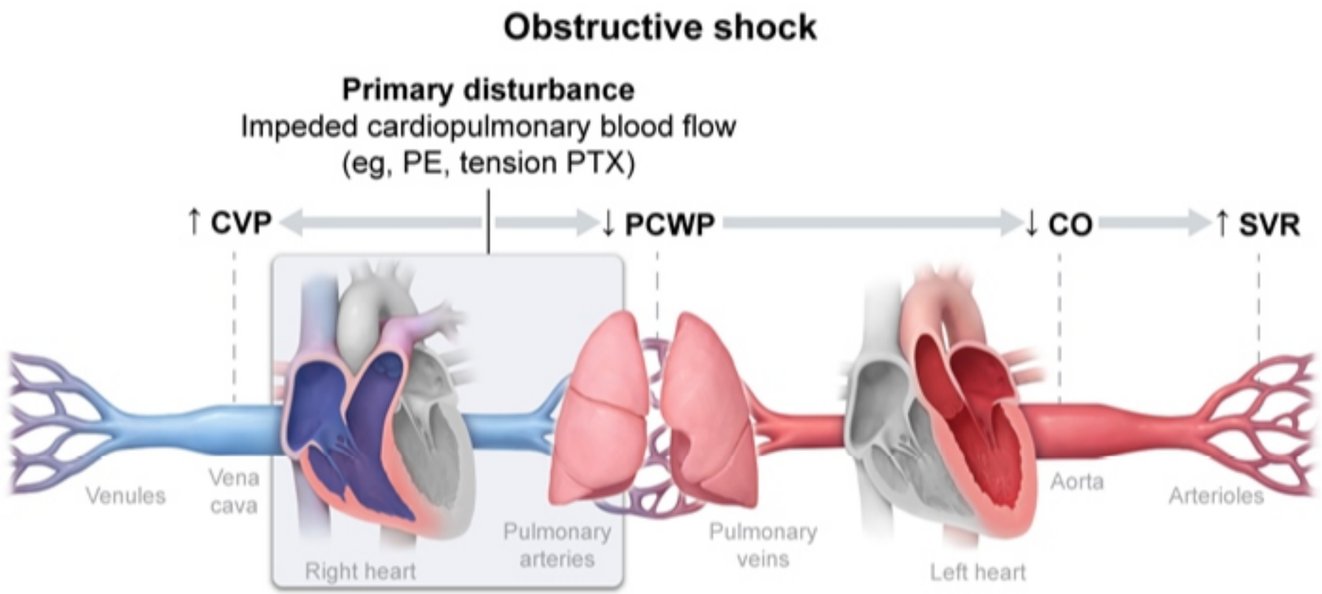

CO = cardiac output; **CVP** = central venous pressure; **PCWP** = pulmonary capillary wedge pressure; **PE** = pulmonary embolism; **PTX** = pneumothorax; **SVR** = systemic vascular resistance.

©UWorld

Zoom In | Zoom Out | Reset | Add To New Card | Existing Card

Copyright © UWorld. All rights reserved.

1
2
3
4
5
6
7
8
9
10
11
12
13
14
15
16
17
18
19
20
21
22
23
24
25
26
27
28
29

Massive PE can lead to hypotension and obstructive shock. There is a rapid increase in pulmonary arterial resistance that leads to an increase in

Exhibit Display

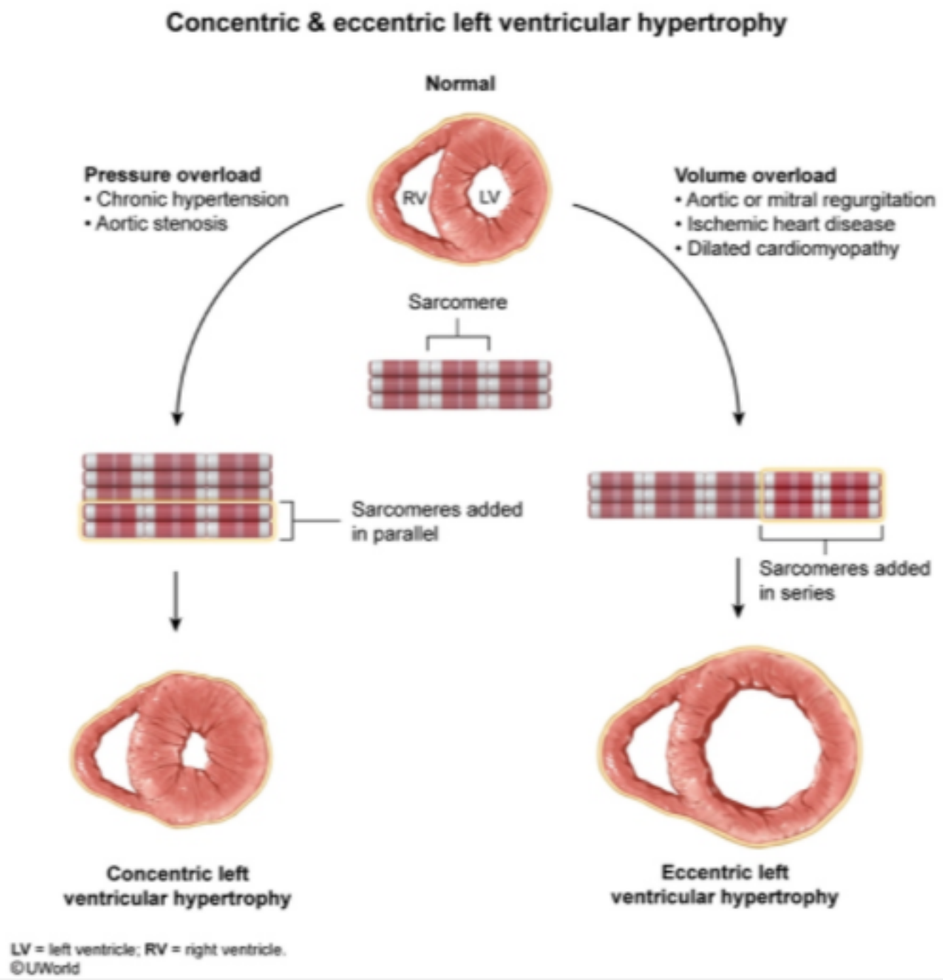

Zoom In | Zoom Out | Reset | Add To New Card | Existing Card

Copyright © UWorld. All rights reserved.

pulmonary arterial and right ventricular (RV) pressure. The rapid pressure increase causes **RV cavity enlargement** due to increased RV wall tension and cardiac muscle stretching. RV myocardial oxygen demand increases and coronary artery perfusion decreases, leading to a supply/demand mismatch and RV ischemia. Consequent **RV dysfunction** then leads to an inability to pump blood through the pulmonary circulation, resulting in decreased left-sided preload and **decreased cardiac output**. Such RV failure caused by an increase in pulmonary vascular resistance is sometimes called **cor pulmonale**.

(Choice A) An enlarged left ventricular (LV) cavity usually results from eccentric hypertrophy in the setting of chronic volume overload, such as occurs in dilated cardiomyopathy or severe aortic or mitral valve regurgitation. In acute PE, the LV cavity is either normal or somewhat reduced in size due to reduced blood flow coming from the right side of the heart.

(Choice C) Left atrial enlargement is typical of severe mitral stenosis, which usually occurs in the setting of rheumatic heart disease. Undiagnosed mitral stenosis can sometimes present acutely with decompensated heart failure; however, a rumbling diastolic murmur and evidence of pulmonary edema (eg, crackles on lung auscultation) are expected.

(Choice D) LV wall thickening is expected with the concentric hypertrophy that occurs with prolonged systemic hypertension or severe aortic stenosis.

(Choice E) RV wall thickening is seen with the concentric hypertrophy that occurs in patients with chronic pulmonary hypertension. In acute PE, there is no time for compensatory wall thickening to occur in response to the increased pressure load; the rapid increase in pressure causes RV dilation that may be accompanied by RV failure.

Educational objective:
A large, acute pulmonary embolism causes a rapid increase in right ventricular (RV) pressure that leads to RV cavity enlargement and RV dysfunction. Thickening of the RV wall is not seen in acute pulmonary embolism, as there is no time for compensatory hypertrophy to occur in response to the increased pressure load.

Pathology	Cardiovascular System	Pulmonary embolism
Subject	System	Topic

Copyright © UWorld. All rights reserved.

1
2
3
4
5
6
7
8
9
10
11
12
13
14
15
16
17
18
19
20
21
22
23
24
25
26
27
28
29

A 4-year-old boy is brought in by his parents for evaluation of a fever that has persisted for the past 5 days. He has also been more irritable than usual and had 2 or 3 episodes of vomiting. The patient has no prior medical problems and takes no medications. He has received all recommended vaccinations. He traveled to China last year to visit his grandparents and cousins but has not traveled outside of the country this year. Temperature is 38.9 C (102 F). Physical examination shows bilateral conjunctival injection with no exudates. His tongue is bright red and lips are cracked. Nonpitting edema is present on his hands and feet. Which of the following complications is this patient at greatest risk for developing?

- A. Aortic dissection
- B. Coronary artery aneurysm
- C. Monocular blindness
- D. Mononeuritis multiplex
- E. Proliferative glomerulonephritis
- F. Pulmonary cavitation

Submit

1
2
3
4
5
6
7
8
9
10
11
12
13
14
15
16
17
18
19
20
21
22
23
24
25
26
27
28
29

A 4-year-old boy is brought in by his parents for evaluation of a fever that has persisted for the past 5 days. He has also been more irritable than usual and had 2 or 3 episodes of vomiting. The patient has no prior medical problems and takes no medications. He has received all recommended vaccinations. He traveled to China last year to visit his grandparents and cousins but has not traveled outside of the country this year. Temperature is 38.9 C (102 F). Physical examination shows bilateral conjunctival injection with no exudates. His tongue is bright red and lips are cracked. Nonpitting edema is present on his hands and feet. Which of the following complications is this patient at greatest risk for developing?

- A. Aortic dissection (4%)
- ✓ B. Coronary artery aneurysm (70%)
- C. Monocular blindness (3%)
- D. Mononeuritis multiplex (3%)
- E. Proliferative glomerulonephritis (16%)
- F. Pulmonary cavitation (1%)

Omitted
Correct answer
B

70%
Answered correctly

02 secs
Time Spent

01/14/2020
Last Updated

Explanation

Kawasaki disease

1
2
3
4
5
6
7
8
9
10
11
12
13
14
15
16
17
18
19
20
21
22
23
24
25
26
27
28
29

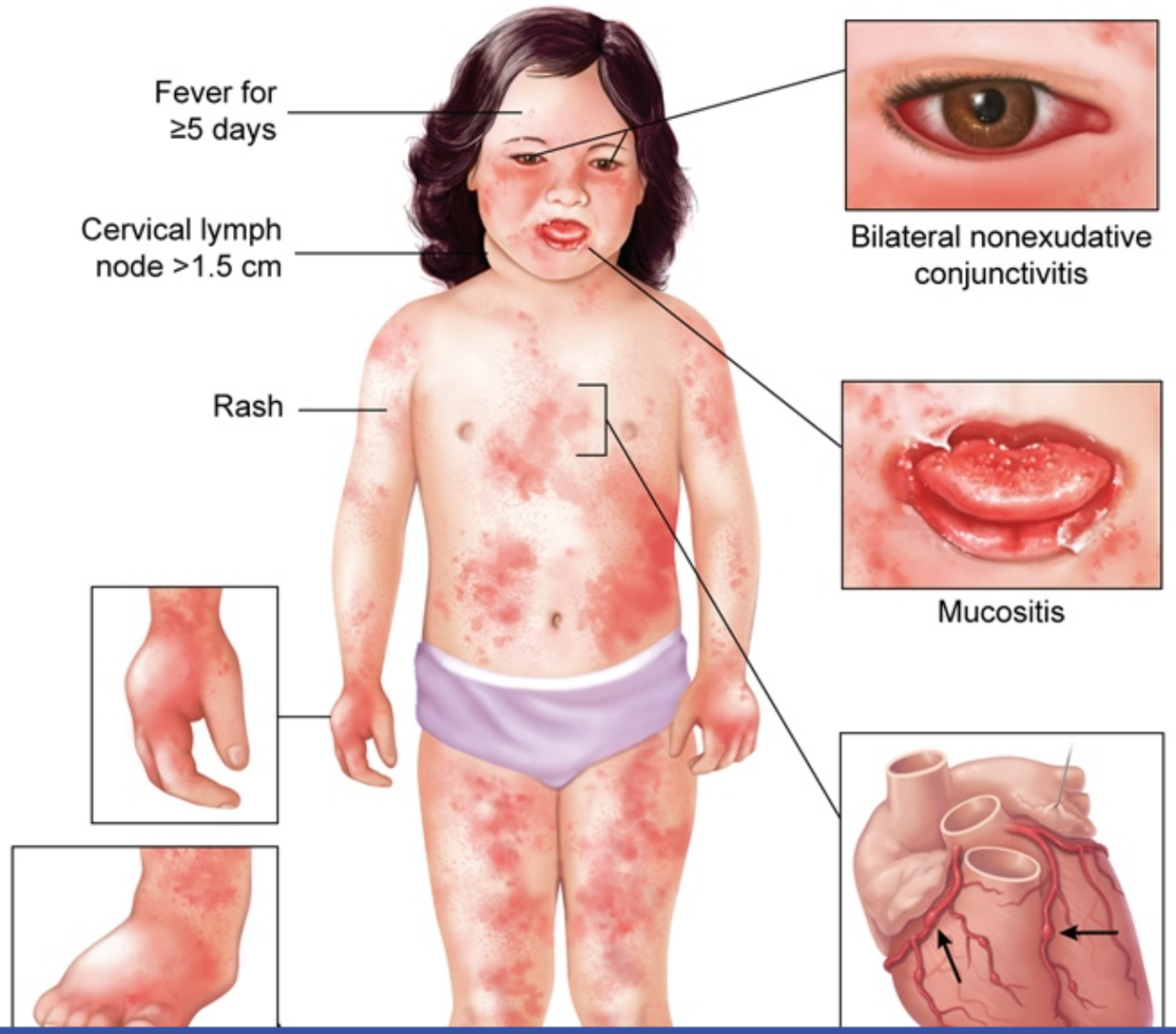

1
2
3
4
5
6
7
8
9
10
11
12
13
14
15
16
17
18
19
20
21
22
23
24
25
26
27
28
29

Exhibit Display

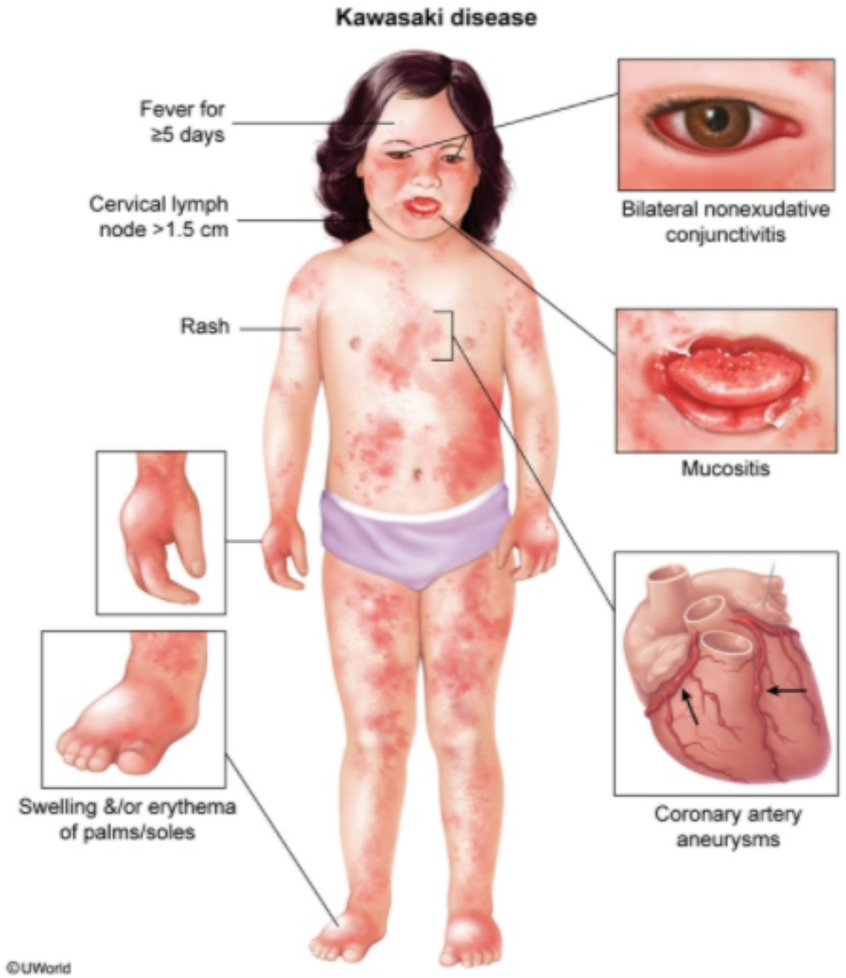

Zoom In | Zoom Out | Reset | Add To New Card | Existing Card

1
2
3
4
5
6
7
8
9
10
11
12
13
14
15
16
17
18
19
20
21
22
23
24
25
26
27
28
29

©UWorld

Kawasaki disease is a vasculitis of **medium-sized arteries** that affects young children (usually age <5 years). It occurs most commonly in patients of **Asian** ethnicity. The diagnosis of Kawasaki disease is based on a **fever for ≥5 days** plus 4 of the following findings:

1. Bilateral non-exudative conjunctival injection (erythema)
2. Cervical lymphadenopathy
3. Mucositis: Erythema of the palatine mucosa, fissured erythematous lips, "strawberry" tongue
4. Extremity changes: Edema of hands and feet, erythema of palms and soles, desquamation of the fingertips (periungual)
5. Rash: Polymorphous (usually urticarial) erythematous rash on the extremities that spreads centripetally to the trunk

A serious complication of Kawasaki disease is coronary artery inflammation leading to the development of **coronary artery aneurysms**.

(Choice A) Dissecting aneurysms of the aorta are associated with long-standing hypertension and Marfan syndrome.

(Choice C) Monocular blindness is a complication of temporal arteritis.

(Choice D) Mononeuritis multiplex is a peripheral neuropathy of multiple individual nerves. It is associated with a variety of diseases, including granulomatosis with polyangiitis (Wegener's) and polyarteritis nodosa.

(Choice E) Acute proliferative glomerulonephritis can occur after group A streptococcal skin/throat infections. Although symptoms such as fever, "strawberry" tongue, and desquamation can occur in scarlet fever, this patient's bilateral nonexudative conjunctivitis, swelling of the hands and feet, and persistent high-grade fever are more suggestive of Kawasaki disease.

(Choice F) Pulmonary cavities can occur following resolution of pulmonary tuberculosis, histoplasmosis, or sarcoidosis.

Educational objective:
Kawasaki disease is a vasculitis of medium-sized arteries that presents with persistent fever for ≥5 days, bilateral conjunctivitis, cervical lymphadenopathy, and mucocutaneous involvement. Coronary artery aneurysms are a serious complication of Kawasaki disease.

References

- Coronary artery dilation in acute Kawasaki disease and acute illnesses associated with Fever.
- Diagnosis, treatment, and long-term management of Kawasaki disease: a statement for health professionals from the Committee on

©UWorld

Exhibit Display

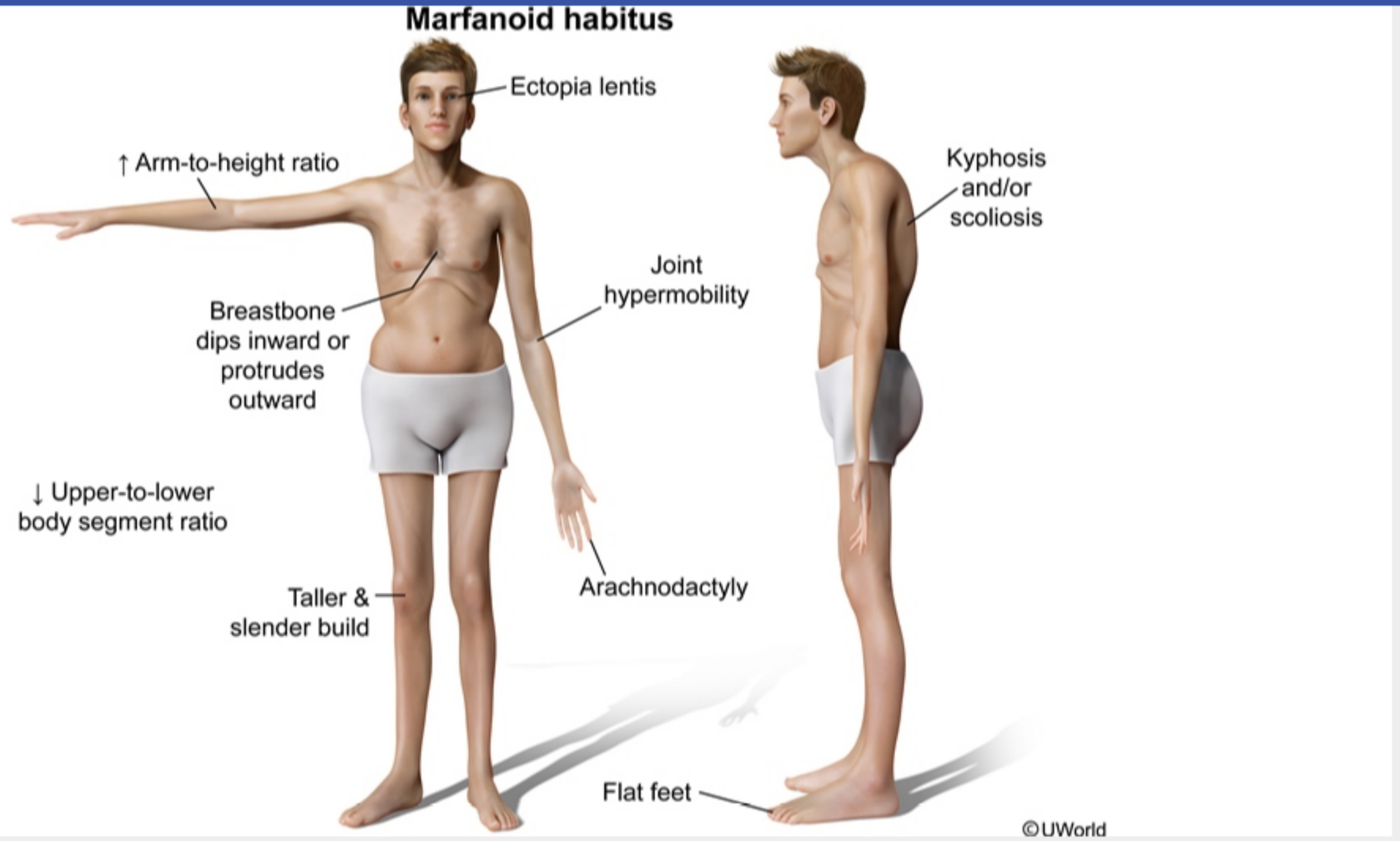

Zoom In | Zoom Out | Reset | Add To New Card | Existing Card

- Diagnosis, treatment, and long-term management of Kawasaki disease: a statement for health professionals from the Committee on

1
2
3
4
5
6
7
8
9
10
11
12
13
14
15
16
17
18
19
20
21
22
23
24
25
26
27
28
29

A 35-year-old previously healthy man is brought to the emergency department after being involved in a motor vehicle accident. He has significant blunt chest and head trauma. Shortly after he arrives, his blood pressure drops suddenly and he begins experiencing respiratory distress. On physical examination, the patient is tachycardic and tachypneic. His lungs are clear to auscultation with vesicular breath sounds heard bilaterally. He has jugular venous distention, and his systolic blood pressure falls 15 mm Hg with inspiration. Which of the following is the most likely cause of this patient's deterioration?

A. Tension pneumothorax
B. Epidural hematoma
C. Hemothorax
D. Aortic rupture
E. Cardiac tamponade

Submit

1
2
3
4
5
6
7
8
9
10
11
12
13
14
15
16
17
18
19
20
21
22
23
24
25
26
27
28
29

A 35-year-old previously healthy man is brought to the emergency department after being involved in a motor vehicle accident. He has significant blunt chest and head trauma. Shortly after he arrives, his blood pressure drops suddenly and he begins experiencing respiratory distress. On physical examination, the patient is tachycardic and tachypneic. His lungs are clear to auscultation with vesicular breath sounds heard bilaterally. He has jugular venous distention, and his systolic blood pressure falls 15 mm Hg with inspiration. Which of the following is the most likely cause of this patient's deterioration?

A. Tension pneumothorax (4%)
B. Epidural hematoma (0%)
C. Hemothorax (2%)
D. Aortic rupture (3%)
✓ E. Cardiac tamponade (88%)

Omitted
Correct answer
E

88%
Answered correctly

02 secs
Time Spent

02/03/2020
Last Updated

Explanation

This patient has pulsus paradoxus (a fall in systolic blood pressure ≥ 10 mm Hg on inspiration), jugular venous distention, and tachycardia. Based on his history and physical examination findings, cardiac tamponade is the most likely diagnosis. Cardiac tamponade should be suspected in any patient who has the characteristic triad of muffled heart sounds, jugular venous distention, and hypotension.

During inspiration, the pressure in the pleural space and lung interstitium decreases, increasing pulmonary vascular capacitance. This causes a fall in venous inflow to the left heart, resulting in decreased left ventricular stroke volume and a drop in systolic blood pressure (normally < 10 mm

This patient has pulsus paradoxus (a fall in systolic blood pressure ≥ 10 mm Hg on inspiration), jugular venous distention, and tachycardia. Based on his history and physical examination findings, cardiac tamponade is the most likely diagnosis. Cardiac tamponade should be suspected in any patient who has the characteristic triad of muffled heart sounds, jugular venous distention, and hypotension.

During inspiration, the pressure in the pleural space and lung interstitium decreases, increasing pulmonary vascular capacitance. This causes a fall in venous inflow to the left heart, resulting in decreased left ventricular stroke volume and a drop in systolic blood pressure (normally < 10 mm Hg). The inspiratory drop in systolic blood pressure is exacerbated in cardiac tamponade due to extrinsic compression of the ventricles. This external compression acts to equalize left and right ventricular diastolic pressures, allowing the intraventricular septum to bulge into the left ventricle as a result of the inspiratory increase in right ventricular filling. This further reduces left ventricular stroke volume, leading to a drop in systolic blood pressure > 10 mm Hg.

Pulsus paradoxus can also occur in other conditions, including constrictive pericarditis, chronic obstructive pulmonary disease, asthma, and pulmonary embolism.

(Choice A) Tension pneumothorax can cause hypotension, tachycardia, tachypnea, and jugular venous distension. It can result from blunt or penetrating chest trauma that injures the visceral pleura or tracheobronchial tree. However, tension pneumothorax would cause absent breath sounds and hyperresonance to percussion on the affected side.

(Choice B) An epidural hematoma may initially cause hypertension and bradycardia due to a Cushing's response to increased intracranial pressure. If an epidural hematoma progresses to cause herniation, hypotension may follow. An epidural hematoma would not cause elevated jugular venous distension or pulsus paradoxus.

(Choice C) Blunt or penetrating chest trauma could cause a massive hemothorax with hemorrhagic hypotension, tachycardia, and tachypnea. However, absent breath sounds and dullness to percussion would be found on the affected side.

(Choice D) An aortic rupture would cause hypovolemic shock, not elevated jugular venous distension.

Educational objective:
The combination of jugular venous distension, hypotension, and muffled heart sounds is highly suggestive of cardiac tamponade. Tachycardia and pulsus paradoxus are also frequently seen with tamponade. Lung examination is normal, which can help distinguish cardiac tamponade from tension pneumothorax.

fall in venous inflow to the left heart, resulting in decreased left ventricular stroke volume and a drop in systolic blood pressure (normally < 10 mm Hg). The inspiratory drop in systolic blood pressure is exacerbated in cardiac tamponade due to extrinsic compression of the ventricles. This external compression acts to equalize left and right ventricular diastolic pressures, allowing the intraventricular septum to bulge into the left ventricle as a result of the inspiratory increase in right ventricular filling. This further reduces left ventricular stroke volume, leading to a drop in systolic blood pressure > 10 mm Hg.

Pulsus paradoxus can also occur in other conditions, including constrictive pericarditis, chronic obstructive pulmonary disease, asthma, and pulmonary embolism.

(Choice A) Tension pneumothorax can cause hypotension, tachycardia, tachypnea, and jugular venous distension. It can result from blunt or penetrating chest trauma that injures the visceral pleura or tracheobronchial tree. However, tension pneumothorax would cause absent breath sounds and hyperresonance to percussion on the affected side.

(Choice B) An epidural hematoma may initially cause hypertension and bradycardia due to a Cushing's response to increased intracranial pressure. If an epidural hematoma progresses to cause herniation, hypotension may follow. An epidural hematoma would not cause elevated jugular venous distension or pulsus paradoxus.

(Choice C) Blunt or penetrating chest trauma could cause a massive hemothorax with hemorrhagic hypotension, tachycardia, and tachypnea. However, absent breath sounds and dullness to percussion would be found on the affected side.

(Choice D) An aortic rupture would cause hypovolemic shock, not elevated jugular venous distension.

Educational objective:
The combination of jugular venous distension, hypotension, and muffled heart sounds is highly suggestive of cardiac tamponade. Tachycardia and pulsus paradoxus are also frequently seen with tamponade. Lung examination is normal, which can help distinguish cardiac tamponade from tension pneumothorax.

Pathology	Cardiovascular System	Cardiac tamponade
Subject	System	Topic

Copyright © UWorld. All rights reserved.

1
2
3
4
5
6
7
8
9
10
11
12
13
14
15
16
17
18
19
20
21
22
23
24
25
26
27
28
29

A 61-year-old woman is hospitalized due to chest pressure and shortness of breath. Two days ago her husband died in a car accident. The patient's medical history is significant for hypertension, hyperlipidemia, and gout. Five years ago, she was diagnosed with breast cancer and treated with surgery and chemotherapy. Blood pressure is 165/90 mm Hg and pulse is 95/min and regular. Physical examination is unremarkable. ECG shows normal sinus rhythm with T-wave inversions in the anterior leads. Echocardiogram shows hypokinesis of the apical wall with decreased left ventricular ejection fraction. Diagnostic coronary angiography shows no evidence of obstructive coronary artery disease. The patient is treated medically and discharged home. Four weeks later, she is seen in the office and has no symptoms. Repeat echocardiography demonstrates normal left ventricular wall motion and ejection fraction. Which of the following is the likely cause of this patient's initial presentation?

A. Catecholamine-induced myocardial stunning

B. Ischemia-induced transmural myocardial necrosis

C. Myocardial hypertrophy and fibrosis due to uncontrolled hypertension

D. Myocardial infiltration by mature lymphocytes

E. Toxin-induced myocardial injury

Submit

1
2
3
4
5
6
7
8
9
10
11
12
13
14
15
16
17
18
19
20
21
22
23
24
25
26
27
28
29

A 61-year-old woman is hospitalized due to chest pressure and shortness of breath. Two days ago her husband died in a car accident. The patient's medical history is significant for hypertension, hyperlipidemia, and gout. Five years ago, she was diagnosed with breast cancer and treated with surgery and chemotherapy. Blood pressure is 165/90 mm Hg and pulse is 95/min and regular. Physical examination is unremarkable. ECG shows normal sinus rhythm with T-wave inversions in the anterior leads. Echocardiogram shows hypokinesis of the apical wall with decreased left ventricular ejection fraction. Diagnostic coronary angiography shows no evidence of obstructive coronary artery disease. The patient is treated medically and discharged home. Four weeks later, she is seen in the office and has no symptoms. Repeat echocardiography demonstrates normal left ventricular wall motion and ejection fraction. Which of the following is the likely cause of this patient's initial presentation?

- ✓ A. Catecholamine-induced myocardial stunning (83%)
- B. Ischemia-induced transmural myocardial necrosis (4%)
- C. Myocardial hypertrophy and fibrosis due to uncontrolled hypertension (4%)
- D. Myocardial infiltration by mature lymphocytes (1%)
- E. Toxin-induced myocardial injury (5%)

Omitted
Correct answer
A

83%
Answered correctly

02 secs
Time Spent

01/07/2020
Last Updated

Explanation

Normal left ventricular contraction **Takotsubo cardiomyopathy**

1
2
3
4
5
6
7
8
9
10
11
12
13
14
15
16
17
18
19
20
21
22
23
24
25
26
27
28
29

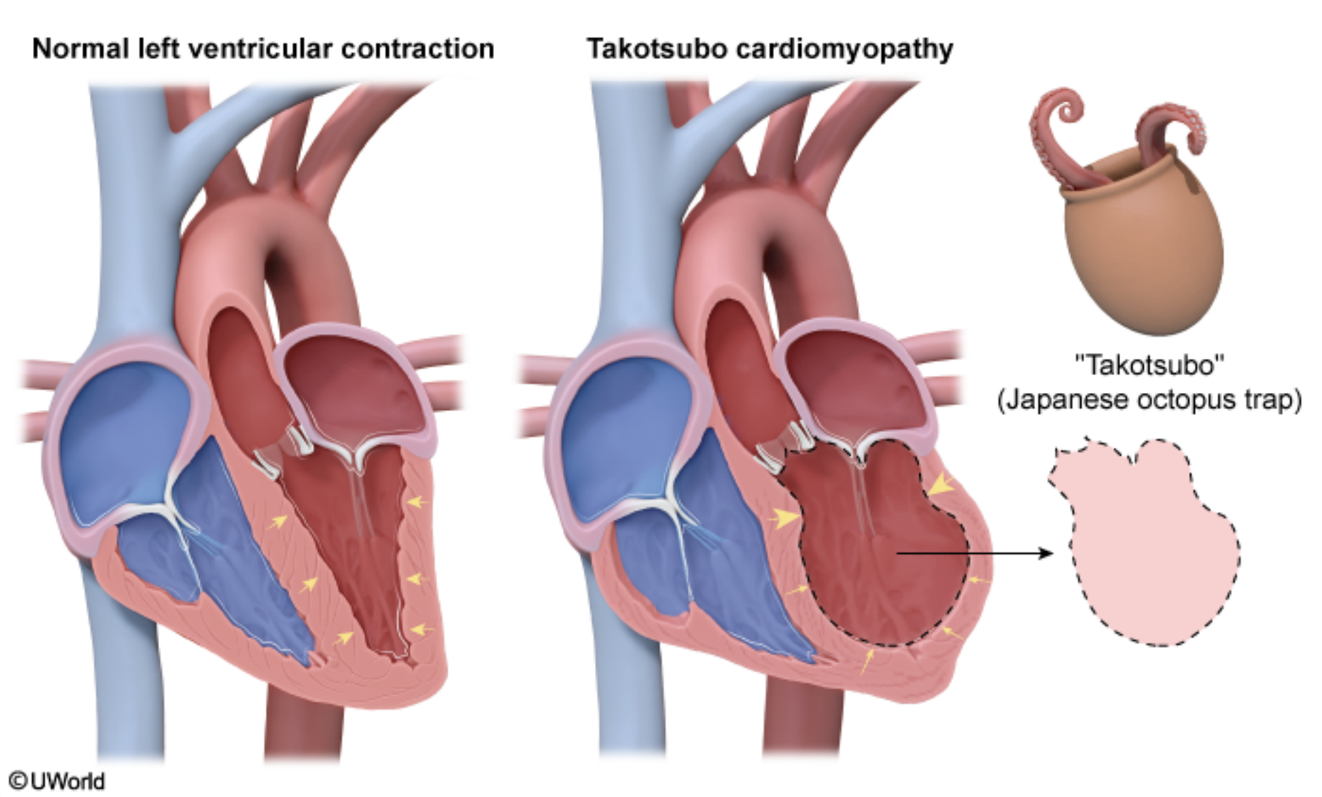

This patient likely has **stress-induced (takotsubo) cardiomyopathy**, which is characterized by hypokinesis of the mid and apical segments and hyperkinesis of the basal segments of the left ventricle (LV), leading to **systolic dysfunction** and reduced ejection fraction. The condition is likely caused by a **catecholamine surge** in the setting of **physical or emotional stress** (eg, death of a loved one). Catecholamines may cause microvascular spasm leading to ischemia and myocardial stunning or they may cause direct myocardial dysfunction. The resulting segmental LV dysfunction creates a characteristic **balloon shape** on echocardiogram that mimics that of an octopus trap (takotsubo means "octopus trap" in Japanese).

Stress-induced cardiomyopathy most commonly affects **postmenopausal women**. Patients typically have chest pain that can mimic a myocardial

©UWorld

This patient likely has **stress-induced (takotsubo) cardiomyopathy**, which is characterized by hypokinesis of the mid and apical segments and hyperkinesis of the basal segments of the left ventricle (LV), leading to **systolic dysfunction** and reduced ejection fraction. The condition is likely caused by a **catecholamine surge** in the setting of **physical or emotional stress** (eg, death of a loved one). Catecholamines may cause microvascular spasm leading to ischemia and myocardial stunning or they may cause direct myocardial dysfunction. The resulting segmental LV dysfunction creates a characteristic **balloon shape** on echocardiogram that mimics that of an octopus trap (takotsubo means "octopus trap" in Japanese).

Stress-induced cardiomyopathy most commonly affects **postmenopausal women**. Patients typically have chest pain that can mimic a myocardial infarction and may also have symptoms of heart failure (eg, dyspnea, lower extremity swelling). ECG often shows evidence of ischemia (eg, ST elevation, T-wave inversion) in the anterior precordial leads; however, coronary angiography typically reveals an **absence of obstructive coronary artery disease**. The condition usually resolves within several weeks with supportive treatment only.

(Choice B) Ischemia-induced transmural myocardial necrosis is seen in patients with acute myocardial infarction, which is unlikely in this patient with no evidence of obstructive coronary artery disease on coronary angiography.

(Choice C) LV hypertrophy due to uncontrolled hypertension typically leads to diastolic dysfunction without systolic wall motion abnormalities.

(Choices D and E) Myocardial infiltration with lymphocytes is seen in patients with acute viral myocarditis. Toxin-induced myocardial injury can occur with exposure to a variety of agents, including alcohol, cocaine, and certain chemotherapy drugs (eg, anthracyclines). These myocardial insults typically lead to dilated cardiomyopathy with global (rather than segmental) LV systolic dysfunction.

Educational objective:
Stress-induced (takotsubo) cardiomyopathy is characterized by hypokinesis of the mid and apical segments and hyperkinesis of the basal segments of the left ventricle, resulting in systolic dysfunction. The condition is likely caused by a surge of catecholamines in the setting of physical or emotional stress. It usually affects postmenopausal women and resolves on its own within several weeks.

References

- Apical ballooning syndrome or takotsubo cardiomyopathy: a systematic review.
- Neurohumoral features of myocardial stunning due to sudden emotional stress.

dysfunction creates a characteristic **balloon shape** on echocardiogram that mimics that of an octopus trap (takotsubo means "octopus trap" in Japanese).

Stress-induced cardiomyopathy most commonly affects **postmenopausal women**. Patients typically have chest pain that can mimic a myocardial infarction and may also have symptoms of heart failure (eg, dyspnea, lower extremity swelling). ECG often shows evidence of ischemia (eg, ST elevation, T-wave inversion) in the anterior precordial leads; however, coronary angiography typically reveals an **absence of obstructive coronary artery disease**. The condition usually resolves within several weeks with supportive treatment only.

(Choice B) Ischemia-induced transmural myocardial necrosis is seen in patients with acute myocardial infarction, which is unlikely in this patient with no evidence of obstructive coronary artery disease on coronary angiography.

(Choice C) LV hypertrophy due to uncontrolled hypertension typically leads to diastolic dysfunction without systolic wall motion abnormalities.

(Choices D and E) Myocardial infiltration with lymphocytes is seen in patients with acute viral myocarditis. Toxin-induced myocardial injury can occur with exposure to a variety of agents, including alcohol, cocaine, and certain chemotherapy drugs (eg, anthracyclines). These myocardial insults typically lead to dilated cardiomyopathy with global (rather than segmental) LV systolic dysfunction.

Educational objective:
Stress-induced (takotsubo) cardiomyopathy is characterized by hypokinesis of the mid and apical segments and hyperkinesis of the basal segments of the left ventricle, resulting in systolic dysfunction. The condition is likely caused by a surge of catecholamines in the setting of physical or emotional stress. It usually affects postmenopausal women and resolves on its own within several weeks.

References

- Apical ballooning syndrome or takotsubo cardiomyopathy: a systematic review.
- Neurohumoral features of myocardial stunning due to sudden emotional stress.

Pathology	Cardiovascular System	Stress cardiomyopathy
Subject	System	Topic

Copyright © UWorld. All rights reserved.

1
2
3
4
5
6
7
8
9
10
11
12
13
14
15
16
17
18
19
20
21
22
23
24
25
26
27
28
29

An 18-year-old man suddenly collapses during a high school soccer game. There was no preceding collision or trauma. Immediate resuscitation is initiated but he dies before the emergency medical team arrives. The patient had recently experienced occasional exertion-related chest discomfort and dyspnea. Otherwise, he had no significant medical history. He took no medications and did not use tobacco, alcohol, or illicit drugs. Which of the following is most likely to be seen on autopsy?

A. Atherosclerotic narrowing of the left anterior descending artery

B. Dilation of all cardiac chambers and flabby ventricular walls

C. Extracellular deposits and stiff ventricular walls

D. Myocardial hypertrophy with patchy interstitial fibrosis

E. Thrombus at the bifurcation of the main pulmonary artery

Submit

1
2
3
4
5
6
7
8
9
10
11
12
13
14
15
16
17
18
19
20
21
22
23
24
25
26
27
28
29

An 18-year-old man suddenly collapses during a high school soccer game. There was no preceding collision or trauma. Immediate resuscitation is initiated but he dies before the emergency medical team arrives. The patient had recently experienced occasional exertion-related chest discomfort and dyspnea. Otherwise, he had no significant medical history. He took no medications and did not use tobacco, alcohol, or illicit drugs. Which of the following is most likely to be seen on autopsy?

A. Atherosclerotic narrowing of the left anterior descending artery (1%)

B. Dilation of all cardiac chambers and flabby ventricular walls (10%)

C. Extracellular deposits and stiff ventricular walls (3%)

✓ D. Myocardial hypertrophy with patchy interstitial fibrosis (82%)

E. Thrombus at the bifurcation of the main pulmonary artery (1%)

Omitted
Correct answer
D

82%
Answered correctly

02 secs
Time Spent

04/07/2020
Last Updated

Explanation

Sudden cardiac death (SCD) is most often precipitated by cardiac arrhythmia (eg, ventricular tachycardia/fibrillation) that leads to markedly decreased cardiac output and impaired coronary artery perfusion. In older adults (eg, age ≥35), myocardial ischemia due to atherosclerotic coronary artery disease **(Choice A)** is the most common cause of SCD. However, young adults who experience SCD usually have underlying structural heart disease; **hypertrophic cardiomyopathy** (HCM) is one of the most common underlying diseases present. Most patients with HCM are asymptomatic, but some may experience exertional dyspnea, fatigue, chest pain, or syncope.

HCM is an autosomal dominant genetic disorder caused by mutation of one of several genes coding for cardiac sarcomere proteins. It is

1
2
3
4
5
6
7
8
9
10
11
12
13
14
15
16
17
18
19
20
21
22
23
24
25
26
27
28
29

Sudden cardiac death (SCD) is most often precipitated by cardiac arrhythmia (eg, ventricular tachycardia/fibrillation) that leads to markedly decreased cardiac output and impaired coronary artery perfusion. In older adults (eg, age ≥35), myocardial ischemia due to atherosclerotic coronary artery disease **(Choice A)** is the most common cause of SCD. However, young adults who experience SCD usually have underlying structural heart disease; **hypertrophic cardiomyopathy** (HCM) is one of the most common underlying diseases present. Most patients with HCM are asymptomatic, but some may experience exertional dyspnea, fatigue, chest pain, or syncope.

HCM is an autosomal dominant genetic disorder caused by mutation of one of several genes coding for cardiac sarcomere proteins. It is characterized by **cardiomyocyte hypertrophy** (predominantly affecting the septum) and **myofiber disarray** consisting of an irregular arrangement of abnormally shaped cardiomyocytes with bizarrely-shaped nuclei and increased interstitial fibrosis. This structural disarray leads to conduction abnormalities that predispose to ventricular arrhythmia and SCD.

(Choice B) Dilated cardiac chambers and flabby ventricular walls are consistent with dilated cardiomyopathy, a less common cause of SCD than HCM in young adults. A patient with DCM would likely have symptoms of heart failure (eg, lower extremity swelling, dyspnea, orthopnea) and would not be capable of participating in strenuous activities such as soccer.

(Choice C) Extracellular deposits and stiff ventricular walls suggest restrictive cardiomyopathy due to amyloidosis or hemochromatosis. Although restrictive cardiomyopathy can cause SCD, there is usually a preceding course of progressive and symptomatic heart failure.

(Choice E) Thrombus at the bifurcation of the main pulmonary artery (ie, saddle pulmonary embolism) is a potential cause of SCD; however, a preceding history of exertion-related dyspnea and chest discomfort would not be expected.

Educational objective:
Hypertrophic cardiomyopathy is a common cause of sudden cardiac death (SCD) in young adults. Histologic features include cardiomyocyte hypertrophy and myofiber disarray with increased interstitial fibrosis. The structural disarray creates a substrate for ventricular arrhythmia (eg, ventricular tachycardia, ventricular fibrillation) that can lead to SCD.

References

- Sudden deaths in young competitive athletes: analysis of 1866 deaths in the United States, 1980-2006.

Pathology | Cardiovascular System | Hypertrophic cardiomyopathy

1
2
3
4
5
6
7
8
9
10
11
12
13
14
15
16
17
18
19
20
21
22
23
24
25
26
27
28
29

Exhibit Display

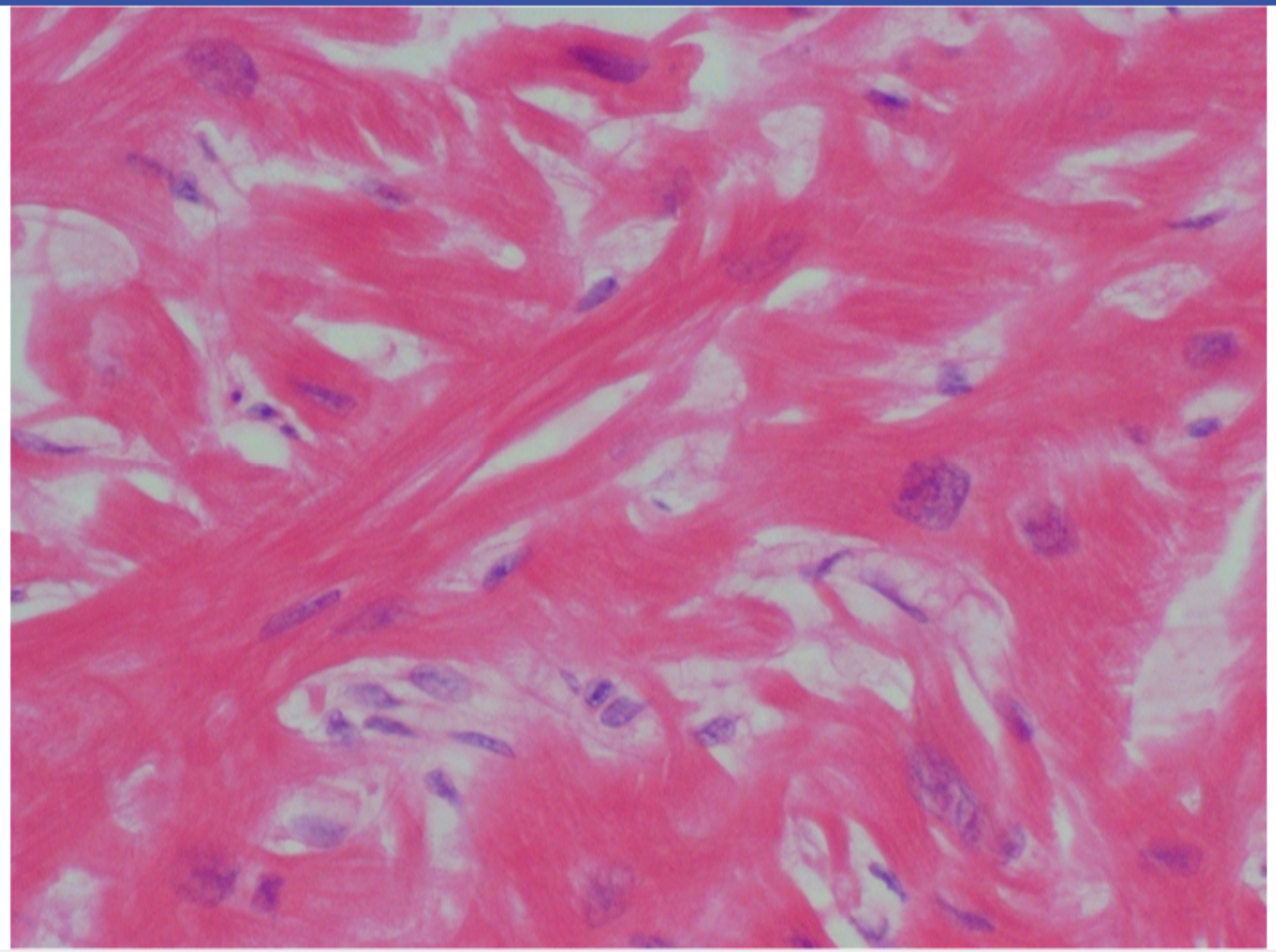

Zoom In | Zoom Out | Reset | Add To New Card | Existing Card

Pathology | Cardiovascular System | Hypertrophic cardiomyopathy

1
2
3
4
5
6
7
8
9
10
11
12
13
14
15
16
17
18
19
20
21
22
23
24
25
26
27
28
29

Exhibit Display

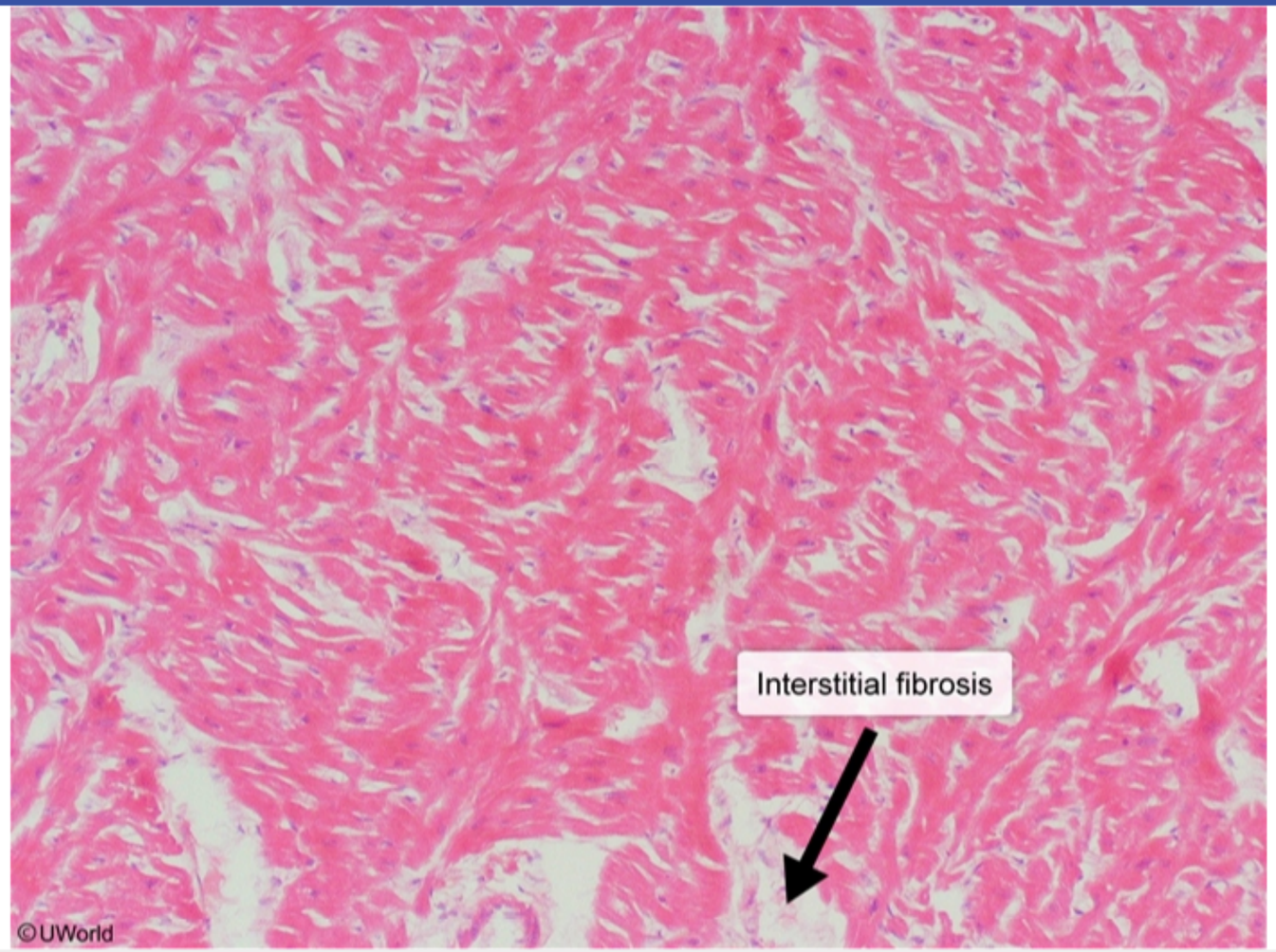

Zoom In | Zoom Out | Reset | Add To New Card | Existing Card

Pathology | Cardiovascular System | Hypertrophic cardiomyopathy

1
2
3
4
5
6
7
8
9
10
11
12
13
14
15
16
17
18
19
20
21
22
23
24
25
26
27
28
29

The following vignette applies to the next **2** items. The items in the set must be answered in sequential order. Once you click **Proceed to Next Item**, you will not be able to add or change an answer.

A 63-year-old man is brought to the emergency department due to an episode of syncope. The patient was recently discharged back to a nursing home after being hospitalized for a urinary tract infection. He has a history of coronary artery disease and takes aspirin, clopidogrel, and atorvastatin. His other medical conditions include type 2 diabetes mellitus and hypertension. The patient does not use tobacco, alcohol, or illicit drugs. Blood pressure is 68/32 mm Hg and pulse is 123/min. Invasive hemodynamic monitoring reveals an elevated right atrial pressure of 17 mm Hg and a pulmonary capillary wedge pressure of 7 mm Hg (normal: 8-10 mm Hg).

Item 1 of 2

Which of the following is the most likely cause of this patient's current condition?

- A. Anaphylactic shock
- B. Gastrointestinal bleeding
- C. Right ventricular infarction
- D. Septic shock
- E. Severe aortic stenosis

Submit

1
2
3
4
5
6
7
8
9
10
11
12
13
14
15
16
17
18
19
20
21
22
23
24
25
26
27
28
29

The following vignette applies to the next **2** items. The items in the set must be answered in sequential order. Once you click **Proceed to Next Item**, you will not be able to add or change an answer.

A 63-year-old man is brought to the emergency department due to an episode of syncope. The patient was recently discharged back to a nursing home after being hospitalized for a urinary tract infection. He has a history of coronary artery disease and takes aspirin, clopidogrel, and atorvastatin. His other medical conditions include type 2 diabetes mellitus and hypertension. The patient does not use tobacco, alcohol, or illicit drugs. Blood pressure is 68/32 mm Hg and pulse is 123/min. Invasive hemodynamic monitoring reveals an elevated right atrial pressure of 17 mm Hg and a pulmonary capillary wedge pressure of 7 mm Hg (normal: 8-10 mm Hg).

Item 1 of 2

Which of the following is the most likely cause of this patient's current condition?

- A. Anaphylactic shock (2%)
- B. Gastrointestinal bleeding (5%)
- ✓ C. Right ventricular infarction (55%)
- D. Septic shock (33%)
- E. Severe aortic stenosis (2%)

Omitted
Correct answer
C

55%
Answered correctly

02 secs
Time Spent

03/30/2020
Last Updated

Explanation

1
2
3
4
5
6
7
8
9
10
11
12
13
14
15
16
17
18
19
20
21
22
23
24
25
26
27
28
29

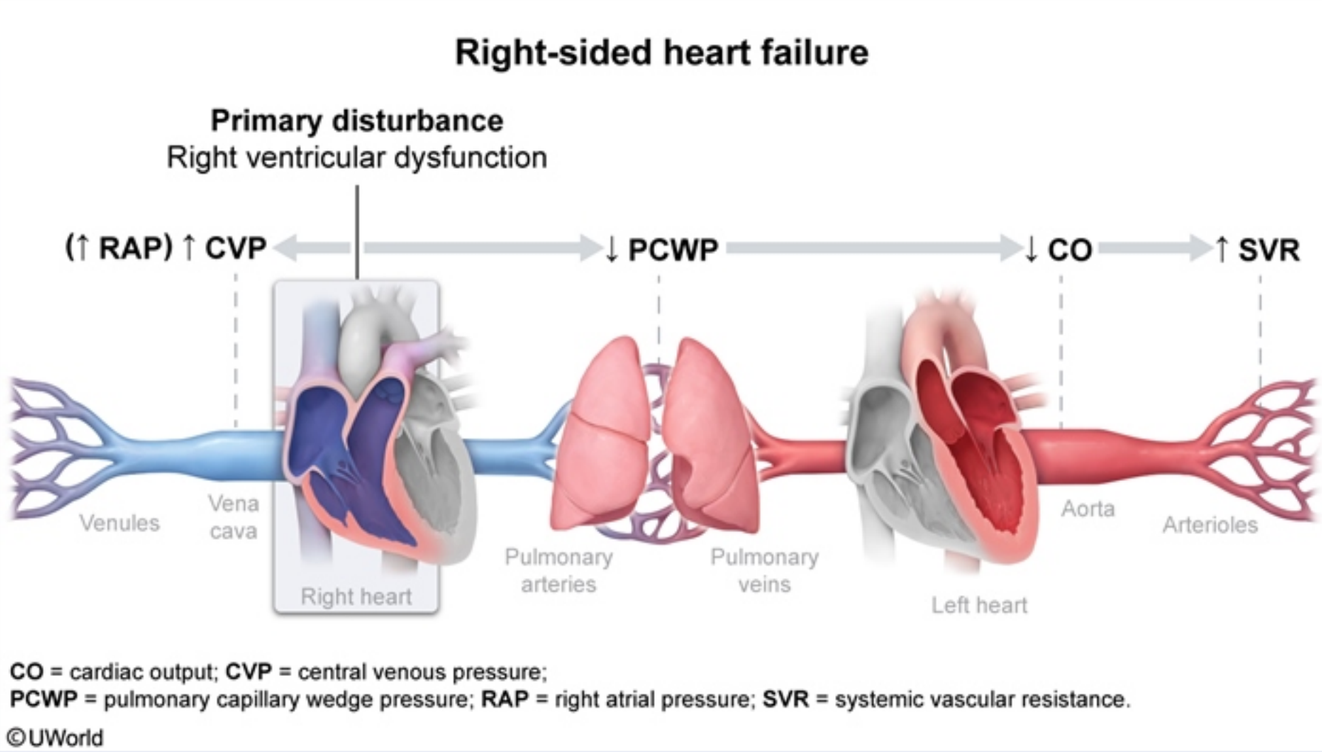

This patient is in shock (eg, severe hypotension, end organ dysfunction [syncope]) due to an unknown cause. Hemodynamic monitoring (eg, pulmonary artery catheterization) shows **decreased pulmonary capillary wedge pressure (PCWP)** and **increased right atrial pressure (RAP)**, which indicate impaired blood flow from the right ventricle to the left side of the heart **(right-sided heart failure)**. Common causes of right-sided heart failure include obstruction of pulmonary circulation (eg, pulmonary arterial hypertension, pulmonary embolism) and **right ventricular infarction** (likely in this patient due to multiple cardiovascular risk factors).

In right ventricular infarction, the right ventricle is unable to effectively pump blood forward into the pulmonary arteries, causing increased pressure in the right atrium (ie, elevated central venous pressure). The decreased right ventricular outflow also lowers PCWP (an indicator of left-sided preload), which subsequently reduces cardiac output and causes hypotension.

(Choices A and D) Anaphylactic shock and septic shock are associated with peripheral vasodilation and massive fluid shift to the extravascular

©UWorld

This patient is in shock (eg, severe hypotension, end organ dysfunction [syncope]) due to an unknown cause. Hemodynamic monitoring (eg, pulmonary artery catheterization) shows **decreased pulmonary capillary wedge pressure (PCWP)** and **increased right atrial pressure (RAP)**, which indicate impaired blood flow from the right ventricle to the left side of the heart **(right-sided heart failure)**. Common causes of right-sided heart failure include obstruction of pulmonary circulation (eg, pulmonary arterial hypertension, pulmonary embolism) and **right ventricular infarction** (likely in this patient due to multiple cardiovascular risk factors).

In right ventricular infarction, the right ventricle is unable to effectively pump blood forward into the pulmonary arteries, causing increased pressure in the right atrium (ie, elevated central venous pressure). The decreased right ventricular outflow also lowers PCWP (an indicator of left-sided preload), which subsequently reduces cardiac output and causes hypotension.

(Choices A and D) Anaphylactic shock and septic shock are associated with peripheral vasodilation and massive fluid shift to the extravascular space. The depleted intravascular volume lowers the mean circulatory filling pressure, reducing both RAP and PCWP, while hypotension caused by widespread peripheral vasodilation leads to a compensatory increase in cardiac output.

(Choice B) Gastrointestinal bleeding can cause hypovolemic shock with decreased RAP, PCWP, and cardiac output. Decreased cardiac output triggers an increase in sympathetic tone with peripheral vasoconstriction (increased systemic vascular resistance) to help maintain perfusion pressure.

(Choice E) Aortic stenosis causes left ventricular outflow obstruction and would increase pressure in the left atrium (increased PCWP) and pulmonary circulation. In severe cases, right-sided heart failure can also develop, leading to increased RAP. Systemic vascular resistance is increased with aortic stenosis in response to a reduction in cardiac output.

Educational objective:
Right ventricular infarction (right-sided heart failure) can lead to shock via impaired forward blood flow to the left heart, which lowers left-sided preload (decreased pulmonary capillary wedge pressure) and decreases cardiac output. The reduced right ventricular output also raises right atrial and central venous pressure.

Pathology	Cardiovascular System	Myocardial infarction
Subject	System	Topic

1 2 3 4 5 6 7 8 9 10 11 12 13 14 15 16 17 18 19 20 21 22 23 24 25 26 27 28 29

pulmonary artery catheterization) shows **decreased pulmonary capillary wedge pressure (PCWP)** and **increased right atrial pressure (RAP)**, which indicate impaired blood flow from the right ventricle to the left side of the heart **(right-sided heart failure)**. Common causes of right-sided heart failure include obstruction of pulmonary circulation (eg, pulmonary arterial hypertension, pulmonary embolism) and **right ventricular infarction** (likely in this patient due to multiple cardiovascular risk factors).

In right ventricular infarction, the right ventricle is unable to effectively pump blood forward into the pulmonary arteries, causing increased pressure in the right atrium (ie, elevated central venous pressure). The decreased right ventricular outflow also lowers PCWP (an indicator of left-sided preload), which subsequently reduces cardiac output and causes hypotension.

(Choices A and D) Anaphylactic shock and septic shock are associated with peripheral vasodilation and massive fluid shift to the extravascular space. The depleted intravascular volume lowers the mean circulatory filling pressure, reducing both RAP and PCWP, while hypotension caused by widespread peripheral vasodilation leads to a compensatory increase in cardiac output.

(Choice B) Gastrointestinal bleeding can cause hypovolemic shock with decreased RAP, PCWP, and cardiac output. Decreased cardiac output triggers an increase in sympathetic tone with peripheral vasoconstriction (increased systemic vascular resistance) to help maintain perfusion pressure.

(Choice E) Aortic stenosis causes left ventricular outflow obstruction and would increase pressure in the left atrium (increased PCWP) and pulmonary circulation. In severe cases, right-sided heart failure can also develop, leading to increased RAP. Systemic vascular resistance is increased with aortic stenosis in response to a reduction in cardiac output.

Educational objective:
Right ventricular infarction (right-sided heart failure) can lead to shock via impaired forward blood flow to the left heart, which lowers left-sided preload (decreased pulmonary capillary wedge pressure) and decreases cardiac output. The reduced right ventricular output also raises right atrial and central venous pressure.

Pathology	Cardiovascular System	Myocardial infarction
Subject	System	Topic

Copyright © UWorld. All rights reserved.

1
2
3
4
5
6
7
8
9
10
11
12
13
14
15
16
17
18
19
20
21
22
23
24
25
26
27
28
29

pulmonary artery catheterization) shows **decreased pulmonary capillary wedge pressure (PCWP)** and **increased right atrial pressure (RAP)**,

Exhibit Display

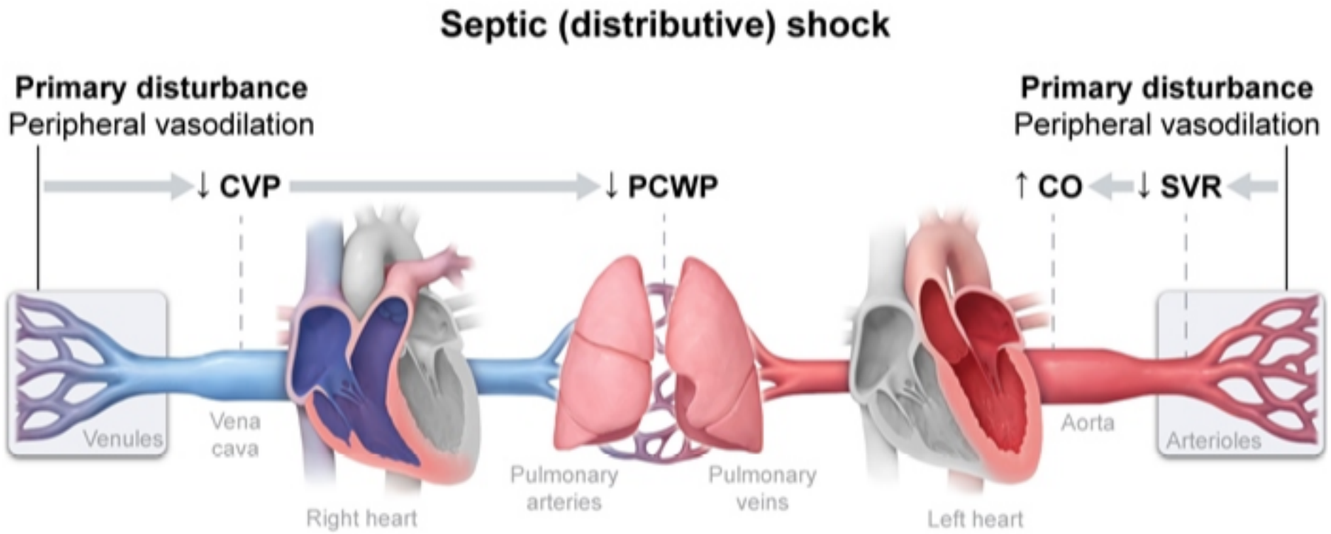

CO = cardiac output; **CVP** = central venous pressure;
PCWP = pulmonary capillary wedge pressure; **SVR** = systemic vascular resistance.

©UWorld

Zoom In | Zoom Out | Reset | Add To New Card | Existing Card

1
2
3
4
5
6
7
8
9
10
11
12
13
14
15
16
17
18
19
20
21
22
23
24
25
26
27
28
29

pulmonary artery catheterization) shows **decreased pulmonary capillary wedge pressure (PCWP)** and **increased right atrial pressure (RAP)**,

Exhibit Display

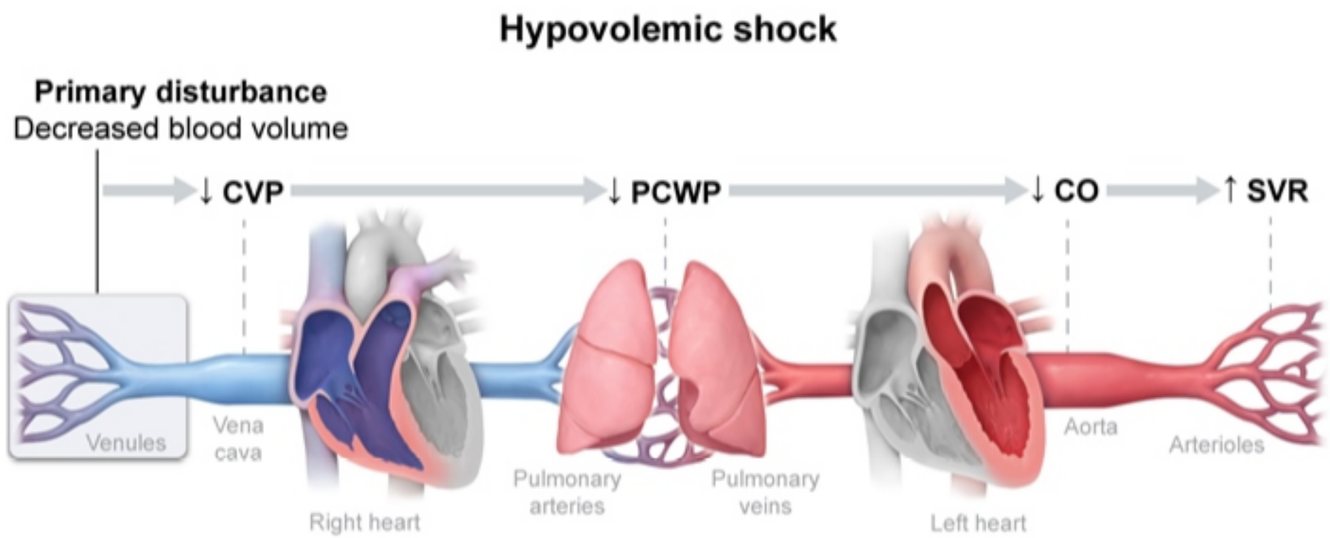

CO = cardiac output; **CVP** = central venous pressure;
PCWP = pulmonary capillary wedge pressure; **SVR** = systemic vascular resistance.

©UWorld

7
8
9
10
11
12
13
14
15
16
17
18
19
20
21
22
23
24
25
26
27
28
29
30
31
32
33
34
35

Item 2 of 2

Intravenous fluids and vasopressors are administered, but the patient remains hypotensive and dies 3 hours later. Autopsy examination is performed and reveals bilateral hippocampal necrosis. Which of the following areas of the colon would be most likely to also demonstrate necrosis?

A. Ascending colon

B. Cecum

C. Hepatic flexure

D. Ileocolic junction

E. Splenic flexure

Submit

7
8
9
10
11
12
13
14
15
16
17
18
19
20
21
22
23
24
25
26
27
28
29
30
31
32
33
34
35

Item 2 of 2

Intravenous fluids and vasopressors are administered, but the patient remains hypotensive and dies 3 hours later. Autopsy examination is performed and reveals bilateral hippocampal necrosis. Which of the following areas of the colon would be most likely to also demonstrate necrosis?

A. Ascending colon (1%)
B. Cecum (1%)
C. Hepatic flexure (2%)
D. Ileocolic junction (4%)
✓ E. Splenic flexure (89%)

Omitted
Correct answer
E

89%
Answered correctly

03 secs
Time Spent

03/30/2020
Last Updated

Explanation

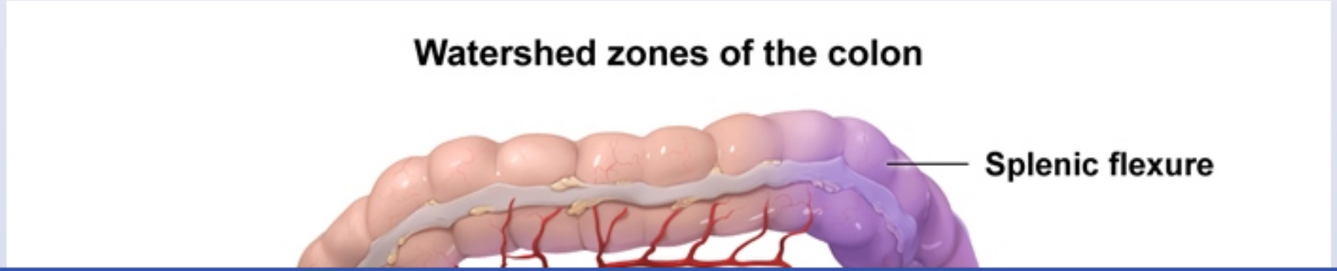

7
8
9
10
11
12
13
14
15
16
17
18
19
20
21
22
23
24
25
26
27
28
29
30
31
32
33
34
35

Watershed zones of the colon

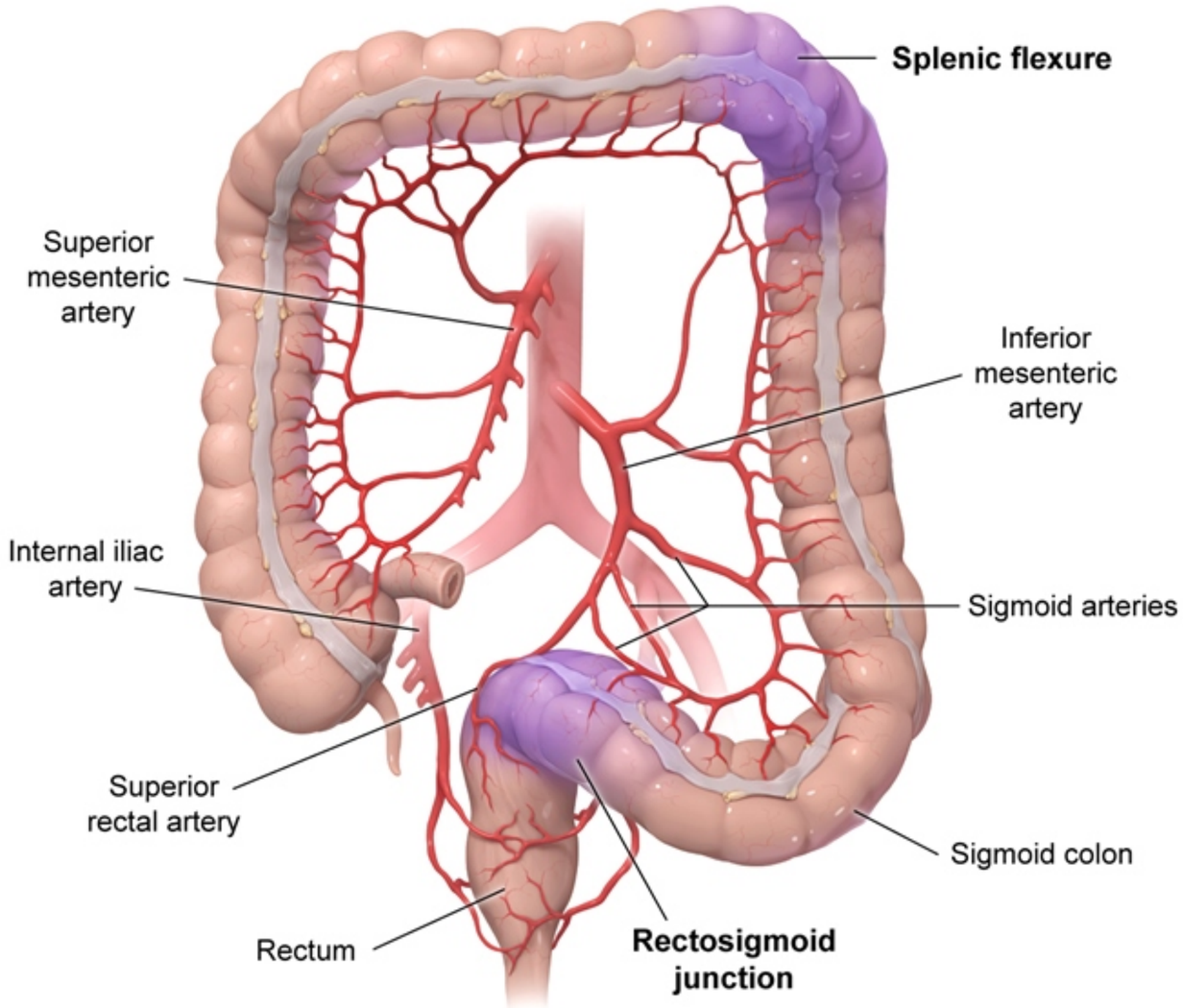

©UWorld

7
8
9
10
11
12
13
14
15
16
17
18
19
20
21
22
23
24
25
26
27
28
29
30
31
32
33
34
35

This patient's bilateral hippocampal necrosis is characteristic of the effects of global cerebral ischemia due to **systemic hypotension**. The hippocampus is particularly vulnerable during shock because of the high metabolic demand of its CA1 pyramidal neurons. **Watershed areas** located between the distal terminal branches of 2 different vascular territories (border zones) are also susceptible to ischemia because they have a low baseline perfusion pressure and poorly tolerate sustained decreases in systemic blood pressure.

Important watershed areas in the body include:

- Gastrointestinal (colon)
  - **Splenic flexure**: the border zone supplied by branches of the superior mesenteric artery and inferior mesenteric artery
  - **Rectosigmoid junction**: the border zone supplied by the sigmoid arteries and the superior rectal arteries
- Brain: the borders of the areas supplied by the anterior cerebral artery, middle cerebral artery, and posterior cerebral artery

(Choices A, B, C, and E) The ascending colon, cecum, hepatic flexure, and ileocolic junction are well perfused by the superior mesenteric artery and do not lie in watershed areas.

Educational objective:
Severe systemic hypotension (eg, shock) is most likely to cause ischemia first in areas of high metabolic demand (eg, hippocampus) or watershed zones, which are areas that are supplied by the distal branches of two different major arteries. Commonly affected areas in the colon include the splenic flexure and rectosigmoid junction.

Pathology	Cardiovascular System	Myocardial infarction
Subject	System	Topic

Copyright © UWorld. All rights reserved.

7
8
9
10
11
12
13
14
15
16
17
18
19
20
21
22
23
24
25
26
27
28
29
30
31
32
33
34
35

Exhibit Display

Cerebral watershed zones

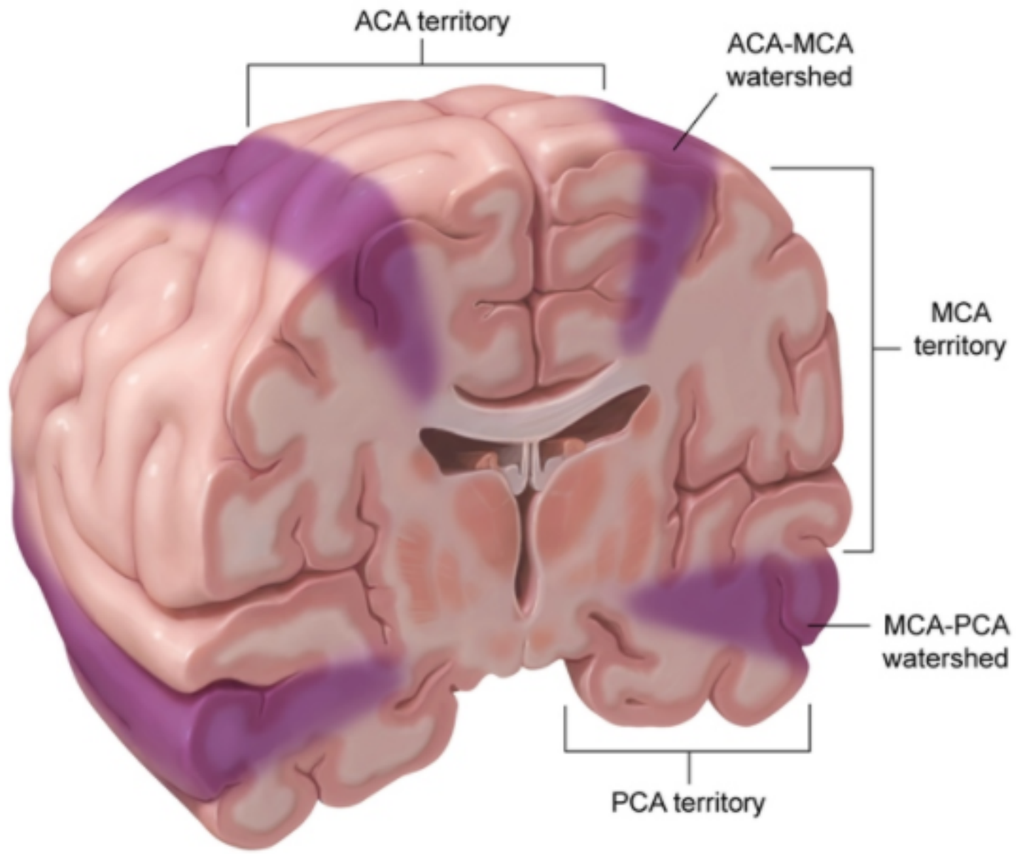

ACA = anterior cerebral artery; **MCA** = middle cerebral artery; **PCA** = posterior cerebral artery.

©UWorld

7
8
9
10
11
12
13
14
15
16
17
18
19
20
21
22
23
24
25
26
27
28
29
30
31
32
33
34
35

A 65-year-old man is admitted to the hospital with an acute ST-segment elevation myocardial infarction. The patient undergoes coronary angiography with stent placement in the left anterior descending coronary artery. On day 3 of hospitalization he experiences chest pain. The pain, described as sharp and radiating to his neck and shoulders, is exacerbated by coughing and swallowing. He has no shortness of breath, lightheadedness, or abdominal pain. The patient is treated with antiplatelet therapy and a beta blocker. Temperature is 37.5 C (99.5 F), blood pressure is 130/80 mm Hg, pulse is 90/min and regular, and respirations are 20/min. The lungs are clear on auscultation. There is no peripheral edema. Which of the following is the most likely cause of this patient's chest pain?

A. Pericardial inflammation due to autoimmune reaction to necrotic tissue

B. Pericardial inflammation due to concomitant viral infection

C. Pericardial inflammation overlying the necrotic segment of myocardium

D. Recurrent thrombosis of the culprit coronary vessel

E. Thrombosis of a nonculprit coronary vessel

Submit

7
8
9
10
11
12
13
14
15
16
17
18
19
20
21
22
23
24
25
26
27
28
29
30
31
32
33
34
35

A 65-year-old man is admitted to the hospital with an acute ST-segment elevation myocardial infarction. The patient undergoes coronary angiography with stent placement in the left anterior descending coronary artery. On day 3 of hospitalization he experiences chest pain. The pain, described as sharp and radiating to his neck and shoulders, is exacerbated by coughing and swallowing. He has no shortness of breath, lightheadedness, or abdominal pain. The patient is treated with antiplatelet therapy and a beta blocker. Temperature is 37.5 C (99.5 F), blood pressure is 130/80 mm Hg, pulse is 90/min and regular, and respirations are 20/min. The lungs are clear on auscultation. There is no peripheral edema. Which of the following is the most likely cause of this patient's chest pain?

A. Pericardial inflammation due to autoimmune reaction to necrotic tissue (14%)

B. Pericardial inflammation due to concomitant viral infection (2%)

✓ C. Pericardial inflammation overlying the necrotic segment of myocardium (69%)

D. Recurrent thrombosis of the culprit coronary vessel (8%)

E. Thrombosis of a nonculprit coronary vessel (5%)

Omitted
Correct answer
C

69%
Answered correctly

02 secs
Time Spent

03/23/2020
Last Updated

Explanation

Acute pericarditis	
	• Viral or idiopathic • Autoimmune disease (eg, SLE)

7
8
9
10
11
12
13
14
15
16
17
18
19
20
21
22
23
24
25
26
27
28
29
30
31
32
33
34
35

Acute pericarditis	

Etiology	• Viral or idiopathic
	• Autoimmune disease (eg, SLE)
	• Uremia (acute or chronic renal failure)
	• Post myocardial infarction
	  ◦ Early: peri-infarction pericarditis
	  ◦ Late: Dressler syndrome

Clinical features & diagnosis	• Pleuritic chest pain (↓ when sitting up) ± fever • Pericardial friction rub • ECG: diffuse ST elevation • Pericardial effusion on echocardiogram

SLE = systemic lupus erythematosus.

The **sharp** and **pleuritic** nature of this patient's new chest pain suggests pericardial involvement. The exacerbation with swallowing indicates that the posterior pericardium may be involved, and the radiation into the neck suggests involvement of the inferior pericardium, which is adjacent to phrenic nerve afferents supplying the diaphragm. The patient's low-grade fever indicates that this is an inflammatory process.

A fibrinous or serofibrinous pericarditis, known as **peri-infarction pericarditis** (PIP), develops in about 10%-20% of patients between **2 and 4 days** following a **transmural myocardial infarction** (MI). This pericarditis is a reaction to necrosis of the myocardium near the epicardial surface; delayed treatment presentation increases the risk of PIP due to higher levels of necrosis. Inflammation of the visceral and parietal pericardium is usually localized to the areas overlying the necrotic myocardial segment. The condition is generally short-lived and resolves with 1-3 days of aspirin therapy.

(Choice A) Dressler syndrome (postcardiac injury syndrome) is an autoimmune-mediated pericarditis that is likely provoked by antigens exposed or created by infarction and necrosis of the cardiac muscle. It is less common and has later onset than PIP, typically occurring a week to a few months after an MI. The pericardium is often diffusely affected in Dressler syndrome.

(Choice B) Viral pericarditis usually follows an antecedent upper respiratory infection. However, a viral cause for this patient's pericarditis is less likely than PIP as a direct complication of his transmural infarction.

7
8
9
10
11
12
13
14
15
16
17
18
19
20
21
22
23
24
25
26
27
28
29
30
31
32
33
34
35

The **sharp** and **pleuritic** nature of this patient's new chest pain suggests pericardial involvement. The exacerbation with swallowing indicates that the posterior pericardium may be involved, and the radiation into the neck suggests involvement of the inferior pericardium, which is adjacent to phrenic nerve afferents supplying the diaphragm. The patient's low-grade fever indicates that this is an inflammatory process.

A fibrinous or serofibrinous pericarditis, known as **peri-infarction pericarditis** (PIP), develops in about 10%-20% of patients between **2 and 4 days** following a **transmural myocardial infarction** (MI). This pericarditis is a reaction to necrosis of the myocardium near the epicardial surface; delayed treatment presentation increases the risk of PIP due to higher levels of necrosis. Inflammation of the visceral and parietal pericardium is usually localized to the areas overlying the necrotic myocardial segment. The condition is generally short-lived and resolves with 1-3 days of aspirin therapy.

(Choice A) Dressler syndrome (postcardiac injury syndrome) is an autoimmune-mediated pericarditis that is likely provoked by antigens exposed or created by infarction and necrosis of the cardiac muscle. It is less common and has later onset than PIP, typically occurring a week to a few months after an MI. The pericardium is often diffusely affected in Dressler syndrome.

(Choice B) Viral pericarditis usually follows an antecedent upper respiratory infection. However, a viral cause for this patient's pericarditis is less likely than PIP as a direct complication of his transmural infarction.

(Choices D and E) Recurrent thrombosis of the recently stented vessel or thrombosis of another coronary vessel would be expected to cause similar pain to the patient's original, anginal type of pain. The pain of myocardial ischemia is not typically sharp or pleuritic, but rather constant, substernal, and "crushing."

Educational objective:
In contrast to angina, the chest pain of pericarditis is sharp and pleuritic and may be exacerbated by swallowing or coughing. Peri-infarction pericarditis (PIP) occurs between 2 and 4 days following a transmural myocardial infarction (MI). PIP is an inflammatory reaction to cardiac muscle necrosis that occurs in the adjacent pericardium.

Pathology	Cardiovascular System	Acute pericarditis
Subject	System	Topic

Copyright © UWorld. All rights reserved.

7
8
9
10
11
12
13
14
15
16
17
18
19
20
21
22
23
24
25
26
27
28
29
30
31
32
33
34
35

A 64-year-old man dies suddenly while playing tennis. In the preceding months, the patient experienced fatigue and some exertional dyspnea. Autopsy reveals rupture of an unsuspected ascending aortic aneurysm. Heart examination shows a septal thickness of 1.2 cm (normal: <1.1), a posterior wall thickness of 1.2 cm (normal: <1.1), and an internal left ventricular diameter of 6.8 cm (normal: 3.5-5.9). No focal myocardial scarring is seen. Which of the following is the most likely cause of the cardiac findings seen in this individual?

A. Aortic regurgitation
B. Aortic stenosis
C. Hypertrophic cardiomyopathy
D. Obstructive coronary artery disease
E. Restrictive cardiomyopathy

Submit

7
8
9
10
11
12
13
14
15
16
17
18
19
20
21
22
23
24
25
26
27
28
29
30
31
32
33
34
35

A 64-year-old man dies suddenly while playing tennis. In the preceding months, the patient experienced fatigue and some exertional dyspnea. Autopsy reveals rupture of an unsuspected ascending aortic aneurysm. Heart examination shows a septal thickness of 1.2 cm (normal: <1.1), a posterior wall thickness of 1.2 cm (normal: <1.1), and an internal left ventricular diameter of 6.8 cm (normal: 3.5-5.9). No focal myocardial scarring is seen. Which of the following is the most likely cause of the cardiac findings seen in this individual?

- ✓ A. Aortic regurgitation (57%)
- B. Aortic stenosis (22%)
- C. Hypertrophic cardiomyopathy (14%)
- D. Obstructive coronary artery disease (2%)
- E. Restrictive cardiomyopathy (3%)

Omitted
Correct answer
A

57%
Answered correctly

02 secs
Time Spent

01/28/2020
Last Updated

Explanation

7
8
9
10
11
12
13
14
15
16
17
18
19
20
21
22
23
24
25
26
27
28
29
30
31
32
33
34
35

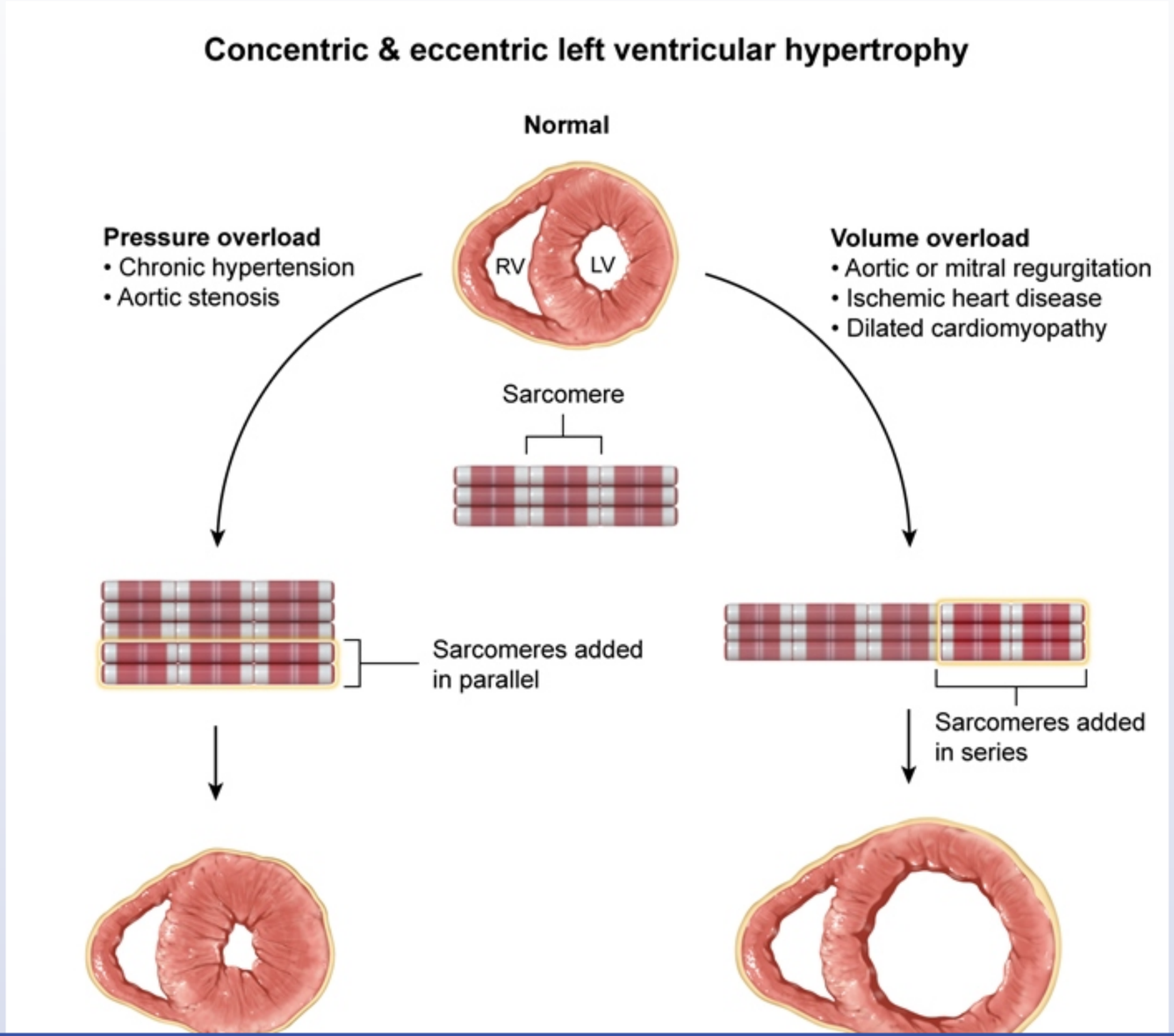

7
8
9
10
11
12
13
14
15
16
17
18
19
20
21
22
23
24
25
26
27
28
29
30
31
32
33
34
35

Exhibit Display

Concentric & eccentric left ventricular hypertrophy

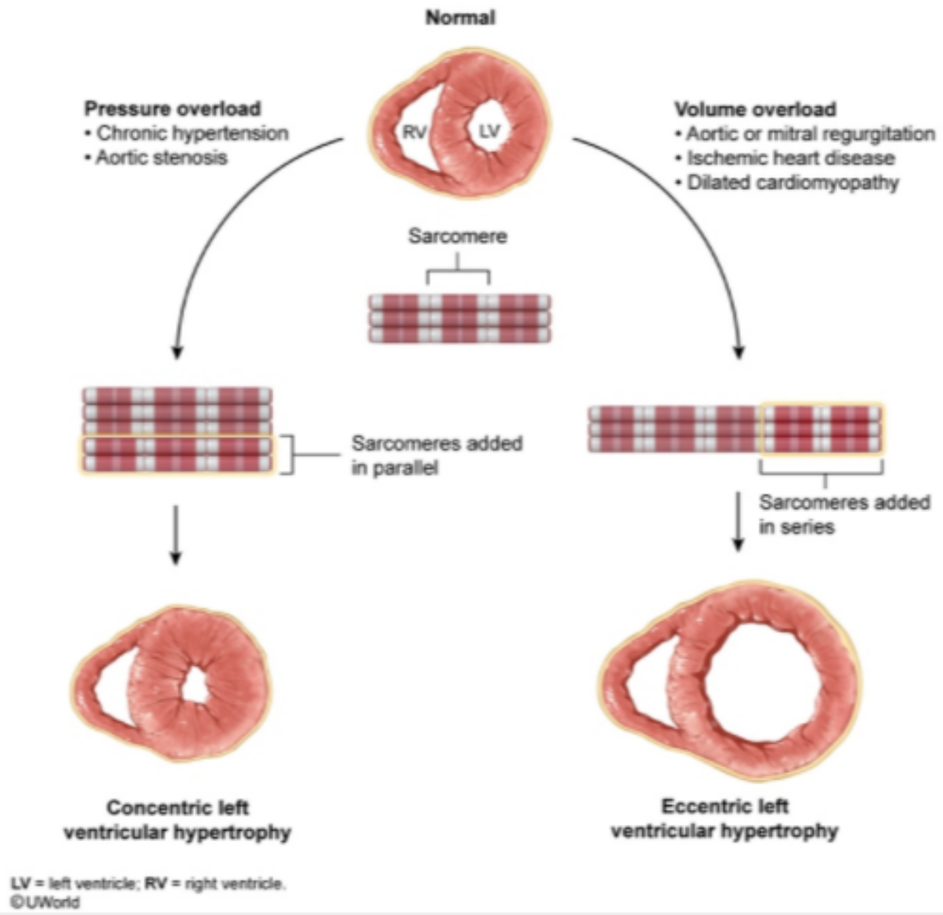

Zoom In | Zoom Out | Reset | Add To New Card | Existing Card

7
8
9
10
11
12
13
14
15
16
17
18
19
20
21
22
23
24
25
26
27
28
29
30
31
32
33
34
35

This individual's autopsy reveals a **dilated left ventricular (LV) cavity** with relatively thin ventricular walls, a finding consistent with **eccentric hypertrophy**. Eccentric hypertrophy results from the addition of myocardial contractile fibers in series in response to chronic **volume overload**. The adaptation allows the left ventricle to increase stroke volume and maintain cardiac output; however, LV wall stress increases, resulting in eventual decompensation and the development of heart failure. Common causes of eccentric hypertrophy include cardiomyopathy, ischemic heart disease, and chronic aortic or mitral valve regurgitation.

In developed countries, **aortic root dilation** is one of the most common causes of **chronic aortic regurgitation**. This individual with an ascending aortic aneurysm likely had aortic root dilation with consequent chronic aortic regurgitation, leading to LV volume overload and eccentric hypertrophy.

(Choice B) Aortic stenosis leads to pressure overload of the left ventricle and the development of concentric hypertrophy (thickening of the LV walls via the addition of myocardial contractile fibers in parallel). However, the ventricular cavity size is typically normal or reduced (not increased).

(Choice C) Hypertrophic cardiomyopathy is an inherited cardiomyopathy that involves localized thickening of the LV septal wall and resulting LV outflow tract obstruction. Although sudden cardiac death can occur (mostly in young athletes), the uniform thickness of this patient's ventricular walls and enlarged chamber size is more consistent with eccentric hypertrophy due to aortic regurgitation.

(Choice D) Obstructive coronary artery disease can lead to eccentric hypertrophy via myocardial contractile dysfunction and consequent LV volume overload (ie, ischemic heart disease). However, chronic aortic regurgitation is more likely in this individual with ascending aortic aneurysm and no evidence of myocardial scarring (scarring would suggest previous myocardial infarction).

(Choice E) Restrictive cardiomyopathy involves a decrease, rather than an increase, in the LV cavity size.

Educational objective:
Eccentric ventricular hypertrophy results in a dilated cavity with relatively thin ventricular walls due to the addition of myocardial contractile fibers in series in response to chronic volume overload. Chronic aortic regurgitation can result from aortic root dilation and is a common cause of eccentric hypertrophy.

Pathology	Cardiovascular System	Aortic regurgitation
Subject	System	Topic

This individual's autopsy reveals a **dilated left ventricular (LV) cavity** with relatively thin ventricular walls, a finding consistent with **eccentric**

Exhibit Display

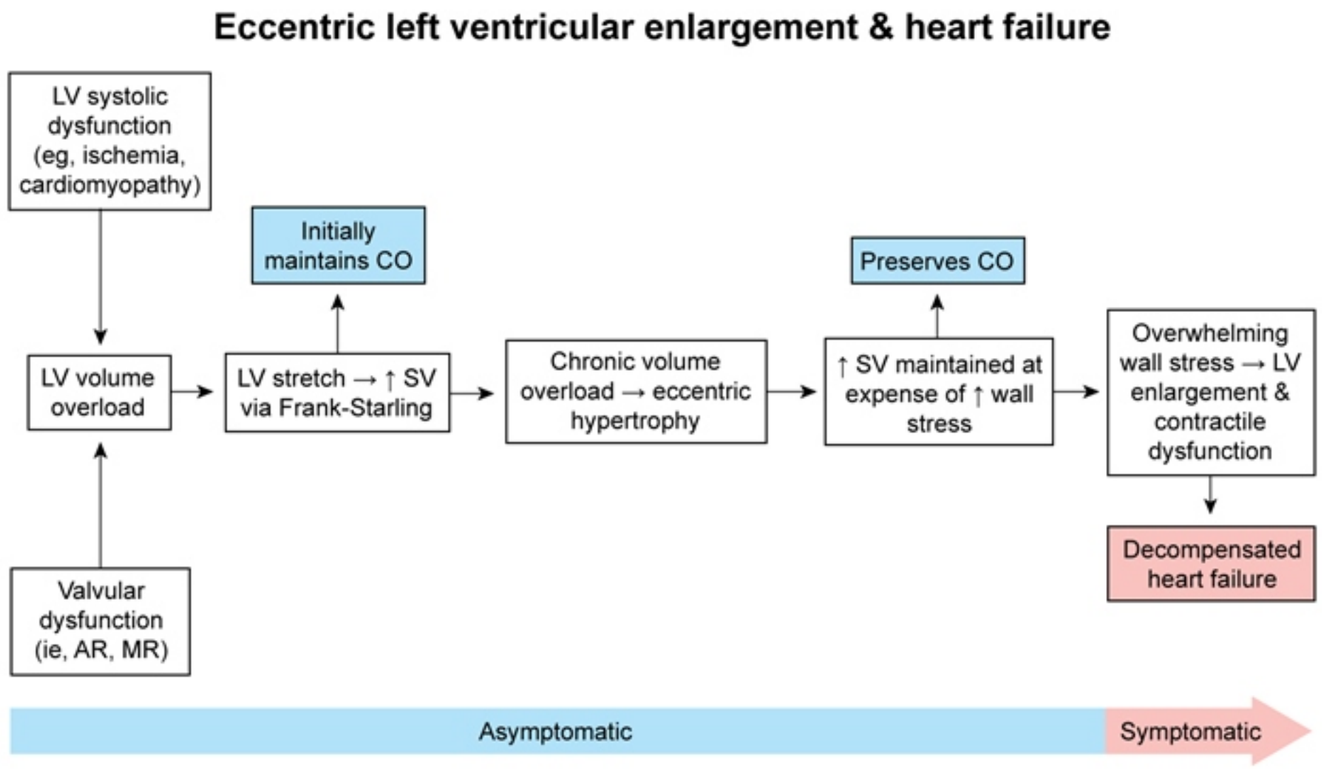

AR = aortic regurgitation; **CO** = cardiac output; **LV** = left ventricular; **MR** = mitral regurgitation; **SV** = stroke volume.
©UWorld

Zoom In | Zoom Out | Reset | Add To New Card | Existing Card

Subject System Topic

7
8
9
10
11
12
13
14
15
16
17
18
19
20
21
22
23
24
25
26
27
28
29
30
31
32
33
34
35

A 63-year-old man comes to the emergency department with 2 hours of chest pain and shortness of breath. The pain started as lower sternal discomfort that he attributed to indigestion, but then spread all over the anterior chest. The patient has never had similar pain before. Medical history includes hypertension, hyperlipidemia, and diet-controlled type 2 diabetes mellitus. The patient is an ex-smoker with a 20-pack-year history. On cardiac auscultation, a systolic murmur is heard. Basilar crackles are present on both sides. After initial evaluation, the patient is taken to the cardiac catheterization laboratory and is found to have a coronary artery occlusion, which is successfully revascularized. The next morning, the patient appears comfortable and wants to go home. The lungs are clear on auscultation, and no heart murmur is present. The murmur heard during initial presentation is most likely explained by a pathologic process involving which of the following structures?

A. Aortic root
B. Aortic valve leaflets
C. Interventricular septum
D. Mitral valve chordae
E. Papillary muscle

Submit

7
8
9
10
11
12
13
14
15
16
17
18
19
20
21
22
23
24
25
26
27
28
29
30
31
32
33
34
35

A 63-year-old man comes to the emergency department with 2 hours of chest pain and shortness of breath. The pain started as lower sternal discomfort that he attributed to indigestion, but then spread all over the anterior chest. The patient has never had similar pain before. Medical history includes hypertension, hyperlipidemia, and diet-controlled type 2 diabetes mellitus. The patient is an ex-smoker with a 20-pack-year history. On cardiac auscultation, a systolic murmur is heard. Basilar crackles are present on both sides. After initial evaluation, the patient is taken to the cardiac catheterization laboratory and is found to have a coronary artery occlusion, which is successfully revascularized. The next morning, the patient appears comfortable and wants to go home. The lungs are clear on auscultation, and no heart murmur is present. The murmur heard during initial presentation is most likely explained by a pathologic process involving which of the following structures?

A. Aortic root (7%)

B. Aortic valve leaflets (17%)

C. Interventricular septum (7%)

D. Mitral valve chordae (22%)

✓ E. Papillary muscle (46%)

Omitted
Correct answer
E

46%
Answered correctly

09 secs
Time Spent

01/27/2020
Last Updated

Explanation

Causes of mitral regurgitation

7
8
9
10
11
12
13
14
15
16
17
18
19
20
21
22
23
24
25
26
27
28
29
30
31
32
33
34
35

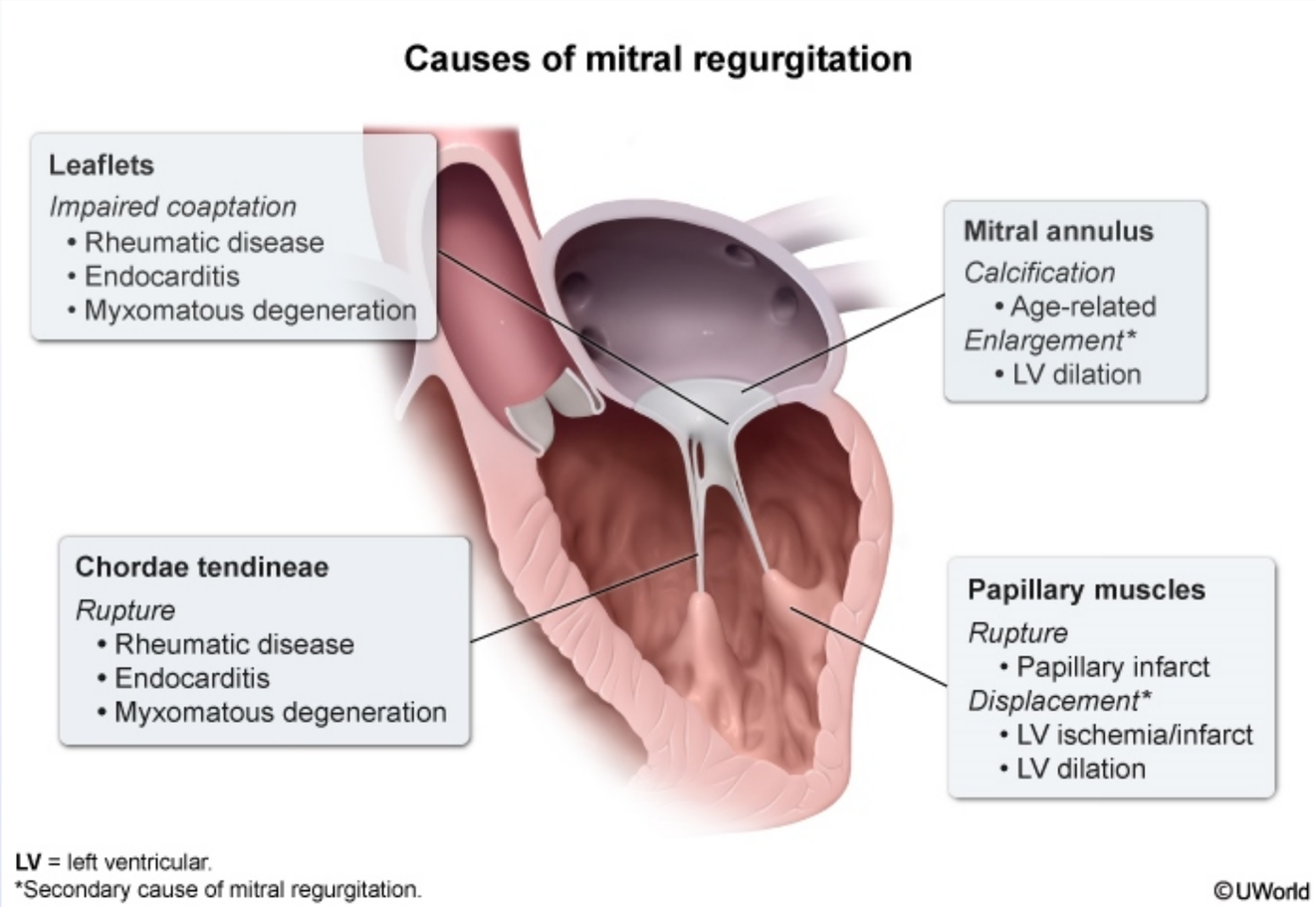

This patient with **myocardial infarction** developed a **new systolic murmur** that resolved following revascularization, which is consistent with **mitral regurgitation** (MR) due to papillary muscle dysfunction. Myocardial infarction can cause **ischemia** of the **papillary muscle** and the adjacent LV wall on which it is mounted. This results in **hypokinesis and outward displacement** of the papillary muscle, creating increased tension on the attached chordae tendineae and preventing complete closure of the corresponding mitral valve cusp. Timely restoration of adequate blood supply with coronary revascularization restores papillary muscle and LV wall motion, often leading to resolution of the MR.

In contrast to papillary muscle dysfunction, papillary muscle rupture is a mechanical complication of MI that occurs acutely or within 3-5 days and

7
8
9
10
11
12
13
14
15
16
17
18
19
20
21
22
23
24
25
26
27
28
29
30
31
32
33
34
35

Secondary cause of mitral regurgitation.

©UWorld

This patient with **myocardial infarction** developed a **new systolic murmur** that resolved following revascularization, which is consistent with **mitral regurgitation** (MR) due to papillary muscle dysfunction. Myocardial infarction can cause **ischemia** of the **papillary muscle** and the adjacent LV wall on which it is mounted. This results in **hypokinesis and outward displacement** of the papillary muscle, creating increased tension on the attached chordae tendineae and preventing complete closure of the corresponding mitral valve cusp. Timely restoration of adequate blood supply with coronary revascularization restores papillary muscle and LV wall motion, often leading to resolution of the MR.

In contrast to papillary muscle dysfunction, papillary muscle rupture is a mechanical complication of MI that occurs acutely or within 3-5 days and leads to acute MR; it does not resolve with coronary revascularization and typically requires surgical repair.

(Choices A and B) Aortic root and aortic valve leaflet function are not directly affected by myocardial ischemia and would not explain a systolic murmur during acute MI.

(Choice C) Rupture of the interventricular septum can occur acutely or within 3-5 days of acute MI. Patients have sudden-onset hypotension, dyspnea, pulmonary edema, and a harsh, holosystolic systolic murmur at the left sternal border with palpable thrill. The condition does not resolve with coronary revascularization and typically requires surgical repair.

(Choice D) Mitral valve chordae tendineae are not directly affected by myocardial ischemia; however, rupture resulting in acute MR can occur in patients with myxomatous mitral valve disease (mitral valve prolapse), rheumatic fever, or endocarditis.

Educational objective:
Myocardial infarction that causes ischemia of the papillary muscle or nearby left ventricular wall can result in acute mitral regurgitation with development of a new systolic murmur. Timely restoration of blood flow can improve papillary muscle dysfunction and lead to resolution of the regurgitation.

References

- Acute valvular regurgitation.
- Ischemic mitral regurgitation on the threshold of a solution: from paradoxes to unifying concepts.

Pathology	Cardiovascular System	Myocardial infarction
Subject	System	Topic

7 8 9 10 11 12 13 14 15 16 17 18 19 20 21 22 23 24 25 26 27 28 29 30 31 32 33 34 35

Secondary cause of mitral regurgitation. ©UWorld

This patient with **myocardial infarction** developed a **new systolic murmur** that resolved following revascularization, which is consistent with **mitral regurgitation** (MR) nd
adjacent LV wall on which c
tension on the attached ch
adequate blood supply wit

In contrast to papillary mu
leads to acute MR; it does

(Choices A and B) Aortic
murmur during acute MI.

(Choice C) Rupture of th olve
dyspnea, pulmonary eden
with coronary revasculariz

(Choice D) Mitral valve c in
patients with myxomatous

Educational objective:
Myocardial infarction that
development of a new sys
regurgitation.

References

- Acute valvular regurgi
- Ischemic mitral regurg

Exhibit Display

Mechanical complications of acute myocardial infarction

Complication	Time frame	Clinical findings
Right ventricular failure	Acute	• Hypotension • Clear lungs • Kussmaul sign
Papillary muscle rupture	Acute or within 3-5 days	• Severe MR with flail leaflet • New holosystolic murmur • Severe pulmonary edema
Interventricular septal rupture	Acute or within 3-5 days	• Chest pain • New holosystolic murmur • Biventricular failure, shock • Step up in O_2 level from RA to RV
Ventricular free-wall rupture	Within 5 days or up to 2 weeks	• Chest pain • Tamponade, shock • Distant heart sounds
Left ventricular aneurysm	Within several months	• Subacute heart failure • Stable angina

MR = mitral regurgitation; **RA** = right atrium; **RV** = right ventricle.

Add To New Card | Existing Card

Pathology	Cardiovascular System	Myocardial infarction
Subject	System	Topic

7
8
9
10
11
12
13
14
15
16
17
18
19
20
21
22
23
24
25
26
27
28
29
30
31
32
33
34
35

Autopsy of a 78-year-old man demonstrates decreased left ventricular cavity size and a sigmoid-shaped ventricular septum. Light microscopy shows increased collagen content within the ventricular wall. Some myocardial cells also have brownish perinuclear cytoplasmic inclusions. The changes described are most consistent with which of the following conditions?

A. Dilated cardiomyopathy
B. Hemolytic anemia
C. Hypertrophic cardiomyopathy
D. Ischemic heart disease
E. Long-standing hypertension
F. Normal aging

Submit

7
8
9
10
11
12
13
14
15
16
17
18
19
20
21
22
23
24
25
26
27
28
29
30
31
32
33
34
35

Autopsy of a 78-year-old man demonstrates decreased left ventricular cavity size and a sigmoid-shaped ventricular septum. Light microscopy shows increased collagen content within the ventricular wall. Some myocardial cells also have brownish perinuclear cytoplasmic inclusions. The changes described are most consistent with which of the following conditions?

- A. Dilated cardiomyopathy (2%)
- B. Hemolytic anemia (1%)
- C. Hypertrophic cardiomyopathy (18%)
- D. Ischemic heart disease (11%)
- E. Long-standing hypertension (13%)
- ✓ F. Normal aging (53%)

Omitted
Correct answer
F

53%
Answered correctly

02 secs
Time Spent

01/06/2020
Last Updated

Explanation

7
8
9
10
11
12
13
14
15
16
17
18
19
20
21
22
23
24
25
26
27
28
29
30
31
32
33
34
35

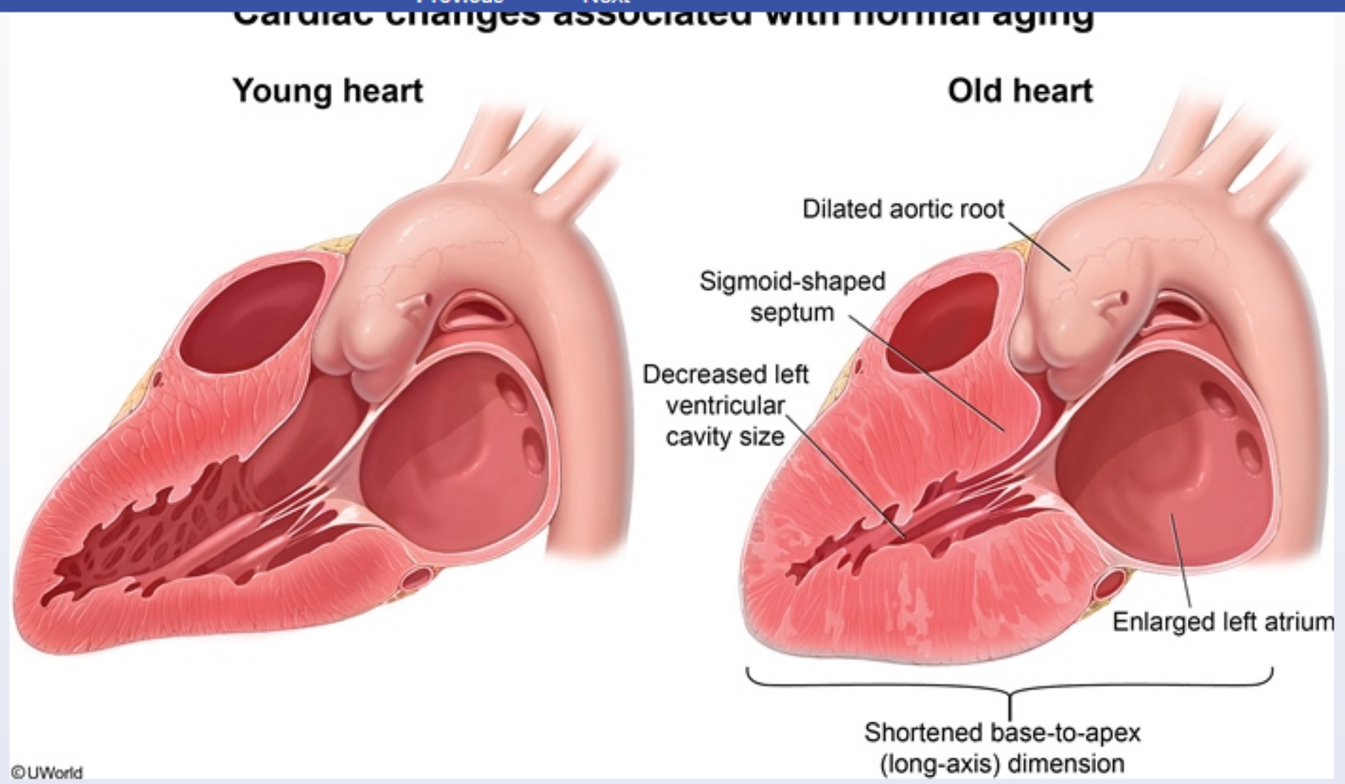

The morphologic changes described are consistent with **normal aging** of the heart. Aging is associated with **decreased left ventricular chamber size**, particularly in the apex-to-base dimension. This decrease in chamber length causes the ventricular septum to acquire a **sigmoid shape**, with the basilar portion bulging into the left ventricular outflow tract. Atrophy of the myocardium results in **increased interstitial connective tissue**, often with concomitant extracellular amyloid deposition. Within the cardiomyocytes, there is a progressive accumulation of cytoplasmic granules containing brownish **lipofuscin pigment** (the result of indigestible byproducts of subcellular membrane lipid oxidation).

(Choice A) Dilated cardiomyopathy causes an increase in the left ventricular chamber size. There is an increased risk of mural thrombi with this condition due to contractile dysfunction.

(Choice B) Chronic hemolytic anemia may result in the formation of hemosiderin granules containing excess iron inside cardiac myocytes (hemosiderosis), which can be visualized with Prussian-blue stain. Excessive deposition of iron within the myocytes usually leads to dilated or

7
8
9
10
11
12
13
14
15
16
17
18
19
20
21
22
23
24
25
26
27
28
29
30
31
32
33
34
35

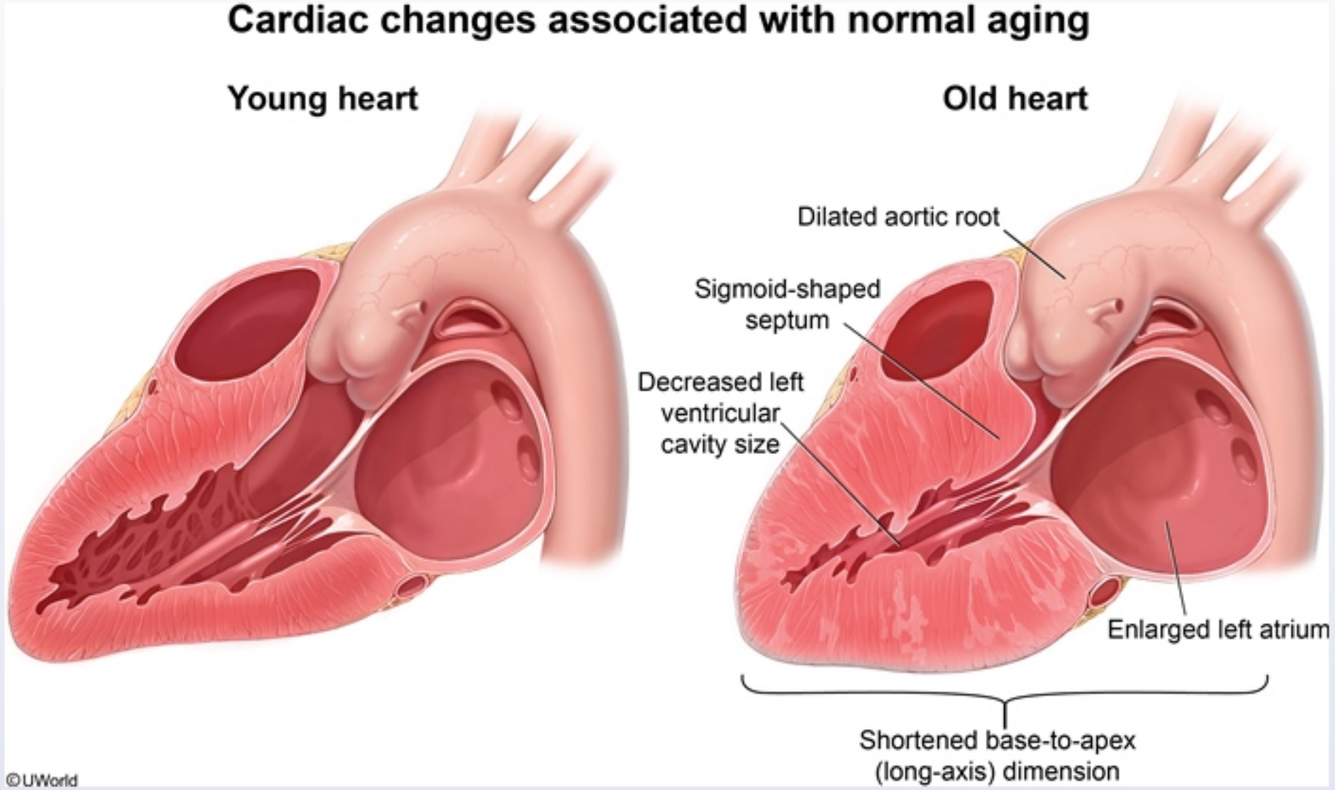

The morphologic changes described are consistent with **normal aging** of the heart. Aging is associated with **decreased left ventricular chamber size**, particularly in the apex-to-base dimension. This decrease in chamber length causes the ventricular septum to acquire a **sigmoid shape**, with the basilar portion bulging into the left ventricular outflow tract. Atrophy of the myocardium results in **increased interstitial connective tissue**, often with concomitant extracellular amyloid deposition. Within the cardiomyocytes, there is a progressive accumulation of cytoplasmic granules containing brownish **lipofuscin pigment** (the result of indigestible byproducts of subcellular membrane lipid oxidation).

(Choice A) Dilated cardiomyopathy causes an increase in the left ventricular chamber size. There is an increased risk of mural thrombi with this condition due to contractile dysfunction.

7
8
9
10
11
12
13
14
15
16
17
18
19
20
21
22
23
24
25
26
27
28
29
30
31
32
33
34
35

The morphologic changes described are consistent with **normal aging** of the heart. Aging is associated with **decreased left ventricular chamber size**, particularly in the apex-to-base dimension. This decrease in chamber length causes the ventricular septum to acquire a **sigmoid shape**, with the basilar portion bulging into the left ventricular outflow tract. Atrophy of the myocardium results in **increased interstitial connective tissue**, often with concomitant extracellular amyloid deposition. Within the cardiomyocytes, there is a progressive accumulation of cytoplasmic granules containing brownish **lipofuscin pigment** (the result of indigestible byproducts of subcellular membrane lipid oxidation).

(Choice A) Dilated cardiomyopathy causes an increase in the left ventricular chamber size. There is an increased risk of mural thrombi with this condition due to contractile dysfunction.

(Choice B) Chronic hemolytic anemia may result in the formation of hemosiderin granules containing excess iron inside cardiac myocytes (hemosiderosis), which can be visualized with Prussian-blue stain. Excessive deposition of iron within the myocytes usually leads to dilated or restrictive cardiomyopathy.

(Choice C) Hypertrophic cardiomyopathy (idiopathic hypertrophic subaortic stenosis) causes asymmetric septal hypertrophy with disproportionate thickening of the ventricular septum compared to the left ventricular free wall. Microscopic examination shows extreme myocyte hypertrophy, disorganized myocyte bundles, and myofiber disarray.

(Choice D) Chronic ischemic heart disease tends to result in progressive congestive heart failure and ventricular dilation. Histologically, the major findings are diffuse subendocardial vacuolization and fibrosis.

(Choice E) Long-standing hypertension results in hypertensive heart disease. Although left ventricular chamber size may be reduced in this condition, the major morphologic change is concentric left ventricular hypertrophy.

Educational objective:
Normal morphological changes in the aging heart include a decrease in left ventricular chamber apex-to-base dimension, development of a sigmoid-shaped ventricular septum, myocardial atrophy with increased collagen deposition, and accumulation of cytoplasmic lipofuscin pigment within cardiomyocytes.

Pathology	Cardiovascular System	Aging
Subject	System	Topic

7
8
9
10
11
12
13
14
15
16
17
18
19
20
21
22
23
24
25
26
27
28
29
30
31
32
33
34
35

chamber size, particularly in the apex-to-base dimension. This decrease in chamber length causes the ventricular septum to acquire a **sigmoid shape**, with the basilar portion bulging into the left ventricular outflow tract. Atrophy of the myocardium results in **increased interstitial connective tissue**, often with concomitant extracellular amyloid deposition. Within the cardiomyocytes, there is a progressive accumulation of cytoplasmic granules containing brownish **lipofuscin pigment** (the result of indigestible byproducts of subcellular membrane lipid oxidation).

(Choice A) Dilated cardiomyopathy causes an increase in the left ventricular chamber size. There is an increased risk of mural thrombi with this condition due to contractile dysfunction.

(Choice B) Chronic hemolytic anemia may result in the formation of hemosiderin granules containing excess iron inside cardiac myocytes (hemosiderosis), which can be visualized with Prussian-blue stain. Excessive deposition of iron within the myocytes usually leads to dilated or restrictive cardiomyopathy.

(Choice C) Hypertrophic cardiomyopathy (idiopathic hypertrophic subaortic stenosis) causes asymmetric septal hypertrophy with disproportionate thickening of the ventricular septum compared to the left ventricular free wall. Microscopic examination shows extreme myocyte hypertrophy, disorganized myocyte bundles, and myofiber disarray.

(Choice D) Chronic ischemic heart disease tends to result in progressive congestive heart failure and ventricular dilation. Histologically, the major findings are diffuse subendocardial vacuolization and fibrosis.

(Choice E) Long-standing hypertension results in hypertensive heart disease. Although left ventricular chamber size may be reduced in this condition, the major morphologic change is concentric left ventricular hypertrophy.

Educational objective:
Normal morphological changes in the aging heart include a decrease in left ventricular chamber apex-to-base dimension, development of a sigmoid-shaped ventricular septum, myocardial atrophy with increased collagen deposition, and accumulation of cytoplasmic lipofuscin pigment within cardiomyocytes.

Pathology	Cardiovascular System	Aging
Subject	System	Topic

Copyright © UWorld. All rights reserved.

7
8
9
10
11
12
13
14
15
16
17
18
19
20
21
22
23
24
25
26
27
28
29
30
31
32
33
34
35

A 54-year-old man comes to the emergency department due to severe shortness of breath and palpitations. During initial assessment, pulse oximetry shows 83%. Diffuse, bilateral crackles are heard on lung auscultation. Chest x-ray is consistent with pulmonary edema. ECG shows atrial fibrillation with rapid ventricular response. The patient dies despite appropriate medical care. Autopsy is performed and gross examination of the heart is shown below.

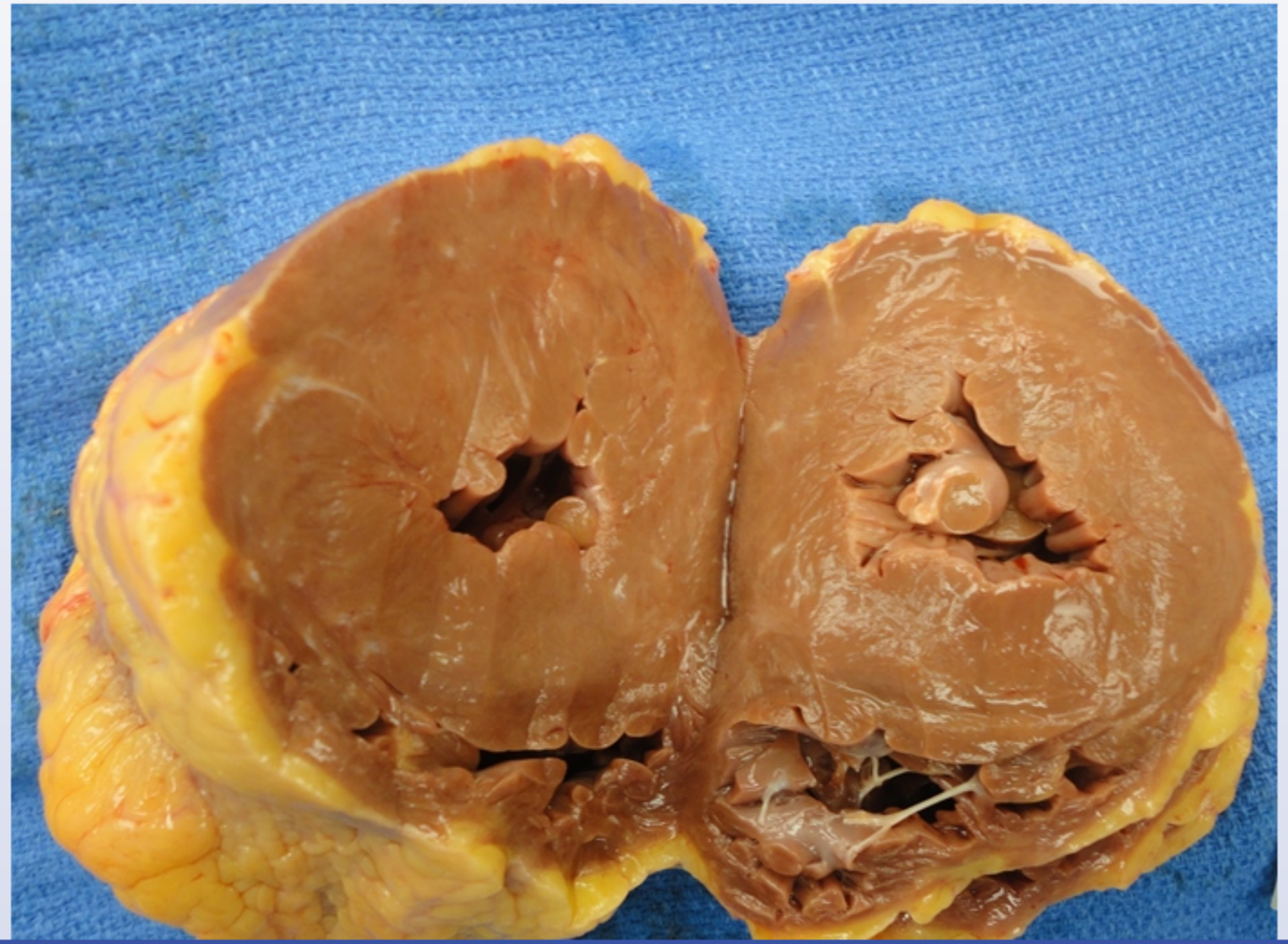

10
11
12
13
14
15
16
17
18
19
20
21
22
23
24
25
26
27
28
29
30
31
32
33
34
35
36
37
38

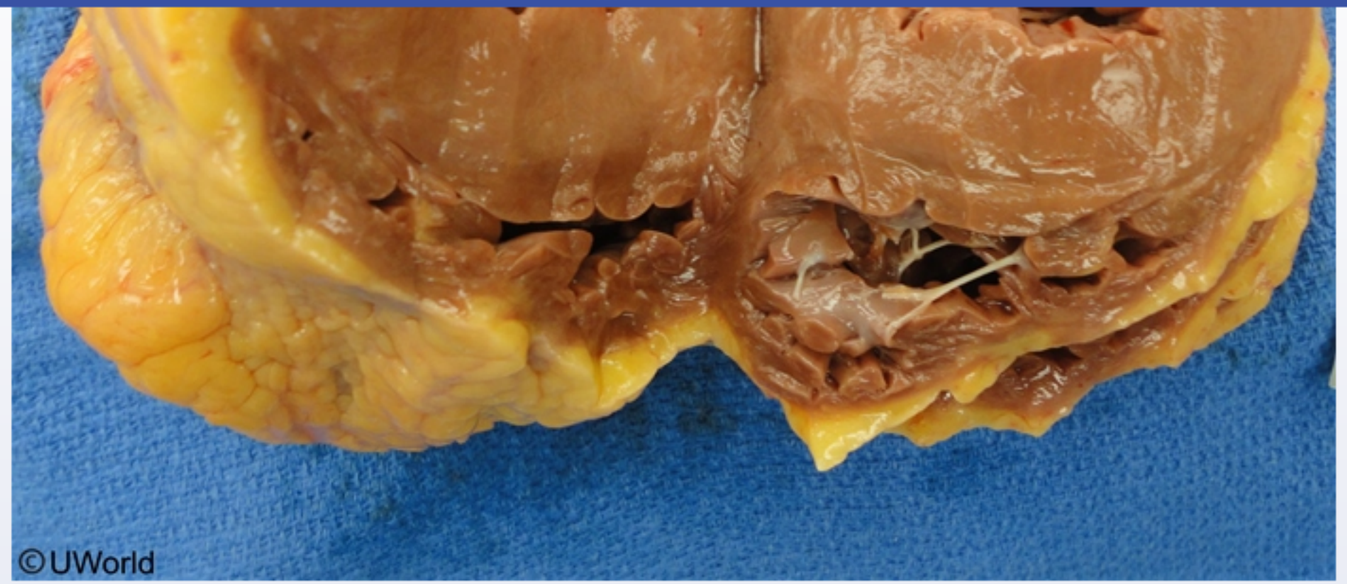

Histologic examination of the myocardial tissue reveals thick myocardial fibers with large, hyperchromatic nuclei as well as mild interstitial fibrosis. Which of the following is the most likely diagnosis?

- A. Cardiac amyloidosis
- B. Hypertensive heart disease
- C. Hypertrophic cardiomyopathy
- D. Mitral stenosis
- E. Pulmonary arterial hypertension

Submit

10
11
12
13
14
15
16
17
18
19
20
21
22
23
24
25
26
27
28
29
30
31
32
33
34
35
36
37
38

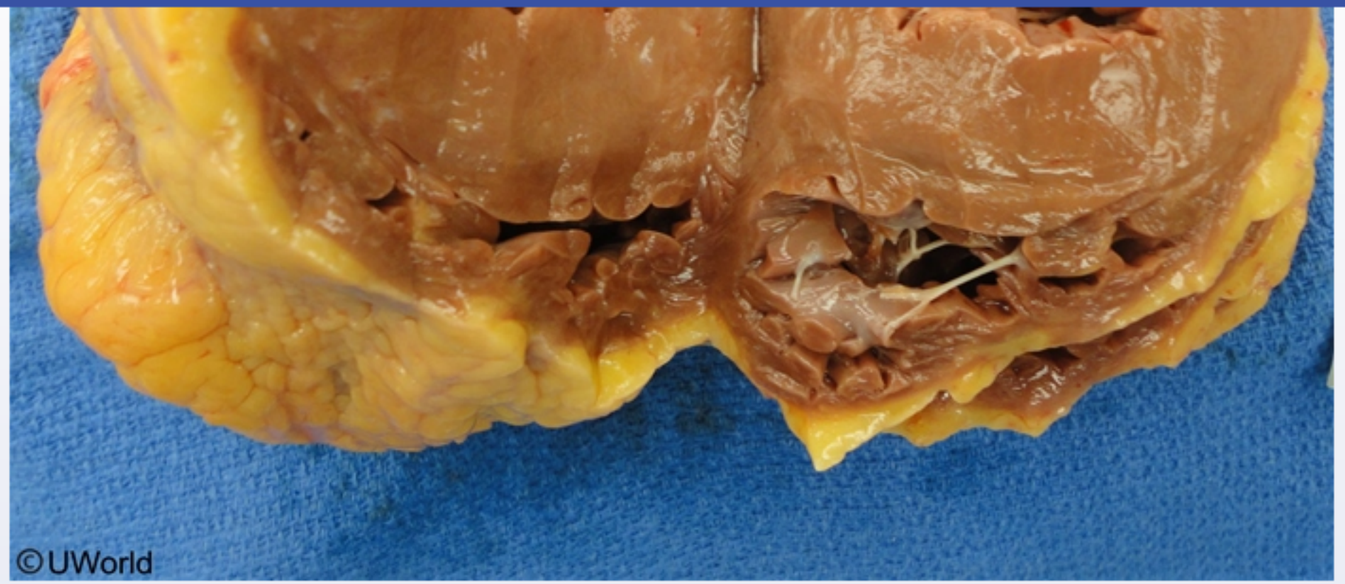

Histologic examination of the myocardial tissue reveals thick myocardial fibers with large, hyperchromatic nuclei as well as mild interstitial fibrosis. Which of the following is the most likely diagnosis?

- A. Cardiac amyloidosis (9%)
- ✓ B. Hypertensive heart disease (44%)
- C. Hypertrophic cardiomyopathy (38%)
- D. Mitral stenosis (3%)
- E. Pulmonary arterial hypertension (4%)

Omitted
Correct answer

44%
Answered correctly

02 mins, 03 secs
Time Spent

02/02/2020
Last Updated

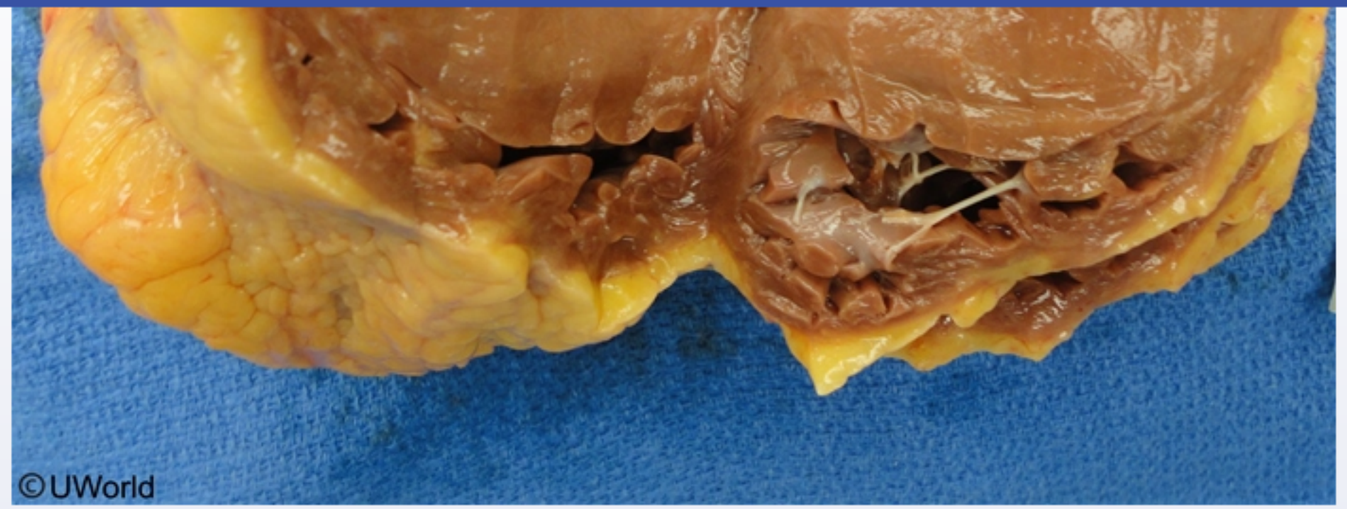

Histologic examination of the myocardial tissue reveals thick myocardial fibers with large, hyperchromatic nuclei as well as mild interstitial fibrosis. Which of the following is the most likely diagnosis?

A. Cardiac amyloidosis (9%)
✓ B. Hypertensive heart disease (44%)
C. Hypertrophic cardiomyopathy (38%)
D. Mitral stenosis (3%)
E. Pulmonary arterial hypertension (4%)

Omitted
Correct answer
B

44%
Answered correctly

02 mins, 03 secs
Time Spent

02/02/2020
Last Updated

10
11
12
13
14
15
16
17
18
19
20
21
22
23
24
25
26
27
28
29
30
31
32
33
34
35
36
37
38

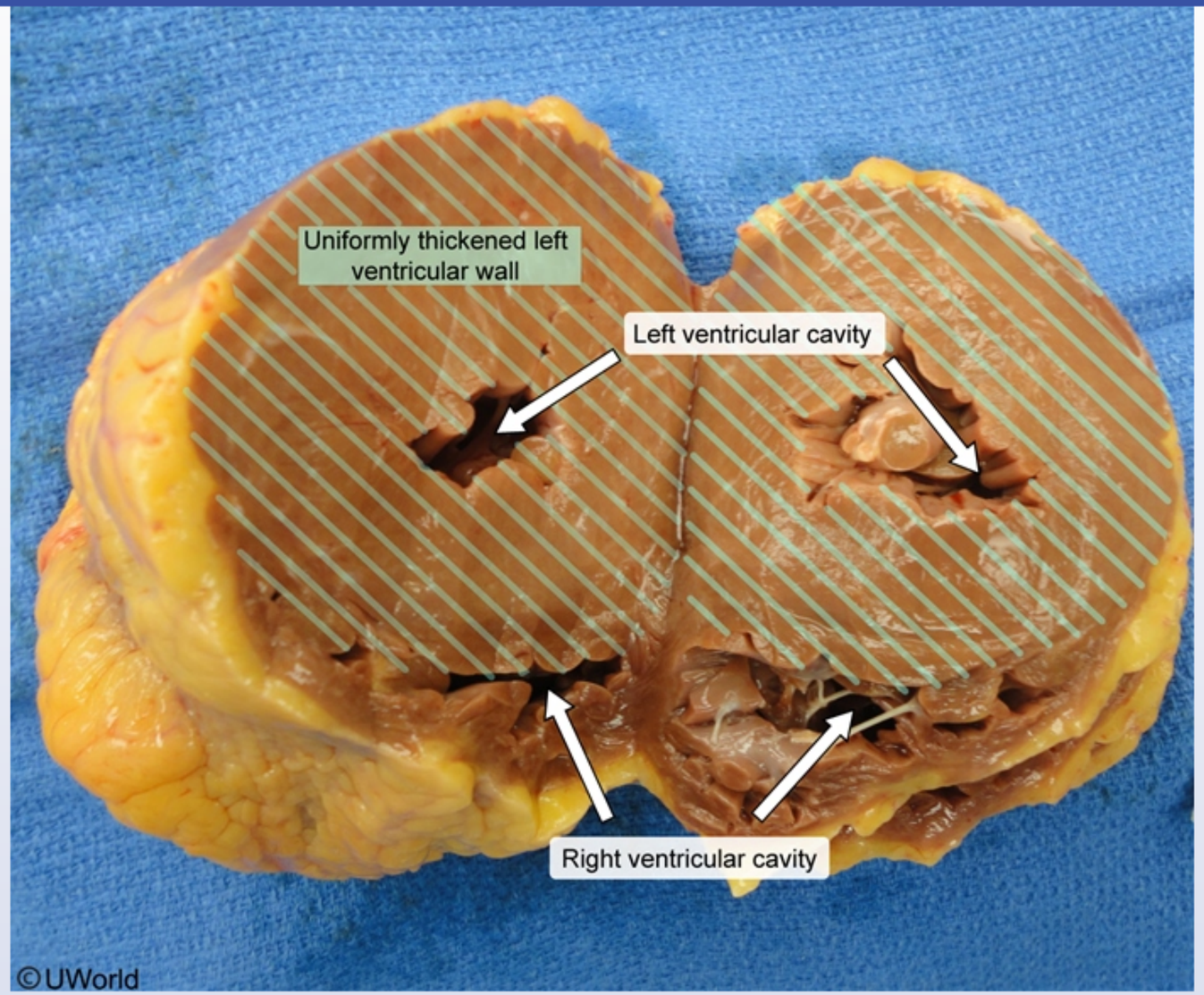

This individual developed acute decompensated heart failure (eg, shortness of breath, pulmonary edema) and likely died due to subsequent cardiogenic shock. Autopsy findings reveal **uniformly thickened** left ventricular (LV) walls and a small LV cavity, which are consistent with

©UWorld

This individual developed acute decompensated heart failure (eg, shortness of breath, pulmonary edema) and likely died due to subsequent cardiogenic shock. Autopsy findings reveal **uniformly thickened** left ventricular (LV) walls and a small LV cavity, which are consistent with concentric LV hypertrophy.

Concentric LV hypertrophy most commonly results from prolonged **systemic hypertension** as myocardial fibers are added in parallel to increase contractile strength and handle the increased pressure load. As concentric hypertrophy worsens, it can manifest clinically as **hypertensive heart disease**, consisting of **impaired diastolic filling** and heart failure with preserved ejection fraction. The elevated diastolic filling pressures are transmitted back to the left atrium, causing atrial dilation and altered conduction that predisposes to **atrial fibrillation**. Loss of atrial contraction can lead to a dramatic **reduction in left ventricular filling** in patients with diastolic heart failure, and can precipitate **acute decompensation** (as likely occured in this patient).

On histopathology, hypertensive heart disease demonstrates transverse thickening of cardiomyocytes with prominent hyperchromatic nuclei. The increased myocardial mass may be inadequately supplied with oxygen, contributing to cellular necrosis and interstitial fibrosis.

(Choice A) Cardiac amyloidosis involves deposition of abnormal proteins in the myocardium and can lead to restrictive cardiomyopathy, which is characterized by impaired diastolic filling due to stiffening, rather than thickening, of the ventricular walls. Histopathology in cardiac amyloidosis reveals collections of pink amorphous material abutting normal cardiomyocytes.

(Choice C) Hypertrophic cardiomyopathy involves localized, rather than uniform, thickening of the LV walls, predominantly affecting the interventricular septum. As in hypertensive heart disease, histopathology can reveal cardiomyocyte thickening, hyperchromatic nuclei, and interstitial fibrosis; however, cardiomyocyte disarray (loss of organized cellular alignment) is also expected.

(Choice D) Mitral stenosis causes impaired diastolic filling and can lead to decompensated heart failure and atrial fibrillation; however, it does not increase the pressure load on the left ventricle and does not cause concentric hypertrophy.

(Choice E) Pulmonary arterial hypertension results from primary changes in the pulmonary arteries that increase pulmonary arterial resistance. The elevated pressure load on the right ventricle can lead to concentric right ventricular hypertrophy and right-sided heart failure. Pulmonary edema is not present in right-sided heart failure.

Educational objective:

Concentric left ventricular (LV) hypertrophy involves uniform thickening of the LV walls with reduction in LV cavity size and most commonly results

Concentric LV hypertrophy most commonly results from prolonged **systemic hypertension** as myocardial fibers are added in parallel to increase contractile strength and handle the increased pressure load. As concentric hypertrophy worsens, it can manifest clinically as **hypertensive heart disease**, consisting of **impaired diastolic filling** and heart failure with preserved ejection fraction. The elevated diastolic filling pressures are transmitted back to the left atrium, causing atrial dilation and altered conduction that predisposes to **atrial fibrillation**. Loss of atrial contraction can lead to a dramatic **reduction in left ventricular filling** in patients with diastolic heart failure, and can precipitate **acute decompensation** (as likely occured in this patient).

On histopathology, hypertensive heart disease demonstrates transverse thickening of cardiomyocytes with prominent hyperchromatic nuclei. The increased myocardial mass may be inadequately supplied with oxygen, contributing to cellular necrosis and interstitial fibrosis.

(Choice A) Cardiac amyloidosis involves deposition of abnormal proteins in the myocardium and can lead to restrictive cardiomyopathy, which is characterized by impaired diastolic filling due to stiffening, rather than thickening, of the ventricular walls. Histopathology in cardiac amyloidosis reveals collections of pink amorphous material abutting normal cardiomyocytes.

(Choice C) Hypertrophic cardiomyopathy involves localized, rather than uniform, thickening of the LV walls, predominantly affecting the interventricular septum. As in hypertensive heart disease, histopathology can reveal cardiomyocyte thickening, hyperchromatic nuclei, and interstitial fibrosis; however, cardiomyocyte disarray (loss of organized cellular alignment) is also expected.

(Choice D) Mitral stenosis causes impaired diastolic filling and can lead to decompensated heart failure and atrial fibrillation; however, it does not increase the pressure load on the left ventricle and does not cause concentric hypertrophy.

(Choice E) Pulmonary arterial hypertension results from primary changes in the pulmonary arteries that increase pulmonary arterial resistance. The elevated pressure load on the right ventricle can lead to concentric right ventricular hypertrophy and right-sided heart failure. Pulmonary edema is not present in right-sided heart failure.

Educational objective:
Concentric left ventricular (LV) hypertrophy involves uniform thickening of the LV walls with reduction in LV cavity size and most commonly results from prolonged systemic hypertension. It can progress to hypertensive heart disease with impaired diastolic filling and heart failure with preserved ejection fraction. Histopathology demonstrates transverse thickening of cardiomyocytes with prominent hyperchromatic nuclei and interstitial fibrosis.

10
11
12
13
14
15
16
17
18
19
20
21
22
23
24
25
26
27
28
29
30
31
32
33
34
35
36
37
38

concentric LV hypertrophy.

Concentric LV hypertrophy most commonly results from prolonged **systemic hypertension** as myocardial fibers are added in parallel to increase contractile strength and ha ... **art disease**, consisting of **imp** ... transmitted back to the lef ... can lead to a dramatic **rec** ... as likely occured in this patie ...

On histopathology, hypert ... The increased myocardial mas ...

(Choice A) Cardiac amyl ... is characterized by impaired ... reveals collections of pink ...

(Choice C) Hypertrophic ... interventricular septum. A ... interstitial fibrosis; howeve ...

(Choice D) Mitral stenosi ... not increase the pressure loa ...

(Choice E) Pulmonary ar ... The elevated pressure loa ... edema is not present in ri ...

Educational objective:
Concentric left ventricular ... from prolonged systemic h ... ejection fraction. Histopathology demonstrates transverse thickening of cardiomyocytes with prominent hyperchromatic nuclei and interstitial fibrosis.

Exhibit Display

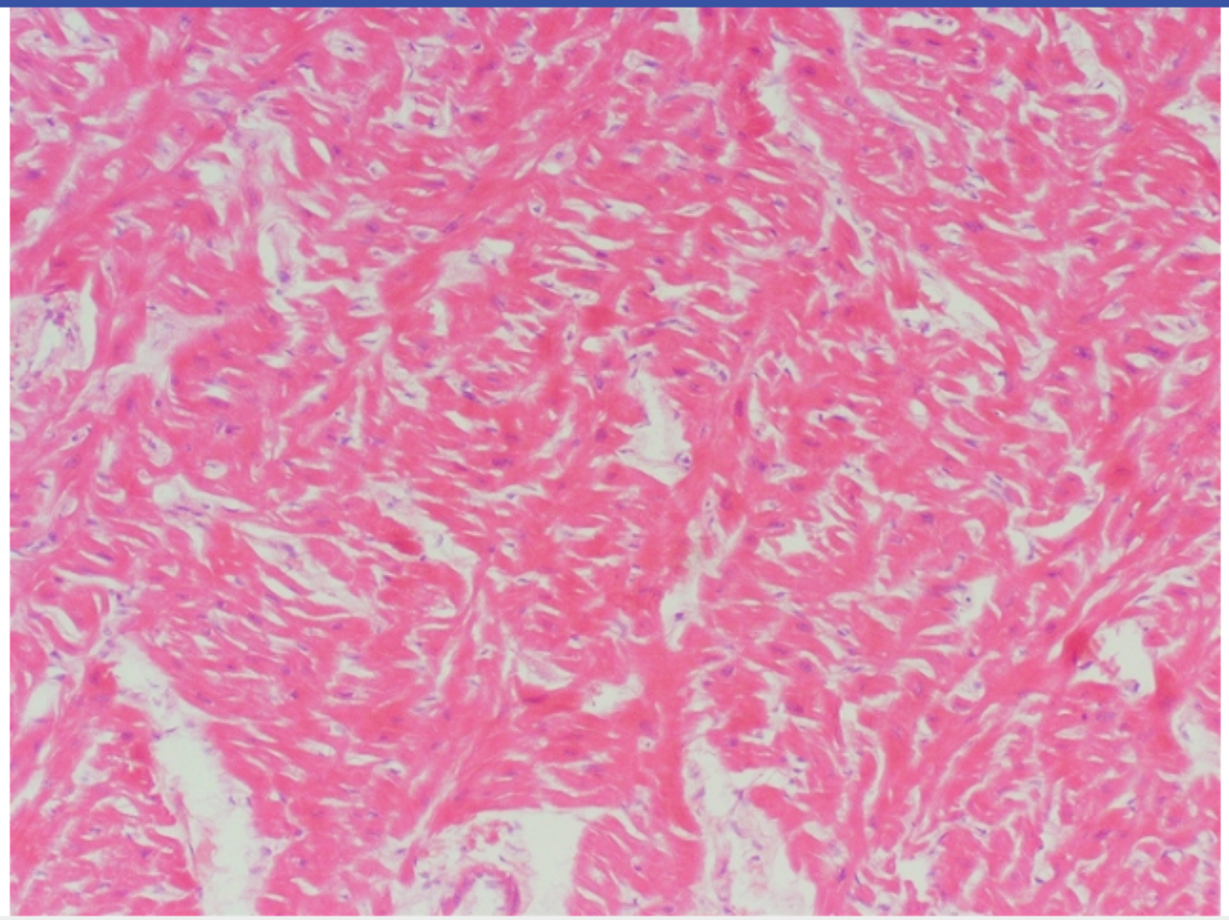

Zoom In | Zoom Out | Reset | Add To New Card | Existing Card

10
11
12
13
14
15
16
17
18
19
20
21
22
23
24
25
26
27
28
29
30
31
32
33
34
35
36
37
38

A 34-year-old Asian female is hospitalized with progressive exertional dyspnea, lower extremity edema and cough. She also describes frequent nocturnal episodes of breathlessness and recent hoarseness. She does not use tobacco, alcohol or drugs. Auscultation reveals loud first and second heart sounds and a mid-diastolic rumble best heard at the cardiac apex. This patient's hoarseness is most likely caused by:

A. Laryngeal edema

B. Impaired arterial supply

C. Nerve impingement

D. Epithelial sloughing

E. Vocal cord polyps

Submit

A 34-year-old Asian female is hospitalized with progressive exertional dyspnea, lower extremity edema and cough. She also describes frequent nocturnal episodes of breathlessness and recent hoarseness. She does not use tobacco, alcohol or drugs. Auscultation reveals loud first and second heart sounds and a mid-diastolic rumble best heard at the cardiac apex. This patient's hoarseness is most likely caused by:

- A. Laryngeal edema (11%)
- B. Impaired arterial supply (6%)
- ✓ C. Nerve impingement (78%)
- D. Epithelial sloughing (1%)
- E. Vocal cord polyps (1%)

Omitted
Correct answer
C

78%
Answered correctly

02 secs
Time Spent

02/03/2020
Last Updated

Explanation

In rare instances, the left recurrent laryngeal nerve may be compressed to the point of neurapraxia (failure of nerve conduction due to blunt injury) by enlargement of the left atrium and/or other structures in the vicinity of its course as it loops behind the ligamentum arteriosum, underneath and around the aortic arch, and back up alongside the trachea to the larynx. Mitral stenosis can cause left atrial dilatation sufficient to impinge on the left recurrent laryngeal nerve (Ortner syndrome).

The recurrent laryngeal nerves innervate all of the intrinsic muscles of the larynx except the cricothyroid muscle. Paresis of vocal cord muscles innervated by left recurrent laryngeal nerve can cause hoarseness.

In rare instances, the left recurrent laryngeal nerve may be compressed to the point of neurapraxia (failure of nerve conduction due to blunt injury) by enlargement of the left atrium and/or other structures in the vicinity of its course as it loops behind the ligamentum arteriosum, underneath and around the aortic arch, and back up alongside the trachea to the larynx. Mitral stenosis can cause left atrial dilatation sufficient to impinge on the left recurrent laryngeal nerve (Ortner syndrome).

The recurrent laryngeal nerves innervate all of the intrinsic muscles of the larynx except the cricothyroid muscle. Paresis of vocal cord muscles innervated by left recurrent laryngeal nerve can cause hoarseness.

(Choice A) Laryngeal edema can cause hoarseness but is commonly due to direct laryngeal inflammation (e.g. by an upper respiratory infection).

(Choice B) Vascular disease or injury resulting in ischemia of the vocal cords, the recurrent laryngeal nerves, and/or the vagal motor nuclei in the brain stem could result in laryngeal neuromuscular dysfunction, producing hoarseness. However, the patient's history and presentation make MS a more likely culprit.

(Choice D) Hoarseness is predominantly due to vocal cord disease (including mucosal inflammation or edema) or vocal cord malfunction. Epithelial sloughing could be associated with laryngeal mucosal disease and might be seen in asthma or airway exposure to noxious external gases or gastric acid. However, the other components of the patient's history and physical make severe MS more likely as an underlying pathogenic factor.

(Choice E) Vocal cord epithelial or mucosal polyps can also cause hoarseness, but are less likely etiologies here, given the patient's history.

Educational Objective:
Left atrial enlargement can sometimes cause left recurrent laryngeal nerve impingement. Neurapraxia resulting in left vocal cord paresis and hoarseness may result.

Pathology	Cardiovascular System	Mitral stenosis
Subject	System	Topic

Copyright © UWorld. All rights reserved.

10
11
12
13
14
15
16
17
18
19
20
21
22
23
24
25
26
27
28
29
30
31
32
33
34
35
36
37
38

A 35-year-old woman is brought to the emergency department due to severe right leg pain. She is a concert pianist with no known medical issues. During rehearsal, she began experiencing cramping of the right foot that did not improve with stretching or rest. The pain quickly spread to her calf, and the patient now rates the pain as 9 out of 10 in intensity. On examination, the right foot and calf appear pale and cool compared with the left, and sensation is diminished. Right-sided dorsalis pedis and posterior tibial pulses are absent, and the popliteal pulse is barely palpable. Emergency embolectomy is performed and a gelatinous mass causing arterial occlusion is successfully removed. Histopathologic section of the mass is shown in the exhibit. Which of the following is the most likely origin of this patient's embolus?

A. Aortic valve
B. Descending aorta
C. Left atrium
D. Left ventricle
E. Mitral valve

Submit

10
11
12
13
14
15
16
17
18
19
20
21
22
23
24
25
26
27
28
29
30
31
32
33
34
35
36
37
38

A 35-year-old woman is brought to the emergency department due to severe right leg pain. She is a concert pianist with no known medical issues. During rehearsal, ad
to her calf, and the patient d
with the left, and sensatio
palpable. Emergency em
section of the mass is sho

A. Aortic valve
B. Descending
C. Left atrium
D. Left ventricle
E. Mitral valve

Submit

Exhibit Display

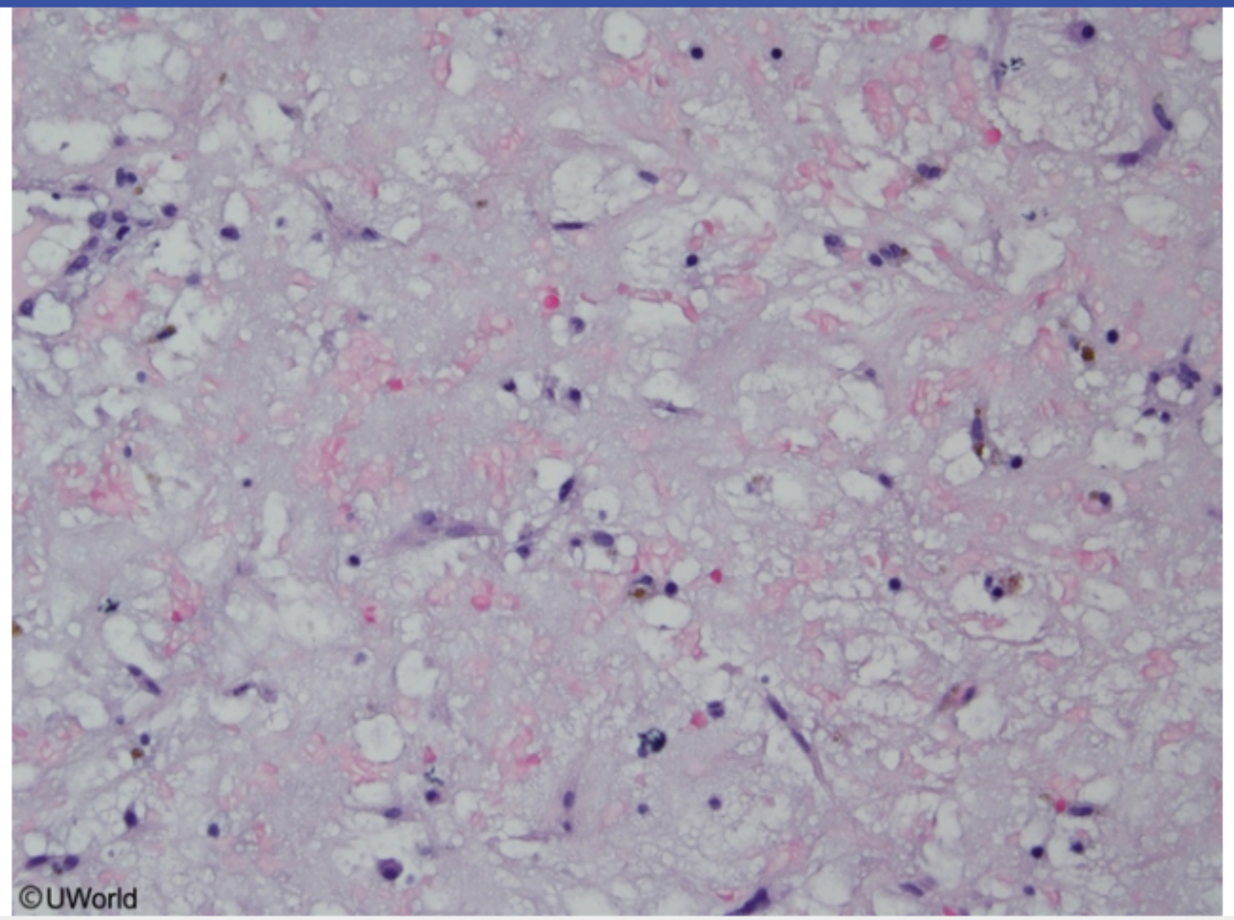

Zoom In
Zoom Out
Reset
Add To New Card | Existing Card

A 35-year-old woman is brought to the emergency department due to severe right leg pain. She is a concert pianist with no known medical issues. During rehearsal, she began experiencing cramping of the right foot that did not improve with stretching or rest. The pain quickly spread to her calf, and the patient now rates the pain as 9 out of 10 in intensity. On examination, the right foot and calf appear pale and cool compared with the left, and sensation is diminished. Right-sided dorsalis pedis and posterior tibial pulses are absent, and the popliteal pulse is barely palpable. Emergency embolectomy is performed and a gelatinous mass causing arterial occlusion is successfully removed. Histopathologic section of the mass is shown in the exhibit. Which of the following is the most likely origin of this patient's embolus?

A. Aortic valve (3%)
B. Descending aorta (14%)
✓ C. Left atrium (62%)
D. Left ventricle (2%)
E. Mitral valve (17%)

Omitted
Correct answer
C

62%
Answered correctly

16 secs
Time Spent

01/28/2020
Last Updated

Explanation

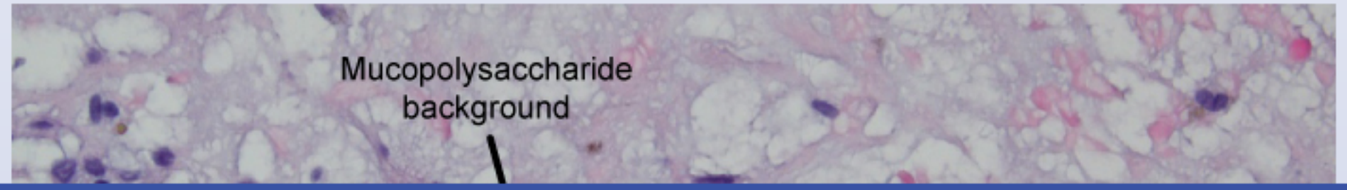

10
11
12
13
14
15
16
17
18
19
20
21
22
23
24
25
26
27
28
29
30
31
32
33
34
35
36
37
38

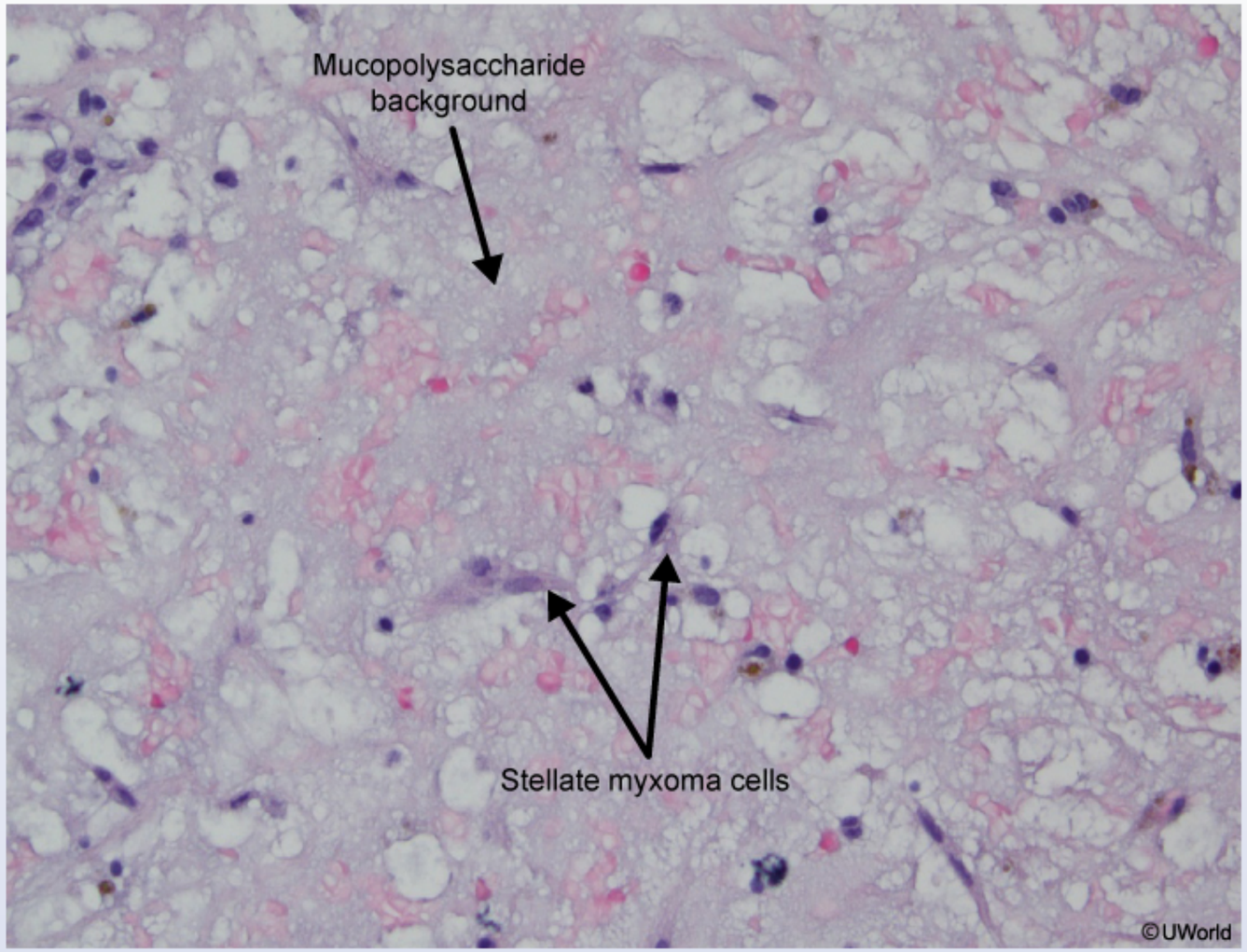

This patient presented with **acute limb ischemia**, as evidenced by the **6 Ps**: pain, pallor, poikilothermia (coolness to touch), paresthesia, paralysis, and reduced or absent pulses. The ischemia resulted from **systemic embolization** of a gelatinous mass, with histopathology demonstrating an **amorphous extracellular matrix** with scattered stellate myxoma cells in mucopolysaccharide ground substance; this is

This patient presented with **acute limb ischemia**, as evidenced by the **6 Ps**: pain, pallor, poikilothermia (coolness to touch), paresthesia, paralysis, and reduced or absent pulses. The ischemia resulted from **systemic embolization** of a gelatinous mass, with histopathology demonstrating an **amorphous extracellular matrix** with scattered stellate myxoma cells in mucopolysaccharide ground substance; this is consistent with tumor fragments from an **atrial myxoma**.

Myxomas are the most common primary cardiac neoplasm. Approximately 80% of these benign tumors originate in the **left atrium**. Patients can initially present with nonspecific constitutional symptoms (eg, fatigue, low-grade fever, weight loss) or systemic embolization (eg, stroke, mesenteric ischemia, acute limb ischemia), as in this patient. In addition, the tumor can cause position-dependent obstruction of the mitral valve, leading to signs and symptoms that **mimic mitral valve stenosis** (eg, dyspnea, orthopnea, cough, mid-diastolic murmur).

(Choices A and E) The aortic and mitral valves can be the source of systemic embolism due to vegetations from bacterial endocarditis or nonbacterial thrombotic endocarditis (Libman-Sacks endocarditis). However, only 5% of myxomas originate on the mitral valve and even fewer originate on the aortic valve.

(Choice B) A complex atherosclerotic plaque or mural thrombus attached to the walls of the descending aorta can lead to systemic embolization to the kidneys, bowel, or lower extremities. However, myxomas very rarely originate from the aorta.

(Choice D) A mural thrombus can originate in the left ventricular cavity in patients with severe left ventricular systolic dysfunction, especially with recent anterior wall myocardial infarction. Other than the left atrium, the right atrium is the most common site for myxoma development. It is quite rare for myxomas to originate in either ventricle.

Educational objective:
Myxomas are the most common primary cardiac neoplasm and approximately 80% originate in the left atrium. Patients may present with symptomatic mitral valve obstruction that may worsen with certain body positions, constitutional findings (eg, fever, weight loss), or systemic embolization (eg, stroke, mesenteric ischemia, acute limb ischemia).

References

- Cardiac myxomas: 24 years of experience in 49 patients.
- Cardiac myxoma: diagnostic approach, surgical treatment and follow-up. A twenty years experience.

10
11
12
13
14
15
16
17
18
19
20
21
22
23
24
25
26
27
28
29
30
31
32
33
34
35
36
37
38

A 52-year-old man comes to the office due to periodic substernal chest heaviness. The pain is precipitated by fast walking, especially uphill and against the wind, and remits after 5 minutes of rest. The patient has a history of hypertension and smokes a pack of cigarettes a day. Blood pressure is 140/80 mm Hg and pulse is 80/min. The lungs are clear to auscultation, and no heart murmurs are heard. There is no peripheral edema. Which of the following pathologic states is most likely to be present in this patient?

A. Atherosclerotic plaque obstructing 50% of the coronary artery lumen, no thrombus

B. Atherosclerotic plaque obstructing 80% of the coronary artery lumen, no thrombus

C. Ruptured atherosclerotic plaque with fully obstructive thrombus

D. Significant coronary artery vasospasm causing flow obstruction

E. Ulcerated atherosclerotic plaque with partially obstructive thrombus

Submit

A 52-year-old man comes to the office due to periodic substernal chest heaviness. The pain is precipitated by fast walking, especially uphill and against the wind, and remits after 5 minutes of rest. The patient has a history of hypertension and smokes a pack of cigarettes a day. Blood pressure is 140/80 mm Hg and pulse is 80/min. The lungs are clear to auscultation, and no heart murmurs are heard. There is no peripheral edema. Which of the following pathologic states is most likely to be present in this patient?

- A. Atherosclerotic plaque obstructing 50% of the coronary artery lumen, no thrombus (16%)
- ✓ B. Atherosclerotic plaque obstructing 80% of the coronary artery lumen, no thrombus (78%)
- C. Ruptured atherosclerotic plaque with fully obstructive thrombus (0%)
- D. Significant coronary artery vasospasm causing flow obstruction (2%)
- E. Ulcerated atherosclerotic plaque with partially obstructive thrombus (1%)

Omitted
Correct answer
B

78%
Answered correctly

02 secs
Time Spent

01/06/2020
Last Updated

Explanation

This patient with multiple risk factors for coronary artery disease (eg, age, hypertension, smoking) has intermittent substernal chest heaviness consistent with **stable angina pectoris**. Stable angina is characterized by substernal or left-sided chest pressure, tightness, or pain that is reliably produced by exertion and relieved by rest. It occurs due to temporary myocardial ischemia resulting from **demand-supply mismatch** of oxygen-rich blood to the myocardium.

Myocardial oxygen demand is determined by heart rate, blood pressure (afterload), left-ventricular end-diastolic volume (preload), and cardiac contractility, whereas myocardial oxygen supply is determined by coronary blood flow. The demand-supply mismatch of stable angina results from

This patient with multiple risk factors for coronary artery disease (eg, age, hypertension, smoking) has intermittent substernal chest heaviness consistent with **stable angina pectoris**. Stable angina is characterized by substernal or left-sided chest pressure, tightness, or pain that is reliably produced by exertion and relieved by rest. It occurs due to temporary myocardial ischemia resulting from **demand-supply mismatch** of oxygen-rich blood to the myocardium.

Myocardial oxygen demand is determined by heart rate, blood pressure (afterload), left-ventricular end-diastolic volume (preload), and cardiac contractility, whereas myocardial oxygen supply is determined by coronary blood flow. The demand-supply mismatch of stable angina results from **restricted coronary blood flow** due to a fixed **atherosclerotic lesion that obstructs >70%** of the coronary artery lumen. These lesions allow sufficient blood flow to the myocardium during rest but insufficient blood flow to meet myocardial oxygen demands during exertion.

(Choice A) An atherosclerotic plaque obstructing 50% of the lumen is unlikely to produce symptomatic myocardial ischemia. Symptoms of stable angina do not become prominent until approximately 70% of the cross-sectional area of the coronary artery lumen is occluded.

(Choice C) Ruptured atherosclerotic plaque with overlying fully obstructive thrombus describes the pathophysiology of ST elevation myocardial infarction. The abrupt cessation of myocardial blood flow leads to transmural infarction and presents with persistent chest pain that is not relieved by rest.

(Choice D) Coronary artery vasospasm (vasospastic angina or Prinzmetal angina) results from hyperactivity of vascular smooth muscle, usually in the absence of significant atherosclerotic coronary artery disease. Transient anginal chest pain is typical; however, the pain is not precipitated by exertion or relieved by rest.

(Choice E) Ulcerated atherosclerotic plaque with overlying partially obstructive thrombus is likely to produce acute coronary syndrome in the form of non-ST elevation (partial-thickness) myocardial infarction or unstable angina. Unstable angina describes anginal pain occurring at rest or with markedly increased frequency, intensity, or duration compared to the patient's baseline stable angina.

Educational objective:
Stable angina pectoris results from myocardial oxygen demand-supply mismatch and manifests as chest pressure, tightness, or pain that is reliably produced by exertion and relieved by rest. It most commonly occurs due to a fixed atherosclerotic plaque obstructing >70% of the coronary artery lumen that limits blood flow during exertion.

References

rich blood to the myocardium.

Myocardial oxygen demand is determined by heart rate, blood pressure (afterload), left-ventricular end-diastolic volume (preload), and cardiac contractility, whereas myocardial oxygen supply is determined by coronary blood flow. The demand-supply mismatch of stable angina results from **restricted coronary blood flow** due to a fixed **atherosclerotic lesion that obstructs >70%** of the coronary artery lumen. These lesions allow sufficient blood flow to the myocardium during rest but insufficient blood flow to meet myocardial oxygen demands during exertion.

(Choice A) An atherosclerotic plaque obstructing 50% of the lumen is unlikely to produce symptomatic myocardial ischemia. Symptoms of stable angina do not become prominent until approximately 70% of the cross-sectional area of the coronary artery lumen is occluded.

(Choice C) Ruptured atherosclerotic plaque with overlying fully obstructive thrombus describes the pathophysiology of ST elevation myocardial infarction. The abrupt cessation of myocardial blood flow leads to transmural infarction and presents with persistent chest pain that is not relieved by rest.

(Choice D) Coronary artery vasospasm (vasospastic angina or Prinzmetal angina) results from hyperactivity of vascular smooth muscle, usually in the absence of significant atherosclerotic coronary artery disease. Transient anginal chest pain is typical; however, the pain is not precipitated by exertion or relieved by rest.

(Choice E) Ulcerated atherosclerotic plaque with overlying partially obstructive thrombus is likely to produce acute coronary syndrome in the form of non-ST elevation (partial-thickness) myocardial infarction or unstable angina. Unstable angina describes anginal pain occurring at rest or with markedly increased frequency, intensity, or duration compared to the patient's baseline stable angina.

Educational objective:
Stable angina pectoris results from myocardial oxygen demand-supply mismatch and manifests as chest pressure, tightness, or pain that is reliably produced by exertion and relieved by rest. It most commonly occurs due to a fixed atherosclerotic plaque obstructing >70% of the coronary artery lumen that limits blood flow during exertion.

References

- 2012 ACCF/AHA/ACP/AATS/PCNA/SCAI/STS guideline for the diagnosis and management of patients with stable ischemic heart disease: a report of the American College of Cardiology Foundation/American Heart Association task force on practice guidelines, and the American College of Physicians, American Association for Thoracic Surgery, Preventive Cardiovascular Nurses Association, Society for Cardiovascular Angiography and Interventions, and Society of Thoracic Surgeons

10
11
12
13
14
15
16
17
18
19
20
21
22
23
24
25
26
27
28
29
30
31
32
33
34
35
36
37
38

rich blood to the myocardium.

Exhibit Display

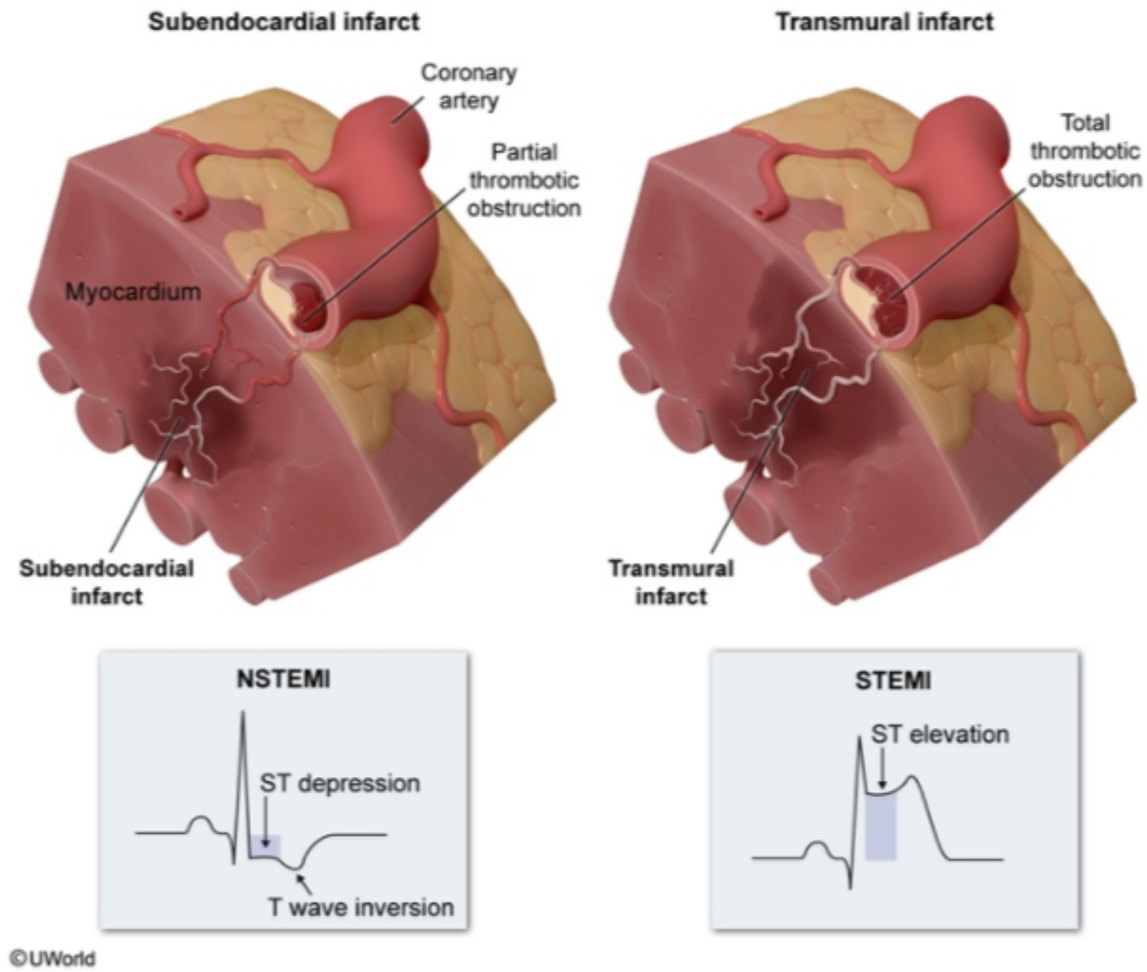

Zoom In | Zoom Out | Reset | Add To New Card | Existing Card

Angiography and Interventions, and Society of Thoracic Surgeons

10
11
12
13
14
15
16
17
18
19
20
21
22
23
24
25
26
27
28
29
30
31
32
33
34
35
36
37
38

A 62-year-old woman comes to the office due to a vague feeling of heaviness in her legs, especially when standing for long periods. She has no history of trauma to the legs. The patient's other medical problems include osteoarthritis and gastroesophageal reflux disease. She has worked as a cashier at a department store for the last 20 years. Vital signs are normal. Jugular venous pressure is normal. The heart has regular rate and rhythm with no murmurs or extra sounds. Lung sounds are clear with normal air movement. The abdomen is soft and without masses. Examination of the lower extremities shows dilated, tortuous veins at the calves and ankles bilaterally, with no erythema or edema. Upper extremity examination is unremarkable. This patient's current condition increases the risk for which of the following?

A. Intermittent claudication
B. Ischemic stroke
C. Myocardial infarction
D. Phlegmasia alba dolens
E. Pulmonary embolism
F. Skin ulcerations

Submit

A 62-year-old woman comes to the office due to a vague feeling of heaviness in her legs, especially when standing for long periods. She has no history of trauma to the legs. The patient's other medical problems include osteoarthritis and gastroesophageal reflux disease. She has worked as a cashier at a department store for the last 20 years. Vital signs are normal. Jugular venous pressure is normal. The heart has regular rate and rhythm with no murmurs or extra sounds. Lung sounds are clear with normal air movement. The abdomen is soft and without masses. Examination of the lower extremities shows dilated, tortuous veins at the calves and ankles bilaterally, with no erythema or edema. Upper extremity examination is unremarkable. This patient's current condition increases the risk for which of the following?

A. Intermittent claudication (13%)

B. Ischemic stroke (0%)

C. Myocardial infarction (0%)

D. Phlegmasia alba dolens (5%)

E. Pulmonary embolism (44%)

✓ F. Skin ulcerations (35%)

Omitted
Correct answer
F

35%
Answered correctly

02 secs
Time Spent

01/30/2020
Last Updated

Explanation

Arterial insufficiency | **Venous insufficiency**

10
11
12
13
14
15
16
17
18
19
20
21
22
23
24
25
26
27
28
29
30
31
32
33
34
35
36
37
38

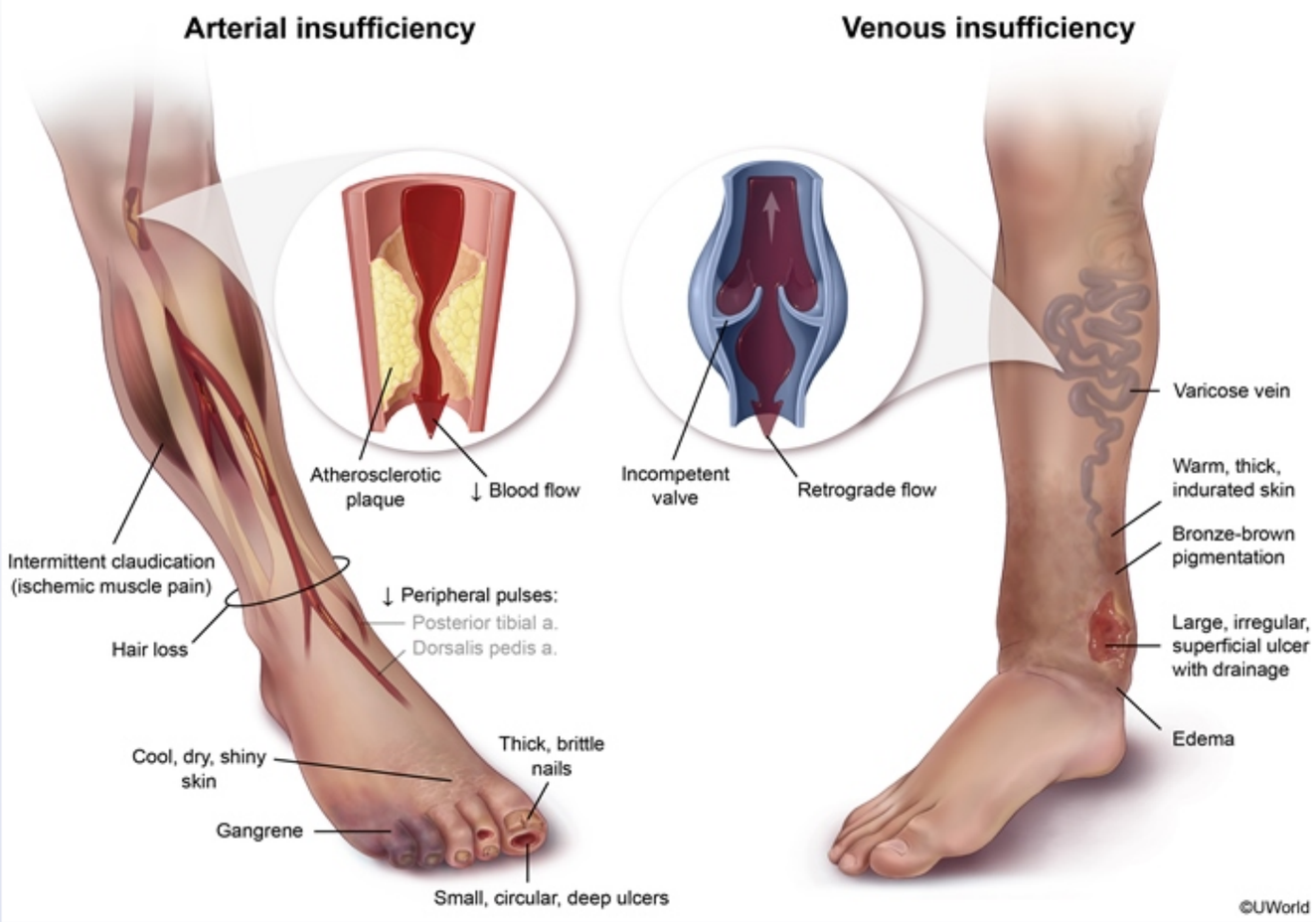

This patient has **varicose veins** - dilated, tortuous veins typically involving the superficial venous drainage of the leg. Increased intraluminal pressure or loss of vessel wall tensile strength can lead to venous dilation and failure of the venous valves. The resulting backflow of blood exacerbates the venous hypertension, precipitating a vicious cycle that leads to further valvular incompetence and venous congestion.

Varicose veins are most common in patients age >50, and the risk is increased by conditions that cause elevated venous pressure (eg, prolonged standing, pregnancy, obesity). There is also often a familial association, suggesting possible genetic factors involving the venous wall or valves.

This patient has **varicose veins** - dilated, tortuous veins typically involving the superficial venous drainage of the leg. Increased intraluminal pressure or loss of vessel wall tensile strength can lead to venous dilation and failure of the venous valves. The resulting backflow of blood exacerbates the venous hypertension, precipitating a vicious cycle that leads to further valvular incompetence and venous congestion.

Varicose veins are most common in patients age >50, and the risk is increased by conditions that cause elevated venous pressure (eg, prolonged standing, pregnancy, obesity). There is also often a familial association, suggesting possible genetic factors involving the venous wall or valves. Common complications include chronic edema, stasis dermatitis, skin ulcerations, poor wound healing, and infection.

(Choices A, B, and C) Intermittent claudication is achy or crampy pain in the legs caused by inadequate arterial blood flow, usually due to atherosclerosis in the branches of the femoral artery. In contrast to venous disease, in which the pain is worsened by prolonged standing or sitting with the legs dependent, claudication due to arterial disease is worse with exertion and relieved with rest. Because peripheral artery atherosclerosis is often associated with atherosclerotic disease elsewhere, patients with intermittent claudication have an increased risk for ischemic stroke and myocardial infarction.

(Choices D and E) Deep venous thrombosis of the lower extremity can lead to pulmonary embolism. In addition, massive iliofemoral thrombosis can cause an acute rise in tissue pressure that impairs arterial inflow, leading to phlegmasia alba dolens (painful white "milk leg"). Although varicose veins can sometimes be complicated by thrombophlebitis, it primarily involves the superficial rather than deep venous system and does not increase the risk for pulmonary embolism or phlegmasia alba dolens.

Educational objective:
Varicose veins are dilated, tortuous veins most commonly found in the superficial veins of the leg. They are caused by chronically increased intraluminal pressure and/or loss of tensile strength in the vessel wall, leading to incompetence of the venous valves. Common complications include edema, stasis dermatitis, skin ulcerations, poor wound healing, and infections.

References

- Pathogenesis of primary varicose veins.

Pathology	Cardiovascular System	Chronic venous insufficiency
Subject	System	Topic

Copyright © UWorld. All rights reserved.

10
11
12
13
14
15
16
17
18
19
20
21
22
23
24
25
26
27
28
29
30
31
32
33
34
35
36
37
38

This patient has **varicose veins** - dilated, tortuous veins typically involving the superficial venous drainage of the leg. Increased intraluminal

Exhibit Display

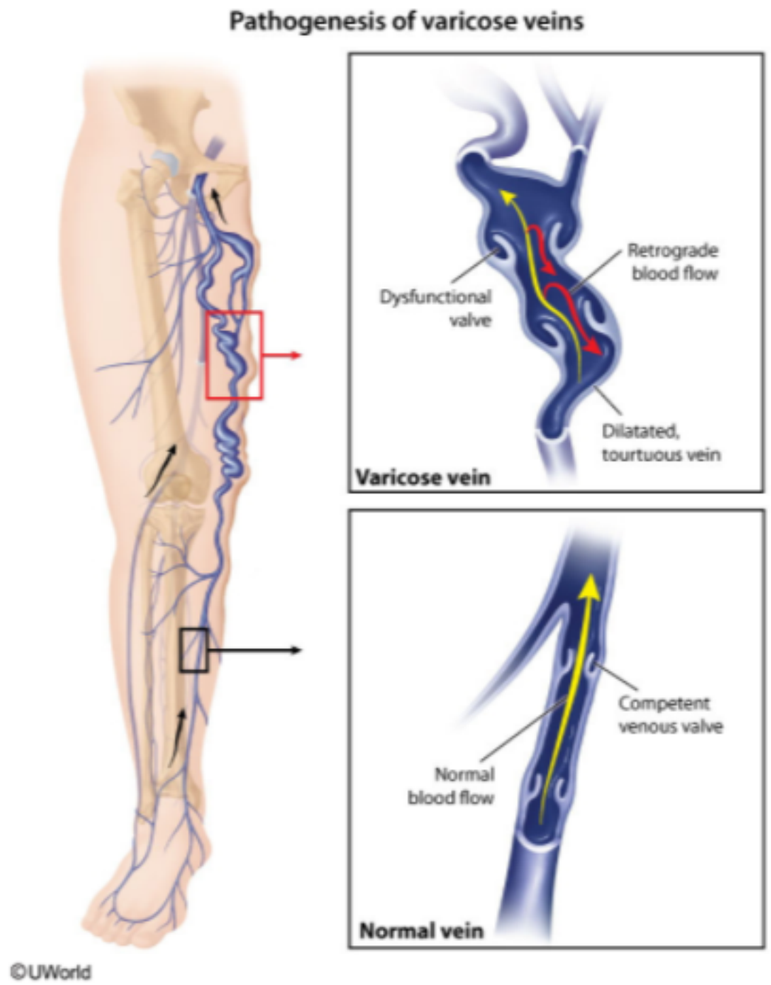

Zoom In | Zoom Out | Reset | Add To New Card | Existing Card

Copyright © UWorld. All rights reserved.

10
11
12
13
14
15
16
17
18
19
20
21
22
23
24
25
26
27
28
29
30
31
32
33
34
35
36
37
38

This patient has **varicose veins** - dilated, tortuous veins typically involving the superficial venous drainage of the leg. Increased intraluminal

Exhibit Display

Zoom In | Zoom Out | Reset | Add To New Card | Existing Card

Copyright © UWorld. All rights reserved.

10
11
12
13
14
15
16
17
18
19
20
21
22
23
24
25
26
27
28
29
30
31
32
33
34
35
36
37
38

A 34-year-old woman comes to the emergency department because of sharp chest pain that radiates to the left shoulder. The pain increases with inspiration and is partially relieved by sitting up and leaning forward. Review of her outpatient medical records shows that she was seen for a facial rash 6 months ago. She is also being evaluated for proteinuria that was identified during her last clinic appointment. Which of the following is the most likely cause of this patient's chest pain?

A. Aortic dissection
B. Cardiac tamponade
C. Intimal hyperplasia of pulmonary arteries
D. Non-infectious cardiac valve vegetations
E. Pericardial inflammation

Submit

A 34-year-old woman comes to the emergency department because of sharp chest pain that radiates to the left shoulder. The pain increases with inspiration and is partially relieved by sitting up and leaning forward. Review of her outpatient medical records shows that she was seen for a facial rash 6 months ago. She is also being evaluated for proteinuria that was identified during her last clinic appointment. Which of the following is the most likely cause of this patient's chest pain?

- A. Aortic dissection (1%)
- B. Cardiac tamponade (3%)
- C. Intimal hyperplasia of pulmonary arteries (1%)
- D. Non-infectious cardiac valve vegetations (9%)
- ✓ E. Pericardial inflammation (83%)

Omitted
Correct answer
E

83%
Answered correctly

02 secs
Time Spent

05/25/2020
Last Updated

Explanation

Manifestations of systemic lupus erythematosus	
Clinical symptoms	• Constitutional: fever, fatigue & weight loss • Symmetric, migratory arthritis • Skin: butterfly rash & photosensitivity • Serositis: pleurisy, pericarditis & peritonitis

Manifestations of systemic lupus erythematosus	
Clinical symptoms	• Constitutional: fever, fatigue & weight loss • Symmetric, migratory arthritis • Skin: butterfly rash & photosensitivity • Serositis: pleurisy, pericarditis & peritonitis • Thromboembolic events (due to vasculitis & antiphospholipid antibodies) • Neurologic: cognitive dysfunction & seizures

Laboratory findings	• Hemolytic anemia, thrombocytopenia & leukopenia
	• Hypocomplementemia (C3 & C4)
	• Antibodies:
	  ◦ ANA (sensitive)
	  ◦ Anti-dsDNA & anti-Sm (specific)
	• Renal involvement: proteinuria & elevated creatinine

ANA = antinuclear antibodies; **dsDNA** = double-stranded DNA.

This patient's chest pain is characteristic of **acute pericarditis**, which along with her facial rash and proteinuria is suggestive of underlying **systemic lupus erythematosus (SLE)**. SLE is a chronic autoimmune disease predominantly affecting women age 20-40 that causes **constitutional** and **multisystemic** symptoms. **Serosal inflammation** is common in SLE and most often manifests as pleuritis or pericarditis.

Pericarditis presents with severe and constant middle or left chest pain that may radiate to the neck and shoulders (particularly the trapezius ridge). The pain increases on **inspiration** (pleuritic) and is relieved by **sitting up and leaning forward** (postural). Auscultation of the chest reveals a scratchy sound called a **pericardial friction rub** that is best heard when the patient is leaning forward or lying prone. Additional cardiovascular manifestations in SLE include pericardial effusion, verrucous (Libman-Sacks) endocarditis, and increased risk of coronary artery disease.

(Choice A) Aortic dissection occurs in patients with long-standing hypertension and those with Marfan and Ehlers-Danlos syndromes (the 2 latter conditions cause cystic medial necrosis of the aortic wall). It presents with abrupt-onset, severe, tearing chest pain that radiates to the back

This patient's chest pain is characteristic of **acute pericarditis**, which along with her facial rash and proteinuria is suggestive of underlying **systemic lupus erythematosus (SLE)**. SLE is a chronic autoimmune disease predominantly affecting women age 20-40 that causes **constitutional** and **multisystemic** symptoms. **Serosal inflammation** is common in SLE and most often manifests as pleuritis or pericarditis.

Pericarditis presents with severe and constant middle or left chest pain that may radiate to the neck and shoulders (particularly the trapezius ridge). The pain increases on **inspiration** (pleuritic) and is relieved by **sitting up and leaning forward** (postural). Auscultation of the chest reveals a scratchy sound called a **pericardial friction rub** that is best heard when the patient is leaning forward or lying prone. Additional cardiovascular manifestations in SLE include pericardial effusion, verrucous (Libman-Sacks) endocarditis, and increased risk of coronary artery disease.

(Choice A) Aortic dissection occurs in patients with long-standing hypertension and those with Marfan and Ehlers-Danlos syndromes (the 2 latter conditions cause cystic medial necrosis of the aortic wall). It presents with abrupt-onset, severe, tearing chest pain that radiates to the back.

(Choice B) Cardiac tamponade is caused by accumulation of fluid in the pericardial space that prevents the heart from filling properly in diastole. It presents with dyspnea and tachypnea. Physical examination shows distended neck veins, hypotension, diminished heart sounds, and pulsus paradoxus (drop in systolic blood pressure $\geq$10 mm Hg on inspiration).

(Choice C) Intimal hyperplasia of the pulmonary arteries is characteristic of both primary and secondary pulmonary hypertension. It presents with dyspnea, malaise, and findings associated with right ventricular failure (eg, jugular venous distention, pedal edema, hepatomegaly). Severe symptomatic pulmonary hypertension is a rare complication of SLE.

(Choice D) Non-bacterial endocarditis (verrucous or Libman-Sacks endocarditis) refers to small, wart-like fibrinous lesions and generalized thickening that can affect the heart valves of patients with SLE. These are typically asymptomatic but may lead to valvular insufficiency or embolism.

Educational objective:
Pericarditis is the most common cardiovascular manifestation associated with systemic lupus erythematosus. It presents with sharp pleuritic chest pain that is relieved by sitting up and leaning forward.

References

- Cardiac involvement in systemic lupus erythematosus.

ridge). The pain increases on **inspiration** (pleuritic) and is relieved by **sitting up and leaning forward** (postural). Auscultation of the chest reveals a scratchy sound called a **pericardial friction rub** that is best heard when the patient is leaning forward or lying prone. Additional cardiovascular manifestations in SLE include pericardial effusion, verrucous (Libman-Sacks) endocarditis, and increased risk of coronary artery disease.

(Choice A) Aortic dissection occurs in patients with long-standing hypertension and those with Marfan and Ehlers-Danlos syndromes (the 2 latter conditions cause cystic medial necrosis of the aortic wall). It presents with abrupt-onset, severe, tearing chest pain that radiates to the back.

(Choice B) Cardiac tamponade is caused by accumulation of fluid in the pericardial space that prevents the heart from filling properly in diastole. It presents with dyspnea and tachypnea. Physical examination shows distended neck veins, hypotension, diminished heart sounds, and pulsus paradoxus (drop in systolic blood pressure ≥10 mm Hg on inspiration).

(Choice C) Intimal hyperplasia of the pulmonary arteries is characteristic of both primary and secondary pulmonary hypertension. It presents with dyspnea, malaise, and findings associated with right ventricular failure (eg, jugular venous distention, pedal edema, hepatomegaly). Severe symptomatic pulmonary hypertension is a rare complication of SLE.

(Choice D) Non-bacterial endocarditis (verrucous or Libman-Sacks endocarditis) refers to small, wart-like fibrinous lesions and generalized thickening that can affect the heart valves of patients with SLE. These are typically asymptomatic but may lead to valvular insufficiency or embolism.

Educational objective:
Pericarditis is the most common cardiovascular manifestation associated with systemic lupus erythematosus. It presents with sharp pleuritic chest pain that is relieved by sitting up and leaning forward.

References

- Cardiac involvement in systemic lupus erythematosus.

Pathology	Cardiovascular System	Acute pericarditis
Subject	System	Topic

Copyright © UWorld. All rights reserved.

A 78-year-old man is brought to the emergency department with lightheadedness that began earlier in the day. This morning, the patient felt unsteady and almost passed out when he tried to get out of bed. He has never had symptoms like these before and has not had chest pain or shortness of breath. The patient has had prior episodes of intermittent palpitations. He has a history of moderate aortic stenosis and coronary artery disease requiring percutaneous coronary intervention. ECG obtained in the emergency department is shown in the exhibit. Which of the following is the most likely cause of this patient's current symptoms?

- A. Degenerative changes involving the atrioventricular node
- B. Degenerative changes involving the sinus node
- C. Increased afterload leading to left ventricular hypertrophy
- D. Sporadic and independent depolarization of atrial myocytes
- E. Thrombotic occlusion of the distal left anterior descending artery

Submit

A 78-year-old man is brought to the emergency department with lightheadedness that began earlier in the day. This morning, the patient felt unsteady and almost passed out when he tried to get out of bed. He has never had symptoms like these before and has not had chest pain or shortness of breath. The patient has had prior episodes of intermittent palpitations. He has a history of moderate aortic stenosis and coronary artery disease requiring percutaneous coronary intervention. ECG obtained in the emergency department is shown in the exhibit. Which of the following is the most likely cause of this patient's current symptoms?

- ✓ A. Degenerative changes involving the atrioventricular node (34%)
- B. Degenerative changes involving the sinus node (21%)
- C. Increased afterload leading to left ventricular hypertrophy (8%)
- D. Sporadic and independent depolarization of atrial myocytes (23%)
- E. Thrombotic occlusion of the distal left anterior descending artery (12%)

Omitted
Correct answer
A

34%
Answered correctly

05 secs
Time Spent

02/23/2020
Last Updated

Explanation

This patient's ECG demonstrates third-degree atrioventricular (AV) block. Third-degree (complete) AV block involves a total lack of communication between the atria and ventricles due to **AV node dysfunction**. It can result from ischemia, infiltrative disease (eg, sarcoidosis), infection (eg, Lyme disease), or **age-related** fibrosis with cellular **degeneration**. Because conduction signals from the atria cannot communicate with the ventricles, the intrinsic pacemaker of the His bundle or ventricles is triggered, resulting in a junctional or ventricular escape rhythm. On ECG, there is **dissociation of P waves and QRS complexes**, with P waves marching out at the intrinsic rate of the sinoatrial node (~75/min) and QRS

Explanation

This patient's ECG demonstrates third-degree atrioventricular (AV) block. Third-degree (complete) AV block involves a total lack of communication between the atria and ventricles due to **AV node dysfunction**. It can result from ischemia, infiltrative disease (eg, sarcoidosis), infection (eg, Lyme disease), or **age-related** fibrosis with cellular **degeneration**. Because conduction signals from the atria cannot communicate with the ventricles, the intrinsic pacemaker of the His bundle or ventricles is triggered, resulting in a junctional or ventricular escape rhythm. On ECG, there is **dissociation of P waves and QRS complexes**, with P waves marching out at the intrinsic rate of the sinoatrial node (~75/min) and QRS complexes at the intrinsic rate of the His bundle or ventricles (~45/min). The QRS-complex escape rhythm in this patient is particularly slow (ie, <30/min).

The slow ventricular rate in third-degree AV block leads to **reduced cardiac output**, potentially causing dyspnea, fatigue, lightheadedness, or syncope. Definitive management requires placement of a permanent pacemaker.

(Choice B) Degenerative changes involving the sinus node can lead to sick sinus syndrome, characterized by bradycardia with sinus pauses (delayed P waves) and sinus arrest (dropped P waves). However, there is no dissociation of P waves and QRS complexes.

(Choice C) Severe aortic stenosis increases afterload and can lead to concentric left ventricular hypertrophy. ECG demonstrates high-voltage QRS complexes, especially prominent in the S wave of V1 and V2 and the R wave of V5 and V6.

(Choice D) Sporadic and independent depolarization of atrial cardiomyocytes occurs in atrial fibrillation. On ECG, QRS intervals are irregular and P waves are absent.

(Choice E) Thrombotic occlusion of the distal left anterior descending artery can cause myocardial infarction of the left ventricle. Ischemic or infarcted ventricular myocardium can generate abnormal electrical impulses to trigger ventricular tachycardia. ECG demonstrates wide QRS complexes that are rapid and regular.

Educational objective:
Third-degree (complete) atrioventricular block involves dysfunction of the atrioventricular node, resulting in total lack of communication between the atria and ventricles. On ECG, there is dissociation of P waves and QRS complexes, with P waves marching out at the intrinsic rate of the sinoatrial node and QRS complexes at the intrinsic rate of the His bundle or ventricles (escape rhythm).

Lyme disease), or **age-related** fibrosis with cellular **degeneration**. Because conduction signals from the atria cannot communicate with the ventricles, the intrinsic pacemaker of the His bundle or ventricles is triggered, resulting in a junctional or ventricular escape rhythm. On ECG, there is **dissociation of P waves and QRS complexes**, with P waves marching out at the intrinsic rate of the sinoatrial node (~75/min) and QRS complexes at the intrinsic rate of the His bundle or ventricles (~45/min). The QRS-complex escape rhythm in this patient is particularly slow (ie, <30/min).

The slow ventricular rate in third-degree AV block leads to **reduced cardiac output**, potentially causing dyspnea, fatigue, lightheadedness, or syncope. Definitive management requires placement of a permanent pacemaker.

(Choice B) Degenerative changes involving the sinus node can lead to sick sinus syndrome, characterized by bradycardia with sinus pauses (delayed P waves) and sinus arrest (dropped P waves). However, there is no dissociation of P waves and QRS complexes.

(Choice C) Severe aortic stenosis increases afterload and can lead to concentric left ventricular hypertrophy. ECG demonstrates high-voltage QRS complexes, especially prominent in the S wave of V1 and V2 and the R wave of V5 and V6.

(Choice D) Sporadic and independent depolarization of atrial cardiomyocytes occurs in atrial fibrillation. On ECG, QRS intervals are irregular and P waves are absent.

(Choice E) Thrombotic occlusion of the distal left anterior descending artery can cause myocardial infarction of the left ventricle. Ischemic or infarcted ventricular myocardium can generate abnormal electrical impulses to trigger ventricular tachycardia. ECG demonstrates wide QRS complexes that are rapid and regular.

Educational objective:
Third-degree (complete) atrioventricular block involves dysfunction of the atrioventricular node, resulting in total lack of communication between the atria and ventricles. On ECG, there is dissociation of P waves and QRS complexes, with P waves marching out at the intrinsic rate of the sinoatrial node and QRS complexes at the intrinsic rate of the His bundle or ventricles (escape rhythm).

Pathology	Cardiovascular System	Heart block
Subject	System	Topic

Copyright © UWorld. All rights reserved.

artery disease requiring percutaneous coronary intervention. ECG obtained in the emergency department is shown in the exhibit. Which of the

Exhibit Display

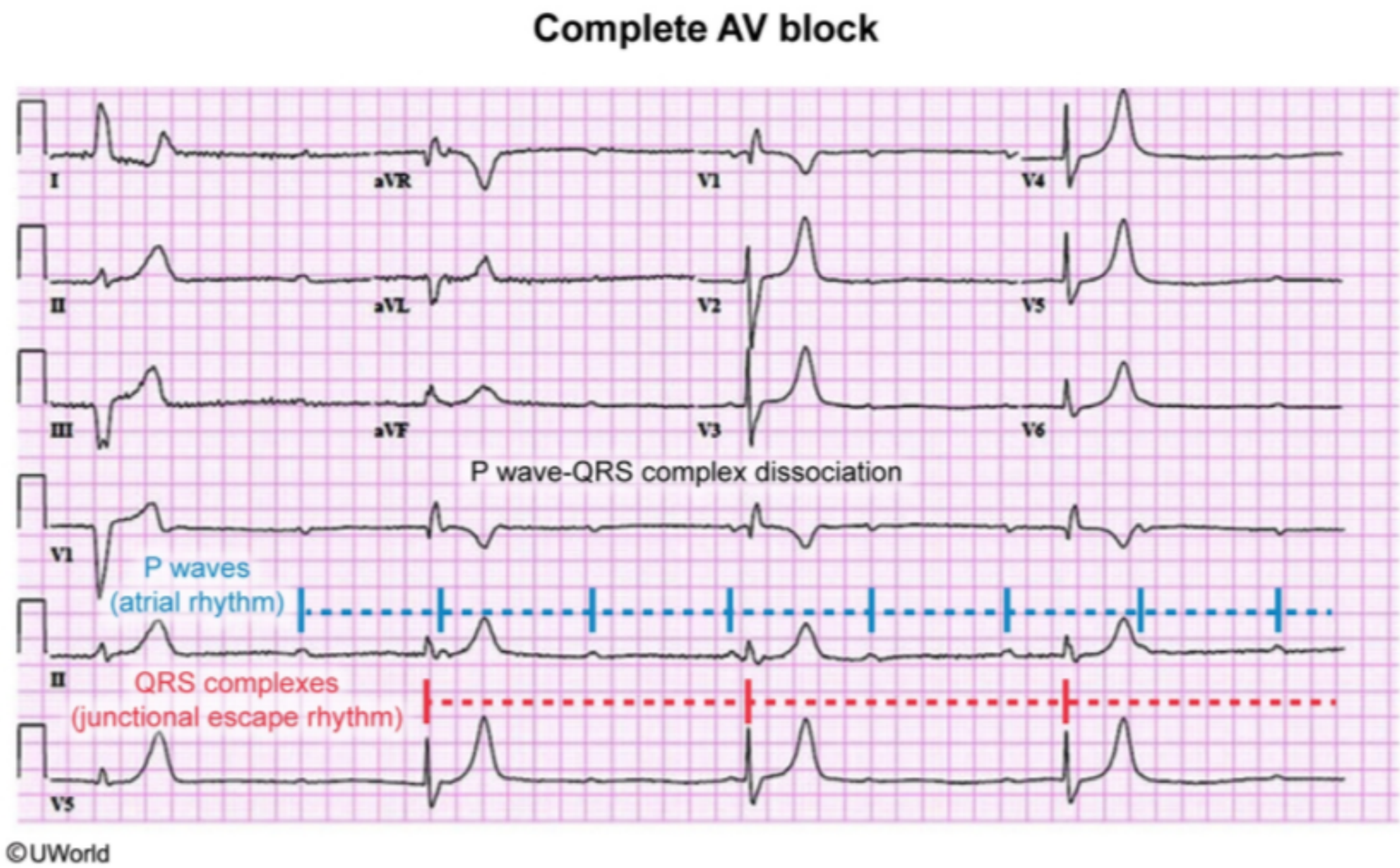

Zoom In | Zoom Out | Reset | Add To New Card | Existing Card

syncope. Definitive management requires placement of a permanent pacemaker.

Lyme disease), or **age-related** fibrosis with cellular **degeneration**. Because conduction signals from the atria cannot communicate with the

Exhibit Display

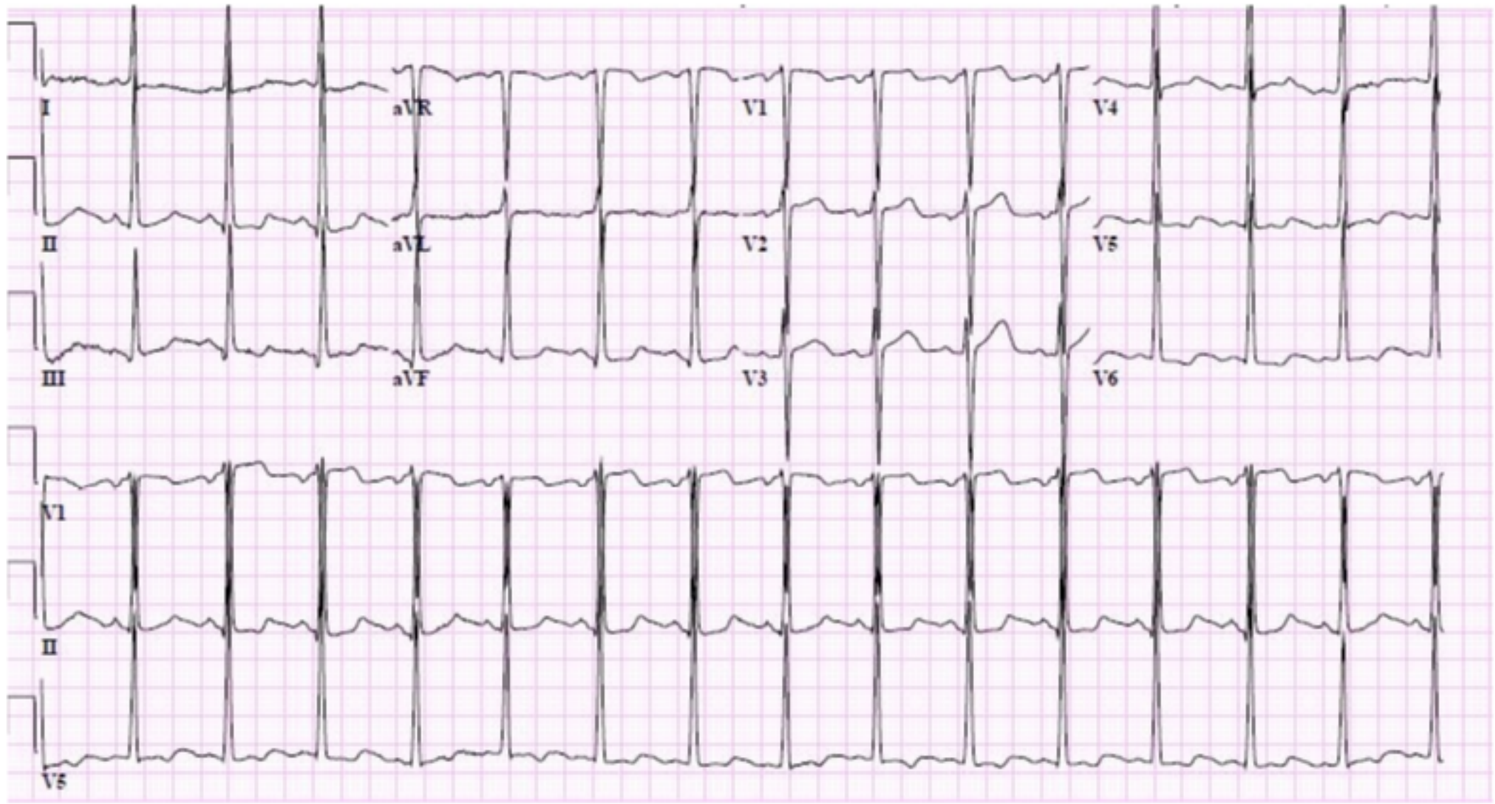

Zoom In | Zoom Out | Reset | Add To New Card | Existing Card

Lyme disease), or **age-related** fibrosis with cellular **degeneration**. Because conduction signals from the atria cannot communicate with the

Exhibit Display

Atrial fibrillation

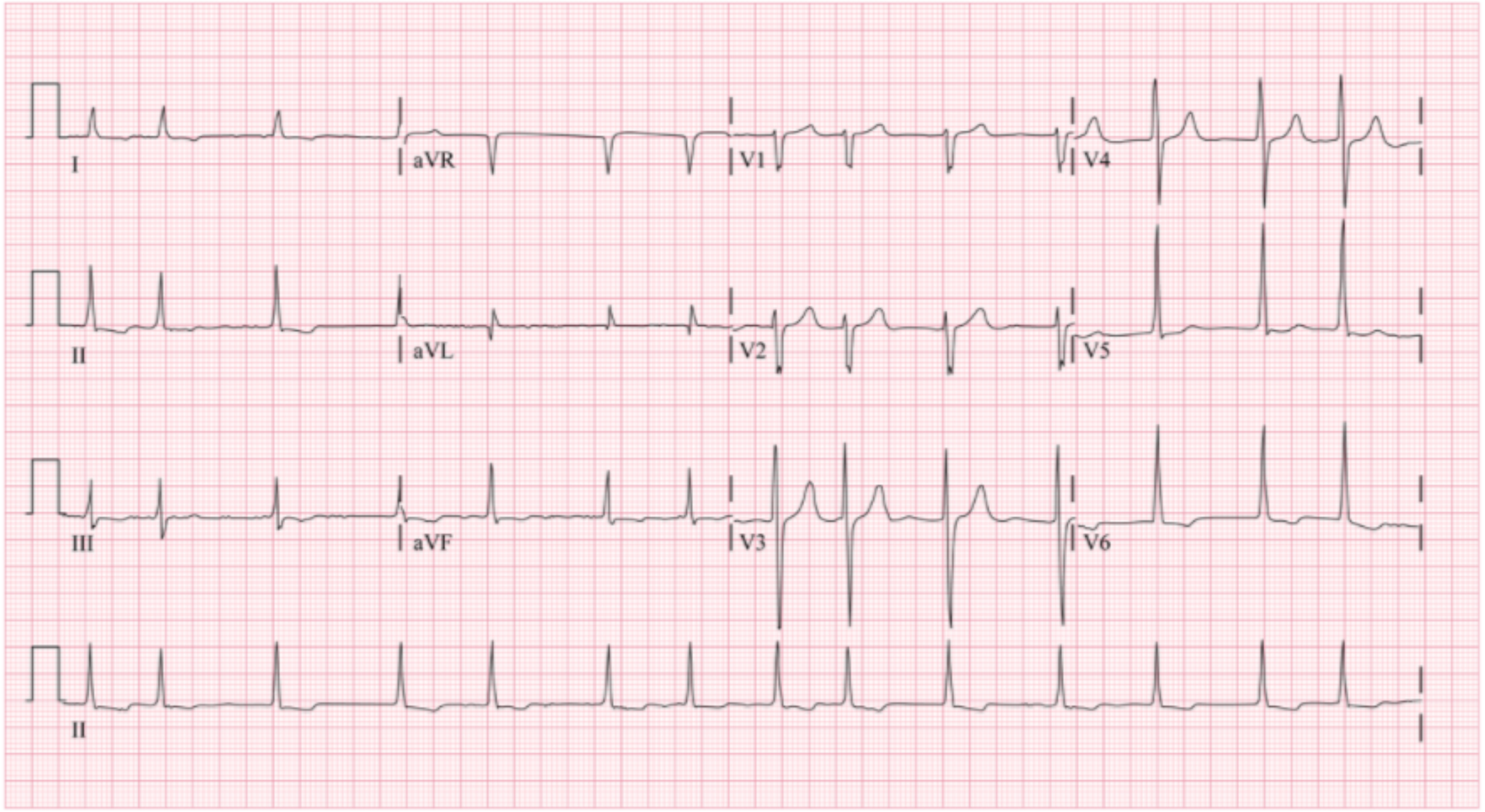

©UWorld

Zoom In | Zoom Out | Reset | Add To New Card | Existing Card

Lyme disease), or **age-related** fibrosis with cellular **degeneration**. Because conduction signals from the atria cannot communicate with the

Exhibit Display

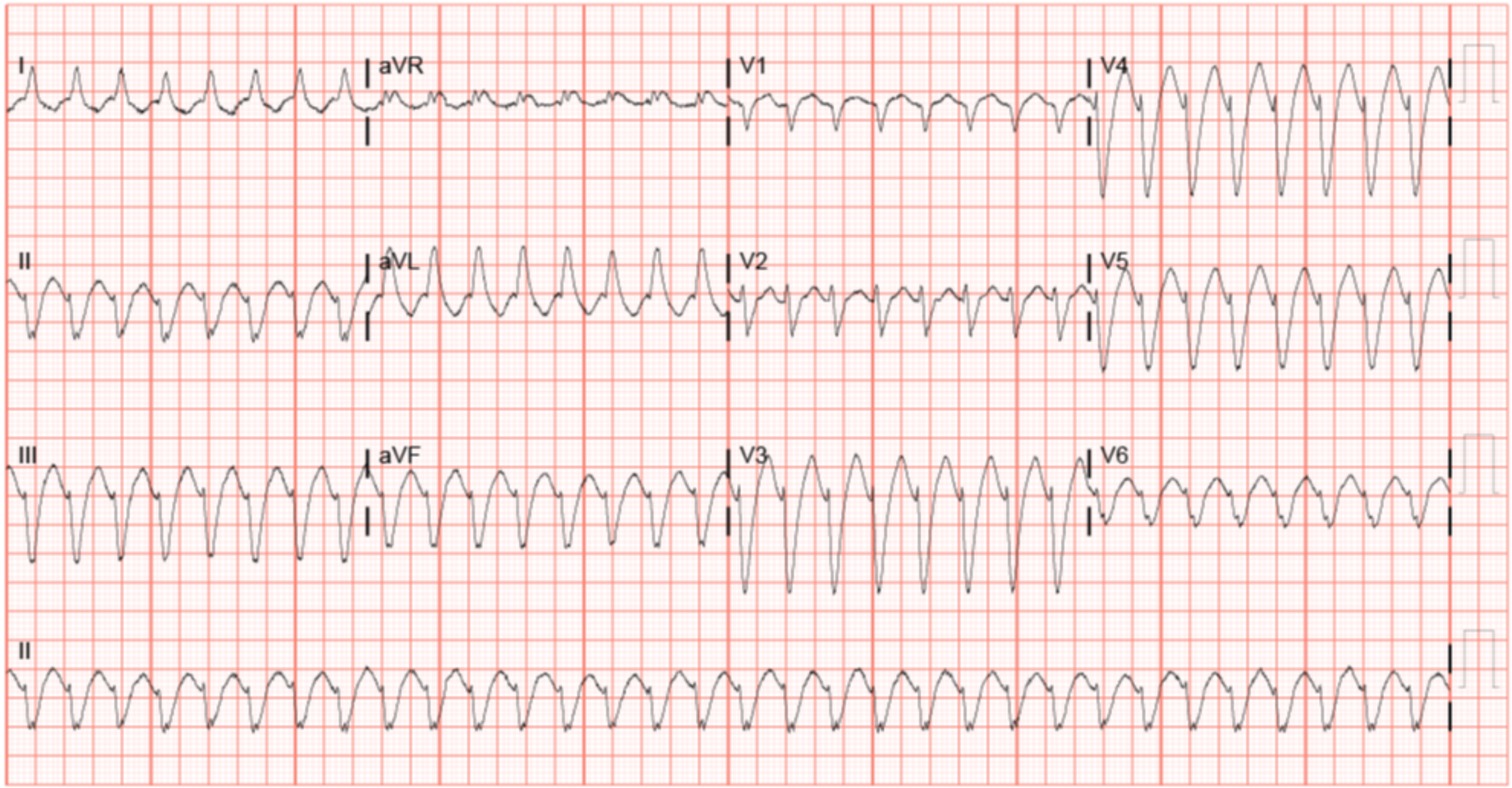

Zoom In | Zoom Out | Reset | Add To New Card | Existing Card

A 55-year-old man is brought to the emergency department due to severe substernal chest pain that is accompanied by sweating and mild dyspnea. The pain started as midline chest discomfort several hours ago but then progressively worsened such that the patient could not fall asleep. He received sublingual nitroglycerin in the ambulance without significant pain relief. His medical history includes hypertension, type 2 diabetes mellitus, and hyperlipidemia. ECG demonstrates normal sinus rhythm and ST-segment elevation in leads I, aVL, and V1-V4, with deep Q wave development over the next several hours. Cardiac catheterization in this patient would most likely show which of the following?

A. Atherosclerotic plaque obstructing 50% of the coronary artery lumen, no thrombus

B. Atherosclerotic plaque obstructing 80% of the coronary artery lumen, no thrombus

C. Ruptured atherosclerotic plaque with fully obstructive thrombus

D. Significant coronary artery vasospasm causing flow obstruction

E. Ulcerated atherosclerotic plaque with partially obstructive thrombus

Submit

1
2
3
4
5
6
7
8
9
10
11
12
13
14
15
16
17
18
19
20
21
22
23
24
25
26
27
28
29

A 55-year-old man is brought to the emergency department due to severe substernal chest pain that is accompanied by sweating and mild dyspnea. The pain started as midline chest discomfort several hours ago but then progressively worsened such that the patient could not fall asleep. He received sublingual nitroglycerin in the ambulance without significant pain relief. His medical history includes hypertension, type 2 diabetes mellitus, and hyperlipidemia. ECG demonstrates normal sinus rhythm and ST-segment elevation in leads I, aVL, and V1-V4, with deep Q wave development over the next several hours. Cardiac catheterization in this patient would most likely show which of the following?

A. Atherosclerotic plaque obstructing 50% of the coronary artery lumen, no thrombus (0%)

B. Atherosclerotic plaque obstructing 80% of the coronary artery lumen, no thrombus (9%)

✓ C. Ruptured atherosclerotic plaque with fully obstructive thrombus (81%)

D. Significant coronary artery vasospasm causing flow obstruction (4%)

E. Ulcerated atherosclerotic plaque with partially obstructive thrombus (4%)

Omitted
Correct answer
C

81%
Answered correctly

06 secs
Time Spent

01/07/2020
Last Updated

Explanation

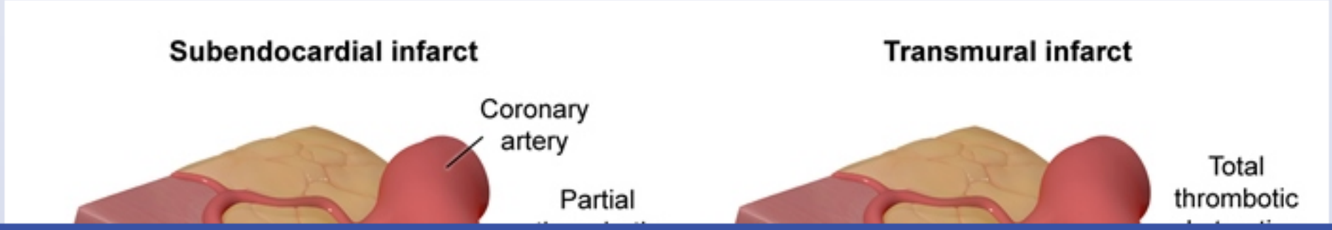

1
2
3
4
5
6
7
8
9
10
11
12
13
14
15
16
17
18
19
20
21
22
23
24
25
26
27
28
29

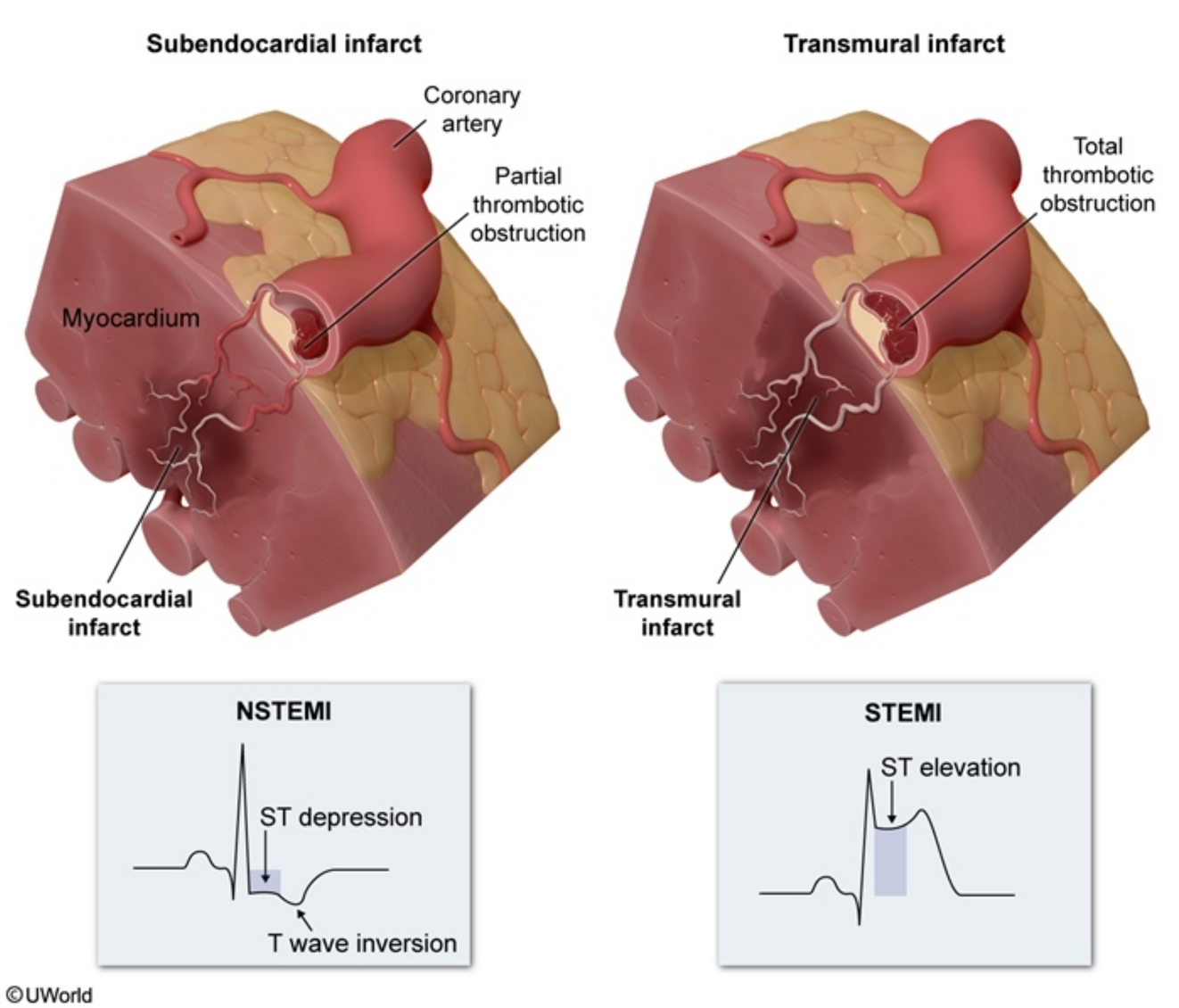

This patient with persistent substernal chest pain and ECG demonstrating ST elevation in the anterolateral leads has an **ST-elevation myocardial**

This patient with persistent substernal chest pain and ECG demonstrating ST elevation in the anterolateral leads has an **ST-elevation myocardial infarction** (STEMI). In the evolution of STEMI on ECG, peaked T waves in the affected leads are typically the first manifestation, followed by the appearance of ST elevation within several minutes, then Q waves within hours to days. Patients with STEMI typically have sudden-onset substernal chest pain that may be accompanied by nausea, diaphoresis, or dyspnea; the pain does not improve with rest or the administration of short-acting nitrates (eg, nitroglycerin).

Myocardial infarction is usually caused by acute **atherosclerotic plaque rupture** with release of lipids, collagen, and tissue factor into the blood stream; because these contents are highly thrombogenic, there is rapid formation of **overlying thrombus**. In STEMI, the overlying thrombus is extensive enough to fully occlude the coronary artery lumen, completely blocking blood flow to a portion of the heart and leading to transmural (full-thickness) infarction of the myocardial wall. Partially obstructive thrombus **(Choice E)** is likely to produce non-STEMI or unstable angina. Non-STEMI is associated with impaired blood flow to only the subendocardial region; the symptomatic presentation is similar to STEMI, but ECG reveals ST segment and T wave abnormalities with no ST elevation.

(Choice A) Atherosclerotic plaque obstructing 50% of the coronary artery lumen is likely to be asymptomatic. Symptoms of stable angina do not typically become prominent until >70% of the cross-sectional area of the coronary artery lumen is occluded.

(Choice B) Atherosclerotic plaque obstructing 80% of the coronary artery lumen is likely to cause stable angina, characterized by substernal or left-sided chest pressure, tightness, or pain that is precipitated by exertion and relieved by rest or short-acting nitrates.

(Choice D) Coronary artery vasospasm (vasospastic or Prinzmetal angina) results from hyperactivity of intimal smooth muscle, usually in the absence of significant atherosclerotic coronary artery disease. Transient anginal chest pain with corresponding ST elevation on ECG can occur; however, the chest pain should rapidly resolve with nitroglycerin.

Educational objective:
ST-elevation myocardial infarction involves transmural (full-thickness) infarction of the myocardial wall, and usually results from acute atherosclerotic plaque rupture with the development of overlying thrombus that fully occludes the coronary artery lumen. It classically presents with sudden-onset substernal chest pain that is not relieved by rest or short-acting nitrates. ECG demonstrates ST elevation in the affected leads with subsequent development of Q waves.

References

- Atherosclerotic plaque rupture—pathologic basis of plaque stability and instability.

This patient with persistent substernal chest pain and ECG demonstrating ST elevation in the anterolateral leads has an **ST-elevation myocardial infarction** (STEMI). In the evolution of STEMI on ECG, peaked T waves in the affected leads are typically the first manifestation, followed by the appearance of ST elevation within several minutes, then Q waves within hours to days. Patients with STEMI typically have sudden-onset substernal chest pain that may be accompanied by nausea, diaphoresis, or dyspnea; the pain does not improve with rest or the administration of short-acting nitrates (eg, nitroglycerin).

Myocardial infarction is usually caused by acute **atherosclerotic plaque rupture** with release of lipids, collagen, and tissue factor into the blood stream; because these contents are highly thrombogenic, there is rapid formation of **overlying thrombus**. In STEMI, the overlying thrombus is extensive enough to fully occlude the coronary artery lumen, completely blocking blood flow to a portion of the heart and leading to transmural (full-thickness) infarction of the myocardial wall. Partially obstructive thrombus **(Choice E)** is likely to produce non-STEMI or unstable angina. Non-STEMI is associated with impaired blood flow to only the subendocardial region; the symptomatic presentation is similar to STEMI, but ECG reveals ST segment and T wave abnormalities with no ST elevation.

(Choice A) Atherosclerotic plaque obstructing 50% of the coronary artery lumen is likely to be asymptomatic. Symptoms of stable angina do not typically become prominent until >70% of the cross-sectional area of the coronary artery lumen is occluded.

(Choice B) Atherosclerotic plaque obstructing 80% of the coronary artery lumen is likely to cause stable angina, characterized by substernal or left-sided chest pressure, tightness, or pain that is precipitated by exertion and relieved by rest or short-acting nitrates.

(Choice D) Coronary artery vasospasm (vasospastic or Prinzmetal angina) results from hyperactivity of intimal smooth muscle, usually in the absence of significant atherosclerotic coronary artery disease. Transient anginal chest pain with corresponding ST elevation on ECG can occur; however, the chest pain should rapidly resolve with nitroglycerin.

Educational objective:
ST-elevation myocardial infarction involves transmural (full-thickness) infarction of the myocardial wall, and usually results from acute atherosclerotic plaque rupture with the development of overlying thrombus that fully occludes the coronary artery lumen. It classically presents with sudden-onset substernal chest pain that is not relieved by rest or short-acting nitrates. ECG demonstrates ST elevation in the affected leads with subsequent development of Q waves.

References

- Atherosclerotic plaque rupture—pathologic basis of plaque stability and instability.

1
2
3
4
5
6
7
8
9
10
11
12
13
14
15
16
17
18
19
20
21
22
23
24
25
26
27
28
29

This patient with persistent substernal chest pain and ECG demonstrating ST elevation in the anterolateral leads has an **ST elevation myocardial**

Exhibit Display

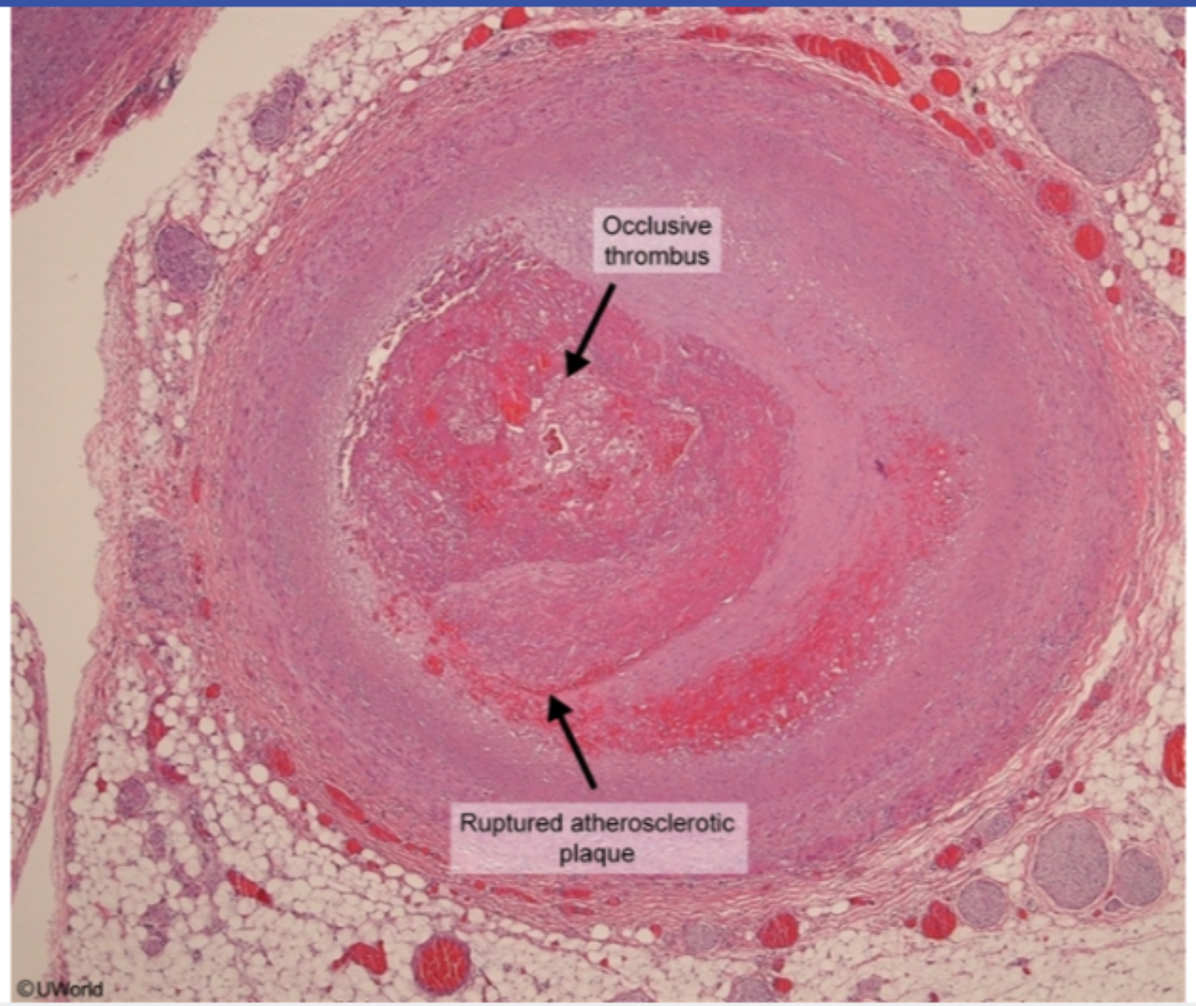

Zoom In | Zoom Out | Reset | Add To New Card | Existing Card

- Atherosclerotic plaque rupture—pathologic basis of plaque stability and instability.

This patient with persistent substernal chest pain and ECG demonstrating ST elevation in the anterolateral leads has an **ST-elevation myocardial infarction** (STEMI). In the evolution of STEMI on ECG, peaked T waves in the affected leads are typically the first manifestation, followed by the appearance of ST elevation within several minutes, then Q waves within hours to days. Patients with STEMI typically have sudden-onset substernal chest pain that may be accompanied by nausea, diaphoresis, or dyspnea; the pain does not improve with rest or the administration of short-acting nitrates (eg, nitroglycerin).

Myocardial infarction is usually caused by acute **atherosclerotic plaque rupture** with release of lipids, collagen, and tissue factor into the blood stream; because these contents are highly thrombogenic, there is rapid formation of **overlying thrombus**. In STEMI, the overlying thrombus is extensive enough to fully occlude the coronary artery lumen, completely blocking blood flow to a portion of the heart and leading to transmural (full-thickness) infarction of the myocardial wall. Partially obstructive thrombus **(Choice E)** is likely to produce non-STEMI or unstable angina. Non-STEMI is associated with impaired blood flow to only the subendocardial region; the symptomatic presentation is similar to STEMI, but ECG reveals ST segment and T wave abnormalities with no ST elevation.

(Choice A) Atherosclerotic plaque obstructing 50% of the coronary artery lumen is likely to be asymptomatic. Symptoms of stable angina do not typically become prominent until >70% of the cross-sectional area of the coronary artery lumen is occluded.

(Choice B) Atherosclerotic plaque obstructing 80% of the coronary artery lumen is likely to cause stable angina, characterized by substernal or left-sided chest pressure, tightness, or pain that is precipitated by exertion and relieved by rest or short-acting nitrates.

(Choice D) Coronary artery vasospasm (vasospastic or Prinzmetal angina) results from hyperactivity of intimal smooth muscle, usually in the absence of significant atherosclerotic coronary artery disease. Transient anginal chest pain with corresponding ST elevation on ECG can occur; however, the chest pain should rapidly resolve with nitroglycerin.

Educational objective:
ST-elevation myocardial infarction involves transmural (full-thickness) infarction of the myocardial wall, and usually results from acute atherosclerotic plaque rupture with the development of overlying thrombus that fully occludes the coronary artery lumen. It classically presents with sudden-onset substernal chest pain that is not relieved by rest or short-acting nitrates. ECG demonstrates ST elevation in the affected leads with subsequent development of Q waves.

References

- Atherosclerotic plaque rupture—pathologic basis of plaque stability and instability.

1
2
3
4
5
6
7
8
9
10
11
12
13
14
15
16
17
18
19
20
21
22
23
24
25
26
27
28
29

This patient with persistent substernal chest pain and ECG demonstrating ST elevation in the anterolateral leads has an **ST elevation myocardial**

Exhibit Display

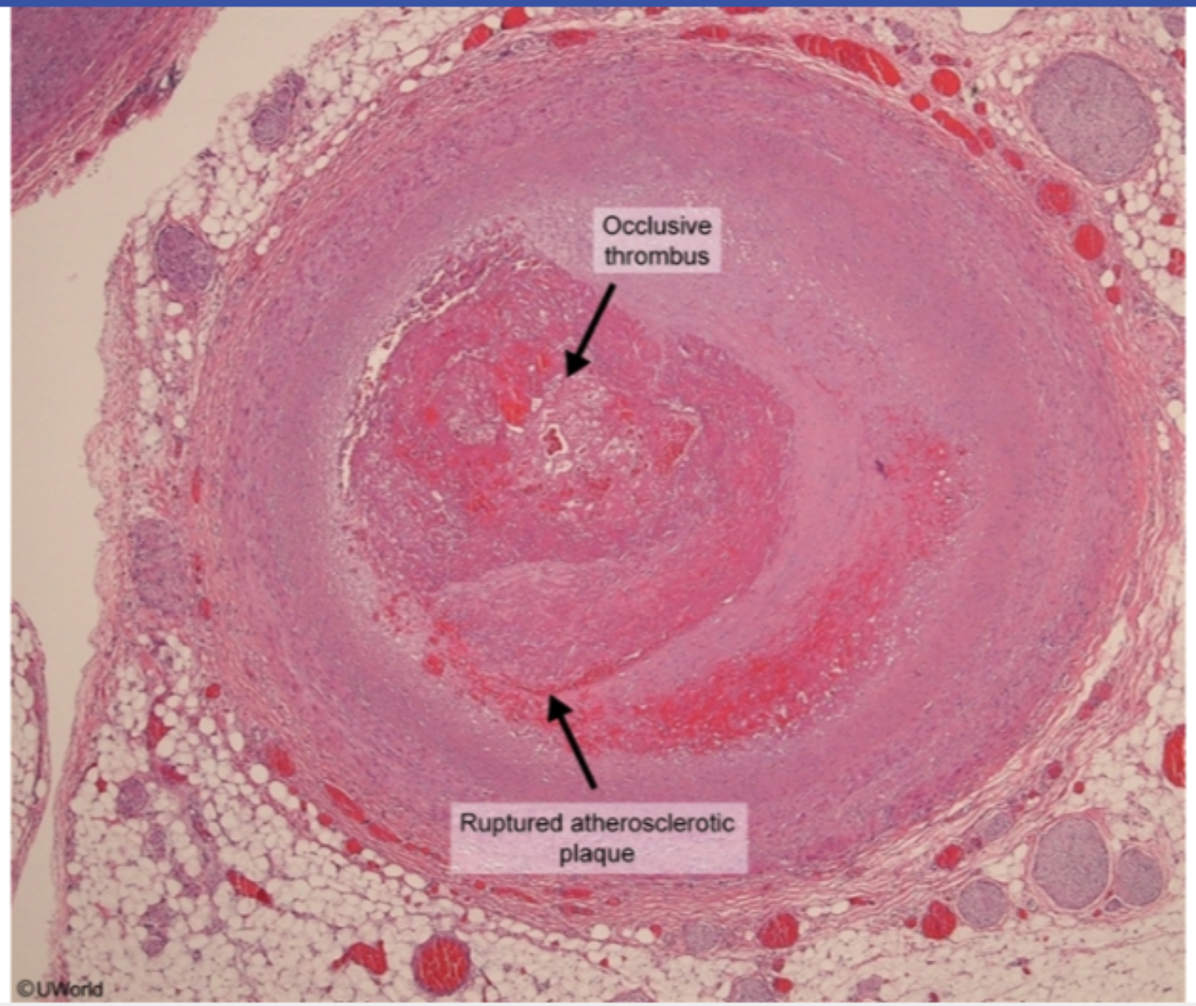

Zoom In | Zoom Out | Reset | Add To New Card | Existing Card

- Atherosclerotic plaque rupture—pathologic basis of plaque stability and instability.

1
2
3
4
5
6
7
8
9
10
11
12
13
14
15
16
17
18
19
20
21
22
23
24
25
26
27
28
29

A 24-year-old woman comes to the physician with a 3-week history of progressive fatigue. Physical examination shows lesions involving the nail beds, as seen in the photograph below.

Further evaluation would most likely reveal additional abnormalities during which part of the physical examination?

1
2
3
4
5
6
7
8
9
10
11
12
13
14
15
16
17
18
19
20
21
22
23
24
25
26
27
28
29

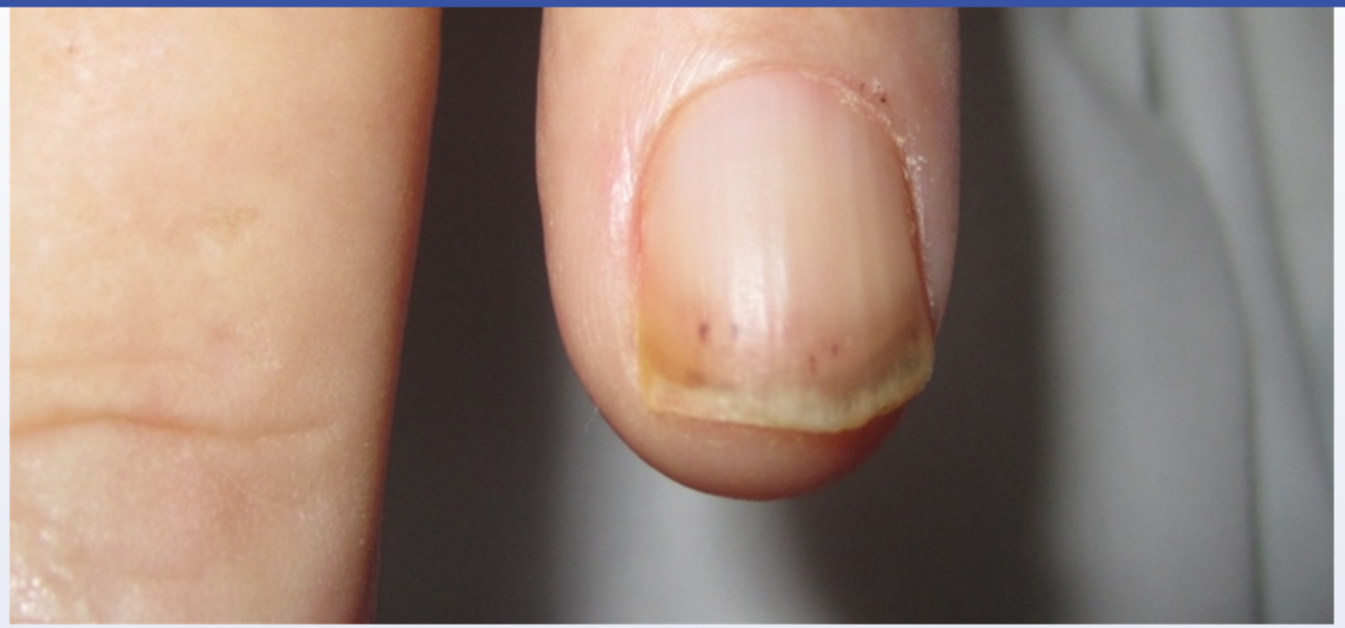

Further evaluation would most likely reveal additional abnormalities during which part of the physical examination?

- A. Neck palpation
- B. Lung auscultation
- C. Cardiac auscultation
- D. Abdominal palpation
- E. Rectal examination

Submit

1
2
3
4
5
6
7
8
9
10
11
12
13
14
15
16
17
18
19
20
21
22
23
24
25
26
27
28
29

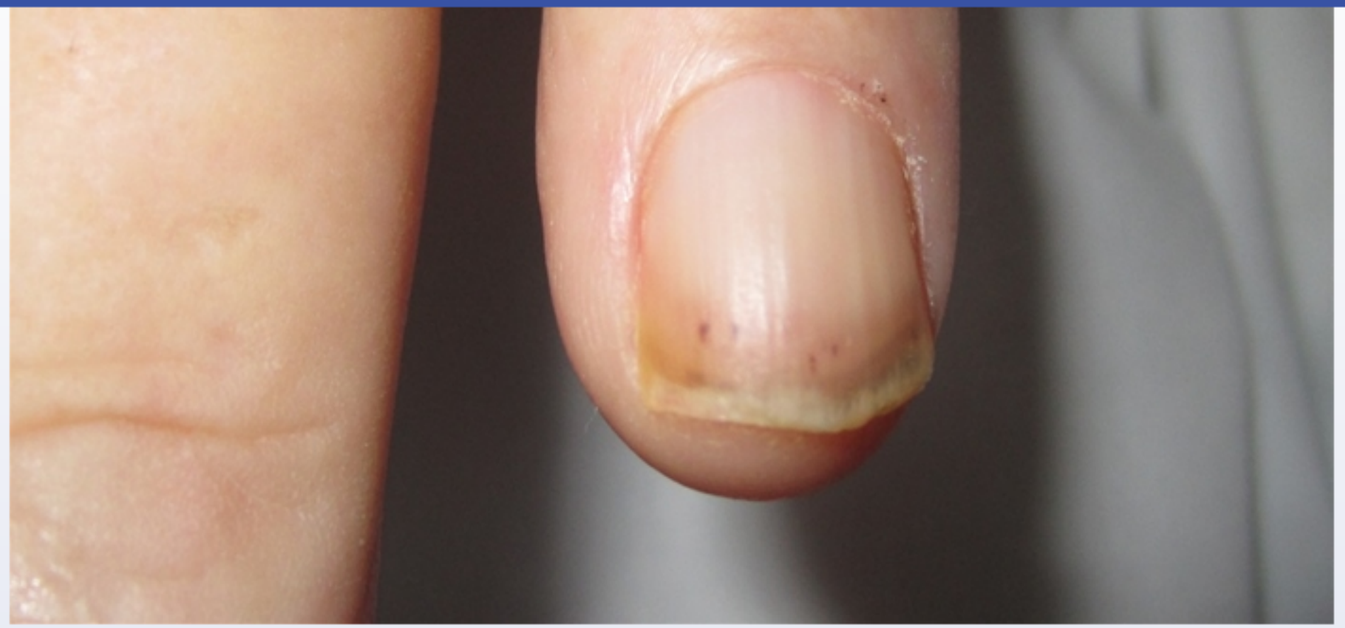

Further evaluation would most likely reveal additional abnormalities during which part of the physical examination?

A. Neck palpation (1%)

B. Lung auscultation (4%)

✓ C. Cardiac auscultation (89%)

D. Abdominal palpation (3%)

E. Rectal examination (0%)

Omitted
Correct answer

89%
Answered correctly

08 secs
Time Spent

04/09/2020
Last Updated

1
2
3
4
5
6
7
8
9
10
11
12
13
14
15
16
17
18
19
20
21
22
23
24
25
26
27
28
29

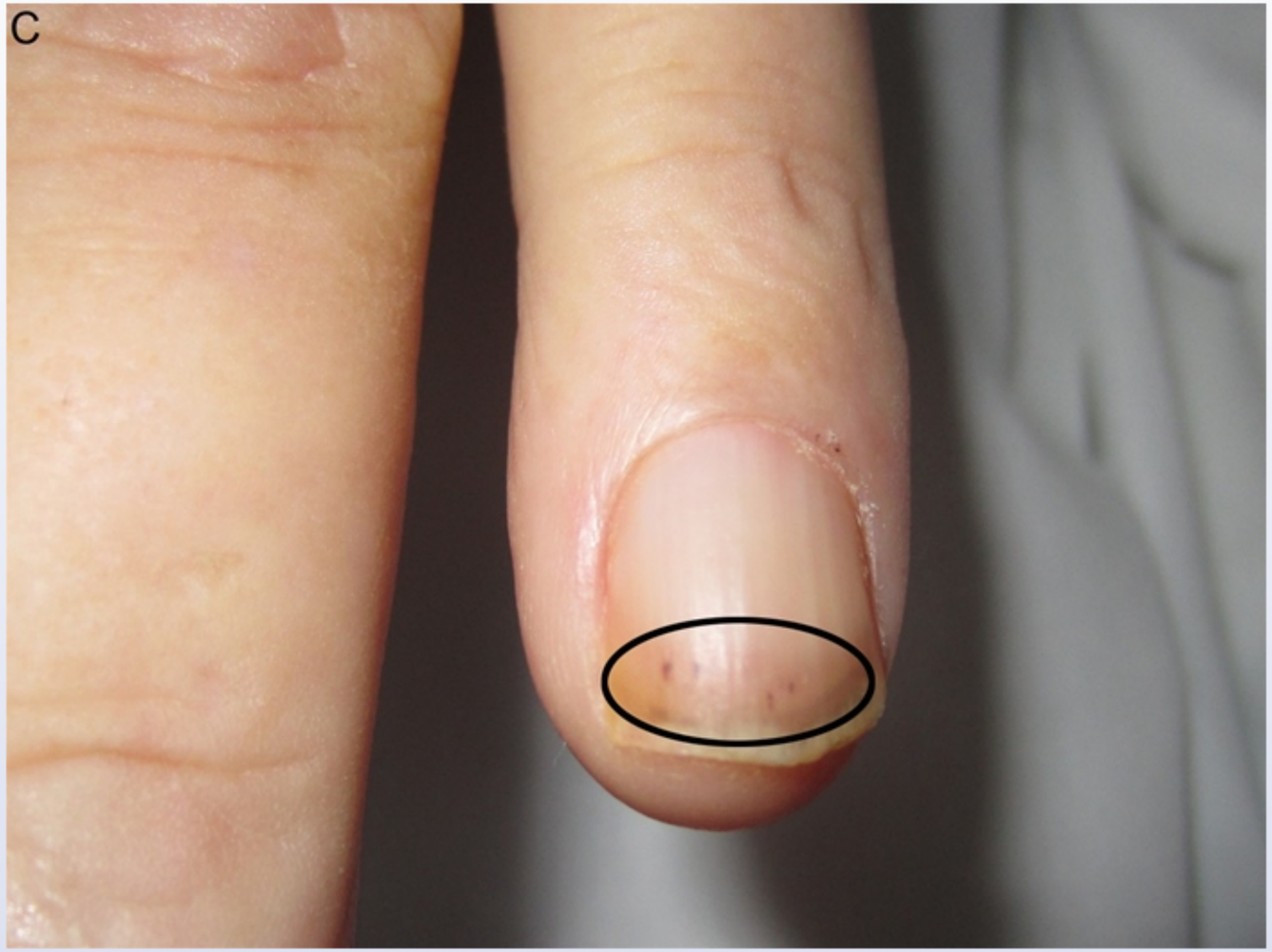

These lesions are subungual splinter hemorrhages, splinter- or flame-shaped hemorrhagic streaks in the nail bed that appear as a consequence of microemboli. Janeway lesions (small, macular, erythematous or hemorrhagic, nontender lesions on the palms and soles) are also a sign of microembolism. Infectious endocarditis (IE) is the usual cause of such microemboli, and progressive fatigue may be the presenting symptom of subacute bacterial endocarditis. Chronically destructive, infected vegetations involving the cardiac valves are the source of the microemboli in

1
2
3
4
5
6
7
8
9
10
11
12
13
14
15
16
17
18
19
20
21
22
23
24
25
26
27
28
29

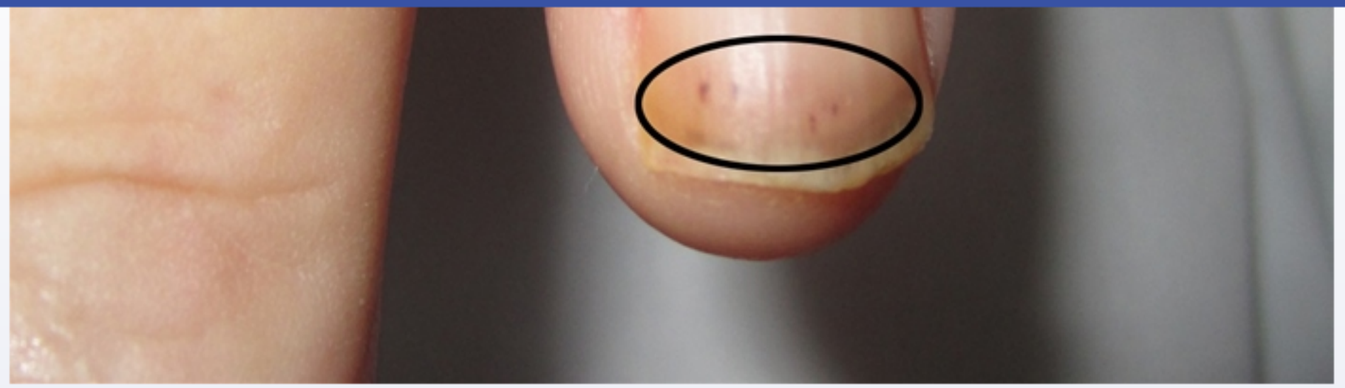

These lesions are subungual splinter hemorrhages, splinter- or flame-shaped hemorrhagic streaks in the nail bed that appear as a consequence of microemboli. Janeway lesions (small, macular, erythematous or hemorrhagic, nontender lesions on the palms and soles) are also a sign of microembolism. Infectious endocarditis (IE) is the usual cause of such microemboli, and progressive fatigue may be the presenting symptom of subacute bacterial endocarditis. Chronically destructive, infected vegetations involving the cardiac valves are the source of the microemboli in bacterial endocarditis. Patients with suspected IE should therefore be evaluated for a regurgitant murmur during cardiac auscultation.

(Choices A, B, and D) Unless the primary source of the bacteremia initiating the IE is a focal neck, pulmonary, or abdominal infection, one would not expect to find any abnormalities in these systems.

(Choice E) Unless the primary source of the original bacteremia was a peri-rectal infection or necrotic, infected rectal neoplasm, one would not expect to find any abnormalities on rectal examination.

Educational objective:
Microemboli from the valvular vegetations of bacterial endocarditis are the most common cause of subungual splinter hemorrhages. The presence of these lesions necessitates careful cardiac auscultation to detect a possible new-onset regurgitant murmur.

Pathology	Cardiovascular System	Endocarditis
Subject	System	Topic

Copyright © UWorld. All rights reserved.

A 54-year-old Caucasian male comes to the emergency room with retrosternal chest pain of 30 minutes duration. The patient also complains of sweating and mild dyspnea. A single tablet of nitroglycerin is delivered sublingually, and the patient's pain decreases significantly. The patient has experienced several similar episodes of pain over the last 12 hours, all of which resolved spontaneously. Which of the following ultrastructural changes would most likely indicate irreversible myocardial cell injury in this patient?

- A. Myofibril relaxation
- B. Disaggregation of polysomes
- C. Mitochondrial vacuolization
- D. Disaggregation of nuclear granules
- E. Triglyceride droplet accumulation
- F. Glycogen loss

Submit

A 54-year-old Caucasian male comes to the emergency room with retrosternal chest pain of 30 minutes duration. The patient also complains of sweating and mild dyspnea. A single tablet of nitroglycerin is delivered sublingually, and the patient's pain decreases significantly. The patient has experienced several similar episodes of pain over the last 12 hours, all of which resolved spontaneously. Which of the following ultrastructural changes would most likely indicate irreversible myocardial cell injury in this patient?

- A. Myofibril relaxation
- B. Disaggregation of polysomes
- C. Mitochondrial vacuolization
- D. Disaggregation of nuclear granules
- E. Triglyceride droplet accumulation
- F. Glycogen loss

Submit

A 54-year-old Caucasian male comes to the emergency room with retrosternal chest pain of 30 minutes duration. The patient also complains of sweating and mild dyspnea. A single tablet of nitroglycerin is delivered sublingually, and the patient's pain decreases significantly. The patient has experienced several similar episodes of pain over the last 12 hours, all of which resolved spontaneously. Which of the following ultrastructural changes would most likely indicate irreversible myocardial cell injury in this patient?

- A. Myofibril relaxation (3%)
- B. Disaggregation of polysomes (3%)
- ✓ C. Mitochondrial vacuolization (59%)
- D. Disaggregation of nuclear granules (28%)
- E. Triglyceride droplet accumulation (2%)
- F. Glycogen loss (2%)

Omitted
Correct answer
C

59%
Answered correctly

03 mins
Time Spent

02/03/2020
Last Updated

Explanation

The appearance of vacuoles and phospholipid-containing amorphous densities within mitochondria generally signifies irreversible injury, and implies a permanent inability to generate further ATP via oxidative phosphorylation. When the mitochondria are injured irreversibly, the cell cannot recover. Simple mitochondrial swelling may be associated with reversible cellular injury, however.

(Choice A) Myofibril relaxation is an early sign of *reversible* injury in cardiac myocytes, which occurs within the first 30 minutes of severe ischemia

1
2
3
4
5
6
7
8
9
10
11
12
13
14
15
16
17
18
19
20
21
22
23
24
25
26
27
28
29

The appearance of vacuoles and phospholipid-containing amorphous densities within mitochondria generally signifies irreversible injury, and implies a permanent inability to generate further ATP via oxidative phosphorylation. When the mitochondria are injured irreversibly, the cell cannot recover. Simple mitochondrial swelling may be associated with reversible cellular injury, however.

(Choice A) Myofibril relaxation is an early sign of *reversible* injury in cardiac myocytes, which occurs within the first 30 minutes of severe ischemia. Myofibril relaxation corresponds with intracellular ATP depletion and lactate accumulation due to anaerobic glycolysis during this period.

(Choice B) Disaggregation of polysomes denotes the dissociation of rRNA from mRNA in *reversible* ischemic/hypoxic injury. Depletion of intracellular ATP is thought to promote the dissolution of polysomes into monosomes as well as the detachment of ribosomes from the rough endoplasmic reticulum. Disaggregation of polysomes results in impaired protein synthesis.

(Choice D) Disaggregation of granular and fibrillar elements of the nucleus is associated with *reversible* cell injury. Another common nuclear change associated with reversible cell injury is clumping of nuclear chromatin, perhaps secondary to a decrease in intracellular pH.

(Choice E) Triglyceride droplet accumulation is characteristic of *reversible* cell injury, especially in hepatocytes, and also in striated muscle cells and renal cells. This fatty change may result from the decreased synthesis of intracellular proteins that occurs with cell injury. In the hepatocyte, decreased production of lipid acceptor proteins prevents the normal incorporation of triglycerides into lipoproteins. Since triglycerides cannot be rapidly exported from the cell in the form of lipoproteins, they accumulate intracellularly.

(Choice F) Glycogen loss is another early and *reversible* cellular response to injury. As a result of lowered mitochondrial ATP production, ATP must be supplied to the cell via anaerobic glycolysis of glucose derived from the cell's glycogen stores. Myocardial glycogen stores may be completely depleted within 30 minutes of the onset of severe ischemia.

Educational Objective:
Mitochondrial vacuolization is typically a sign of irreversible cell injury, signifying that the involved mitochondria are permanently unable to generate ATP.

Pathology	Cardiovascular System	Myocardial infarction
Subject	System	Topic

A 74-year-old man is brought to the emergency department due to acute-onset lower abdominal and back pain that was followed by an episode of syncope 2 hours ago. The pain is sharp and constant. He has had no changes in bowel or bladder function. Other medical conditions include hypertension and hyperlipidemia. The patient has a 50-pack-year history of smoking cigarettes. Temperature is 36.9 C (98.4 F), blood pressure is 90/60 mm Hg, pulse is 108/min and regular, and respirations are 18/min. BMI is 34 kg/m^2. The patient is diaphoretic and appears pale. Heart and lung sounds are normal. Abdominal examination reveals moderate tenderness to deep palpation in the lower abdomen; there is no guarding or rebound tenderness. Bowel sounds are normal. Which of the following is the most likely diagnosis?

A. Acute mesenteric ischemia
B. Colonic perforation
C. Renal colic
D. Ruptured abdominal aortic aneurysm
E. Vertebral compression fracture

Submit

A 74-year-old man is brought to the emergency department due to acute-onset lower abdominal and back pain that was followed by an episode of syncope 2 hours ago. The pain is sharp and constant. He has had no changes in bowel or bladder function. Other medical conditions include hypertension and hyperlipidemia. The patient has a 50-pack-year history of smoking cigarettes. Temperature is 36.9 C (98.4 F), blood pressure is 90/60 mm Hg, pulse is 108/min and regular, and respirations are 18/min. BMI is 34 kg/m^2. The patient is diaphoretic and appears pale. Heart and lung sounds are normal. Abdominal examination reveals moderate tenderness to deep palpation in the lower abdomen; there is no guarding or rebound tenderness. Bowel sounds are normal. Which of the following is the most likely diagnosis?

- A. Acute mesenteric ischemia (18%)
- B. Colonic perforation (2%)
- C. Renal colic (1%)
- ✓ D. Ruptured abdominal aortic aneurysm (75%)
- E. Vertebral compression fracture (1%)

Omitted
Correct answer
D

75%
Answered correctly

04 secs
Time Spent

04/18/2020
Last Updated

Explanation

Abdominal aortic aneurysm	
Risk factors	• Advanced age (>60) • Smoking, male sex, hypertension

1
2
3
4
5
6
7
8
9
10
11
12
13
14
15
16
17
18
19
20
21
22
23
24
25
26
27
28
29

Abdominal aortic aneurysm	
Risk factors	• Advanced age (>60) • Smoking, male sex, hypertension • History of atherosclerosis or CTD

Clinical presentation	• Asymptomatic until rupture or rapid expansion
	• Rupture
	  ◦ Sudden, severe abdominal/back pain ± shock
	  ◦ Umbilical/flank hematoma

Management	• Smoking cessation • Periodic imaging to assess for expansion • Elective repair for large, asymptomatic aneurysm

CTD = connective tissue disease.

Ruptured abdominal aortic aneurysm (AAA) is a surgical emergency involving full-thickness compromise of the aortic wall with extravasation of blood into surrounding tissues and spaces. The **acute onset** of **severe abdominal and back pain** is the most common presenting symptom. In general, anterior rupture into the **peritoneal cavity** is quickly accompanied by **syncope**, hypotension, and **shock**, whereas posterior rupture into the retroperitoneum may be temporarily contained, resulting in delayed onset of hemodynamic instability. Other signs suggesting AAA rupture include abdominal distension, a pulsatile abdominal mass, and umbilical or flank hematoma (indicators of retroperitoneal hemorrhage).

Early detection of AAA can be difficult because patients frequently have few symptoms until the AAA either ruptures or markedly expands. Therefore, ruptured AAA should be suspected in patients with consistent symptoms and known **risk factors**, which include advanced age (>60), **smoking**, male sex, and a history of atherosclerosis or connective tissue disease. CT imaging can confirm the diagnosis, but hemodynamically unstable patients with suspected ruptured AAA should go straight to emergent surgical repair.

(Choice A) Acute mesenteric ischemia has similar risk factors to AAA. Patients typically describe severe abdominal pain but have few findings on physical examination (eg, minimal tenderness) and hypotension and syncope are not usually seen.

Ruptured abdominal aortic aneurysm (AAA) is a surgical emergency involving full-thickness compromise of the aortic wall with extravasation of blood into surrounding tissues and spaces. The **acute onset** of **severe abdominal and back pain** is the most common presenting symptom. In general, anterior rupture into the **peritoneal cavity** is quickly accompanied by **syncope**, hypotension, and **shock**, whereas posterior rupture into the retroperitoneum may be temporarily contained, resulting in delayed onset of hemodynamic instability. Other signs suggesting AAA rupture include abdominal distension, a pulsatile abdominal mass, and umbilical or flank hematoma (indicators of retroperitoneal hemorrhage).

Early detection of AAA can be difficult because patients frequently have few symptoms until the AAA either ruptures or markedly expands. Therefore, ruptured AAA should be suspected in patients with consistent symptoms and known **risk factors**, which include advanced age (>60), **smoking**, male sex, and a history of atherosclerosis or connective tissue disease. CT imaging can confirm the diagnosis, but hemodynamically unstable patients with suspected ruptured AAA should go straight to emergent surgical repair.

(Choice A) Acute mesenteric ischemia has similar risk factors to AAA. Patients typically describe severe abdominal pain but have few findings on physical examination (eg, minimal tenderness) and hypotension and syncope are not usually seen.

(Choice B) Colonic perforation can be due to diverticulitis, malignancy, or complications from colonoscopy. Patients can develop hypotension due to sepsis, but signs of infection (eg, fever) and peritonitis (eg, rebound, guarding) are also expected.

(Choice C) Renal colic is characterized by episodic (eg, every 30 min) flank or groin pain due to capsular stretch from nephrolithiasis-associated obstruction. Hypotension and syncope are not typical features.

(Choice E) Vertebral compression fractures can cause acute back pain exacerbated by minimal movement (eg, coughing, bending). Although the pain can occasionally refer to the abdomen, it is most commonly at the midline over the spinous processes. There should not be associated hypotension.

Educational objective:
Ruptured abdominal aortic aneurysm is a surgical emergency that usually presents with the acute onset of severe abdominal and back pain in patients with appropriate risk factors (eg, advanced age, smoking, atherosclerosis). Accompanying syncope, hypotension, and shock may occur quickly (intraperitoneal rupture) or may be delayed (retroperitoneal rupture).

References

- Abdominal aortic aneurysm.

1
2
3
4
5
6
7
8
9
10
11
12
13
14
15
16
17
18
19
20
21
22
23
24
25
26
27
28
29

Ruptured abdominal aortic aneurysm (AAA) is a surgical emergency involving full thickness compromise of the aortic wall with extravasation of

Exhibit Display

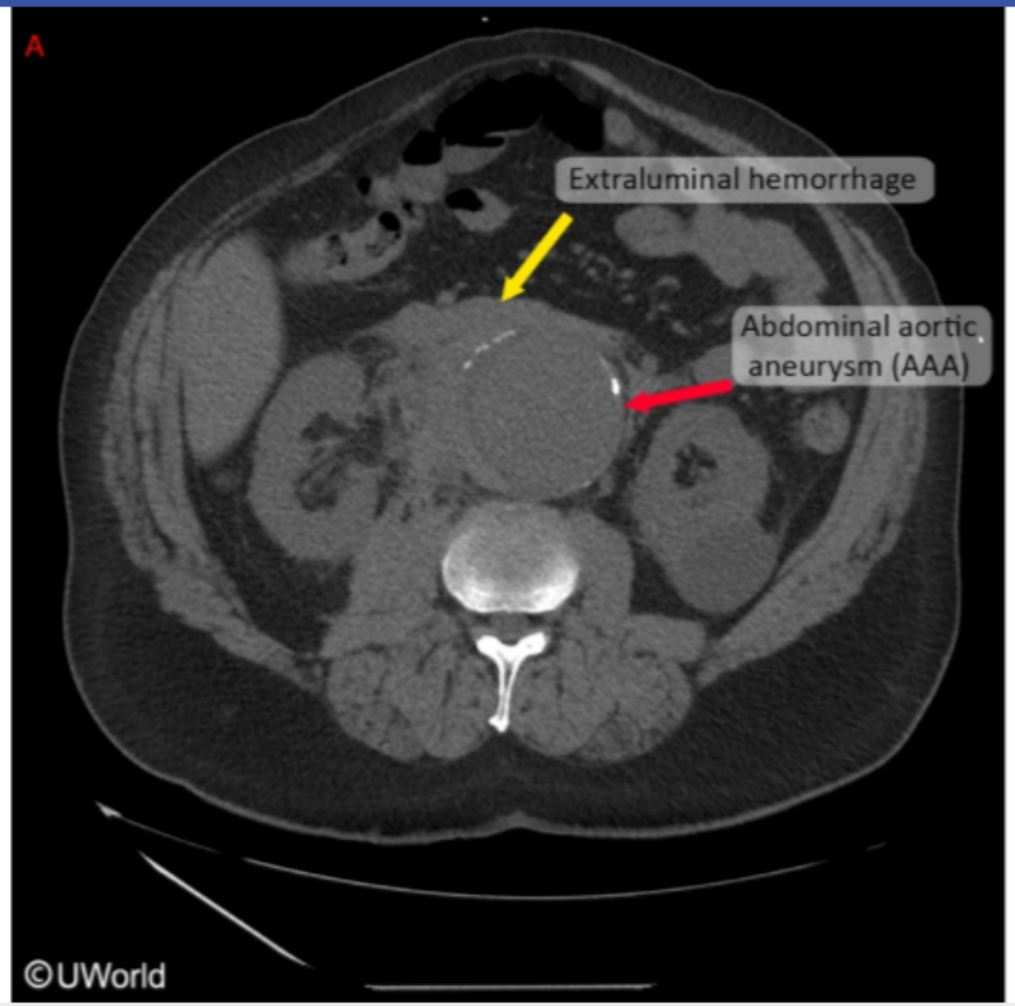

Zoom In | Zoom Out | Reset | Add To New Card | Existing Card

- Abdominal aortic aneurysm.

Therefore, ruptured AAA should be suspected in patients with consistent symptoms and known **risk factors**, which include advanced age (>60), **smoking**, male sex, and a history of atherosclerosis or connective tissue disease. CT imaging can confirm the diagnosis, but hemodynamically unstable patients with suspected ruptured AAA should go straight to emergent surgical repair.

(Choice A) Acute mesenteric ischemia has similar risk factors to AAA. Patients typically describe severe abdominal pain but have few findings on physical examination (eg, minimal tenderness) and hypotension and syncope are not usually seen.

(Choice B) Colonic perforation can be due to diverticulitis, malignancy, or complications from colonoscopy. Patients can develop hypotension due to sepsis, but signs of infection (eg, fever) and peritonitis (eg, rebound, guarding) are also expected.

(Choice C) Renal colic is characterized by episodic (eg, every 30 min) flank or groin pain due to capsular stretch from nephrolithiasis-associated obstruction. Hypotension and syncope are not typical features.

(Choice E) Vertebral compression fractures can cause acute back pain exacerbated by minimal movement (eg, coughing, bending). Although the pain can occasionally refer to the abdomen, it is most commonly at the midline over the spinous processes. There should not be associated hypotension.

Educational objective:
Ruptured abdominal aortic aneurysm is a surgical emergency that usually presents with the acute onset of severe abdominal and back pain in patients with appropriate risk factors (eg, advanced age, smoking, atherosclerosis). Accompanying syncope, hypotension, and shock may occur quickly (intraperitoneal rupture) or may be delayed (retroperitoneal rupture).

References

- Abdominal aortic aneurysm.
- Ruptured abdominal aortic aneurysm: the state of play.

Pathology	Cardiovascular System	Aortic aneurysm
Subject	System	Topic

Copyright © UWorld. All rights reserved.

1
2
3
4
5
6
7
8
9
10
11
12
13
14
15
16
17
18
19
20
21
22
23
24
25
26
27
28
29

A 32-year-old man dies suddenly in his sleep. He had been experiencing easy fatigability for the past 6 months and mentioned that he was feeling tired "'all the time'" and needed to take naps during the day. He did not drink alcohol or use illicit drugs. He smoked a pack of cigarettes per day for 10 years. His father died from a "heart problem" at age 40. On autopsy, the heart appears grossly enlarged. A layered mural thrombus is seen in the left ventricular apex. Coronary atherosclerosis is present, with 20% narrowing of the mid-left anterior descending artery and 25% narrowing of the left circumflex artery. Which of the following is the most likely cause of death of this patient?

A. Antiphospholipid antibody syndrome
B. Dilated cardiomyopathy
C. Hypertrophic cardiomyopathy
D. Ischemic heart disease
E. Restrictive cardiomyopathy

Submit

A 32-year-old man dies suddenly in his sleep. He had been experiencing easy fatigability for the past 6 months and mentioned that he was feeling tired "'all the time'" and needed to take naps during the day. He did not drink alcohol or use illicit drugs. He smoked a pack of cigarettes per day for 10 years. His father died from a "heart problem" at age 40. On autopsy, the heart appears grossly enlarged. A layered mural thrombus is seen in the left ventricular apex. Coronary atherosclerosis is present, with 20% narrowing of the mid-left anterior descending artery and 25% narrowing of the left circumflex artery. Which of the following is the most likely cause of death of this patient?

- A. Antiphospholipid antibody syndrome (8%)
- ✓ B. Dilated cardiomyopathy (44%)
- C. Hypertrophic cardiomyopathy (30%)
- D. Ischemic heart disease (12%)
- E. Restrictive cardiomyopathy (3%)

Omitted
Correct answer
B

44%
Answered correctly

04 secs
Time Spent

02/23/2020
Last Updated

Explanation

This patient most likely died due to **dilated cardiomyopathy** (DCM). A primary insult to the myocardium leads to impaired myocardial contractile function with dilation of one or both ventricles. The structural changes to the ventricular myocardium places these patients at risk of **sudden cardiac death** from ventricular arrhythmia (ie, ventricular tachycardia, ventricular fibrillation). In addition, the global hypokinesis of the left ventricle leads to stagnation of blood flow and the possible development of LV mural thrombus and subsequent systemic embolization.

Causes of DCM include infection (eg, viral myocarditis, Chagas disease), chemical toxicity (eg, alcohol), and inherited disease. The premature

1
2
3
4
5
6
7
8
9
10
11
12
13
14
15
16
17
18
19
20
21
22
23
24
25
26
27
28
29

This patient most likely died due to **dilated cardiomyopathy** (DCM). A primary insult to the myocardium leads to impaired myocardial contractile function with dilation of one or both ventricles. The structural changes to the ventricular myocardium places these patients at risk of **sudden cardiac death** from ventricular arrhythmia (ie, ventricular tachycardia, ventricular fibrillation). In addition, the global hypokinesis of the left ventricle leads to stagnation of blood flow and the possible development of LV mural thrombus and subsequent systemic embolization.

Causes of DCM include infection (eg, viral myocarditis, Chagas disease), chemical toxicity (eg, alcohol), and inherited disease. The premature death of this patient's father from a heart problem suggests **familial DCM**, which is typically transmitted in an **autosomal dominant** inheritance pattern. Truncating mutations affecting the ***TTN* gene**, which encodes for the cardiac sarcomere protein **titin**, are the most common cause of familial DCM.

(Choice A) Antiphospholipid antibody syndrome is an autoimmune disorder characterized by venous and/or arterial thrombosis. Cardiac manifestations can include valvular thickening, nonbacterial vegetations, and increased risk of coronary atherosclerosis; however, LV cavity enlargement and mural thrombus are not typical.

(Choice C) Hypertrophic cardiomyopathy is an autosomal dominant genetic disorder caused by mutation in genes encoding for one of several cardiac sarcomere proteins (eg, beta-myosin heavy chain, myosin-binding protein C). It is a common cause of sudden cardiac death in young individuals, usually during exertion. Autopsy typically shows asymmetric septal hypertrophy of the left ventricle.

(Choice D) Ischemic heart disease can lead to myocardial dysfunction and LV enlargement that mimics DCM; however, this patient's coronary arteries had only minor atherosclerotic narrowing (ie, 20% and 25%) that would not have caused clinically significant myocardial ischemia.

(Choice E) Restrictive cardiomyopathy is typically the early cardiac manifestation of an infiltrative process (eg, amyloidosis, sarcoidosis) and is characterized by nondilated ventricles with enlargement of both atria.

Educational objective:
Dilated cardiomyopathy results from primary myocardial dysfunction leading to eccentric remodeling of the left ventricle. Patients can develop left ventricular mural thrombus and are at risk for sudden cardiac death due to ventricular arrhythmia. Familial dilated cardiomyopathy is typically inherited in an autosomal dominant pattern, and most commonly results from truncating mutations of the *TTN* gene that codes for the sarcomere protein titin.

References

- Classification of the cardiomyopathies: a position statement from the European Society of Cardiology Working Group on Myocardial and

pattern. Truncating mutations affecting the ***TTN* gene**, which encodes for the cardiac sarcomere protein **titin**, are the most common cause of familial DCM.

(Choice A) Antiphospholipid antibody syndrome is an autoimmune disorder characterized by venous and/or arterial thrombosis. Cardiac manifestations can include valvular thickening, nonbacterial vegetations, and increased risk of coronary atherosclerosis; however, LV cavity enlargement and mural thrombus are not typical.

(Choice C) Hypertrophic cardiomyopathy is an autosomal dominant genetic disorder caused by mutation in genes encoding for one of several cardiac sarcomere proteins (eg, beta-myosin heavy chain, myosin-binding protein C). It is a common cause of sudden cardiac death in young individuals, usually during exertion. Autopsy typically shows asymmetric septal hypertrophy of the left ventricle.

(Choice D) Ischemic heart disease can lead to myocardial dysfunction and LV enlargement that mimics DCM; however, this patient's coronary arteries had only minor atherosclerotic narrowing (ie, 20% and 25%) that would not have caused clinically significant myocardial ischemia.

(Choice E) Restrictive cardiomyopathy is typically the early cardiac manifestation of an infiltrative process (eg, amyloidosis, sarcoidosis) and is characterized by nondilated ventricles with enlargement of both atria.

Educational objective:
Dilated cardiomyopathy results from primary myocardial dysfunction leading to eccentric remodeling of the left ventricle. Patients can develop left ventricular mural thrombus and are at risk for sudden cardiac death due to ventricular arrhythmia. Familial dilated cardiomyopathy is typically inherited in an autosomal dominant pattern, and most commonly results from truncating mutations of the *TTN* gene that codes for the sarcomere protein titin.

References

- Classification of the cardiomyopathies: a position statement from the European Society of Cardiology Working Group on Myocardial and Pericardial Diseases.

Pathology	Cardiovascular System	Dilated cardiomyopathy
Subject	System	Topic

Copyright © UWorld. All rights reserved.

Correct answer
44%
Answered correctly
04 secs
Time Spent
02/23/2020
Last Updated

Exhibit Display

Cardiac sarcomere protein structure

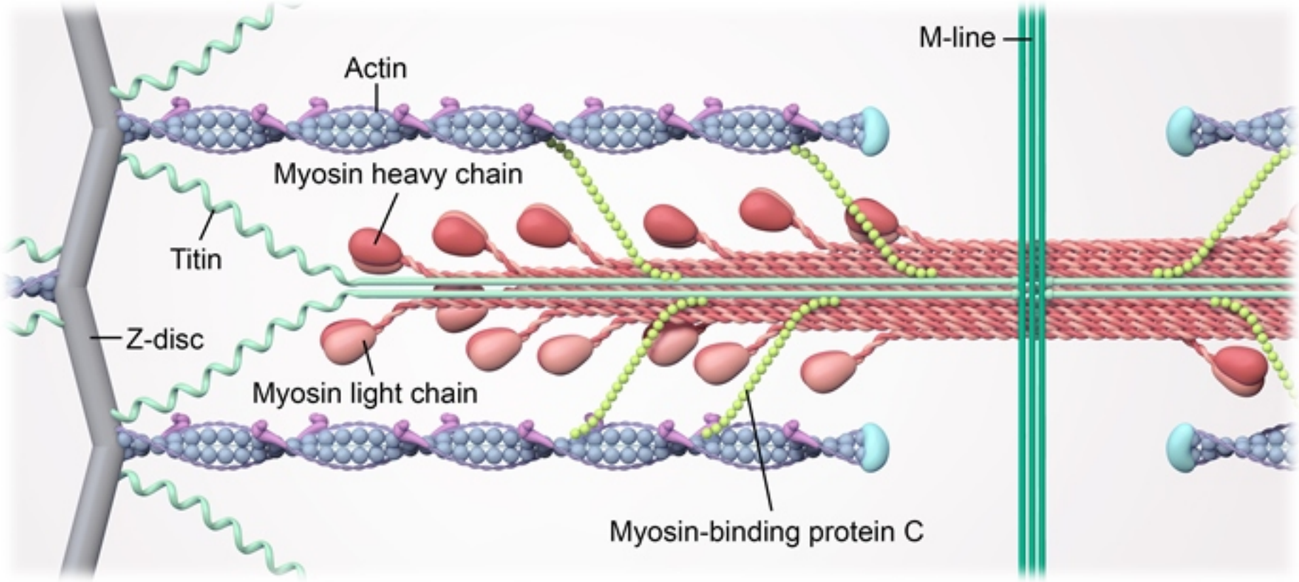

©UWorld

Zoom In | Zoom Out | Reset | Add To New Card | Existing Card

Dilated cardiomyopathy results from primary myocardial dysfunction leading to eccentric remodeling of the left ventricle. Patients can develop left

pattern. Truncating mutations affecting the ***TTN* gene**, which encodes for the cardiac sarcomere protein **titin**, are the most common cause of familial DCM.

(Choice A) Antiphospholipid antibody syndrome is an autoimmune disorder characterized by venous and/or arterial thrombosis. Cardiac manifestations can include valvular thickening, nonbacterial vegetations, and increased risk of coronary atherosclerosis; however, LV cavity enlargement and mural thrombus are not typical.

(Choice C) Hypertrophic cardiomyopathy is an autosomal dominant genetic disorder caused by mutation in genes encoding for one of several cardiac sarcomere proteins (eg, beta-myosin heavy chain, myosin-binding protein C). It is a common cause of sudden cardiac death in young individuals, usually during exertion. Autopsy typically shows asymmetric septal hypertrophy of the left ventricle.

(Choice D) Ischemic heart disease can lead to myocardial dysfunction and LV enlargement that mimics DCM; however, this patient's coronary arteries had only minor atherosclerotic narrowing (ie, 20% and 25%) that would not have caused clinically significant myocardial ischemia.

(Choice E) Restrictive cardiomyopathy is typically the early cardiac manifestation of an infiltrative process (eg, amyloidosis, sarcoidosis) and is characterized by nondilated ventricles with enlargement of both atria.

Educational objective:
Dilated cardiomyopathy results from primary myocardial dysfunction leading to eccentric remodeling of the left ventricle. Patients can develop left ventricular mural thrombus and are at risk for sudden cardiac death due to ventricular arrhythmia. Familial dilated cardiomyopathy is typically inherited in an autosomal dominant pattern, and most commonly results from truncating mutations of the *TTN* gene that codes for the sarcomere protein titin.

References

- Classification of the cardiomyopathies: a position statement from the European Society of Cardiology Working Group on Myocardial and Pericardial Diseases.

Pathology	Cardiovascular System	Dilated cardiomyopathy
Subject	System	Topic

Copyright © UWorld. All rights reserved.

1
2
3
4
5
6
7
8
9
10
11
12
13
14
15
16
17
18
19
20
21
22
23
24
25
26
27
28
29

A 62-year-old man is brought to the emergency department by a friend due to severe shortness of breath. He is agitated and gasping for air and is unable to provide history. His friend says the patient has a history of alcohol abuse and attends Alcoholics Anonymous meetings. He is unaware of any other medical history. Temperature is 36.7 C (98 F), blood pressure is 110/70 mm Hg, pulse is 104/min, and respirations are 32/min. Due to worsening respiratory distress, immediate endotracheal intubation is performed and mechanical ventilation is begun. The patient is admitted to the intensive care unit and, despite appropriate therapy, dies several hours later. Autopsy examination is performed, and histopathology of the lungs reveals engorged pulmonary capillaries and intraalveolar, acellular, pink material that is more prominent at the bases. This patient most likely had which of the following conditions?

A. Aspiration pneumonia
B. Centriacinar emphysema
C. Hypersensitivity pneumonitis
D. Pulmonary arterial hypertension
E. Pulmonary edema
F. Pulmonary infarction

Submit

1
2
3
4
5
6
7
8
9
10
11
12
13
14
15
16
17
18
19
20
21
22
23
24
25
26
27
28
29

A 62-year-old man is brought to the emergency department by a friend due to severe shortness of breath. He is agitated and gasping for air and is unable to provide history. His friend says the patient has a history of alcohol abuse and attends Alcoholics Anonymous meetings. He is unaware of any other medical history. Temperature is 36.7 C (98 F), blood pressure is 110/70 mm Hg, pulse is 104/min, and respirations are 32/min. Due to worsening respiratory distress, immediate endotracheal intubation is performed and mechanical ventilation is begun. The patient is admitted to the intensive care unit and, despite appropriate therapy, dies several hours later. Autopsy examination is performed, and histopathology of the lungs reveals engorged pulmonary capillaries and intraalveolar, acellular, pink material that is more prominent at the bases. This patient most likely had which of the following conditions?

- A. Aspiration pneumonia (20%)
- B. Centriacinar emphysema (3%)
- C. Hypersensitivity pneumonitis (5%)
- D. Pulmonary arterial hypertension (16%)
- ✓ E. Pulmonary edema (48%)
- F. Pulmonary infarction (6%)

Omitted
Correct answer
E

48%
Answered correctly

03 secs
Time Spent

01/29/2020
Last Updated

Explanation

Engorged alveolar capillaries reflect increased pulmonary venous pressure, and pink, acellular material within the alveoli results from transudation of fluid plasma across the alveolar-capillary membrane. These histopathologic findings are most consistent with **acute pulmonary edema** caused

Explanation

Engorged alveolar capillaries reflect increased pulmonary venous pressure, and pink, acellular material within the alveoli results from transudation of fluid plasma across the alveolar-capillary membrane. These histopathologic findings are most consistent with **acute pulmonary edema** caused by **increased alveolar capillary hydrostatic pressure** from **left-sided heart failure**. This patient likely had **dilated cardiomyopathy** due to **chronic alcohol abuse** and had an acute exacerbation of heart failure, resulting in cardiogenic shock with pulmonary edema and acute respiratory failure.

(Choice A) Aspiration pneumonia may be chemical (eg, aspiration of gastric contents) or bacterial (eg, aspiration of oral flora). Histopathology shows neutrophil-rich, inflammatory exudates within the bronchioles and alveolar spaces.

(Choice B) Centriacinar emphysema most commonly results from heavy smoking. Enlarged airspaces with macrophage-predominant infiltrates are expected.

(Choice C) Hypersensitivity pneumonitis results from exposure to an environmental irritant (eg, mold). Histopathology shows lymphocyte-predominant, interstitial inflammation, sometimes accompanied by necrotizing granulomas and loose fibroelastic tissue within the small airways.

(Choice D) Histopathology in pulmonary arterial hypertension typically shows hypertrophy of the pulmonary vascular smooth muscle.

(Choice F) Pulmonary infarction yields hemorrhagic, ischemic necrosis of the lung parenchyma. Histopathology shows a well-demarcated area of alveolar and vascular wall necrosis with cells that lack nuclei, and the alveolar spaces may contain red blood cells.

Educational objective:
Acute cardiogenic pulmonary edema results from increased pulmonary venous pressure. The alveolar capillaries become engorged with blood and there is a transudation of fluid plasma across the alveolar-capillary membrane, appearing as pink, acellular material within the alveoli.

Pathology	Cardiovascular System	Acute heart failure
Subject	System	Topic

Copyright © UWorld. All rights reserved.

1
2
3
4
5
6
7
8
9
10
11
12
13
14
15
16
17
18
19
20
21
22
23
24
25
26
27
28
29

Exhibit Display



Zoom In | Zoom Out | Reset | Add To New Card | Existing Card

1
2
3
4
5
6
7
8
9
10
11
12
13
14
15
16
17
18
19
20
21
22
23
24
25
26
27
28
29

Exhibit Display

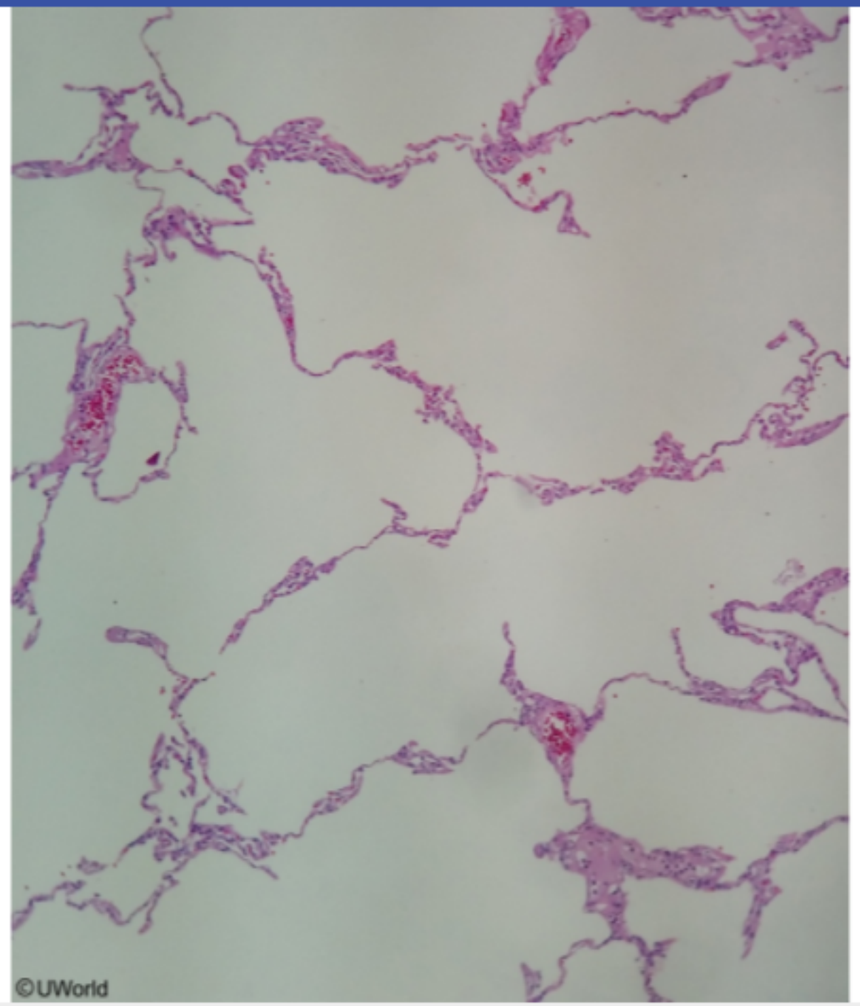

Zoom In
Zoom Out
Reset
Add To New Card | Existing Card

1
2
3
4
5
6
7
8
9
10
11
12
13
14
15
16
17
18
19
20
21
22
23
24
25
26
27
28
29

Exhibit Display

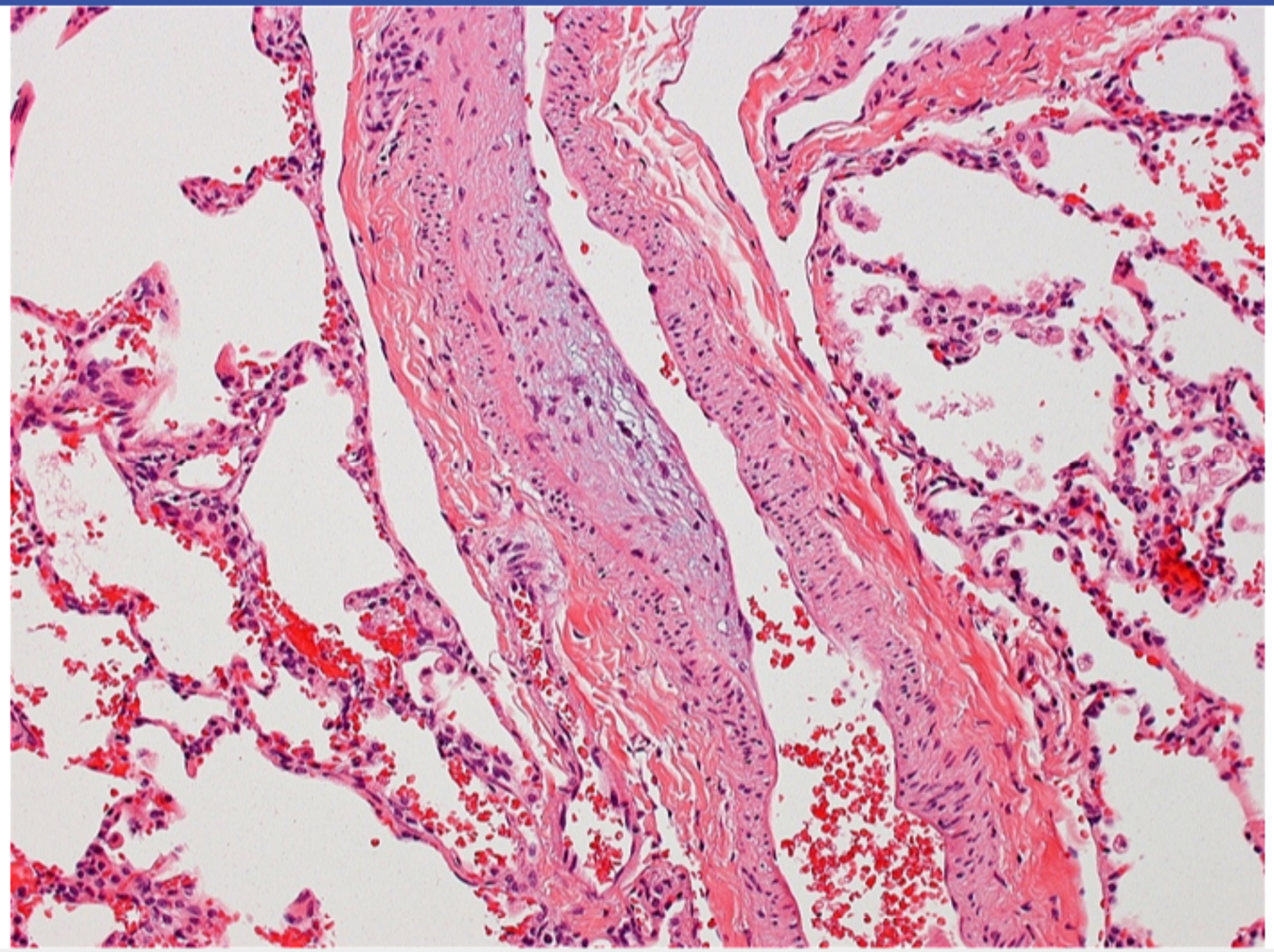

Zoom In | Zoom Out | Reset | Add To New Card | Existing Card

1
2
3
4
5
6
7
8
9
10
11
12
13
14
15
16
17
18
19
20
21
22
23
24
25
26
27
28
29

A 23-year-old Caucasian male who notes recurrent severe nosebleeds is found to have pink spider-like lesions on his oral and nasal mucosa, face, and arms. The patient most likely suffers from:

- A. Von Recklinghausen's disease
- B. Neurofibromatosis type 2
- C. Sturge-Weber syndrome
- D. Von Hippel-Lindau disease
- E. Tuberous sclerosis
- F. Osler-Weber-Rendu syndrome

Submit

A 23-year-old Caucasian male who notes recurrent severe nosebleeds is found to have pink spider-like lesions on his oral and nasal mucosa, face, and arms. The patient most likely suffers from:

- A. Von Recklinghausen's disease (5%)
- B. Neurofibromatosis type 2 (2%)
- C. Sturge-Weber syndrome (15%)
- D. Von Hippel-Lindau disease (9%)
- E. Tuberous sclerosis (6%)
- ✓ F. Osler-Weber-Rendu syndrome (60%)

Omitted
Correct answer
F

60%
Answered correctly

04 secs
Time Spent

02/03/2020
Last Updated

Explanation

This patient presents with skin and mucosal telangiectasias as well as recurrent severe nosebleeds. The most likely diagnosis is Osler-Weber-Rendu syndrome (hereditary hemorrhagic telangiectasia), a condition characterized by the autosomal dominant inheritance of congenital telangiectasias to the skin and mucous membranes. The mucosal involvement may affect the lips, oronasopharynx, respiratory tract, gastrointestinal tract, or urinary tract. In rare instances, the telangiectasias of Osler-Weber-Rendu syndrome may occur in the brain, liver, and spleen as well. Rupture of these telangiectasias may cause epistaxis, gastrointestinal bleeding, and hematuria.

(Choice A) Von Recklinghausen's disease, or neurofibromatosis type 1 (NF1), is an inherited *peripheral nervous system* tumor syndrome. Patients develop neurofibromas, optic nerve gliomas, Lisch nodules (pigmented nodules of the iris), and café-au-lait spots (hyperpigmented

1
2
3
4
5
6
7
8
9
10
11
12
13
14
15
16
17
18
19
20
21
22
23
24
25
26
27
28
29

Explanation

This patient presents with skin and mucosal telangiectasias as well as recurrent severe nosebleeds. The most likely diagnosis is Osler-Weber-Rendu syndrome (hereditary hemorrhagic telangiectasia), a condition characterized by the autosomal dominant inheritance of congenital telangiectasias to the skin and mucous membranes. The mucosal involvement may affect the lips, oronasopharynx, respiratory tract, gastrointestinal tract, or urinary tract. In rare instances, the telangiectasias of Osler-Weber-Rendu syndrome may occur in the brain, liver, and spleen as well. Rupture of these telangiectasias may cause epistaxis, gastrointestinal bleeding, and hematuria.

(Choice A) Von Recklinghausen's disease, or neurofibromatosis type 1 (NF1), is an inherited *peripheral nervous system* tumor syndrome. Patients develop neurofibromas, optic nerve gliomas, Lisch nodules (pigmented nodules of the iris), and café au lait spots (hyperpigmented cutaneous macules).

(Choice B) Neurofibromatosis type 2 is an autosomal dominant nervous system tumor syndrome, in which patients commonly develop bilateral cranial nerve VIII schwannomas and multiple meningiomas.

(Choice C) Sturge-Weber syndrome (encephalotrigeminal angiomatosis) is a rare congenital neurocutaneous disorder characterized by the presence of cutaneous facial angiomas as well as leptomeningeal angiomas. This condition is associated with mental retardation, seizures, hemiplegia, and skull radiopacities. Skull radiographs may show characteristic "tram-track" calcifications.

(Choice D) Von Hippel–Lindau disease is a rare, autosomal dominant condition characterized by the presence of capillary hemangioblastomas in the retina and/or cerebellum, as well as congenital cysts and/or neoplasms in the kidney, liver, and pancreas. Patients are also at increased risk for renal cell carcinoma, which can be bilateral.

(Choice E) Although tuberous sclerosis (TS) may cause kidney, liver, and pancreatic cysts, central nervous system (CNS) involvement manifests not as angiomatous lesions, but as cortical and subependymal *hamartomas*. This autosomal dominant syndrome is also characterized by cutaneous angiofibromas (adenoma sebaceum), visceral cysts, and a variety of other hamartomas, as well as renal angiomyolipomas and cardiac rhabdomyomas. Clinically, seizures are a major complication.

Educational Objective:
Osler-Weber-Rendu syndrome (hereditary hemorrhagic telangiectasia) is an autosomal dominant condition marked by the presence of telangiectasias in the skin as well as the mucous membranes of the lips, oronasopharynx, respiratory tract, gastrointestinal tract, and urinary tract.

spleen as well. Rupture of these telangiectasias may cause epistaxis, gastrointestinal bleeding, and hematuria.

(Choice A) Von Recklinghausen's disease, or neurofibromatosis type 1 (NF1), is an inherited *peripheral nervous system* tumor syndrome. Patients develop neurofibromas, optic nerve gliomas, Lisch nodules (pigmented nodules of the iris), and café au lait spots (hyperpigmented cutaneous macules).

(Choice B) Neurofibromatosis type 2 is an autosomal dominant nervous system tumor syndrome, in which patients commonly develop bilateral cranial nerve VIII schwannomas and multiple meningiomas.

(Choice C) Sturge-Weber syndrome (encephalotrigeminal angiomatosis) is a rare congenital neurocutaneous disorder characterized by the presence of cutaneous facial angiomas as well as leptomeningeal angiomas. This condition is associated with mental retardation, seizures, hemiplegia, and skull radiopacities. Skull radiographs may show characteristic "tram-track" calcifications.

(Choice D) Von Hippel–Lindau disease is a rare, autosomal dominant condition characterized by the presence of capillary hemangioblastomas in the retina and/or cerebellum, as well as congenital cysts and/or neoplasms in the kidney, liver, and pancreas. Patients are also at increased risk for renal cell carcinoma, which can be bilateral.

(Choice E) Although tuberous sclerosis (TS) may cause kidney, liver, and pancreatic cysts, central nervous system (CNS) involvement manifests not as angiomatous lesions, but as cortical and subependymal *hamartomas*. This autosomal dominant syndrome is also characterized by cutaneous angiofibromas (adenoma sebaceum), visceral cysts, and a variety of other hamartomas, as well as renal angiomyolipomas and cardiac rhabdomyomas. Clinically, seizures are a major complication.

Educational Objective:
Osler-Weber-Rendu syndrome (hereditary hemorrhagic telangiectasia) is an autosomal dominant condition marked by the presence of telangiectasias in the skin as well as the mucous membranes of the lips, oronasopharynx, respiratory tract, gastrointestinal tract, and urinary tract. Rupture of these telangiectasias may cause epistaxis, gastrointestinal bleeding, or hematuria.

Pathology	Cardiovascular System	Hereditary hemorrhagic telangiectasia
Subject	System	Topic

Copyright © UWorld. All rights reserved.

1
2
3
4
5
6
7
8
9
10
11
12
13
14
15
16
17
18
19
20
21
22
23
24
25
26
27
28
29

A 22-year-old woman comes to the office due to worsening dyspnea. The patient has also experienced low-grade fevers, a 6.8-kg (15-lb) weight loss, and syncopal episodes over the last 3 months. Her shortness of breath worsens when sitting and improves when lying down. Medical history is insignificant. The patient does not use tobacco, alcohol, or illicit drugs. Temperature is 37.4 C (99.3 F), blood pressure is 115/72 mm Hg, pulse is 75/min and regular, and respirations are 12/min. The lungs are clear. Cardiac auscultation reveals a low-pitched, mid-diastolic rumble at the cardiac apex. The remainder of the physical examination is normal. ECG reveals left atrial enlargement, and echocardiography shows a large, pedunculated mass in the left atrium. Histologic analysis of this mass will most likely reveal which of the following?

A. Coarse, filamented, branching septate hyphae

B. Gram-positive cocci in clusters

C. Malignant myeloid cells

D. Scattered cells within a mucopolysaccharide stroma

E. Solid mass of platelets and fibrin

Submit

1
2
3
4
5
6
7
8
9
10
11
12
13
14
15
16
17
18
19
20
21
22
23
24
25
26
27
28
29

A 22-year-old woman comes to the office due to worsening dyspnea. The patient has also experienced low-grade fevers, a 6.8-kg (15-lb) weight loss, and syncopal episodes over the last 3 months. Her shortness of breath worsens when sitting and improves when lying down. Medical history is insignificant. The patient does not use tobacco, alcohol, or illicit drugs. Temperature is 37.4 C (99.3 F), blood pressure is 115/72 mm Hg, pulse is 75/min and regular, and respirations are 12/min. The lungs are clear. Cardiac auscultation reveals a low-pitched, mid-diastolic rumble at the cardiac apex. The remainder of the physical examination is normal. ECG reveals left atrial enlargement, and echocardiography shows a large, pedunculated mass in the left atrium. Histologic analysis of this mass will most likely reveal which of the following?

A. Coarse, filamented, branching septate hyphae (1%)

B. Gram-positive cocci in clusters (5%)

C. Malignant myeloid cells (10%)

✓ D. Scattered cells within a mucopolysaccharide stroma (71%)

E. Solid mass of platelets and fibrin (11%)

Omitted
Correct answer
D

71%
Answered correctly

02 secs
Time Spent

05/24/2020
Last Updated

Explanation

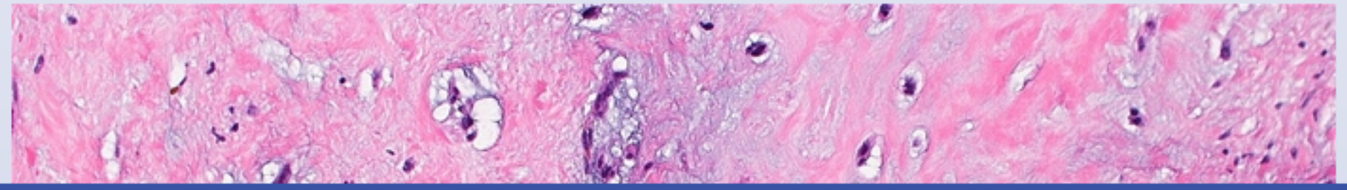

1
2
3
4
5
6
7
8
9
10
11
12
13
14
15
16
17
18
19
20
21
22
23
24
25
26
27
28
29

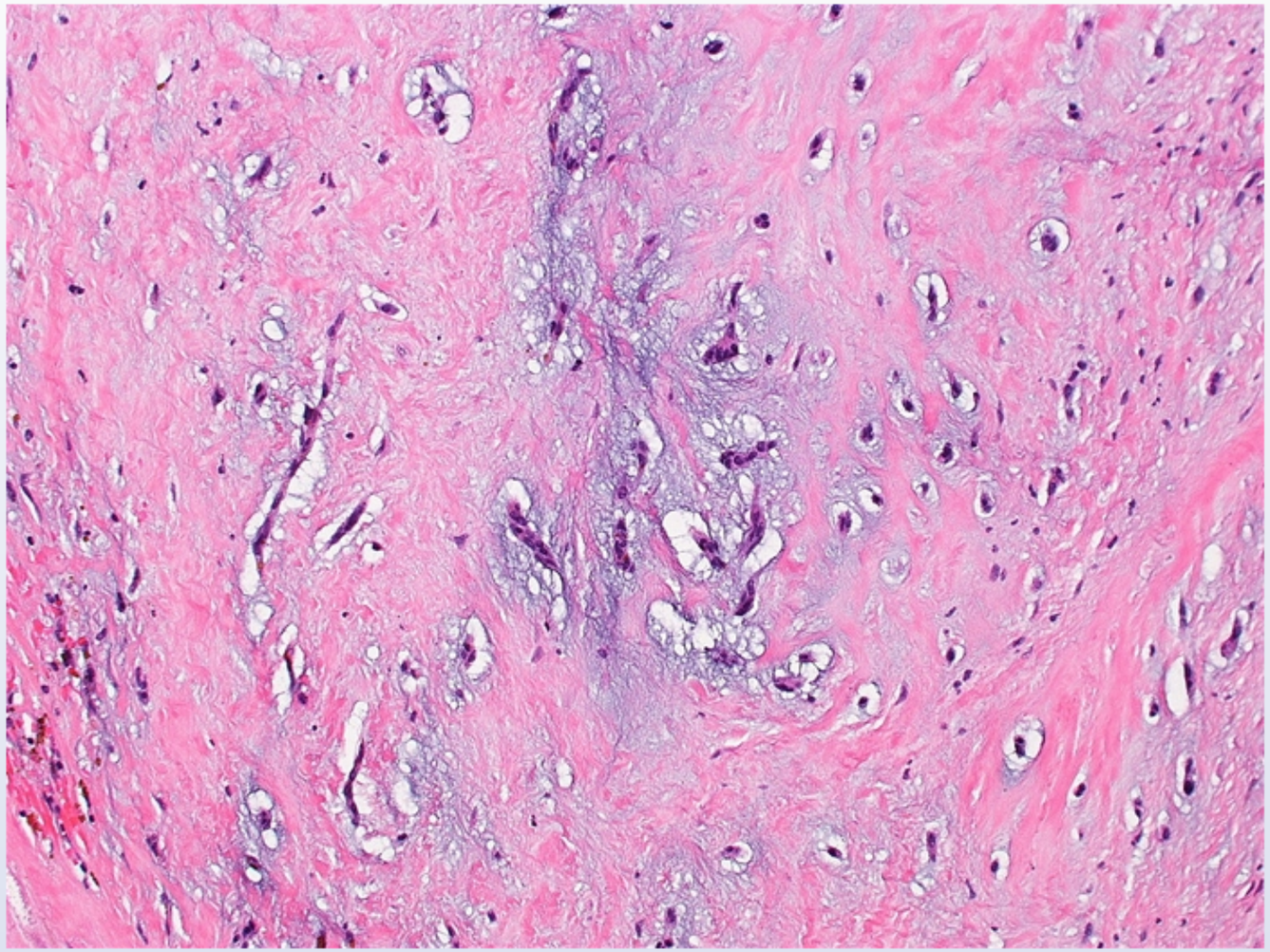

This patient with a large, pedunculated mass in the left atrium most likely has an **atrial myxoma**. Myxomas are the most common primary cardiac neoplasm, and approximately 80% arise within the **left atrium**.

Left atrial myxomas frequently obstruct blood flow from the left atrium to the left ventricle, leading to a **murmur** mimicking that of mitral stenosis

This patient with a large, pedunculated mass in the left atrium most likely has an **atrial myxoma**. Myxomas are the most common primary cardiac neoplasm, and approximately 80% arise within the **left atrium**.

Left atrial myxomas frequently obstruct blood flow from the left atrium to the left ventricle, leading to a **murmur** mimicking that of mitral stenosis (ie, mid-diastolic rumble at the apex). The obstruction can also lead to a decrease in cardiac output that manifests as dyspnea, lightheadedness, or syncope. Because the mass is typically mobile, **obstructive symptoms** may be transient and **influenced by position** (ie, upright posture exacerbates mitral obstruction, whereas lying down alleviates it). In some patients, fragments of the mass may embolize into the systemic circulation (eg, resulting in stroke or acute limb ischemia). In addition, some myxomas can produce cytokines (eg, interleukin-6) that lead to **constitutional symptoms** including fever and weight loss.

Histologically, these tumors demonstrate scattered cells within a **mucopolysaccharide stroma** (see image above) and abnormal blood vessels. Myxomas produce a large amount of vascular endothelial growth factor, which contributes to the angiogenesis (white arrows), hemorrhaging (seen as brown hemosiderin deposits), and friability characterizing these tumors.

(Choices A and B) Coarse, filamented, branching septate hyphae are found in fungal endocarditis, whereas gram-positive cocci in clusters are consistent with bacterial endocarditis. Both are unlikely in this young woman with no history of valvular disease or intravenous drug use. In addition, endocarditis typically causes a regurgitant murmur, with valvular vegetations seen on echocardiography.

(Choice C) Acute myeloid leukemia (AML) rarely may involve the heart. Signs and symptoms related to anemia (eg, weakness, fatigue), neutropenia (eg, infections), and thrombocytopenia (eg, ecchymoses, epistaxis), are typically present with AML.

(Choice E) Nonbacterial thrombotic endocarditis involves the valvular deposition of sterile platelets and fibrin and most commonly occurs in the setting of advanced malignancy or systemic lupus erythematosus. The disease usually presents with systemic embolization, and heart murmurs are often absent; if a murmur is present, it is typically regurgitant rather than stenotic.

Educational objective:
Myxomas are the most common primary cardiac neoplasm and usually arise within the left atrium. The tumors typically cause position-dependent obstruction of the mitral valve, leading to a mid-diastolic murmur and symptoms of decreased cardiac output (eg, dyspnea, syncope). Constitutional symptoms (eg, fever, weight loss) may also be present. Histologically, the tumors demonstrate scattered cells within a mucopolysaccharide stroma and abnormal blood vessels with hemorrhaging.

circulation (eg, resulting in stroke or acute limb ischemia). In addition, some myxomas can produce cytokines (eg, interleukin-6) that lead to **constitutional symptoms** including fever and weight loss.

Histologically, these tumors demonstrate scattered cells within a **mucopolysaccharide stroma** (see image above) and abnormal blood vessels. Myxomas produce a large amount of vascular endothelial growth factor, which contributes to the angiogenesis (white arrows), hemorrhaging (seen as brown hemosiderin deposits), and friability characterizing these tumors.

(Choices A and B) Coarse, filamented, branching septate hyphae are found in fungal endocarditis, whereas gram-positive cocci in clusters are consistent with bacterial endocarditis. Both are unlikely in this young woman with no history of valvular disease or intravenous drug use. In addition, endocarditis typically causes a regurgitant murmur, with valvular vegetations seen on echocardiography.

(Choice C) Acute myeloid leukemia (AML) rarely may involve the heart. Signs and symptoms related to anemia (eg, weakness, fatigue), neutropenia (eg, infections), and thrombocytopenia (eg, ecchymoses, epistaxis), are typically present with AML.

(Choice E) Nonbacterial thrombotic endocarditis involves the valvular deposition of sterile platelets and fibrin and most commonly occurs in the setting of advanced malignancy or systemic lupus erythematosus. The disease usually presents with systemic embolization, and heart murmurs are often absent; if a murmur is present, it is typically regurgitant rather than stenotic.

Educational objective:
Myxomas are the most common primary cardiac neoplasm and usually arise within the left atrium. The tumors typically cause position-dependent obstruction of the mitral valve, leading to a mid-diastolic murmur and symptoms of decreased cardiac output (eg, dyspnea, syncope). Constitutional symptoms (eg, fever, weight loss) may also be present. Histologically, the tumors demonstrate scattered cells within a mucopolysaccharide stroma and abnormal blood vessels with hemorrhaging.

References

- Atrial myxoma: case report and a review of the literature.

Pathology	Cardiovascular System	Atrial myxoma
Subject	System	Topic

Copyright © UWorld. All rights reserved.

circulation (eg, resulting in stroke or acute limb ischemia). In addition, some myxomas can produce cytokines (eg, interleukin-6) that lead to **constitutional symptoms** including fever and weight loss.

Histologically, these tumors demonstrate scattered cells within a **mucopolysaccharide stroma** (see image above) and abnormal blood vessels. Myxomas produce a large amount of vascular endothelial growth factor, which contributes to the angiogenesis (white arrows), hemorrhaging (seen as brown hemosiderin deposits), and friability characterizing these tumors.

(Choices A and B) Coarse, filamented, branching septate hyphae are found in fungal endocarditis, whereas gram-positive cocci in clusters are consistent with bacterial endocarditis. Both are unlikely in this young woman with no history of valvular disease or intravenous drug use. In addition, endocarditis typically causes a regurgitant murmur, with valvular vegetations seen on echocardiography.

(Choice C) Acute myeloid leukemia (AML) rarely may involve the heart. Signs and symptoms related to anemia (eg, weakness, fatigue), neutropenia (eg, infections), and thrombocytopenia (eg, ecchymoses, epistaxis), are typically present with AML.

(Choice E) Nonbacterial thrombotic endocarditis involves the valvular deposition of sterile platelets and fibrin and most commonly occurs in the setting of advanced malignancy or systemic lupus erythematosus. The disease usually presents with systemic embolization, and heart murmurs are often absent; if a murmur is present, it is typically regurgitant rather than stenotic.

Educational objective:
Myxomas are the most common primary cardiac neoplasm and usually arise within the left atrium. The tumors typically cause position-dependent obstruction of the mitral valve, leading to a mid-diastolic murmur and symptoms of decreased cardiac output (eg, dyspnea, syncope). Constitutional symptoms (eg, fever, weight loss) may also be present. Histologically, the tumors demonstrate scattered cells within a mucopolysaccharide stroma and abnormal blood vessels with hemorrhaging.

References

- Atrial myxoma: case report and a review of the literature.

Pathology	Cardiovascular System	Atrial myxoma
Subject	System	Topic

Copyright © UWorld. All rights reserved.

1
2
3
4
5
6
7
8
9
10
11
12
13
14
15
16
17
18
19
20
21
22
23
24
25
26
27
28
29

A 44-year-old man is evaluated in the clinic for occasional chest discomfort that is not consistently related to exertion. The patient's past medical history is significant for hypertension and hyperlipidemia. His grandfather experienced a myocardial infarction at age 50. Coronary CT angiography reveals several nonobstructive atherosclerotic plaques in the coronary arteries. One plaque in the proximal left anterior descending artery appears extensive, has a large hypodense core, and occupies 40% of the lumen. No intervention is performed. One year later, the patient comes to the emergency department with acute severe chest pain and is found to have thrombotic occlusion of the proximal left anterior descending artery. High intraplaque activity of which of the following enzymes most likely resulted in this patient's myocardial infarction?

A. Hydroxymethylglutaryl CoA reductase
B. Lysyl oxidase
C. Metalloproteinases
D. Procollagen peptidases
E. Prolyl hydroxylase

Submit

A 44-year-old man is evaluated in the clinic for occasional chest discomfort that is not consistently related to exertion. The patient's past medical history is significant for hypertension and hyperlipidemia. His grandfather experienced a myocardial infarction at age 50. Coronary CT angiography reveals several nonobstructive atherosclerotic plaques in the coronary arteries. One plaque in the proximal left anterior descending artery appears extensive, has a large hypodense core, and occupies 40% of the lumen. No intervention is performed. One year later, the patient comes to the emergency department with acute severe chest pain and is found to have thrombotic occlusion of the proximal left anterior descending artery. High intraplaque activity of which of the following enzymes most likely resulted in this patient's myocardial infarction?

- A. Hydroxymethylglutaryl CoA reductase (16%)
- B. Lysyl oxidase (10%)
- ✓ C. Metalloproteinases (59%)
- D. Procollagen peptidases (9%)
- E. Prolyl hydroxylase (4%)

Omitted
Correct answer
C

59%
Answered correctly

04 secs
Time Spent

03/29/2020
Last Updated

Explanation



1
2
3
4
5
6
7
8
9
10
11
12
13
14
15
16
17
18
19
20
21
22
23
24
25
26
27
28
29

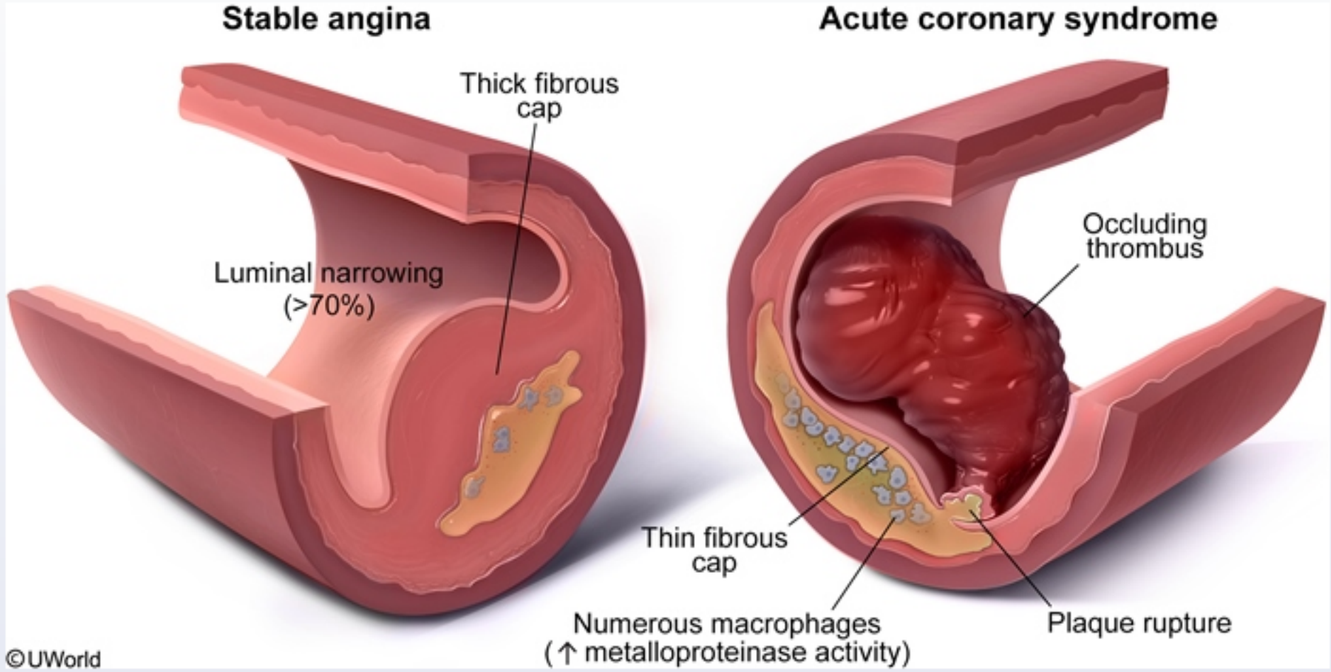

This patient with coronary atherosclerosis has likely developed plaque rupture with thrombotic occlusion of the left anterior descending artery, resulting in acute coronary syndrome (unstable angina, myocardial infarction).

Patients with coronary atherosclerosis can be asymptomatic but typically develop symptoms of stable angina (exertional chest pain relieved with rest/nitroglycerin) if progressive enlargement of the atherosclerotic plaque causes >70% luminal stenosis. **Acute coronary syndrome** usually occurs due to **plaque rupture**, which leads to superimposed **thrombosis** and vessel occlusion. The likelihood of plaque rupture is typically related to plaque stability rather than plaque size or degree of luminal narrowing. Plaque stability largely depends on the mechanical strength of the fibrous cap: Thin-cap fibroatheromas are generally unstable and more vulnerable to rupture.

During the chronic inflammatory progression of an atheroma, the fibrous cap is continually being remodeled. The balance of collagen synthesis and degradation determines the mechanical strength of the cap. **Thin-cap fibroatheromas** are characterized by a large necrotic core covered by a thin fibrous cap. Activated macrophages infiltrating the atheroma contribute to the breakdown of extracellular matrix proteins (eg, collagen) by

This patient with coronary atherosclerosis has likely developed plaque rupture with thrombotic occlusion of the left anterior descending artery, resulting in acute coronary syndrome (unstable angina, myocardial infarction).

Patients with coronary atherosclerosis can be asymptomatic but typically develop symptoms of stable angina (exertional chest pain relieved with rest/nitroglycerin) if progressive enlargement of the atherosclerotic plaque causes >70% luminal stenosis. **Acute coronary syndrome** usually occurs due to **plaque rupture**, which leads to superimposed **thrombosis** and vessel occlusion. The likelihood of plaque rupture is typically related to plaque stability rather than plaque size or degree of luminal narrowing. Plaque stability largely depends on the mechanical strength of the fibrous cap: Thin-cap fibroatheromas are generally unstable and more vulnerable to rupture.

During the chronic inflammatory progression of an atheroma, the fibrous cap is continually being remodeled. The balance of collagen synthesis and degradation determines the mechanical strength of the cap. **Thin-cap fibroatheromas** are characterized by a large necrotic core covered by a thin fibrous cap. Activated macrophages infiltrating the atheroma contribute to the breakdown of extracellular matrix proteins (eg, collagen) by secreting **metalloproteinases**. Ongoing intimal inflammation can destabilize the mechanical integrity of the plaque through release of these metalloproteinases, resulting in plaque rupture and consequent acute coronary syndrome.

(Choice A) Hydroxymethylglutaryl (HMG) CoA reductase is the rate-limiting enzyme in cholesterol synthesis and is mostly expressed in the liver, intestine, adrenal cortex, and reproductive tissues. Patients with hyperlipidemia are typically treated with statins (eg, atorvastatin), which competitively inhibit HMG CoA reductase.

(Choice B) Lysyl oxidase strengthens extracellular collagen fibers by mediating cross-link formation between lysine and hydroxylysine residues (requires copper). Therefore, a high activity of lysyl oxidase would favor atheroma stabilization by strengthening collagen in the fibrous cap.

(Choice D) Procollagen peptidase cleaves the terminal regions of procollagen molecules exocytosed by fibroblasts or smooth muscle cells, transforming procollagen into insoluble tropocollagen. Tropocollagen then aggregates to form collagen fibrils.

(Choice E) Prolyl hydroxylase is responsible for the hydroxylation of proline on procollagen chains (requires vitamin C), which is a necessary step in the formation of a stable collagen triple helix.

Educational objective:
The likelihood of plaque rupture is related to plaque stability rather than plaque size or the degree of luminal narrowing. Plaque stability largely depends on the mechanical strength of the fibrous cap. Inflammatory macrophages in the intima may reduce plaque stability by secreting metalloproteinases, which degrade extracellular matrix proteins (eg, collagen).

a thin fibrous cap. Activated macrophages infiltrating the atheroma contribute to the breakdown of extracellular matrix proteins (eg, collagen) by secreting **metalloproteinases**. Ongoing intimal inflammation can destabilize the mechanical integrity of the plaque through release of these metalloproteinases, resulting in plaque rupture and consequent acute coronary syndrome.

(Choice A) Hydroxymethylglutaryl (HMG) CoA reductase is the rate-limiting enzyme in cholesterol synthesis and is mostly expressed in the liver, intestine, adrenal cortex, and reproductive tissues. Patients with hyperlipidemia are typically treated with statins (eg, atorvastatin), which competitively inhibit HMG CoA reductase.

(Choice B) Lysyl oxidase strengthens extracellular collagen fibers by mediating cross-link formation between lysine and hydroxylysine residues (requires copper). Therefore, a high activity of lysyl oxidase would favor atheroma stabilization by strengthening collagen in the fibrous cap.

(Choice D) Procollagen peptidase cleaves the terminal regions of procollagen molecules exocytosed by fibroblasts or smooth muscle cells, transforming procollagen into insoluble tropocollagen. Tropocollagen then aggregates to form collagen fibrils.

(Choice E) Prolyl hydroxylase is responsible for the hydroxylation of proline on procollagen chains (requires vitamin C), which is a necessary step in the formation of a stable collagen triple helix.

Educational objective:
The likelihood of plaque rupture is related to plaque stability rather than plaque size or the degree of luminal narrowing. Plaque stability largely depends on the mechanical strength of the fibrous cap. Inflammatory macrophages in the intima may reduce plaque stability by secreting metalloproteinases, which degrade extracellular matrix proteins (eg, collagen).

References

- Evidence for increased collagenolysis by interstitial collagenases-1 and -3 in vulnerable human atheromatous plaques.
- Inflammation in atherosclerosis.

Pathology	Cardiovascular System	Atherosclerosis
Subject	System	Topic

Copyright © UWorld. All rights reserved.

1
2
3
4
5
6
7
8
9
10
11
12
13
14
15
16
17
18
19
20
21
22
23
24
25
26
27
28
29

In experiments, transient myocardial ischemia causes myocardial cells to increase in size. This effect is due in part to which of the following?

A. Intracellular K^+ accumulation

B. Intracellular Ca^{2+} accumulation

C. High cellular HCO_3^- content

D. Cascade protein phosphorylation

E. Net cellular solute loss

Submit

In experiments, transient myocardial ischemia causes myocardial cells to increase in size. This effect is due in part to which of the following?

- A. Intracellular K^+ accumulation (21%)
- ✓ B. Intracellular Ca^{2+} accumulation (54%)
- C. High cellular HCO_3^- content (5%)
- D. Cascade protein phosphorylation (11%)
- E. Net cellular solute loss (6%)

Omitted
Correct answer
B

54%
Answered correctly

02 secs
Time Spent

02/03/2020
Last Updated

Explanation

When blood flow cannot meet myocardial demands, cardiac myocytes transition from aerobic to anaerobic metabolism. However, anaerobic metabolism cannot maintain proper intracellular ATP levels, and ADP, AMP and adenosine accumulate. Without ATP, the membrane Na^+/K^+-ATPases and the sarcoplasmic reticulum Ca^{2+}-ATPases fail, leading to increased intracellular Na^+ and Ca^{2+} and increased intramitochondrial Ca^{2+} concentrations. These increased concentrations attract free water, causing cellular and mitochondrial swelling. Failure of the sarcoplasmic reticulum to resequester Ca^{2+} leads to cessation of contraction within ischemic zones of myocardium.

(Choice A) The cell membrane Na^+/K^+-ATPase pump normally brings K^+ into the cell in exchange for Na+. Thus, in ischemic tissue, intracellular K^+ is decreased.

1
2
3
4
5
6
7
8
9
10
11
12
13
14
15
16
17
18
19
20
21
22
23
24
25
26
27
28
29

Explanation

When blood flow cannot meet myocardial demands, cardiac myocytes transition from aerobic to anaerobic metabolism. However, anaerobic metabolism cannot maintain proper intracellular ATP levels, and ADP, AMP and adenosine accumulate. Without ATP, the membrane Na^+/K^+-ATPases and the sarcoplasmic reticulum Ca^{2+}-ATPases fail, leading to increased intracellular Na^+ and Ca^{2+} and increased intramitochondrial Ca^{2+} concentrations. These increased concentrations attract free water, causing cellular and mitochondrial swelling. Failure of the sarcoplasmic reticulum to resequester Ca^{2+} leads to cessation of contraction within ischemic zones of myocardium.

(Choice A) The cell membrane Na^+/K^+-ATPase pump normally brings K^+ into the cell in exchange for Na+. Thus, in ischemic tissue, intracellular K^+ is decreased.

(Choice C) Cellular HCO_3^- is not elevated in cardiac ischemia. Anaerobic metabolism leads to lactic acid production and a decrease in pH. Tissue CO_2, the conjugate acid of HCO_3^-, is thus elevated in ischemic myocardium.

(Choice D) Protein phosphorylation cascades play a role in a variety of processes including second messenger signaling and regulation of apoptosis. The cell's response to ischemia does involve initiating certain metabolic processes through protein phosphorylation, but this does not cause cell swelling.

(Choice E) Ischemia causes a net solute gain within cardiac myocytes. Elevated concentrations of Na^+ and Ca^{2+} draw free water into the cells, causing edema.

Educational Objective:
Ion pump failure due to ATP deficiency during cardiac ischemia causes intracellular accumulation of Na^+ and Ca^{2+}. The increased intracellular solute concentration draws free water into the cell, causing the cellular and mitochondrial swelling that is observed histologically.

Pathology	Cardiovascular System	Myocardial infarction
Subject	System	Topic

Copyright © UWorld. All rights reserved.

1
2
3
4
5
6
7
8
9
10
11
12
13
14
15
16
17
18
19
20
21
22
23
24
25
26
27
28
29

A 62-year-old, obese woman is brought to the hospital due to acute-onset chest pain and shortness of breath. Medical history includes hyperlipidemia, diet-controlled type 2 diabetes mellitus, and peripheral artery disease. Two years ago, she had an ischemic stroke but had no residual neurologic deficits. The patient is a current smoker with a 30-pack-year history. After initial evaluation, she is taken to the cardiac catheterization laboratory where she has a cardiac arrest due to ventricular arrhythmia and cannot be resuscitated. Autopsy reveals thrombotic occlusion of the left anterior descending artery. In addition, it shows 95% atherosclerotic narrowing of the proximal right renal artery but no significant stenosis of the left renal artery. Compared with the right kidney, this patient's left kidney is more likely to demonstrate which of the following findings?

A. Arteriolar wall thickening

B. Atrophic tubules

C. Cortical thinning

D. Interstitial fibrosis

E. Small crowded glomeruli

Submit

A 62-year-old, obese woman is brought to the hospital due to acute-onset chest pain and shortness of breath. Medical history includes hyperlipidemia, diet-controlled type 2 diabetes mellitus, and peripheral artery disease. Two years ago, she had an ischemic stroke but had no residual neurologic deficits. The patient is a current smoker with a 30-pack-year history. After initial evaluation, she is taken to the cardiac catheterization laboratory where she has a cardiac arrest due to ventricular arrhythmia and cannot be resuscitated. Autopsy reveals thrombotic occlusion of the left anterior descending artery. In addition, it shows 95% atherosclerotic narrowing of the proximal right renal artery but no significant stenosis of the left renal artery. Compared with the right kidney, this patient's left kidney is more likely to demonstrate which of the following findings?

- ✓ A. Arteriolar wall thickening (53%)
- B. Atrophic tubules (7%)
- C. Cortical thinning (9%)
- D. Interstitial fibrosis (4%)
- E. Small crowded glomeruli (24%)

Omitted
Correct answer
A

53%
Answered correctly

03 secs
Time Spent

01/09/2020
Last Updated

Explanation

Renal artery stenosis

1
2
3
4
5
6
7
8
9
10
11
12
13
14
15
16
17
18
19
20
21
22
23
24
25
26
27
28
29

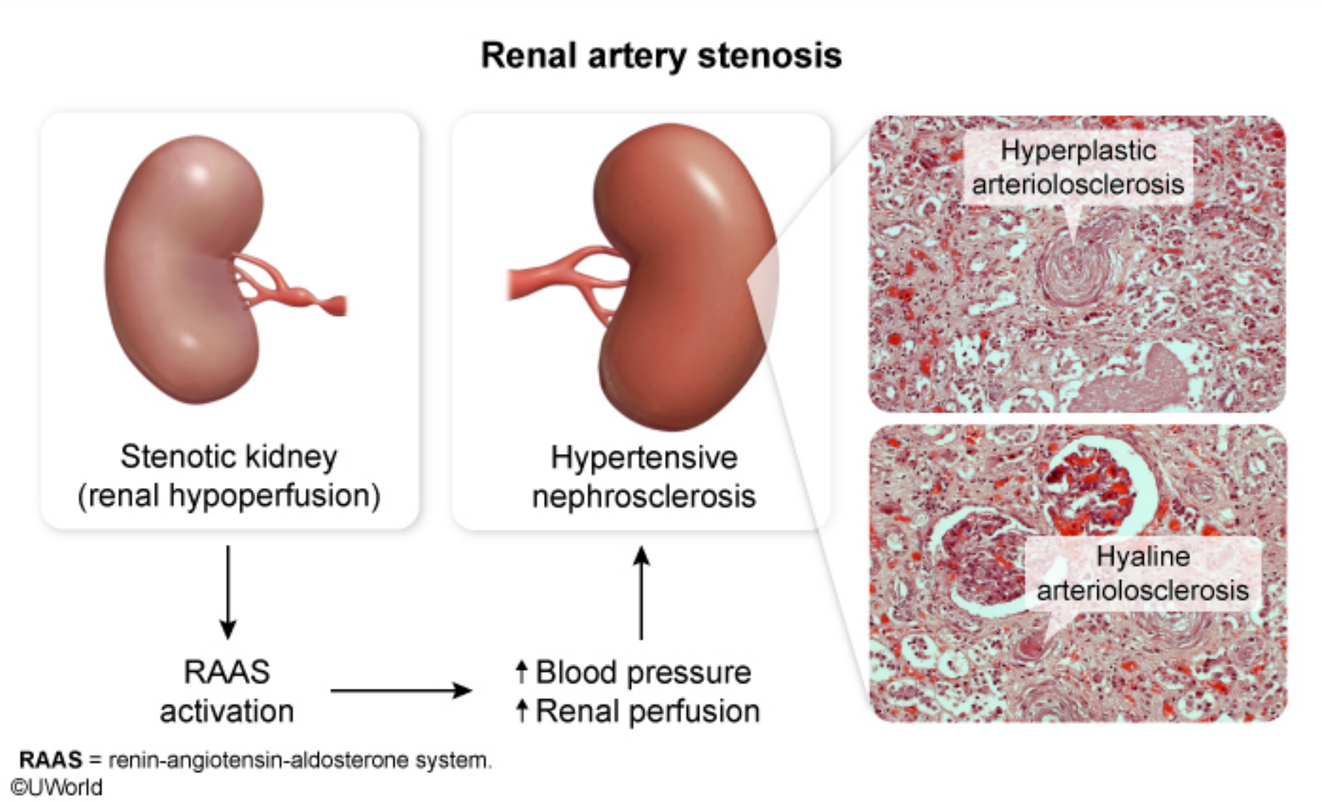

This patient's autopsy findings are consistent with severe, **unilateral renal artery stenosis** (RAS), a condition that occurs most commonly in older individuals due to atherosclerosis. Hypoperfusion of the stenotic (right) kidney stimulates **renin release** by juxtaglomerular apparatus cells. Renin converts angiotensinogen to angiotensin I, which is then converted by angiotensin-converting enzyme to angiotensin II, a potent vasoconstrictor that causes **systemic hypertension**.

Unilateral RAS causes morphologic changes that markedly differ in the stenotic (right) kidney and the nonstenotic (left) kidney. Narrowing of the renal artery in the **stenotic (right) kidney** leads to hypoperfusion and **renal parenchymal ischemia**, which manifests as diffuse cortical thinning, tubular atrophy, interstitial fibrosis, and small crowded glomeruli. Juxtaglomerular apparatus enlargement can also occur due to chronic stimulation and increased renin release.

RAAS = renin-angiotensin-aldosterone system.
©UWorld

This patient's autopsy findings are consistent with severe, **unilateral renal artery stenosis** (RAS), a condition that occurs most commonly in older individuals due to atherosclerosis. Hypoperfusion of the stenotic (right) kidney stimulates **renin release** by juxtaglomerular apparatus cells. Renin converts angiotensinogen to angiotensin I, which is then converted by angiotensin-converting enzyme to angiotensin II, a potent vasoconstrictor that causes **systemic hypertension**.

Unilateral RAS causes morphologic changes that markedly differ in the stenotic (right) kidney and the nonstenotic (left) kidney. Narrowing of the renal artery in the **stenotic (right) kidney** leads to hypoperfusion and **renal parenchymal ischemia**, which manifests as diffuse cortical thinning, tubular atrophy, interstitial fibrosis, and small crowded glomeruli. Juxtaglomerular apparatus enlargement can also occur due to chronic stimulation and increased renin release.

In contrast, the contralateral, **nonstenotic (left) kidney** is exposed to **high blood pressure** and therefore demonstrates typical signs of hypertensive nephrosclerosis, which is characterized by **arteriolar wall thickening** due to **hyaline** arteriolosclerosis (hyalinization of the arterioles due to extravasation of plasma proteins) and **hyperplastic arteriolosclerosis** (concentric smooth muscle cell proliferation in response to pressure ["onion-skinning"]).

(Choices B, C, D, and E) With unilateral RAS, the nonstenotic (left) kidney develops significant arteriolosclerosis due to exposure to high blood pressure. This can lead to narrowing of the arteriolar lumen with subsequent ischemic changes. However, these ischemic findings would be much more prominent in the stenotic (right) kidney.

Educational objective:
In unilateral renal artery stenosis, the narrowed renal artery causes hypoperfusion of the affected kidney with subsequent ischemic damage (eg, tubular atrophy, interstitial ischemia, glomerular crowding). In contrast, the contralateral kidney is exposed to high blood pressure and typically shows changes of hypertensive nephrosclerosis (eg, arteriolar wall thickening due to hyaline or hyperplastic arteriolosclerosis).

Pathology	Cardiovascular System	Renal artery stenosis
Subject	System	Topic

Copyright © UWorld. All rights reserved.

1
2
3
4
5
6
7
8
9
10
11
12
13
14
15
16
17
18
19
20
21
22
23
24
25
26
27
28
29

A 54-year-old man comes to the office due to 2 days of redness and pain in his right arm. He was recently diagnosed with superficial thrombophlebitis involving the left lower and upper extremities. His symptoms then subsided within days of nonsteroidal anti-inflammatory drug therapy only. The patient has no other past medical history. He has some abdominal discomfort that he attributes to gastroesophageal reflux disease. Temperature is 37.6 C (99.7 F). On examination, there is erythema and tenderness extending linearly from the right forearm to just anterior to the right antecubital fossa. No fluid collection is palpable. Complete blood count shows mild leukocytosis. The patient's symptoms may indicate the presence of which of the following?

A. Celiac sprue

B. Chlamydial infection

C. Hyperthyroidism

D. Polycystic kidneys

E. Visceral cancer

Submit

A 54-year-old man comes to the office due to 2 days of redness and pain in his right arm. He was recently diagnosed with superficial thrombophlebitis involving the left lower and upper extremities. His symptoms then subsided within days of nonsteroidal anti-inflammatory drug therapy only. The patient has no other past medical history. He has some abdominal discomfort that he attributes to gastroesophageal reflux disease. Temperature is 37.6 C (99.7 F). On examination, there is erythema and tenderness extending linearly from the right forearm to just anterior to the right antecubital fossa. No fluid collection is palpable. Complete blood count shows mild leukocytosis. The patient's symptoms may indicate the presence of which of the following?

- A. Celiac sprue (22%)
- B. Chlamydial infection (8%)
- C. Hyperthyroidism (3%)
- D. Polycystic kidneys (5%)
- ✓ E. Visceral cancer (60%)

Omitted
Correct answer
E

60%
Answered correctly

03 secs
Time Spent

04/22/2020
Last Updated

Explanation

Migratory thrombophlebitis should raise suspicion for **cancer**. Hypercoagulability is a very common paraneoplastic syndrome seen most frequently in **visceral** adenocarcinomas of the **pancreas**, colon, and lung. **Hypercoagulability** develops because adenocarcinomas produce a thromboplastin-like substance capable of causing chronic intravascular coagulations that can disseminate and tend to migrate.

Migratory superficial thrombophlebitis, known as **Trousseau syndrome**, is named after Armand Trousseau, a well-respected French physician

1
2
3
4
5
6
7
8
9
10
11
12
13
14
15
16
17
18
19
20
21
22
23
24
25
26
27
28
29

Migratory thrombophlebitis should raise suspicion for **cancer**. Hypercoagulability is a very common paraneoplastic syndrome seen most frequently in **visceral** adenocarcinomas of the **pancreas**, colon, and lung. **Hypercoagulability** develops because adenocarcinomas produce a thromboplastin-like substance capable of causing chronic intravascular coagulations that can disseminate and tend to migrate.

Migratory superficial thrombophlebitis, known as **Trousseau syndrome**, is named after Armand Trousseau, a well-respected French physician who first described the association with cancer. Trousseau later diagnosed his own visceral cancer after developing the syndrome.

Trousseau also described the Trousseau sign (hand/forearm muscle spasms on sphygmomanometric measurement) associated with hypocalcemia.

(Choice A) Celiac sprue has been associated with a hemorrhagic diathesis (rather than abnormal thrombosis). The malabsorption resulting from celiac sprue can result in vitamin K deficiency.

(Choices B and D) Polycystic kidney disease is not among the conditions commonly associated with an acquired prothrombotic state. Disseminated chlamydia infections are classically associated with reactive arthritis (not thrombophlebitis), and infections in general can create a systemic inflammatory state that favors thrombosis. However, malignancy would be a more likely explanation for migratory superficial thrombophlebitis accompanied by vague abdominal pain.

(Choice C) Hyperthyroidism has been associated with a hypercoagulable state and is occasionally reported in cases of cerebral venous thrombosis, but there is no evidence of a significant association with venous thrombotic events.

Educational objective:
A paraneoplastic syndrome of hypercoagulability may be seen in some patients with cancer, especially adenocarcinomas of the pancreas, colon, or lung. Superficial venous thromboses may therefore appear in one site and then resolve, only to recur in another site. This is known as Trousseau syndrome (migratory superficial thrombophlebitis), an indication of visceral cancer.

Pathology	Cardiovascular System	Thrombophlebitis
Subject	System	Topic

Copyright © UWorld. All rights reserved.

1
2
3
4
5
6
7
8
9
10
11
12
13
14
15
16
17
18
19
20
21
22
23
24
25
26
27
28
29

Migratory thrombophlebitis should raise suspicion for **cancer**. Hypercoagulability is a very common paraneoplastic syndrome seen most frequently in **visceral** adenocarcinomas of the **pancreas**, colon, and lung. **Hypercoagulability** develops because adenocarcinomas produce a thromboplastin-like substance capable of causing chronic intravascular coagulations that can disseminate and tend to migrate.

Migratory superficial thrombophlebitis, known as **Trousseau syndrome**, is named after Armand Trousseau, a well-respected French physician who first described the association with cancer. Trousseau later diagnosed his own visceral cancer after developing the syndrome.

Trousseau also described the Trousseau sign (hand/forearm muscle spasms on sphygmomanometric measurement) associated with hypocalcemia.

(Choice A) Celiac sprue has been associated with a hemorrhagic diathesis (rather than abnormal thrombosis). The malabsorption resulting from celiac sprue can result in vitamin K deficiency.

(Choices B and D) Polycystic kidney disease is not among the conditions commonly associated with an acquired prothrombotic state. Disseminated chlamydia infections are classically associated with reactive arthritis (not thrombophlebitis), and infections in general can create a systemic inflammatory state that favors thrombosis. However, malignancy would be a more likely explanation for migratory superficial thrombophlebitis accompanied by vague abdominal pain.

(Choice C) Hyperthyroidism has been associated with a hypercoagulable state and is occasionally reported in cases of cerebral venous thrombosis, but there is no evidence of a significant association with venous thrombotic events.

Educational objective:
A paraneoplastic syndrome of hypercoagulability may be seen in some patients with cancer, especially adenocarcinomas of the pancreas, colon, or lung. Superficial venous thromboses may therefore appear in one site and then resolve, only to recur in another site. This is known as Trousseau syndrome (migratory superficial thrombophlebitis), an indication of visceral cancer.

Pathology	Cardiovascular System	Thrombophlebitis
Subject	System	Topic

Copyright © UWorld. All rights reserved.

1
2
3
4
5
6
7
8
9
10
11
12
13
14
15
16
17
18
19
20
21
22
23
24
25
26
27
28
29

A 45-year-old man comes to the emergency department because of severe chest pain, diaphoresis, and palpitations. The patient dies two hours after the onset of his symptoms. Autopsy reveals 100% occlusion of the left anterior descending artery. At the time of the patient's death, light microscopy of the affected myocardium would most likely demonstrate which of the following?

- A. Edema and punctate hemorrhages
- B. Myocyte hypereosinophilia
- C. Dense interstitial neutrophil infiltrate
- D. Extensive macrophage phagocytosis of the dead cells
- E. Fibrovascular granulation tissue with neovascularization
- F. Dense collagen scar
- G. Normal myocardium

Submit

A 45-year-old man comes to the emergency department because of severe chest pain, diaphoresis, and palpitations. The patient dies two hours after the onset of his symptoms. Autopsy reveals 100% occlusion of the left anterior descending artery. At the time of the patient's death, light microscopy of the affected myocardium would most likely demonstrate which of the following?

- A. Edema and punctate hemorrhages (12%)
- B. Myocyte hypereosinophilia (7%)
- C. Dense interstitial neutrophil infiltrate (9%)
- D. Extensive macrophage phagocytosis of the dead cells (1%)
- E. Fibrovascular granulation tissue with neovascularization (0%)
- F. Dense collagen scar (0%)
- ✓ G. Normal myocardium (67%)

Omitted
Correct answer
G

67%
Answered correctly

11 secs
Time Spent

06/07/2020
Last Updated

Explanation

Time after myocardial infarction	Predominant light microscopic changes
0-4 hrs	minimal change
4-12 hrs	early coagulation necrosis, edema, hemorrhage, wavy fibers

1
2
3
4
5
6
7
8
9
10
11
12
13
14
15
16
17
18
19
20
21
22
23
24
25
26
27
28
29

Time after myocardial infarction	Predominant light microscopic changes
0-4 hrs	minimal change
4-12 hrs	early coagulation necrosis, edema, hemorrhage, wavy fibers
12-24 hrs	coagulation necrosis and marginal contraction band necrosis
1 to 5 days	coagulation necrosis and neutrophilic infiltrate
5 to 10 days	macrophage phagocytosis of dead cells
10 to 14 days	granulation tissue and neovascularization
2 weeks to 2 months	collagen deposition / scar formation

The cause of death was most likely an acute myocardial infarction. In myocardial infarction, changes on light microscopy are usually not apparent until 4 hours after the onset of severe ischemia. Although a variable waviness of myofibrils at the border of the infarct (due to myofibril relaxation) might be observed before this, more definite signs of early coagulative necrosis, such as cytoplasmic eosinophilia and nuclear pyknosis, take at least 4 hours to develop.

Other potentially lethal causes of chest pain, diaphoresis, and palpitations/tachycardia include aortic dissection and/or rupture, massive pulmonary embolism, and tension pneumothorax. The chest pain of aortic dissection is typically tearing in nature and often radiates to the back. Dyspnea is typically the most prominent symptom in the event of a pulmonary embolus or tension pneumothorax.

(Choices A & B) Cytoplasmic hypereosinophilia on light microscopy is one of the earliest signs of coagulative necrosis of cardiac myocytes. It begins approximately 4 hours after the onset of lethal ischemia. Light microscopy may also reveal edema and punctate hemorrhages in infarcted myocardium starting also at about 4 hours after the ischemic event.

(Choice C) An interstitial infiltrate of neutrophils around a zone of myocardial infarction is not seen until 1 to 3 days after the onset of severe ischemia.

1
2
3
4
5
6
7
8
9
10
11
12
13
14
15
16
17
18
19
20
21
22
23
24
25
26
27
28
29

The cause of death was most likely an acute myocardial infarction. In myocardial infarction, changes on light microscopy are usually not apparent until 4 hours after the onset of severe ischemia. Although a variable waviness of myofibrils at the border of the infarct (due to myofibril relaxation) might be observed before this, more definite signs of early coagulative necrosis, such as cytoplasmic eosinophilia and nuclear pyknosis, take at least 4 hours to develop.

Other potentially lethal causes of chest pain, diaphoresis, and palpitations/tachycardia include aortic dissection and/or rupture, massive pulmonary embolism, and tension pneumothorax. The chest pain of aortic dissection is typically tearing in nature and often radiates to the back. Dyspnea is typically the most prominent symptom in the event of a pulmonary embolus or tension pneumothorax.

(Choices A & B) Cytoplasmic hypereosinophilia on light microscopy is one of the earliest signs of coagulative necrosis of cardiac myocytes. It begins approximately 4 hours after the onset of lethal ischemia. Light microscopy may also reveal edema and punctate hemorrhages in infarcted myocardium starting also at about 4 hours after the ischemic event.

(Choice C) An interstitial infiltrate of neutrophils around a zone of myocardial infarction is not seen until 1 to 3 days after the onset of severe ischemia.

(Choice D) Extensive macrophage phagocytosis of the dead cells generally does not develop until at least 5 days after myocardial infarction, and is most prominent during post-infarction days 7 to 10.

(Choice E) Fibrovascular granulation tissue with neovascularization generally begins to develop 7 days after myocardial infarction, and is most prominent on post-infarction days 10 to 14.

(Choice F) Increased collagen deposition and decreased cellularity in a zone of infarcted myocardium is not generally evident until 2 weeks post-infarction. Fibrosis continues during weeks 2 to 8, producing a dense collagenous scar by two months post-infarction.

Educational objective:
After the onset of severe ischemia leading to myocardial infarction (MI), early signs of coagulative necrosis do not become apparent on light microscopy until 4 hours after the onset of MI.

Pathology	Cardiovascular System	Myocardial infarction
Subject	System	Topic

1
2
3
4
5
6
7
8
9
10
11
12
13
14
15
16
17
18
19
20
21
22
23
24
25
26
27
28
29

A 65-year-old man is evaluated for progressive shortness of breath. He has had exertional dyspnea for the past year and has been experiencing weight gain and peripheral edema for the last several weeks. He has no previous history of cardiac or pulmonary disease. Cardiac biopsy of the left ventricle shows the histopathologic findings on the slide below.

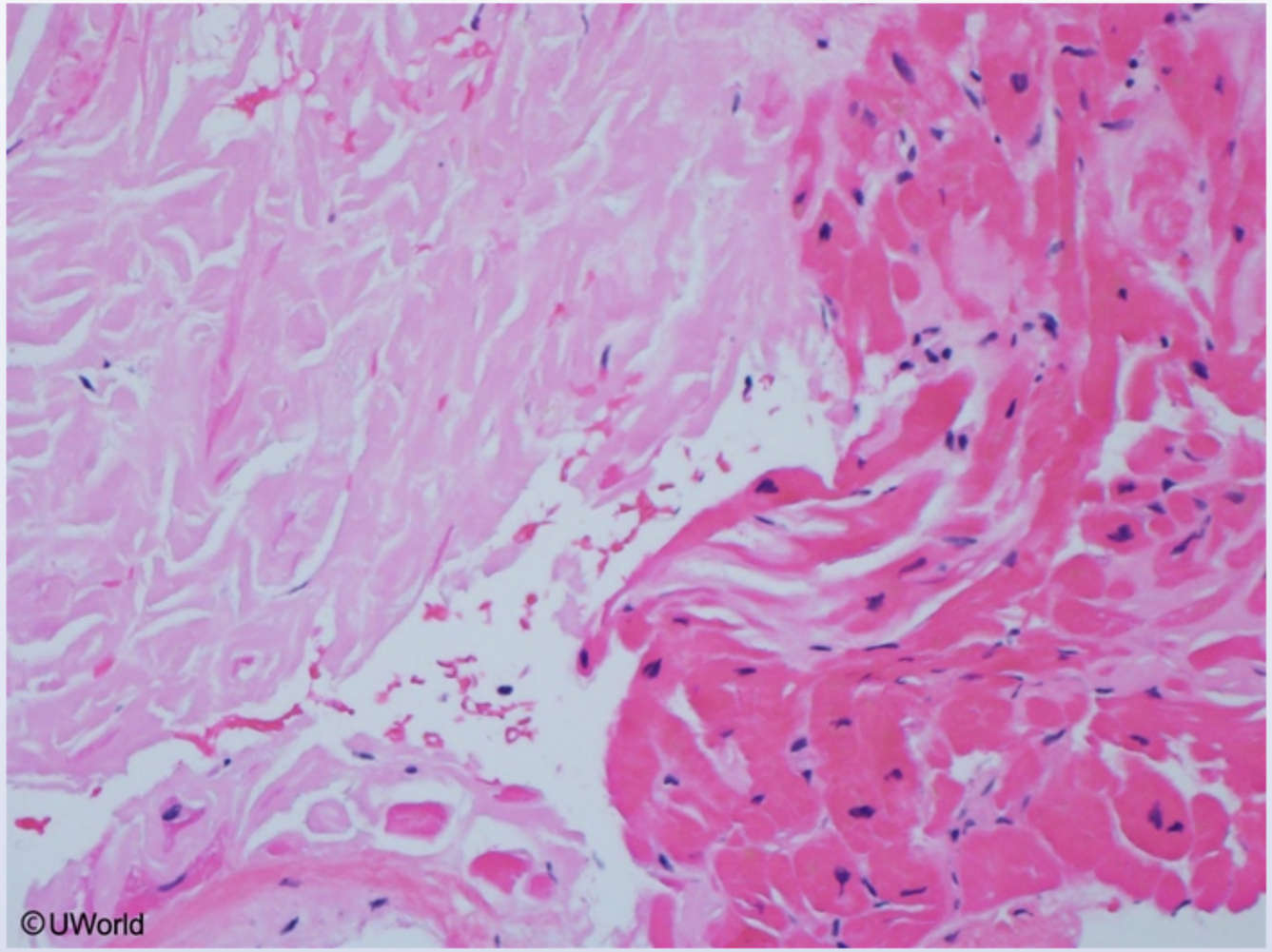

1
2
3
4
5
6
7
8
9
10
11
12
13
14
15
16
17
18
19
20
21
22
23
24
25
26
27
28
29

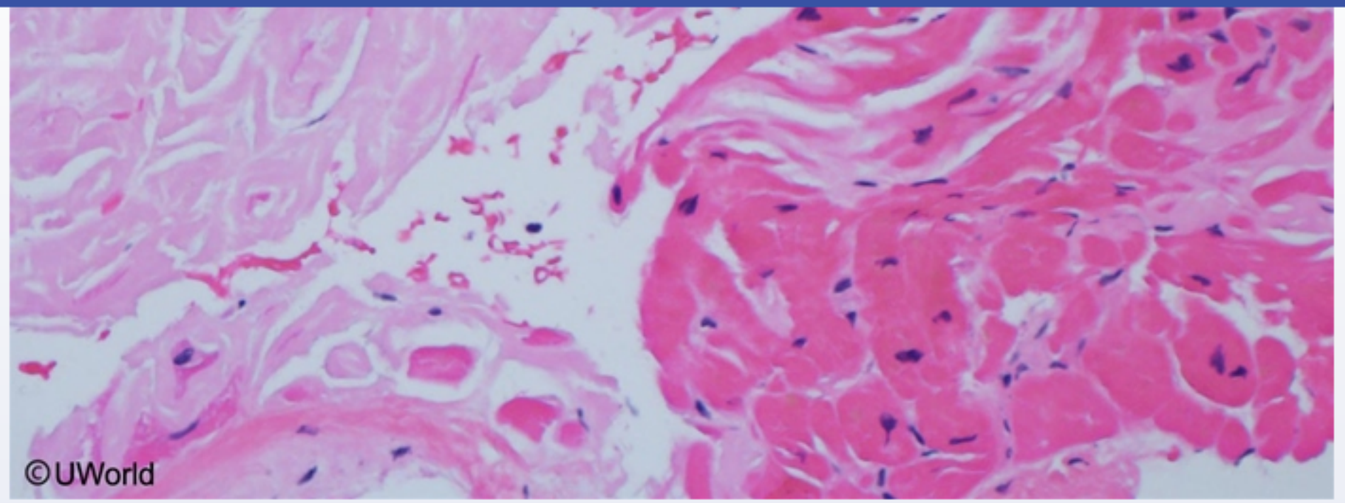

Which of the following are the most likely echocardiographic findings in this patient?

	Left atrial cavity size	Left ventricular cavity size	Left ventricular wall thickness	Left ventricular relaxation
A.	Dilated	Not dilated	Normal	Normal
B.	Dilated	Dilated	Normal	Impaired
C.	Dilated	Not dilated	Increased	Impaired
D.	Not dilated	Dilated	Increased	Impaired
E.	Not dilated	Dilated	Increased	Normal

Submit

1
2
3
4
5
6
7
8
9
10
11
12
13
14
15
16
17
18
19
20
21
22
23
24
25
26
27
28
29

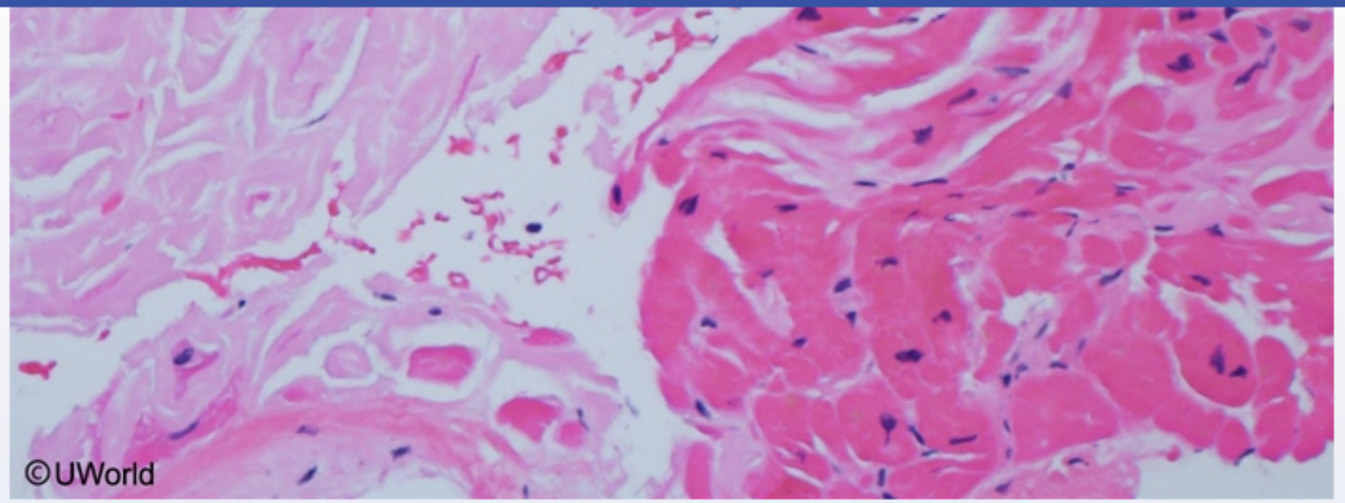

Which of the following are the most likely echocardiographic findings in this patient?

	Left atrial cavity size	Left ventricular cavity size	Left ventricular wall thickness	Left ventricular relaxation
A. (3%)	Dilated	Not dilated	Normal	Normal
B. (20%)	Dilated	Dilated	Normal	Impaired
✓ C. (59%)	Dilated	Not dilated	Increased	Impaired
D. (11%)	Not dilated	Dilated	Increased	Impaired
E. (5%)	Not dilated	Dilated	Increased	Normal

1
2
3
4
5
6
7
8
9
10
11
12
13
14
15
16
17
18
19
20
21
22
23
24
25
26
27
28
29

Explanation

Amyloid

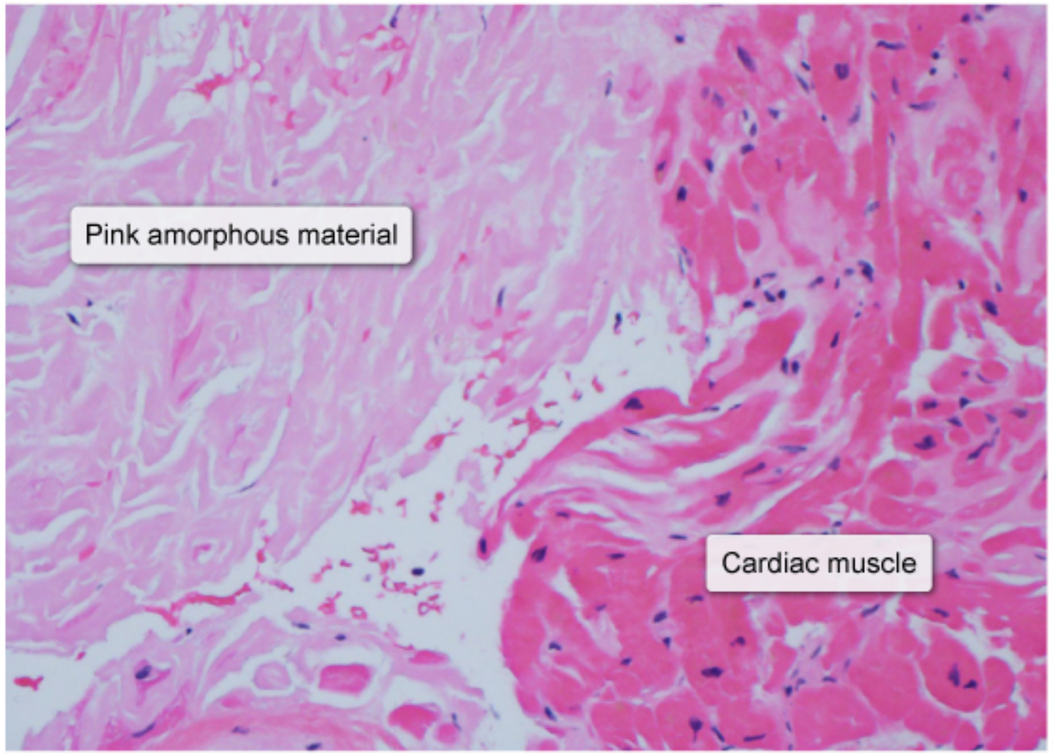

©UWorld

This patient with **decompensated heart failure** (eg, progressive dyspnea, weight gain, peripheral edema) has copious pink, amorphous material (hyaline) on cardiac biopsy, which is characteristic of **amyloid cardiomyopathy**. Amyloidosis is a systemic disorder caused by the **extracellular deposition** of fibrils of misfolded amyloid protein in various tissues (eg, liver, kidney, blood vessels), resulting in organ enlargement and dysfunction (eg, hepatomegaly, nephrotic syndrome, easy bruising).

1
2
3
4
5
6
7
8
9
10
11
12
13
14
15
16
17
18
19
20
21
22
23
24
25
26
27
28
29

This patient with **decompensated heart failure** (eg, progressive dyspnea, weight gain, peripheral edema) has copious pink, amorphous material (hyaline) on cardiac biopsy, which is characteristic of **amyloid cardiomyopathy**. Amyloidosis is a systemic disorder caused by the **extracellular deposition** of fibrils of misfolded amyloid protein in various tissues (eg, liver, kidney, blood vessels), resulting in organ enlargement and dysfunction (eg, hepatomegaly, nephrotic syndrome, easy bruising).

Cardiac amyloid deposition typically causes a **restrictive cardiomyopathy** with **uniformly thickened ventricular walls** (normal thickness is seen with other noninfiltrative etiologies) that are stiff with **impaired diastolic relaxation**. Left ventricular (LV) cavity size is normal or decreased, and the impaired diastolic relaxation both increases LV filling pressure and reduces cardiac output (leading to dyspnea). The elevated LV pressure is transmitted backward, leading to **left atrial dilation**, increased pulmonary arterial pressure, and progressive right-sided heart failure (eg, jugular venous distension, peripheral edema).

(Choice A) A dilated left atrial cavity with normal LV parameters is indicative of mitral stenosis. Patients typically have pulmonary edema in addition to symptoms of right-sided heart failure. Accumulation of amorphous extracellular material is not expected on autopsy.

(Choice B) Dilated left atrial and ventricular cavities with normal LV wall thickness is consistent with dilated cardiomyopathy, which results from contractile dysfunction after direct myocardial insult (eg, infection, chronic alcohol toxicity). LV relaxation may be normal or impaired depending on the disease progression and underlying etiology. Interstitial fibrosis would be prominent on microscopy in addition to findings specific to the underlying cause (eg, inflammatory cells in viral myocarditis).

(Choice D) These changes are not characteristic of any specific cardiac condition.

(Choice E) Normal left atrial cavity size with a dilated LV cavity and thickened LV walls but normal LV relaxation is consistent with the changes that occur in response to intense endurance training in an athlete's heart. As these changes are physiologic, decompensated heart failure does not occur.

Educational objective:
Amyloid cardiomyopathy, caused by the accumulation of misfolded amyloid fibrils, appears as pink, amorphous extracellular material on light microscopy. The ventricular walls become stiff and uniformly thickened, leading to impaired diastolic relaxation, a dilated left atrial cavity, and progressive left- and right-sided heart failure. Left ventricular cavity size is typically normal or decreased.

References

- Serial Doppler echocardiographic follow-up of left ventricular diastolic function in cardiac amyloidosis.

1
2
3
4
5
6
7
8
9
10
11
12
13
14
15
16
17
18
19
20
21
22
23
24
25
26
27
28
29

This patient with **decompensated heart failure** (eg, progressive dyspnea, weight gain, peripheral edema) has copious pink, amorphous material

Exhibit Display

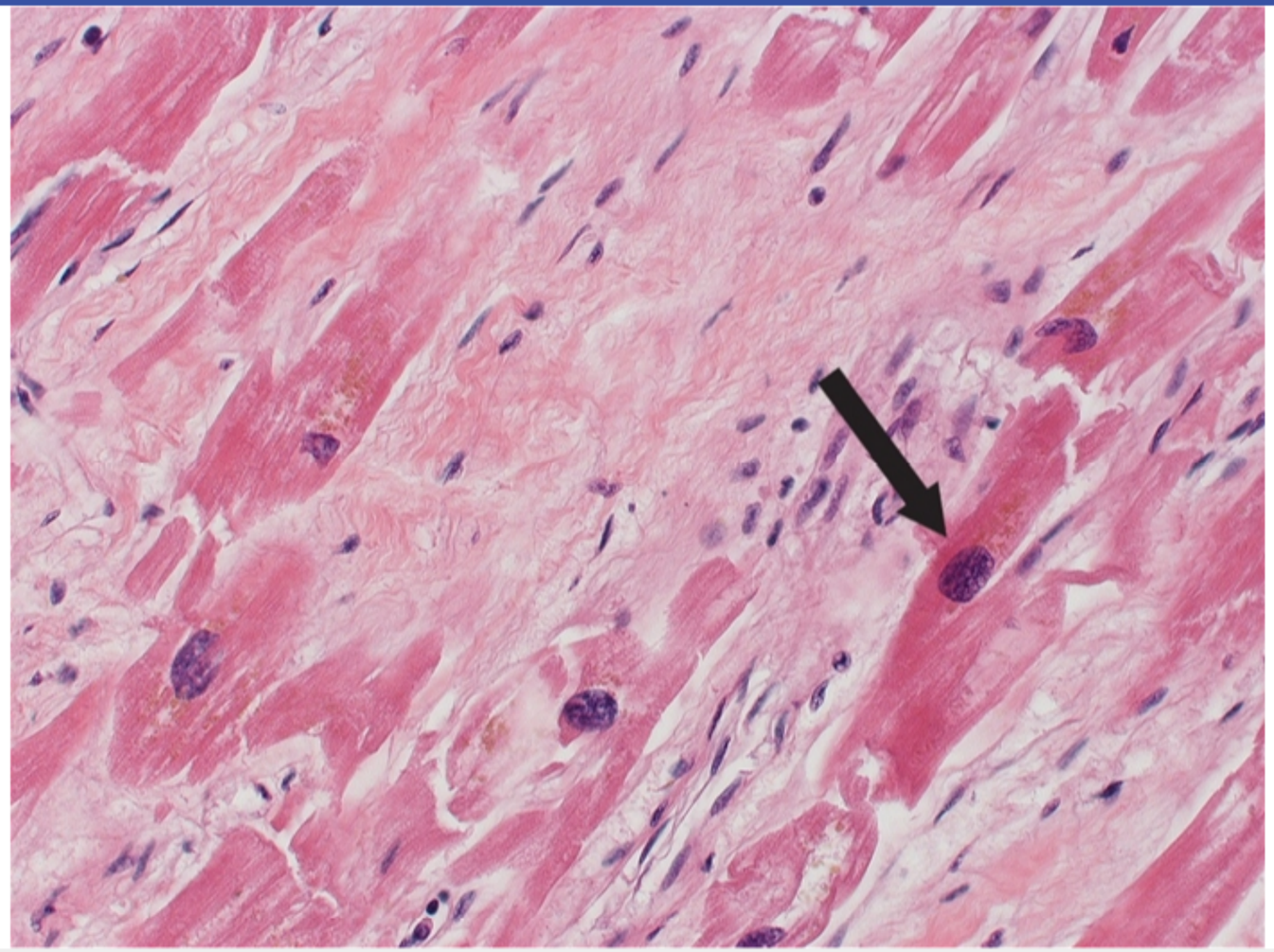

Zoom In Zoom Out Reset Add To Flash Card

- Serial Doppler echocardiographic follow-up of left ventricular diastolic function in cardiac amyloidosis.

A 42-year-old man is brought to the emergency department due to severe, ripping chest pain that started abruptly 2 hours ago. The pain is midline, constant, and 10/10 in intensity. He has no fever, cough, or shortness of breath. His only medical condition is hypertension. On examination, the patient is diaphoretic and appears in severe distress due to pain. Temperature is 37.0 C (98.6 F), pulse is 116/min, and respirations are 24/min. Systolic blood pressure is 82 mm Hg in the right arm and 60 mm Hg in the left arm. Jugular veins are distended with a pressure of 13 cm H_2O. The lungs are clear to auscultation. The point of maximal impulse is not palpable and heart sounds are distant. The extremities are cold with no peripheral edema. The patient develops cardiac arrest and dies soon after arrival. Autopsy would most likely reveal which of the following?

A. Aortic dissection extending to the pericardial space

B. Left ventricular transmural myocardial infarction

C. Ruptured abdominal aortic aneurysm with retroperitoneal hemorrhage

D. Rupture of papillary muscles and flail mitral valve

E. Saddle thrombus obstructing the pulmonary artery trunk

Submit

1
2
3
4
5
6
7
8
9
10
11
12
13
14
15
16
17
18
19
20
21
22
23
24
25
26
27
28
29

A 42-year-old man is brought to the emergency department due to severe, ripping chest pain that started abruptly 2 hours ago. The pain is midline, constant, and 10/10 in intensity. He has no fever, cough, or shortness of breath. His only medical condition is hypertension. On examination, the patient is diaphoretic and appears in severe distress due to pain. Temperature is 37.0 C (98.6 F), pulse is 116/min, and respirations are 24/min. Systolic blood pressure is 82 mm Hg in the right arm and 60 mm Hg in the left arm. Jugular veins are distended with a pressure of 13 cm H_2O. The lungs are clear to auscultation. The point of maximal impulse is not palpable and heart sounds are distant. The extremities are cold with no peripheral edema. The patient develops cardiac arrest and dies soon after arrival. Autopsy would most likely reveal which of the following?

- ✓ A. Aortic dissection extending to the pericardial space (91%)
- B. Left ventricular transmural myocardial infarction (1%)
- C. Ruptured abdominal aortic aneurysm with retroperitoneal hemorrhage (3%)
- D. Rupture of papillary muscles and flail mitral valve (0%)
- E. Saddle thrombus obstructing the pulmonary artery trunk (1%)

Omitted
Correct answer
A

91%
Answered correctly

01 sec
Time Spent

04/07/2020
Last Updated

Explanation

Acute aortic dissection	
	• History of HTN, Marfan syndrome, or cocaine use

1
2
3
4
5
6
7
8
9
10
11
12
13
14
15
16
17
18
19
20
21
22
23
24
25
26
27
28
29

Acute aortic dissection	
Clinical features	• History of HTN, Marfan syndrome, or cocaine use • Severe, sharp, tearing chest or back pain • ± >20 mm Hg variation in SBP between arms
Complications due to extension (involved structure)	• Stroke (carotid artery) • Acute aortic regurgitation (aortic valve) • Myocardial ischemia/infarction (coronary artery ostia) • Pericardial effusion/tamponade (pericardium) • Renal injury, abdominal pain (renal, mesenteric arteries) • Lower-extremity paraplegia (spinal arteries)

HTN = hypertension; **SBP** = systolic blood pressure.

This patient's presentation is most consistent with an **ascending aortic dissection** complicated by cardiac tamponade. Dissections can affect the ascending aorta (type A) or may involve only the descending aorta (type B). The most common symptom is sharp or tearing **chest and back pain** that is severe and sudden. If an ascending dissection extends proximally to the aortic root, it can affect the coronary ostia or aortic valve, resulting in myocardial ischemia or aortic regurgitation, respectively. Other signs and symptoms include **blood pressure asymmetry**, stroke, or paraplegia, depending on the vessels and structures involved (eg, subclavian artery, carotid artery, spinal arteries).

In addition, a dissection may extend proximally into the **pericardium**, leading to life-threatening **acute tamponade**. As blood accumulates in the pericardial sac, the rising pressure can rapidly supersede right-sided filling pressure and restrict venous return, resulting in a precipitous drop in cardiac output and hemodynamic collapse **(obstructive shock)**. Signs of tamponade include jugular venous distension, muffled heart sounds, and hypotension (Beck triad), as well as reduced point of maximal impulse, cool extremities, and clear lungs.

(Choices B and D) Myocardial infarction or papillary muscle rupture can lead to left ventricular failure with hemodynamic collapse and cardiogenic shock. However, because the heart failure is left-sided (rather than right-sided as in tamponade), pulmonary edema is expected.

This patient's presentation is most consistent with an **ascending aortic dissection** complicated by cardiac tamponade. Dissections can affect the ascending aorta (type A) or may involve only the descending aorta (type B). The most common symptom is sharp or tearing **chest and back pain** that is severe and sudden. If an ascending dissection extends proximally to the aortic root, it can affect the coronary ostia or aortic valve, resulting in myocardial ischemia or aortic regurgitation, respectively. Other signs and symptoms include **blood pressure asymmetry**, stroke, or paraplegia, depending on the vessels and structures involved (eg, subclavian artery, carotid artery, spinal arteries).

In addition, a dissection may extend proximally into the **pericardium**, leading to life-threatening **acute tamponade**. As blood accumulates in the pericardial sac, the rising pressure can rapidly supersede right-sided filling pressure and restrict venous return, resulting in a precipitous drop in cardiac output and hemodynamic collapse **(obstructive shock)**. Signs of tamponade include jugular venous distension, muffled heart sounds, and hypotension (Beck triad), as well as reduced point of maximal impulse, cool extremities, and clear lungs.

(Choices B and D) Myocardial infarction or papillary muscle rupture can lead to left ventricular failure with hemodynamic collapse and cardiogenic shock. However, because the heart failure is left-sided (rather than right-sided as in tamponade), pulmonary edema is expected. Upper extremity blood pressure asymmetry is also not typical.

(Choice C) Rupture of an abdominal aortic aneurysm most commonly occurs into the retroperitoneum. Patients can develop hemorrhagic (hypovolemic) shock, especially if the bleeding progresses into the peritoneal cavity (large potential space). However, in such a setting, heart sounds are not reduced, a point of maximal tenderness should be palpable, and neck veins would be flat.

(Choice E) A saddle pulmonary thromboembolism can lead to hemodynamic instability (obstructive shock) with right ventricular failure and jugular venous distension. However, it would not account for upper extremity blood pressure asymmetry or distant heart sounds.

Educational objective:
The most common symptom of acute aortic dissection is sudden onset of severe, sharp or tearing chest and back pain. Complications include stroke, aortic regurgitation, and myocardial ischemia. In addition, a dissection can extend into the pericardium, resulting in tamponade with reduced cardiac output and shock.

References

- Acute aortic dissection and intramural hematoma: a systematic review.
- Screening, evaluation, and early management of acute aortic dissection in the ED.

1
2
3
4
5
6
7
8
9
10
11
12
13
14
15
16
17
18
19
20
21
22
23
24
25
26
27
28
29

A 42-year-old man comes to the emergency department due to fatigue and exertional dyspnea. Over the last 2 weeks his symptoms have progressively worsened to the point that he can no longer walk across his living room without becoming short of breath. He is admitted to the hospital but dies suddenly despite aggressive treatment. An autopsy is performed, and a cross-section of his heart is shown in the image below.

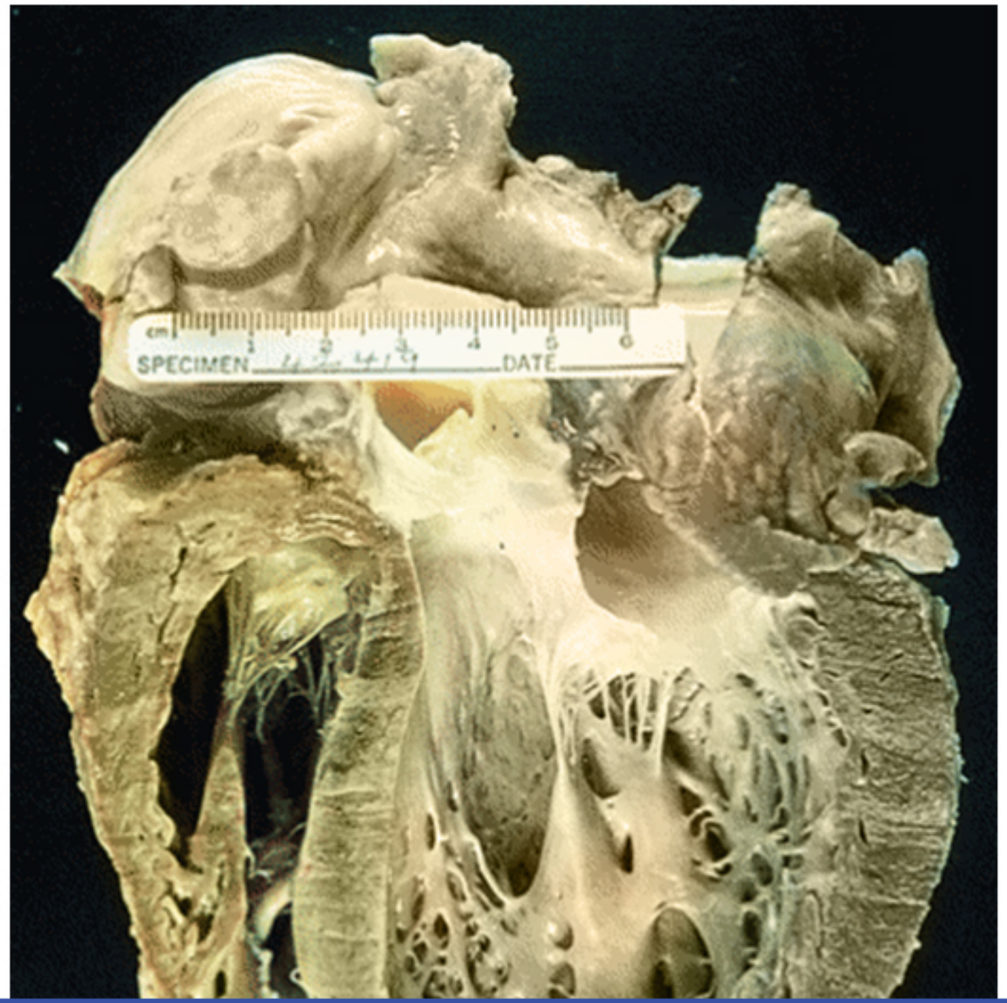

1
2
3
4
5
6
7
8
9
10
11
12
13
14
15
16
17
18
19
20
21
22
23
24
25
26
27
28
29

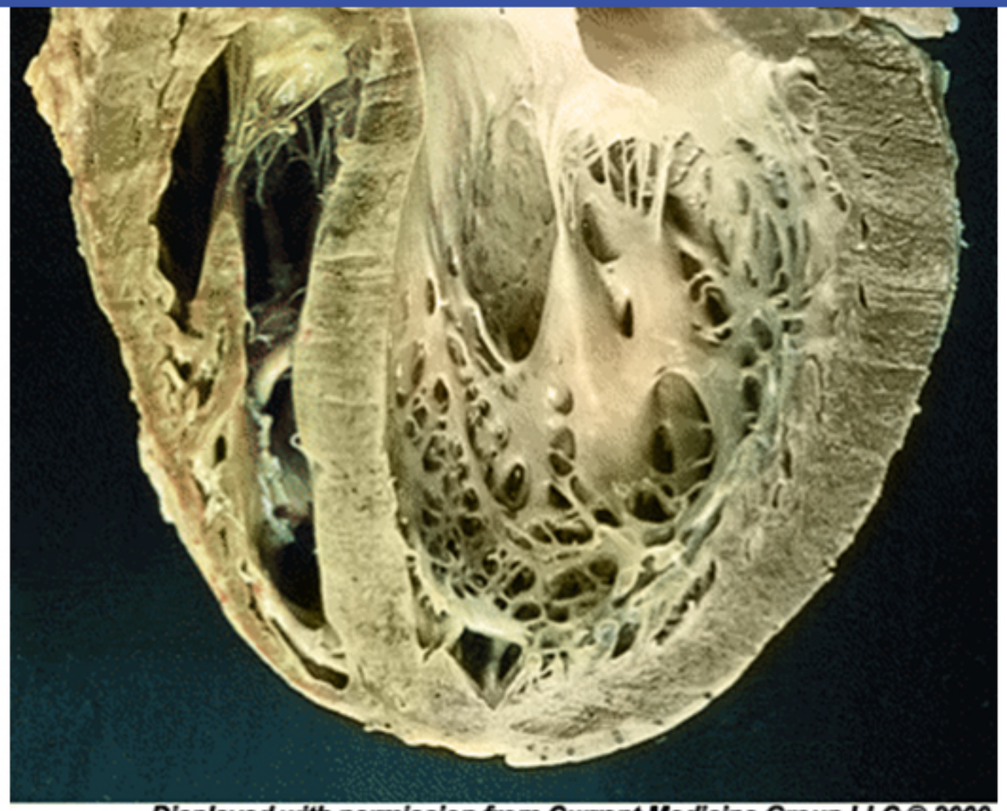

Displayed with permission from Current Medicine Group LLC © 2000.

This patient's symptoms were most likely caused by which of the following mechanisms?

- A. Decreased ventricular contraction force
- B. Dynamic left ventricular outflow obstruction
- C. Impaired left ventricular filling
- D. Increased pulmonary vascular resistance
- E. Poor ventricular wall compliance

1
2
3
4
5
6
7
8
9
10
11
12
13
14
15
16
17
18
19
20
21
22
23
24
25
26
27
28
29

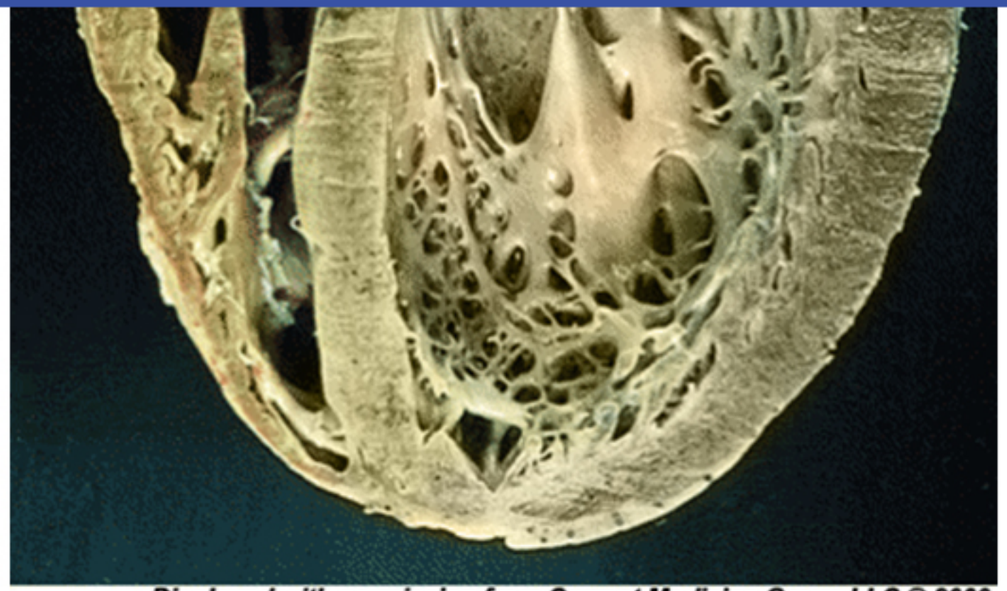

Displayed with permission from Current Medicine Group LLC © 2000.

This patient's symptoms were most likely caused by which of the following mechanisms?

- A. Decreased ventricular contraction force
- B. Dynamic left ventricular outflow obstruction
- C. Impaired left ventricular filling
- D. Increased pulmonary vascular resistance
- E. Poor ventricular wall compliance

Submit

1
2
3
4
5
6
7
8
9
10
11
12
13
14
15
16
17
18
19
20
21
22
23
24
25
26
27
28
29

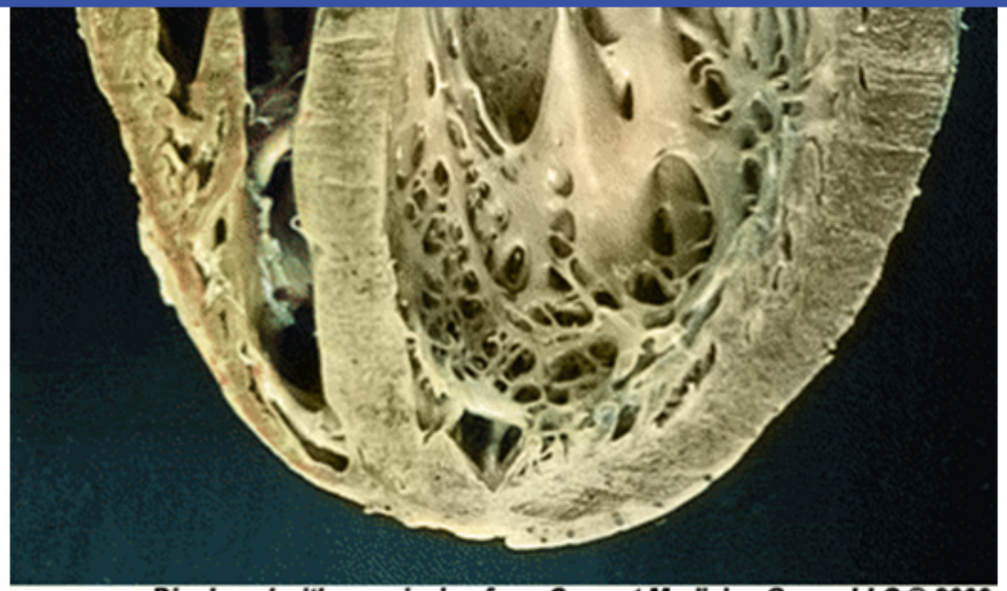

Displayed with permission from Current Medicine Group LLC © 2000.

This patient's symptoms were most likely caused by which of the following mechanisms?

- ✓ A. Decreased ventricular contraction force (64%)
- B. Dynamic left ventricular outflow obstruction (12%)
- C. Impaired left ventricular filling (6%)
- D. Increased pulmonary vascular resistance (6%)
- E. Poor ventricular wall compliance (9%)

Omitted
Correct answer

64%
Answered correctly

08 secs
Time Spent

04/30/2020
Last Updated

1
2
3
4
5
6
7
8
9
10
11
12
13
14
15
16
17
18
19
20
21
22
23
24
25
26
27
28
29

Causes of nonvalvular heart failure				
	Ventricular wall thickness	**Ventricular cavity size**	**Contractile function**	**Diastolic function**
Ischemic heart disease	↓ or normal	↑	↓	↓ or normal
Dilated cardiomyopathy*				
Hypertensive heart disease	↑	↓	normal	↓
Hypertrophic cardiomyopathy*	↑ septal thickening	↓	normal	↓
Restrictive cardiomyopathy*	normal (but stiff)	↓ or normal	normal	↓

*Cardiomyopathies are characterized by primary myocardial dysfunction (eg, viral myocarditis, genetic disorder, infiltrative disease). Myocardial disease caused by secondary factors (eg, hypertension, coronary artery disease, valvular dysfunction) is not classified as a cardiomyopathy.

The gross specimen of this patient's heart demonstrates **left ventricular (LV) cavity enlargement** consistent with eccentric hypertrophy, which is initially an adaptive mechanism that allows the LV to maintain cardiac output in the setting of increasing **volume overload**. Multiple disease processes can lead to eccentric hypertrophy, including **ischemic heart disease**, certain types of valvular disease (ie, aortic regurgitation, mitral regurgitation), and primary myocardial dysfunction (eg, due to viral infection, chronic alcohol abuse, inherited disease) manifesting as **dilated cardiomyopathy**.

Eventually, progressive eccentric enlargement of the LV becomes maladaptive with overwhelming wall stress leading to **decreased ventricular contractility**. The reduced cardiac output leads to **decompensated heart failure** manifesting with fatigue, dyspnea, orthopnea, and peripheral edema. The structural changes to the LV also increase the risk of ventricular arrhythmia (ie, ventricular tachycardia, ventricular fibrillation), a potential cause of sudden cardiac death in these patients.

(Choice B) Dynamic LV outflow tract (LVOT) obstruction can be seen in hypertrophic cardiomyopathy as the degree of LVOT obstruction varies with changes in LV blood volume. Maneuvers or clinical conditions that decrease LV blood volume (eg, Valsalva strain phase, dehydration) exacerbate the obstruction, whereas those that increase LV blood volume (eg, squatting) lessen or may resolve the obstruction.

The gross specimen of this patient's heart demonstrates **left ventricular (LV) cavity enlargement** consistent with eccentric hypertrophy, which is initially an adaptive mechanism that allows the LV to maintain cardiac output in the setting of increasing **volume overload**. Multiple disease processes can lead to eccentric hypertrophy, including **ischemic heart disease**, certain types of valvular disease (ie, aortic regurgitation, mitral regurgitation), and primary myocardial dysfunction (eg, due to viral infection, chronic alcohol abuse, inherited disease) manifesting as **dilated cardiomyopathy**.

Eventually, progressive eccentric enlargement of the LV becomes maladaptive with overwhelming wall stress leading to **decreased ventricular contractility**. The reduced cardiac output leads to **decompensated heart failure** manifesting with fatigue, dyspnea, orthopnea, and peripheral edema. The structural changes to the LV also increase the risk of ventricular arrhythmia (ie, ventricular tachycardia, ventricular fibrillation), a potential cause of sudden cardiac death in these patients.

(Choice B) Dynamic LV outflow tract (LVOT) obstruction can be seen in hypertrophic cardiomyopathy as the degree of LVOT obstruction varies with changes in LV blood volume. Maneuvers or clinical conditions that decrease LV blood volume (eg, Valsalva strain phase, dehydration) exacerbate the obstruction, whereas those that increase LV blood volume (eg, squatting) lessen or may resolve the obstruction.

(Choices C and E) Poor ventricular wall compliance leads to impaired LV filling (diastolic dysfunction). This most commonly occurs as the initial manifestation of hypertensive heart disease with pressure overload leading to concentric LV hypertrophy with thickened LV walls and a small LV cavity. Poor LV wall compliance is also typically present in restrictive cardiomyopathy, severe aortic stenosis, and hypertrophic cardiomyopathy.

(Choice D) Increased pulmonary vascular resistance can cause right heart failure due to pulmonary hypertension. There is initially right ventricular wall thickening eventually leading to right ventricular cavity enlargement as contractile function begins to fail. This patient's right ventricular wall thickness and cavity size appear normal.

Educational objective:
Dilation of the left ventricular cavity commonly occurs in response to systolic dysfunction (eg, ischemic heart disease, dilated cardiomyopathy) or certain types of valvular disease (ie, aortic regurgitation, mitral regurgitation). Chronic volume overload causes progressive eccentric hypertrophy that eventually leads to reduced ventricular contractility and decompensated heart failure.

Pathology	Cardiovascular System	Dilated cardiomyopathy
Subject	System	Topic

1
2
3
4
5
6
7
8
9
10
11
12
13
14
15
16
17
18
19
20
21
22
23
24
25
26
27
28
29

Exhibit Display

Eccentric left ventricular enlargement & heart failure

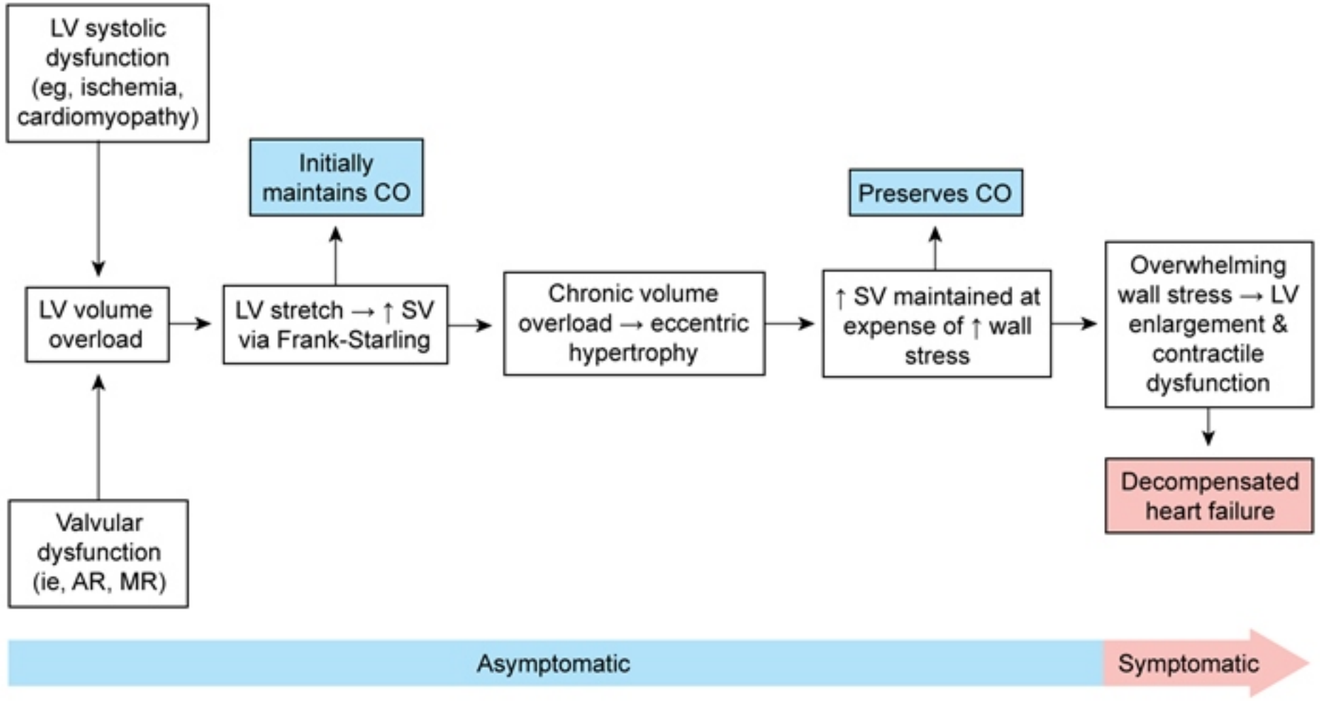

AR = aortic regurgitation; **CO** = cardiac output; **LV** = left ventricular; **MR** = mitral regurgitation; **SV** = stroke volume.

©UWorld

1
2
3
4
5
6
7
8
9
10
11
12
13
14
15
16
17
18
19
20
21
22
23
24
25
26
27
28
29

Exhibit Display

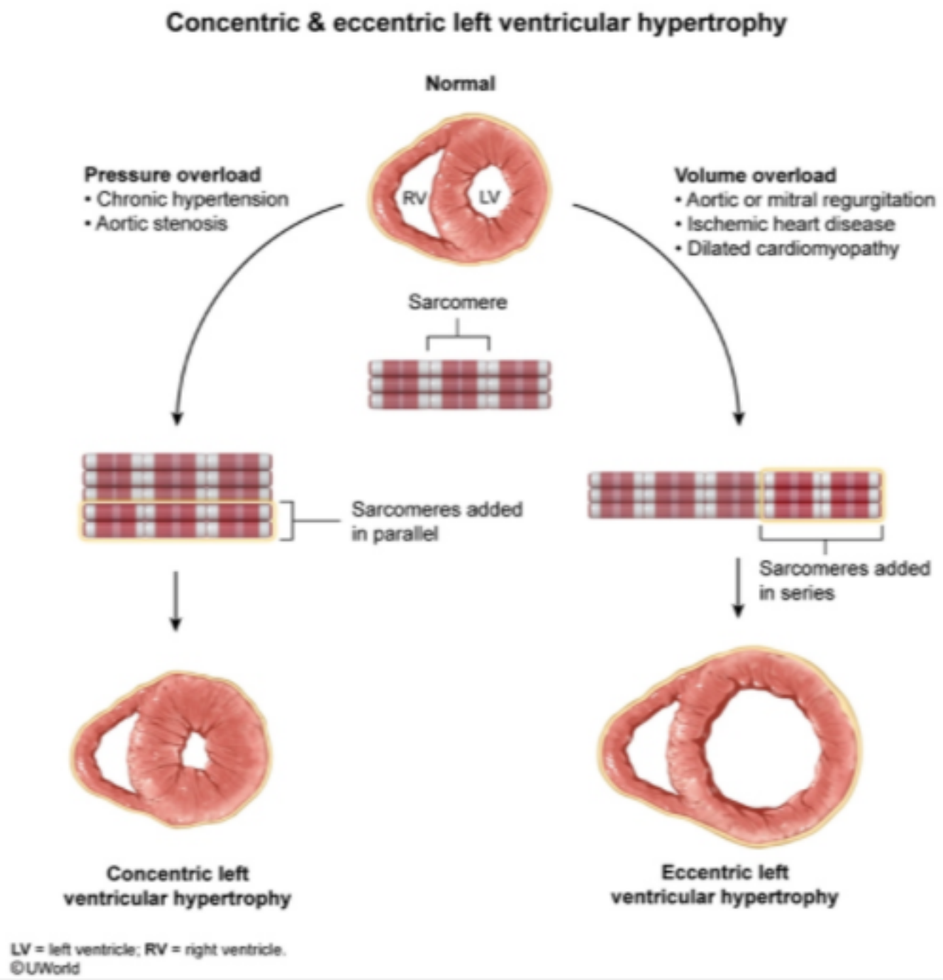

Zoom In | Zoom Out | Reset | Add To New Card | Existing Card

Subject System Topic

1
2
3
4
5
6
7
8
9
10
11
12
13
14
15
16
17
18
19
20
21
22
23
24
25
26
27
28
29

A 5-week-old boy is being evaluated for a week-long history of rapid breathing and tiring with feeds. The infant was born at home after an uneventful pregnancy. The mother declined all prenatal testing and ultrasound evaluations. His temperature is 36.7 C (98 F), blood pressure is 76/38 mm Hg, pulse is 124/min, and respirations are 66/min. The patient's cardiovascular examination is notable for a hyperdynamic precordium, a mid-diastolic rumble at the left sternal border, and a 3/6 holosystolic murmur in the apex that radiates to the left axilla. An echocardiogram shows defects in the lower part of the interatrial septum and the interventricular septum. This patient's condition is most likely associated with which of the following genetic conditions?

A. 22q11.2 deletion
B. Autosomal trisomy
C. Fibrillin mutation
D. Frataxin mutation
E. *Hamartin* gene mutation
F. Sex chromosome monosomy

Submit

1
2
3
4
5
6
7
8
9
10
11
12
13
14
15
16
17
18
19
20
21
22
23
24
25
26
27
28
29

A 5-week-old boy is being evaluated for a week-long history of rapid breathing and tiring with feeds. The infant was born at home after an uneventful pregnancy. The mother declined all prenatal testing and ultrasound evaluations. His temperature is 36.7 C (98 F), blood pressure is 76/38 mm Hg, pulse is 124/min, and respirations are 66/min. The patient's cardiovascular examination is notable for a hyperdynamic precordium, a mid-diastolic rumble at the left sternal border, and a 3/6 holosystolic murmur in the apex that radiates to the left axilla. An echocardiogram shows defects in the lower part of the interatrial septum and the interventricular septum. This patient's condition is most likely associated with which of the following genetic conditions?

A. 22q11.2 deletion (23%)
✓ B. Autosomal trisomy (64%)
C. Fibrillin mutation (5%)
D. Frataxin mutation (3%)
E. *Hamartin* gene mutation (1%)
F. Sex chromosome monosomy (1%)

Omitted
Correct answer
B

64%
Answered correctly

03 secs
Time Spent

04/13/2020
Last Updated

Explanation

Complete atrioventricular canal defect

1
2
3
4
5
6
7
8
9
10
11
12
13
14
15
16
17
18
19
20
21
22
23
24
25
26
27
28
29

Complete atrioventricular canal defect

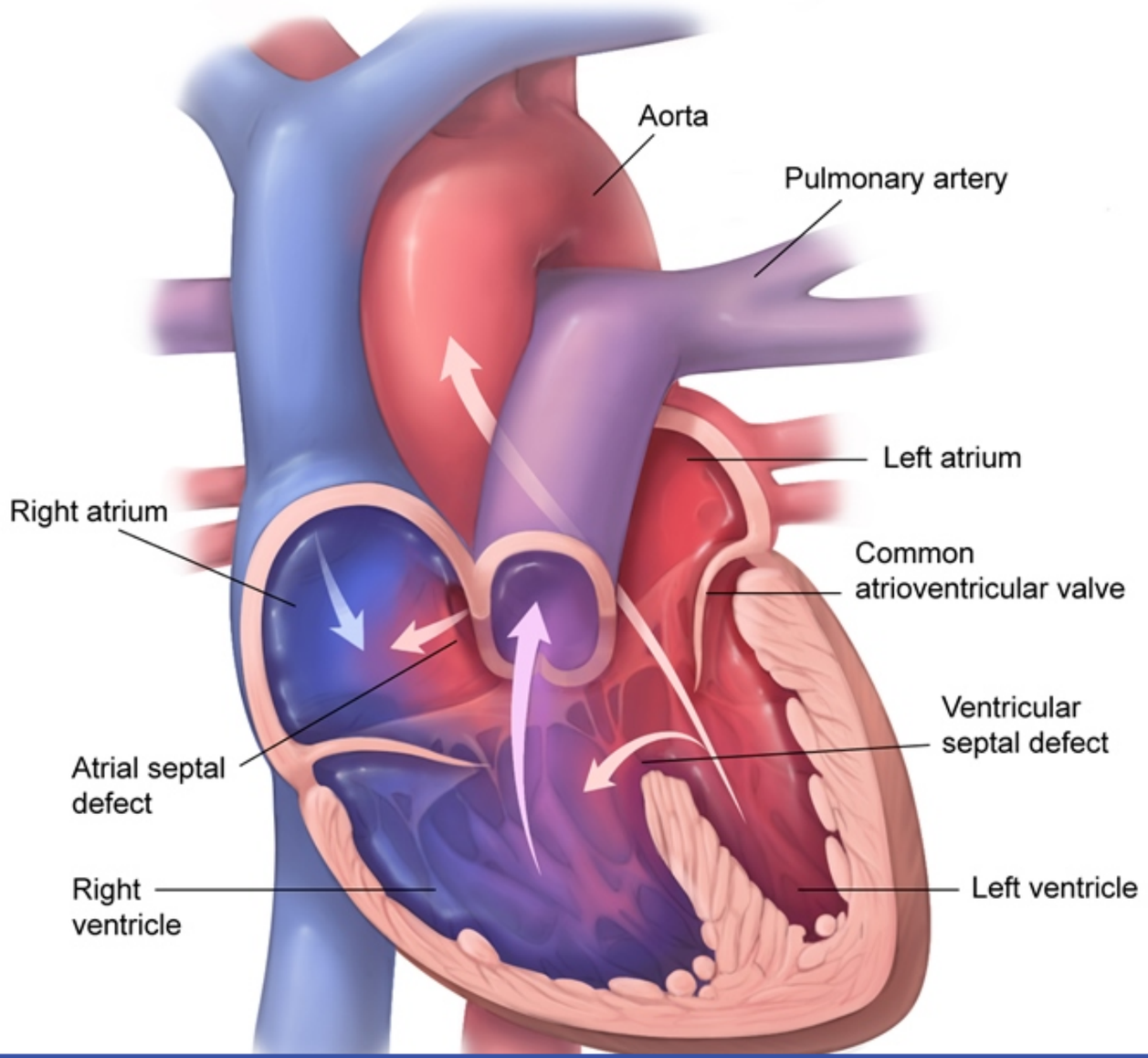

This patient's echocardiogram suggests a **complete atrioventricular (AV)** canal defect, the most common type of cardiac defect in patients with **Down syndrome**, an autosomal trisomy. Failure of endocardial cushion fusion results in an ostium primum atrial septal defect; a ventricular septal defect; and a single AV valve. Significant left-to-right shunting and AV valve regurgitation lead to excessive pulmonary blood flow and symptoms of **heart failure** (eg, tachypnea, poor feeding). Auscultatory findings of AV valve regurgitation (holosystolic, best heard at apex) and increased pulmonary venous return (mid-diastolic rumble) are characteristic.

(Choice A) DiGeorge syndrome (22q11.2 deletion) is characterized by thymic aplasia (T cell deficiency) and hypoparathyroidism (hypocalcemia). It is associated with tetralogy of Fallot, truncus arteriosus, and transposition of the great arteries.

(Choice C) Marfan syndrome (fibrillin-1 mutation) is associated with cystic medial necrosis of the aorta, which may result in dissecting aortic aneurysms and aortic valve regurgitation. Mitral valve prolapse is also common, but septal defects are not.

(Choice D) Mutations in frataxin, a mitochondrial protein important in iron homeostasis and respiratory function, cause Friedreich ataxia. It is characterized by spinocerebellar degeneration and is associated with hypertrophic cardiomyopathy, but not septal defects.

(Choice E) Mutations in tuberin and harmartin are seen in tuberous sclerosis. These patients may develop cardiac rhabdomyomas in ventricular walls and AV valves, cutaneous angiofibromas (adenoma sebaceum), central nervous system hamartomas, and renal cysts. However, septal defects are not characteristic.

(Choice F) A missing sex chromosome (monosomy) is seen in Turner syndrome (45,X), which is associated with bicuspid aortic valve (most common cardiac lesion) and coarctation of the aorta.

Educational objective:
A complete atrioventricular (AV) canal defect is comprised of an atrial septal defect, a ventricular septal defect, and a common AV valve. It is the most common congenital cardiac anomaly associated with Down syndrome.

References

- Genetic syndromes associated with congenital heart disease.

Pathology	Cardiovascular System	Atrioventricular canal defect
Subject	System	Topic

1
2
3
4
5
6
7
8
9
10
11
12
13
14
15
16
17
18
19
20
21
22
23
24
25
26
27
28
29

This patient's echocardiogram suggests a **complete atrioventricular (AV)** canal defect, the most common type of cardiac defect in patients with

Exhibit Display

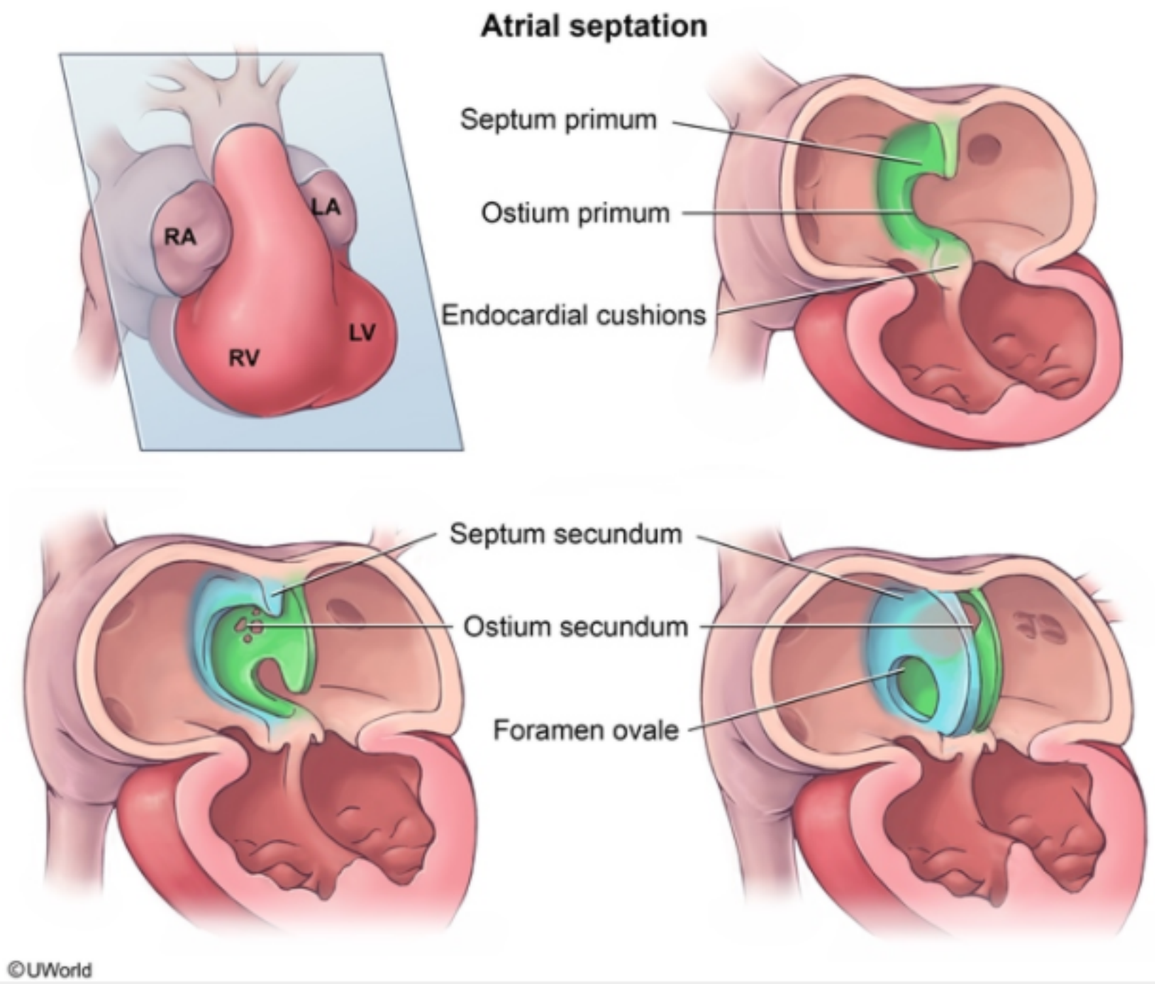

Zoom In | Zoom Out | Reset | Add To New Card | Existing Card

Subject System Topic

This patient's echocardiogram suggests a **complete atrioventricular (AV)** canal defect, the most common type of cardiac defect in patients with

Exhibit Display

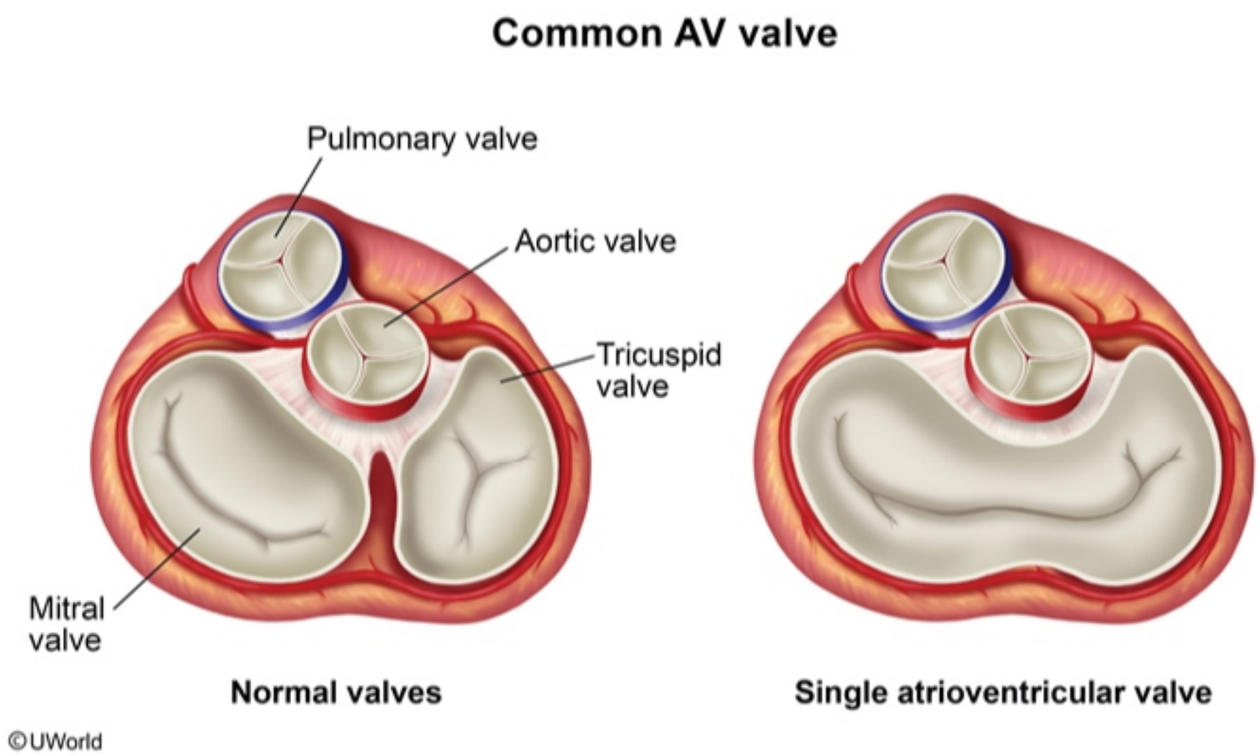

Zoom In | Zoom Out | Reset | Add To New Card | Existing Card

1
2
3
4
5
6
7
8
9
10
11
12
13
14
15
16
17
18
19
20
21
22
23
24
25
26
27
28
29

This patient's echocardiogram suggests a **complete atrioventricular (AV)** canal defect, the most common type of cardiac defect in patients with

Exhibit Display

Tetralogy of Fallot

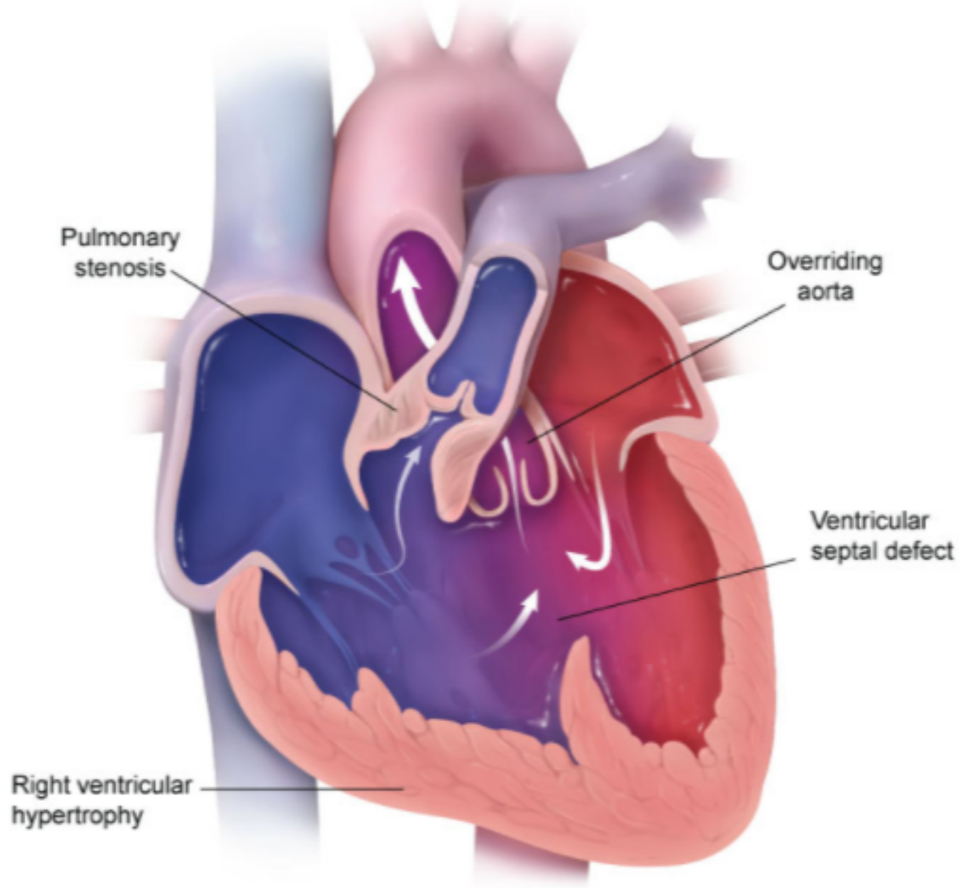

©UWorld

Zoom In | Zoom Out | Reset | Add To New Card | Existing Card

Subject System Topic

1
2
3
4
5
6
7
8
9
10
11
12
13
14
15
16
17
18
19
20
21
22
23
24
25
26
27
28
29

This patient's echocardiogram suggests a **complete atrioventricular (AV)** canal defect, the most common type of cardiac defect in patients with

Exhibit Display

Transposition of the great vessels

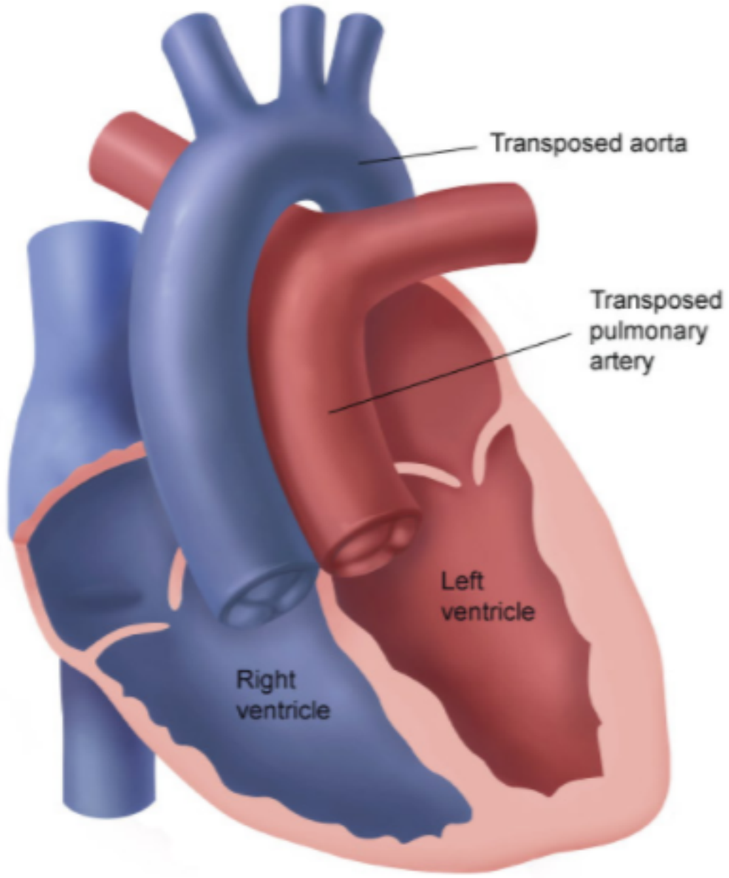

©UWorld

Zoom In | Zoom Out | Reset | Add To New Card | Existing Card

Subject System Topic

This patient's echocardiogram suggests a **complete atrioventricular (AV)** canal defect, the most common type of cardiac defect in patients with

Exhibit Display

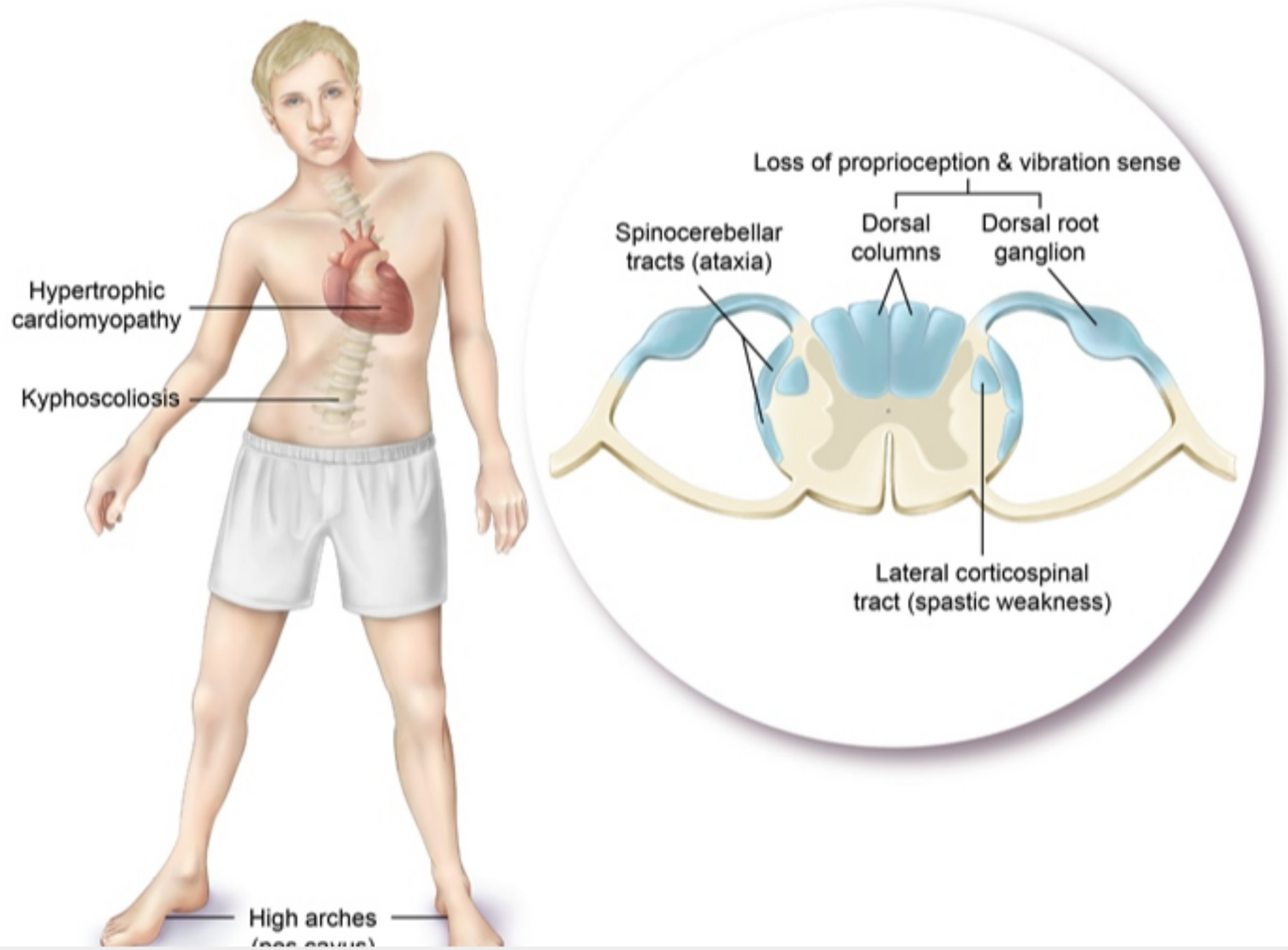

Zoom In | Zoom Out | Reset | Add To New Card | Existing Card

1
2
3
4
5
6
7
8
9
10
11
12
13
14
15
16
17
18
19
20
21
22
23
24
25
26
27
28
29

This patient's echocardiogram suggests a **complete atrioventricular (AV) canal defect**, the most common type of cardiac defect in patients with

Exhibit Display

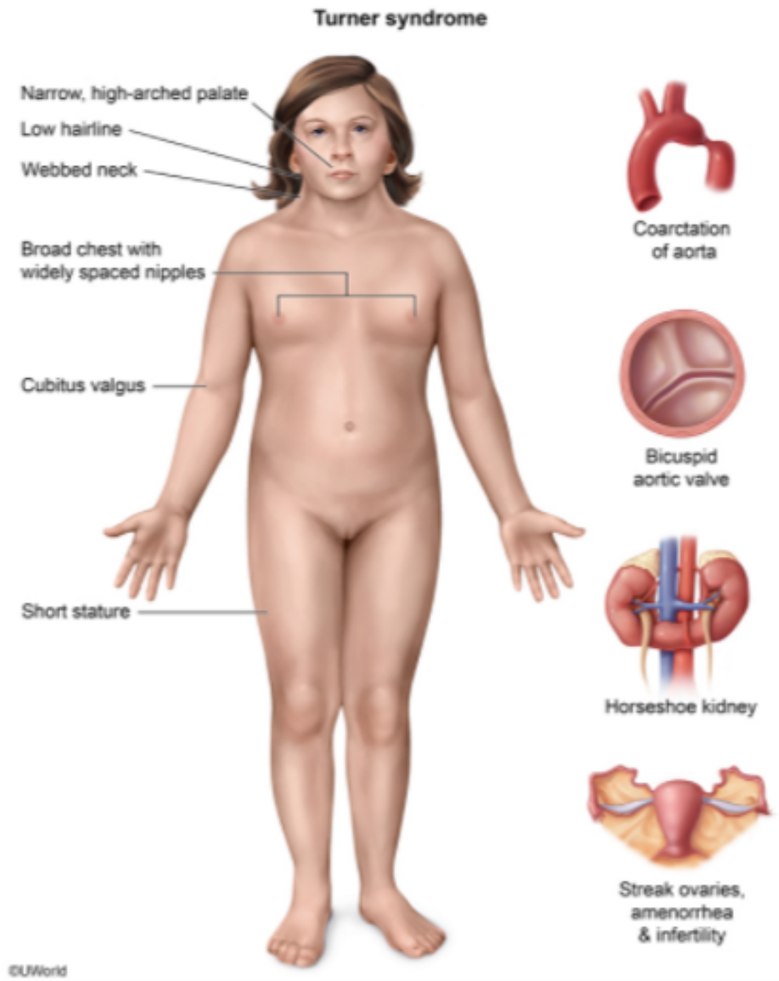

Zoom In | Zoom Out | Reset | Add To New Card | Existing Card

Subject System Topic

1
2
3
4
5
6
7
8
9
10
11
12
13
14
15
16
17
18
19
20
21
22
23
24
25
26
27
28
29

A 10-year-old boy comes to the emergency department with shortness of breath and palpitations for a day. He also has had a fever, poor appetite, and fatigue for 3 days. Vital signs indicate tachypnea, tachycardia, and hypotension. On cardiac auscultation, the patient has a new holosystolic murmur. He is admitted to the hospital for further workup and management. A cardiac biopsy is performed due to decompensation and an unclear diagnosis. Light microscopy of the tissue specimen is shown in the image below.

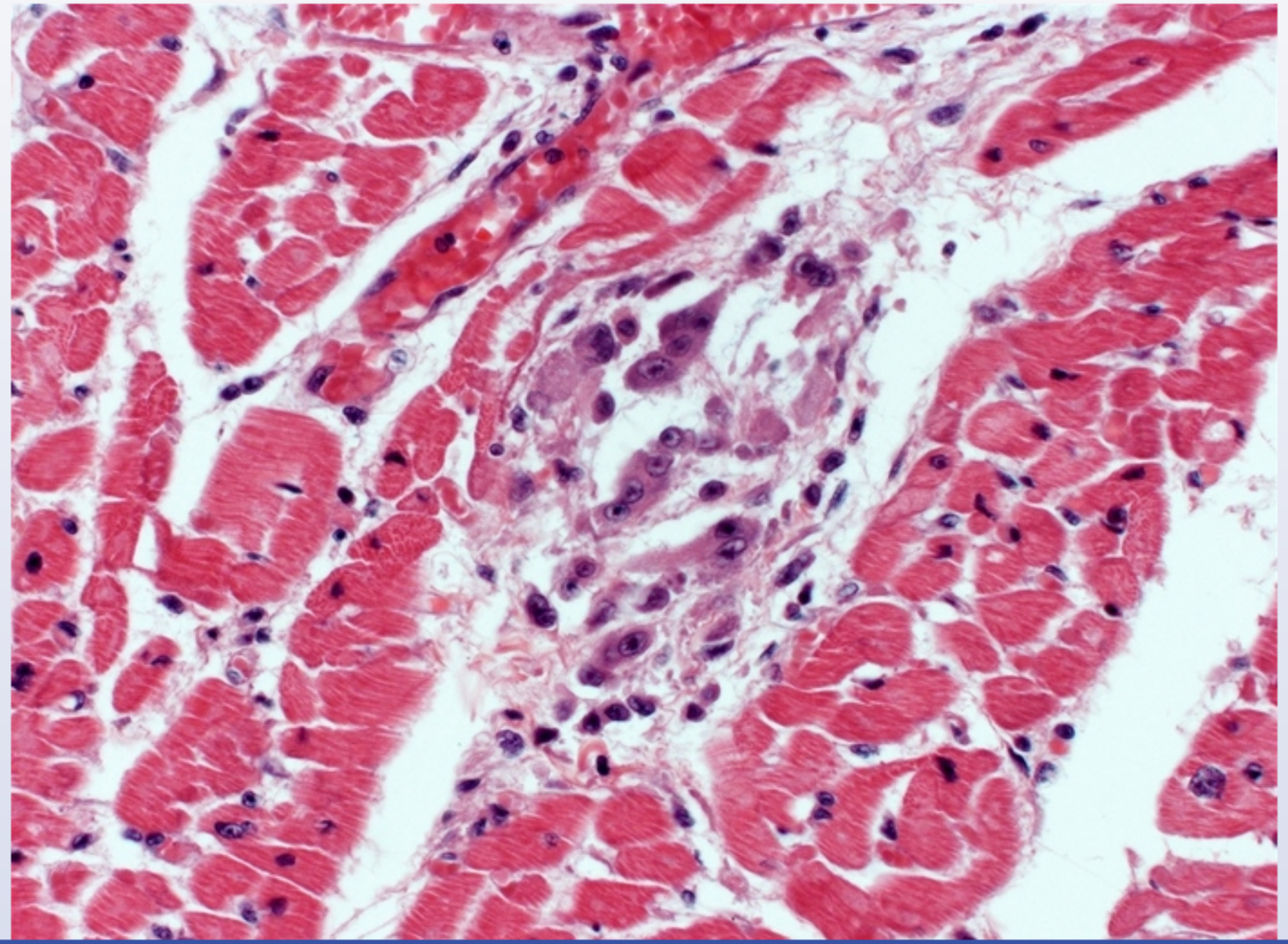

1
2
3
4
5
6
7
8
9
10
11
12
13
14
15
16
17
18
19
20
21
22
23
24
25
26
27
28
29

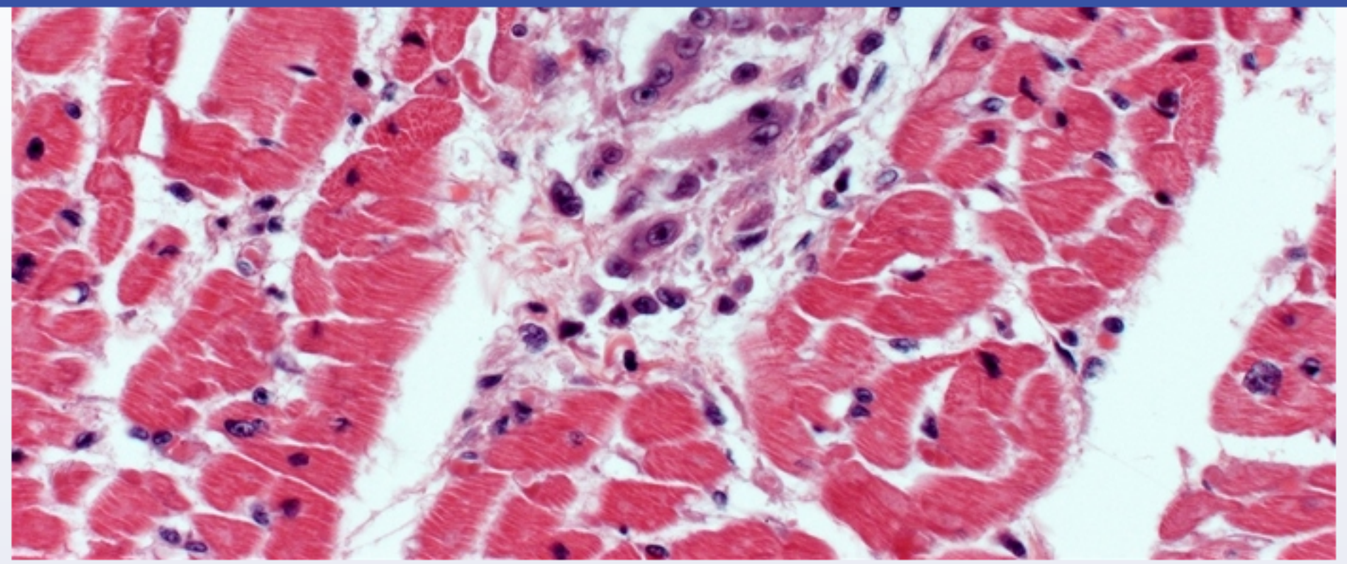

Which of the following most likely preceded this patient's current condition?

- A. Antibiotic exposure
- B. Bacterial infection
- C. Chemotherapy
- D. Genetic mutation
- E. Travel to South America
- F. Viral infection

Submit

1
2
3
4
5
6
7
8
9
10
11
12
13
14
15
16
17
18
19
20
21
22
23
24
25
26
27
28
29

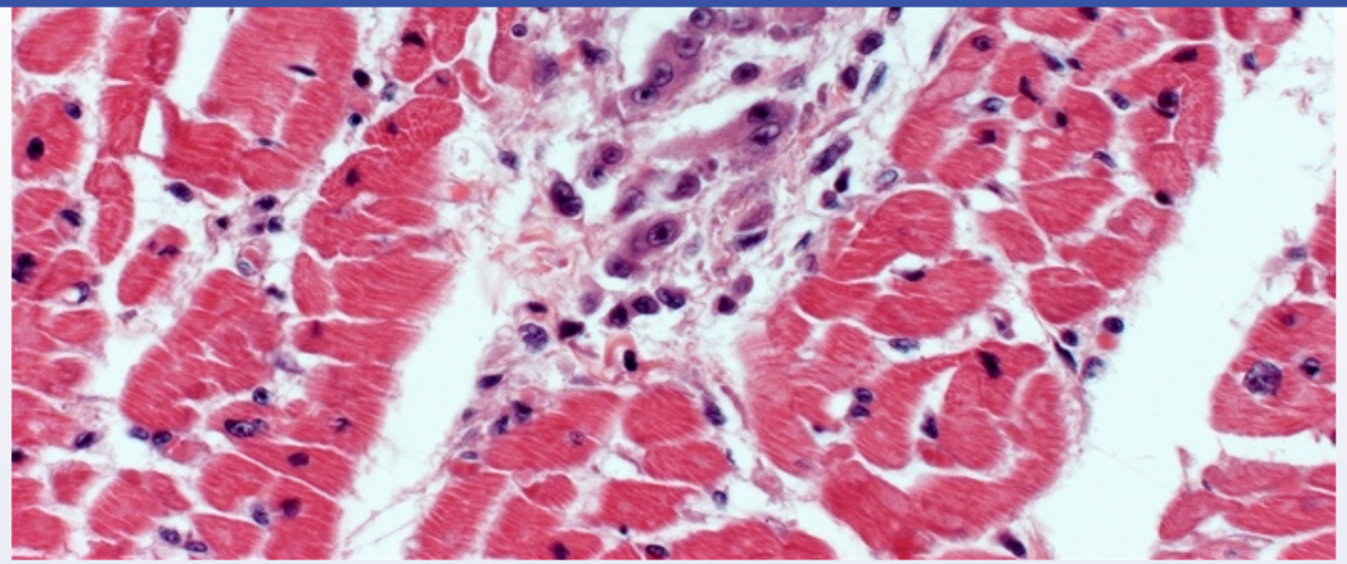

Which of the following most likely preceded this patient's current condition?

- A. Antibiotic exposure (0%)
- ✓ B. Bacterial infection (58%)
- C. Chemotherapy (1%)
- D. Genetic mutation (3%)
- E. Travel to South America (10%)
- F. Viral infection (26%)

Omitted
Correct answer

58%
Answered correctly

06 secs
Time Spent

07/02/2020
Last Updated

1
2
3
4
5
6
7
8
9
10
11
12
13
14
15
16
17
18
19
20
21
22
23
24
25
26
27
28
29

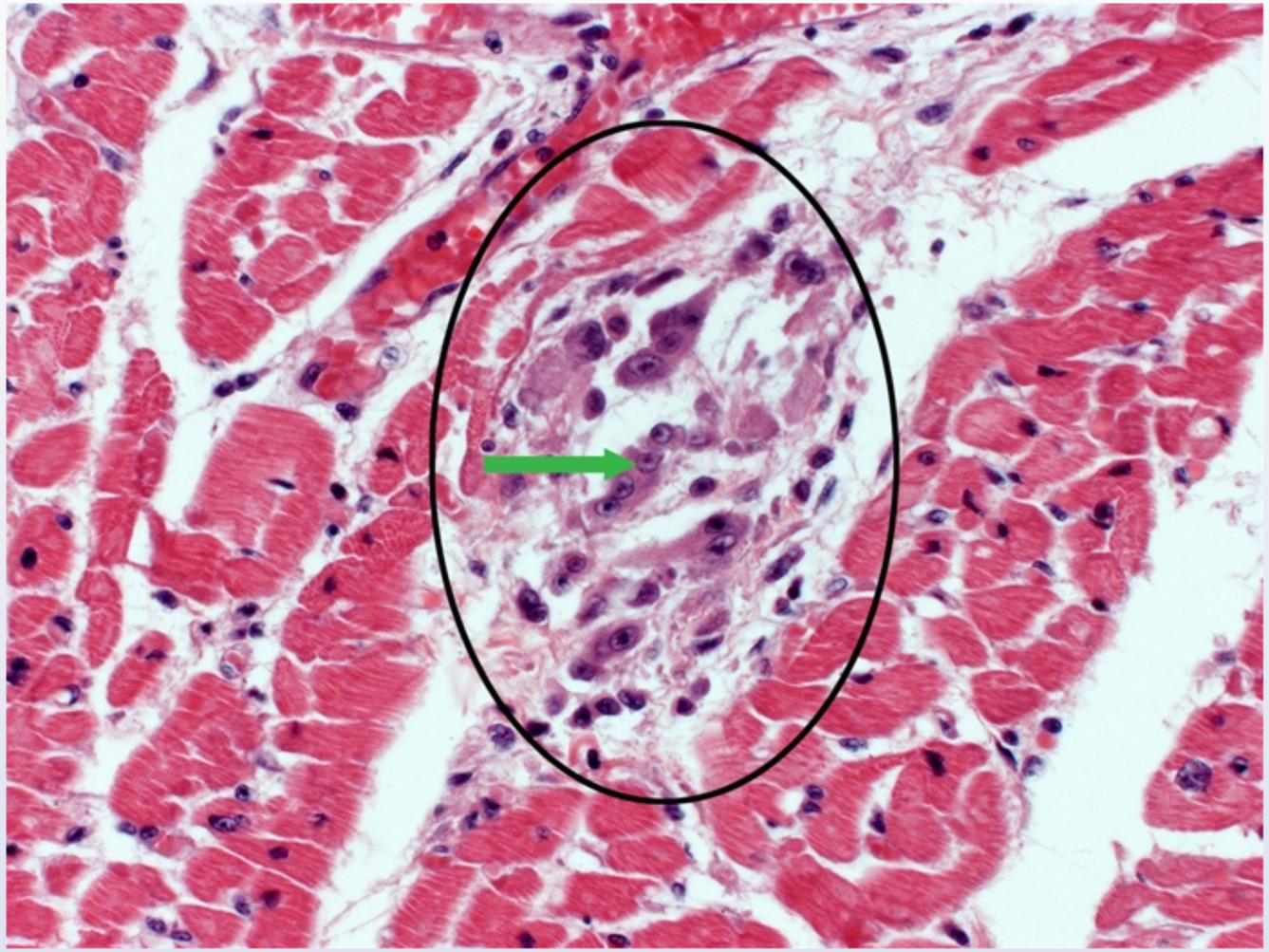

Acute rheumatic fever (ARF) is an immune-mediated complication of an **untreated group A streptococcal pharyngeal infection**. The most serious manifestation of ARF is **pancarditis**, which can cause nonspecific fever, fatigue, and anorexia as well as altered vital signs (tachycardia, tachypnea, hypotension). Endocardial involvement resulting in valvular dysfunction (specifically acute **mitral valve regurgitation**) is the most likely cause of the patient's new **holosystolic murmur**.

1
2
3
4
5
6
7
8
9
10
11
12
13
14
15
16
17
18
19
20
21
22
23
24
25
26
27
28
29

Acute rheumatic fever (ARF) is an immune-mediated complication of an **untreated group A streptococcal pharyngeal infection**. The most serious manifestation of ARF is **pancarditis**, which can cause nonspecific fever, fatigue, and anorexia as well as altered vital signs (tachycardia, tachypnea, hypotension). Endocardial involvement resulting in valvular dysfunction (specifically acute **mitral valve regurgitation**) is the most likely cause of the patient's new **holosystolic murmur**.

This patient's myocardial biopsy shows interstitial fibrosis with central lymphocytes and macrophages as well as scattered multinucleated giant cells (green arrow). This **interstitial myocardial granuloma**, or **Aschoff body** (encircled), is pathognomonic for ARF-related myocarditis. Plump macrophages with abundant cytoplasm and central, slender chromatin ribbons called Anitschkow (or caterpillar) cells are also often present. Over subsequent years, Aschoff bodies are replaced by **fibrous scar tissue**, leading to chronic **mitral valve stenosis** and regurgitation.

(Choice A) Hypersensitivity myocarditis, which results from an autoimmune reaction to a medication, is characterized by an interstitial infiltrate of eosinophils. Many classes of drugs, including diuretics (eg, furosemide, hydrochlorothiazide) and antibiotics (eg, ampicillin, azithromycin), can cause this hypersensitivity.

(Choice C) Anthracyclines (eg, doxorubicin, daunorubicin) are cardiotoxic chemotherapeutic agents. These agents can cause dose-related acute and chronic cardiac damage (eg, dilated cardiomyopathy). On biopsy, patchy fibrosis with vacuolization and lysis of myocytes are evident.

(Choice D) A genetic mutation involving sarcomere genes can lead to the development of hypertrophic cardiomyopathy (HCM). HCM leads to left ventricular hypertrophy and, in turn, both systolic and diastolic dysfunction. The pathology involves disorganized, hypertrophied myocytes.

(Choice E) Recent travel to South America is associated with Chagas disease, which is caused by the protozoan parasite *Trypanosoma cruzi*. Chagas disease can result in a myocarditis characterized by distension of individual myofibers with intracellular trypanosomes.

(Choice F) Viral myocarditis produces a predominantly lymphocytic interstitial infiltrate with focal necrosis of myocytes. Aschoff bodies are not seen. Viral infection (eg, adenovirus, Coxsackie B virus, parvovirus B19) is the most common cause of myocarditis in the general population.

Educational objective:
Interstitial myocardial granulomas (Aschoff bodies) are found in carditis due to acute rheumatic fever, which develops after an untreated group A streptococcal pharyngeal infection. Aschoff bodies contain plump macrophages with abundant cytoplasm and central, slender ribbons of chromatin (Anitschkow, or caterpillar, cells).

1
2
3
4
5
6
7
8
9
10
11
12
13
14
15
16
17
18
19
20
21
22
23
24
25
26
27
28
29

Exhibit Display

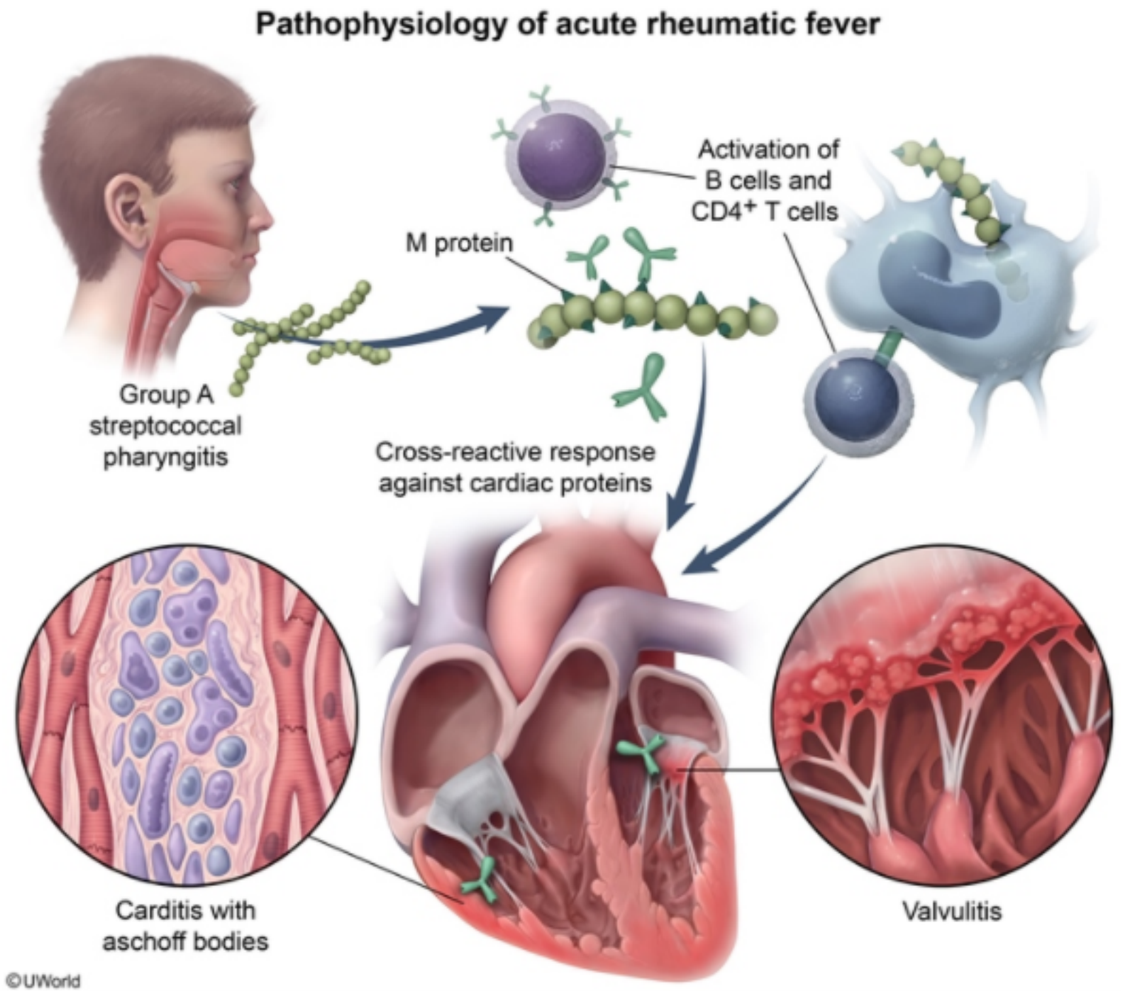

Zoom In | Zoom Out | Reset | Add To New Card | Existing Card

chromatin (Anitschkow, or caterpillar, cells).

1
2
3
4
5
6
7
8
9
10
11
12
13
14
15
16
17
18
19
20
21
22
23
24
25
26
27
28
29

Exhibit Display

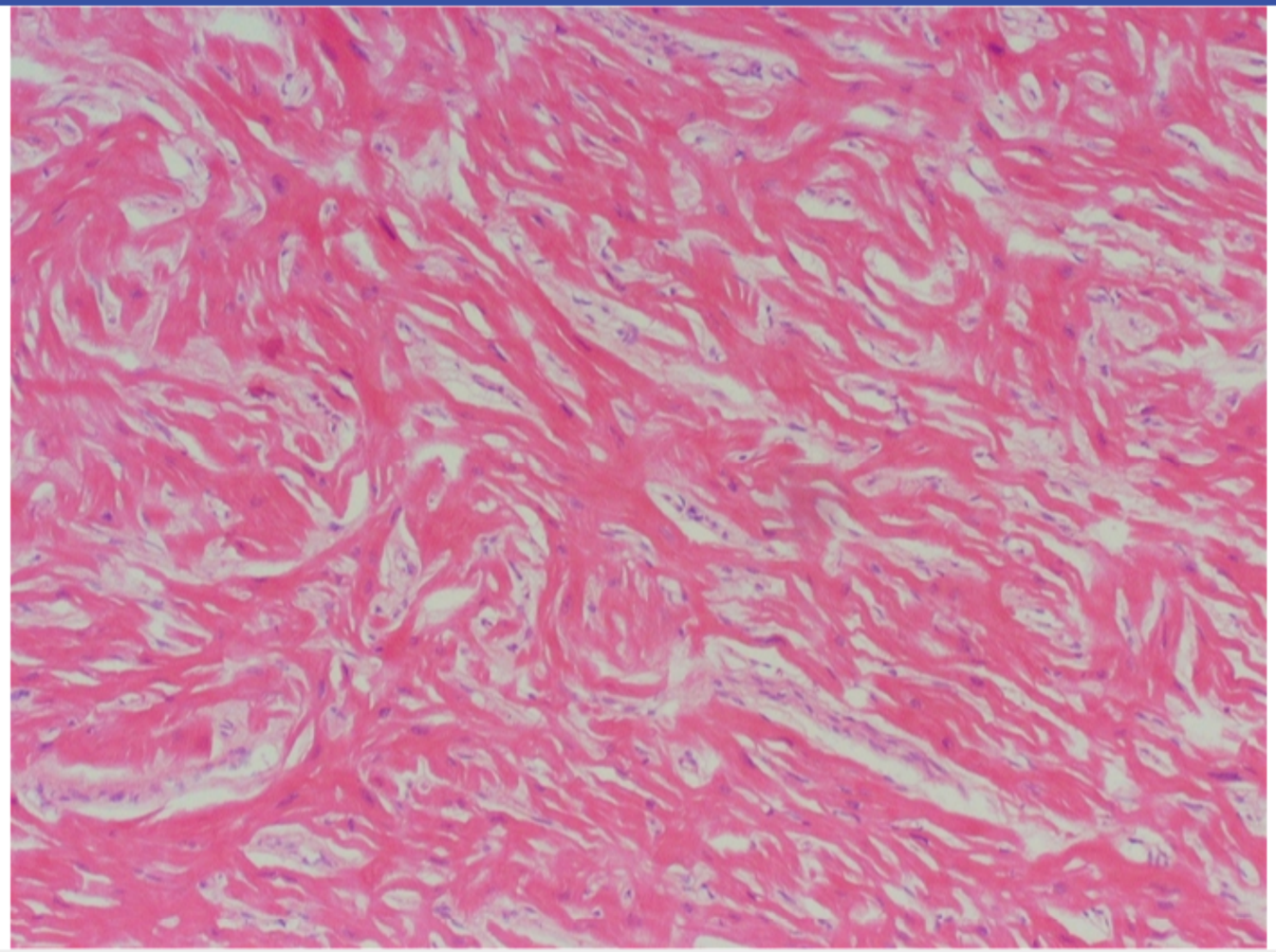

Zoom In | Zoom Out | Reset | Add To New Card | Existing Card

chromatin (Anitschkow, or caterpillar, cells).

1
2
3
4
5
6
7
8
9
10
11
12
13
14
15
16
17
18
19
20
21
22
23
24
25
26
27
28
29

Exhibit Display

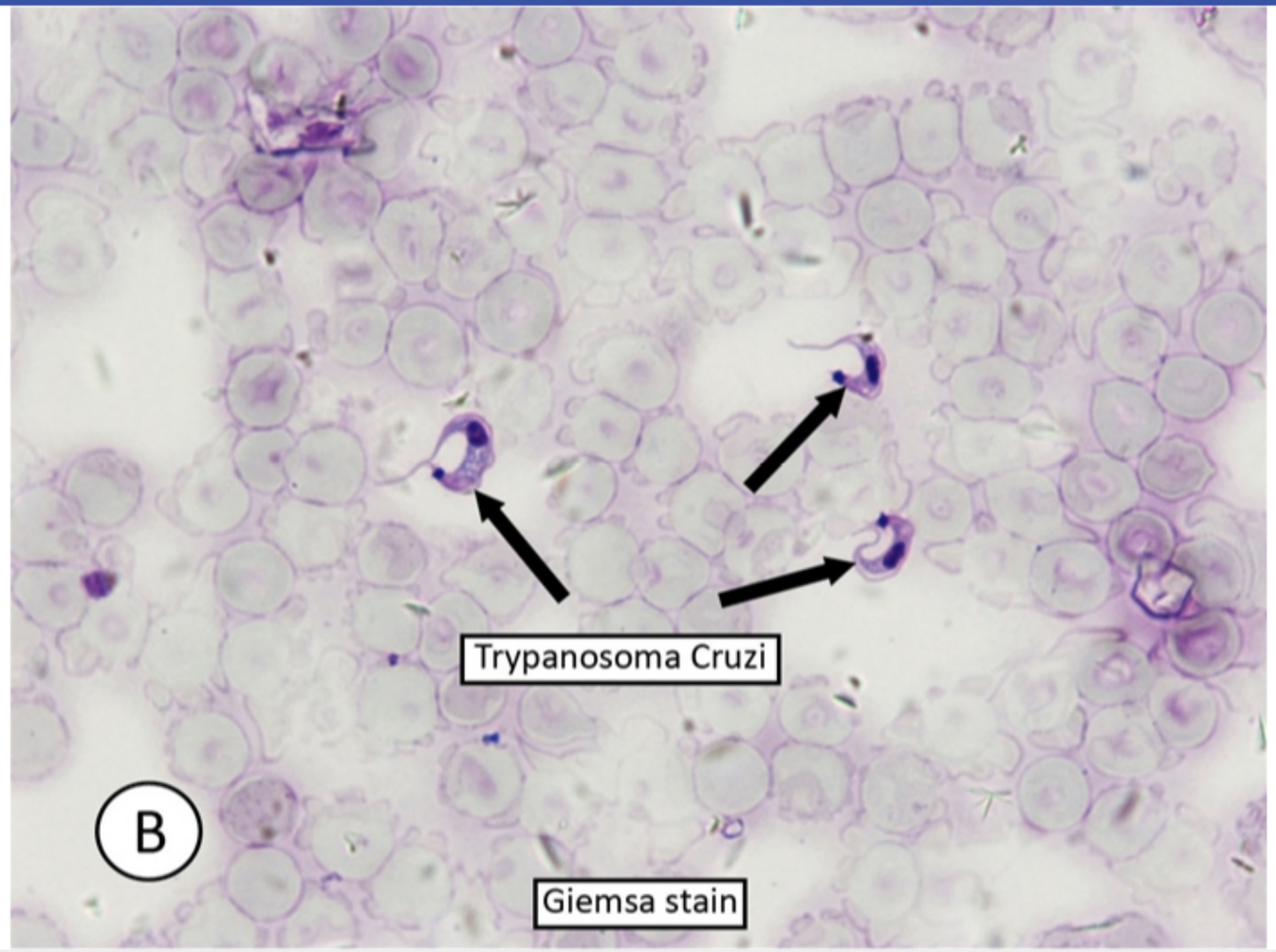

Zoom In Zoom Out Reset Add To New Card | Existing Card

chromatin (Anitschkow, or caterpillar, cells).

subsequent years, Aschoff bodies are replaced by **fibrous scar tissue**, leading to chronic **mitral valve stenosis** and regurgitation.

Exhibit Display

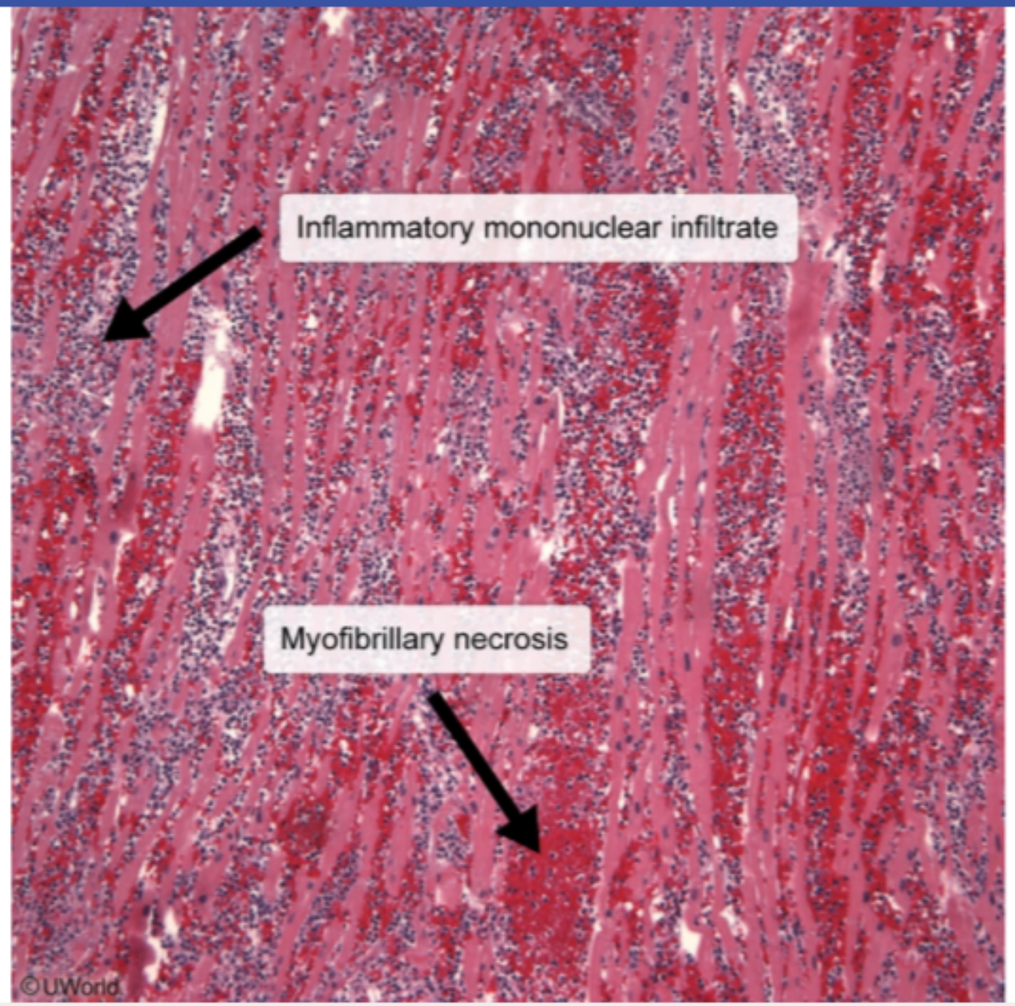

Zoom In | Zoom Out | Reset | Add To New Card | Existing Card

1
2
3
4
5
6
7
8
9
10
11
12
13
14
15
16
17
18
19
20
21
22
23
24
25
26
27
28
29

1
2
3
4
5
6
7
8
9
10
11
12
13
14
15
16
17
18
19
20
21
22
23
24
25
26
27
28
29

A 75-year-old man comes to the office due to worsening dyspnea and fatigue on exertion over the last 6 months. Recently, he has had severe lightheadedness during physical activity. Blood pressure is 125/65 mm Hg and pulse is 65/min and regular. Physical examination reveals a harsh ejection-type systolic murmur at the base of the heart radiating to the neck. The second heart sound is diminished in intensity. A fourth heart sound is heard at the cardiac apex. Which of the following is the most likely cause of this patient's heart condition?

A. Extensive valve calcification with impaired leaflet mobility

B. Fusion of valve commissures due to repetitive inflammation

C. Hypertrophy of the basal interventricular septum with subaortic obstruction

D. Infectious vegetations attached to the valve cusps

E. Myxomatous valve degeneration with leaflet prolapse

Submit

A 75-year-old man comes to the office due to worsening dyspnea and fatigue on exertion over the last 6 months. Recently, he has had severe lightheadedness during physical activity. Blood pressure is 125/65 mm Hg and pulse is 65/min and regular. Physical examination reveals a harsh ejection-type systolic murmur at the base of the heart radiating to the neck. The second heart sound is diminished in intensity. A fourth heart sound is heard at the cardiac apex. Which of the following is the most likely cause of this patient's heart condition?

- ✓ A. Extensive valve calcification with impaired leaflet mobility (77%)
- B. Fusion of valve commissures due to repetitive inflammation (2%)
- C. Hypertrophy of the basal interventricular septum with subaortic obstruction (14%)
- D. Infectious vegetations attached to the valve cusps (1%)
- E. Myxomatous valve degeneration with leaflet prolapse (4%)

Omitted
Correct answer
A

77%
Answered correctly

03 secs
Time Spent

03/03/2020
Last Updated

Explanation

This patient's presentation (fatigue, progressive dyspnea, presyncope with exertion, and a cardiac murmur) is suggestive of **aortic valve stenosis** (AS). In AS, the heart is unable to adequately increase cardiac output during exercise, causing pulmonary vascular congestion and reduced mean arterial pressure. These changes cause dyspnea and lightheadedness, respectively. AS can also chronically lower cardiac output, causing an increased tendency toward fatigue in general. AS murmur is usually a harsh ejection-type systolic murmur heard best at the base of the heart in the "aortic area" (second right intercostal space) with radiation to the carotid arteries. Second heart sound (S2) is diminished in intensity due to reduced mobility of the aortic leaflets, and a fourth heart sound (S4) may be heard due to decreased compliance of the hypertrophic myocardium.

1
2
3
4
5
6
7
8
9
10
11
12
13
14
15
16
17
18
19
20
21
22
23
24
25
26
27
28
29

This patient's presentation (fatigue, progressive dyspnea, presyncope with exertion, and a cardiac murmur) is suggestive of **aortic valve stenosis** (AS). In AS, the heart is unable to adequately increase cardiac output during exercise, causing pulmonary vascular congestion and reduced mean arterial pressure. These changes cause dyspnea and lightheadedness, respectively. AS can also chronically lower cardiac output, causing an increased tendency toward fatigue in general. AS murmur is usually a harsh ejection-type systolic murmur heard best at the base of the heart in the "aortic area" (second right intercostal space) with radiation to the carotid arteries. Second heart sound (S2) is diminished in intensity due to reduced mobility of the aortic leaflets, and a fourth heart sound (S4) may be heard due to decreased compliance of the hypertrophic myocardium.

Calcific degeneration of the trileaflet aortic valve is the most common cause of valvular AS in developed nations. AS is characterized by progressive aortic valve leaflet thickening and calcification, leading to restricted leaflet excursion and mobility. Congenital heart disease, such as bicuspid aortic valve, can also lead to AS due to accelerated valve degeneration. On the other hand, rheumatic valve disease is a common cause of AS in developing nations and is characterized by fusion of valve commissures due to repetitive inflammation **(Choice B)**. Rheumatic valve disease usually presents at an earlier age and involves the mitral valve as well.

(Choice C) Hypertrophy of the basal interventricular septum with subaortic obstruction is the pathophysiologic process in patients with hypertrophic cardiomyopathy. Physical examination reveals a harsh crescendo-decrescendo murmur heard best at the apex and lower sternal border. The murmur does not radiate to the neck, and S2 is usually normal.

(Choice D) Infective endocarditis can lead to aortic regurgitation (AR) due to inadequate coaptation of the aortic leaflets. AR murmur is an early, decrescendo, high-pitched, blowing diastolic murmur that begins immediately after A2. It is best heard along the left sternal border at the third and fourth intercostal spaces.

(Choice E) Myxomatous degeneration of the mitral valve leaflets leads to mitral valve prolapse. Cardiac auscultation usually reveals a non-ejection click and mid-to-late systolic murmur of mitral regurgitation.

Educational objective:
Calcific degeneration of the trileaflet aortic valve is the most common cause of aortic stenosis (AS) in developed nations. AS is characterized by progressive aortic valve leaflet thickening and calcification, leading to restricted leaflet excursion and mobility. AS murmur is usually a harsh ejection-type systolic murmur heard best at the base of the heart in the "aortic area" (second right intercostal space) with radiation to the carotid arteries.

1
2
3
4
5
6
7
8
9
10
11
12
13
14
15
16
17
18
19
20
21
22
23
24
25
26
27
28
29

A 50-year-old man is brought to the emergency department due to chest pain. He passed out briefly after the pain started. Medical history includes hypertension, hyperlipidemia, and early-stage chronic kidney disease. The patient reports that his father had a heart attack at a young age. Despite treatment, the patient dies during hospitalization. An autopsy is performed. Light microscopy of the aortic wall is shown on the slide below.

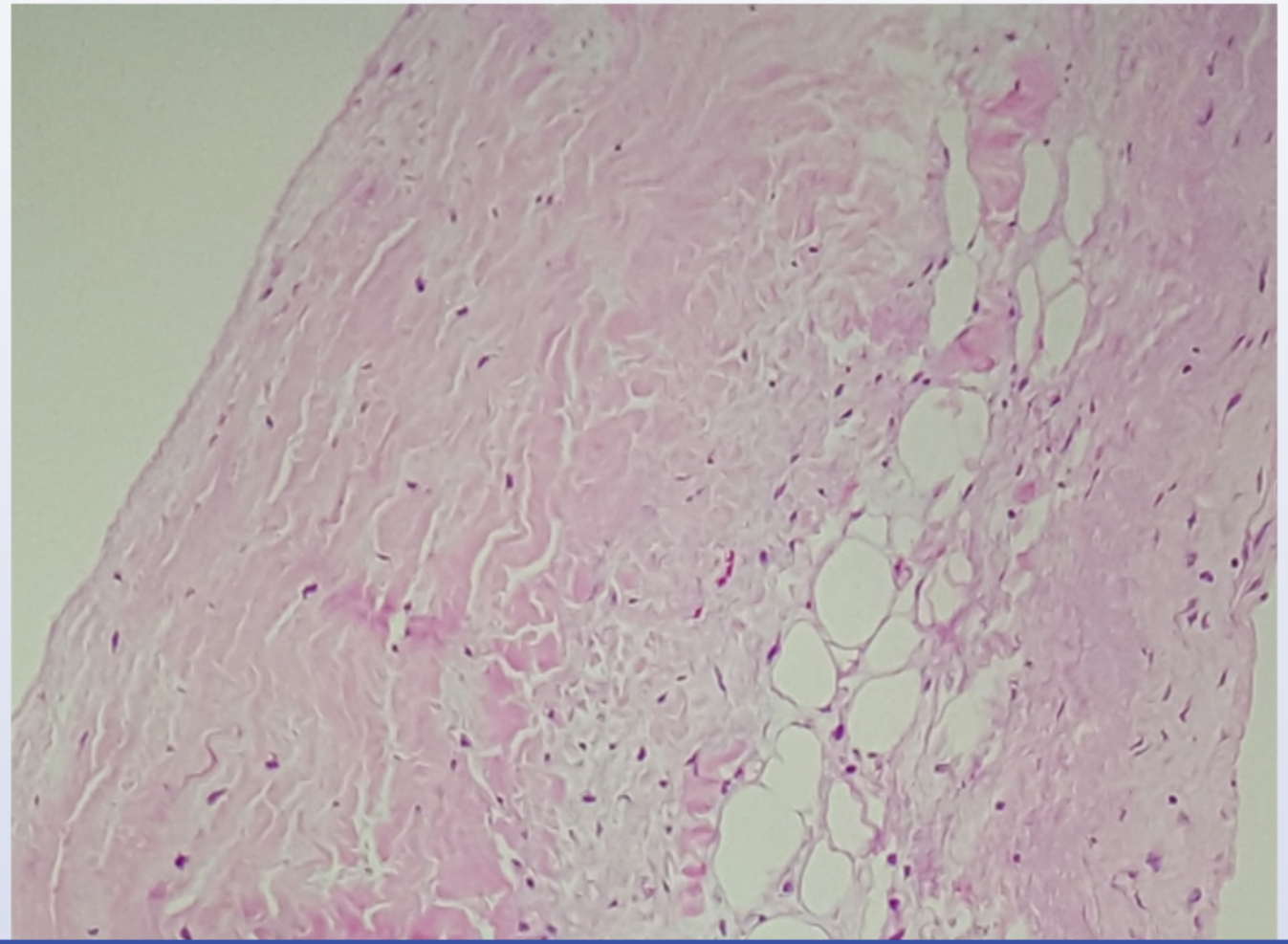

1
2
3
4
5
6
7
8
9
10
11
12
13
14
15
16
17
18
19
20
21
22
23
24
25
26
27
28
29

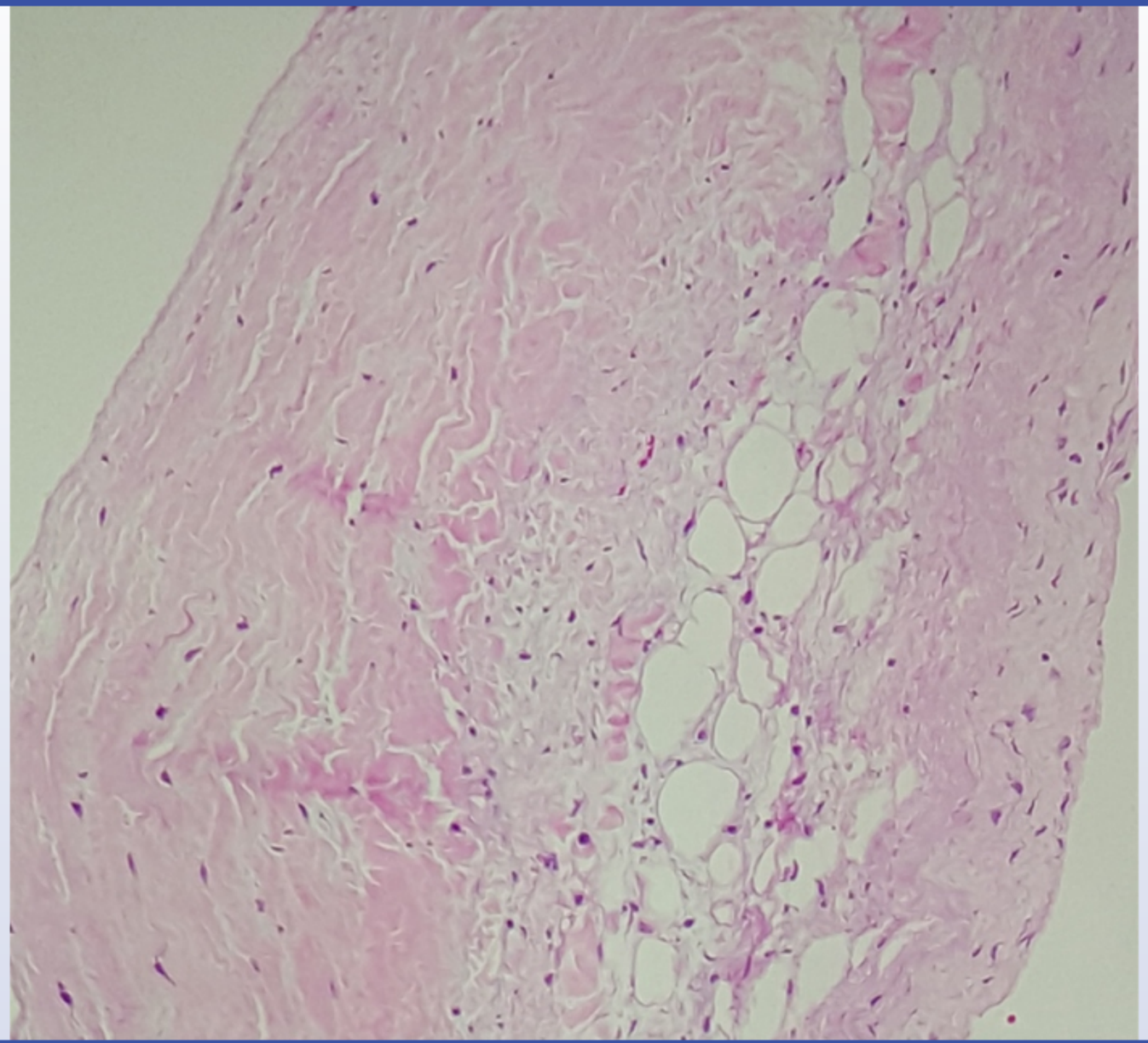

1
2
3
4
5
6
7
8
9
10
11
12
13
14
15
16
17
18
19
20
21
22
23
24
25
26
27
28
29

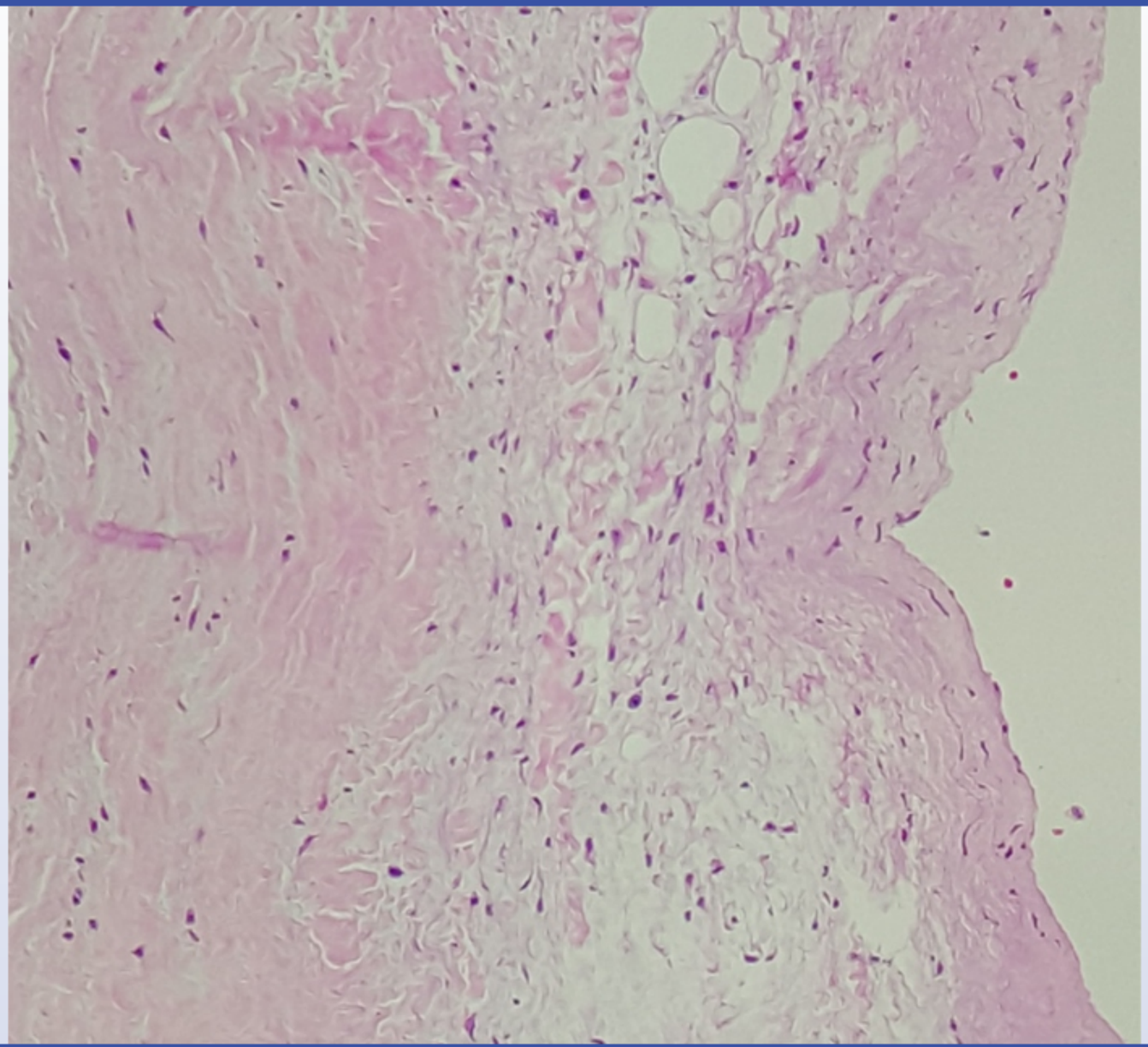

1
2
3
4
5
6
7
8
9
10
11
12
13
14
15
16
17
18
19
20
21
22
23
24
25
26
27
28
29

Exhibit Display

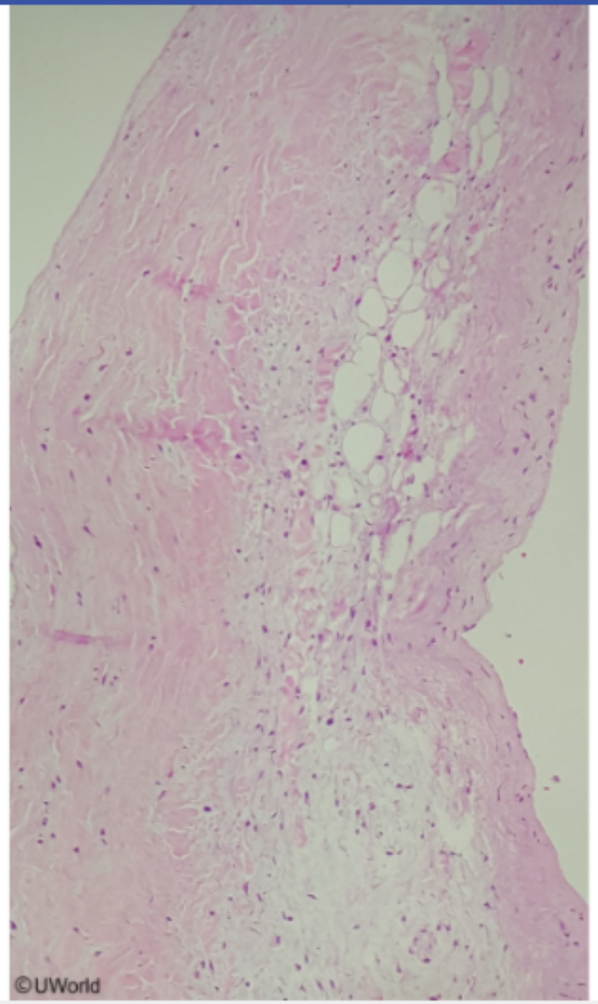

Zoom In
Zoom Out
Reset
Add To New Card | Existing Card

1
2
3
4
5
6
7
8
9
10
11
12
13
14
15
16
17
18
19
20
21
22
23
24
25
26
27
28
29

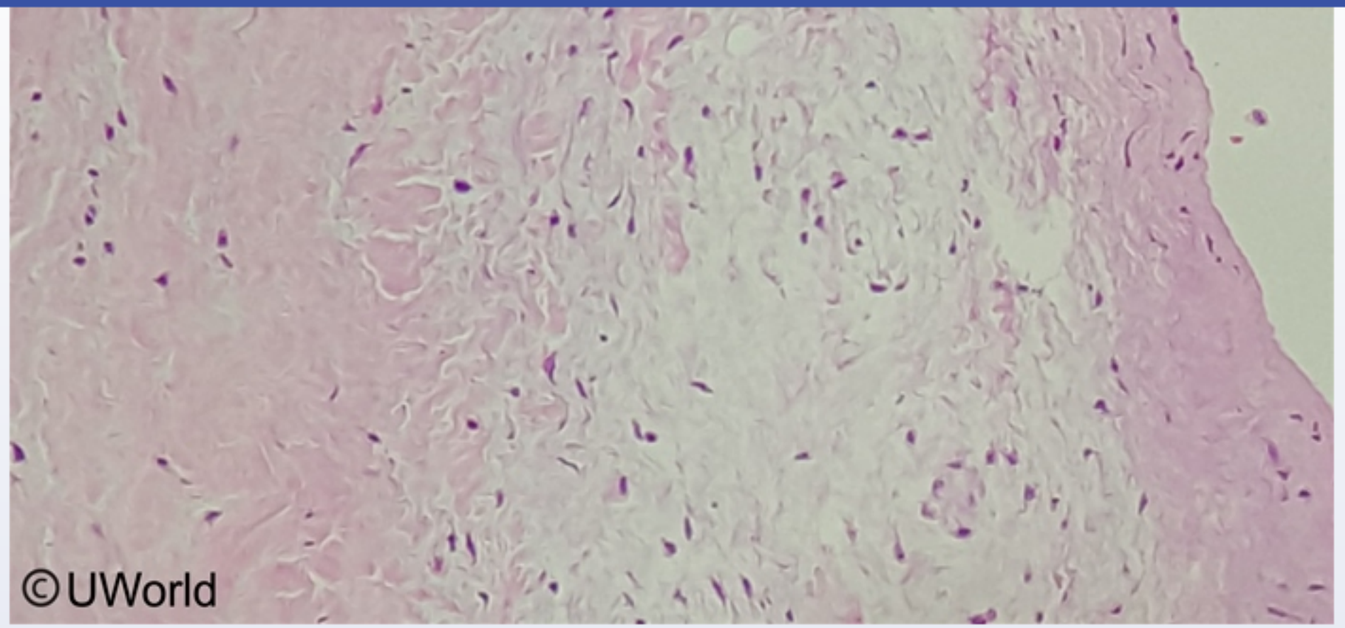

Which of the following underlying mechanisms is most likely responsible for this patient's disease process?

- A. Atherosclerosis
- B. Calciphylaxis
- C. Cystic degeneration of the media
- D. Granulomatous inflammation
- E. Monckeberg sclerosis

Submit

1
2
3
4
5
6
7
8
9
10
11
12
13
14
15
16
17
18
19
20
21
22
23
24
25
26
27
28
29

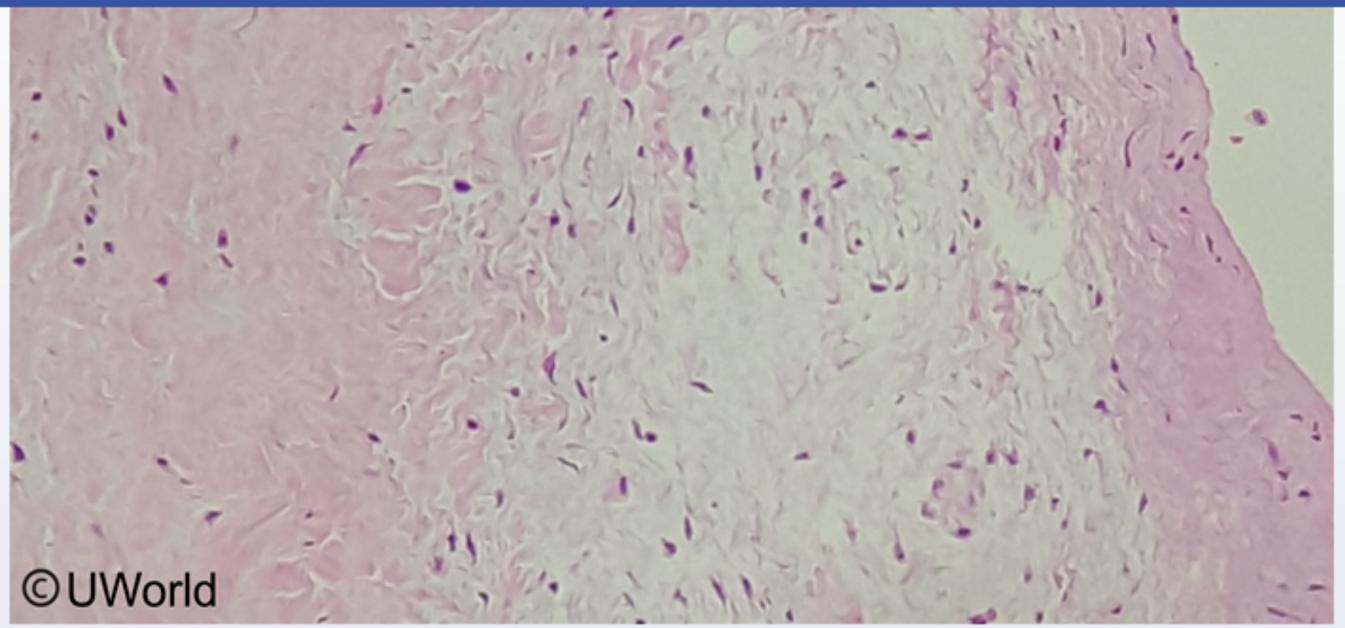

Which of the following underlying mechanisms is most likely responsible for this patient's disease process?

- A. Atherosclerosis (30%)
- B. Calciphylaxis (1%)
- ✓ C. Cystic degeneration of the media (63%)
- D. Granulomatous inflammation (1%)
- E. Monckeberg sclerosis (4%)

Omitted
Correct answer

63%
Answered correctly

14 secs
Time Spent

05/03/2020
Last Updated

1
2
3
4
5
6
7
8
9
10
11
12
13
14
15
16
17
18
19
20
21
22
23
24
25
26
27
28
29

Marfan syndrome (cystic medial degeneration)

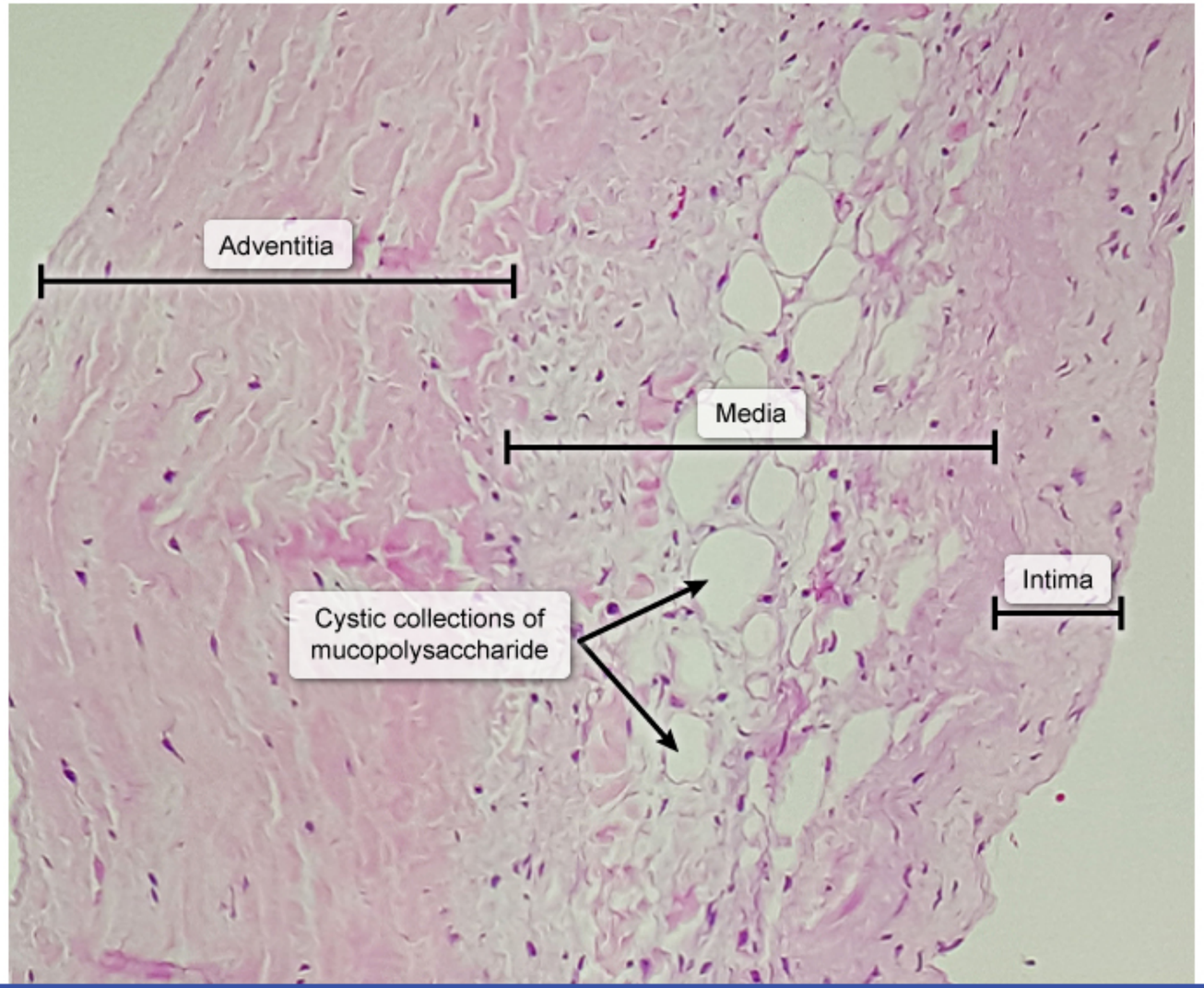

1
2
3
4
5
6
7
8
9
10
11
12
13
14
15
16
17
18
19
20
21
22
23
24
25
26
27
28
29

The above autopsy image shows **cystic medial degeneration** (necrosis), the classic histologic finding in **aortic dissection**. The tunica media is the largest and strongest of the 3 portions of the aortic wall. With aging, collagen, elastin, and smooth muscle in the aortic media are broken down and replaced by a mucoid extracellular matrix. There is elastic tissue fragmentation in a "basket weave" pattern with development of many cystic collections of mucopolysaccharide. These changes result in progressive **loss of integrity**, reducing the vessel's ability to handle wall stress from conditions such as systemic hypertension.

Once cystic medial degeneration develops, a **small intimal tear** can readily **extend** into and throughout the media, creating a lengthy **dissection plane** that propagates proximally or distally. As blood enters the dissection plane a false aortic lumen is created and aortic branches (eg, left subclavian artery, renal arteries) may become obstructed. The enlarging hematoma in the false lumen can eventually penetrate the adventitia, resulting in full-thickness rupture.

(Choice A) Atherosclerosis primarily affects the intima and is an important contributor to acute coronary syndrome. Histologically it appears as an atheroma with an endothelial covering, fibrous cap, and necrotic core. Atherosclerosis can contribute to cystic medial degeneration but is not the primary pathophysiologic mechanism.

(Choice B) Calcific uremic arteriolopathy (calciphylaxis) can occur with advanced chronic kidney disease and leads to severe skin ischemia and necrosis. Histologically, it is characterized by superficial arteriolar calcification, subintimal fibrosis, and thrombosis. It does not typically affect large vessels such as the aorta.

(Choice D) Granulomatous inflammation of large vessels can occur in Takayasu arteritis and tuberculous aortitis. Histopathology demonstrates granuloma formation in the media with multinucleated giant cells.

(Choice E) Monckeberg sclerosis is a rare disease that results in diffuse medial calcification of small and medium-sized arteries. Calcification typically appears as blue-to-violet irregular deposits on hematoxylin–eosin stains, as seen in this calcified atherosclerotic plaque.

Educational objective:
Cystic medial degeneration (necrosis) is the classic histologic finding in aortic dissection, as it weakens the aortic wall and allows a small intimal tear to readily propagate. Collagen, elastin, and smooth muscle are replaced by a basophilic mucoid extracellular matrix with elastic tissue fragmentation and cystic collections of mucopolysaccharide.

References

- Impact of connective tissue disease on the surgical outcomes of aortic dissection in patients with cystic medial necrosis.

1
2
3
4
5
6
7
8
9
10
11
12
13
14
15
16
17
18
19
20
21
22
23
24
25
26
27
28
29

mucopolysaccharide

Exhibit Display

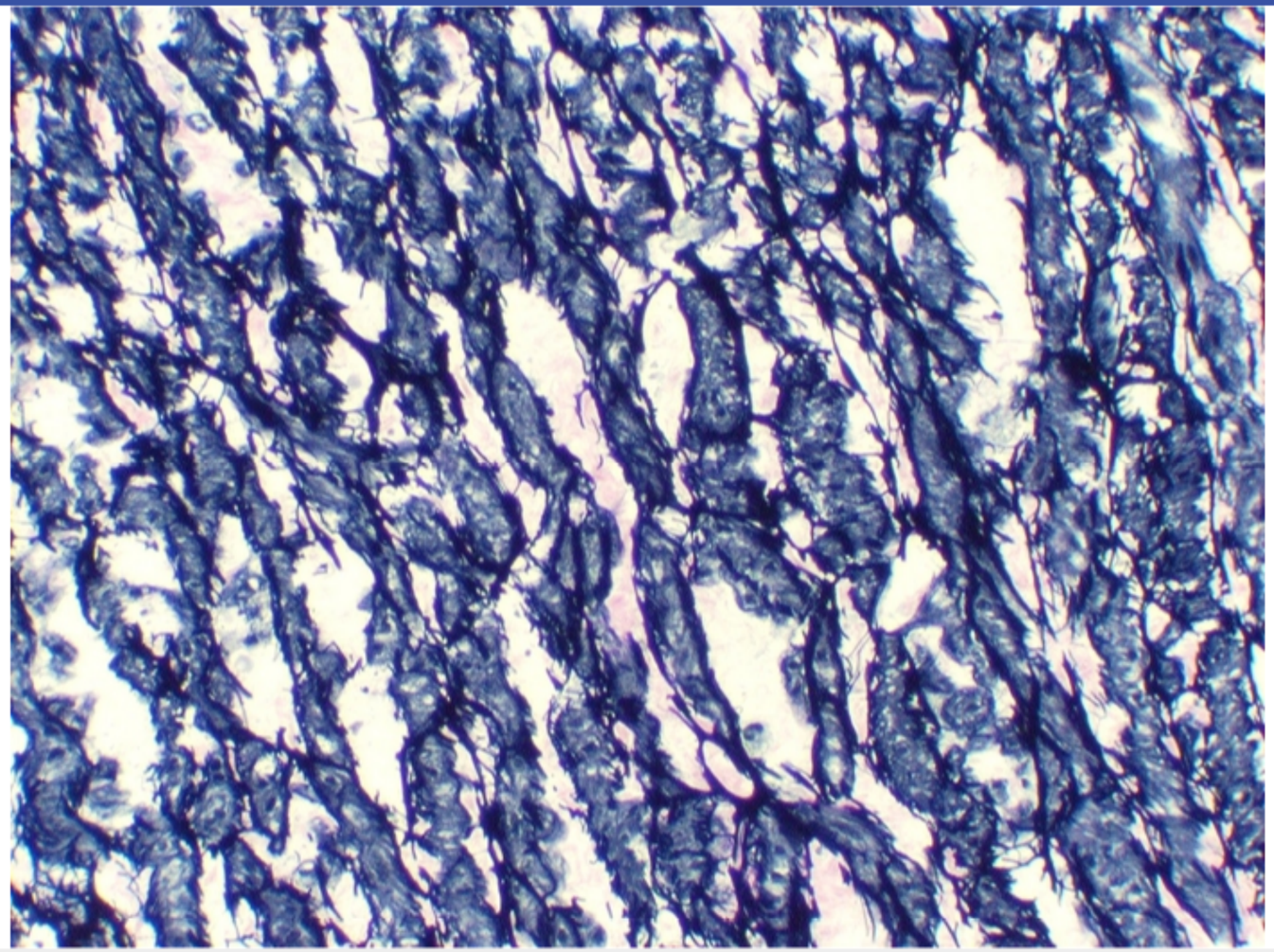

Zoom In Zoom Out Reset Add To New Card | Existing Card

(Choice D) Granulomatous inflammation of large vessels can occur in Takayasu arteritis and tuberculous aortitis. Histopathology demonstrates

mucopolysaccharide

Exhibit Display

Cystic medial degeneration of aorta Aortic dissection and cystic medial degeneration.

Cystic medial degeneration of aorta

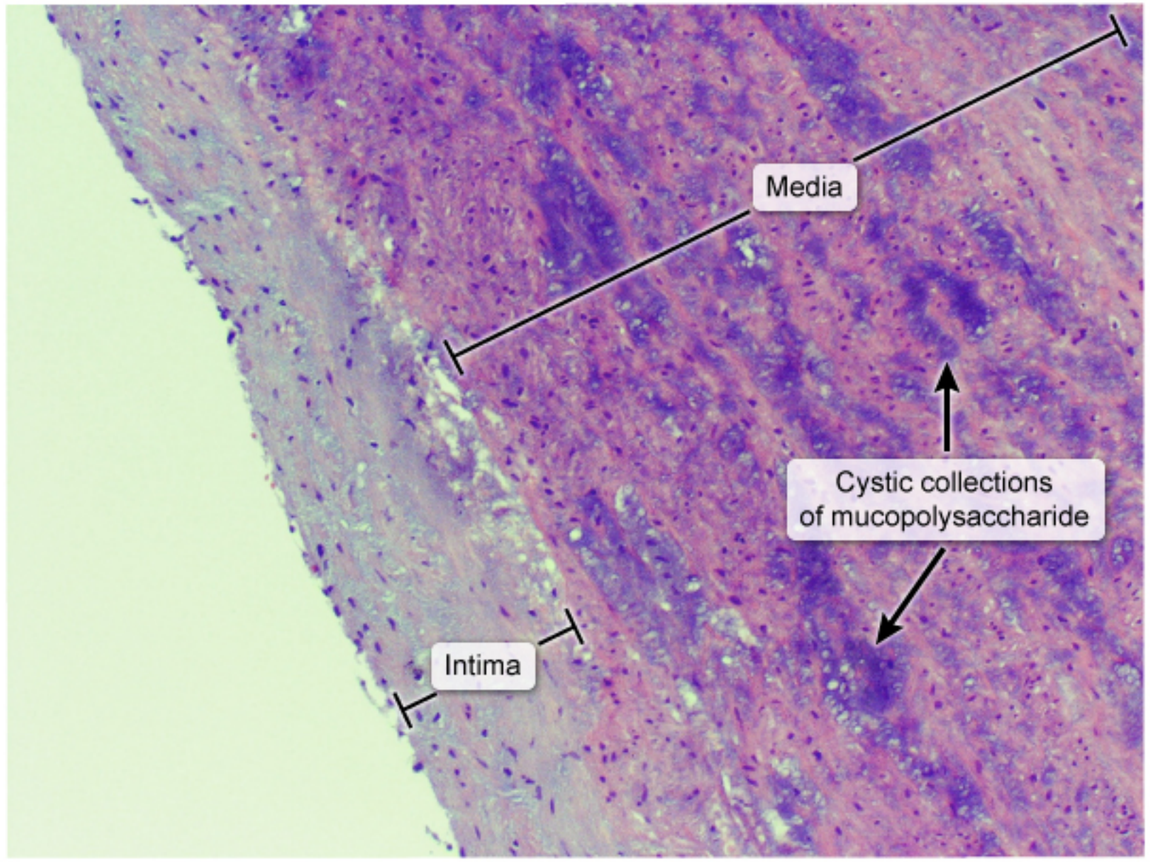

Zoom In Zoom Out Reset Add To New Card | Existing Card

(Choice D) Granulomatous inflammation of large vessels can occur in Takayasu arteritis and tuberculous aortitis. Histopathology demonstrates

mucopolysaccharide

Exhibit Display

Cystic medial degeneration of aorta Aortic dissection and cystic medial degeneration.

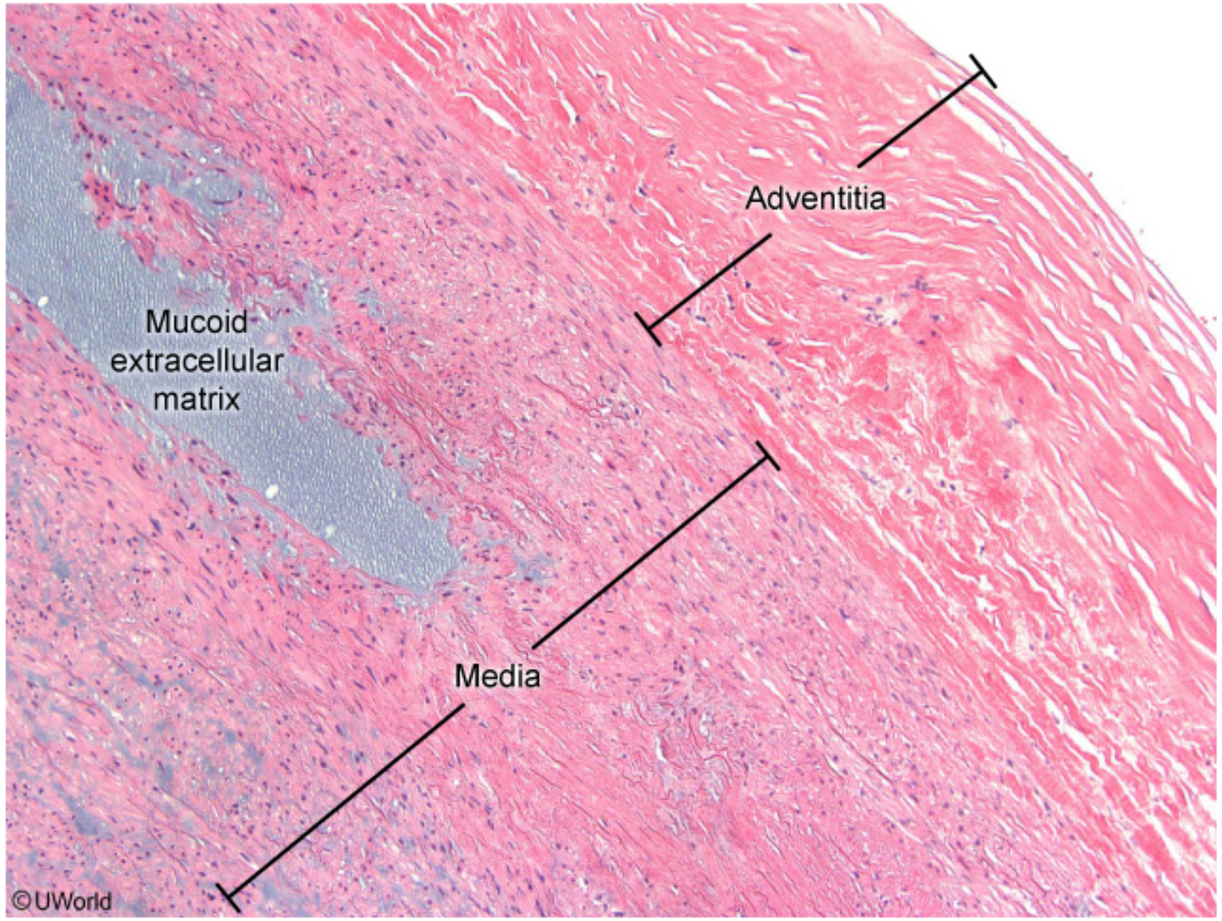

Zoom In Zoom Out Reset Add To New Card | Existing Card

(Choice D) Granulomatous inflammation of large vessels can occur in Takayasu arteritis and tuberculous aortitis. Histopathology demonstrates

1
2
3
4
5
6
7
8
9
10
11
12
13
14
15
16
17
18
19
20
21
22
23
24
25
26
27
28
29

collections of mucopolysaccharide. These changes result in progressive **loss of integrity**, reducing the vessel's ability to handle wall stress from conditions such as systemic hypertension.

Exhibit Display

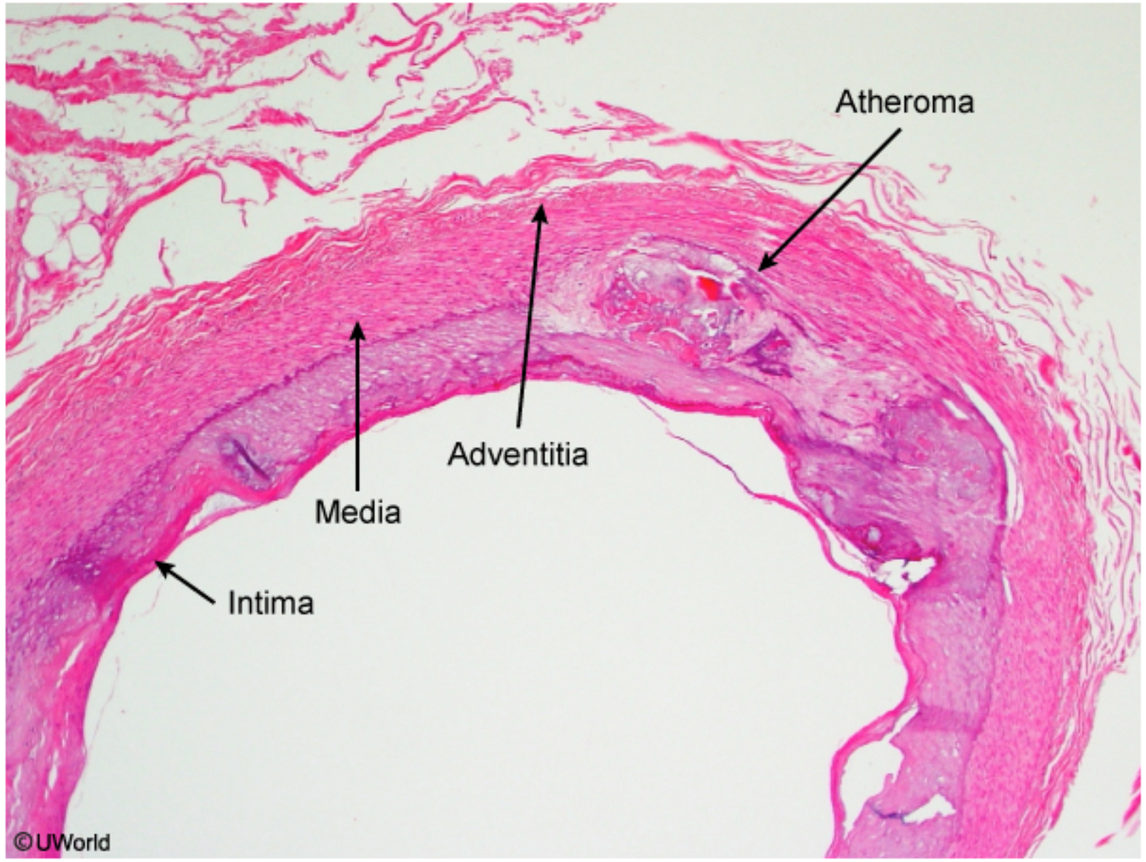

Zoom In | Zoom Out | Reset | Add To New Card | Existing Card

1
2
3
4
5
6
7
8
9
10
11
12
13
14
15
16
17
18
19
20
21
22
23
24
25
26
27
28
29

collections of mucopolysaccharide. These changes result in progressive **loss of integrity**, reducing the vessel's ability to handle wall stress from conditions such as systemic hypertension.

Exhibit Display

Calcific atherosclerosis

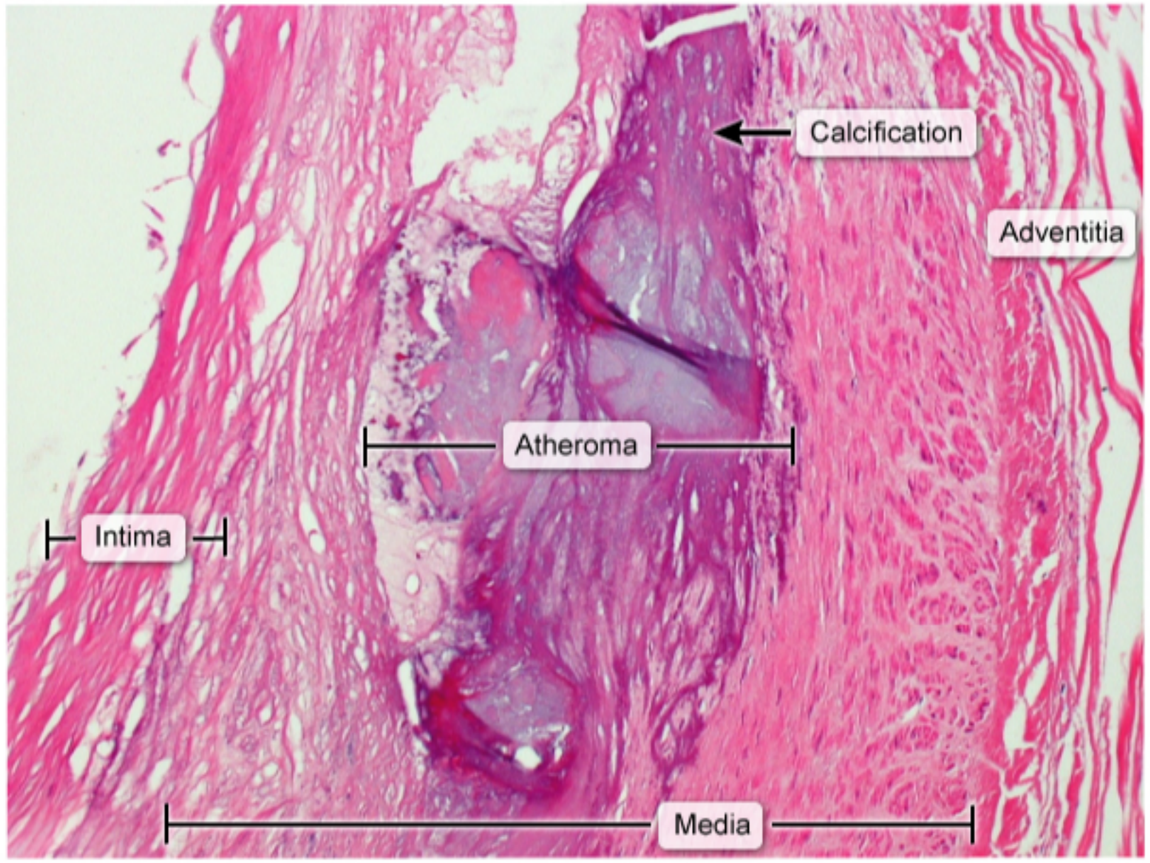

©UWorld

Zoom In | Zoom Out | Reset | Add To New Card | Existing Card

Pathology | Cardiovascular System | Aortic dissection

1
2
3
4
5
6
7
8
9
10
11
12
13
14
15
16
17
18
19
20
21
22
23
24
25
26
27
28
29

A 42-year-old woman comes to the emergency department for evaluation of chest pain. She was moving furniture in her summer house 2 days ago when she experienced sharp pain in the left side of the sternum that quickly subsided. Since then, the patient has had episodic pain with deep inspiration or trunk movement. She has no fever or cough. The patient has a history of hypertension. Her father died of myocardial infarction at age 67. She does not use tobacco or illicit drugs. Blood pressure is 146/85 mm Hg in the right arm and 142/80 mm Hg in the left arm, pulse is 86/min, and respirations are 12/min. She has localized tenderness to palpation at the left sternal border. Lungs are clear to auscultation, and cardiac examination reveals normal heart sounds without gallops or murmurs. The abdomen is soft and nontender. There is no peripheral edema. Which of the following is the most likely cause of this patient's symptoms?

- A. Acute pericarditis
- B. Aortic dissection
- C. Costochondritis
- D. Esophageal spasm
- E. Gastroesophageal reflux disease
- F. Panic disorder
- G. Pneumonia
- H. Pulmonary arterial hypertension
- I. Pulmonary embolism
- J. Unstable angina

Submit

1
2
3
4
5
6
7
8
9
10
11
12
13
14
15
16
17
18
19
20
21
22
23
24
25
26
27
28
29

A 42-year-old woman comes to the emergency department for evaluation of chest pain. She was moving furniture in her summer house 2 days ago when she experienced sharp pain in the left side of the sternum that quickly subsided. Since then, the patient has had episodic pain with deep inspiration or trunk movement. She has no fever or cough. The patient has a history of hypertension. Her father died of myocardial infarction at age 67. She does not use tobacco or illicit drugs. Blood pressure is 146/85 mm Hg in the right arm and 142/80 mm Hg in the left arm, pulse is 86/min, and respirations are 12/min. She has localized tenderness to palpation at the left sternal border. Lungs are clear to auscultation, and cardiac examination reveals normal heart sounds without gallops or murmurs. The abdomen is soft and nontender. There is no peripheral edema. Which of the following is the most likely cause of this patient's symptoms?

- A. Acute pericarditis (8%)
- B. Aortic dissection (8%)
- ✓ C. Costochondritis (73%)
- D. Esophageal spasm (0%)
- E. Gastroesophageal reflux disease (0%)
- F. Panic disorder (0%)
- G. Pneumonia (0%)
- H. Pulmonary arterial hypertension (1%)
- I. Pulmonary embolism (1%)
- J. Unstable angina (5%)

Omitted
Correct answer
C

73%
Answered correctly

03 secs
Time Spent

01/23/2020
Last Updated

1
2
3
4
5
6
7
8
9
10
11
12
13
14
15
16
17
18
19
20
21
22
23
24
25
26
27
28
29

Differential diagnosis & features of chest pain	
Coronary artery disease	• Substernal • Radiation to arm, shoulder, or jaw • Precipitated by **exertion** • Relieved by **rest or nitroglycerin**
Pulmonary/pleuritic (pleurisy, pneumonia, pericarditis, PE)	• Sharp/stabbing pain • Worse with inspiration • **Pericarditis:** worse when lying flat • **PE**, **pneumothorax:** respiratory distress, hypoxia
Aortic (dissection, intramural hematoma)	• **Sudden**, **severe** "tearing" pain • Radiates to **back** • Elderly men • Hypertension & risk factors for atherosclerosis
Gastrointestinal/esophageal	• Nonexertional, relieved by antacids • Upper abdominal & substernal • Associated with regurgitation, nausea, dysphagia • **Nocturnal pain**
Chest wall/musculoskeletal	• Persistent &/or prolonged pain • Worse with movement or change in position • Often follows **repetitive activity**

PE = pulmonary embolism.

This patient's chest pain is most likely due to **costosternal syndrome** (also known as costochondritis or anterior chest wall syndrome) involving the regional chest wall. It usually occurs after repetitive activity and involves the upper costal cartilage at the costochondral or costosternal

1
2
3
4
5
6
7
8
9
10
11
12
13
14
15
16
17
18
19
20
21
22
23
24
25
26
27
28
29

PE = pulmonary embolism.

This patient's chest pain is most likely due to **costosternal syndrome** (also known as costochondritis or anterior chest wall syndrome) involving the regional chest wall. It usually occurs after repetitive activity and involves the upper costal cartilage at the costochondral or costosternal junctions. The pain is typically **reproduced with palpation** and worsened with movement or changes in position (eg, horizontal arm flexion). Patients typically do not have palpable warmth, swelling, or erythema.

(Choices A, G, and I) Conditions causing inflammation of the pleura or pericardium can cause sharp pain worsened with inspiration. Pericarditis often follows an upper respiratory viral syndrome. The pain of pericarditis is typically worse when lying flat and relieved by leaning forward. Examination may show a pericardial friction rub. Pulmonary embolism can cause pleural inflammation with chest pain. However, such cases are typically due to large emboli and are associated with significant hypoxia and shortness of breath. Pneumonia usually presents with fever, cough, and shortness of breath. None of these conditions would be associated with focal tenderness of the chest wall.

(Choice B) Aortic dissection causes sudden, tearing chest pain radiating to the back and blood pressure disparity between the arms. This patient's episodic pain makes this less likely. Blood pressure will normally vary mildly between arms; a difference in systolic or diastolic blood pressure <10 mm Hg is not considered significant.

(Choices D and E) Gastroesophageal reflux disease typically causes postprandial or nocturnal burning pain in the upper abdomen and chest. Esophageal spasm can cause chest pain with meals or swallowing.

(Choice F) Panic disorder is usually a diagnosis of exclusion and can present with episodic chest pain, shortness of breath, and palpitations. Patients usually have intense fear/anxiety, and chest wall tenderness is not seen.

(Choice H) Pulmonary arterial hypertension usually presents with exertional dyspnea, lethargy, and fatigue. Other symptoms, such as exertional chest pain, syncope, and peripheral edema, are generally seen in advanced disease.

(Choice J) Unstable angina is characterized by exertional chest pressure, often radiating to the arm or jaw. Local chest tenderness does not rule out a cardiac cause of chest pain but is unusual.

Educational objective:
Costosternal syndrome (costochondritis) usually occurs after repetitive activity and is characterized by pain that is reproducible with palpation and worsened with movement or changes in position.

Examination may show a pericardial friction rub. Pulmonary embolism can cause pleural inflammation with chest pain. However, such cases are typically due to large emboli and are associated with significant hypoxia and shortness of breath. Pneumonia usually presents with fever, cough, and shortness of breath. None of these conditions would be associated with focal tenderness of the chest wall.

(Choice B) Aortic dissection causes sudden, tearing chest pain radiating to the back and blood pressure disparity between the arms. This patient's episodic pain makes this less likely. Blood pressure will normally vary mildly between arms; a difference in systolic or diastolic blood pressure <10 mm Hg is not considered significant.

(Choices D and E) Gastroesophageal reflux disease typically causes postprandial or nocturnal burning pain in the upper abdomen and chest. Esophageal spasm can cause chest pain with meals or swallowing.

(Choice F) Panic disorder is usually a diagnosis of exclusion and can present with episodic chest pain, shortness of breath, and palpitations. Patients usually have intense fear/anxiety, and chest wall tenderness is not seen.

(Choice H) Pulmonary arterial hypertension usually presents with exertional dyspnea, lethargy, and fatigue. Other symptoms, such as exertional chest pain, syncope, and peripheral edema, are generally seen in advanced disease.

(Choice J) Unstable angina is characterized by exertional chest pressure, often radiating to the arm or jaw. Local chest tenderness does not rule out a cardiac cause of chest pain but is unusual.

Educational objective:
Costosternal syndrome (costochondritis) usually occurs after repetitive activity and is characterized by pain that is reproducible with palpation and worsened with movement or changes in position.

References

- Costochondritis: diagnosis and treatment.

Pathology	Cardiovascular System	Costochondritis
Subject	System	Topic

Copyright © UWorld. All rights reserved.

1
2
3
4
5
6
7
8
9
10
11
12
13
14
15
16
17
18
19
20
21
22
23
24
25
26
27
28
29

A 27-year-old man comes to the emergency department due to acute-onset chest pain and shortness of breath. The pain started suddenly an hour ago while he was lifting a box of books. The patient has no chronic medical conditions, and he was in his usual state of health prior to the onset of symptoms. He does not use tobacco, alcohol, or illicit drugs. Height is 182 cm (71.7 in) and weight is 72 kg (158.7 lb). On physical examination, the patient is in acute respiratory distress. Temperature is 37 C (98.6 F), blood pressure is 90/60 mm Hg, pulse is 120/min and regular, and respirations are 26/min. Pulse oximetry shows 86% saturation on room air. Cardiopulmonary examination reveals pectus excavatum, bilateral pulmonary crackles, and a decrescendo diastolic murmur at the right upper sternal border. The abdomen is soft and nontender. There is no peripheral edema. Subsequently, the patient develops cardiac arrest and dies. Which of the following histologic changes is most likely to be seen on autopsy?

A. Atherosclerotic thickening of the intima

B. Coagulative necrosis of the left ventricular wall

C. Fragmentation of the elastic lamellae in the aortic media

D. Necrosis of the papillary muscles

E. Perivascular inflammation around the vasa vasorum

Submit

A 27-year-old man comes to the emergency department due to acute-onset chest pain and shortness of breath. The pain started suddenly an hour ago while he was lifting a box of books. The patient has no chronic medical conditions, and he was in his usual state of health prior to the onset of symptoms. He does not use tobacco, alcohol, or illicit drugs. Height is 182 cm (71.7 in) and weight is 72 kg (158.7 lb). On physical examination, the patient is in acute respiratory distress. Temperature is 37 C (98.6 F), blood pressure is 90/60 mm Hg, pulse is 120/min and regular, and respirations are 26/min. Pulse oximetry shows 86% saturation on room air. Cardiopulmonary examination reveals pectus excavatum, bilateral pulmonary crackles, and a decrescendo diastolic murmur at the right upper sternal border. The abdomen is soft and nontender. There is no peripheral edema. Subsequently, the patient develops cardiac arrest and dies. Which of the following histologic changes is most likely to be seen on autopsy?

- A. Atherosclerotic thickening of the intima (1%)
- B. Coagulative necrosis of the left ventricular wall (2%)
- ✓ C. Fragmentation of the elastic lamellae in the aortic media (87%)
- D. Necrosis of the papillary muscles (3%)
- E. Perivascular inflammation around the vasa vasorum (4%)

Omitted
Correct answer
C

87%
Answered correctly

03 secs
Time Spent

04/03/2020
Last Updated

Explanation

Aortic wall

1
2
3
4
5
6
7
8
9
10
11
12
13
14
15
16
17
18
19
20
21
22
23
24
25
26
27
28
29

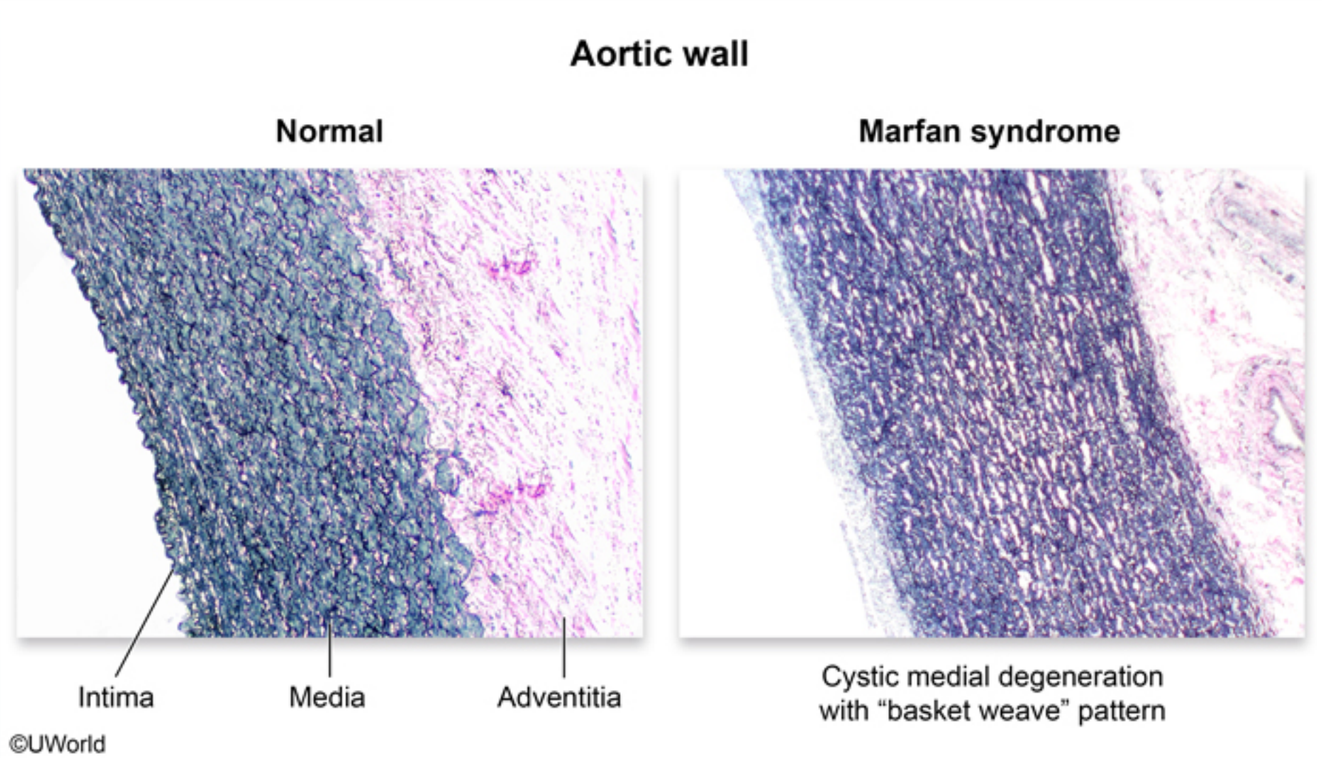

This young patient likely had Marfan syndrome complicated by aortic root disease, leading to **aortic dissection** with **acute aortic regurgitation** and heart failure. Aortic dissection typically presents with sudden-onset, severe chest or back pain. In Marfan syndrome, the dissection almost always affects the ascending aorta; it can propagate proximally to impair aortic valve closure, causing acute aortic regurgitation (evidenced by a decrescendo diastolic murmur) and heart failure (evidenced by pulmonary edema).

Marfan syndrome results from a mutation that disrupts the synthesis, secretion, and incorporation into the extracellular matrix of **fibrillin**, a protein that provides the glycoprotein scaffolding for elastin structure. The most common histologic findings in aortic root disease include **fragmentation** and loss of the **elastic lamellae** with fibrosis and cystic medial degeneration (replacement of collagen, elastin, and smooth muscle by a basophilic mucoid extracellular matrix with irregular fiber cross-linkages and cystic collections of mucopolysaccharide). Cystic medial degeneration also

1
2
3
4
5
6
7
8
9
10
11
12
13
14
15
16
17
18
19
20
21
22
23
24
25
26
27
28
29

This young patient likely had Marfan syndrome complicated by aortic root disease, leading to **aortic dissection** with **acute aortic regurgitation** and heart failure. Aortic dissection typically presents with sudden-onset, severe chest or back pain. In Marfan syndrome, the dissection almost always affects the ascending aorta; it can propagate proximally to impair aortic valve closure, causing acute aortic regurgitation (evidenced by a decrescendo diastolic murmur) and heart failure (evidenced by pulmonary edema).

Marfan syndrome results from a mutation that disrupts the synthesis, secretion, and incorporation into the extracellular matrix of **fibrillin**, a protein that provides the glycoprotein scaffolding for elastin structure. The most common histologic findings in aortic root disease include **fragmentation** and loss of the **elastic lamellae** with fibrosis and cystic medial degeneration (replacement of collagen, elastin, and smooth muscle by a basophilic mucoid extracellular matrix with irregular fiber cross-linkages and cystic collections of mucopolysaccharide). Cystic medial degeneration also occurs with normal aging, but is accelerated in Marfan syndrome.

(Choices A and B) Fatty streaking (the early stages of atherosclerosis) is often present in male patients in their 20s, but significant atherosclerotic thickening of the intima is not expected. Coagulative necrosis of the left ventricular wall typically results from atherosclerotic plaque rupture leading to myocardial infarction, which is unlikely in the absence of significant atherosclerotic disease.

(Choice D) Myocardial infarction can cause papillary muscle necrosis and rupture. This mechanical complication typically occurs acutely or within 3-5 days of myocardial infarction and leads to acute mitral regurgitation with a holosystolic – rather than diastolic decrescendo – murmur.

(Choice E) Inflammation of the vasa vasorum can lead to aortitis and aneurysm formation in syphilis and certain vasculitides (eg, Behçet syndrome). However, such diseases are associated with multiple other manifestations (eg, rash, ulcer, airway disease) and would not explain this patient's pectus excavatum.

Educational objective:
Marfan syndrome involves a deleterious mutation in fibrillin that mainly affects the structural integrity of the cardiovascular and musculoskeletal systems. Aortic root disease predisposes to aortic dissection, which can present with sudden-onset chest or back pain, acute aortic regurgitation, and heart failure. Common histologic findings in aortic disease include fragmentation and loss of the elastic lamellae with fibrosis and cystic medial degeneration.

References

- Pathogenesis of aortic wall complications in Marfan syndrome.

1 2 3 4 5 6 7 8 9 10 11 12 13 14 15 16 17 18 19 20 21 22 23 24 25 26 27 28 29

Marfan syndrome results from a mutation that disrupts the synthesis, secretion, and incorporation into the extracellular matrix of **fibrillin**, a protein that provides the glycoprotein scaffolding for elastin structure. The most common histologic findings in aortic root disease include **fragmentation** and loss of the **elastic lamellae** with fibrosis and cystic medial degeneration (replacement of collagen, elastin, and smooth muscle by a basophilic mucoid extracellular matrix with irregular fiber cross-linkages and cystic collections of mucopolysaccharide). Cystic medial degeneration also occurs with normal aging, but is accelerated in Marfan syndrome.

(Choices A and B) Fatty streaking (the early stages of atherosclerosis) is often present in male patients in their 20s, but significant atherosclerotic thickening of the intima is not expected. Coagulative necrosis of the left ventricular wall typically results from atherosclerotic plaque rupture leading to myocardial infarction, which is unlikely in the absence of significant atherosclerotic disease.

(Choice D) Myocardial infarction can cause papillary muscle necrosis and rupture. This mechanical complication typically occurs acutely or within 3-5 days of myocardial infarction and leads to acute mitral regurgitation with a holosystolic – rather than diastolic decrescendo – murmur.

(Choice E) Inflammation of the vasa vasorum can lead to aortitis and aneurysm formation in syphilis and certain vasculitides (eg, Behçet syndrome). However, such diseases are associated with multiple other manifestations (eg, rash, ulcer, airway disease) and would not explain this patient's pectus excavatum.

Educational objective:
Marfan syndrome involves a deleterious mutation in fibrillin that mainly affects the structural integrity of the cardiovascular and musculoskeletal systems. Aortic root disease predisposes to aortic dissection, which can present with sudden-onset chest or back pain, acute aortic regurgitation, and heart failure. Common histologic findings in aortic disease include fragmentation and loss of the elastic lamellae with fibrosis and cystic medial degeneration.

References

- Pathogenesis of aortic wall complications in Marfan syndrome.

Pathology	Cardiovascular System	Aortic dissection
Subject	System	Topic

Copyright © UWorld. All rights reserved.

1
2
3
4
5
6
7
8
9
10
11
12
13
14
15
16
17
18
19
20
21
22
23
24
25
26
27
28
29

Exhibit Display

Cardiac auscultatory locations

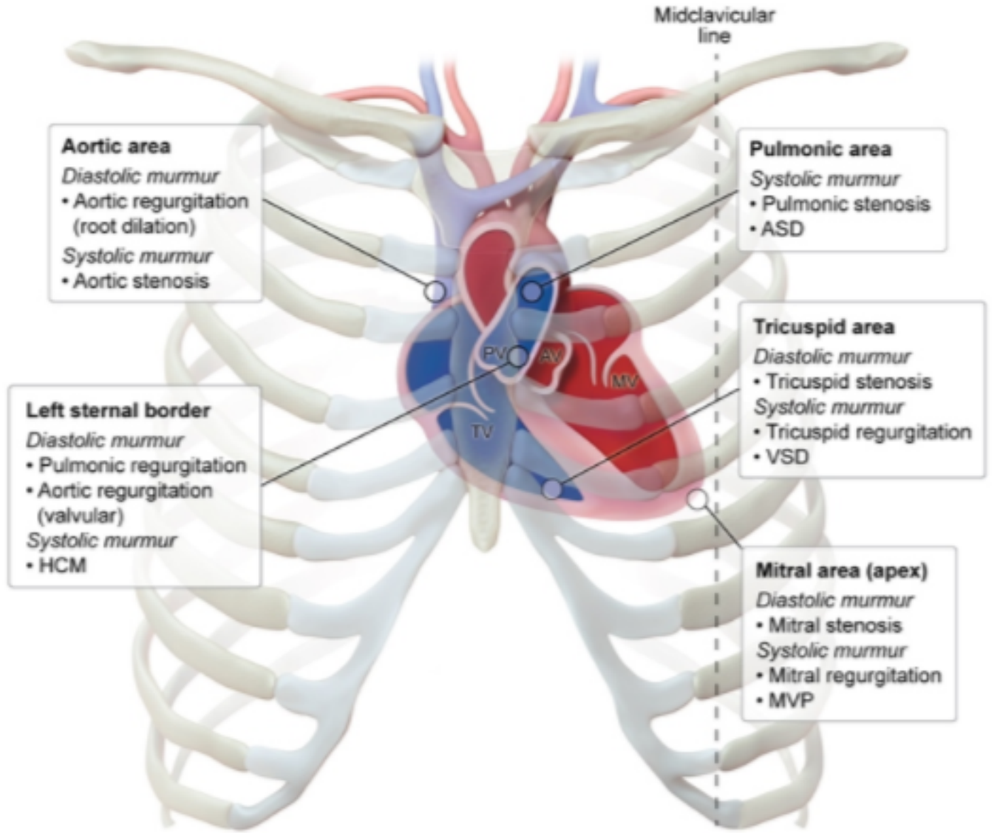

ASD = atrial septal defect; **AV** = aortic valve; **HCM** = hypertrophic cardiomyopathy; **MV** = mitral valve; **MVP** = mitral valve prolapse; **PV** = pulmonic valve; **TV** = tricuspid valve; **VSD** = ventricular septal defect.

©UWorld

Zoom In | Zoom Out | Reset | Add To New Card | Existing Card

1
2
3
4
5
6
7
8
9
10
11
12
13
14
15
16
17
18
19
20
21
22
23
24
25
26
27
28
29

Exhibit Display

Cystic medial degeneration of aorta

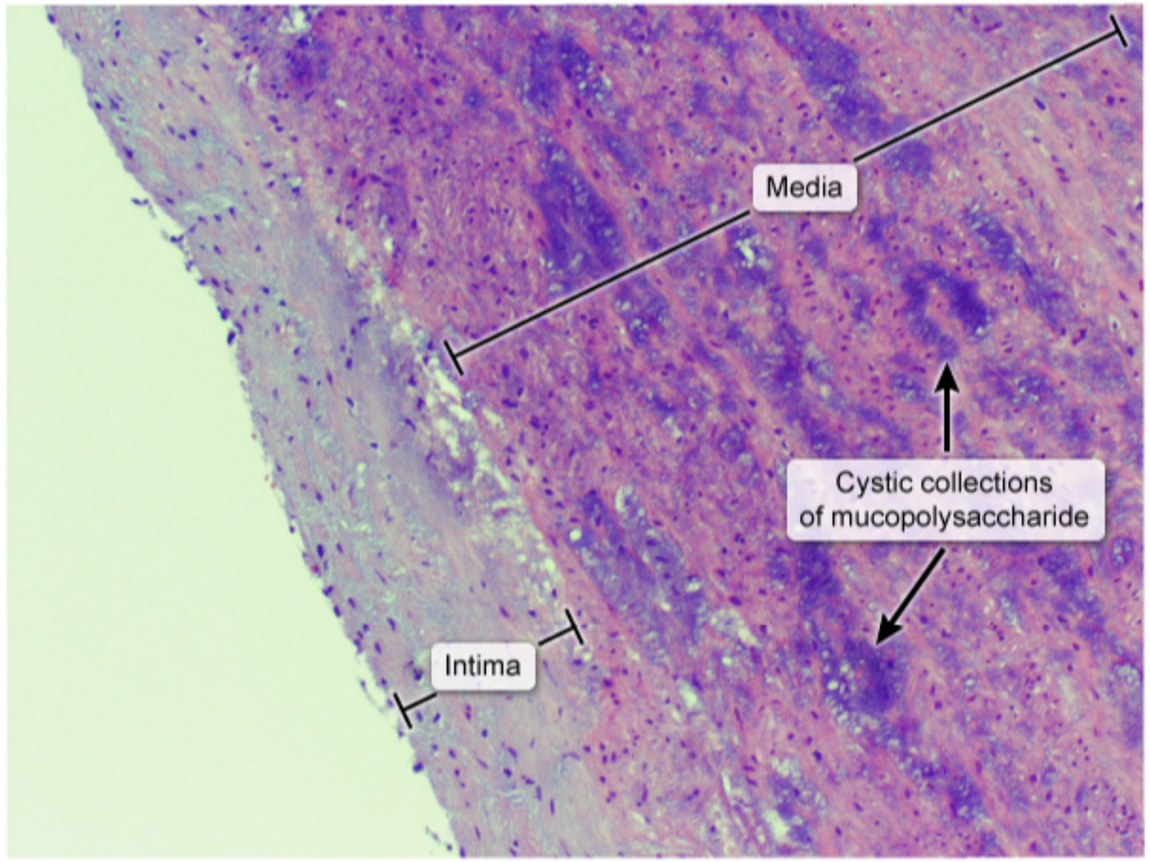

©UWorld

Zoom In | Zoom Out | Reset | Add To New Card | Existing Card

1
2
3
4
5
6
7
8
9
10
11
12
13
14
15
16
17
18
19
20
21
22
23
24
25
26
27
28
29

Exhibit Display

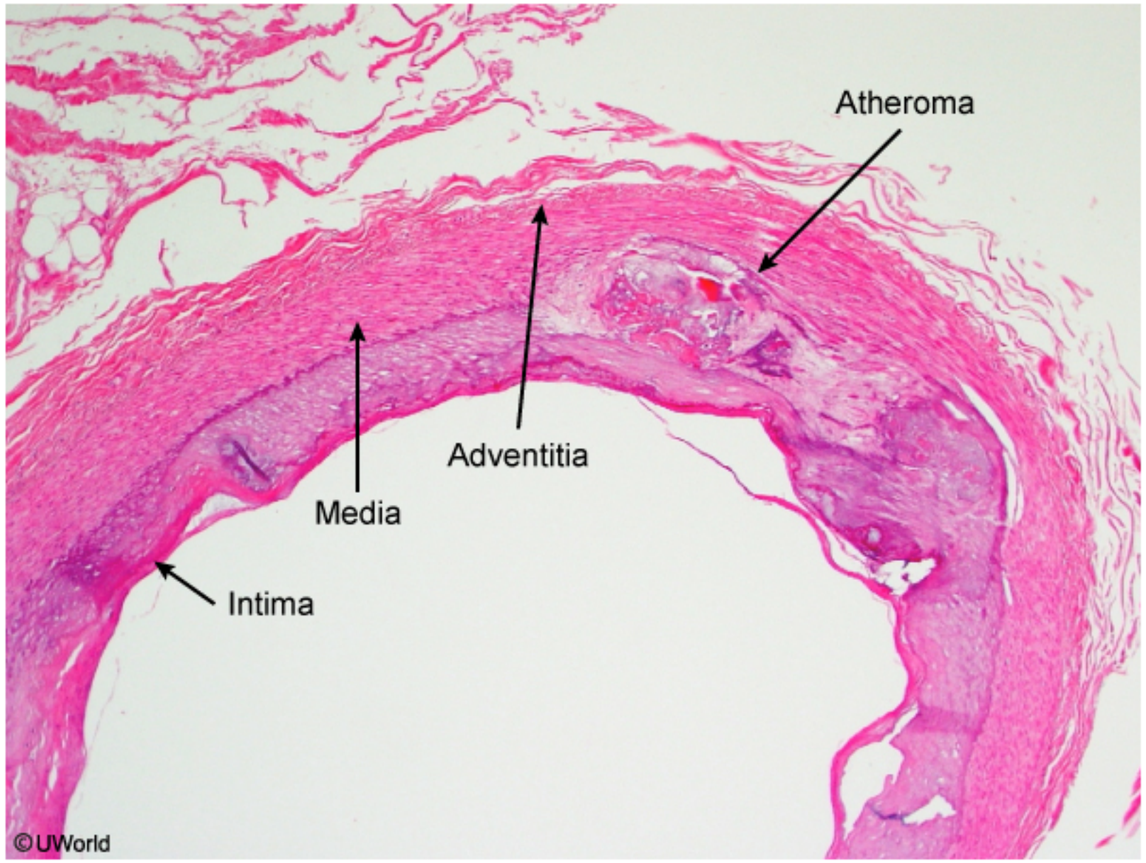

Zoom In | Zoom Out | Reset | Add To New Card | Existing Card

1
2
3
4
5
6
7
8
9
10
11
12
13
14
15
16
17
18
19
20
21
22
23
24
25
26
27
28
29

A research center studying cardiovascular pathology is conducting trials in which experimental rabbits are fed sweet peas containing substances that alter connective tissue synthesis and maturation. The animals are monitored for several weeks prior to euthanasia. Autopsy shows myxomatous degeneration with pooling of proteoglycans in the media layer and an intact intima layer in large arteries. The pathologic findings seen in the experiment are most similar to which of the following conditions?

A. Aortic aneurysm
B. Atherosclerosis
C. Berry aneurysm
D. False aneurysm
E. Giant cell arteritis
F. Malignant hypertension

Submit

1
2
3
4
5
6
7
8
9
10
11
12
13
14
15
16
17
18
19
20
21
22
23
24
25
26
27
28
29

A research center studying cardiovascular pathology is conducting trials in which experimental rabbits are fed sweet peas containing substances that alter connective tissue synthesis and maturation. The animals are monitored for several weeks prior to euthanasia. Autopsy shows myxomatous degeneration with pooling of proteoglycans in the media layer and an intact intima layer in large arteries. The pathologic findings seen in the experiment are most similar to which of the following conditions?

- ✓ A. Aortic aneurysm (48%)
- B. Atherosclerosis (11%)
- C. Berry aneurysm (6%)
- D. False aneurysm (14%)
- E. Giant cell arteritis (10%)
- F. Malignant hypertension (7%)

Omitted
Correct answer
A

48%
Answered correctly

03 secs
Time Spent

05/12/2020
Last Updated

Explanation

Cystic medial degeneration of aorta

1
2
3
4
5
6
7
8
9
10
11
12
13
14
15
16
17
18
19
20
21
22
23
24
25
26
27
28
29

Cystic medial degeneration of aorta

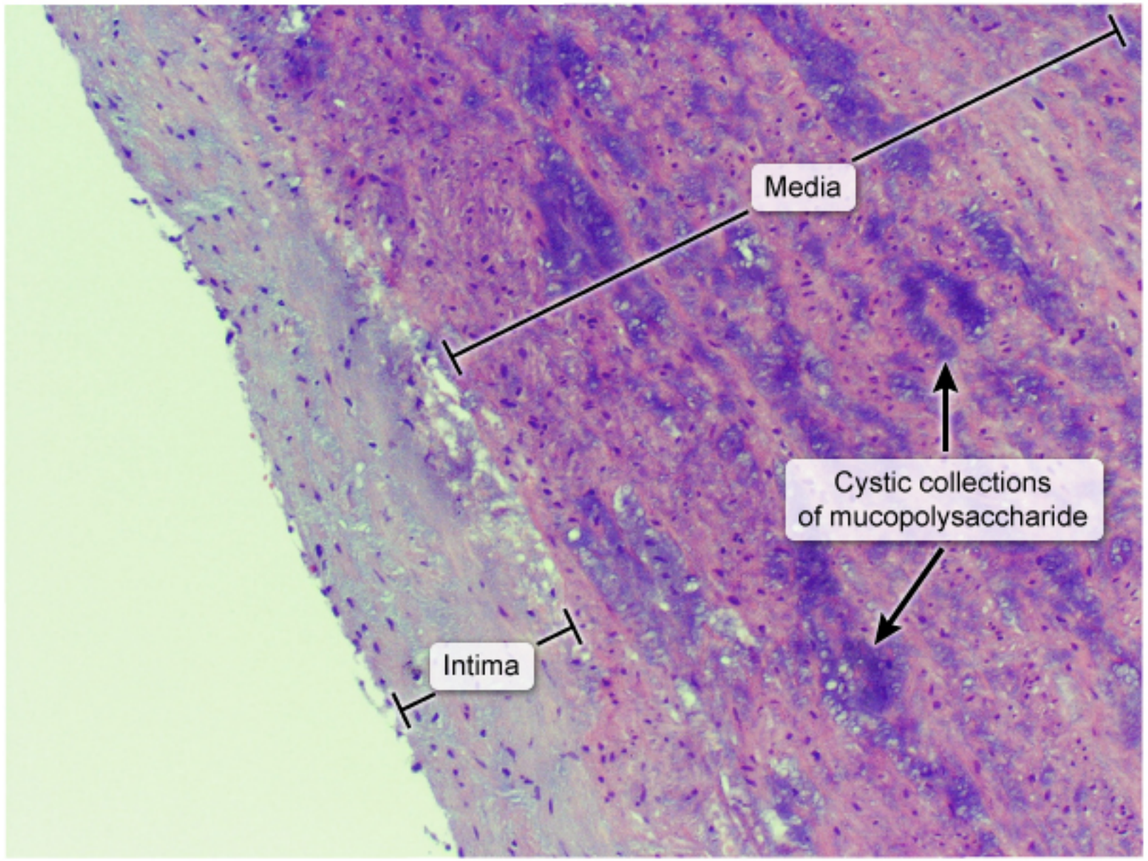

©UWorld

Myxomatous changes in the media of large arteries is found in **cystic medial degeneration**, a form of pathologic weakening of connective tissue that occurs in large arteries. Medial degeneration is characterized by the fragmentation of elastic tissue and separation of the elastic and fibromuscular components of the tunica media by small, clefted spaces that become filled with amorphous extracellular matrix (ie, mucopolysaccharide).

©UWorld

Myxomatous changes in the media of large arteries is found in **cystic medial degeneration**, a form of pathologic weakening of connective tissue that occurs in large arteries. Medial degeneration is characterized by the fragmentation of elastic tissue and separation of the elastic and fibromuscular components of the tunica media by small, clefted spaces that become filled with amorphous extracellular matrix (ie, mucopolysaccharide).

Marfan syndrome is a frequent cause of cystic medial degeneration in younger patients. It is characterized by an autosomal dominant defect in the extracellular glycoprotein fibrillin-1, which is a major component of the extracellular matrix microfibrils that form the scaffolding for elastic fibers. Mutation of the fibrillin-1 gene results in elastic tissue fragmentation, which predisposes affected patients to **aortic aneurysms** (with an intact intima) and dissections (with an intimal tear).

Beta-aminopropionitrile (a chemical found in certain kinds of sweet peas) causes inhibition of lysyl oxidase, an enzyme responsible for cross-linking elastin fibers and collagen fibers. Ingestion of this compound can cause **connective tissue disruption** in the aorta that mimics the myxomatous degeneration seen in patients with Marfan syndrome.

(Choice B) Atherosclerosis is the formation of intimal atheromas in response to chronic or repetitive endothelial injury. Myxomatous degeneration does not play a significant role in the pathogenesis of atherosclerosis.

(Choice C) The pathogenesis of berry aneurysms is multifactorial. Contributory factors include hemodynamic stress, hypertension, and certain connective tissue disorders. Type IV Ehlers-Danlos syndrome (which results in abnormalities in type III collagen) predisposes patients to the development of berry aneurysms. Myxomatous degeneration is not associated with berry aneurysms.

(Choice D) A false aneurysm, or pseudoaneurysm, is the result of a breach in the continuity of all the layers of a blood vessel, leading to blood leakage outside the vessel wall (eg, hematoma). The intima would not be intact in a false aneurysm.

(Choice E) Giant cell arteritis involves granulomatous inflammation of the media and fragmentation of the internal elastic lamina, perhaps due to autoimmunity to elastin. It is not related to myxomatous changes of the arterial wall.

(Choice F) Hyperplastic arteriolosclerosis of the renal arterioles is associated with malignant hypertension. It results from concentric lamellar reduplication of the intimal smooth muscle cells ("onion-skinning"). Myxomatous degeneration is not a contributing factor.

Educational objective:

1 2 3 4 5 6 7 8 9 10 11 12 13 14 15 16 17 18 19 20 21 22 23 24 25 26 27 28 29

Beta-aminopropionitrile (a chemical found in certain kinds of sweet peas) causes inhibition of lysyl oxidase, an enzyme responsible for cross-linking elastin fibers and collagen fibers. Ingestion of this compound can cause **connective tissue disruption** in the aorta that mimics the myxomatous degeneration seen in patients with Marfan syndrome.

(Choice B) Atherosclerosis is the formation of intimal atheromas in response to chronic or repetitive endothelial injury. Myxomatous degeneration does not play a significant role in the pathogenesis of atherosclerosis.

(Choice C) The pathogenesis of berry aneurysms is multifactorial. Contributory factors include hemodynamic stress, hypertension, and certain connective tissue disorders. Type IV Ehlers-Danlos syndrome (which results in abnormalities in type III collagen) predisposes patients to the development of berry aneurysms. Myxomatous degeneration is not associated with berry aneurysms.

(Choice D) A false aneurysm, or pseudoaneurysm, is the result of a breach in the continuity of all the layers of a blood vessel, leading to blood leakage outside the vessel wall (eg, hematoma). The intima would not be intact in a false aneurysm.

(Choice E) Giant cell arteritis involves granulomatous inflammation of the media and fragmentation of the internal elastic lamina, perhaps due to autoimmunity to elastin. It is not related to myxomatous changes of the arterial wall.

(Choice F) Hyperplastic arteriolosclerosis of the renal arterioles is associated with malignant hypertension. It results from concentric lamellar reduplication of the intimal smooth muscle cells ("onion-skinning"). Myxomatous degeneration is not a contributing factor.

Educational objective:
Myxomatous changes, with pooling of mucopolysaccharides in the media layer of large arteries, are found in cystic medial degeneration, which predisposes affected patients to the development of aortic aneurysms. Medial degeneration in younger individuals is frequently due to Marfan syndrome.

References

- Histological pattern and changes in extracellular matrix in aortic dissections.
- Cystic medial necrosis: pathological findings and clinical implications.

Pathology	Cardiovascular System	Aortic aneurysm
Subject	System	Topic

1
2
3
4
5
6
7
8
9
10
11
12
13
14
15
16
17
18
19
20
21
22
23
24
25
26
27
28
29

Exhibit Display

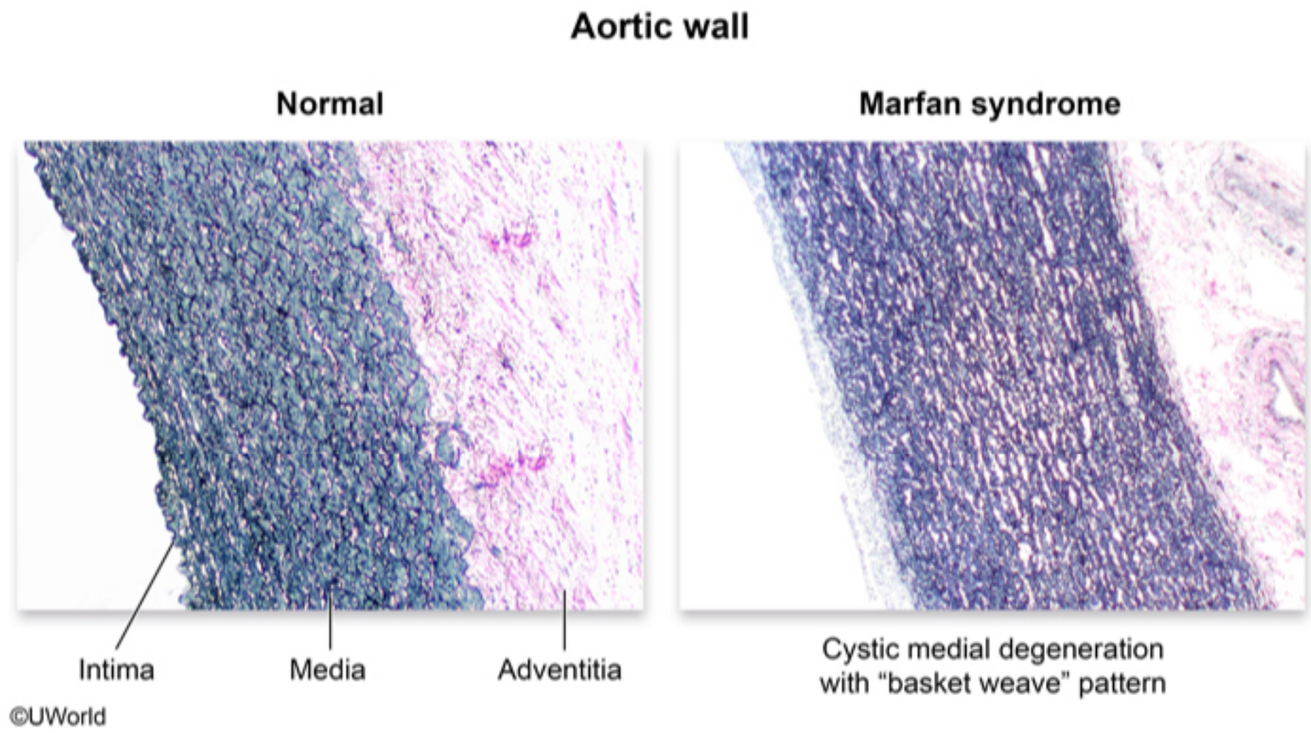

Zoom In | Zoom Out | Reset | Add To New Card | Existing Card

1
2
3
4
5
6
7
8
9
10
11
12
13
14
15
16
17
18
19
20
21
22
23
24
25
26
27
28
29

Marfan syndrome is a frequent cause of cystic medial degeneration in younger patients. It is characterized by an autosomal dominant defect in

Exhibit Display

True & false aneurysms

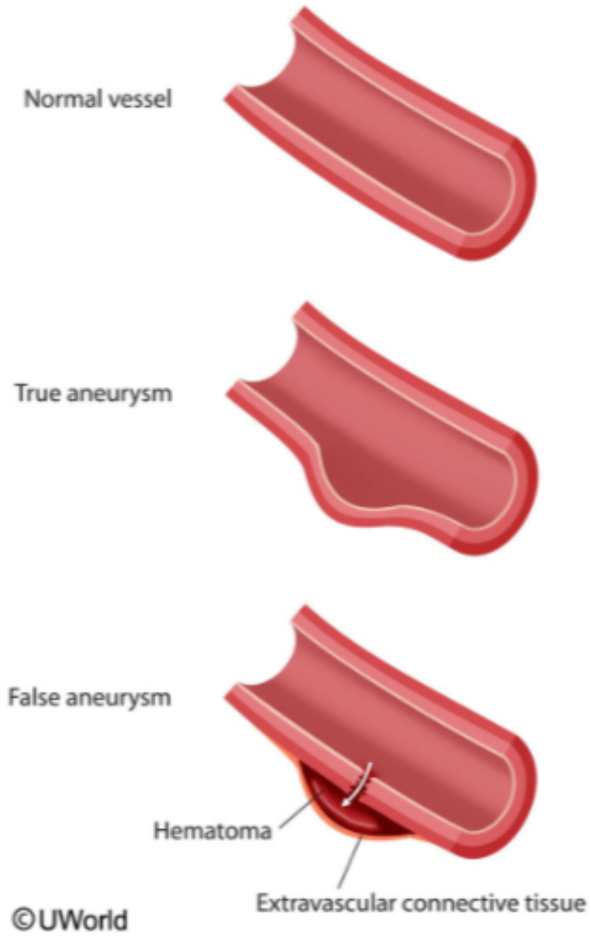

Zoom In | Zoom Out | Reset | Add To New Card | Existing Card

- Histological pattern and changes in extracellular matrix in aortic dissections.

1
2
3
4
5
6
7
8
9
10
11
12
13
14
15
16
17
18
19
20
21
22
23
24
25
26
27
28
29

A 42-year-old man is brought to the emergency department 1 hour after the onset of severe headache, nausea, vomiting, and confusion. The patient has primary (essential) hypertension and chronic kidney disease; he has been prescribed 2 antihypertensive agents but has been noncompliant with therapy. Temperature is 36.8 C (98.2 F), blood pressure is 240/150 mm Hg, heart rate is 90/min, and respirations are 20/min. Ophthalmologic examination shows bilateral papilledema. The lungs are clear to auscultation. Cardiac examination reveals an S4 and no murmurs. Laboratory results are as follows:

	Today	2 months ago
Hematocrit	23%	30%
Platelets	78,000/mm^3	150,000/mm^3
Blood urea nitrogen	60 mg/dL	26 mg/dL
Serum creatinine	4.5 mg/dL	1.8 mg/dL
Peripheral smear	numerous schistocytes	

If renal biopsy is performed in this patient, which of the following pathologic findings is most likely to be found?

A. Fibrinoid necrosis of small arteriolar walls
B. Focal global glomerulosclerosis
C. Granulomatous inflammation of the media
D. Homogenous acellular thickening of arteriolar walls
E. Interstitial fibrosis and tubular atrophy

Submit

1
2
3
4
5
6
7
8
9
10
11
12
13
14
15
16
17
18
19
20
21
22
23
24
25
26
27
28
29

A 42-year-old man is brought to the emergency department 1 hour after the onset of severe headache, nausea, vomiting, and confusion. The patient has primary (essential) hypertension and chronic kidney disease; he has been prescribed 2 antihypertensive agents but has been noncompliant with therapy. Temperature is 36.8 C (98.2 F), blood pressure is 240/150 mm Hg, heart rate is 90/min, and respirations are 20/min. Ophthalmologic examination shows bilateral papilledema. The lungs are clear to auscultation. Cardiac examination reveals an S4 and no murmurs. Laboratory results are as follows:

	Today	2 months ago
Hematocrit	23%	30%
Platelets	78,000/mm^3	150,000/mm^3
Blood urea nitrogen	60 mg/dL	26 mg/dL
Serum creatinine	4.5 mg/dL	1.8 mg/dL
Peripheral smear	numerous schistocytes	

If renal biopsy is performed in this patient, which of the following pathologic findings is most likely to be found?

- ✓ A. Fibrinoid necrosis of small arteriolar walls (40%)
- B. Focal global glomerulosclerosis (10%)
- C. Granulomatous inflammation of the media (2%)
- D. Homogenous acellular thickening of arteriolar walls (30%)
- E. Interstitial fibrosis and tubular atrophy (15%)

Omitted
40%
04 secs
02/08/2020

Hypertensive emergency is a condition defined as severely elevated blood pressure (typically >180/120 mm Hg) with evidence of ongoing end-organ damage (eg, renal injury). Hypertensive emergencies typically occur in patients with preexisting essential hypertension and may be induced by medication noncompliance, which can result in a rapid increase in systemic blood pressure. Severe hypertension can cause damage to the vascular endothelium, leading to increased vascular permeability to coagulation factors (eg, fibrinogen), platelet activation, and endothelial cell death. In the kidney, this manifests as **malignant nephrosclerosis**, which is characterized by 2 distinct histopathologic patterns:

- **Fibrinoid necrosis:** Cell death and excessive fibrin deposition within the arteriolar walls is visible as circumferential, amorphous, pink material with smudged, necrotic endothelial cells that lack cytologic detail.
- **Hyperplastic arteriolosclerosis:** Over time, activated platelets and injured cells release growth factors, which induce concentric hyperplasia and layering of smooth muscle cells and collagen, resulting in intimal thickening and an "onion-skin" appearance.

These changes result in narrowing and/or obliteration of the arteriolar lumen; the resultant erythrocyte fragmentation and platelet consumption can cause a **microangiopathic hemolytic anemia** that is histologically indistinguishable from hemolytic uremic syndrome. Laboratory abnormalities reflect renal injury (eg, elevated creatinine and blood urea nitrogen) and hemolytic anemia (eg, schistocytes [fragmented red blood cells] on peripheral smear, elevated lactate dehydrogenase and indirect bilirubin).

Other end-organ manifestations of hypertensive emergency include papilledema, retinal hemorrhages, pulmonary edema, acute coronary syndrome, encephalopathy, and stroke.

(Choices B, D, and E) Hypertensive nephrosclerosis is characterized by interstitial fibrosis, tubular atrophy, and varying degrees of glomerulosclerosis (focal or global). Hyaline arteriolosclerosis is characterized by homogeneous deposition of hyaline material in the intima and media of small arteries and arterioles. These changes may be seen in chronic hypertension; however, the severely elevated blood pressure and evidence of end-organ dysfunction in this patient suggest hypertensive emergency and malignant nephrosclerosis.

(Choice C) Granulomatous inflammation of the media characterizes temporal (giant cell) arteritis, the most common form of systemic vasculitis in adults.

Educational objective:
Hypertensive emergency is severely elevated blood pressure (typically >180/120 mm Hg) with evidence of end-organ damage. In the kidneys, this can manifest as malignant nephrosclerosis, characterized by fibrinoid necrosis and hyperplastic arteriolosclerosis ("onion-skin" appearance). A microangiopathic hemolytic anemia can occur due to erythrocyte fragmentation and platelet consumption at the narrowed arteriolar lumen.

1 2 3 4 5 6 7 8 9 10 11 12 13 14 15 16 17 18 19 20 21 22 23 24 25 26 27 28 29

- **Fibrinoid necrosis:** Cell death and excessive fibrin deposition within the arteriolar walls is visible as circumferential, amorphous, pink material with smudged, necrotic endothelial cells that lack cytologic detail.
- **Hyperplastic arteriolosclerosis:** Over time, activated platelets and injured cells release growth factors, which induce concentric hyperplasia and layering of smooth muscle cells and collagen, resulting in intimal thickening and an "onion-skin" appearance.

These changes result in narrowing and/or obliteration of the arteriolar lumen; the resultant erythrocyte fragmentation and platelet consumption can cause a **microangiopathic hemolytic anemia** that is histologically indistinguishable from hemolytic uremic syndrome. Laboratory abnormalities reflect renal injury (eg, elevated creatinine and blood urea nitrogen) and hemolytic anemia (eg, schistocytes [fragmented red blood cells] on peripheral smear, elevated lactate dehydrogenase and indirect bilirubin).

Other end-organ manifestations of hypertensive emergency include papilledema, retinal hemorrhages, pulmonary edema, acute coronary syndrome, encephalopathy, and stroke.

(Choices B, D, and E) Hypertensive nephrosclerosis is characterized by interstitial fibrosis, tubular atrophy, and varying degrees of glomerulosclerosis (focal or global). Hyaline arteriolosclerosis is characterized by homogeneous deposition of hyaline material in the intima and media of small arteries and arterioles. These changes may be seen in chronic hypertension; however, the severely elevated blood pressure and evidence of end-organ dysfunction in this patient suggest hypertensive emergency and malignant nephrosclerosis.

(Choice C) Granulomatous inflammation of the media characterizes temporal (giant cell) arteritis, the most common form of systemic vasculitis in adults.

Educational objective:
Hypertensive emergency is severely elevated blood pressure (typically >180/120 mm Hg) with evidence of end-organ damage. In the kidneys, this can manifest as malignant nephrosclerosis, characterized by fibrinoid necrosis and hyperplastic arteriolosclerosis ("onion-skin" appearance). A microangiopathic hemolytic anemia can occur due to erythrocyte fragmentation and platelet consumption at the narrowed arteriolar lumen.

Pathology	Cardiovascular System	Primary hypertension
Subject	System	Topic

Copyright © UWorld. All rights reserved.

1
2
3
4
5
6
7
8
9
10
11
12
13
14
15
16
17
18
19
20
21
22
23
24
25
26
27
28
29

Exhibit Display

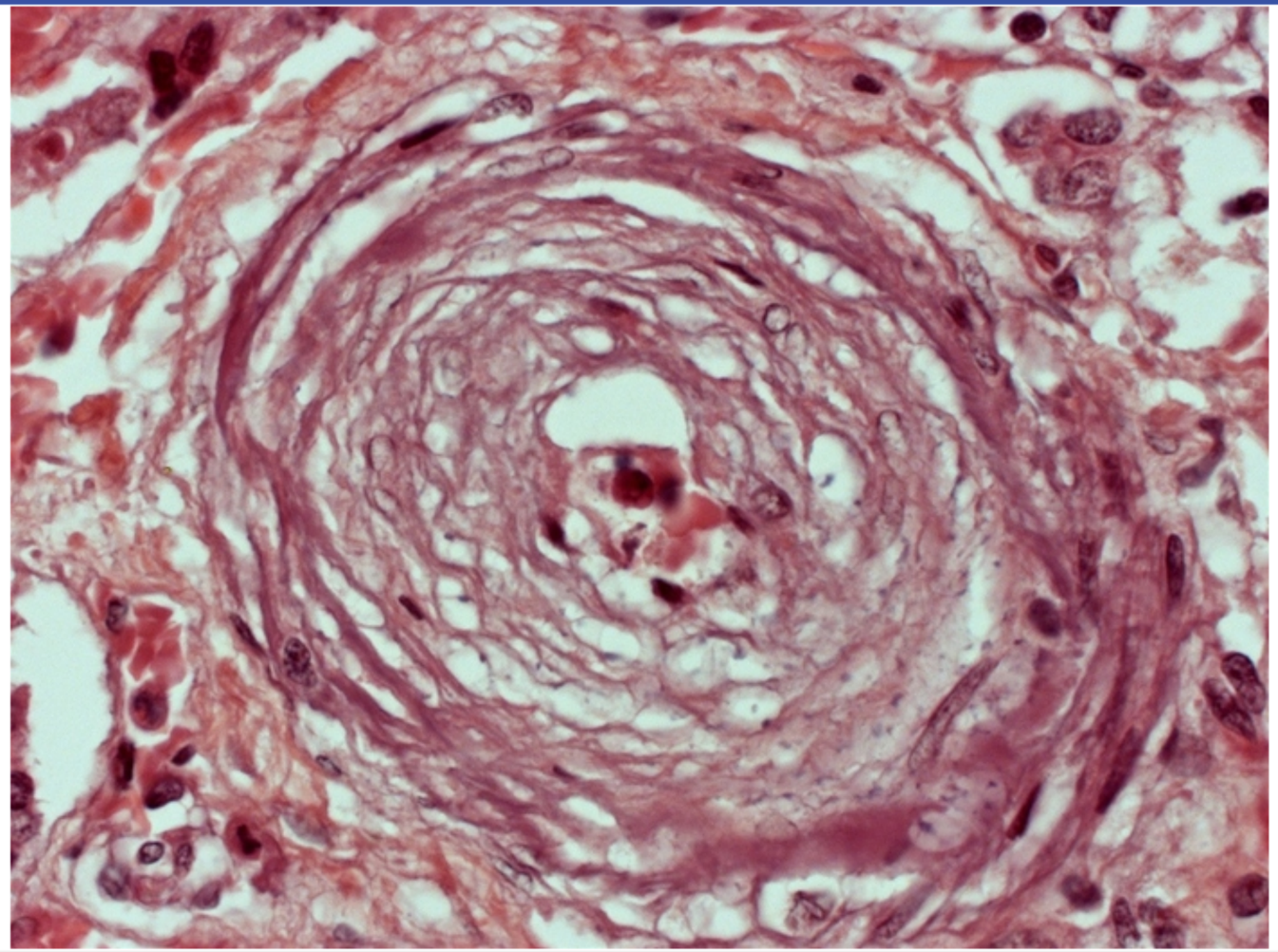

Zoom In | Zoom Out | Reset | Add To New Card | Existing Card

1
2
3
4
5
6
7
8
9
10
11
12
13
14
15
16
17
18
19
20
21
22
23
24
25
26
27
28
29

An 18-year-old woman is referred to a cardiologist after a heart murmur is discovered during a routine checkup. The patient is healthy and has no symptoms. Medical history is unremarkable. She runs daily and wants to start actively training for a half marathon. The patient is concerned that the murmur is a sign of heart disease. She has no family history of sudden cardiac death. Auscultation reveals a midsystolic click followed by a short late-systolic murmur at the cardiac apex. The murmur disappears with squatting. This patient's condition is most likely related to an abnormality involving which of the following tissues?

A. Cardiac muscle
B. Connective tissue
C. Coronary vessels
D. Endocardial lining
E. Parietal pericardium

Submit

1
2
3
4
5
6
7
8
9
10
11
12
13
14
15
16
17
18
19
20
21
22
23
24
25
26
27
28
29

An 18-year-old woman is referred to a cardiologist after a heart murmur is discovered during a routine checkup. The patient is healthy and has no symptoms. Medical history is unremarkable. She runs daily and wants to start actively training for a half marathon. The patient is concerned that the murmur is a sign of heart disease. She has no family history of sudden cardiac death. Auscultation reveals a midsystolic click followed by a short late-systolic murmur at the cardiac apex. The murmur disappears with squatting. This patient's condition is most likely related to an abnormality involving which of the following tissues?

- A. Cardiac muscle (15%)
- ✓ B. Connective tissue (64%)
- C. Coronary vessels (2%)
- D. Endocardial lining (17%)
- E. Parietal pericardium (0%)

Omitted
Correct answer
B

64%
Answered correctly

02 secs
Time Spent

01/07/2020
Last Updated

Explanation

1
2
3
4
5
6
7
8
9
10
11
12
13
14
15
16
17
18
19
20
21
22
23
24
25
26
27
28
29

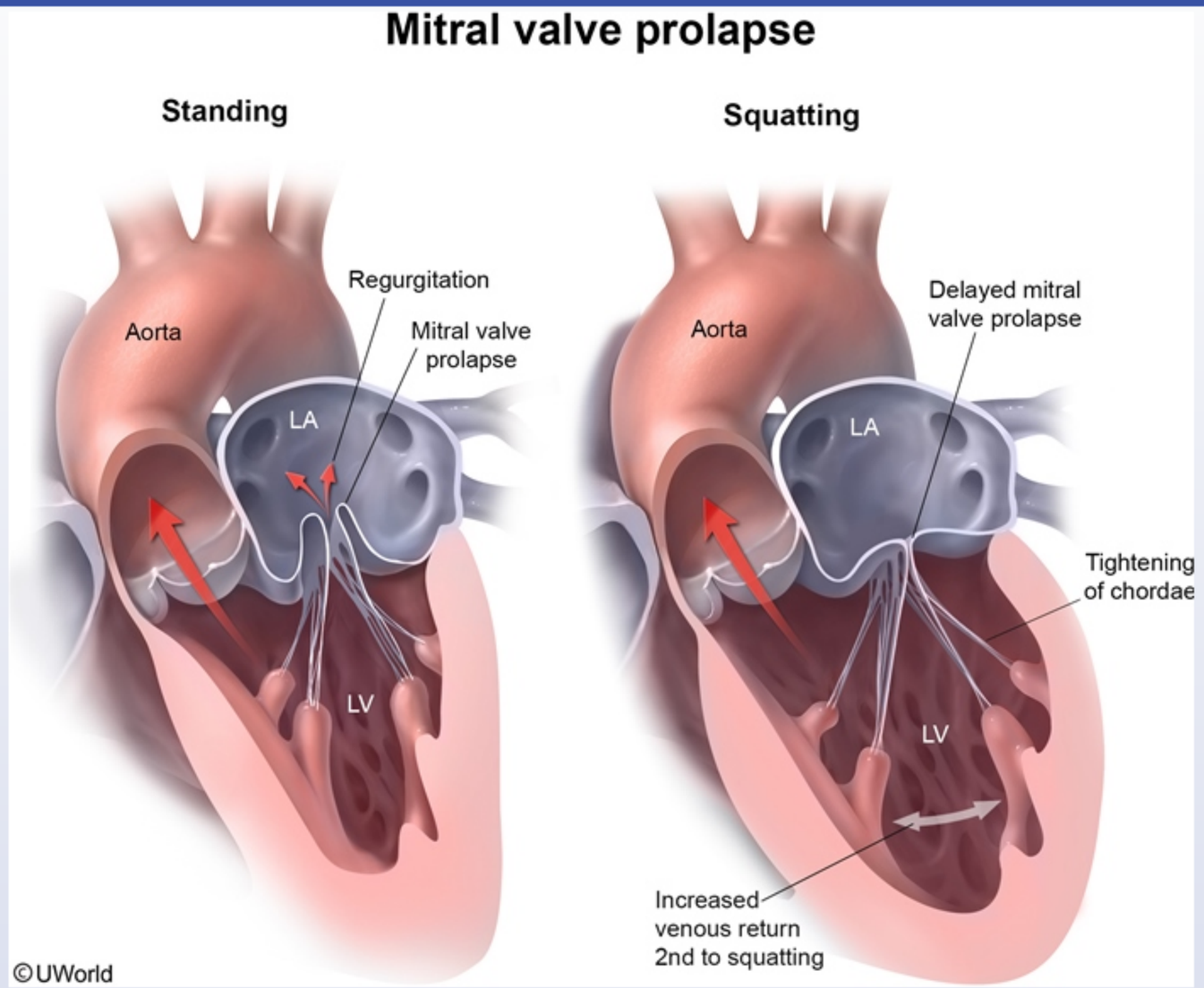

The presence of a **midsystolic click** followed by a systolic murmur at the cardiac apex that disappears with squatting is most consistent with mitral valve prolapse (MVP). The click is caused by sudden tensing of the chordae tendineae as they are pulled taut by the ballooning valve

©UWorld

The presence of a **midsystolic click** followed by a systolic murmur at the cardiac apex that disappears with squatting is most consistent with mitral valve prolapse (MVP). The click is caused by sudden tensing of the chordae tendineae as they are pulled taut by the ballooning valve leaflets, and the murmur results from regurgitation of blood due to malalignment of the valve margins with prolapse.

During systole, there is a critical left ventricular (LV) size at which prolapse occurs; therefore, maneuvers that change LV end-diastolic volume affect the timing of the click and murmur. **Squatting increases venous return** and **LV volume**, increasing the tension and **decreasing the slack** in the mitral valve apparatus. Because the ventricular walls have farther to travel to reach the critical LV size at which prolapse occurs, **prolapse occurs later** in systole or not at all.

Primary MVP is most commonly a sporadic disorder and is characterized by myxomatous degeneration (ie, pathologic **deterioration of the connective tissue**) affecting the mitral valve leaflets and chordae tendineae. Secondary MVP is associated with inherited connective tissue disorders, including Marfan or Ehlers-Danlos syndrome and osteogenesis imperfecta.

(Choice A) Hypertrophic cardiomyopathy (HCM) presents with a systolic murmur at the left sternal border that decreases in intensity with squatting (due to increased LV volume and decreased outflow tract obstruction). A midsystolic click is not heard with HCM.

(Choice C) Coronary artery disease can cause myocardial ischemia or infarction leading to papillary muscle dysfunction and acute mitral regurgitation. In such patients, squatting from a standing position increases murmur intensity due to a higher blood volume of regurgitation. In addition, such a murmur is not preceded by a midsystolic click.

(Choice D) Endomyocardial fibrosis and endocardial fibroelastosis are disorders that affect the endocardium and are not associated with MVP.

(Choice E) Pericardial disease may infrequently result in cardiac tamponade or constrictive pericarditis. Pericarditis may produce a friction rub; however, it is not associated with a cardiac murmur.

Educational objective:
Mitral valve prolapse is most often caused by defects in connective tissue proteins that predispose to myxomatous degeneration of the mitral leaflets and chordae tendineae. Cardiac auscultation typically reveals a midsystolic click followed by a mitral regurgitation murmur; the click and murmur occur later in systole or disappear completely with maneuvers (eg, squatting) that increase left ventricular end-diastolic volume.

References

©UWorld

The presence of a **midsystolic click** followed by a systolic murmur at the cardiac apex that disappears with squatting is most consistent with mitral valve prolapse (MV

leaflets, and the murmur r

During systole, there is a

affect the timing of the clic

in the mitral valve apparat

occurs later in systole or

Primary MVP is most com

connective tissue) affect

disorders, including Marfa

(Choice A) Hypertrophic

squatting (due to increase

(Choice C) Coronary arte

regurgitation. In such pati

addition, such a murmur is

(Choice D) Endomyocard

(Choice E) Pericardial di

however, it is not associat

Educational objective:

Mitral valve prolapse is m

leaflets and chordae tendi

murmur occur later in syst

References

Exhibit Display

Auscultation of murmurs

Maneuver	Change in cardiac parameters	Murmurs that increase	Murmurs that decrease
Inspiration	↑ Venous return to right heart ↓ Venous return to left heart	Most right-sided murmurs	Most left-sided murmurs
Valsalva strain phase	↓ Preload	MVP & HCM (↓ LV volume)	Most other murmurs (↓ flow through stenotic or regurgitant valve)
Abrupt standing			
Squatting	↑ Preload ↑ Afterload	Most other murmurs (↑ flow through stenotic or regurgitant valve)	MVP & HCM (↑ LV volume)
Passive leg raise	↑ Preload		
			HCM (↑ LV volume)

Add To New Card | Existing Card

©UWorld

The presence of a **midsystolic click** followed by a systolic murmur at the cardiac apex that disappears with squatting is most consistent with

Exhibit Display

Auscultation of murmurs

Maneuver	Change in cardiac parameters	Murmurs that increase	Murmurs that decrease
Inspiration	↑ Venous return to right heart ↓ Venous return to left heart	Most right-sided murmurs	Most left-sided murmurs
Valsalva strain phase	↓ Preload	MVP & HCM (↓ LV volume)	Most other murmurs (↓ flow through stenotic or regurgitant valve)
Abrupt standing			
Squatting	↑ Preload ↑ Afterload	Most other murmurs (↑ flow through stenotic or regurgitant valve)	MVP & HCM (↑ LV volume)
Passive leg raise	↑ Preload		
Handgrip	↑ Afterload	AR, MR & VSD (↑ LV & aortic pressure)	HCM (↑ LV volume) AS (↓ transvalvular pressure gradient)

Add To New Card | Existing Card

References

©UWorld

The presence of a **midsystolic click** followed by a systolic murmur at the cardiac apex that disappears with squatting is most consistent with

Exhibit Display

Maneuver	Change in cardiac parameters	Murmurs that increase	Murmurs that decrease
Inspiration	↑ Venous return to right heart ↓ Venous return to left heart	Most right-sided murmurs	Most left-sided murmurs
Valsalva strain phase	↓ Preload	MVP & HCM (↓ LV volume)	Most other murmurs (↓ flow through stenotic or regurgitant valve)
Abrupt standing			
Squatting	↑ Preload ↑ Afterload	Most other murmurs (↑ flow through stenotic or regurgitant valve)	MVP & HCM (↑ LV volume)
Passive leg raise	↑ Preload		
Handgrip	↑ Afterload	AR, MR & VSD (↑ LV & aortic pressure)	HCM (↑ LV volume) AS (↓ transvalvular pressure gradient)

AR = aortic regurgitation; **AS** = aortic stenosis; **HCM** = hypertrophic cardiomyopathy; **LV** = left ventricular; **MR** = mitral regurgitation; **MVP** = mitral valve prolapse; **VSD** = ventricular septal defect.

Add To New Card | Existing Card

References

1
2
3
4
5
6
7
8
9
10
11
12
13
14
15
16
17
18
19
20
21
22
23
24
25
26
27
28
29

A 21-year-old Caucasian male presents to the emergency department following an episode of syncope. The syncopal episode was not provoked by any activity or circumstance, nor was it preceded by lightheadedness. The patient has no significant past medical history and he is not taking any medications. An ECG obtained in the ER reveals QT-interval prolongation but is otherwise unremarkable. Assuming this is an inherited condition, the relevant mutation most likely affects which of the following structures?

A. Cardiac cell cytoskeleton proteins

B. Cardiac cell sarcomere proteins

C. Mitochondrial enzymes of oxidative phosphorylation

D. Calcium-binding sarcoplasmic reticulum protein

E. Membrane potassium channel proteins

Submit

1
2
3
4
5
6
7
8
9
10
11
12
13
14
15
16
17
18
19
20
21
22
23
24
25
26
27
28
29

A 21-year-old Caucasian male presents to the emergency department following an episode of syncope. The syncopal episode was not provoked by any activity or circumstance, nor was it preceded by lightheadedness. The patient has no significant past medical history and he is not taking any medications. An ECG obtained in the ER reveals QT-interval prolongation but is otherwise unremarkable. Assuming this is an inherited condition, the relevant mutation most likely affects which of the following structures?

A. Cardiac cell cytoskeleton proteins (4%)

B. Cardiac cell sarcomere proteins (13%)

C. Mitochondrial enzymes of oxidative phosphorylation (3%)

D. Calcium-binding sarcoplasmic reticulum protein (12%)

✓ E. Membrane potassium channel proteins (66%)

Omitted
Correct answer
E

66%
Answered correctly

03 secs
Time Spent

02/03/2020
Last Updated

Explanation

This patient's sudden-onset syncopal episode suggests a sudden cardiac arrhythmia. QT prolongation in an otherwise healthy young individual is usually congenital. The mutation most likely to cause QT-interval prolongation can be determined based on an understanding of cardiac electrophysiology. On an ECG tracing, the QT interval begins at the start of the QRS complex and ends at the end of the T wave. Thus, the QT-interval reflects the cardiac myocyte action potential duration, which is determined in part by K^+ currents through channel proteins. The mutations listed in the other answer choices would be less likely to directly affect the cardiac cell action potential duration.

1
2
3
4
5
6
7
8
9
10
11
12
13
14
15
16
17
18
19
20
21
22
23
24
25
26
27
28
29

This patient's sudden-onset syncopal episode suggests a sudden cardiac arrhythmia. QT prolongation in an otherwise healthy young individual is usually congenital. The mutation most likely to cause QT-interval prolongation can be determined based on an understanding of cardiac electrophysiology. On an ECG tracing, the QT interval begins at the start of the QRS complex and ends at the end of the T wave. Thus, the QT-interval reflects the cardiac myocyte action potential duration, which is determined in part by K^+ currents through channel proteins. The mutations listed in the other answer choices would be less likely to directly affect the cardiac cell action potential duration.

There are two important congenital syndromes that cause QT prolongation: Jervell and Lange-Nielsen syndrome (autosomal recessive, with neurosensory deafness) and the more common Romano-Ward syndrome (autosomal dominant, no deafness). Both may predispose to *torsades de pointes* (a ventricular tachyarrhythmia) at a young age, causing syncopal episodes and possible sudden cardiac death.

(Choices A and C) Mutations affecting cardiac cell cytoskeletal proteins or the mitochondrial enzymes of oxidative phosphorylation are thought to cause the genetic form of dilated cardiomyopathy (DCM). DCM usually presents with gradual onset of left-sided heart failure (with symptoms like dyspnea on exertion initially), as opposed to the sudden syncopal episode in a previously asymptomatic patient described above.

(Choice B) Mutations in cardiac cell sarcomere proteins (e.g. beta-myosin heavy chain) underlie hypertrophic cardiomyopathy (HCM). Although HCM may present as syncope in a previously asymptomatic young person, the syncope of HCM is typically provoked by exertion. Additionally, QT prolongation is not generally found in HCM.

(Choice D) Mutations of a calcium-binding sarcoplasmic reticulum protein might underlie some cases of arrhythmogenic right ventricular cardiomyopathy (ARVC), a progressive fibrofatty replacement of the right ventricular myocardium of uncertain pathogenesis. QT prolongation is not generally seen with ARVC.

Educational Objective:
Unprovoked syncope in a previously asymptomatic young person may result from a congenital QT prolongation syndrome. The two most important congenital syndromes with QT prolongation − Romano-Ward syndrome and Jervell and Lange-Nielsen syndrome − are thought to result from mutations in a K^+ channel protein that contributes to the delayed rectifier current (I_K) of the cardiac action potential.

Pathology	Cardiovascular System	Long QT syndrome
Subject	System	Topic

1
2
3
4
5
6
7
8
9
10
11
12
13
14
15
16
17
18
19
20
21
22
23
24
25
26
27
28
29

usually congenital. The mutation most likely to cause QT-interval prolongation can be determined based on an understanding of cardiac electrophysiology. On an ECG tracing, the QT interval begins at the start of the QRS complex and ends at the end of the T wave. Thus, the QT-interval reflects the cardiac myocyte action potential duration, which is determined in part by K^+ currents through channel proteins. The mutations listed in the other answer choices would be less likely to directly affect the cardiac cell action potential duration.

There are two important congenital syndromes that cause QT prolongation: Jervell and Lange-Nielsen syndrome (autosomal recessive, with neurosensory deafness) and the more common Romano-Ward syndrome (autosomal dominant, no deafness). Both may predispose to *torsades de pointes* (a ventricular tachyarrhythmia) at a young age, causing syncopal episodes and possible sudden cardiac death.

(Choices A and C) Mutations affecting cardiac cell cytoskeletal proteins or the mitochondrial enzymes of oxidative phosphorylation are thought to cause the genetic form of dilated cardiomyopathy (DCM). DCM usually presents with gradual onset of left-sided heart failure (with symptoms like dyspnea on exertion initially), as opposed to the sudden syncopal episode in a previously asymptomatic patient described above.

(Choice B) Mutations in cardiac cell sarcomere proteins (e.g. beta-myosin heavy chain) underlie hypertrophic cardiomyopathy (HCM). Although HCM may present as syncope in a previously asymptomatic young person, the syncope of HCM is typically provoked by exertion. Additionally, QT prolongation is not generally found in HCM.

(Choice D) Mutations of a calcium-binding sarcoplasmic reticulum protein might underlie some cases of arrhythmogenic right ventricular cardiomyopathy (ARVC), a progressive fibrofatty replacement of the right ventricular myocardium of uncertain pathogenesis. QT prolongation is not generally seen with ARVC.

Educational Objective:
Unprovoked syncope in a previously asymptomatic young person may result from a congenital QT prolongation syndrome. The two most important congenital syndromes with QT prolongation − Romano-Ward syndrome and Jervell and Lange-Nielsen syndrome − are thought to result from mutations in a K^+ channel protein that contributes to the delayed rectifier current (I_K) of the cardiac action potential.

Pathology	Cardiovascular System	Long QT syndrome
Subject	System	Topic

Copyright © UWorld. All rights reserved.

1
2
3
4
5
6
7
8
9
10
11
12
13
14
15
16
17
18
19
20
21
22
23
24
25
26
27
28
29

A 54-year-old man comes to the emergency department due to severe fatigue and dyspnea. He has a long history of progressively worsening heart failure that has been resistant to treatment with medications, including diuretics. He was treated with chest radiation 10 years ago for non-Hodgkin lymphoma and has been in remission since then. The patient is admitted to the hospital, but his condition continues to deteriorate despite aggressive therapy. He dies 3 days later, and an autopsy is performed. Gross inspection of the heart shows dense, thick, fibrous tissue in the pericardial space between the visceral and parietal pericardium. Which of the following signs would most likely have been detected during a physical examination of this patient just prior to his death?

A. Kussmaul sign

B. Loud P2

C. Paradoxical splitting of S2

D. S3 gallop

E. Sustained left parasternal lift

Submit

A 54-year-old man comes to the emergency department due to severe fatigue and dyspnea. He has a long history of progressively worsening heart failure that has been resistant to treatment with medications, including diuretics. He was treated with chest radiation 10 years ago for non-Hodgkin lymphoma and has been in remission since then. The patient is admitted to the hospital, but his condition continues to deteriorate despite aggressive therapy. He dies 3 days later, and an autopsy is performed. Gross inspection of the heart shows dense, thick, fibrous tissue in the pericardial space between the visceral and parietal pericardium. Which of the following signs would most likely have been detected during a physical examination of this patient just prior to his death?

- ✓ A. Kussmaul sign (64%)
- B. Loud P2 (3%)
- C. Paradoxical splitting of S2 (11%)
- D. S3 gallop (13%)
- E. Sustained left parasternal lift (6%)

Omitted
Correct answer
A

64%
Answered correctly

05 secs
Time Spent

01/31/2020
Last Updated

Explanation

Constrictive pericarditis	
Etiology	• Idiopathic or viral pericarditis • Cardiac surgery or radiation therapy

1
2
3
4
5
6
7
8
9
10
11
12
13
14
15
16
17
18
19
20
21
22
23
24
25
26
27
28
29

Constrictive pericarditis	
Etiology	• Idiopathic or viral pericarditis • Cardiac surgery or radiation therapy • Tuberculosis (in endemic areas)
Pathogenesis	• Rigid pericardium prevents ventricular expansion and restricts diastolic filling • Predominantly right-sided manifestations
Physical examination	• ↑ Jugular venous pressure • Pericardial knock • Pulsus paradoxus • Kussmaul sign

The autopsy finding of thick, fibrous tissue in the pericardial space is consistent with **constrictive pericarditis**, a potential complication of chest radiation therapy for non-Hodgkin lymphoma. This dense, rigid pericardial tissue encases the heart and **restricts ventricular filling**, causing low cardiac output (manifesting with fatigue and dyspnea on exertion) and progressive **right-sided heart failure** (manifesting with hepatomegaly and peripheral edema).

Physical examination in constrictive pericarditis typically shows **elevated jugular venous pressure (JVP)** with prominent x and y descents and a **pericardial knock** (early diastolic sound that occurs before S3) and may also demonstrate **pulsus paradoxus** (>10 mm Hg drop in systolic blood pressure during inspiration). In addition, **Kussmaul sign** may be present. Under normal circumstances, the decrease in intrathoracic pressure during inspiration increases venous return to the right side of the heart and lowers JVP. However, in constrictive pericarditis, the rigid pericardium prevents the right side of the heart from accommodating increased venous return, which leads to a **paradoxical rise in JVP during inspiration**, referred to as Kussmaul sign.

(Choice B) A loud pulmonic component of the second heart sound (P2) is heard in patients with pulmonary hypertension.

(Choice C) During inspiration, venous return to the right side of the heart is increased, resulting in later closure of the pulmonic valve and physiologic splitting of the aortic (A2) and pulmonic components of S2. Paradoxical splitting occurs when cardiac pathology (eg, aortic stenosis,

1
2
3
4
5
6
7
8
9
10
11
12
13
14
15
16
17
18
19
20
21
22
23
24
25
26
27
28
29

The autopsy finding of thick, fibrous tissue in the pericardial space is consistent with **constrictive pericarditis**, a potential complication of chest radiation therapy for non-Hodgkin lymphoma. This dense, rigid pericardial tissue encases the heart and **restricts ventricular filling**, causing low cardiac output (manifesting with fatigue and dyspnea on exertion) and progressive **right-sided heart failure** (manifesting with hepatomegaly and peripheral edema).

Physical examination in constrictive pericarditis typically shows **elevated jugular venous pressure (JVP)** with prominent x and y descents and a **pericardial knock** (early diastolic sound that occurs before S3) and may also demonstrate **pulsus paradoxus** (>10 mm Hg drop in systolic blood pressure during inspiration). In addition, **Kussmaul sign** may be present. Under normal circumstances, the decrease in intrathoracic pressure during inspiration increases venous return to the right side of the heart and lowers JVP. However, in constrictive pericarditis, the rigid pericardium prevents the right side of the heart from accommodating increased venous return, which leads to a **paradoxical rise in JVP during inspiration**, referred to as Kussmaul sign.

(Choice B) A loud pulmonic component of the second heart sound (P2) is heard in patients with pulmonary hypertension.

(Choice C) During inspiration, venous return to the right side of the heart is increased, resulting in later closure of the pulmonic valve and physiologic splitting of the aortic (A2) and pulmonic components of S2. Paradoxical splitting occurs when cardiac pathology (eg, aortic stenosis, left bundle branch block) delays closure of the aortic valve, causing A2 to occur noticeably later than P2.

(Choice D) An S3 gallop occurs due to the sudden deceleration of blood as it enters a dilated ventricle; it is typically heard in patients with dilated cardiomyopathy or severe mitral regurgitation.

(Choice E) A sustained left parasternal lift is most commonly a sign of right ventricular hypertrophy, such as occurs with chronic right ventricular pressure overload (eg, pulmonary hypertension, pulmonic stenosis) or volume overload (eg, tricuspid regurgitation).

Educational objective:
In constrictive pericarditis, normal pericardium is replaced by dense, rigid pericardial tissue that restricts ventricular filling, leading to low cardiac output and progressive right-sided heart failure. Physical examination findings in such patients include elevated jugular venous pressure (JVP), pericardial knock, pulsus paradoxus, and a paradoxical rise in JVP with inspiration (Kussmaul sign).

References

- Constrictive pericarditis: diagnostic aspects and surgical results in 23 cases.

Physical examination in constrictive pericarditis typically shows **elevated jugular venous pressure (JVP)** with prominent x and y descents and a **pericardial knock** (early diastolic sound that occurs before S3) and may also demonstrate **pulsus paradoxus** (>10 mm Hg drop in systolic blood pressure during inspiration). In addition, **Kussmaul sign** may be present. Under normal circumstances, the decrease in intrathoracic pressure during inspiration increases venous return to the right side of the heart and lowers JVP. However, in constrictive pericarditis, the rigid pericardium prevents the right side of the heart from accommodating increased venous return, which leads to a **paradoxical rise in JVP during inspiration**, referred to as Kussmaul sign.

(Choice B) A loud pulmonic component of the second heart sound (P2) is heard in patients with pulmonary hypertension.

(Choice C) During inspiration, venous return to the right side of the heart is increased, resulting in later closure of the pulmonic valve and physiologic splitting of the aortic (A2) and pulmonic components of S2. Paradoxical splitting occurs when cardiac pathology (eg, aortic stenosis, left bundle branch block) delays closure of the aortic valve, causing A2 to occur noticeably later than P2.

(Choice D) An S3 gallop occurs due to the sudden deceleration of blood as it enters a dilated ventricle; it is typically heard in patients with dilated cardiomyopathy or severe mitral regurgitation.

(Choice E) A sustained left parasternal lift is most commonly a sign of right ventricular hypertrophy, such as occurs with chronic right ventricular pressure overload (eg, pulmonary hypertension, pulmonic stenosis) or volume overload (eg, tricuspid regurgitation).

Educational objective:
In constrictive pericarditis, normal pericardium is replaced by dense, rigid pericardial tissue that restricts ventricular filling, leading to low cardiac output and progressive right-sided heart failure. Physical examination findings in such patients include elevated jugular venous pressure (JVP), pericardial knock, pulsus paradoxus, and a paradoxical rise in JVP with inspiration (Kussmaul sign).

References

- Constrictive pericarditis: diagnostic aspects and surgical results in 23 cases.

Pathology	Cardiovascular System	Constrictive pericarditis
Subject	System	Topic

Copyright © UWorld. All rights reserved.

1
2
3
4
5
6
7
8
9
10
11
12
13
14
15
16
17
18
19
20
21
22
23
24
25
26
27
28
29

A 68-year-old man is brought to the emergency department with chest pain. For the last year, the patient has had exertional chest pain that has progressively worsened. He was shoveling snow this morning when the pain became unbearable. He has smoked a pack of cigarettes daily for 40 years. Blood pressure is 140/100 mm Hg and pulse is 90/min. Examination showed mild diaphoresis. The lungs are clear to auscultation. ECG shows ST-and T-wave changes suggestive of ischemia. Cardiac enzymes are elevated. Emergent coronary angiography is performed, which demonstrates significant atherosclerotic involvement of the left anterior descending and circumflex arteries. Development of these vascular lesions most likely involved growth factors released from which of the following sources?

A. B lymphocytes
B. Eosinophils
C. Erythrocytes
D. Mast cells
E. Neutrophils
F. Platelets

Submit

1
2
3
4
5
6
7
8
9
10
11
12
13
14
15
16
17
18
19
20
21
22
23
24
25
26
27
28
29

A 68-year-old man is brought to the emergency department with chest pain. For the last year, the patient has had exertional chest pain that has progressively worsened. He was shoveling snow this morning when the pain became unbearable. He has smoked a pack of cigarettes daily for 40 years. Blood pressure is 140/100 mm Hg and pulse is 90/min. Examination showed mild diaphoresis. The lungs are clear to auscultation. ECG shows ST-and T-wave changes suggestive of ischemia. Cardiac enzymes are elevated. Emergent coronary angiography is performed, which demonstrates significant atherosclerotic involvement of the left anterior descending and circumflex arteries. Development of these vascular lesions most likely involved growth factors released from which of the following sources?

A. B lymphocytes (2%)
B. Eosinophils (0%)
C. Erythrocytes (1%)
D. Mast cells (3%)
E. Neutrophils (23%)
✓ F. Platelets (68%)

Omitted
Correct answer
F

68%
Answered correctly

04 secs
Time Spent

05/17/2020
Last Updated

Explanation

Formation of atheroma

1
2
3
4
5
6
7
8
9
10
11
12
13
14
15
16
17
18
19
20
21
22
23
24
25
26
27
28
29

Formation of atheroma

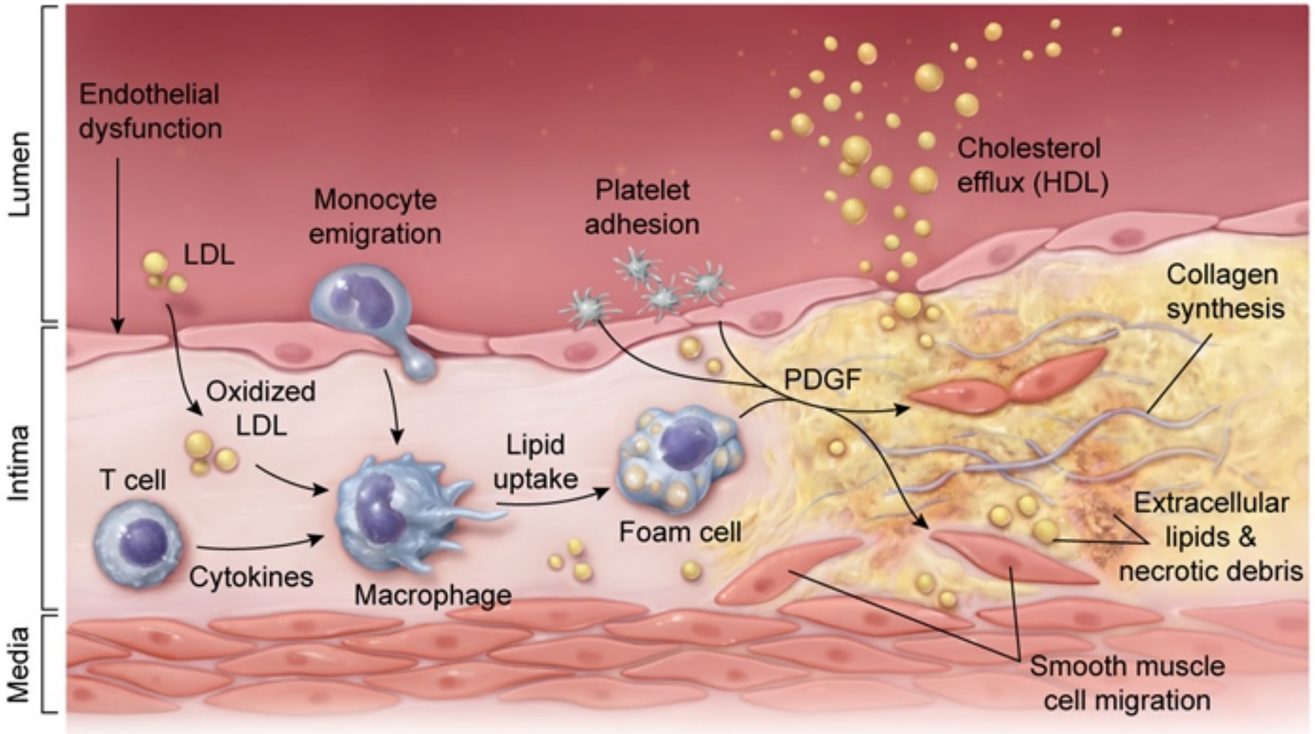

PDGF = platelet-derived growth factor.

©UWorld

The development of atherosclerotic plaque, or **atheroma**, involves a multistep process:

- Initially, factors including hyperlipidemia, hypertension, hyperglycemia, and smoking trigger **endothelial injury and/or dysfunction**. This leads to increased vascular permeability, enhanced leukocyte adhesion, and a higher propensity for thrombosis.
- Lipoproteins (ie, LDL and oxidized LDL) enter the arterial wall intima and begin to accumulate. Monocytes adhere to the endothelial wall and enter into the intima as well; these cells transform into macrophages and engulf lipid particles to become foam cells. **Platelets** adhere

©UWorld

The development of atherosclerotic plaque, or **atheroma**, involves a multistep process:

- Initially, factors including hyperlipidemia, hypertension, hyperglycemia, and smoking trigger **endothelial injury and/or dysfunction**. This leads to increased vascular permeability, enhanced leukocyte adhesion, and a higher propensity for thrombosis.
- Lipoproteins (ie, LDL and oxidized LDL) enter the arterial wall intima and begin to accumulate. Monocytes adhere to the endothelial wall and enter into the intima as well; these cells transform into macrophages and engulf lipid particles to become foam cells. **Platelets** adhere to the abnormal endothelium and become activated.
- Growth factors, namely **platelet-derived growth factor** (PDGF), are released from platelets, **activated macrophages**, and endothelial cells. This triggers **smooth muscle cell** (SMC) recruitment from the media and **proliferation** in the intima.

Over time, progressive SMC proliferation and accumulation of necrotic debris (due to macrophage/foam cell and SMC death) lead to growth of the atheroma. SMCs encourage plaque stability by synthesizing collagen, whereas activated inflammatory cells break down collagen and contribute to plaque instability. HDL likely extracts lipids from the intima back into the bloodstream and helps slow atheroma development.

(Choice A) B lymphocytes are not known to play a significant role in atheroma development. However, T lymphocytes in the arterial wall intima likely play a role in activating macrophages, endothelial cells, and SMCs by releasing inflammatory cytokines (eg, interferon-γ).

(Choices B and D) Eosinophils and mast cells are important in IgE-mediated (Type I) hypersensitivity reactions; mast cells release histamine in the early phase, and eosinophils release leukotrienes and major basic protein in the late phase of the reaction. However, these cells are not significantly involved in atheroma development.

(Choices C and E) Neither erythrocytes nor neutrophils release growth factors or play a significant role in atheroma development.

Educational objective:
During the development of atherosclerotic plaque (atheroma), activated macrophages, platelets, and endothelial cells release growth factors (eg, platelet-derived growth factor) that stimulate recruitment of smooth muscle cells from the arterial wall media and their subsequent proliferation in the intima.

Pathology	Cardiovascular System	Atherosclerosis
Subject	System	Topic

©UWorld

The development of atherosclerotic plaque, or **atheroma**, involves a multistep process:

- Initially, factors including hyperlipidemia, hypertension, hyperglycemia, and smoking trigger **endothelial injury and/or dysfunction**. This leads to increased vascular permeability, enhanced leukocyte adhesion, and a higher propensity for thrombosis.
- Lipoproteins (ie, LDL and oxidized LDL) enter the arterial wall intima and begin to accumulate. Monocytes adhere to the endothelial wall and enter into the intima as well; these cells transform into macrophages and engulf lipid particles to become foam cells. **Platelets** adhere to the abnormal endothelium and become activated.
- Growth factors, namely **platelet-derived growth factor** (PDGF), are released from platelets, **activated macrophages**, and endothelial cells. This triggers **smooth muscle cell** (SMC) recruitment from the media and **proliferation** in the intima.

Over time, progressive SMC proliferation and accumulation of necrotic debris (due to macrophage/foam cell and SMC death) lead to growth of the atheroma. SMCs encourage plaque stability by synthesizing collagen, whereas activated inflammatory cells break down collagen and contribute to plaque instability. HDL likely extracts lipids from the intima back into the bloodstream and helps slow atheroma development.

(Choice A) B lymphocytes are not known to play a significant role in atheroma development. However, T lymphocytes in the arterial wall intima likely play a role in activating macrophages, endothelial cells, and SMCs by releasing inflammatory cytokines (eg, interferon-γ).

(Choices B and D) Eosinophils and mast cells are important in IgE-mediated (Type I) hypersensitivity reactions; mast cells release histamine in the early phase, and eosinophils release leukotrienes and major basic protein in the late phase of the reaction. However, these cells are not significantly involved in atheroma development.

(Choices C and E) Neither erythrocytes nor neutrophils release growth factors or play a significant role in atheroma development.

Educational objective:
During the development of atherosclerotic plaque (atheroma), activated macrophages, platelets, and endothelial cells release growth factors (eg, platelet-derived growth factor) that stimulate recruitment of smooth muscle cells from the arterial wall media and their subsequent proliferation in the intima.

Pathology	Cardiovascular System	Atherosclerosis
Subject	System	Topic

©UWorld

The development of atherosclerotic plaque, or **atheroma**, involves a multistep process:

- Initially, factors including hyperlipidemia, hypertension, hyperglycemia, and smoking trigger **endothelial injury and/or dysfunction**. This leads to increased vascular permeability, enhanced leukocyte adhesion, and a higher propensity for thrombosis.
- Lipoproteins (ie, LDL and oxidized LDL) enter the arterial wall intima and begin to accumulate. Monocytes adhere to the endothelial wall and enter into the intima as well; these cells transform into macrophages and engulf lipid particles to become foam cells. **Platelets** adhere to the abnormal endothelium and become activated.
- Growth factors, namely **platelet-derived growth factor** (PDGF), are released from platelets, **activated macrophages**, and endothelial cells. This triggers **smooth muscle cell** (SMC) recruitment from the media and **proliferation** in the intima.

Over time, progressive SMC proliferation and accumulation of necrotic debris (due to macrophage/foam cell and SMC death) lead to growth of the atheroma. SMCs encourage plaque stability by synthesizing collagen, whereas activated inflammatory cells break down collagen and contribute to plaque instability. HDL likely extracts lipids from the intima back into the bloodstream and helps slow atheroma development.

(Choice A) B lymphocytes are not known to play a significant role in atheroma development. However, T lymphocytes in the arterial wall intima likely play a role in activating macrophages, endothelial cells, and SMCs by releasing inflammatory cytokines (eg, interferon-γ).

(Choices B and D) Eosinophils and mast cells are important in IgE-mediated (Type I) hypersensitivity reactions; mast cells release histamine in the early phase, and eosinophils release leukotrienes and major basic protein in the late phase of the reaction. However, these cells are not significantly involved in atheroma development.

(Choices C and E) Neither erythrocytes nor neutrophils release growth factors or play a significant role in atheroma development.

Educational objective:
During the development of atherosclerotic plaque (atheroma), activated macrophages, platelets, and endothelial cells release growth factors (eg, platelet-derived growth factor) that stimulate recruitment of smooth muscle cells from the arterial wall media and their subsequent proliferation in the intima.

Pathology	Cardiovascular System	Atherosclerosis
Subject	System	Topic

1
2
3
4
5
6
7
8
9
10
11
12
13
14
15
16
17
18
19
20
21
22
23
24
25
26
27
28
29

A 57-year-old unconscious man is brought to the emergency department by his wife. Thirty minutes prior, the patient developed severe chest pain and asked to be taken to the hospital. On the way, he became unresponsive. According to his wife, the patient had been having intermittent, short-lived episodes of chest pain over the past several days. The patient's medical history is significant for hypertension, type 2 diabetes mellitus, and hypercholesterolemia. He is not adherent with medications or follow-up. In the emergency department, the patient has no spontaneous respirations or circulation and is pronounced dead. An autopsy examination is performed, and a cross-section of the mid-right coronary artery is shown in the exhibit. Which of the following is the most likely immediate cause of death in this patient?

A. Atrial fibrillation
B. Cardiac free wall rupture
C. Embolic stroke
D. Regional contractile dysfunction
E. Ventricular fibrillation
F. Ventricular septal rupture

Submit

1
2
3
4
5
6
7
8
9
10
11
12
13
14
15
16
17
18
19
20
21
22
23
24
25
26
27
28
29

Exhibit Display

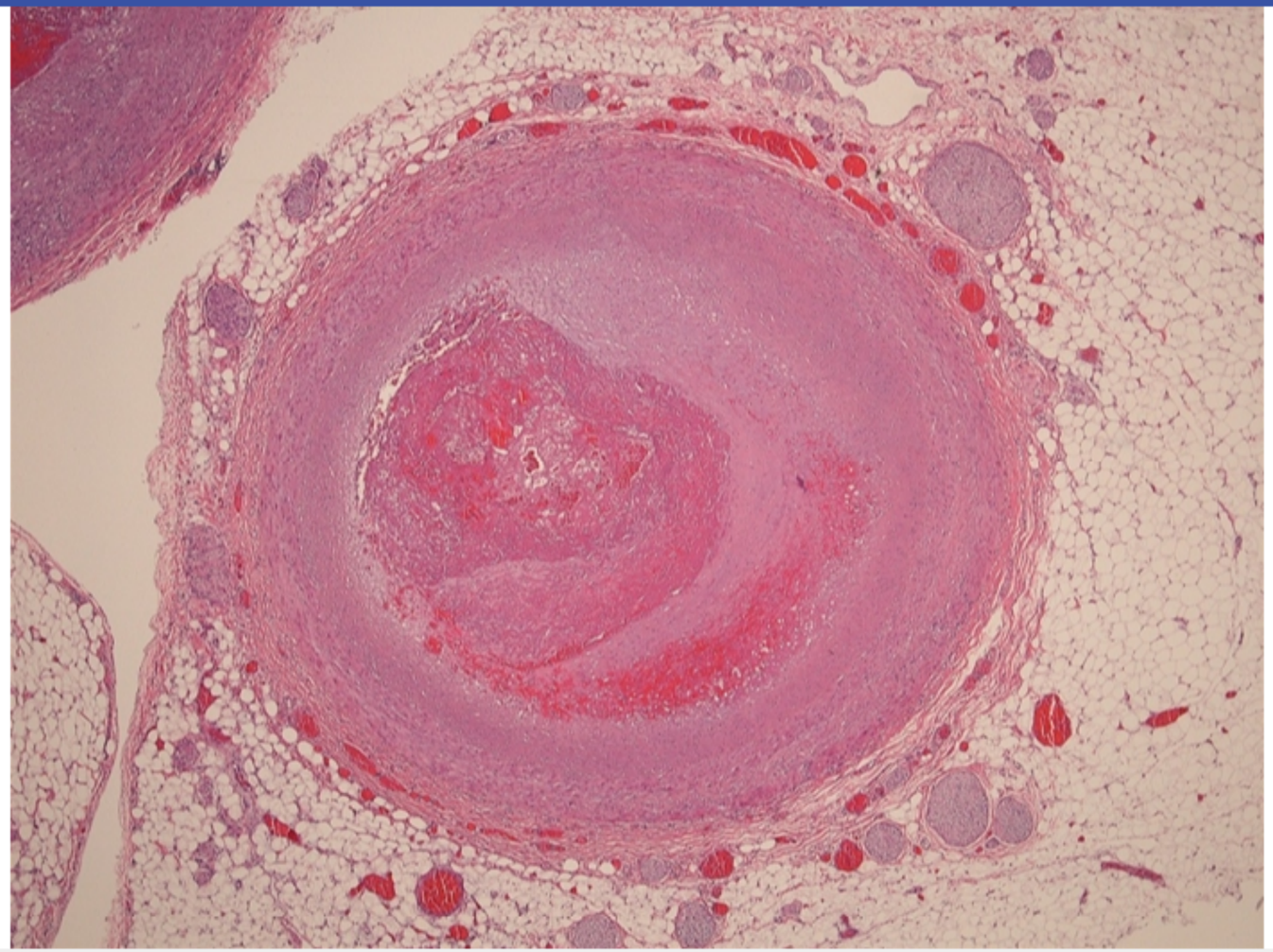

Zoom In | Zoom Out | Reset | Add To New Card | Existing Card

1 2 3 4 5 6 7 8 9 10 11 12 13 14 15 16 17 18 19 20 21 22 23 24 25 26 27 28 29

A 57-year-old unconscious man is brought to the emergency department by his wife. Thirty minutes prior, the patient developed severe chest pain and asked to be taken to the hospital. On the way, he became unresponsive. According to his wife, the patient had been having intermittent, short-lived episodes of chest pain over the past several days. The patient's medical history is significant for hypertension, type 2 diabetes mellitus, and hypercholesterolemia. He is not adherent with medications or follow-up. In the emergency department, the patient has no spontaneous respirations or circulation and is pronounced dead. An autopsy examination is performed, and a cross-section of the mid-right coronary artery is shown in the exhibit. Which of the following is the most likely immediate cause of death in this patient?

- A. Atrial fibrillation (8%)
- B. Cardiac free wall rupture (5%)
- C. Embolic stroke (15%)
- D. Regional contractile dysfunction (13%)
- ✓ E. Ventricular fibrillation (55%)
- F. Ventricular septal rupture (1%)

Omitted
Correct answer
E

55%
Answered correctly

10 secs
Time Spent

01/27/2020
Last Updated

Explanation

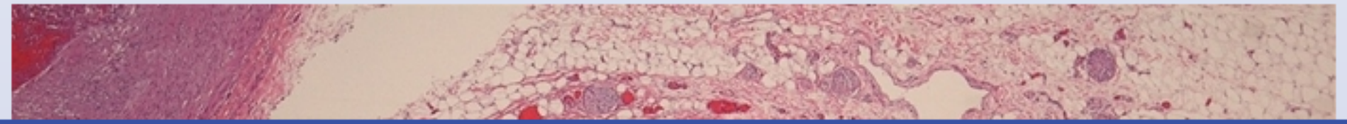

1
2
3
4
5
6
7
8
9
10
11
12
13
14
15
16
17
18
19
20
21
22
23
24
25
26
27
28
29

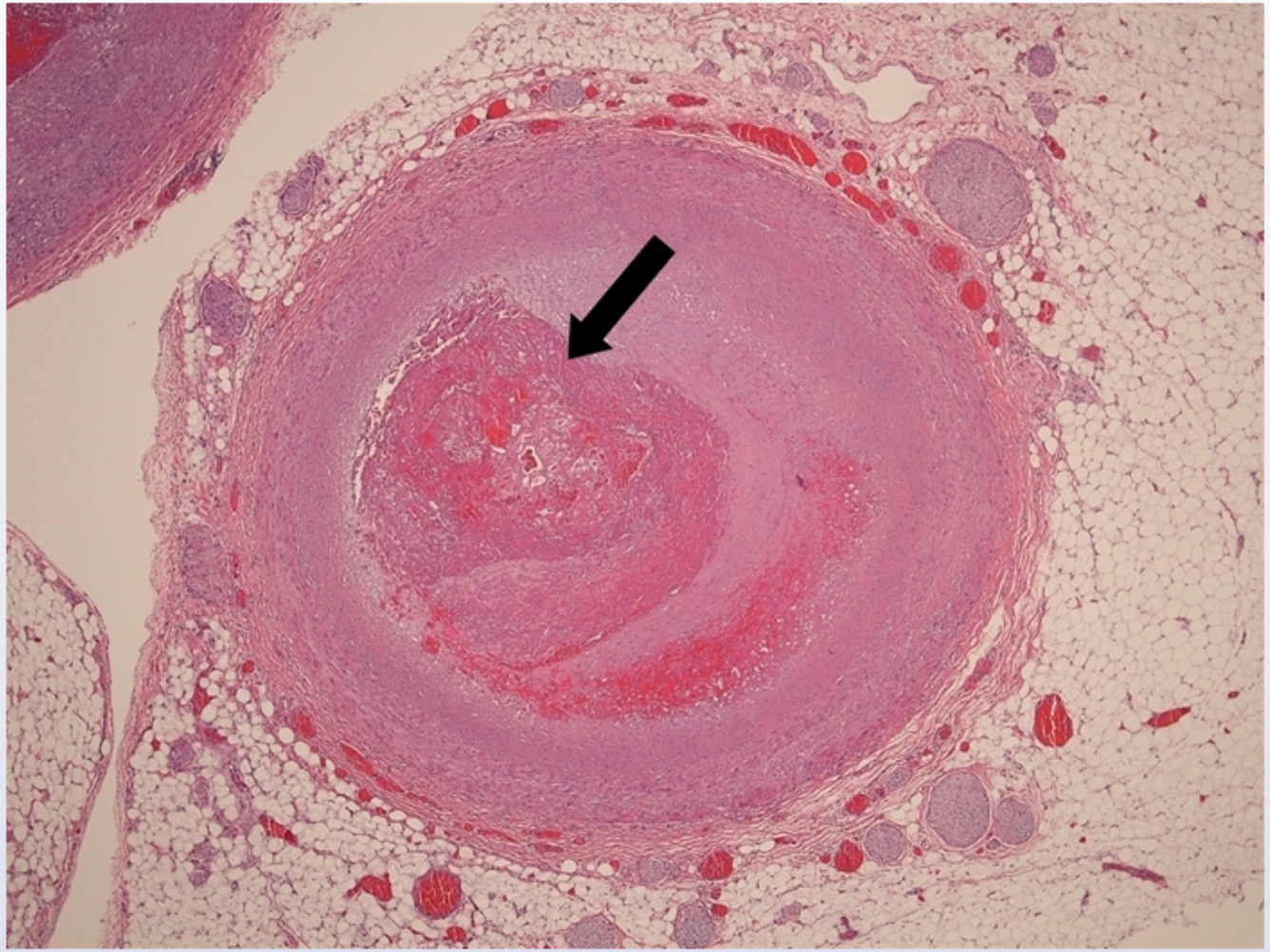

This patient's clinical features are suggestive of **coronary artery disease** (chest pain and multiple risk factors) causing an **acute myocardial infarction** (MI). The diagnosis is confirmed by autopsy showing a large atheromatous plaque with superimposed thrombosis causing complete obstruction of the right coronary artery.

This patient's clinical features are suggestive of **coronary artery disease** (chest pain and multiple risk factors) causing an **acute myocardial infarction** (MI). The diagnosis is confirmed by autopsy showing a large atheromatous plaque with superimposed thrombosis causing complete obstruction of the right coronary artery.

Acute MI is a common cause of **sudden cardiac death** (SCD) (the abrupt cessation of organized cardiac activity leading to hemodynamic collapse and inadequate tissue perfusion). SCD due to acute MI usually results from a malignant ventricular arrhythmia (ie, **ventricular fibrillation** or ventricular tachycardia degenerating to ventricular fibrillation) that is triggered by **electrical instability** in the ischemic myocardium.

(Choice A) Atrial fibrillation can sometimes occur during acute MI; however, organ perfusion is usually maintained and it is not a common cause of SCD.

(Choices B and F) Ventricular septal rupture (most common with left anterior descending artery occlusion) and cardiac free wall rupture are mechanical complications of acute MI that typically occur several days following the event. Septal rupture can sometimes occur acutely, but it is likely to cause symptomatic cardiogenic shock (eg, hypotension, respiratory distress/failure) rather than SCD.

(Choice C) Embolic stroke can result from embolization of a left ventricular (LV) mural thrombus that forms in an area of infarcted and akinetic myocardium. However, LV thrombus typically takes several days to form, and embolic stroke does not typically lead to SCD.

(Choice D) Acute MI commonly causes regional contractile dysfunction in the area of myocardium supplied by the affected artery. Infarction involving >50% of the myocardium (eg, proximal left anterior descending artery occlusion) can cause ventricular failure and cardiogenic shock. However, a mid right coronary artery obstruction is less likely to result in severe LV dysfunction.

Educational objective:
Ventricular fibrillation is the most common mechanism of sudden cardiac death due to acute myocardial infarction. It results from arrhythmogenic foci triggered by electrical instability in the ischemic myocardium.

References

- Incidence and prognosis of early primary ventricular fibrillation in acute myocardial infarction—results of the Gruppo Italiano per lo Studio della Sopravvivenza nell'Infarto Miocardico (GISSI-2) database.

This patient's clinical featu
infarction (MI). The diag
obstruction of the right co

Acute MI is a common ca
collapse and inadequate t
fibrillation or ventricular t

(Choice A) Atrial fibrillati
of SCD.

(Choices B and F) Ventr
mechanical complications
likely to cause symptomat

(Choice C) Embolic strok
myocardium. However, L

(Choice D) Acute MI com
involving >50% of the myo
However, a mid right coro

Educational objective:
Ventricular fibrillation is th
foci triggered by electrical

References

- Incidence and progno
Sopravvivenza nell'Infarto Miocardico (GISSI-2) database.

Exhibit Display

Mechanical complications of acute myocardial infarction

Complication	Time frame	Clinical findings
Right ventricular failure	Acute	• Hypotension • Clear lungs • Kussmaul sign
Papillary muscle rupture	Acute or within 3-5 days	• Severe MR with flail leaflet • New holosystolic murmur • Severe pulmonary edema
Interventricular septal rupture	Acute or within 3-5 days	• Chest pain • New holosystolic murmur • Biventricular failure, shock • Step up in O_2 level from RA to RV
Ventricular free-wall rupture	Within 5 days or up to 2 weeks	• Chest pain • Tamponade, shock • Distant heart sounds
Left ventricular aneurysm	Within several months	• Subacute heart failure • Stable angina

MR = mitral regurgitation; **RA** = right atrium; **RV** = right ventricle.

Add To New Card | Existing Card

1 2 3 4 5 6 7 8 9 10 11 12 13 14 15 16 17 18 19 20 21 22 23 24 25 26 27 28 29

A 42-year-old man is found dead at home. His medical problems included hypertension and dyslipidemia, but he had been noncompliant with his medications. The patient had a lengthy smoking history and, despite constant urging from his physicians to stop smoking, he had only quit recently. An autopsy is requested by the family. Pathological examination shows complete thrombotic occlusion of the left main coronary artery and diffuse atherosclerotic vascular disease characterized by multiple atheromas. Along with a lipid core, these atheromas have a fibrous cap formed from dense deposition of collagen. Which of the following cells are directly responsible for synthesizing this fibrous cap?

A. Endothelial cells
B. Interstitial fibroblasts
C. Macrophages
D. Smooth muscle cells
E. T lymphocytes

Submit

A 42-year-old man is found dead at home. His medical problems included hypertension and dyslipidemia, but he had been noncompliant with his medications. The patient had a lengthy smoking history and, despite constant urging from his physicians to stop smoking, he had only quit recently. An autopsy is requested by the family. Pathological examination shows complete thrombotic occlusion of the left main coronary artery and diffuse atherosclerotic vascular disease characterized by multiple atheromas. Along with a lipid core, these atheromas have a fibrous cap formed from dense deposition of collagen. Which of the following cells are directly responsible for synthesizing this fibrous cap?

- A. Endothelial cells (7%)
- B. Interstitial fibroblasts (45%)
- C. Macrophages (13%)
- ✓ D. Smooth muscle cells (33%)
- E. T lymphocytes (0%)

Omitted
Correct answer
D

33%
Answered correctly

02 secs
Time Spent

01/29/2020
Last Updated

Explanation



Explanation

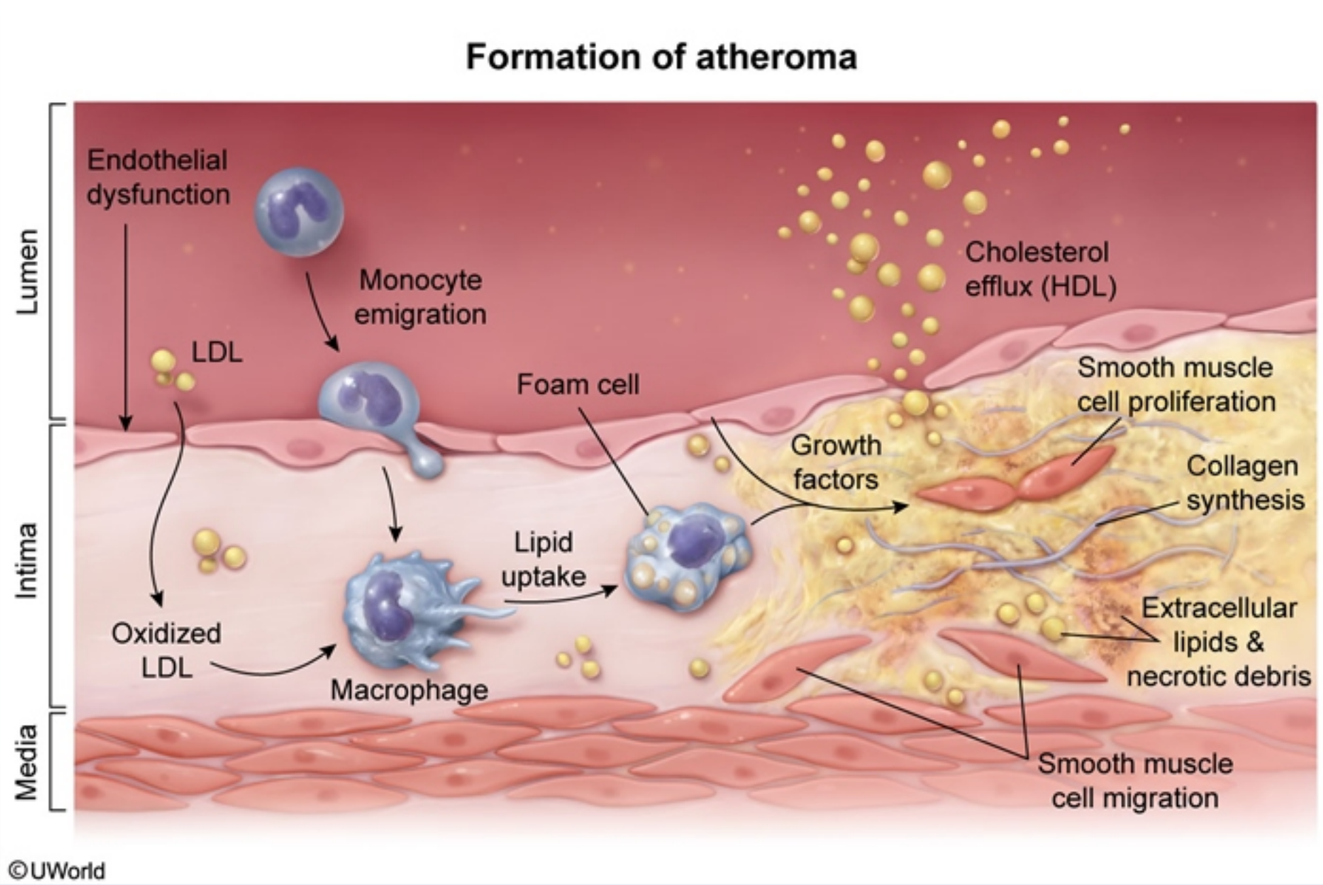

Atherosclerosis is a chronic inflammatory and fibroproliferative disease. Endothelial cells, vascular smooth muscle cells (VSMCs), and leukocytes play an important role in the development and progression of this disease. The process is initiated by chronic hemodynamic stress and hyperlipidemia, which cause **endothelial cell injury**. This leads to increased expression of surface vascular cell-adhesion molecules (VCAMs) that allow adherence and migration of **monocytes** and T lymphocytes into the intima. The infiltrating leukocytes and dysfunctional endothelium release cytokines and growth factors (eg, platelet-derived growth factor, fibroblast growth factor, endothelin-1, interleukin-1) that promote

Atherosclerosis is a chronic inflammatory and fibroproliferative disease. Endothelial cells, vascular smooth muscle cells (VSMCs), and leukocytes play an important role in the development and progression of this disease. The process is initiated by chronic hemodynamic stress and hyperlipidemia, which cause **endothelial cell injury**. This leads to increased expression of surface vascular cell-adhesion molecules (VCAMs) that allow adherence and migration of **monocytes** and T lymphocytes into the intima. The infiltrating leukocytes and dysfunctional endothelium release cytokines and growth factors (eg, platelet-derived growth factor, fibroblast growth factor, endothelin-1, interleukin-1) that promote **migration and proliferation** of **VSMCs** within the intima. VSMCs are also stimulated to synthesize extracellular matrix proteins (eg, **collagen**, elastin, proteoglycans) that form the fibrous cap typical of mature atheromas. Disruption of the fibrous cap with luminal thrombosis **(atherosclerotic plaque rupture)** has catastrophic clinical consequences and is responsible for the majority of acute coronary syndrome cases and sudden cardiac deaths.

(Choice A) Endothelial cell dysfunction is the earliest pathophysiologic change that precedes the formation of atherosclerotic lesions. Endothelial injury results in increased lipid permeability, leukocyte (monocytes, T cells) and platelet recruitment, and migration and proliferation of VSMC from media to the intima. However, the VSMCs are directly responsible for the synthesis of new collagen.

(Choice B) Fibroblasts are found infrequently in the tunica intima of blood vessels and are not significantly involved in atherosclerosis pathogenesis.

(Choices C and E) Activated macrophages and T lymphocytes secrete growth factors that recruit the VSMCs responsible for forming the fibrous cap, but they are not directly responsible for the dense deposition of fibrillar collagen. Macrophages also produce matrix metalloproteinases and tissue factors that degrade the extracellular matrix, causing the formation of a large, soft lipid-rich core with thinning of the fibrous cap. Such vulnerable plaques have an increased propensity for rupture.

Educational objective:
Vascular smooth muscle cells (VSMCs) are the only cells within the atherosclerotic plaque capable of synthesizing structurally important collagen isoforms and other matrix components. Progressive enlargement of the plaque results in remodeling of the extracellular matrix and VSMC death, promoting development of vulnerable plaques with an increased propensity for rupture.

References

- The role of vascular smooth muscle cells on the pathogenesis of atherosclerosis.
- Pathogenesis of atherosclerosis.

migration and proliferation of **VSMCs** within the intima. VSMCs are also stimulated to synthesize extracellular matrix proteins (eg, **collagen**, elastin, proteoglycans) that form the fibrous cap typical of mature atheromas. Disruption of the fibrous cap with luminal thrombosis **(atherosclerotic plaque rupture)** has catastrophic clinical consequences and is responsible for the majority of acute coronary syndrome cases and sudden cardiac deaths.

(Choice A) Endothelial cell dysfunction is the earliest pathophysiologic change that precedes the formation of atherosclerotic lesions. Endothelial injury results in increased lipid permeability, leukocyte (monocytes, T cells) and platelet recruitment, and migration and proliferation of VSMC from media to the intima. However, the VSMCs are directly responsible for the synthesis of new collagen.

(Choice B) Fibroblasts are found infrequently in the tunica intima of blood vessels and are not significantly involved in atherosclerosis pathogenesis.

(Choices C and E) Activated macrophages and T lymphocytes secrete growth factors that recruit the VSMCs responsible for forming the fibrous cap, but they are not directly responsible for the dense deposition of fibrillar collagen. Macrophages also produce matrix metalloproteinases and tissue factors that degrade the extracellular matrix, causing the formation of a large, soft lipid-rich core with thinning of the fibrous cap. Such vulnerable plaques have an increased propensity for rupture.

Educational objective:
Vascular smooth muscle cells (VSMCs) are the only cells within the atherosclerotic plaque capable of synthesizing structurally important collagen isoforms and other matrix components. Progressive enlargement of the plaque results in remodeling of the extracellular matrix and VSMC death, promoting development of vulnerable plaques with an increased propensity for rupture.

References

- The role of vascular smooth muscle cells on the pathogenesis of atherosclerosis.
- Pathogenesis of atherosclerosis.

Pathology	Cardiovascular System	Coronary artery disease
Subject	System	Topic

Copyright © UWorld. All rights reserved.

7
8
9
10
11
12
13
14
15
16
17
18
19
20
21
22
23
24
25
26
27
28
29
30
31
32
33
34
35

A 6-year-old boy is evaluated in the office for difficulty hearing. The patient has no ear pain, discharge, or upper respiratory symptoms. Initial testing suggests that he has bilateral sensorineural hearing loss. He has no motor deficits or cerebellar signs. His paternal uncle died suddenly at age 12. Examination of the ears, nose, and throat is normal. ECG shows normal sinus rhythm with a prolonged QT interval (520 msec). Echocardiogram shows normal left and right ventricular function with no significant valvular disease. A genetic defect affecting which of the following is most likely present in this patient?

A. Calcium channels
B. Membrane anchoring protein
C. Potassium channels
D. Sodium channels
E. Sodium-potassium ATPase

Submit

7
8
9
10
11
12
13
14
15
16
17
18
19
20
21
22
23
24
25
26
27
28
29
30
31
32
33
34
35

A 6-year-old boy is evaluated in the office for difficulty hearing. The patient has no ear pain, discharge, or upper respiratory symptoms. Initial testing suggests that he has bilateral sensorineural hearing loss. He has no motor deficits or cerebellar signs. His paternal uncle died suddenly at age 12. Examination of the ears, nose, and throat is normal. ECG shows normal sinus rhythm with a prolonged QT interval (520 msec). Echocardiogram shows normal left and right ventricular function with no significant valvular disease. A genetic defect affecting which of the following is most likely present in this patient?

A. Calcium channels (8%)
B. Membrane anchoring protein (5%)
✓ C. Potassium channels (70%)
D. Sodium channels (8%)
E. Sodium-potassium ATPase (6%)

Omitted
Correct answer
C

70%
Answered correctly

03 secs
Time Spent

01/10/2020
Last Updated

Explanation

7
8
9
10
11
12
13
14
15
16
17
18
19
20
21
22
23
24
25
26
27
28
29
30
31
32
33
34
35

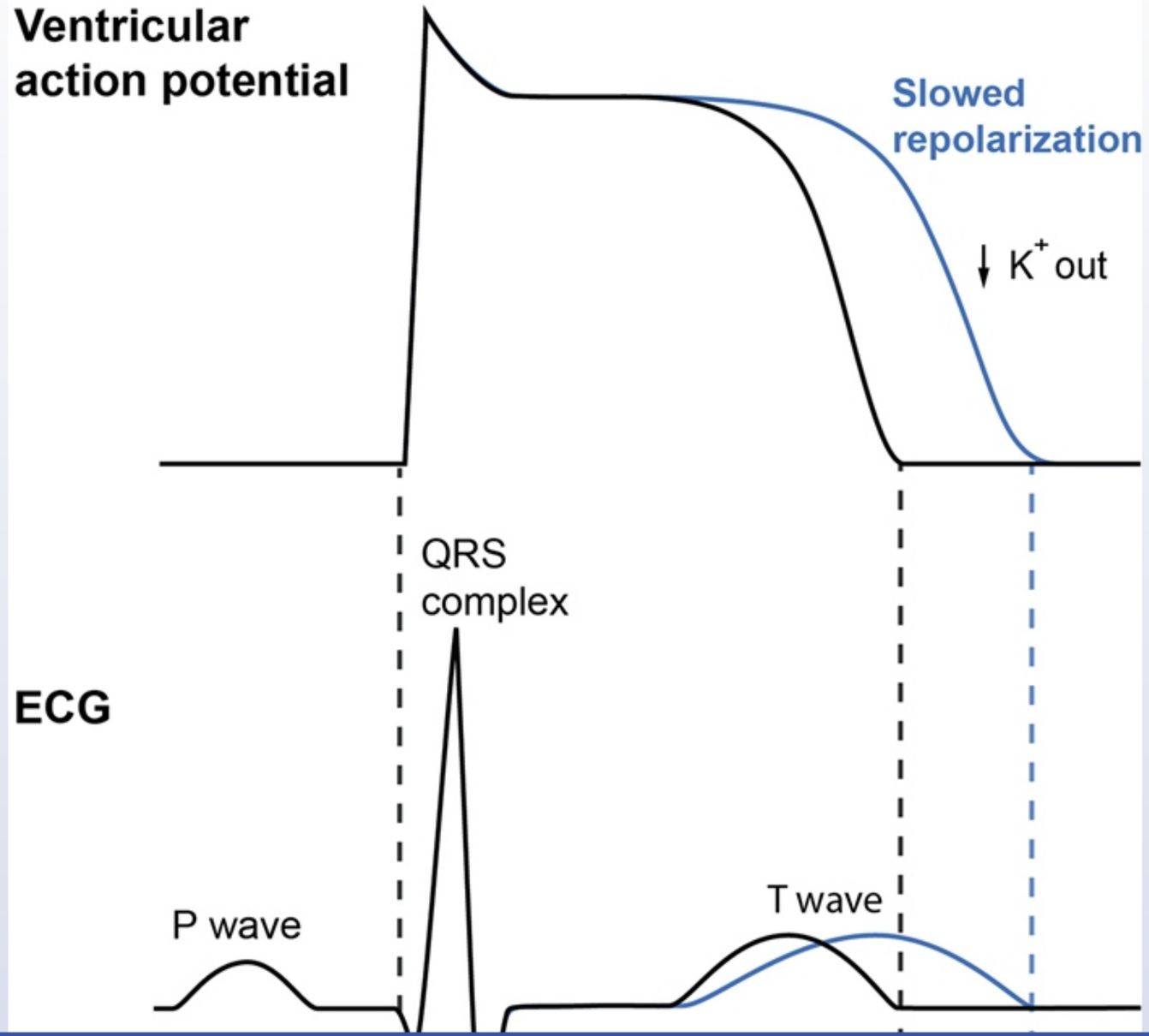

7
8
9
10
11
12
13
14
15
16
17
18
19
20
21
22
23
24
25
26
27
28
29
30
31
32
33
34
35

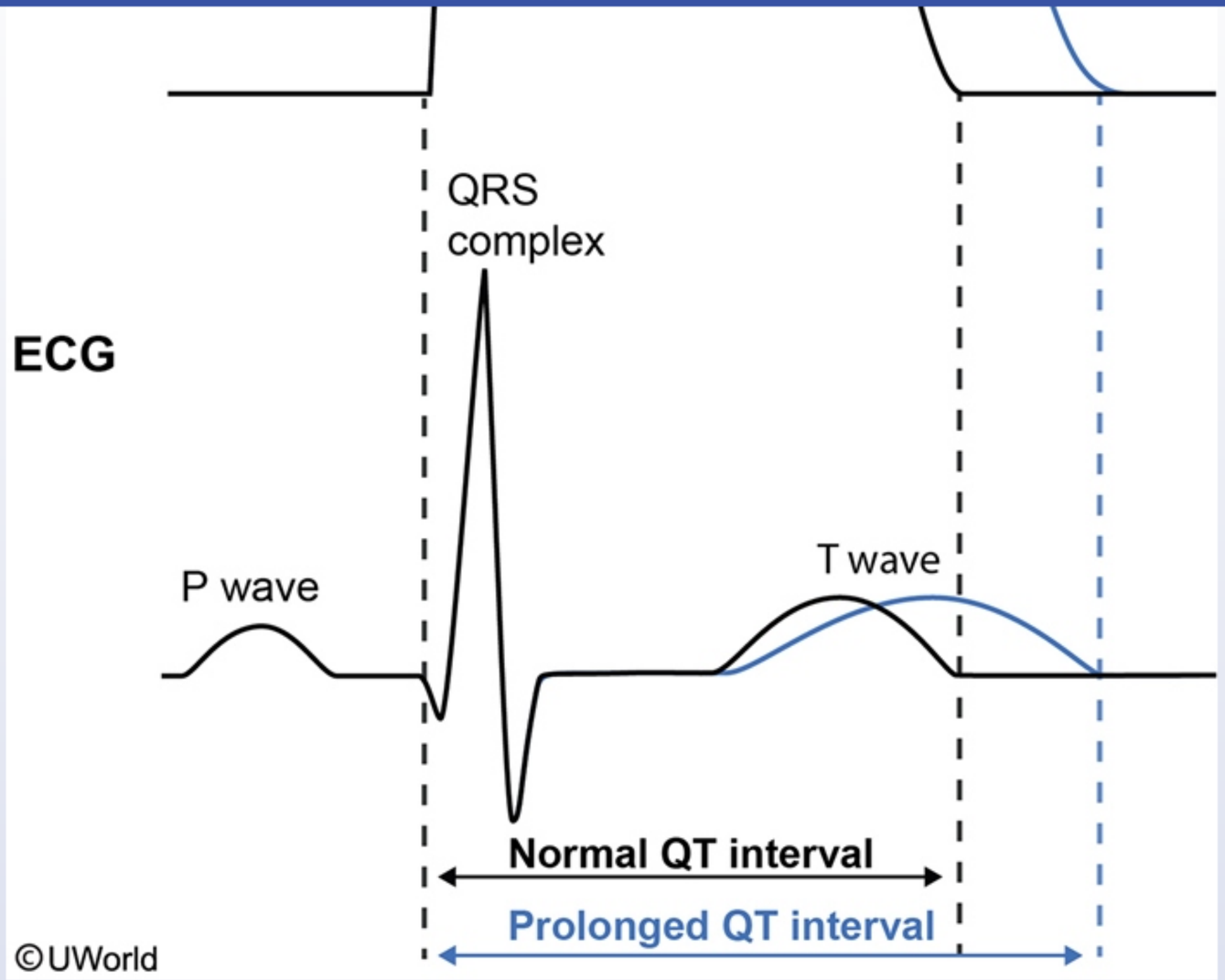

This patient's clinical presentation is suggestive of **Jervell and Lange-Nielsen syndrome**, an autosomal recessive disorder characterized by profound bilateral **sensorineural hearing loss** and **congenital long QT syndrome**, which predisposes individuals to syncope and sudden cardiac death.

7
8
9
10
11
12
13
14
15
16
17
18
19
20
21
22
23
24
25
26
27
28
29
30
31
32
33
34
35

This patient's clinical presentation is suggestive of **Jervell and Lange-Nielsen syndrome**, an autosomal recessive disorder characterized by profound bilateral **sensorineural hearing loss** and **congenital long QT syndrome**, which predisposes individuals to syncope and sudden cardiac death.

This syndrome occurs secondary to **mutations** in genes (eg, KCNQ1, KCNE1) that encode the alpha and beta subunits of **voltage-gated potassium channels**. These subunits contribute to the slow-acting component of the outward-rectifying potassium current, which is responsible for ventricular repolarization during phase 3 of the cardiac action potential. Mutations in the potassium channel lead to a decrease in potassium current with prolongation of action potential duration and the QT interval. QT interval prolongation predisposes to the development of life-threatening **ventricular arrhythmias**, such as torsades de pointes and ventricular fibrillation.

(Choices A and D) Brugada syndrome is an autosomal dominant condition that can be associated with mutations in cardiac sodium or L-type calcium channels, leading to characteristic ECG changes (eg, pseudo right bundle branch block, ST-segment elevation in leads V1-V3) and an increased risk of ventricular tachyarrhythmias and sudden cardiac death.

(Choice B) Duchenne muscular dystrophy is an X-linked disorder caused by mutations in dystrophin, a structural membrane protein that stabilizes the plasma membrane of myocytes. Patients typically present with progressive proximal muscle degeneration and weakness. Additional features may include cardiomyopathy and conduction abnormalities.

(Choice E) Genetic defects in the sodium-potassium ATPase pump typically are not associated with long QT syndrome. Cardiac glycosides (eg, digoxin) inhibit the sodium-potassium ATPase in myocardial cells, resulting in a mild increase in intracellular sodium and subsequent inhibition of the sodium-calcium exchanger. This leads to increased intracellular calcium and cardiac contractility, which can help reduce symptoms in patients with advanced systolic heart failure.

Educational objective:
Jervell and Lange-Nielsen syndrome is an autosomal recessive disorder characterized by profound bilateral sensorineural hearing loss and congenital long QT syndrome, which predisposes to ventricular arrhythmias and sudden cardiac death. This condition occurs secondary to mutations in genes that encode voltage-gated potassium channels.

References

- The long QT syndromes: genetic basis and clinical implications.

7
8
9
10
11
12
13
14
15
16
17
18
19
20
21
22
23
24
25
26
27
28
29
30
31
32
33
34
35

threatening **ventricular arrhythmias**, such as torsades de pointes and ventricular fibrillation.

(Choices A and D) Brugada syndrome is an autosomal dominant condition that can be associated with mutations in cardiac sodium or L-type calcium channels, leading to characteristic ECG changes (eg, pseudo right bundle branch block, ST-segment elevation in leads V1-V3) and an increased risk of ventricular tachyarrhythmias and sudden cardiac death.

(Choice B) Duchenne muscular dystrophy is an X-linked disorder caused by mutations in dystrophin, a structural membrane protein that stabilizes the plasma membrane of myocytes. Patients typically present with progressive proximal muscle degeneration and weakness. Additional features may include cardiomyopathy and conduction abnormalities.

(Choice E) Genetic defects in the sodium-potassium ATPase pump typically are not associated with long QT syndrome. Cardiac glycosides (eg, digoxin) inhibit the sodium-potassium ATPase in myocardial cells, resulting in a mild increase in intracellular sodium and subsequent inhibition of the sodium-calcium exchanger. This leads to increased intracellular calcium and cardiac contractility, which can help reduce symptoms in patients with advanced systolic heart failure.

Educational objective:
Jervell and Lange-Nielsen syndrome is an autosomal recessive disorder characterized by profound bilateral sensorineural hearing loss and congenital long QT syndrome, which predisposes to ventricular arrhythmias and sudden cardiac death. This condition occurs secondary to mutations in genes that encode voltage-gated potassium channels.

References

- The long QT syndromes: genetic basis and clinical implications.
- A spectrum of functional effects for disease causing mutations in the Jervell and Lange-Nielsen syndrome.
- Genetics and cardiac channelopathies.

Pathology	Cardiovascular System	Long QT syndrome
Subject	System	Topic

Copyright © UWorld. All rights reserved.

7
8
9
10
11
12
13
14
15
16
17
18
19
20
21
22
23
24
25
26
27
28
29
30
31
32
33
34
35

©UW

This patient's clinical pres
profound bilateral **sensori**
cardiac death.

This syndrome occurs sec
potassium channels. Th
for ventricular repolarizatio
current with prolongation o
threatening **ventricular ar**

(Choices A and D) Bruga
calcium channels, leading
increased risk of ventricula

(Choice B) Duchenne mu
stabilizes the plasma mem
Additional features may in

(Choice E) Genetic defec
digoxin) inhibit the sodium
the sodium-calcium excha
with advanced systolic heart failure.

Educational objective:

Exhibit Display

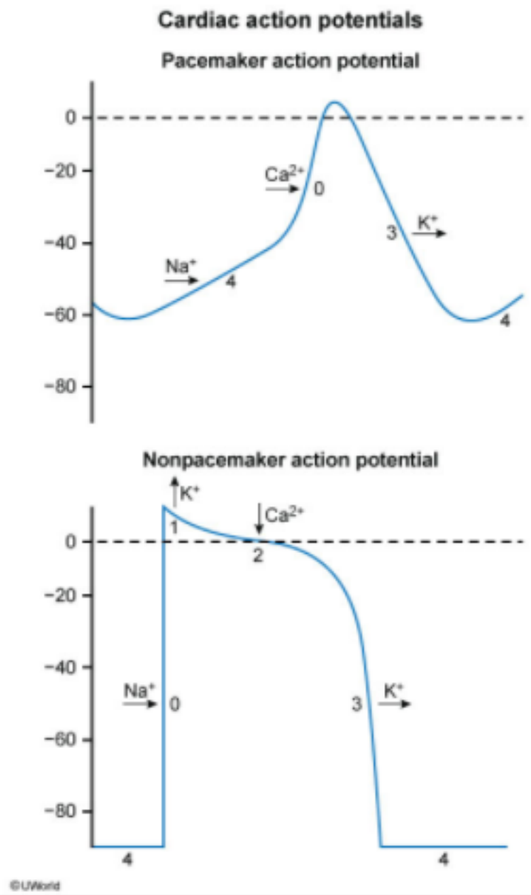

Zoom In | Zoom Out | Reset | Add To New Card | Existing Card

7
8
9
10
11
12
13
14
15
16
17
18
19
20
21
22
23
24
25
26
27
28
29
30
31
32
33
34
35

A 38-year-old woman comes to the office due to worsening shortness of breath over the past 4 weeks. She has no chest pain or lightheadedness but has noticed some ankle puffiness. The patient can hardly do chores without having to stop to catch her breath. Medical history is unremarkable. She delivered a healthy child 2 months ago without complications. The patient is a lifetime nonsmoker and does not use alcohol. She has no family history of early heart disease or sudden cardiac death. Blood pressure is 96/60 mm Hg and pulse is 92/min and regular. The apical impulse is palpated along the anterior axillary line, and S3 is heard at the apex. There are no heart murmurs. Which of the following best describes the left ventricular changes in this patient?

	Ejection fraction	Compliance
A.	Decreased	Increased
B.	Decreased	Normal
C.	Normal	Decreased
D.	Normal	Increased
E.	Normal	Normal

Submit

7
8
9
10
11
12
13
14
15
16
17
18
19
20
21
22
23
24
25
26
27
28
29
30
31
32
33
34
35

A 38-year-old woman comes to the office due to worsening shortness of breath over the past 4 weeks. She has no chest pain or lightheadedness but has noticed some ankle puffiness. The patient can hardly do chores without having to stop to catch her breath. Medical history is unremarkable. She delivered a healthy child 2 months ago without complications. The patient is a lifetime nonsmoker and does not use alcohol. She has no family history of early heart disease or sudden cardiac death. Blood pressure is 96/60 mm Hg and pulse is 92/min and regular. The apical impulse is palpated along the anterior axillary line, and S3 is heard at the apex. There are no heart murmurs. Which of the following best describes the left ventricular changes in this patient?

	Ejection fraction	Compliance
✓ A. (57%)	Decreased	Increased
B. (18%)	Decreased	Normal
C. (13%)	Normal	Decreased
D. (8%)	Normal	Increased
E. (2%)	Normal	Normal

Omitted
Correct answer
A

57%
Answered correctly

02 secs
Time Spent

02/11/2020
Last Updated

Explanation

7
8
9
10
11
12
13
14
15
16
17
18
19
20
21
22
23
24
25
26
27
28
29
30
31
32
33
34
35

Explanation

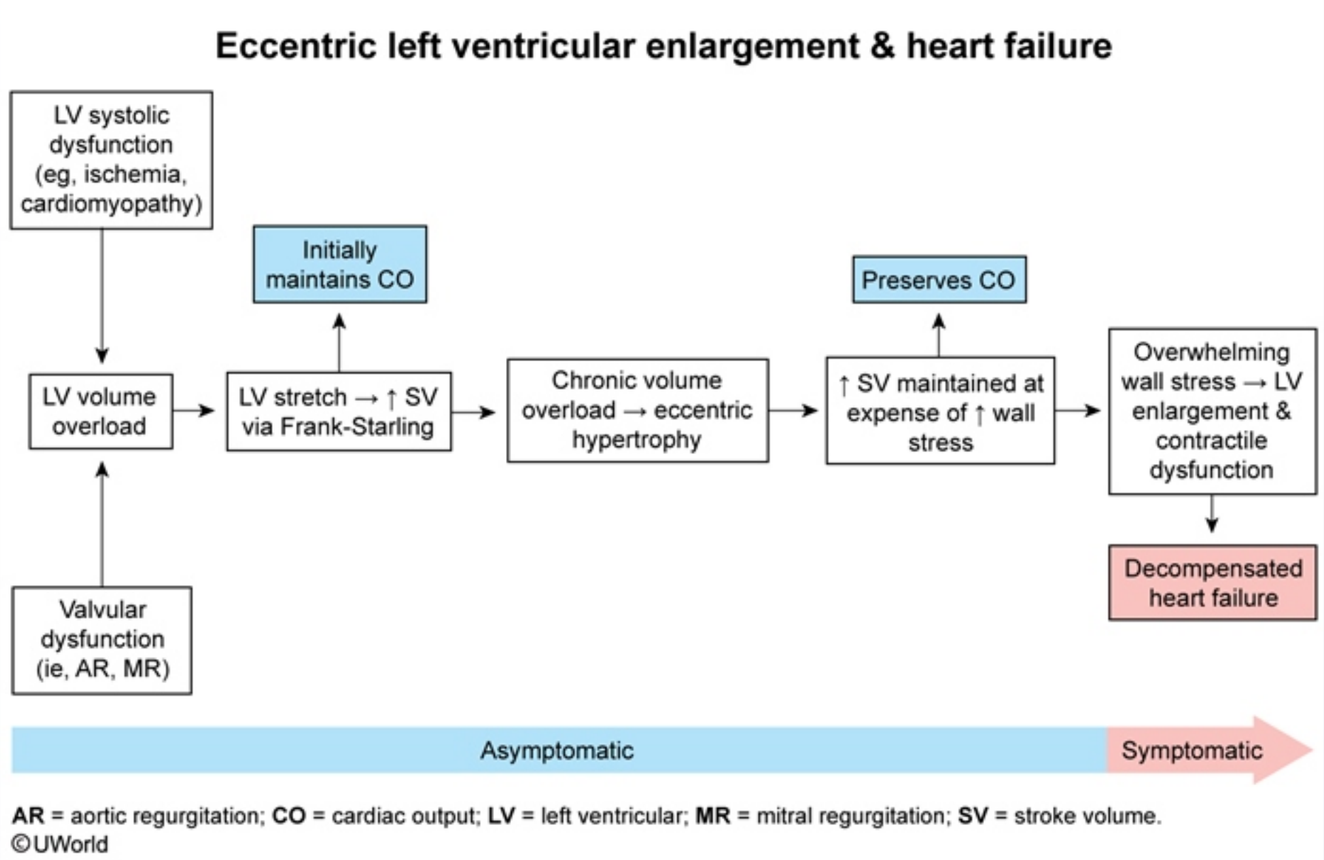

AR = aortic regurgitation; **CO** = cardiac output; **LV** = left ventricular; **MR** = mitral regurgitation; **SV** = stroke volume.
©UWorld

This patient with progressive dyspnea and peripheral edema, as well as a laterally displaced point of maximal impulse and S3 on physical examination, likely has **heart failure** due to **peripartum cardiomyopathy**. Peripartum cardiomyopathy is relatively uncommon and manifests as a **dilated cardiomyopathy** that occurs during the last month of pregnancy or within 5 months after delivery. The pathogenesis of the condition is poorly understood, but it may be related to **impaired function of angiogenic growth factors** (eg, vascular endothelial growth factor) during the peripartum period. In addition, certain individuals may have genetic mutations affecting cardiac structural proteins that predispose to the development of peripartum cardiomyopathy.

©UWorld

This patient with progressive dyspnea and peripheral edema, as well as a laterally displaced point of maximal impulse and S3 on physical examination, likely has **heart failure** due to **peripartum cardiomyopathy**. Peripartum cardiomyopathy is relatively uncommon and manifests as a **dilated cardiomyopathy** that occurs during the last month of pregnancy or within 5 months after delivery. The pathogenesis of the condition is poorly understood, but it may be related to **impaired function of angiogenic growth factors** (eg, vascular endothelial growth factor) during the peripartum period. In addition, certain individuals may have genetic mutations affecting cardiac structural proteins that predispose to the development of peripartum cardiomyopathy.

In dilated cardiomyopathy, myocardial dysfunction causes an increase in left ventricular end-diastolic volume, which is compensated for by eccentric hypertrophy to maintain cardiac output. The dilation of the left ventricle allows for **increased compliance** to accommodate the increase in end-diastolic volume. Eventually, however, overwhelming wall stress leads to left ventricular failure with **reduced ejection fraction** and symptomatic heart failure.

(Choice B) Normal compliance with decreased ejection fraction may occur in neurogenic shock due to impaired sympathetic stimulation resulting in decreased myocardial contractility.

(Choice C) Decreased compliance with normal (or increased) ejection fraction (diastolic heart failure) is seen with left ventricular hypertrophy due to long-standing hypertension.

(Choice D) Increased compliance with relatively normal ejection fraction occurs during the compensated period of eccentric hypertrophy, before overwhelming wall stress leads to systolic failure.

(Choice E) Normal compliance and ejection fraction describes a heart that is without underlying pathology.

Educational objective:
Peripartum cardiomyopathy is a relatively uncommon cause of dilated cardiomyopathy that may be related to impaired function of angiogenic growth factors. Dilated cardiomyopathy involves compensatory eccentric hypertrophy, which increases ventricular compliance and also allows for temporary maintenance of cardiac output. Over time, overwhelming wall stress leads to left ventricular failure with reduced ejection fraction and symptomatic heart failure.

References

- Peripartum cardiomyopathy: current state of knowledge, new developments and future directions.

7
8
9
10
11
12
13
14
15
16
17
18
19
20
21
22
23
24
25
26
27
28
29
30
31
32
33
34
35

eccentric hypertrophy to maintain cardiac output. The dilation of the left ventricle allows for **increased compliance** to accommodate the increase in end-diastolic volume. Eventually, however, overwhelming wall stress leads to left ventricular failure with **reduced ejection fraction** and symptomatic heart failure.

(Choice B) Normal compliance with decreased ejection fraction may occur in neurogenic shock due to impaired sympathetic stimulation resulting in decreased myocardial contractility.

(Choice C) Decreased compliance with normal (or increased) ejection fraction (diastolic heart failure) is seen with left ventricular hypertrophy due to long-standing hypertension.

(Choice D) Increased compliance with relatively normal ejection fraction occurs during the compensated period of eccentric hypertrophy, before overwhelming wall stress leads to systolic failure.

(Choice E) Normal compliance and ejection fraction describes a heart that is without underlying pathology.

Educational objective:
Peripartum cardiomyopathy is a relatively uncommon cause of dilated cardiomyopathy that may be related to impaired function of angiogenic growth factors. Dilated cardiomyopathy involves compensatory eccentric hypertrophy, which increases ventricular compliance and also allows for temporary maintenance of cardiac output. Over time, overwhelming wall stress leads to left ventricular failure with reduced ejection fraction and symptomatic heart failure.

References

- Peripartum cardiomyopathy: current state of knowledge, new developments and future directions.
- Current state of knowledge on aetiology, diagnosis, management, and therapy of peripartum cardiomyopathy: a position statement from the Heart Failure Association of the European Society of Cardiology Working Group on peripartum cardiomyopathy.
- Cardiac angiogenic imbalance leads to peripartum cardiomyopathy.

Pathology	Cardiovascular System	Dilated cardiomyopathy
Subject	System	Topic

Copyright © UWorld. All rights reserved.

7
8
9
10
11
12
13
14
15
16
17
18
19
20
21
22
23
24
25
26
27
28
29
30
31
32
33
34
35

A 64-year-old man comes to the emergency department due to flank discomfort and red urine. He has a history of hypertension and type 2 diabetes mellitus. Three months ago, the patient had an ischemic stroke and now has mild, residual, right-sided weakness. Serum creatinine is 0.9 mg/dL, and serum lactate dehydrogenase is elevated. Urine microscopy shows many red blood cells. The findings of a CT scan of the abdomen with contrast are shown in the image below:

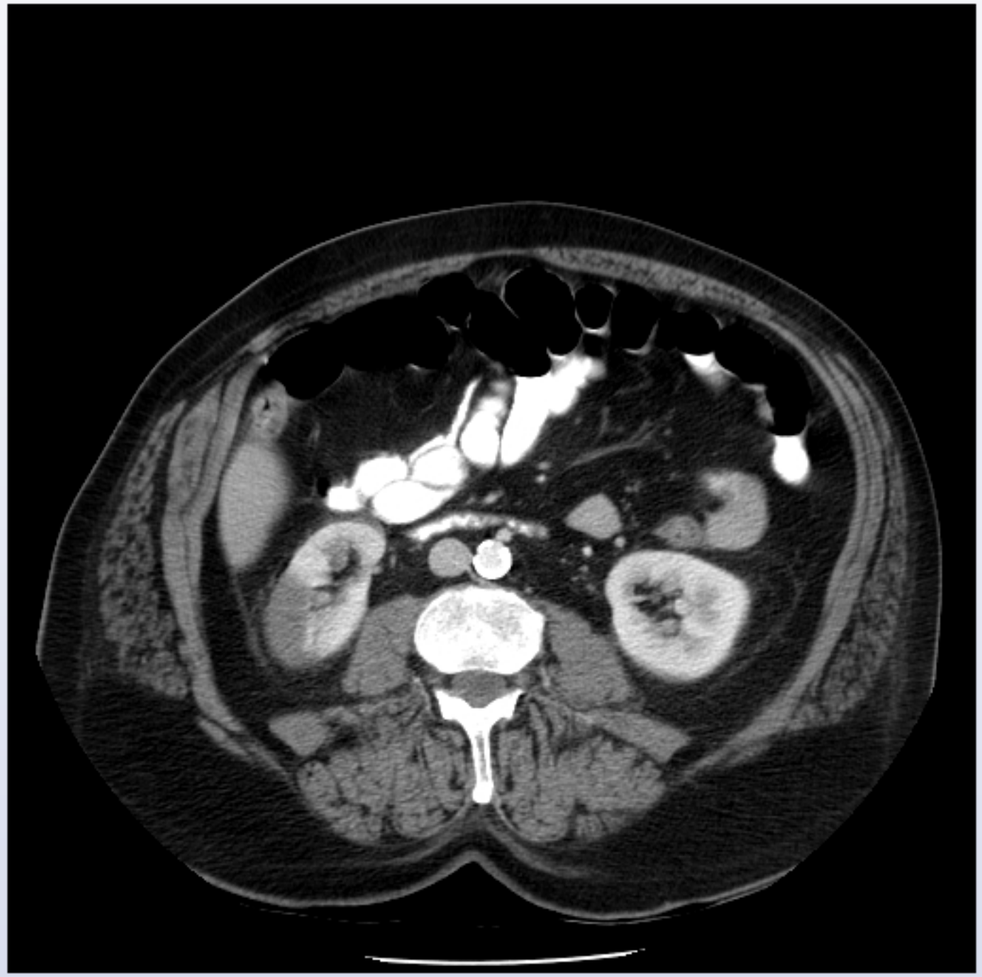

7
8
9
10
11
12
13
14
15
16
17
18
19
20
21
22
23
24
25
26
27
28
29
30
31
32
33
34
35

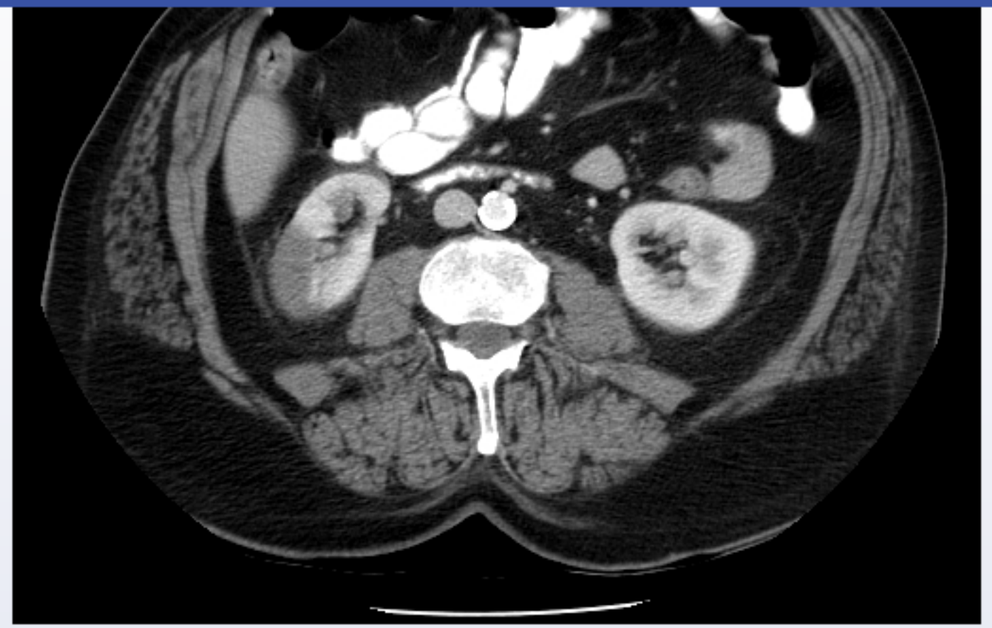

Which of the following is the most likely cause of this patient's symptoms?

A. Atrial fibrillation

B. Deep venous thrombosis of the lower extremities

C. Focal segmental glomerulosclerosis

D. Hypersensitivity interstitial nephritis

E. Pulmonary hypertension

Submit

7
8
9
10
11
12
13
14
15
16
17
18
19
20
21
22
23
24
25
26
27
28
29
30
31
32
33
34
35

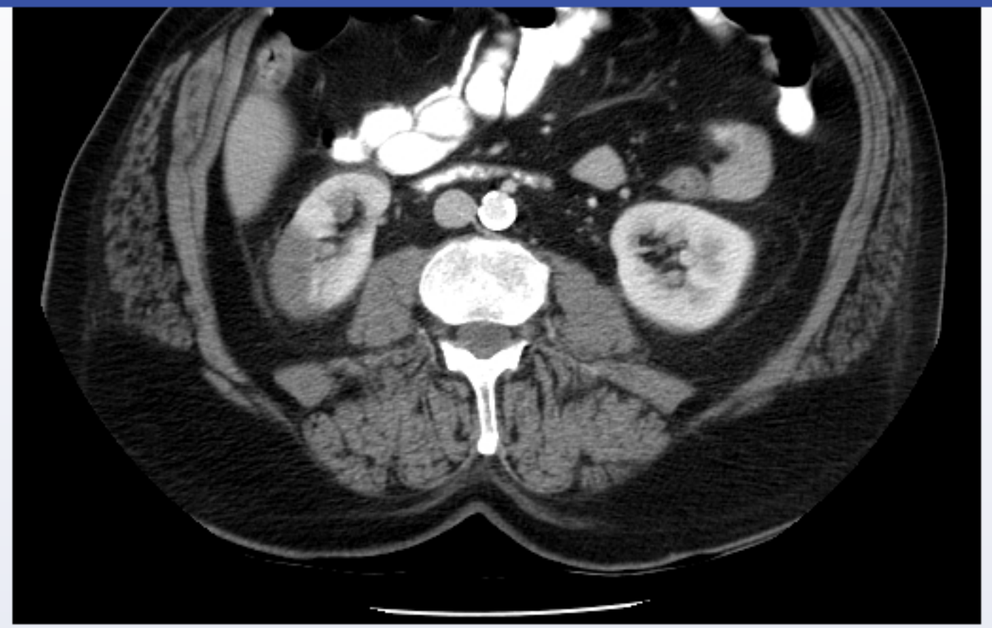

Which of the following is the most likely cause of this patient's symptoms?

- ✓ A. Atrial fibrillation (48%)
- B. Deep venous thrombosis of the lower extremities (10%)
- C. Focal segmental glomerulosclerosis (25%)
- D. Hypersensitivity interstitial nephritis (12%)
- E. Pulmonary hypertension (2%)

Omitted
Correct answer

48%
Answered correctly

06 secs
Time Spent

04/07/2020
Last Updated

7
8
9
10
11
12
13
14
15
16
17
18
19
20
21
22
23
24
25
26
27
28
29
30
31
32
33
34
35

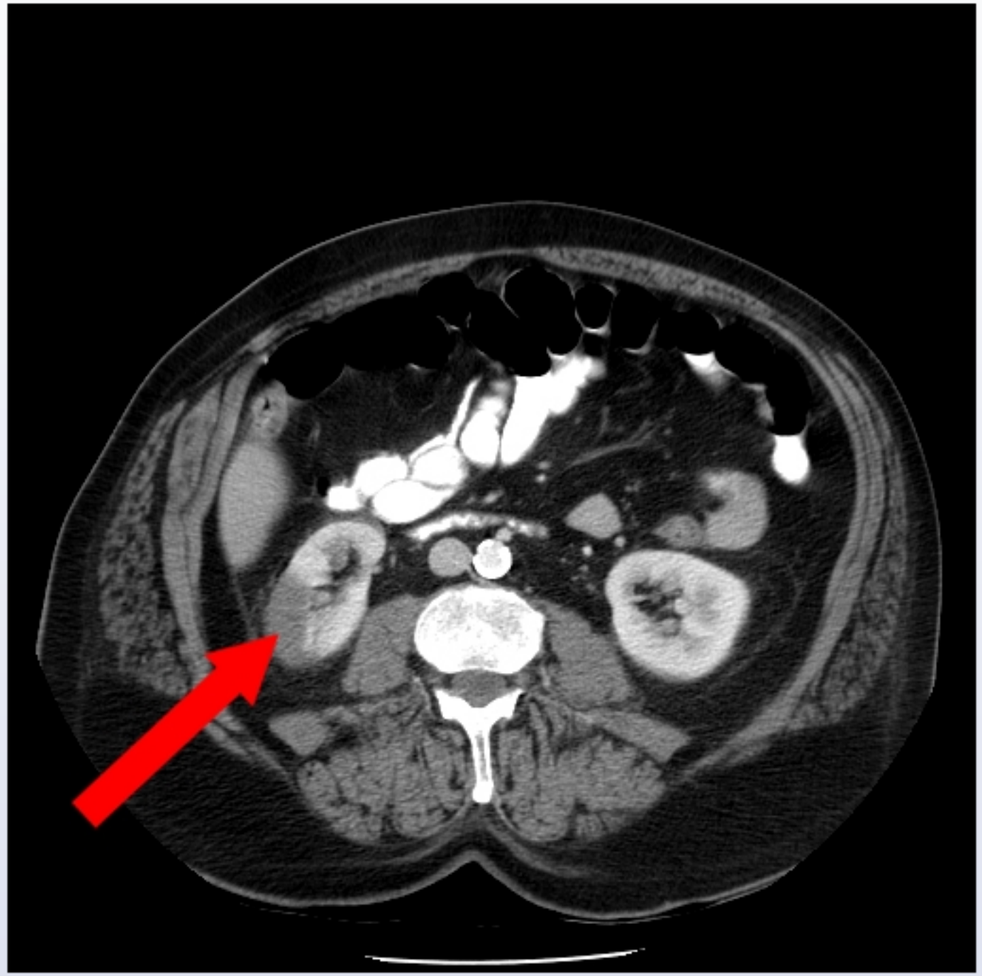

This patient with flank pain, hematuria, and a wedge-shaped kidney lesion on CT scan likely has a **renal infarction**, which results from interruption of the normal blood supply to the kidney. The lack of collaterals between segmental renal arteries ("**end-organ**" blood supply) means that any interruption of blood flow can lead to coagulative infarcts. Common laboratory findings include elevated lactate dehydrogenase (reflecting cell necrosis), mild leukocytosis, and hematuria. Serum creatinine is usually normal due to compensation by the unaffected kidney. Macroscopically,

7
8
9
10
11
12
13
14
15
16
17
18
19
20
21
22
23
24
25
26
27
28
29
30
31
32
33
34
35

This patient with flank pain, hematuria, and a wedge-shaped kidney lesion on CT scan likely has a **renal infarction**, which results from interruption of the normal blood supply to the kidney. The lack of collaterals between segmental renal arteries ("**end-organ**" blood supply) means that any interruption of blood flow can lead to coagulative infarcts. Common laboratory findings include elevated lactate dehydrogenase (reflecting cell necrosis), mild leukocytosis, and hematuria. Serum creatinine is usually normal due to compensation by the unaffected kidney. Macroscopically, renal infarcts appear as pale **wedges**, with the base (widest part) at the renal cortex and the apex pointing to the medulla.

The most common cause of renal infarction is **systemic thromboembolism** from the left atrium or ventricle. Thromboembolism is a common complication of **atrial fibrillation** because the irregular contractions lead to sluggish, uneven flow in the left atrium and facilitate clot formation. Emboli from atrial fibrillation, which can be paroxysmal (thereby going undiagnosed), may have also caused this patient's recent stroke. The **brain and kidneys** are more likely than other organs to suffer embolic infarctions because they are perfused at a higher rate.

(Choice B) Lower extremity venous thromboembolism can lead to pulmonary embolism because returning blood passes through the right heart and subsequently to the lungs. Although communication from the right to the left side of the heart (eg, atrial or ventricular septal defect) can allow for systemic (paradoxical) embolus to the brain or kidneys, this is relatively rare.

(Choice C) Focal segmental glomerulosclerosis manifests as nephrotic syndrome. Urinary loss of certain natural anticoagulants (eg, antithrombin III) leads to a hypercoagulable state. However, this rarely causes systemic embolization and patients usually have elevated creatinine.

(Choice D) Acute interstitial nephritis, a hypersensitivity reaction that can occur 1-2 weeks after starting a new medication, presents with fever, rash, elevated creatinine, eosinophilia, and eosinophiluria.

(Choice E) Pulmonary hypertension can cause right-sided heart failure (cor pulmonale) and is sometimes associated with secondary polycythemia, causing increased blood viscosity. Although thrombotic complications may occur, embolic complications are less common.

Educational objective:
Renal infarction presents with flank pain, hematuria, elevated lactate dehydrogenase, and a wedge-shaped kidney lesion on CT scan. The most common cause of renal infarction is systemic thromboembolism, often due to thrombus formation during atrial fibrillation. The brain and kidneys are more likely than other organs to suffer embolic infarctions because they are perfused at a higher rate.

Pathology Cardiovascular System Renal infarction

interruption of blood flow can lead to coagulative infarcts. Common laboratory findings include elevated lactate dehydrogenase (reflecting cell necrosis), mild leukocytosis, and hematuria. Serum creatinine is usually normal due to compensation by the unaffected kidney. Macroscopically, renal infarcts appear as pale **wedges**, with the base (widest part) at the renal cortex and the apex pointing to the medulla.

The most common cause of renal infarction is **systemic thromboembolism** from the left atrium or ventricle. Thromboembolism is a common complication of **atrial fibrillation** because the irregular contractions lead to sluggish, uneven flow in the left atrium and facilitate clot formation. Emboli from atrial fibrillation, which can be paroxysmal (thereby going undiagnosed), may have also caused this patient's recent stroke. The **brain and kidneys** are more likely than other organs to suffer embolic infarctions because they are perfused at a higher rate.

(Choice B) Lower extremity venous thromboembolism can lead to pulmonary embolism because returning blood passes through the right heart and subsequently to the lungs. Although communication from the right to the left side of the heart (eg, atrial or ventricular septal defect) can allow for systemic (paradoxical) embolus to the brain or kidneys, this is relatively rare.

(Choice C) Focal segmental glomerulosclerosis manifests as nephrotic syndrome. Urinary loss of certain natural anticoagulants (eg, antithrombin III) leads to a hypercoagulable state. However, this rarely causes systemic embolization and patients usually have elevated creatinine.

(Choice D) Acute interstitial nephritis, a hypersensitivity reaction that can occur 1-2 weeks after starting a new medication, presents with fever, rash, elevated creatinine, eosinophilia, and eosinophiluria.

(Choice E) Pulmonary hypertension can cause right-sided heart failure (cor pulmonale) and is sometimes associated with secondary polycythemia, causing increased blood viscosity. Although thrombotic complications may occur, embolic complications are less common.

Educational objective:
Renal infarction presents with flank pain, hematuria, elevated lactate dehydrogenase, and a wedge-shaped kidney lesion on CT scan. The most common cause of renal infarction is systemic thromboembolism, often due to thrombus formation during atrial fibrillation. The brain and kidneys are more likely than other organs to suffer embolic infarctions because they are perfused at a higher rate.

Pathology	Cardiovascular System	Renal infarction
Subject	System	Topic

Copyright © UWorld. All rights reserved.

7
8
9
10
11
12
13
14
15
16
17
18
19
20
21
22
23
24
25
26
27
28
29
30
31
32
33
34
35

A 67-year-old man is admitted to the hospital due to acute right-sided weakness. Medical history includes hypertension, hyperlipidemia, and coronary artery disease, for which the patient underwent placement of 2 stents in the left anterior descending artery. He also has intermittent claudication that limits exercise capacity. The patient's antihypertensive regimen includes chlorthalidone, amlodipine, and lisinopril, which he takes as prescribed. He is an ex-smoker with a 35-pack-year history. Blood pressure is 180/110 mm Hg and pulse is 80/min. Serum creatinine is 1.6 mg/dL. CT scan of the head reveals hemorrhage of the left basal ganglia, and renal ultrasound shows that the right kidney is 7 cm long and the left kidney is 11 cm long. Which of the following mechanisms most likely explains the renal morphology in this patient?

A. Congenital hypoplasia
B. Denervation
C. Lack of trophic hormones
D. Oxygen and nutrient deprivation
E. Senile changes

Submit

7
8
9
10
11
12
13
14
15
16
17
18
19
20
21
22
23
24
25
26
27
28
29
30
31
32
33
34
35

A 67-year-old man is admitted to the hospital due to acute right-sided weakness. Medical history includes hypertension, hyperlipidemia, and coronary artery disease, for which the patient underwent placement of 2 stents in the left anterior descending artery. He also has intermittent claudication that limits exercise capacity. The patient's antihypertensive regimen includes chlorthalidone, amlodipine, and lisinopril, which he takes as prescribed. He is an ex-smoker with a 35-pack-year history. Blood pressure is 180/110 mm Hg and pulse is 80/min. Serum creatinine is 1.6 mg/dL. CT scan of the head reveals hemorrhage of the left basal ganglia, and renal ultrasound shows that the right kidney is 7 cm long and the left kidney is 11 cm long. Which of the following mechanisms most likely explains the renal morphology in this patient?

- A. Congenital hypoplasia (4%)
- B. Denervation (2%)
- C. Lack of trophic hormones (2%)
- ✓ D. Oxygen and nutrient deprivation (86%)
- E. Senile changes (3%)

Omitted
Correct answer
D

86%
Answered correctly

02 secs
Time Spent

06/17/2020
Last Updated

Explanation

Renal artery stenosis	
Etiology	• Atherosclerotic narrowing of the renal artery (>90% of cases) • Fibromuscular dysplasia (younger women)

7
8
9
10
11
12
13
14
15
16
17
18
19
20
21
22
23
24
25
26
27
28
29
30
31
32
33
34
35

Renal artery stenosis	
Etiology	• Atherosclerotic narrowing of the renal artery (>90% of cases) • Fibromuscular dysplasia (younger women)
Risk factors	• Other atherosclerotic disease (eg, CAD, carotid stenosis) • Smoking, diabetes, hypertension
Presentation	• Refractory hypertension • Recurrent flash pulmonary edema • Abdominal bruits • Acute kidney injury after initiation of ACE inhibitor
Pathology	• Gross: Shrunken, atrophic kidney • Microscopic: Crowded glomeruli, tubular atrophy, interstitial fibrosis, focal inflammatory infiltrates

CAD = coronary artery disease.

This patient has an intraparenchymal hemorrhage in the setting of severe, **refractory hypertension**. He has coronary artery disease and peripheral vascular disease (claudication) with multiple risk factors (eg, smoking, hyperlipidemia) for diffuse atherosclerosis. The elevated serum creatinine and the renal ultrasound demonstrating a small (atrophic) right kidney suggest that the patient's refractory hypertension is most likely due to **unilateral renal artery stenosis**.

The most common cause of renal artery stenosis is obstruction by **atheromatous plaque** at the origin of the renal artery, leading to unilateral **renal ischemia**. The ischemic kidney secretes high levels of renin, which activates the renin-angiotensin-aldosterone system and results in systemic hypertension that is often difficult to control despite aggressive antihypertensive therapy. Eventually, the stenosis may also cause **renal atrophy** due to **oxygen and nutrient deprivation**. On histologic examination, the atrophic kidney shows crowded glomeruli, tubulointerstitial atrophy and fibrosis, and often, focal inflammatory infiltrates.

7
8
9
10
11
12
13
14
15
16
17
18
19
20
21
22
23
24
25
26
27
28
29
30
31
32
33
34
35

CAD = coronary artery disease.

This patient has an intraparenchymal hemorrhage in the setting of severe, **refractory hypertension**. He has coronary artery disease and peripheral vascular disease (claudication) with multiple risk factors (eg, smoking, hyperlipidemia) for diffuse atherosclerosis. The elevated serum creatinine and the renal ultrasound demonstrating a small (atrophic) right kidney suggest that the patient's refractory hypertension is most likely due to **unilateral renal artery stenosis**.

The most common cause of renal artery stenosis is obstruction by **atheromatous plaque** at the origin of the renal artery, leading to unilateral **renal ischemia**. The ischemic kidney secretes high levels of renin, which activates the renin-angiotensin-aldosterone system and results in systemic hypertension that is often difficult to control despite aggressive antihypertensive therapy. Eventually, the stenosis may also cause **renal atrophy** due to **oxygen and nutrient deprivation**. On histologic examination, the atrophic kidney shows crowded glomeruli, tubulointerstitial atrophy and fibrosis, and often, focal inflammatory infiltrates.

(Choice A) Congenital renal hypoplasia is a failure of the kidneys to develop to normal size. Involvement is unilateral in most cases. However, this condition does not cause secondary hypertension.

(Choice B) Unilateral denervation of a kidney, either during or after development, is not known to have significant trophic effects (affecting kidney growth or morphology).

(Choice C) The role of trophic hormones in renal development remains unclear. Still, a deficiency of such hormones would be expected to produce bilateral renal dysplasia.

(Choice E) Aging is associated with loss of nephron mass as a result of variable degrees of arteriolosclerosis, focal glomerulosclerosis, and tubulointerstitial fibrosis. These processes produce symmetric, not unilateral, decrements in kidney size and functional capacity.

Educational objective:
Renal artery stenosis is most often due to atherosclerosis. It can cause severe, refractory hypertension due to activation of the renin-angiotensin-aldosterone system. Over time, renal atrophy may occur due to chronic oxygen and nutrient deprivation. Histologic examination may show crowded glomeruli, tubulointerstitial atrophy and fibrosis, and focal inflammatory infiltrates.

References

- Renal artery stenosis.

7
8
9
10
11
12
13
14
15
16
17
18
19
20
21
22
23
24
25
26
27
28
29
30
31
32
33
34
35

A 25-year-old woman comes to the office with a 3-month history of fatigue, myalgias, arthralgias, and a 5-kg (11-lb) weight loss. She has also recently experienced leg pain with activity, which resolves with rest. The patient has no other medical conditions and takes no medications. Temperature is 37.6 C (99.7 F), and blood pressure is 160/90 mm Hg in the right arm and 120/80 mm Hg in the left. A bruit is heard over the left subclavian artery. Left radial pulse and dorsalis pedis pulses in both legs are weak. The remainder of the examination shows no abnormalities. Laboratory results reveal a hemoglobin level of 9.8 g/dL and an erythrocyte sedimentation rate of 110 mm/hr. Which of the following most likely underlies this patient's current condition?

A. Exaggerated vascular smooth muscle contraction

B. Granulomatous inflammation of large arteries

C. Lipid-rich deposits in large- and medium-sized arteries

D. Necrotizing inflammation of medium-sized arteries

E. Segmental inflammation of medium-sized arteries and veins

Submit

A 25-year-old woman comes to the office with a 3-month history of fatigue, myalgias, arthralgias, and a 5-kg (11-lb) weight loss. She has also recently experienced leg pain with activity, which resolves with rest. The patient has no other medical conditions and takes no medications. Temperature is 37.6 C (99.7 F), and blood pressure is 160/90 mm Hg in the right arm and 120/80 mm Hg in the left. A bruit is heard over the left subclavian artery. Left radial pulse and dorsalis pedis pulses in both legs are weak. The remainder of the examination shows no abnormalities. Laboratory results reveal a hemoglobin level of 9.8 g/dL and an erythrocyte sedimentation rate of 110 mm/hr. Which of the following most likely underlies this patient's current condition?

A. Exaggerated vascular smooth muscle contraction (5%)
✓ B. Granulomatous inflammation of large arteries (62%)
C. Lipid-rich deposits in large- and medium-sized arteries (8%)
D. Necrotizing inflammation of medium-sized arteries (10%)
E. Segmental inflammation of medium-sized arteries and veins (12%)

Omitted
Correct answer
B

62%
Answered correctly

03 secs
Time Spent

03/20/2020
Last Updated

Explanation

Takayasu arteritis	
Risk factors	• **Female** • Asian

Takayasu arteritis	
Risk factors	• **Female** • Asian • Age <40
Clinical/laboratory findings	• **Constitutional**: fever, weight loss, fatigue • **Arterio-occlusive**: claudication, BP discrepancies, bruits, pulse deficits • Visual & neurologic deficits • Arthralgias & myalgias • Elevated inflammatory markers (eg, CRP, ESR)
Histopathology	• Granulomatous inflammation of arterial media • Transmural fibrous thickening, narrowing of lumen • Predominantly affects aorta & its branches

BP = blood pressure; CRP = C-reactive protein; ESR = erythrocyte sedimentation rate.

This patient with lower extremity **claudication** (ie, exertional pain due to limited blood flow reserve) and **constitutional symptoms** has typical features of **Takayasu arteritis** (TA). TA is a chronic, large-artery vasculitis that primarily involves the **aorta and its branches**. TA predominantly affects women of reproductive age and is more common in Asians.

Arterial narrowing in TA can manifest as audible bruits, blood pressure discrepancies, pulse deficits, and distal ulcerations. Characteristic findings on histopathology include mononuclear infiltrates and **granulomatous inflammation** of the vascular media, leading to arterial wall thickening and occlusion. The pathologic abnormalities in TA closely resemble giant cell (temporal) arteritis; however, TA primarily affects **younger individuals**, whereas giant cell arteritis occurs almost exclusively in patients age ≥50.

(Choice A) Exaggerated vascular smooth muscle contraction (eg, in response to cold or vibration) causes Raynaud phenomenon. Symptoms are typically acute and episodic and manifest as a triphasic color change (pallor, cyanosis, erythema) in the distal extremities. This patient's progressive symptoms and proximal arterial findings are more consistent with TA.

BP = blood pressure; CRP = C-reactive protein; ESR = erythrocyte sedimentation rate.

This patient with lower extremity **claudication** (ie, exertional pain due to limited blood flow reserve) and **constitutional symptoms** has typical features of **Takayasu arteritis** (TA). TA is a chronic, large-artery vasculitis that primarily involves the **aorta and its branches**. TA predominantly affects women of reproductive age and is more common in Asians.

Arterial narrowing in TA can manifest as audible bruits, blood pressure discrepancies, pulse deficits, and distal ulcerations. Characteristic findings on histopathology include mononuclear infiltrates and **granulomatous inflammation** of the vascular media, leading to arterial wall thickening and occlusion. The pathologic abnormalities in TA closely resemble giant cell (temporal) arteritis; however, TA primarily affects **younger individuals**, whereas giant cell arteritis occurs almost exclusively in patients age ≥50.

(Choice A) Exaggerated vascular smooth muscle contraction (eg, in response to cold or vibration) causes Raynaud phenomenon. Symptoms are typically acute and episodic and manifest as a triphasic color change (pallor, cyanosis, erythema) in the distal extremities. This patient's progressive symptoms and proximal arterial findings are more consistent with TA.

(Choice C) Atherosclerosis is characterized by lipid-rich deposits in large- and medium-sized arteries. It is common in older patients with cardiovascular risk factors (eg, smoking, hypertension, hyperlipidemia) but is rare in individuals as young as this patient. In addition, in contrast to this patient who has both upper and lower extremity abnormalities, upper extremity atherosclerosis is usually a late finding.

(Choice D) Necrotizing inflammation of medium-sized arteries is seen in polyarteritis nodosa, which is characterized by multisystem involvement (eg, glomerulonephritis, skin lesions, neuropathy, bowel ischemia, myositis). This patient's bruits, blood pressure discrepancies, and pulse deficits indicate a large artery disorder.

(Choice E) Thromboangiitis obliterans (Buerger disease) is a segmental, thrombosing vasculitis of medium- and small-sized arteries, principally the tibial and radial arteries. Manifestations are most noticeable in the distal extremities (eg, ulcerations), and the condition is almost always seen in association with heavy cigarette smoking.

Educational objective:
Takayasu arteritis is a chronic, large-artery vasculitis that primarily involves the aorta and its branches. It presents with constitutional (eg, fever, weight loss) and arterio-occlusive (eg, claudication, blood pressure discrepancies, pulse deficits) findings in patients age <40. Histopathology shows granulomatous inflammation of the vascular media.

BP = blood pressure; CRP = C-reactive protein; ESR = erythrocyte sedimentation rate.

This patient with lower extr **claudication** (ie, exertional pain due to limited blood flow reserve) and **constitutional symptoms** has typical features of **Takayasu arte** tly affects women of reprodu

Arterial narrowing in TA findings on histopathology thickening and occlusion. **younger individuals**, whe

(Choice A) Exaggerated typically acute and episod progressive symptoms an are

(Choice C) Atheroscleros cardiovascular risk factors this patient who has both t to

(Choice D) Necrotizing in (eg, glomerulonephritis, sk indicate a large artery disc ent icits

(Choice E) Thromboangi the tibial and radial arterie in association with heavy ly een

Educational objective:
Takayasu arteritis is a chr weight loss) and arterio-oc shows granulomatous inflammation of the vascular media.

Exhibit Display

Zoom In | Zoom Out | Reset | Add To New Card | Existing Card

7
8
9
10
11
12
13
14
15
16
17
18
19
20
21
22
23
24
25
26
27
28
29
30
31
32
33
34
35

An 82-year-old man comes to the office due to progressive dyspnea and fatigue over the last year, which now limit his daily activities. He has also noticed bilateral swelling of his feet. The patient has hypertension, which is controlled with amlodipine. His blood pressure is 122/72 mm Hg and pulse is 55/min. Physical examination reveals elevated jugular venous pressure with rapid 'y' descent and a prominent S4. Abdominal examination shows moderate ascites. The patient has 3+ bilateral lower extremity pitting edema. Echocardiogram reveals left atrial enlargement with marked left ventricular hypertrophy and normal left ventricular ejection fraction. Complete blood count, basic metabolic panel, and serum and urine protein electrophoresis are within normal limits. Endomyocardial biopsy findings are shown below.

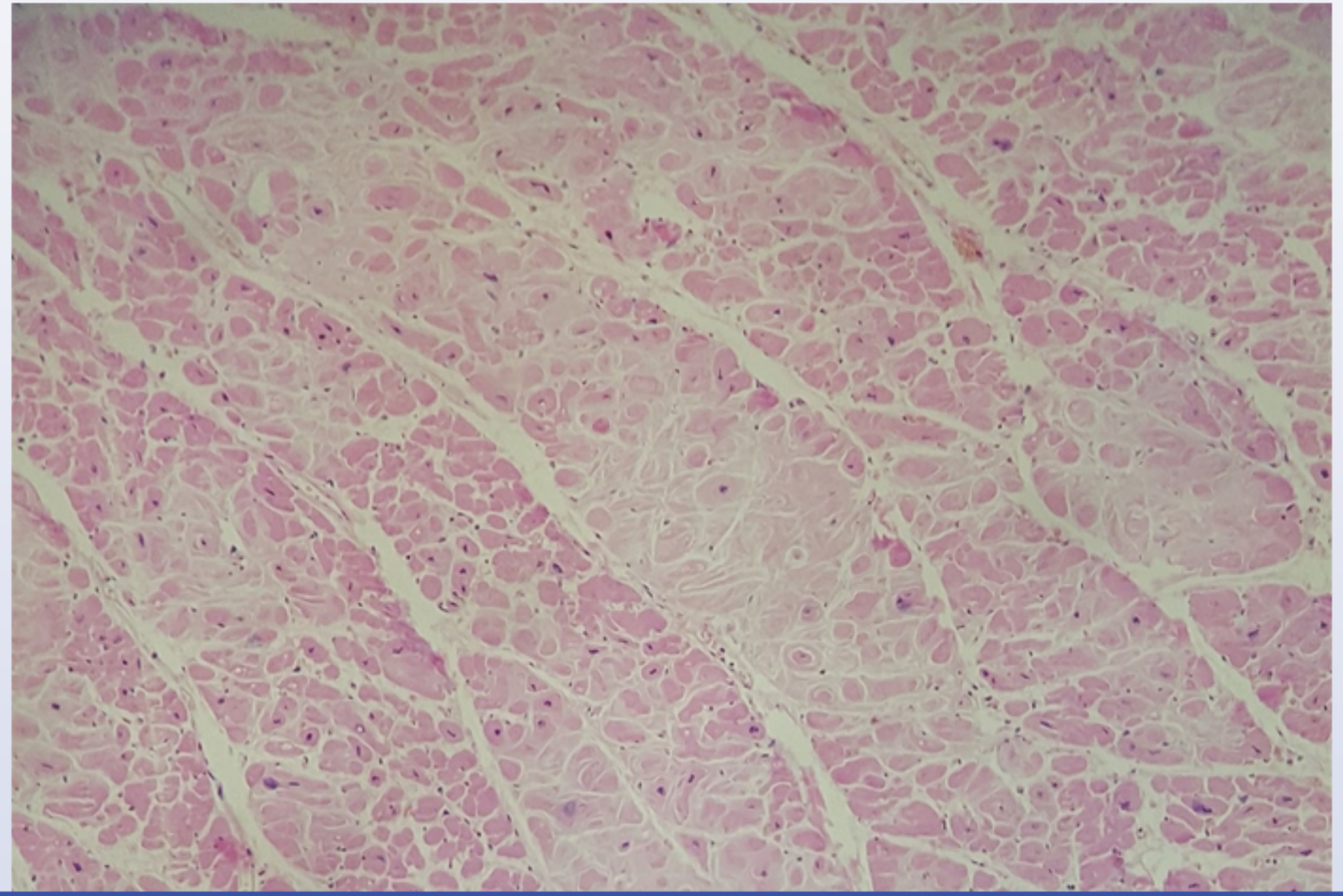

7
8
9
10
11
12
13
14
15
16
17
18
19
20
21
22
23
24
25
26
27
28
29
30
31
32
33
34
35

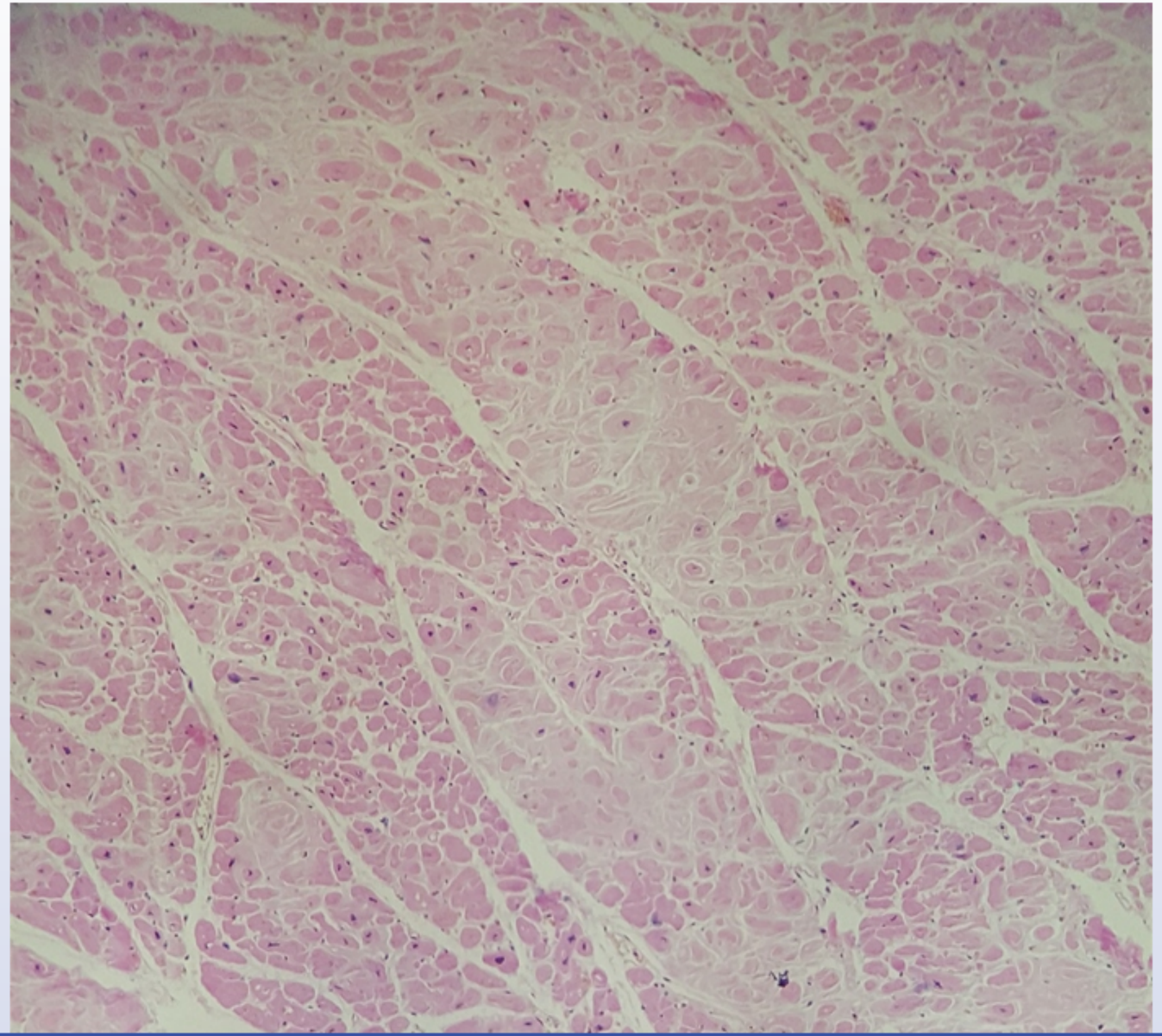

7
8
9
10
11
12
13
14
15
16
17
18
19
20
21
22
23
24
25
26
27
28
29
30
31
32
33
34
35

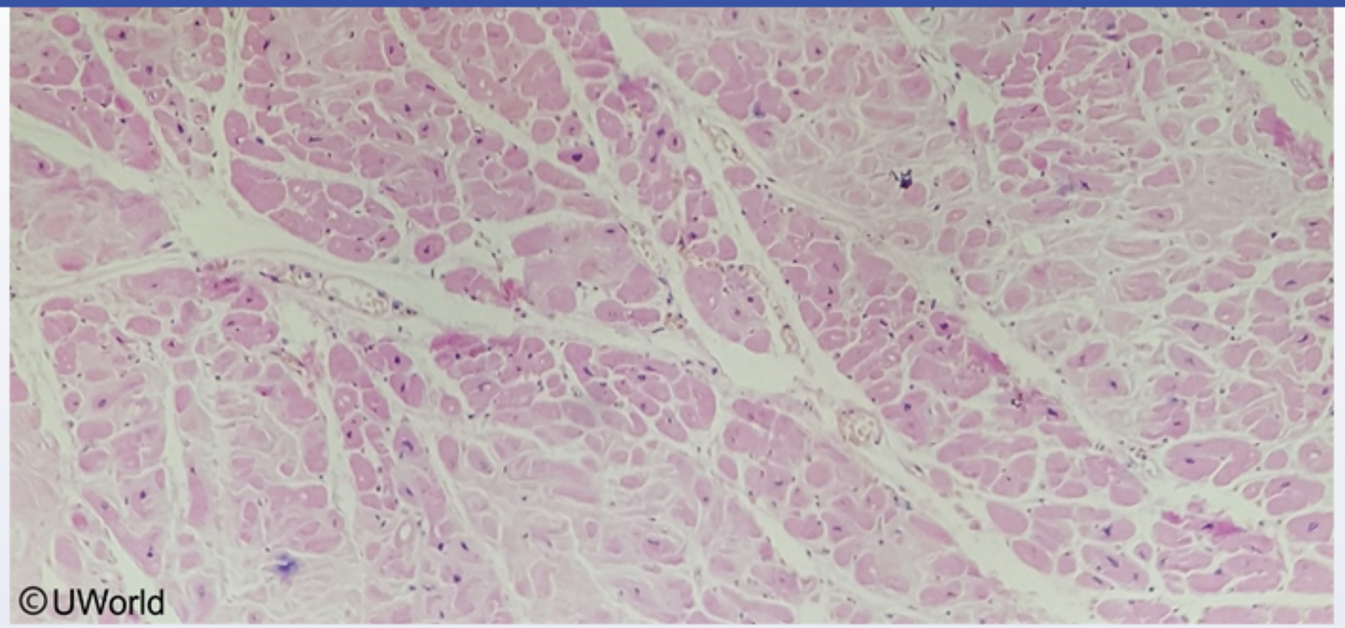

Which of the following is the most likely diagnosis for this patient?

- A. Cardiac myxoma
- B. Cardiac sarcoidosis
- C. Chagas disease
- D. Hemochromatosis
- E. Senile amyloidosis

Submit

7
8
9
10
11
12
13
14
15
16
17
18
19
20
21
22
23
24
25
26
27
28
29
30
31
32
33
34
35

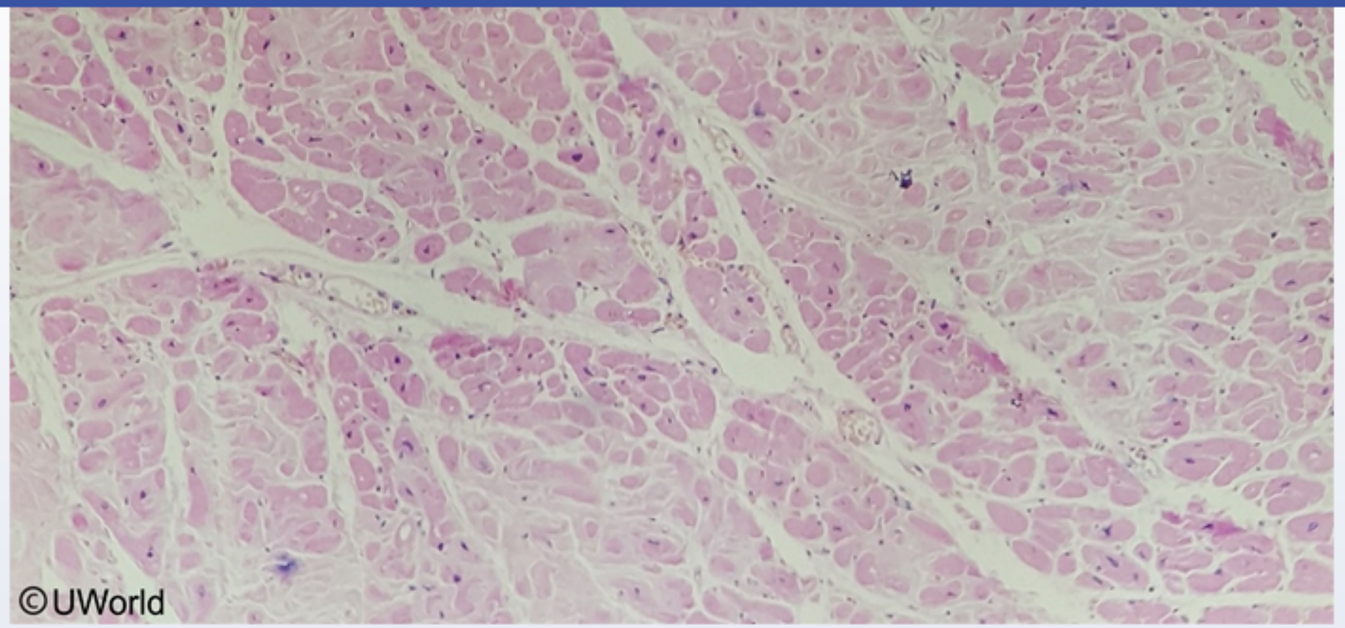

Which of the following is the most likely diagnosis for this patient?

A. Cardiac myxoma (14%)
B. Cardiac sarcoidosis (8%)
C. Chagas disease (6%)
D. Hemochromatosis (6%)
✓ E. Senile amyloidosis (63%)

Omitted
Correct answer

63%
Answered correctly

10 secs
Time Spent

01/07/2020
Last Updated

7
8
9
10
11
12
13
14
15
16
17
18
19
20
21
22
23
24
25
26
27
28
29
30
31
32
33
34
35

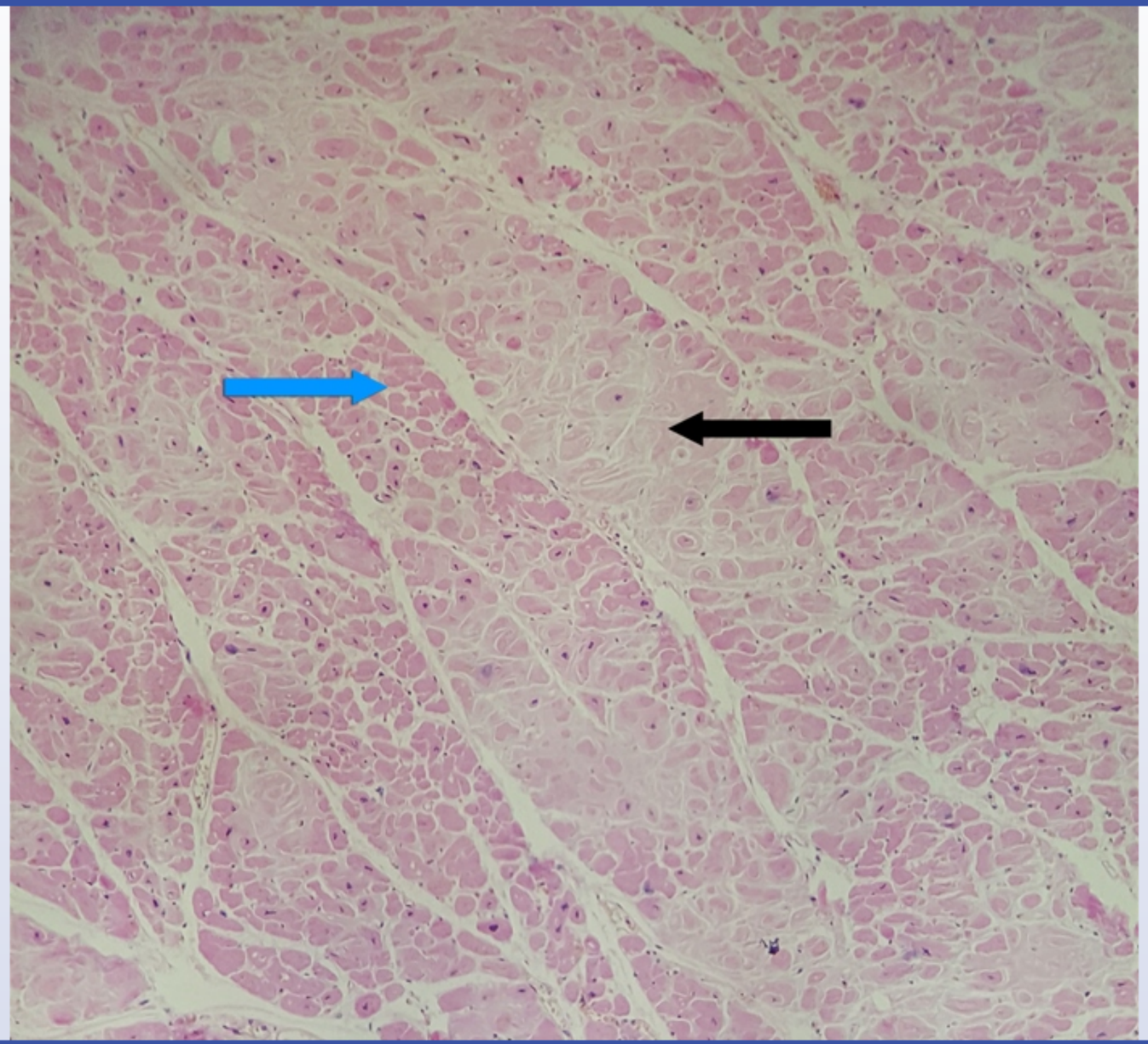

7
8
9
10
11
12
13
14
15
16
17
18
19
20
21
22
23
24
25
26
27
28
29
30
31
32
33
34
35

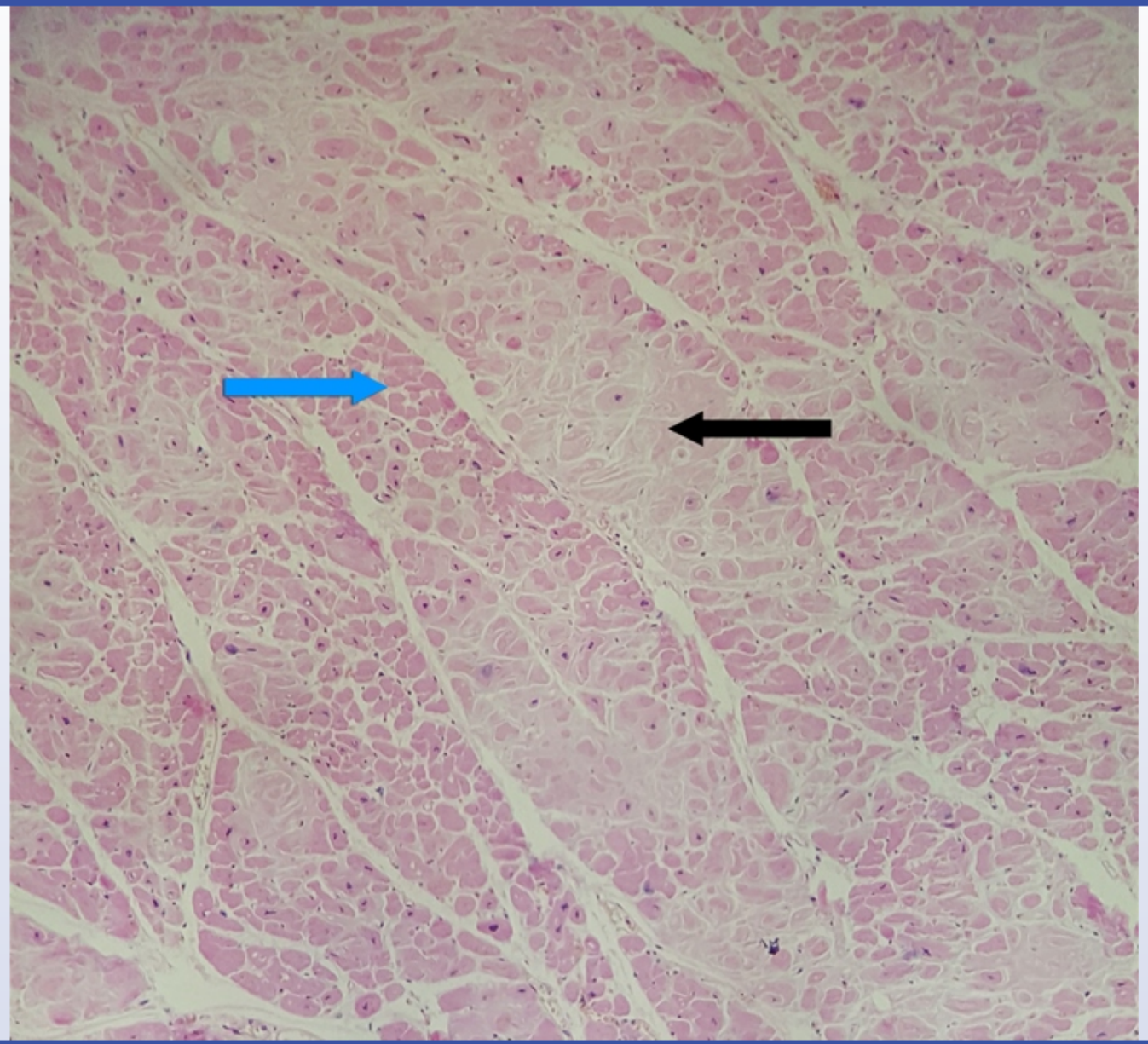

©UWorld

This patient's clinical presentation (eg, progressive exertional dyspnea, edema, ascites, elevated jugular venous pressure with rapid 'y' descent, prominent S4) and echocardiogram findings (eg, left atrial enlargement, left ventricular hypertrophy, normal ejection fraction) are consistent with **diastolic heart failure** due to restrictive cardiomyopathy. **Restrictive cardiomyopathy** can be idiopathic or caused by infiltrative diseases (eg, amyloidosis, sarcoidosis, hemochromatosis), radiation fibrosis, or endomyocardial fibrosis. Although most cases are associated with normal ventricular wall thickness, infiltrative conditions such as cardiac amyloidosis may lead to significant **ventricular hypertrophy**. Infiltrative diseases can also cause conduction system abnormalities (eg, bradycardia) that may ultimately require pacemaker implantation.

Cardiac amyloidosis results from abnormal extracellular deposition of insoluble proteins such as monoclonal light chains (AL amyloidosis), mutated transthyretin (familial ATTR amyloidosis), or wild-type transthyretin (**senile systemic amyloidosis**) in myocardial tissue. Endomyocardial biopsy typically reveals cross-sections of normal myocardial cells (blue arrow) with other areas of myocardium infiltrated by an **amorphous and acellular pink material** (black arrow). Congo red stain classically shows apple-green birefringence under polarized light microscopy.

(Choice A) Cardiac myxomas are the most common primary cardiac neoplasms, with approximately 80% originating in the left atrium. Left atrial myxomas can obstruct blood flow across the mitral valve, resulting in syncope and symptoms of heart failure. Endomyocardial biopsy typically reveals numerous bland stellate cells in a background of myxoid ground substance.

(Choice B) Cardiac sarcoidosis can present with restrictive or dilated cardiomyopathy along with conduction defects and atrial or ventricular arrhythmias; sudden death can also occur. Microscopic examination of the myocardium reveals the presence of noncaseating granulomas containing giant cells.

(Choice C) Chagas disease occurs secondary to *Trypanosoma cruzi* infection and is a common cause of myopericarditis and dilated cardiomyopathy in Latin America. Microscopic examination typically shows multiple parasitic protozoa within the myocardial fibers with a dense cellular infiltrate and myofiber destruction.

(Choice D) Hemochromatosis leads to excessive iron deposition in the myocardium and can cause conduction abnormalities and restrictive or dilated cardiomyopathy. Endomyocardial biopsy typically reveals excessive iron deposition in the myocardium, which can be confirmed with Prussian blue staining.

Educational objective:
Restrictive cardiomyopathy can be caused by infiltrative diseases (eg, amyloidosis, sarcoidosis, hemochromatosis) and often results in diastolic

biopsy typically reveals cross-sections of normal myocardial cells (blue arrow) with other areas of myocardium infiltrated by an **amorphous and acellular pink material** (black arrow). Congo red stain classically shows apple-green birefringence under polarized light microscopy.

(Choice A) Cardiac myxomas are the most common primary cardiac neoplasms, with approximately 80% originating in the left atrium. Left atrial myxomas can obstruct blood flow across the mitral valve, resulting in syncope and symptoms of heart failure. Endomyocardial biopsy typically reveals numerous bland stellate cells in a background of myxoid ground substance.

(Choice B) Cardiac sarcoidosis can present with restrictive or dilated cardiomyopathy along with conduction defects and atrial or ventricular arrhythmias; sudden death can also occur. Microscopic examination of the myocardium reveals the presence of noncaseating granulomas containing giant cells.

(Choice C) Chagas disease occurs secondary to *Trypanosoma cruzi* infection and is a common cause of myopericarditis and dilated cardiomyopathy in Latin America. Microscopic examination typically shows multiple parasitic protozoa within the myocardial fibers with a dense cellular infiltrate and myofiber destruction.

(Choice D) Hemochromatosis leads to excessive iron deposition in the myocardium and can cause conduction abnormalities and restrictive or dilated cardiomyopathy. Endomyocardial biopsy typically reveals excessive iron deposition in the myocardium, which can be confirmed with Prussian blue staining.

Educational objective:
Restrictive cardiomyopathy can be caused by infiltrative diseases (eg, amyloidosis, sarcoidosis, hemochromatosis) and often results in diastolic heart failure due to ventricular hypertrophy with impaired ventricular filling. Cardiac amyloidosis is characterized histologically by areas of myocardium infiltrated by an amorphous and acellular pink material (amyloid).

References

- Cardiac transthyretin amyloidosis.

Pathology	Cardiovascular System	Amyloidosis
Subject	System	Topic

Copyright © UWorld. All rights reserved.

7
8
9
10
11
12
13
14
15
16
17
18
19
20
21
22
23
24
25
26
27
28
29
30
31
32
33
34
35

Exhibit Display

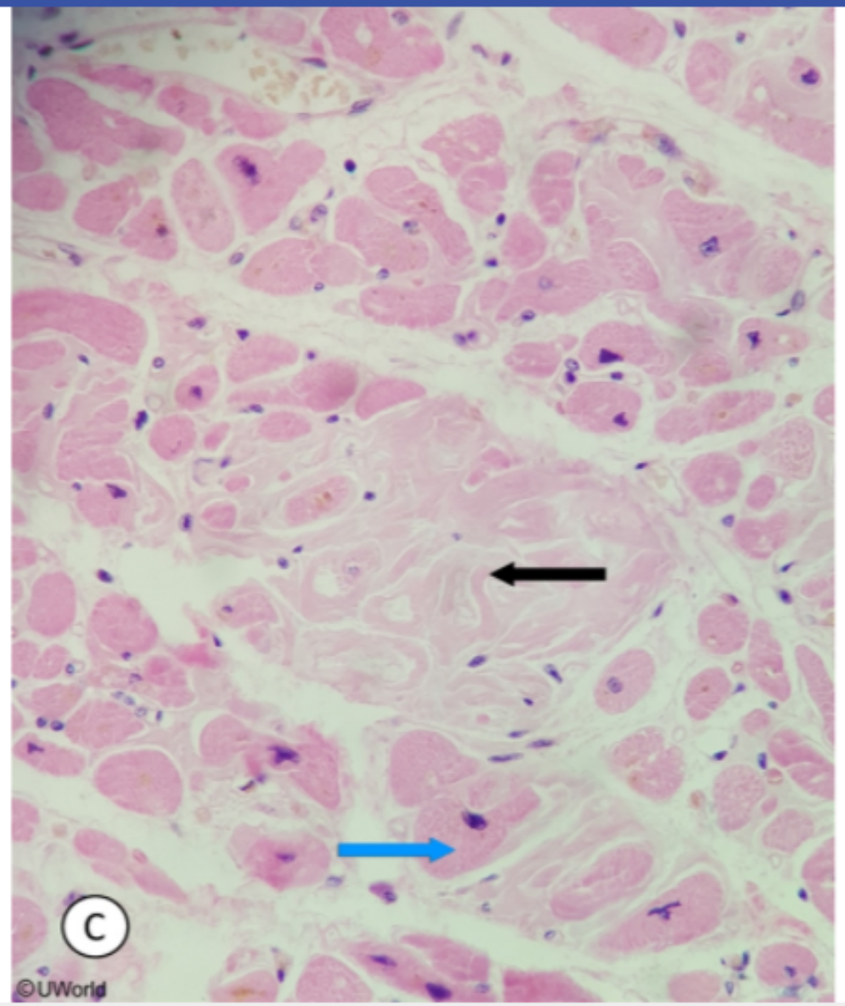

Zoom In | Zoom Out | Reset | Add To New Card | Existing Card

7
8
9
10
11
12
13
14
15
16
17
18
19
20
21
22
23
24
25
26
27
28
29
30
31
32
33
34
35

Exhibit Display

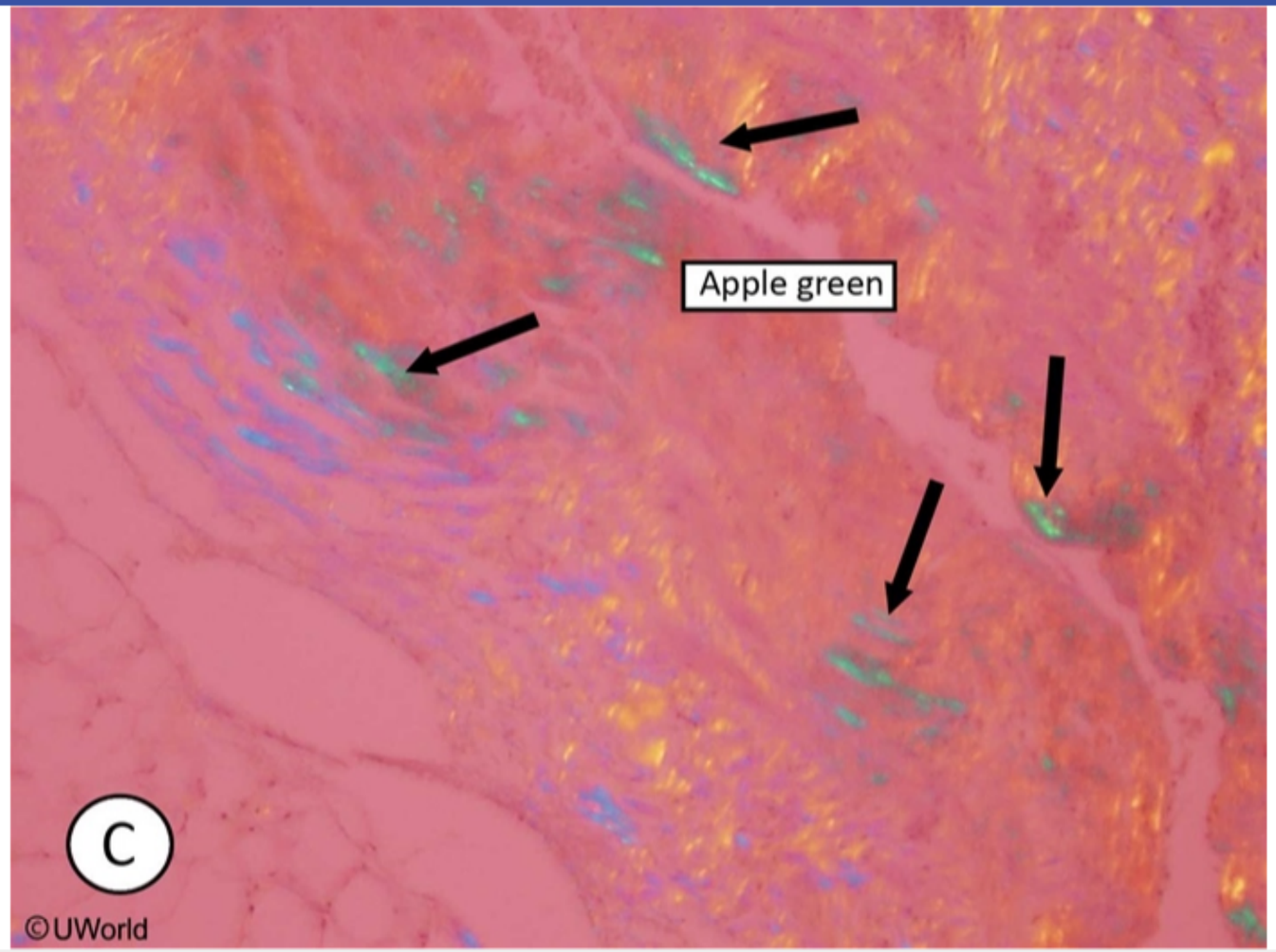

Zoom In | Zoom Out | Reset | Add To New Card | Existing Card

7
8
9
10
11
12
13
14
15
16
17
18
19
20
21
22
23
24
25
26
27
28
29
30
31
32
33
34
35

This patient's clinica
prominent S4) and e
diastolic heart failu
amyloidosis, sarcoid
ventricular wall thick
can also cause cond

Cardiac amyloidos
mutated transthyreti
biopsy typically reve
acellular pink mate

(Choice A) Cardiac
myxomas can obstr
reveals numerous b

(Choice B) Cardiac
arrhythmias; sudder
containing giant cell

(Choice C) Chagas

Exhibit Display

Left atrial myxoma Left atrial myxoma

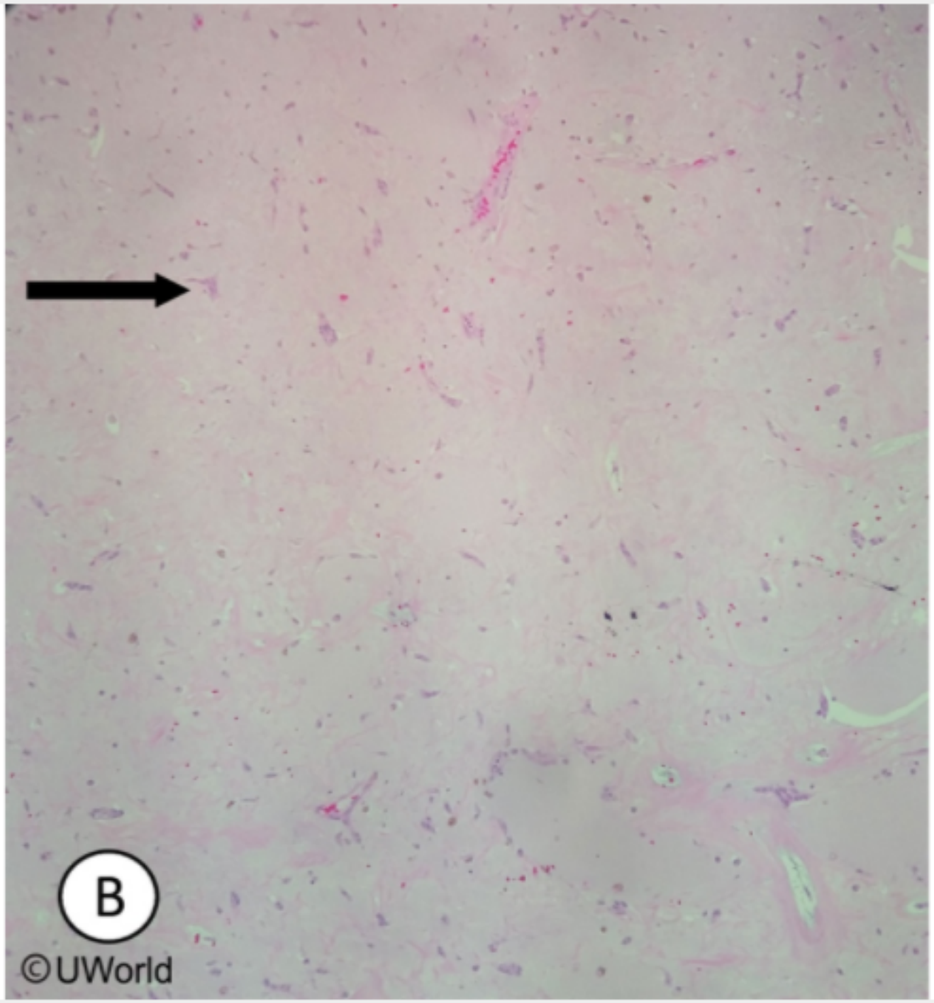

Zoom In Zoom Out Reset Add To New Card | Existing Card

7
8
9
10
11
12
13
14
15
16
17
18
19
20
21
22
23
24
25
26
27
28
29
30
31
32
33
34
35

This patient's clinica
prominent S4) and e
diastolic heart failu
amyloidosis, sarcoid
ventricular wall thick
can also cause cond

Cardiac amyloidos
mutated transthyreti
biopsy typically reve
acellular pink mate

(Choice A) Cardiac
myxomas can obstru
reveals numerous b

(Choice B) Cardiac
arrhythmias; sudder
containing giant cell

(Choice C) Chagas

Exhibit Display

Left atrial myxoma Left atrial myxoma

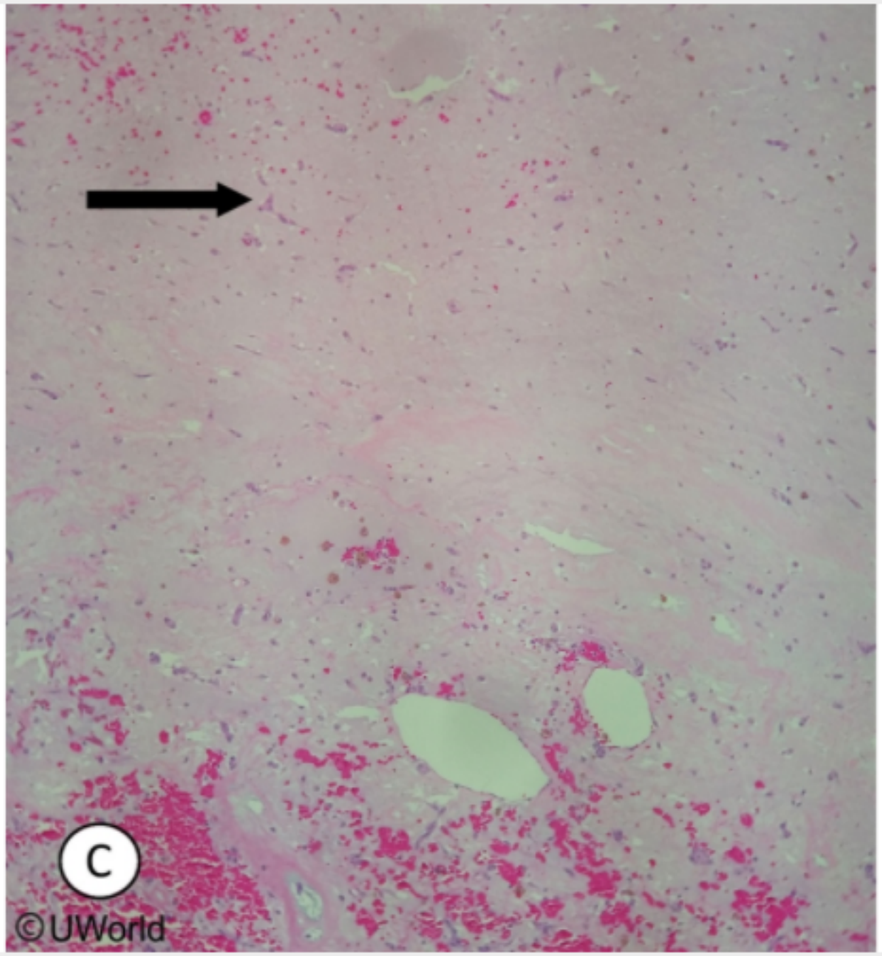

Zoom In Zoom Out Reset Add To New Card | Existing Card

7
8
9
10
11
12
13
14
15
16
17
18
19
20
21
22
23
24
25
26
27
28
29
30
31
32
33
34
35

Exhibit Display

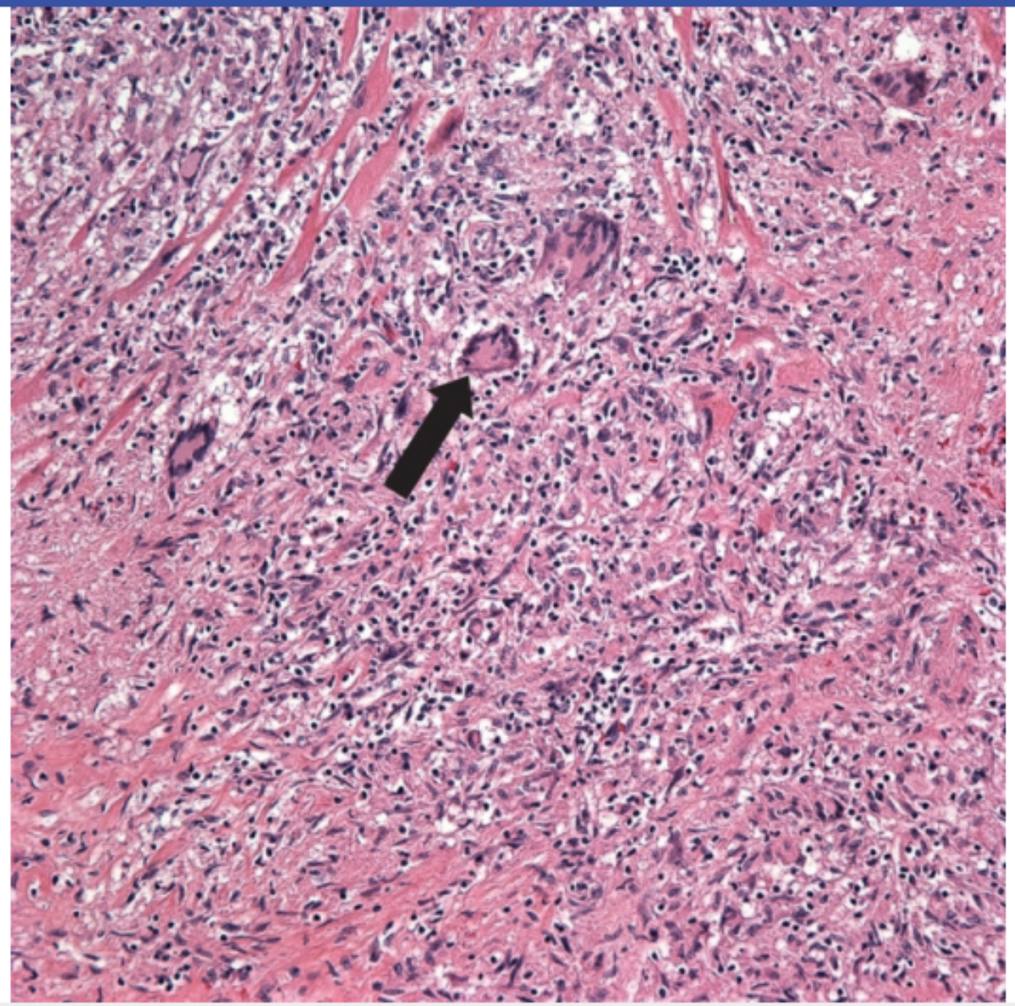

Zoom In | Zoom Out | Reset | Add To New Card | Existing Card

Exhibit Display

Chagas disease Chagas disease

Zoom In Zoom Out Reset Add To New Card | Existing Card

7
8
9
10
11
12
13
14
15
16
17
18
19
20
21
22
23
24
25
26
27
28
29
30
31
32
33
34
35

Exhibit Display

Chagas disease Chagas disease

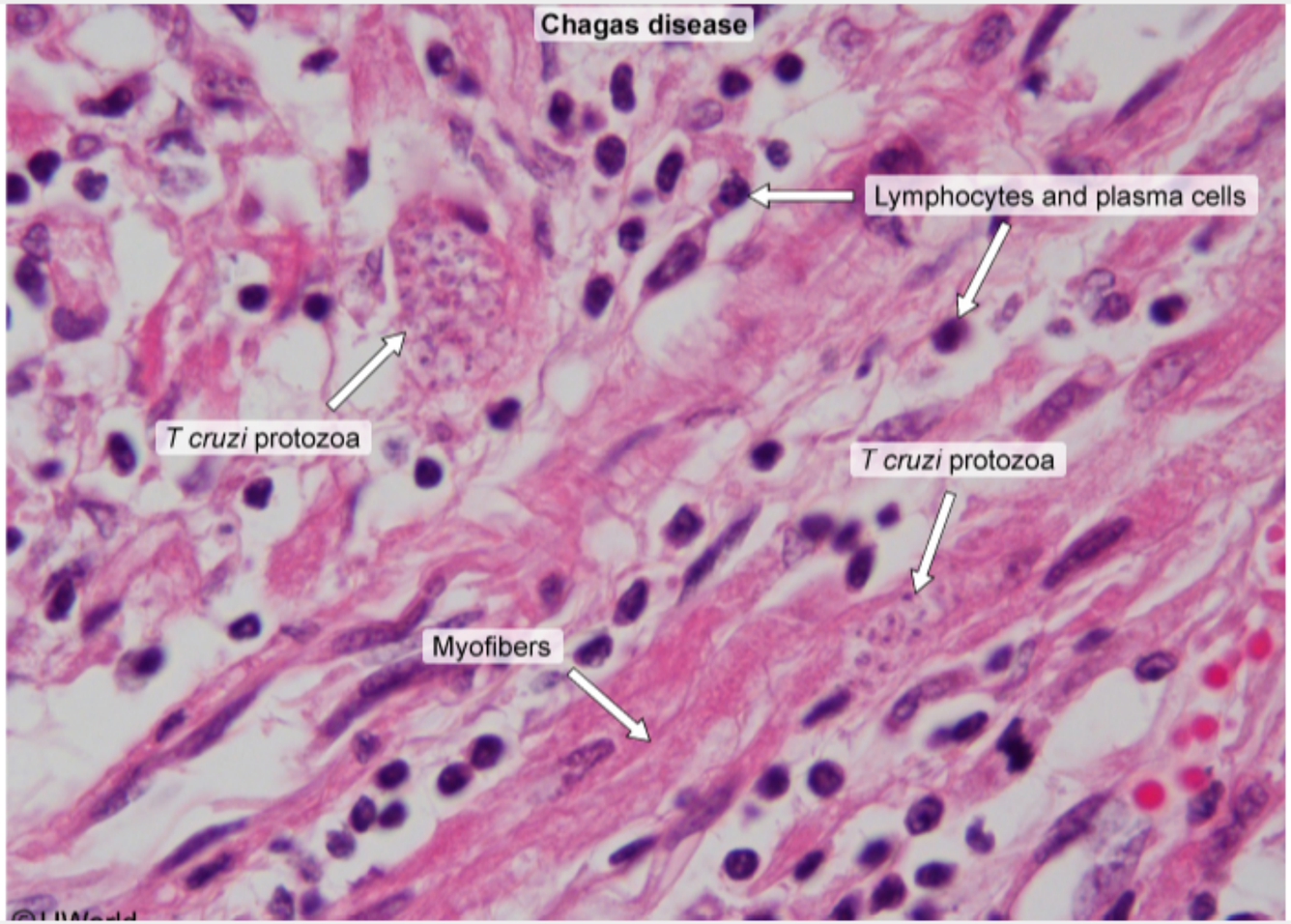

Zoom In Zoom Out Reset Add To New Card | Existing Card

biopsy typically reveals cross-sections of normal myocardial cells (blue arrow) with other areas of myocardium infiltrated by an **amorphous and acellular pink material** (black arrow). Congo red stain classically shows apple-green birefringence under polarized light microscopy.

(Choice A) Cardiac myxomas are the most common primary cardiac neoplasms, with approximately 80% originating in the left atrium. Left atrial myxomas can obstruct blood flow across the mitral valve, resulting in syncope and symptoms of heart failure. Endomyocardial biopsy typically reveals numerous bland stellate cells in a background of myxoid ground substance.

(Choice B) Cardiac sarcoidosis can present with restrictive or dilated cardiomyopathy along with conduction defects and atrial or ventricular arrhythmias; sudden death can also occur. Microscopic examination of the myocardium reveals the presence of noncaseating granulomas containing giant cells.

(Choice C) Chagas disease occurs secondary to *Trypanosoma cruzi* infection and is a common cause of myopericarditis and dilated cardiomyopathy in Latin America. Microscopic examination typically shows multiple parasitic protozoa within the myocardial fibers with a dense cellular infiltrate and myofiber destruction.

(Choice D) Hemochromatosis leads to excessive iron deposition in the myocardium and can cause conduction abnormalities and restrictive or dilated cardiomyopathy. Endomyocardial biopsy typically reveals excessive iron deposition in the myocardium, which can be confirmed with Prussian blue staining.

Educational objective:
Restrictive cardiomyopathy can be caused by infiltrative diseases (eg, amyloidosis, sarcoidosis, hemochromatosis) and often results in diastolic heart failure due to ventricular hypertrophy with impaired ventricular filling. Cardiac amyloidosis is characterized histologically by areas of myocardium infiltrated by an amorphous and acellular pink material (amyloid).

References

- Cardiac transthyretin amyloidosis.

Pathology	Cardiovascular System	Amyloidosis
Subject	System	Topic

Copyright © UWorld. All rights reserved.

7
8
9
10
11
12
13
14
15
16
17
18
19
20
21
22
23
24
25
26
27
28
29
30
31
32
33
34
35

A 58-year-old man with dyspnea and chronic exertional angina is evaluated for coronary revascularization. He has a history of hypertension, type 2 diabetes mellitus, and hypercholesterolemia. His blood pressure is 130/80 mm Hg and pulse is 72/min and regular. Cardiopulmonary examination is normal with the exception of a fourth heart sound. Echocardiogram reveals hypokinesia of the anterior wall of the left ventricle and a left ventricular ejection fraction (LVEF) of 35%. The patient undergoes coronary artery bypass grafting. Repeat echocardiogram 10 days after the surgery shows that hypokinesia is no longer evident and LVEF has increased to 50%. Which of the following best explains the changes in the cardiac contractility and wall motion seen in this patient?

A. Hibernating myocardium
B. Ischemic preconditioning
C. Post-infarction myocardial scarring
D. Reperfusion injury
E. Ventricular remodeling

Submit

A 58-year-old man with dyspnea and chronic exertional angina is evaluated for coronary revascularization. He has a history of hypertension, type 2 diabetes mellitus, and hypercholesterolemia. His blood pressure is 130/80 mm Hg and pulse is 72/min and regular. Cardiopulmonary examination is normal with the exception of a fourth heart sound. Echocardiogram reveals hypokinesia of the anterior wall of the left ventricle and a left ventricular ejection fraction (LVEF) of 35%. The patient undergoes coronary artery bypass grafting. Repeat echocardiogram 10 days after the surgery shows that hypokinesia is no longer evident and LVEF has increased to 50%. Which of the following best explains the changes in the cardiac contractility and wall motion seen in this patient?

- ✓ A. Hibernating myocardium (42%)
- B. Ischemic preconditioning (19%)
- C. Post-infarction myocardial scarring (3%)
- D. Reperfusion injury (5%)
- E. Ventricular remodeling (28%)

Omitted
Correct answer
A

42%
Answered correctly

04 secs
Time Spent

03/02/2020
Last Updated

Explanation

Myocardial hibernation refers to a state of **chronic myocardial ischemia** in which both myocardial metabolism and function are reduced to match a concomitant reduction in coronary blood flow (due to moderate/severe flow-limiting stenosis). This new equilibrium prevents myocardial necrosis. Chronically hibernating myocardium demonstrates decreased expression and disorganization of contractile and cytoskeletal proteins, altered adrenergic control, and reduced calcium responsiveness. These changes lead to **decreased contractility** and left ventricular (LV) systolic

Myocardial hibernation refers to a state of **chronic myocardial ischemia** in which both myocardial metabolism and function are reduced to match a concomitant reduction in coronary blood flow (due to moderate/severe flow-limiting stenosis). This new equilibrium prevents myocardial necrosis. Chronically hibernating myocardium demonstrates decreased expression and disorganization of contractile and cytoskeletal proteins, altered adrenergic control, and reduced calcium responsiveness. These changes lead to **decreased contractility** and left ventricular (LV) systolic dysfunction. However, coronary revascularization and subsequent restoration of blood flow to hibernating myocardium improves contractility and LV function.

(Choice B) Ischemic preconditioning is a phenomenon in which brief repetitive episodes of myocardial ischemia, followed by reperfusion, protect the myocardium from subsequent prolonged episodes of ischemia. In clinical terms, repetitive episodes of angina prior to myocardial infarction can delay cell death after complete coronary occlusion and therefore provide greater time for myocardial salvage with coronary revascularization.

(Choice C) Post-infarction myocardial scarring refers to the replacement of myocardium with collagen and fibrous tissue. This leads to complete loss of myocardial contractile function, and cardiac contractility would not be expected to improve with coronary revascularization.

(Choice D) Reperfusion injury refers to further myocardial cell damage due to restoration of blood flow after a sudden ischemic event. The clinical manifestations of reperfusion injury include arrhythmias, microvascular dysfunction with myocardial stunning, and myocyte injury and death.

(Choice E) Ventricular remodeling refers to a change in the structure (cardiac mass or dimensions) or function of the heart in response to cardiac injury or hemodynamic changes (pressure/volume overload). Remodeling can occur with long-term myocardial hibernation, but it would take weeks to months (not days) to recover following reperfusion therapy.

Educational objective:
Hibernating myocardium refers to the presence of left ventricular systolic dysfunction due to reduced coronary blood flow at rest that is partially or completely reversible by coronary revascularization.

References

- The hibernating myocardium in ischaemia and congestive heart failure.

Pathology Cardiovascular System Myocardial infarction

7
8
9
10
11
12
13
14
15
16
17
18
19
20
21
22
23
24
25
26
27
28
29
30
31
32
33
34
35

A 58-year-old man comes to the emergency department with abrupt-onset, severe chest pain that radiates to his back. His blood pressure is 220/130 mm Hg in the left arm and 180/100 mm Hg in the right. His heart rate is 100/min. Initial laboratory studies show normal serum troponin levels. Electrocardiogram is negative for ST-segment changes. This patient's acute condition was most likely triggered by which of the following events?

A. Intimal fatty streak formation
B. Intimal tearing
C. Medial calcification
D. Medial inflammation
E. Vasa vasorum obliteration

Submit

A 58-year-old man comes to the emergency department with abrupt-onset, severe chest pain that radiates to his back. His blood pressure is 220/130 mm Hg in the left arm and 180/100 mm Hg in the right. His heart rate is 100/min. Initial laboratory studies show normal serum troponin levels. Electrocardiogram is negative for ST-segment changes. This patient's acute condition was most likely triggered by which of the following events?

- A. Intimal fatty streak formation (3%)
- ✓ B. Intimal tearing (85%)
- C. Medial calcification (2%)
- D. Medial inflammation (2%)
- E. Vasa vasorum obliteration (5%)

Omitted
Correct answer
B

85%
Answered correctly

02 secs
Time Spent

03/12/2020
Last Updated

Explanation

7
8
9
10
11
12
13
14
15
16
17
18
19
20
21
22
23
24
25
26
27
28
29
30
31
32
33
34
35

Exhibit Display

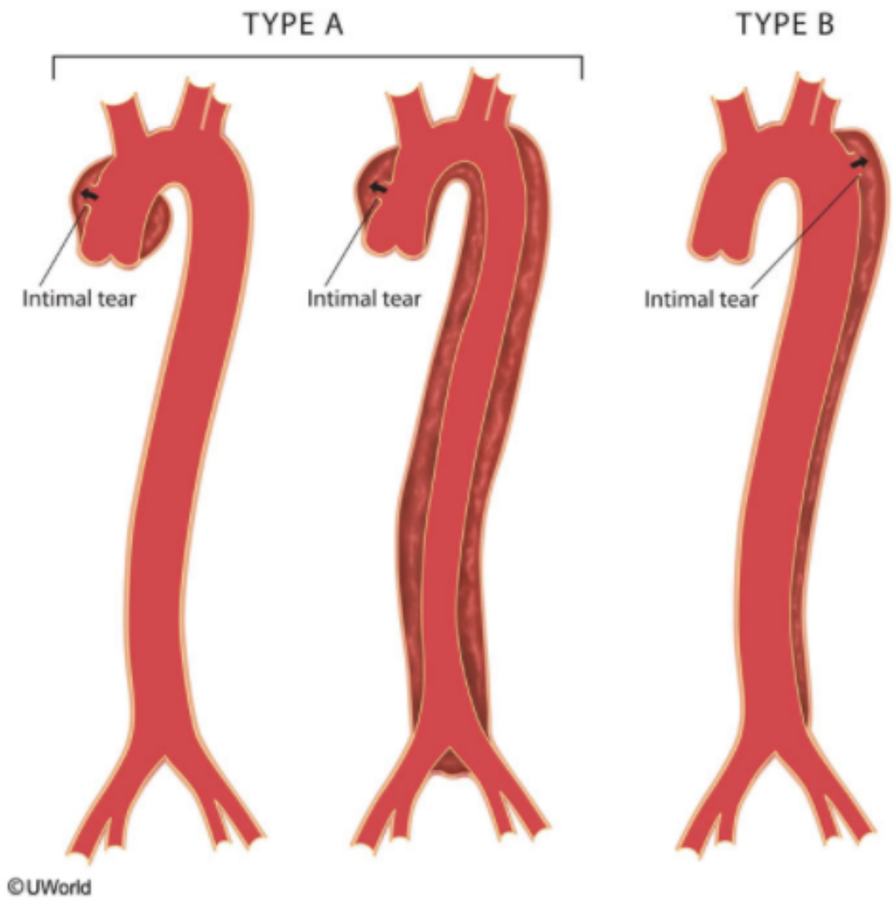

Zoom In | Zoom Out | Reset | Add To New Card | Existing Card

©UWorld

This patient's presentation is most consistent with aortic dissection, which is characterized by severe retrosternal chest pain radiating to the mid-to-upper back that can move downward as the dissection progresses. It is initiated by a **tear in the aortic intima** that typically extends for about 1-5 cm in a transverse or oblique direction. The dissection can progress both proximally and distally as blood is forced through the tear, bisecting through the aortic media. Dissections involving any portion of the ascending aorta are classified as type A; those confined to the descending aorta are classified as type B. As the dissecting intramural hematoma spreads along the aortic wall, it can compress major arterial branches. This patient's brachial **blood pressure discrepancy** suggests compromise of the brachiocephalic trunk servicing his right arm.

Hypertension is the primary risk factor for aortic dissection. In many patients with longstanding hypertension, there is medial hypertrophy of the aortic vasa vasorum and, consequently, reduced blood flow to the aortic media. This can cause medial degeneration with a loss of smooth muscle cells, leading to aortic enlargement and increased wall stiffness. Both of these changes exacerbate aortic wall stress, which is already increased due to the hypertension itself. This synergistic increase in aortic wall stress greatly increases the risk of intimal tearing and subsequent development of aortic dissection.

(Choice A) An intimal fatty streak is the initial lesion of atherosclerosis. Some fatty streaks progress to frank atheromas, which can progressively weaken the underlying media of the aortic wall. However, atherosclerosis predisposes more to aortic aneurysm formation than to aortic dissection.

(Choice C) Monckeberg sclerosis (medial calcific sclerosis) is a form of arteriosclerosis characterized by calcific deposits in the medial layer of muscular arteries. These lesions generally occur in patients age >50 and are thought to cause isolated systolic hypertension due to arterial hardening.

(Choices D and E) Aortitis with medial inflammation can be caused by autoimmune conditions such as Takayasu and giant cell arteritis. **Tertiary syphilis** can also cause a form of aortitis characterized by **obliterative endarteritis** of the vasa vasorum. These conditions weaken the aortic wall and can predispose to aortic aneurysms and, rarely, dissections. However, hypertension is a more important risk factor for the development of intimal tearing, the primary triggering event of an aortic dissection.

Educational objective:
Aortic dissection classically presents with severe retrosternal pain that radiates to the back. This condition develops when overwhelming hemodynamic stress leads to tearing of the aortic intima with blood subsequently dissecting through the aortic media. The resulting intramural hematoma can extend both proximally and distally and can compress major arterial branches and impair blood flow.

Hypertension is the primary risk factor for aortic dissection. In many patients with longstanding hypertension, there is medial hypertrophy of the

Exhibit Display

Zoom In | Zoom Out | Reset | Add To New Card | Existing Card

The following vignette applies to the next **2** items. The items in the set must be answered in sequential order. Once you click **Proceed to Next Item**, you will not be able to add or change an answer.

A 53-year-old man comes to the emergency department due to fever and progressive weakness over the last 2 weeks. Yesterday, he also developed shortness of breath. The patient emigrated from Eastern Europe 2 years ago and says he was diagnosed with "heart disease" in the distant past, but he does not recall any details. He does not use tobacco, alcohol, or illicit drugs. Despite receiving appropriate medical care, the patient expires during hospitalization. On autopsy, gross examination of his heart shows large, friable masses on the mitral valve with extensive destruction of cuspal tissue.

Item 1 of 2

Which of the following is the most likely predisposing factor for this patient's presenting condition?

- A. Myocardial hypertrophy
- B. Myocardial thinning and fibrosis
- C. Pericardial effusion
- D. Rupture of chordae tendineae
- E. Valvular inflammation and scarring

Submit

The following vignette applies to the next **2** items. The items in the set must be answered in sequential order. Once you click **Proceed to Next Item**, you will not be able to add or change an answer.

A 53-year-old man comes to the emergency department due to fever and progressive weakness over the last 2 weeks. Yesterday, he also developed shortness of breath. The patient emigrated from Eastern Europe 2 years ago and says he was diagnosed with "heart disease" in the distant past, but he does not recall any details. He does not use tobacco, alcohol, or illicit drugs. Despite receiving appropriate medical care, the patient expires during hospitalization. On autopsy, gross examination of his heart shows large, friable masses on the mitral valve with extensive destruction of cuspal tissue.

Item 1 of 2

Which of the following is the most likely predisposing factor for this patient's presenting condition?

A. Myocardial hypertrophy (2%)

B. Myocardial thinning and fibrosis (1%)

C. Pericardial effusion (1%)

D. Rupture of chordae tendineae (12%)

✓ E. Valvular inflammation and scarring (82%)

Omitted
Correct answer
E

82%
Answered correctly

11 secs
Time Spent

06/21/2020
Last Updated

Explanation

This patient's presentation - fever, progressive weakness, and dyspnea (due to valvular regurgitation) - along with the presence of vegetations on the mitral valve is consistent with **infective endocarditis** (IE). Predisposing factors for IE include **valvular abnormalities** (eg, rheumatic heart disease, mitral valve prolapse, prosthetic valves, congenital heart disease) and conditions that promote **bacteremia/fungemia** (eg, intravenous drug use, dental procedures).

This patient likely had a remote history of **rheumatic heart disease** (immigrant from developing region, history of heart disease) with underlying degeneration of the mitral valve due to chronic **valvular inflammation and scarring**.

(Choice A) Myocardial hypertrophy is seen in patients with uncontrolled hypertension, aortic stenosis, and hypertrophic cardiomyopathy and, in general, does not predispose to IE.

(Choice B) Myocardial fibrosis is associated with infiltrative cardiomyopathy (sarcoidosis, amyloidosis), Chagas disease, myocarditis, and prior myocardial infarction. It does not lead to increased risk of IE.

(Choice C) Pericardial effusion occurs as a result of inflammation of the pericardium (acute or chronic pericarditis) and has no association with the risk of IE.

(Choice D) Rupture of chordae tendineae is a complication of endocarditis or myocardial infarction; it is not a risk factor for development of IE.

Educational objective:
Chronic valvular inflammation and scarring associated with rheumatic heart disease predispose to an increased risk of infective endocarditis, which is characterized by valvular vegetations with destruction of the underlying cardiac tissue.

References

- Underlying cardiac lesions in adults with infective endocarditis. The changing spectrum.

Pathology	Cardiovascular System	Endocarditis
Subject	System	Topic

Copyright © UWorld. All rights reserved.

Item 2 of 2

The blood cultures obtained from this patient on admission grow *Streptococcus* species. Which of the following processes was the most likely initiating step in the pathogenesis of this patient's condition?

A. Endocardial fibrosis

B. Fibrin deposition

C. Liquefactive necrosis

D. Myxomatous degeneration

E. White blood cell infiltration

Submit

Item 2 of 2

The blood cultures obtained from this patient on admission grow *Streptococcus* species. Which of the following processes was the most likely initiating step in the pathogenesis of this patient's condition?

A. Endocardial fibrosis (8%)
✓ B. Fibrin deposition (52%)
C. Liquefactive necrosis (1%)
D. Myxomatous degeneration (13%)
E. White blood cell infiltration (24%)

Omitted
Correct answer
B

52%
Answered correctly

03 secs
Time Spent

06/21/2020
Last Updated

Explanation

The initial process involved in the pathogenesis of infective endocarditis (IE) is a **disruption of normal endocardial surface**. This occurs most commonly at the areas of maximal turbulence to blood flow in preexisting valvular lesions, typically the atrial surface of incompetent atrioventricular valves or the ventricular surface of incompetent semilunar valves. This is followed by focal adherence of fibrin and platelets, forming a **sterile fibrin-platelet nidus**.

During bacteremia from any cause, microorganisms colonize the sterile nidus on the endothelial surface with subsequent microbial growth leading to further activation of the coagulation system. Streptococci infect the cardiac valves with preexisting endothelial lesions. In contrast, *Staphylococcus aureus* can adhere to damaged or normal endothelial cells. Macroscopic vegetations consist of fibrin and platelets on the surface

Explanation

The initial process involved in the pathogenesis of infective endocarditis (IE) is a **disruption of normal endocardial surface**. This occurs most commonly at the areas of maximal turbulence to blood flow in preexisting valvular lesions, typically the atrial surface of incompetent atrioventricular valves or the ventricular surface of incompetent semilunar valves. This is followed by focal adherence of fibrin and platelets, forming a **sterile fibrin-platelet nidus**.

During bacteremia from any cause, microorganisms colonize the sterile nidus on the endothelial surface with subsequent microbial growth leading to further activation of the coagulation system. Streptococci infect the cardiac valves with preexisting endothelial lesions. In contrast, *Staphylococcus aureus* can adhere to damaged or normal endothelial cells. Macroscopic vegetations consist of fibrin and platelets on the surface, with red blood cell debris, leukocytes, and clusters of microorganisms embedded deep within the lesion.

(Choice A) Endomyocardial fibrosis is a restrictive cardiomyopathy characterized by thickening and fibrosis of the apical endocardial surface. It occurs most commonly in tropical regions (eg, Uganda).

(Choices C and E) Neutrophil-rich inflammatory infiltrates with subsequent abscess formation and/or liquefactive necrosis of underlying cardiac tissue are common in advanced lesions.

(Choice D) Myxomatous degeneration of the mitral valve is characterized by thickened and redundant mitral leaflets with elongated chordae leading to prolapse of one or both mitral leaflets (mitral valve prolapse). Myxomatous degeneration can predispose patients to the development of endocarditis; however, endocarditis vegetations themselves are not formed through myxomatous degeneration.

Educational objective:
Vegetations are caused by bacterial colonization and growth on a sterile fibrin-platelet nidus that forms on the damaged/disrupted endothelial surface of the valvular apparatus.

References

- Pathogenesis of streptococcal and staphylococcal endocarditis.
- Mechanisms of infective endocarditis: pathogen-host interaction and risk states.

Pathology Cardiovascular System Endocarditis

A 45-year-old woman comes to the office due to 3 days of progressive pain in the right upper quadrant, nausea, and vomiting. In the preceding year, the patient has had fatigue, weight loss, joint pain, and intermittent abdominal pain. Laboratory studies show increased blood urea nitrogen and serum creatinine. Right-upper quadrant ultrasound shows no evidence of gallstones, but an inflamed gallbladder is present. The patient undergoes cholecystectomy, and subsequent biopsy of the submucosal gallbladder vessels is shown in the exhibit (2 images). Which of the following is the most likely diagnosis?

A. Angiodysplasia

B. Antiphospholipid-antibody syndrome

C. Granulomatosis with polyangiitis

D. Polyarteritis nodosa

E. Thromboangiitis obliterans

Submit

1
2
3
4
5
6
7
8
9
10
11
12
13
14
15
16
17
18
19
20
21
22
23

Exhibit Display

Exhibit 1 Exhibit 2

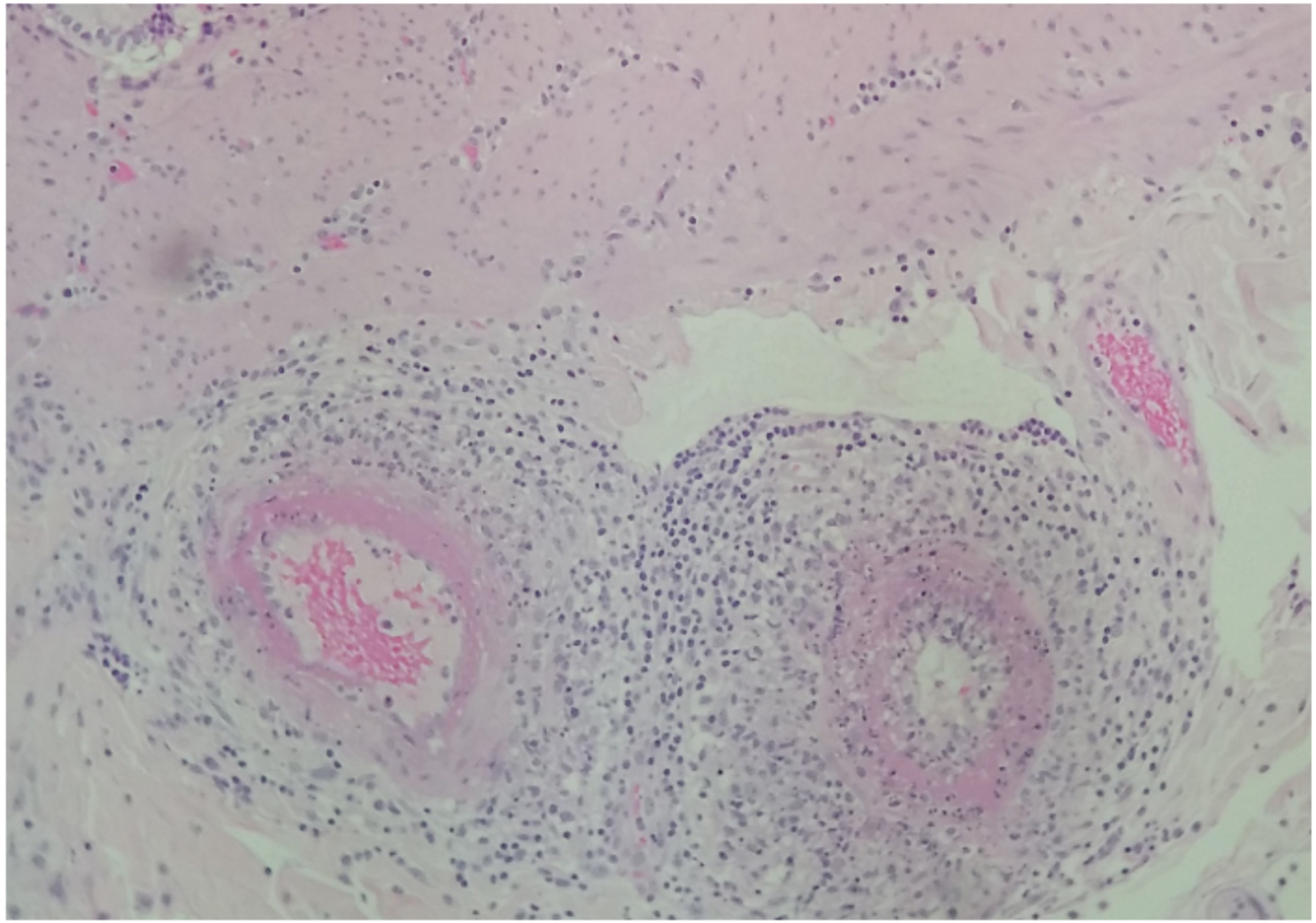

Zoom In Zoom Out Reset Add To New Card | Existing Card

- internal/external elastic lamina damage → microaneurysm formation → rupture & bleeding

1
2
3
4
5
6
7
8
9
10
11
12
13
14
15
16
17
18
19
20
21
22
23

Exhibit Display

Exhibit 1 Exhibit 2

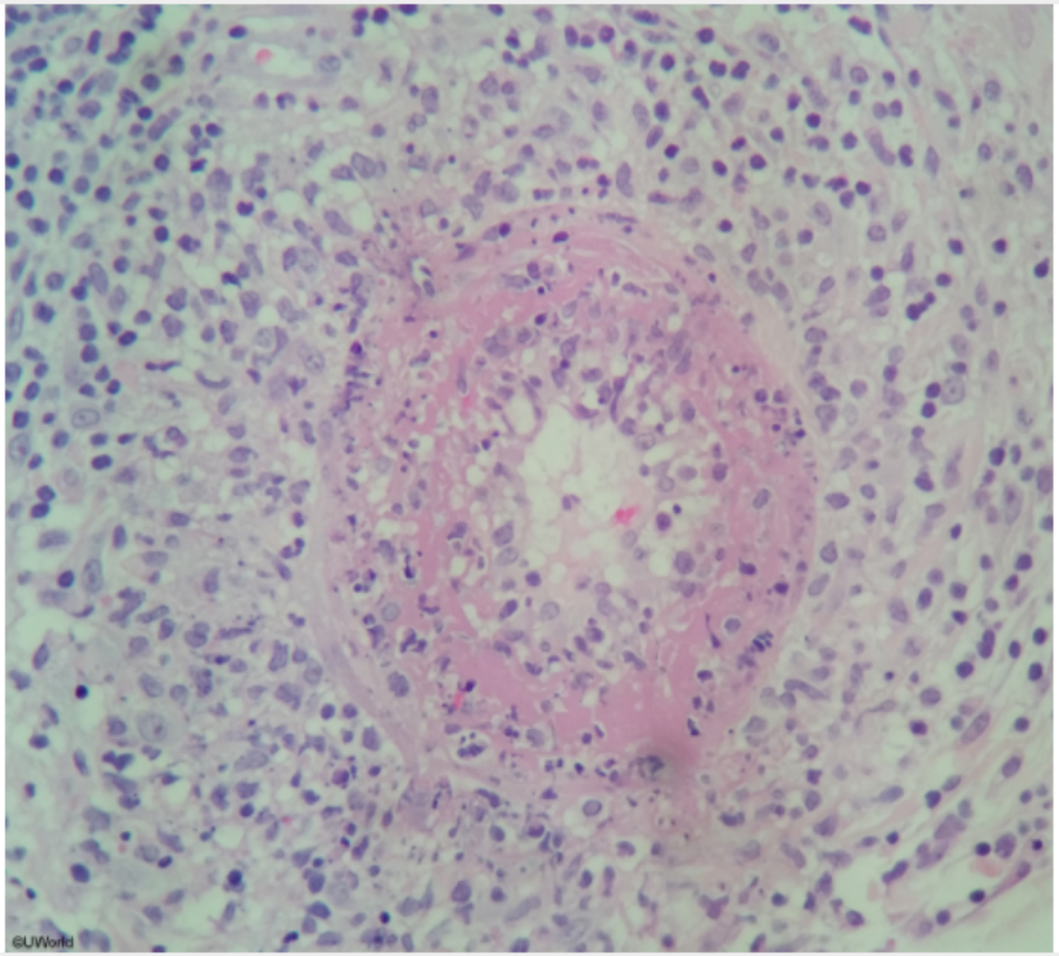

Zoom In Zoom Out Reset Add To New Card | Existing Card

- internal/external elastic lamina damage → microaneurysm formation → rupture & bleeding

1
2
3
4
5
6
7
8
9
10
11
12
13
14
15
16
17
18
19
20
21
22
23

Exhibit Display

Exhibit 1 Exhibit 2

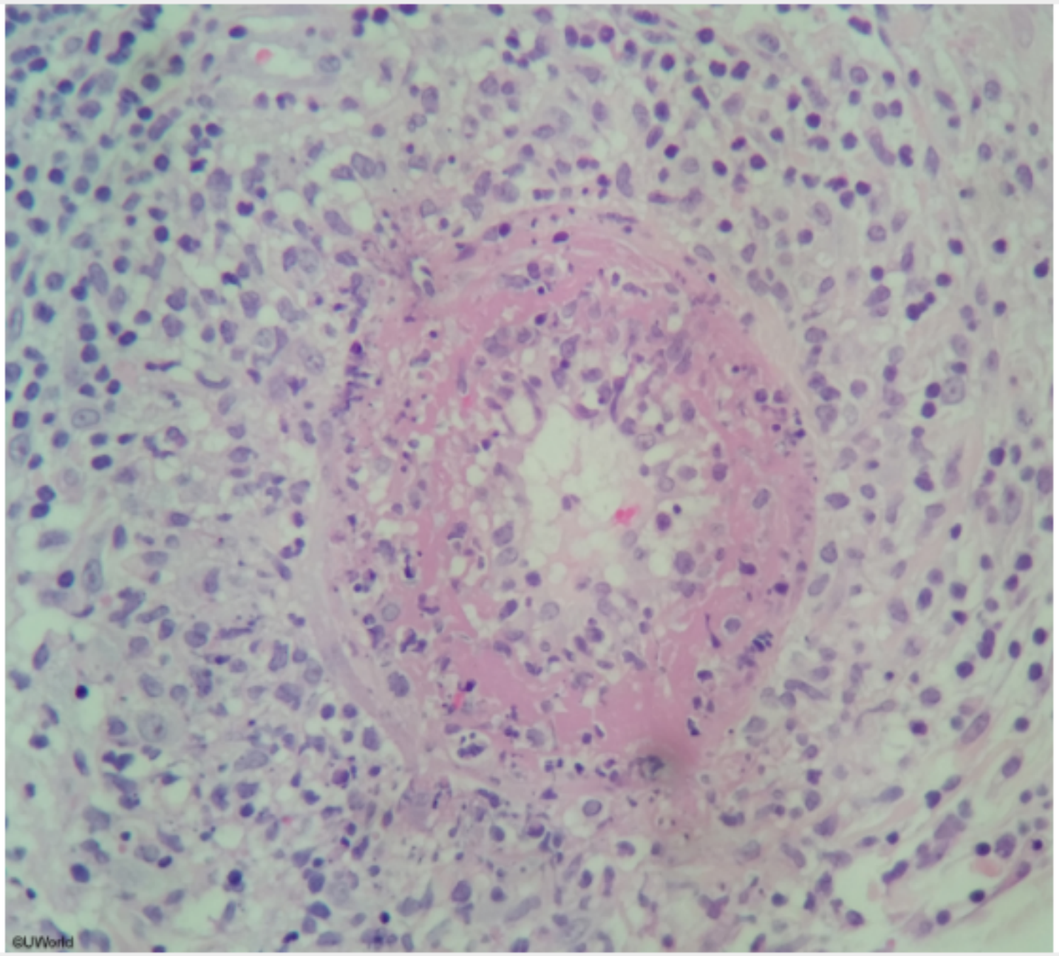

Zoom In Zoom Out Reset Add To New Card | Existing Card

- internal/external elastic lamina damage → microaneurysm formation → rupture & bleeding

A 45-year-old woman comes to the office due to 3 days of progressive pain in the right upper quadrant, nausea, and vomiting. In the preceding year, the patient has had fatigue, weight loss, joint pain, and intermittent abdominal pain. Laboratory studies show increased blood urea nitrogen and serum creatinine. Right-upper quadrant ultrasound shows no evidence of gallstones, but an inflamed gallbladder is present. The patient undergoes cholecystectomy, and subsequent biopsy of the submucosal gallbladder vessels is shown in the exhibit (2 images). Which of the following is the most likely diagnosis?

- A. Angiodysplasia (6%)
- B. Antiphospholipid-antibody syndrome (9%)
- C. Granulomatosis with polyangiitis (21%)
- ✓ D. Polyarteritis nodosa (53%)
- E. Thromboangiitis obliterans (8%)

Omitted
Correct answer
D

53%
Answered correctly

02 secs
Time Spent

06/23/2020
Last Updated

Explanation

Polyarteritis nodosa	
Pathophysiology	• Correlation with underlying hepatitis B/C (immune complexes) • Fibrinoid necrosis of arterial wall → luminal narrowing & thrombosis → tissue ischemia • Internal/external elastic lamina damage → microaneurysm formation → rupture & bleeding

Polyarteritis nodosa	
Pathophysiology	• Correlation with underlying hepatitis B/C (immune complexes) • Fibrinoid necrosis of arterial wall → luminal narrowing & thrombosis → tissue ischemia • Internal/external elastic lamina damage → microaneurysm formation → rupture & bleeding
Clinical features	• Constitutional: fever, weight loss, malaise • Skin: nodules, livedo reticularis, ulcers, purpura • Renal: hypertension, renal insufficiency, arterial aneurysms • Nervous: headache, seizures, mononeuritis multiplex • Gastrointestinal: mesenteric ischemia/infarction • Musculoskeletal: myalgias, arthritis
Diagnosis	• Negative ANCA & ANA • Angiography: microaneurysms & segmental/distal narrowing • Tissue biopsy: nongranulomatous transmural inflammation

ANA = antinuclear antibodies; **ANCA** = antineutrophil cytoplasmic antibodies.

This patient's vomiting, right upper quadrant pain, and gallbladder inflammation with no evidence of gallstones indicates **acute acalculous cholecystitis**. Although a variety of conditions cause acute acalculous cholecystitis, the presence of long-standing, nonspecific symptoms (eg, **fatigue**, weight loss, **arthralgias**) and biopsy findings of fibrinoid necrosis in the submucosal arteries of the gallbladder raise strong suspicion for **polyarteritis nodosa** (PAN).

PAN is a systemic vasculitis of **medium-sized muscular arteries**; biopsy of affected areas generally reveals the following:

- Segmental fibrinoid necrosis (amorphic, eosinophilic areas) in the vessel wall
- Infiltration of the vessel wall with mononuclear cells and neutrophils
- Internal and external **elastic laminae damage**, which may cause microaneurysms

In contrast to many other vasculitides (eg, granulomatosis with polyangiitis), there is **no granulomatous inflammation** in PAN.

ANA = antinuclear antibodies; **ANCA** = antineutrophil cytoplasmic antibodies.

This patient's vomiting, right upper quadrant pain, and gallbladder inflammation with no evidence of gallstones indicates **acute acalculous cholecystitis**. Although a variety of conditions cause acute acalculous cholecystitis, the presence of long-standing, nonspecific symptoms (eg, **fatigue**, weight loss, **arthralgias**) and biopsy findings of fibrinoid necrosis in the submucosal arteries of the gallbladder raise strong suspicion for **polyarteritis nodosa** (PAN).

PAN is a systemic vasculitis of **medium-sized muscular arteries**; biopsy of affected areas generally reveals the following:

- Segmental fibrinoid necrosis (amorphic, eosinophilic areas) in the vessel wall
- Infiltration of the vessel wall with mononuclear cells and neutrophils
- Internal and external **elastic laminae damage**, which may cause microaneurysms

In contrast to many other vasculitides (eg, granulomatosis with polyangiitis), there is **no granulomatous inflammation** in PAN.

PAN typically attacks arteries of the **kidneys** (eg, increased BUN/creatinine), skin, neurologic system, and **gastrointestinal tract**; most cases present due to symptoms of **tissue ischemia** from artery lumen narrowing/thrombosis or **bleeding** from microaneurysm rupture. In this case, damage to the submucosal gallbladder arteries likely caused gallbladder ischemia, which lead to acalculous cholecystitis. Other common gastrointestinal findings in PAN include bead-like microaneurysm formation in the mesenteric vessels, mesenteric ischemia, and bowel necrosis/rupture.

(Choice A) Angiodysplasia is thought to arise from intermittent obstruction of submucosal veins at the muscularis propria of the gastrointestinal tract. Biopsy shows dilated small vessels lined by thin-walled endothelium; infiltration with inflammatory cells would not be seen. In addition, patients with angiodysplasia generally have gastrointestinal bleeding, not acalculous cholecystitis.

(Choice B) Antiphospholipid-antibody syndrome is characterized by small-vessel thrombosis due to the formation of autoantibodies against phospholipid-binding proteins. It is often triggered by underlying systemic lupus erythematosus, which can cause long-standing nonspecific symptoms. However, acute biopsy would show thrombosed vessels, not vessels with fibrinoid necrosis and neutrophilic inflammation.

(Choice C) Granulomatosis with polyangiitis is an antineutrophil cytoplasmic antibody–positive vasculitis that generally affects the upper airways, lungs, and kidneys. Gastrointestinal involvement is uncommon.

(Choice E) Thromboangiitis obliterans primarily attacks vessels in the extremities. It is marked by inflammatory thrombi with relative sparing of

ANA = antinuclear antibodies; **ANCA** = antineutrophil cytoplasmic antibodies.

Exhibit Display

Gallbladder vasculitis

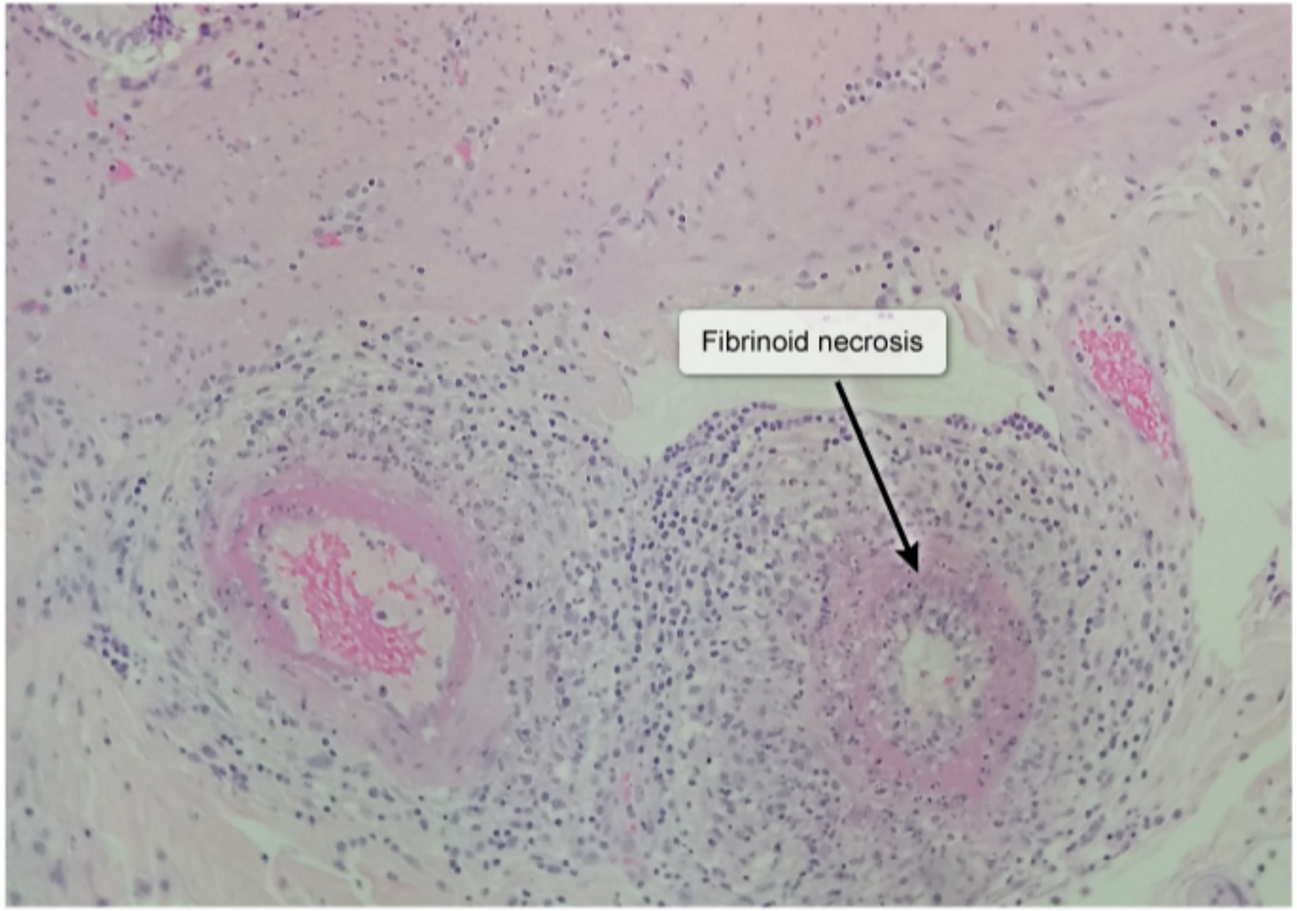

Zoom In Zoom Out Reset Add To New Card | Existing Card

(Choice E) Thromboangiitis obliterans primarily attacks vessels in the extremities. It is marked by inflammatory thrombi with relative sparing of

In contrast to many other vasculitides (eg, granulomatosis with polyangiitis), there is **no granulomatous inflammation** in PAN.

PAN typically attacks arteries of the **kidneys** (eg, increased BUN/creatinine), skin, neurologic system, and **gastrointestinal tract**; most cases present due to symptoms of **tissue ischemia** from artery lumen narrowing/thrombosis or **bleeding** from microaneurysm rupture. In this case, damage to the submucosal gallbladder arteries likely caused gallbladder ischemia, which lead to acalculous cholecystitis. Other common gastrointestinal findings in PAN include bead-like microaneurysm formation in the mesenteric vessels, mesenteric ischemia, and bowel necrosis/rupture.

(Choice A) Angiodysplasia is thought to arise from intermittent obstruction of submucosal veins at the muscularis propria of the gastrointestinal tract. Biopsy shows dilated small vessels lined by thin-walled endothelium; infiltration with inflammatory cells would not be seen. In addition, patients with angiodysplasia generally have gastrointestinal bleeding, not acalculous cholecystitis.

(Choice B) Antiphospholipid-antibody syndrome is characterized by small-vessel thrombosis due to the formation of autoantibodies against phospholipid-binding proteins. It is often triggered by underlying systemic lupus erythematosus, which can cause long-standing nonspecific symptoms. However, acute biopsy would show thrombosed vessels, not vessels with fibrinoid necrosis and neutrophilic inflammation.

(Choice C) Granulomatosis with polyangiitis is an antineutrophil cytoplasmic antibody–positive vasculitis that generally affects the upper airways, lungs, and kidneys. Gastrointestinal involvement is uncommon.

(Choice E) Thromboangiitis obliterans primarily attacks vessels in the extremities. It is marked by inflammatory thrombi with relative sparing of the vessel wall (eg, no fibrinoid necrosis). Most cases are seen in young smokers.

Educational objective:
Polyarteritis nodosa is characterized by segmental, transmural, necrotizing inflammation of medium-sized muscular arteries. Manifestations arise due to tissue ischemia from arterial lumen narrowing/thrombosis or bleeding from microaneurysms. The vessels of the kidneys, skin, peripheral nerves, and gastrointestinal tract are affected most commonly; the lung is typically spared.

Pathology	Cardiovascular System	Polyarteritis nodosa
Subject	System	Topic

Copyright © UWorld. All rights reserved.

A 56-year-old woman with unknown medical history is brought to the emergency department in an unresponsive state. Paramedics were called for sudden-onset, left-sided weakness, and when they arrived at the patient's house she was having a generalized tonic-clonic seizure. Antiseizure medications were given and the patient was subsequently intubated. Evaluation shows a comatose woman with left hemiplegia. Neuroimaging reveals a large infarction in the right middle cerebral artery territory with cerebral edema. Despite aggressive interventions, the patient dies from brain herniation. Autopsy reveals multiple small, nondestructive masses attached to the edges of the mitral valve leaflets. Microscopy shows that these masses are composed of platelet-rich thrombi, but no organisms are present. Which of the following conditions is most closely associated with this patient's heart valve findings?

- A. Advanced malignancy
- B. Chronic liver failure
- C. Dilated cardiomyopathy
- D. End-stage renal disease
- E. Large-vessel vasculitis

Submit

A 56-year-old woman with unknown medical history is brought to the emergency department in an unresponsive state. Paramedics were called for sudden-onset, left-sided weakness, and when they arrived at the patient's house she was having a generalized tonic-clonic seizure. Antiseizure medications were given and the patient was subsequently intubated. Evaluation shows a comatose woman with left hemiplegia. Neuroimaging reveals a large infarction in the right middle cerebral artery territory with cerebral edema. Despite aggressive interventions, the patient dies from brain herniation. Autopsy reveals multiple small, nondestructive masses attached to the edges of the mitral valve leaflets. Microscopy shows that these masses are composed of platelet-rich thrombi, but no organisms are present. Which of the following conditions is most closely associated with this patient's heart valve findings?

- ✓ A. Advanced malignancy (35%)
- B. Chronic liver failure (5%)
- C. Dilated cardiomyopathy (17%)
- D. End-stage renal disease (25%)
- E. Large-vessel vasculitis (16%)

Omitted
Correct answer
A

35%
Answered correctly

03 secs
Time Spent

03/17/2020
Last Updated

Explanation

The autopsy finding of **sterile platelet-rich thrombi** attached to the mitral valve leaflets is characteristic of **nonbacterial thrombotic endocarditis** (NBTE) (marantic endocarditis). The pathogenesis of NBTE is thought to begin with valvular endothelial injury caused by circulating inflammatory cytokines, which triggers platelet deposition in the presence of an underlying **hypercoagulable state**. NBTE is most commonly

Explanation

The autopsy finding of **sterile platelet-rich thrombi** attached to the mitral valve leaflets is characteristic of **nonbacterial thrombotic endocarditis** (NBTE) (marantic endocarditis). The pathogenesis of NBTE is thought to begin with valvular endothelial injury caused by circulating inflammatory cytokines, which triggers platelet deposition in the presence of an underlying **hypercoagulable state**. NBTE is most commonly associated with **advanced malignancy** (especially mucinous adenocarcinoma) and systemic lupus erythematosus (Libman-Sacks endocarditis); less commonly, it can occur with antiphospholipid syndrome, disseminated intravascular coagulation, and extensive burns.

Histologically, NBTE vegetations consist of bland thrombus with strands of fibrin, immune complexes, and mononuclear cells (white thrombus). The vegetations typically affect the left-sided heart valves (mitral or aortic) and are often asymptomatic; however, **systemic embolization** (eg, stroke, acute limb ischemia) can occur and is the most common presentation of NBTE.

(Choice B) Chronic liver failure (ie, cirrhosis) can be complicated by portal vein thrombosis; however, it is not associated with NBTE.

(Choice C) Dilated cardiomyopathy is characterized by ventricular enlargement and reduced systolic function. It can occasionally lead to left ventricular mural thrombus with risk of systemic embolization, but it is not associated with NBTE.

(Choice D) Although systemic lupus erythematosus is often complicated by end-stage renal disease, NBTE is not directly associated with renal disease. End-stage renal disease can accelerate aortic valve calcification, however.

(Choice E) Temporal (giant cell) arteritis, a large-vessel vasculitis that typically presents with headaches and fever, is associated with an increased risk of venous thromboembolic disease. Although associated NBTE has been reported, it is quite rare.

Educational objective:
Nonbacterial thrombotic endocarditis is a form of noninfectious endocarditis characterized by valvular deposition of sterile platelet-rich thrombi. It likely results from valvular damage due to inflammatory cytokines in the setting of an underlying hypercoagulable state, and it is most commonly seen with advanced malignancy (especially mucinous adenocarcinoma) or systemic lupus erythematosus.

References

- Nonbacterial thrombotic endocarditis: clinicopathologic study of a necropsy series.

A 74-year-old man comes to the office for a follow-up visit for hypertension. His last visit was a year ago. He has no chest pain, shortness of breath, leg swelling, or dizziness. The patient is compliant with his medications and can tolerate a moderate level of physical activity. Blood pressure is 145/75 mm Hg and pulse is 67/min and regular. Auscultation findings at the base of the heart are depicted in the exhibit below.

Which of the following is the most likely cause of this patient's physical findings?

- A. Ankylosing spondylitis
- B. Chordal rupture
- C. Coronary artery disease
- D. Cystic medial necrosis
- E. Infective endocarditis
- F. Rheumatic fever
- G. Right ventricular failure
- H. Valvular calcification

1
2
3
4
5
6
7
8
9
10
11
12
13
14
15
16
17
18
19
20
21
22
23

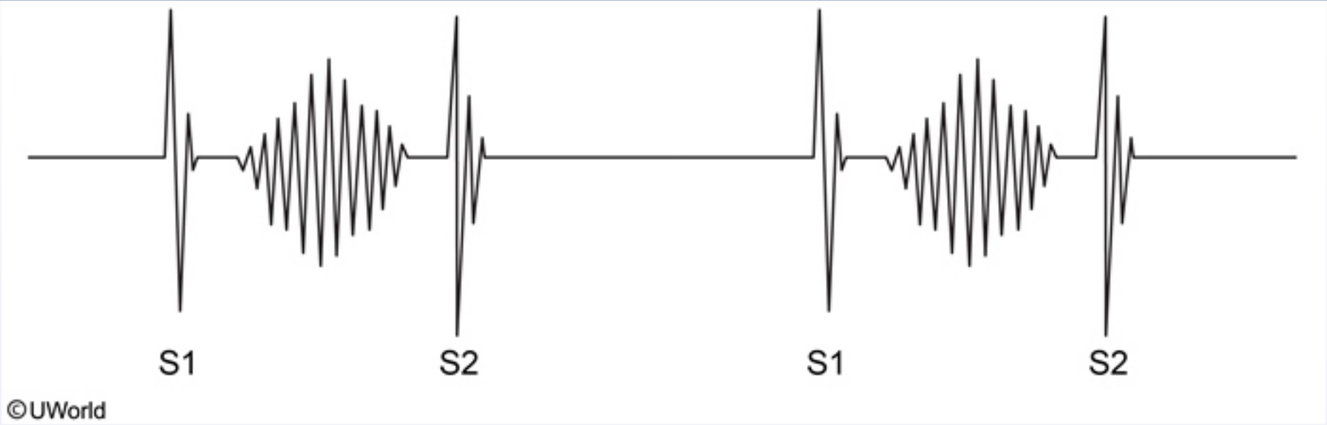

Which of the following is the most likely cause of this patient's physical findings?

- A. Ankylosing spondylitis
- B. Chordal rupture
- C. Coronary artery disease
- D. Cystic medial necrosis
- E. Infective endocarditis
- F. Rheumatic fever
- G. Right ventricular failure
- H. Valvular calcification

Submit

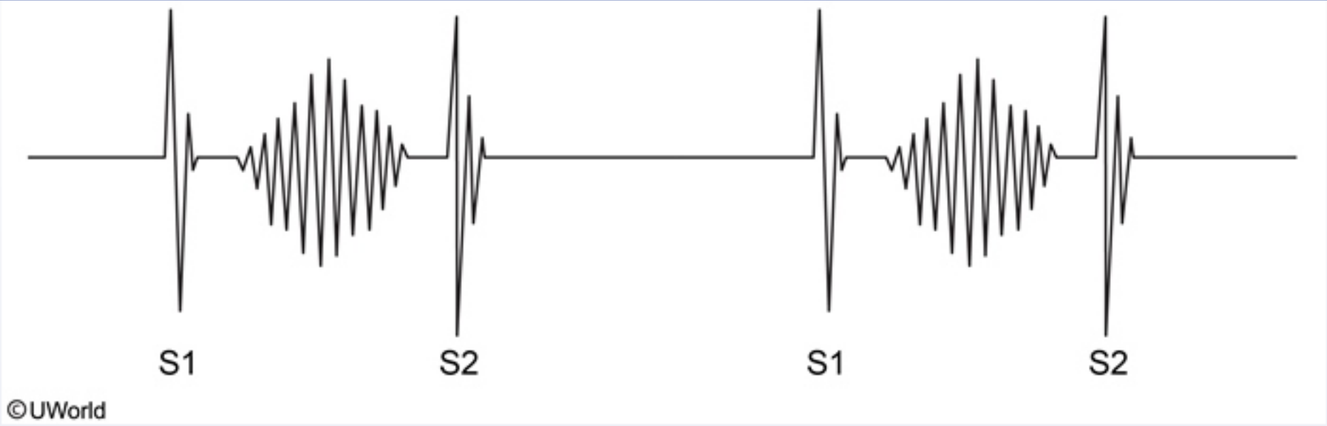

Which of the following is the most likely cause of this patient's physical findings?

- A. Ankylosing spondylitis (0%)
- B. Chordal rupture (3%)
- C. Coronary artery disease (2%)
- D. Cystic medial necrosis (1%)
- E. Infective endocarditis (1%)
- F. Rheumatic fever (5%)
- G. Right ventricular failure (1%)
- ✓ H. Valvular calcification (84%)

Omitted
Correct answer

84%
Answered correctly

08 secs
Time Spent

02/16/2020
Last Updated

The diagram above depicts a **crescendo-decrescendo systolic murmur** peaking in midsystole, characteristic of **aortic or pulmonic stenosis**. The most common cause of aortic stenosis (AS) in elderly patients (age ≥70) is degenerative calcification of the aortic valve leaflets. **Calcific AS** is caused by chronic hemodynamic stress or atherosclerotic inflammation that eventually leads to progressive aortic valve leaflet thickening, calcification, and stenosis. The murmur of valvular AS is best heard over **the right second interspace** (where the aorta leaves the base of the heart) with radiation to neck and carotid arteries. A longer and late-peaking murmur usually indicates severe AS, whereas a brief and early-peaking murmur indicates less severe stenosis. However, the intensity of the murmur does not correlate with the severity of stenosis.

(Choice A) Ankylosing spondylitis is a chronic inflammatory disease of the axial skeleton characterized by progressive pain and stiffness of the spine, sacroiliitis, and increased risk of aortic regurgitation.

(Choice B) Chordal rupture would lead to flail mitral leaflet with mitral valve prolapse and mitral regurgitation. Mitral regurgitation associated with chordal rupture would lead to a holosystolic decrescendo murmur.

(Choice C) Coronary artery disease is not associated with a systolic murmur on auscultation.

(Choice D) Cystic medial necrosis predisposes to the formation of thoracic aortic aneurysms with an increased risk of aortic dissection. It can also cause dilation of the aortic root leading to aortic regurgitation.

(Choice E) Infectious endocarditis of the aortic or mitral valve typically causes aortic or mitral regurgitation, respectively. Aortic regurgitation leads to an early diastolic murmur, best heard over the lower left sternal border or right second interspace with the patient sitting and leaning forward with breath held in full expiration. Mitral regurgitation causes a holosystolic murmur best heard at the cardiac apex in the left lateral decubitus position.

(Choice F) Rheumatic heart disease is the most common cause of AS in the developing world and is invariably accompanied by rheumatic mitral valve disease (mitral stenosis and/or regurgitation). It is an uncommon cause of AS in developed nations.

(Choice G) Right ventricular failure leads to jugular venous distension, along with hepatomegaly, ascites, and peripheral edema. Significant right ventricular dilation can cause tricuspid insufficiency, which is characterized by a holosystolic murmur at the left lower sternal border.

Educational objective:
The murmur of valvular aortic stenosis is typically an ejection or midsystolic murmur of crescendo-decrescendo configuration with maximum intensity over the right second interspace and radiation to neck and carotid arteries. The most common cause of aortic stenosis in elderly patients

(Choice A) Ankylosing spondylitis is a chronic inflammatory disease of the axial skeleton characterized by progressive pain and stiffness of the spine, sacroiliitis, and increased risk of aortic regurgitation.

(Choice B) Chordal rupture would lead to flail mitral leaflet with mitral valve prolapse and mitral regurgitation. Mitral regurgitation associated with chordal rupture would lead to a holosystolic decrescendo murmur.

(Choice C) Coronary artery disease is not associated with a systolic murmur on auscultation.

(Choice D) Cystic medial necrosis predisposes to the formation of thoracic aortic aneurysms with an increased risk of aortic dissection. It can also cause dilation of the aortic root leading to aortic regurgitation.

(Choice E) Infectious endocarditis of the aortic or mitral valve typically causes aortic or mitral regurgitation, respectively. Aortic regurgitation leads to an early diastolic murmur, best heard over the lower left sternal border or right second interspace with the patient sitting and leaning forward with breath held in full expiration. Mitral regurgitation causes a holosystolic murmur best heard at the cardiac apex in the left lateral decubitus position.

(Choice F) Rheumatic heart disease is the most common cause of AS in the developing world and is invariably accompanied by rheumatic mitral valve disease (mitral stenosis and/or regurgitation). It is an uncommon cause of AS in developed nations.

(Choice G) Right ventricular failure leads to jugular venous distension, along with hepatomegaly, ascites, and peripheral edema. Significant right ventricular dilation can cause tricuspid insufficiency, which is characterized by a holosystolic murmur at the left lower sternal border.

Educational objective:
The murmur of valvular aortic stenosis is typically an ejection or midsystolic murmur of crescendo-decrescendo configuration with maximum intensity over the right second interspace and radiation to neck and carotid arteries. The most common cause of aortic stenosis in elderly patients (age ≥70) is degenerative calcification of the aortic valve leaflets.

References

- The evolving epidemiology of valvular aortic stenosis. The Tromsø study.

Pathology	Cardiovascular System	Aortic stenosis
Subject	System	Topic

A 65-year-old man dies while hospitalized for severe breathing difficulty. The patient had several prior episodes of dyspnea and cough requiring hospitalization. He had a history of hypertension and chronic kidney disease. The patient smoked a pack of cigarettes daily for 38 years and immigrated to the United States 20 years ago. Autopsy is performed, and microscopic examination of the lungs reveals alveolar macrophages containing aggregates of golden-brown cytoplasmic granules that turn dark blue with Prussian blue staining. Which of the following conditions is most likely associated with this patient's microscopic findings?

- A. Airway hyperreactivity
- B. Coal particle inhalation
- C. Granulomatous microbial infection
- D. Left ventricular dysfunction
- E. Pulmonary arterial hypertension
- F. Pulmonary thromboembolism

Submit

A 65-year-old man dies while hospitalized for severe breathing difficulty. The patient had several prior episodes of dyspnea and cough requiring hospitalization. He had a history of hypertension and chronic kidney disease. The patient smoked a pack of cigarettes daily for 38 years and immigrated to the United States 20 years ago. Autopsy is performed, and microscopic examination of the lungs reveals alveolar macrophages containing aggregates of golden-brown cytoplasmic granules that turn dark blue with Prussian blue staining. Which of the following conditions is most likely associated with this patient's microscopic findings?

- A. Airway hyperreactivity (3%)
- B. Coal particle inhalation (10%)
- C. Granulomatous microbial infection (6%)
- ✓ D. Left ventricular dysfunction (67%)
- E. Pulmonary arterial hypertension (10%)
- F. Pulmonary thromboembolism (2%)

Omitted
Correct answer
D

67%
Answered correctly

02 secs
Time Spent

03/22/2020
Last Updated

Explanation

This patient most likely had heart failure due to **left ventricular dysfunction**. Impaired forward pumping by the left ventricle causes increased pulmonary capillary pressure that can lead to pulmonary edema and dyspnea. The rise in hydrostatic pressure also disrupts the integrity of the pulmonary capillaries, leading to **extravasation of red blood cells** and alveolar hemorrhage. The red blood cells are eventually **phagocytosed by macrophages**, and the iron from hemoglobin is converted to hemosiderin.

This patient most likely had heart failure due to **left ventricular dysfunction**. Impaired forward pumping by the left ventricle causes increased pulmonary capillary pressure that can lead to pulmonary edema and dyspnea. The rise in hydrostatic pressure also disrupts the integrity of the pulmonary capillaries, leading to **extravasation of red blood cells** and alveolar hemorrhage. The red blood cells are eventually **phagocytosed by macrophages**, and the iron from hemoglobin is converted to hemosiderin.

Prussian blue stain detects intracellular iron. In the Prussian blue reaction, colorless potassium ferrocyanide is converted by iron to blue-black ferric ferrocyanide. Macrophages containing golden-brown cytoplasmic granules that turn blue with Prussian blue staining represent **hemosiderin-laden macrophages** (siderophages). These cells may be found in any tissue where macrophages encounter extravasated red blood cells; in the alveolar parenchyma, they are often called "heart failure cells."

(Choice A) Airway hyperreactivity occurs in asthma or chronic obstructive pulmonary disease, neither of which is associated with hemosiderin-laden macrophages.

(Choice B) Coal worker's pneumoconiosis results from chronic inhalation of coal dust and is associated with alveolar macrophages containing black intracytoplasmic aggregates, so-called carbon-laden macrophages. These carbon aggregates do not stain blue with Prussian blue staining.

(Choice C) A number of infectious organisms (eg, *Mycobacterium tuberculosis*, *Histoplasma capsulatum*) can survive within macrophages and produce a granulomatous response in the lungs; however these organisms are typically visualized using other special staining methods (eg, acid-fast staining) and would not stain blue with Prussian blue staining.

(Choices E and F) Pulmonary arterial hypertension (primary pulmonary hypertension) and pulmonary thromboembolism both involve an elevation in pulmonary arterial pressure; however, pulmonary edema with extravasation of red blood cells does not occur as pulmonary capillary and pulmonary venous pressures are not elevated.

Educational objective:
Alveolar hemosiderin-laden macrophages indicate alveolar hemorrhage. They most commonly result from chronic elevation of pulmonary capillary hydrostatic pressure in the setting of left-sided heart failure.

Pathology	Cardiovascular System	Chronic heart failure
Subject	System	Topic

pulmonary capillary pressure that can lead to pulmonary edema and dyspnea. The rise in hydrostatic pressure also disrupts the integrity of the pulmonary capillaries, leading to **extravasation of red blood cells** and alveolar hemorrhage. The red blood cells are eventually **phagocytosed by macrophages**, and the iron from hemoglobin is converted to hemosiderin.

Prussian blue stain detects intracellular iron. In the Prussian blue reaction, colorless potassium ferrocyanide is converted by iron to blue-black ferric ferrocyanide. Macrophages containing golden-brown cytoplasmic granules that turn blue with Prussian blue staining represent **hemosiderin-laden macrophages** (siderophages). These cells may be found in any tissue where macrophages encounter extravasated red blood cells; in the alveolar parenchyma, they are often called "heart failure cells."

(Choice A) Airway hyperreactivity occurs in asthma or chronic obstructive pulmonary disease, neither of which is associated with hemosiderin-laden macrophages.

(Choice B) Coal worker's pneumoconiosis results from chronic inhalation of coal dust and is associated with alveolar macrophages containing black intracytoplasmic aggregates, so-called carbon-laden macrophages. These carbon aggregates do not stain blue with Prussian blue staining.

(Choice C) A number of infectious organisms (eg, *Mycobacterium tuberculosis*, *Histoplasma capsulatum*) can survive within macrophages and produce a granulomatous response in the lungs; however these organisms are typically visualized using other special staining methods (eg, acid-fast staining) and would not stain blue with Prussian blue staining.

(Choices E and F) Pulmonary arterial hypertension (primary pulmonary hypertension) and pulmonary thromboembolism both involve an elevation in pulmonary arterial pressure; however, pulmonary edema with extravasation of red blood cells does not occur as pulmonary capillary and pulmonary venous pressures are not elevated.

Educational objective:
Alveolar hemosiderin-laden macrophages indicate alveolar hemorrhage. They most commonly result from chronic elevation of pulmonary capillary hydrostatic pressure in the setting of left-sided heart failure.

Pathology	Cardiovascular System	Chronic heart failure
Subject	System	Topic

Copyright © UWorld. All rights reserved.

1
2
3
4
5
6
7
8
9
10
11
12
13
14
15
16
17
18
19
20
21
22
23

pulmonary capillary pressure that can lead to pulmonary edema and dyspnea. The rise in hydrostatic pressure also disrupts the integrity of the

Exhibit Display

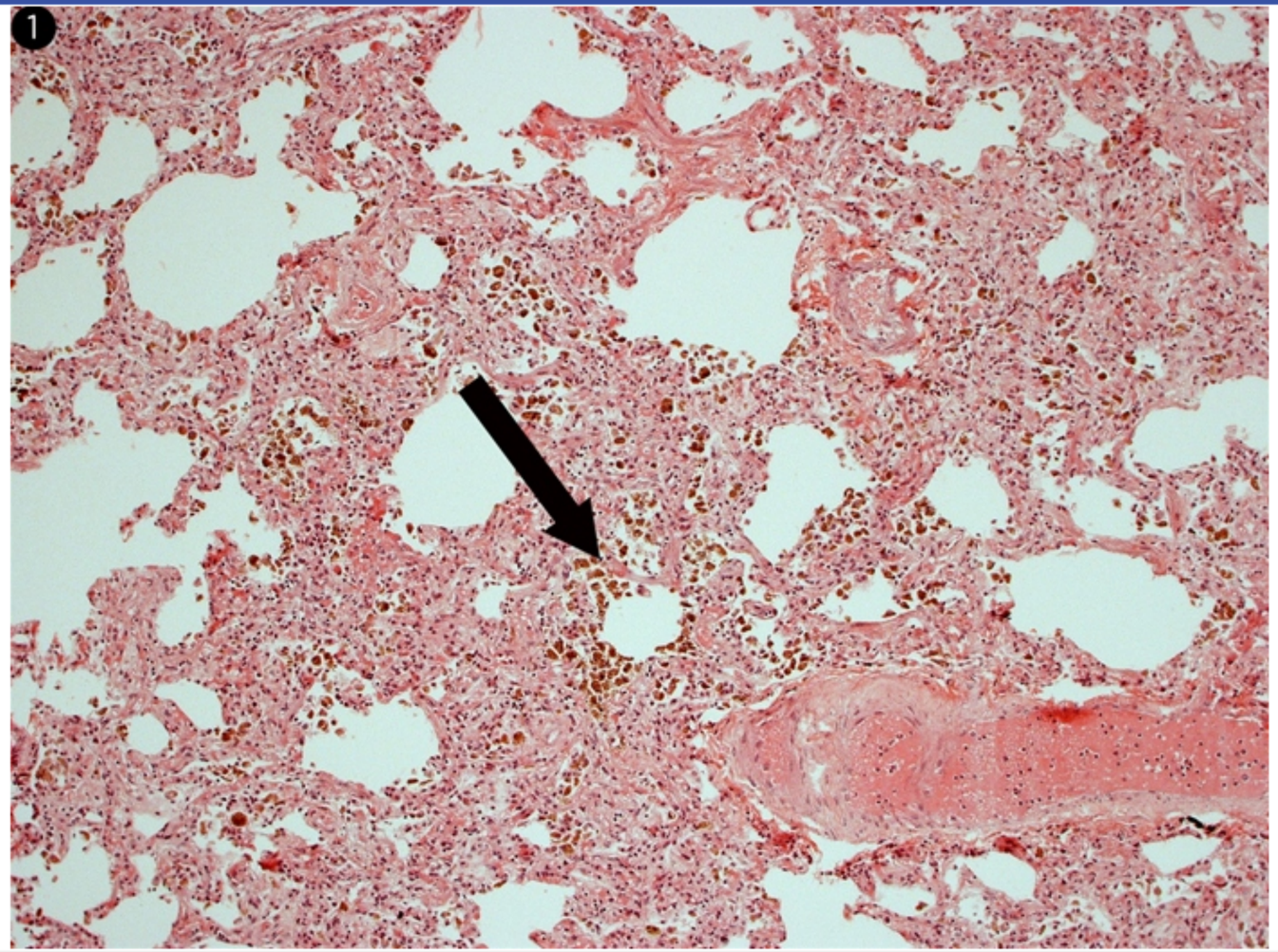

Zoom In Zoom Out Reset Add To New Card | Existing Card

A 30-year-old Asian man comes to the clinic due to painful, ulcerated fingers. His symptoms began with pain and discoloration of the fingers several weeks ago, which progressed to ulceration at the fingertips. He also reports pain in the hands that occurs with activity and is relieved by rest. Medical history is unremarkable. The patient has smoked 2 packs of cigarettes a day for the last 5 years. He occasionally drinks alcohol but does not use illicit drugs. Vital signs are within normal limits. No heart murmurs are heard and the lungs are clear. Examination of the hands is shown in the exhibit. Radial pulses are diminished. There is erythema and tenderness along a superficial vein of the left forearm. Hemoglobin A1c and a fasting lipid panel are within normal limits. Which of the following pathologic findings is most likely to be present in this patient?

A. Granulomatous inflammation of the media

B. Lipid-filled intimal plaque

C. Onion skin–appearing, concentric thickening of the arteriolar wall

D. Segmental vasculitis extending into contiguous veins and nerves

E. Transmural inflammation of the arterial wall with fibrinoid necrosis

Submit

A 30-year-old Asian man comes to the clinic due to painful, ulcerated fingers. His symptoms began with pain and discoloration of the fingers several weeks ago, which progressed to ulceration at the fingertips. He also reports pain in the hands that occurs with activity and is relieved by rest. Medical history is unremarkable. The patient has smoked 2 packs of cigarettes a day for the last 5 years. He occasionally drinks alcohol but does not use illicit drugs. Vital signs are within normal limits. No heart murmurs are heard and the lungs are clear. Examination of the hands is shown in the exhibit. Radial pulses are diminished. There is erythema and tenderness along a superficial vein of the left forearm. Hemoglobin A1c and a fasting lipid panel are within normal limits. Which of the following pathologic findings is most likely to be present in this patient?

- A. Granulomatous inflammation of the media (10%)
- B. Lipid-filled intimal plaque (2%)
- C. Onion skin–appearing, concentric thickening of the arteriolar wall (5%)
- ✓ D. Segmental vasculitis extending into contiguous veins and nerves (58%)
- E. Transmural inflammation of the arterial wall with fibrinoid necrosis (23%)

Omitted
Correct answer
D

58%
Answered correctly

03 secs
Time Spent

04/25/2020
Last Updated

Explanation

Thromboangiitis obliterans (Buerger disease)	
Etiology	• Segmental small & medium-sized vessel vasculitis • Likely triggered by tobacco smoke

1
2
3
4
5
6
7
8
9
10
11
12
13
14
15
16
17
18
19
20
21
22
23

Thromboangiitis obliterans (Buerger disease)	
Etiology	• Segmental small & medium-sized vessel vasculitis • Likely triggered by tobacco smoke
Clinical features	• Age <45, predominantly men • Digital ischemic ulcerations, limb claudication • Raynaud phenomenon, superficial thrombophlebitis
Histopathology	• Inflammatory intraluminal thrombi with vessel wall sparing • Extension into contiguous veins & nerves

This patient's presentation is consistent with **thromboangiitis obliterans (Buerger disease)**, a segmental, inflammatory vasculitis that affects the small- and medium-sized arteries and veins of the distal extremities. It typically affects **young**, **heavy smokers** (age <45) and is more common in men. It is also most prevalent in Asian populations. Toe and/or finger ischemia and **ischemic ulcerations** are the most common manifestation, and patients with involvement of proximal arteries can develop claudication affecting the lower legs, feet, or hands. **Raynaud phenomenon** and superficial thrombophlebitis (erythema, tenderness along veins) may also occur as early manifestations of the disease.

In thromboangiitis obliterans, chronic exposure to tobacco products is thought to cause direct endothelial injury or trigger a delayed-type hypersensitivity reaction against the endothelium. Histopathology shows highly cellular, **inflammatory intraluminal thrombi** (ie, containing neutrophils, multinucleated giant cells) in the arteries and veins with **sparing of the vessel wall** and internal elastic lamina. This segmental, thrombosing vasculitis often extends into contiguous veins and nerves, a feature rarely seen in other types of vasculitis.

(Choice A) Giant cell arteritis (temporal arteritis) is the most common form of systemic vasculitis, affecting mostly large arteries with a predilection for the carotid artery and its branches. It typically affects patients age >50 and presents with unilateral headache, jaw claudication, and transient vision loss (amaurosis fugax). Arterial biopsy reveals characteristic granulomatous inflammation of the media with infiltration of $CD4^+$ lymphocytes and macrophages.

(Choice B) Lipid-filled intimal plaques that bulge into the arterial lumen are seen in patients with atherosclerosis.

	• Extension into contiguous veins & nerves

This patient's presentation is consistent with **thromboangiitis obliterans (Buerger disease)**, a segmental, inflammatory vasculitis that affects the small- and medium-sized arteries and veins of the distal extremities. It typically affects **young**, **heavy smokers** (age <45) and is more common in men. It is also most prevalent in Asian populations. Toe and/or finger ischemia and **ischemic ulcerations** are the most common manifestation, and patients with involvement of proximal arteries can develop claudication affecting the lower legs, feet, or hands. **Raynaud phenomenon** and superficial thrombophlebitis (erythema, tenderness along veins) may also occur as early manifestations of the disease.

In thromboangiitis obliterans, chronic exposure to tobacco products is thought to cause direct endothelial injury or trigger a delayed-type hypersensitivity reaction against the endothelium. Histopathology shows highly cellular, **inflammatory intraluminal thrombi** (ie, containing neutrophils, multinucleated giant cells) in the arteries and veins with **sparing of the vessel wall** and internal elastic lamina. This segmental, thrombosing vasculitis often extends into contiguous veins and nerves, a feature rarely seen in other types of vasculitis.

(Choice A) Giant cell arteritis (temporal arteritis) is the most common form of systemic vasculitis, affecting mostly large arteries with a predilection for the carotid artery and its branches. It typically affects patients age >50 and presents with unilateral headache, jaw claudication, and transient vision loss (amaurosis fugax). Arterial biopsy reveals characteristic granulomatous inflammation of the media with infiltration of $CD4^+$ lymphocytes and macrophages.

(Choice B) Lipid-filled intimal plaques that bulge into the arterial lumen are seen in patients with atherosclerosis.

(Choice C) Hyperplastic arteriosclerosis is characterized by thickening of the arteriolar wall due to the concentric proliferation of smooth muscle cells and reduplicated basement membranes, giving the arterioles an onion-skin appearance. These changes occur as an adaptive response of arterioles to severe (malignant) hypertension.

(Choice E) Transmural inflammation of the arterial wall with fibrinoid necrosis is seen in several types of systemic vasculitis, including microscopic polyangiitis and granulomatosis with polyangiitis. The latter is a necrotizing vasculitis that predominantly involves small- to medium-sized vessels and presents with inflammation of the upper and lower respiratory tracts and necrotizing glomerulonephritis.

Educational objective:
Thromboangiitis obliterans (Buerger disease) is a segmental, inflammatory vasculitis that affects the small- and medium-sized arteries and veins of the distal extremities with inflammatory, intraluminal thrombi and sparing of the vessel wall. It is usually seen in young, heavy smokers, and can present with digital ischemia and ulceration, extremity claudication, Raynaud phenomenon, and superficial thrombophlebitis.

In thromboangiitis obliterans, chronic exposure to tobacco products is thought to cause direct endothelial injury or trigger a delayed-type hypersensitivity reaction against the endothelium. Histopathology shows highly cellular, **inflammatory intraluminal thrombi** (ie, containing neutrophils, multinucleated giant cells) in the arteries and veins with **sparing of the vessel wall** and internal elastic lamina. This segmental, thrombosing vasculitis often extends into contiguous veins and nerves, a feature rarely seen in other types of vasculitis.

(Choice A) Giant cell arteritis (temporal arteritis) is the most common form of systemic vasculitis, affecting mostly large arteries with a predilection for the carotid artery and its branches. It typically affects patients age >50 and presents with unilateral headache, jaw claudication, and transient vision loss (amaurosis fugax). Arterial biopsy reveals characteristic granulomatous inflammation of the media with infiltration of $CD4^+$ lymphocytes and macrophages.

(Choice B) Lipid-filled intimal plaques that bulge into the arterial lumen are seen in patients with atherosclerosis.

(Choice C) Hyperplastic arteriosclerosis is characterized by thickening of the arteriolar wall due to the concentric proliferation of smooth muscle cells and reduplicated basement membranes, giving the arterioles an onion-skin appearance. These changes occur as an adaptive response of arterioles to severe (malignant) hypertension.

(Choice E) Transmural inflammation of the arterial wall with fibrinoid necrosis is seen in several types of systemic vasculitis, including microscopic polyangiitis and granulomatosis with polyangiitis. The latter is a necrotizing vasculitis that predominantly involves small- to medium-sized vessels and presents with inflammation of the upper and lower respiratory tracts and necrotizing glomerulonephritis.

Educational objective:
Thromboangiitis obliterans (Buerger disease) is a segmental, inflammatory vasculitis that affects the small- and medium-sized arteries and veins of the distal extremities with inflammatory, intraluminal thrombi and sparing of the vessel wall. It is usually seen in young, heavy smokers, and can present with digital ischemia and ulceration, extremity claudication, Raynaud phenomenon, and superficial thrombophlebitis.

References

- Thromboangiitis obliterans (Buerger's disease).
- Thromboangitis obliterans in the 21st century—a new face of disease.

Pathology	Cardiovascular System	Peripheral vascular disease
Subject	System	Topic

1
2
3
4
5
6
7
8
9
10
11
12
13
14
15
16
17
18
19
20
21
22
23

A 53-year-old woman comes to the office due to aching pain in her legs. She is a hair stylist and has cut down on her work hours due to the discomfort. The patient has a history of migraine and untreated chronic hepatitis C. She smokes a pack of cigarettes daily but does not use alcohol or illicit drugs. Physical examination findings are shown in the image below.

1
2
3
4
5
6
7
8
9
10
11
12
13
14
15
16
17
18
19
20
21
22
23

An abnormality of which of the following is the most likely cause of this patient's symptoms?

A. Arterial intima
B. Capillary permeability
C. Lymphoid capillaries
D. Plasma oncotic pressure
E. Vasa vasorum
F. Venous valves

Submit

An abnormality of which of the following is the most likely cause of this patient's symptoms?

- A. Arterial intima (1%)
- B. Capillary permeability (0%)
- C. Lymphoid capillaries (0%)
- D. Plasma oncotic pressure (4%)
- E. Vasa vasorum (1%)
- ✓ F. Venous valves (90%)

Omitted
Correct answer

90%
Answered correctly

07 secs
Time Spent

06/06/2020
Last Updated

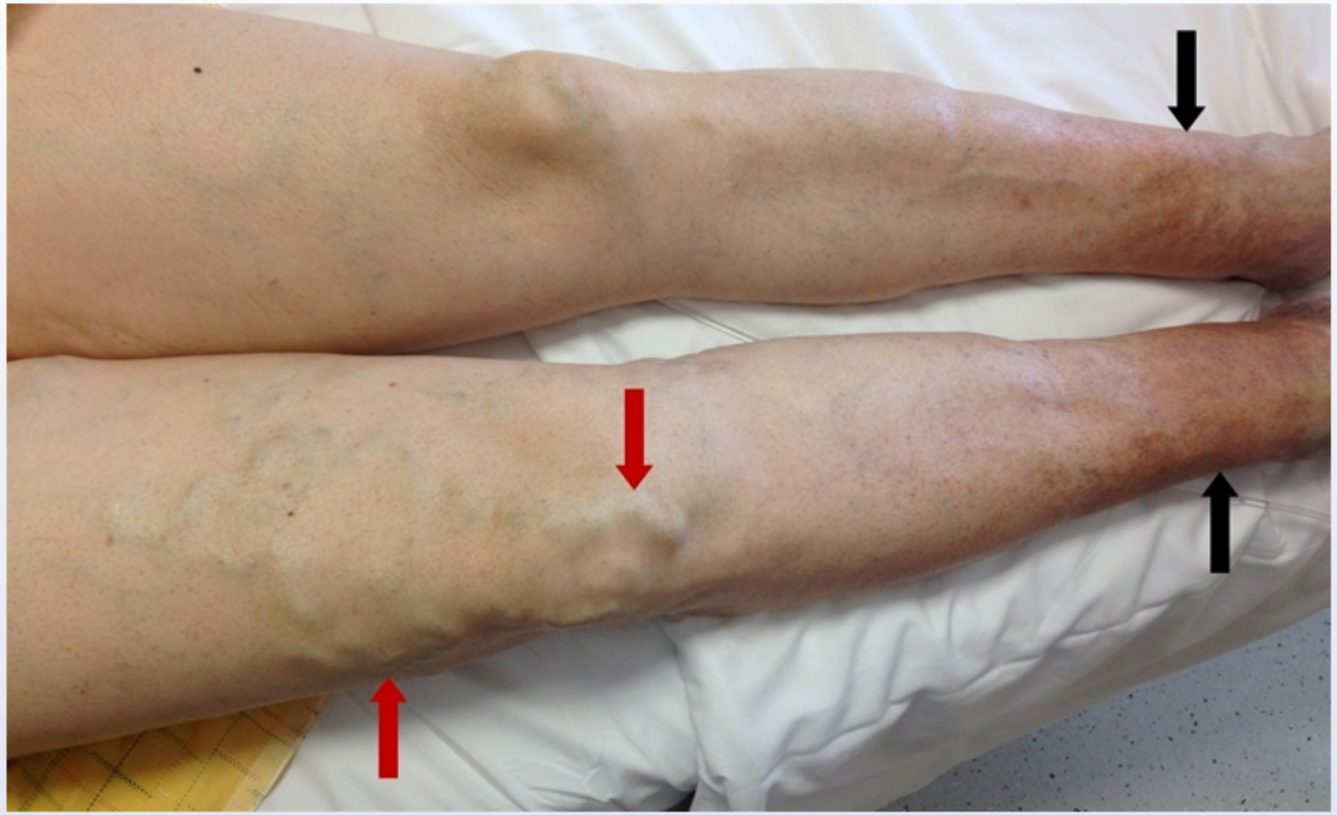

Venous blood normally flows from superficial veins through perforating veins into the deep veins of the extremities. Blood from the deep veins then travels upward and eventually drains into the inferior vena cava. Valves located in the superficial, perforating, and deep veins prevent backward flow from deep to superficial veins. Chronically elevated intraluminal pressure can lead to dilation of the veins (varicose veins) and **incompetence of the valves**. This allows retrograde flow into superficial veins and results in a further increase in venous pressure. The resulting tissue ischemia causes **venous stasis dermatitis** and is associated with poor wound healing. Extravasation of red blood cells into the tissues leads to iron deposition and the characteristic brawny discoloration.

This patient has dilated superficial veins (red arrows) and associated skin changes consistent with stasis dermatitis (black arrows). Common risk

Venous blood normally flows from superficial veins through perforating veins into the deep veins of the extremities. Blood from the deep veins then travels upward and eventually drains into the inferior vena cava. Valves located in the superficial, perforating, and deep veins prevent backward flow from deep to superficial veins. Chronically elevated intraluminal pressure can lead to dilation of the veins (varicose veins) and **incompetence of the valves**. This allows retrograde flow into superficial veins and results in a further increase in venous pressure. The resulting tissue ischemia causes **venous stasis dermatitis** and is associated with poor wound healing. Extravasation of red blood cells into the tissues leads to iron deposition and the characteristic brawny discoloration.

This patient has dilated superficial veins (red arrows) and associated skin changes consistent with stasis dermatitis (black arrows). Common risk factors for varicose veins and stasis dermatitis include obstruction of venous return (eg, obesity, pregnancy) and conditions that damage the venous valves (eg, deep venous thrombosis). Prolonged standing and sedentary lifestyles are also associated with varicose veins.

(Choice A) Atherosclerotic changes of the arterial intima predispose to peripheral arterial disease. Arterial occlusive disease of the lower extremities presents with leg pain during exercise (claudication) and, if severe, ischemic pain at rest and possible distal gangrene.

(Choice B) Increased capillary permeability is associated with anaphylaxis and other allergic reactions, inflammation, and shock. Increased capillary permeability causes edema due to the extravasation of serum contents into the interstitium. Capillary permeability does not play a role in the development of varicose veins.

(Choice C) Obstruction of lymphoid capillaries produces lymphedema, with marked swelling of the dorsum of the distal limb that may extend proximally. It is initially soft and pitting but eventually becomes firm and nonpitting due to progressive fibrosis and thickening of the overlying skin.

(Choice D) Decreased plasma oncotic pressure results primarily from low plasma protein content, as may be seen in malnutrition, nephrotic syndrome, cirrhosis/liver failure, or protein-losing enteropathy; it results in generalized edema. Cirrhosis with portal hypertension can cause esophageal and anorectal varices as collateral channels from the portal to systemic circulation. However, lower extremity veins do not communicate with the portal circulation.

(Choice E) Narrowing of the arterioles of the vasa vasorum in chronic hypertension can lead to medial ischemia of the aorta and contribute to aneurysm formation.

tissue ischemia causes **venous stasis dermatitis** and is associated with poor wound healing. Extravasation of red blood cells into the tissues leads to iron deposition and the characteristic brawny discoloration.

This patient has dilated superficial veins (red arrows) and associated skin changes consistent with stasis dermatitis (black arrows). Common risk factors for varicose veins and stasis dermatitis include obstruction of venous return (eg, obesity, pregnancy) and conditions that damage the venous valves (eg, deep venous thrombosis). Prolonged standing and sedentary lifestyles are also associated with varicose veins.

(Choice A) Atherosclerotic changes of the arterial intima predispose to peripheral arterial disease. Arterial occlusive disease of the lower extremities presents with leg pain during exercise (claudication) and, if severe, ischemic pain at rest and possible distal gangrene.

(Choice B) Increased capillary permeability is associated with anaphylaxis and other allergic reactions, inflammation, and shock. Increased capillary permeability causes edema due to the extravasation of serum contents into the interstitium. Capillary permeability does not play a role in the development of varicose veins.

(Choice C) Obstruction of lymphoid capillaries produces lymphedema, with marked swelling of the dorsum of the distal limb that may extend proximally. It is initially soft and pitting but eventually becomes firm and nonpitting due to progressive fibrosis and thickening of the overlying skin.

(Choice D) Decreased plasma oncotic pressure results primarily from low plasma protein content, as may be seen in malnutrition, nephrotic syndrome, cirrhosis/liver failure, or protein-losing enteropathy; it results in generalized edema. Cirrhosis with portal hypertension can cause esophageal and anorectal varices as collateral channels from the portal to systemic circulation. However, lower extremity veins do not communicate with the portal circulation.

(Choice E) Narrowing of the arterioles of the vasa vasorum in chronic hypertension can lead to medial ischemia of the aorta and contribute to aneurysm formation.

Educational objective:
Chronically elevated venous pressure in the lower extremities can lead to incompetent venous valves and venous dilation (varicose veins). Venous congestion and tissue ischemia can result in venous stasis dermatitis.

Pathology	Cardiovascular System	Chronic venous insufficiency
Subject	System	Topic

Copyright © UWorld. All rights reserved.

1
2
3
4
5
6
7
8
9
10
11
12
13
14
15
16
17
18
19
20
21
22
23

tissue ischemia causes **venous stasis dermatitis** and is associated with poor wound healing. Extravasation of red blood cells into the tissues

Exhibit Display

Zoom In | Zoom Out | Reset | Add To New Card | Existing Card

Copyright © UWorld. All rights reserved.

1
2
3
4
5
6
7
8
9
10
11
12
13
14
15
16
17
18
19
20
21
22
23

A 20-year-old student collapses suddenly in class and dies, despite resuscitation efforts. Review of the medical chart is conducted—including symptoms, review of systems, medical history, and substance use—and is unremarkable except for a family history of sudden cardiac death. Autopsy is performed and myocardial histology is shown in the image. Complete genotyping is most likely to reveal a pathologic mutation that affects a protein belonging to which of the following structures?

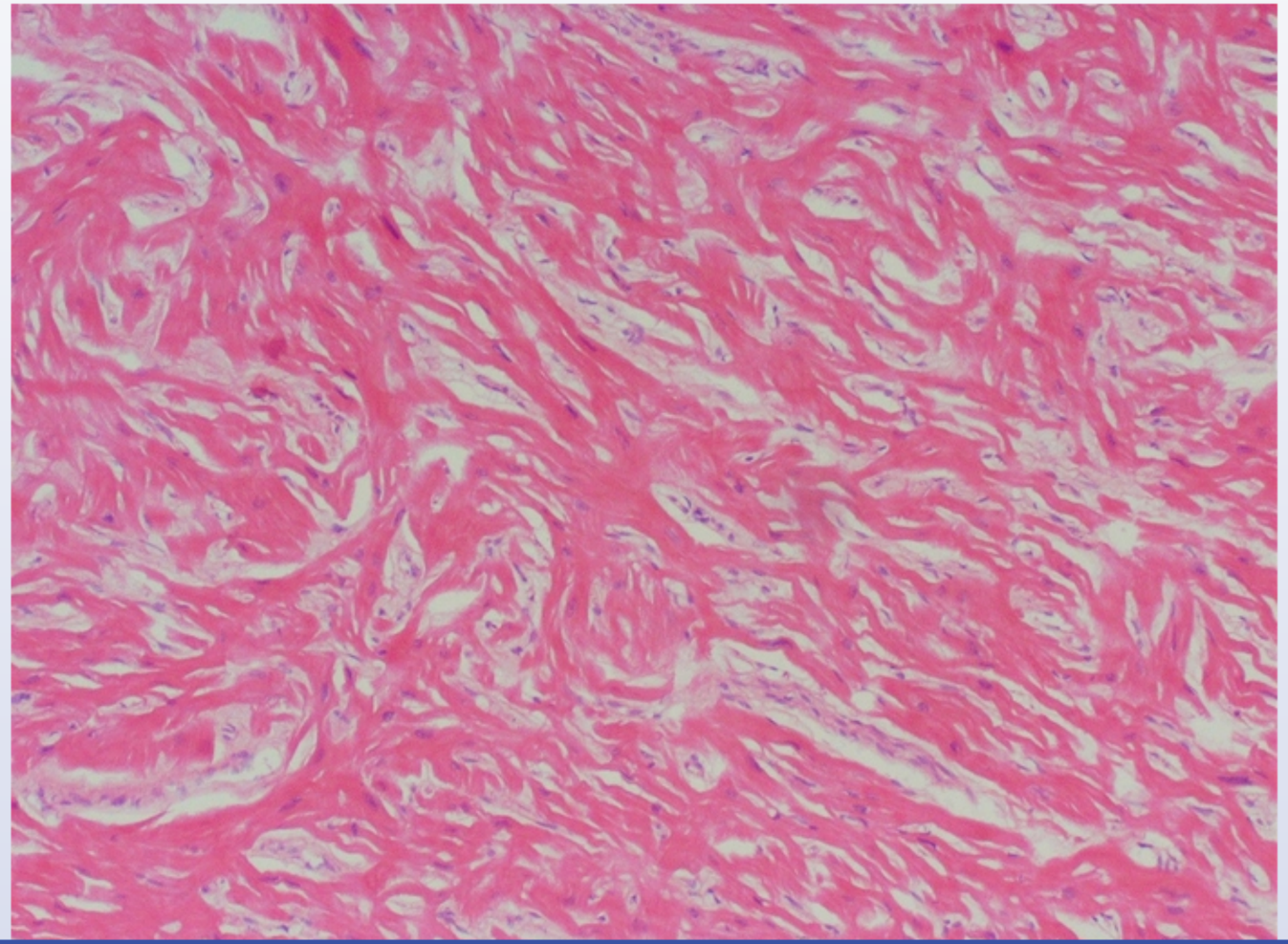

1
2
3
4
5
6
7
8
9
10
11
12
13
14
15
16
17
18
19
20
21
22
23

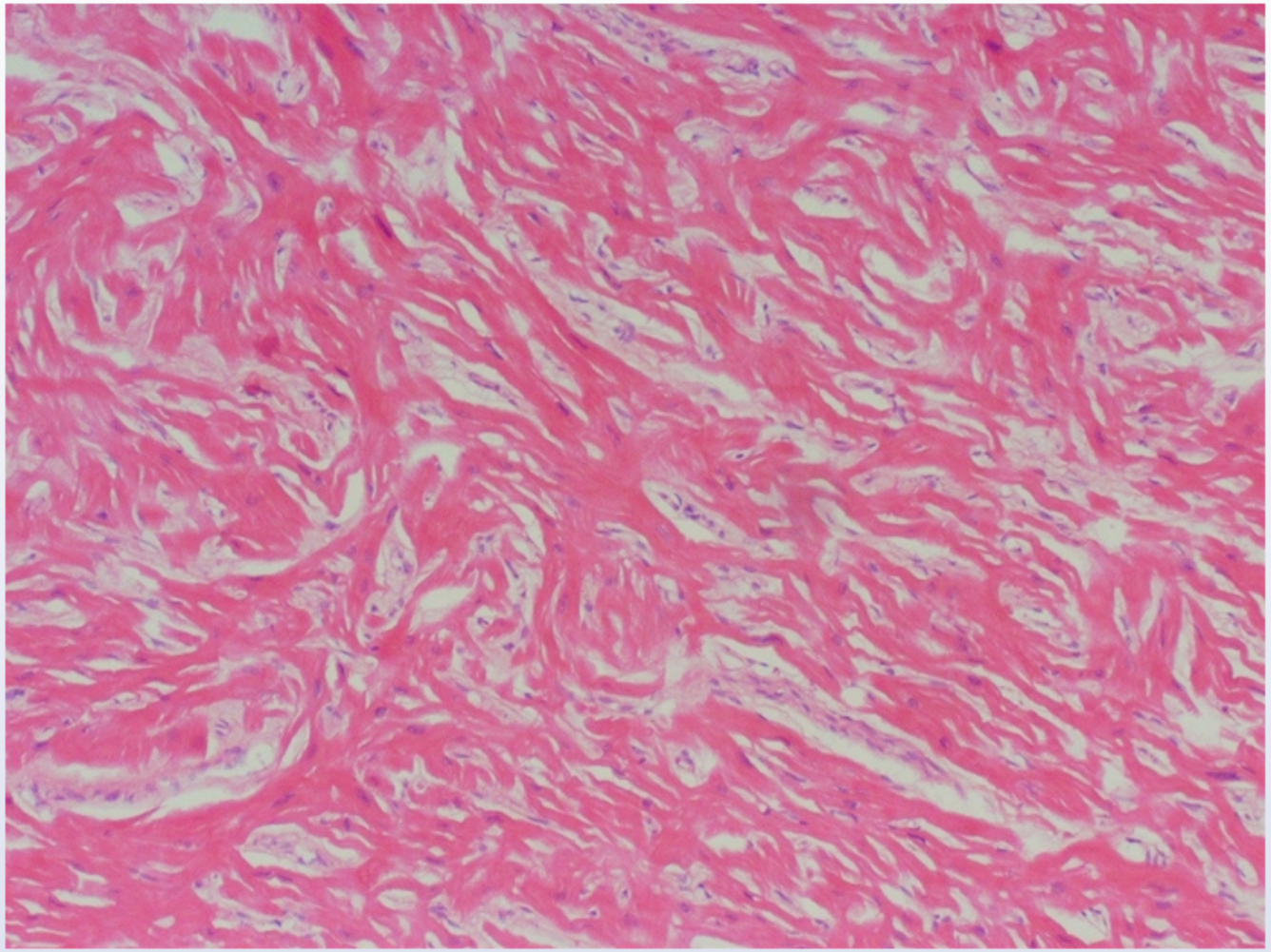

A. Cell junction complex

B. Ion channel

C. Mitochondria

1
2
3
4
5
6
7
8
9
10
11
12
13
14
15
16
17
18
19
20
21
22
23

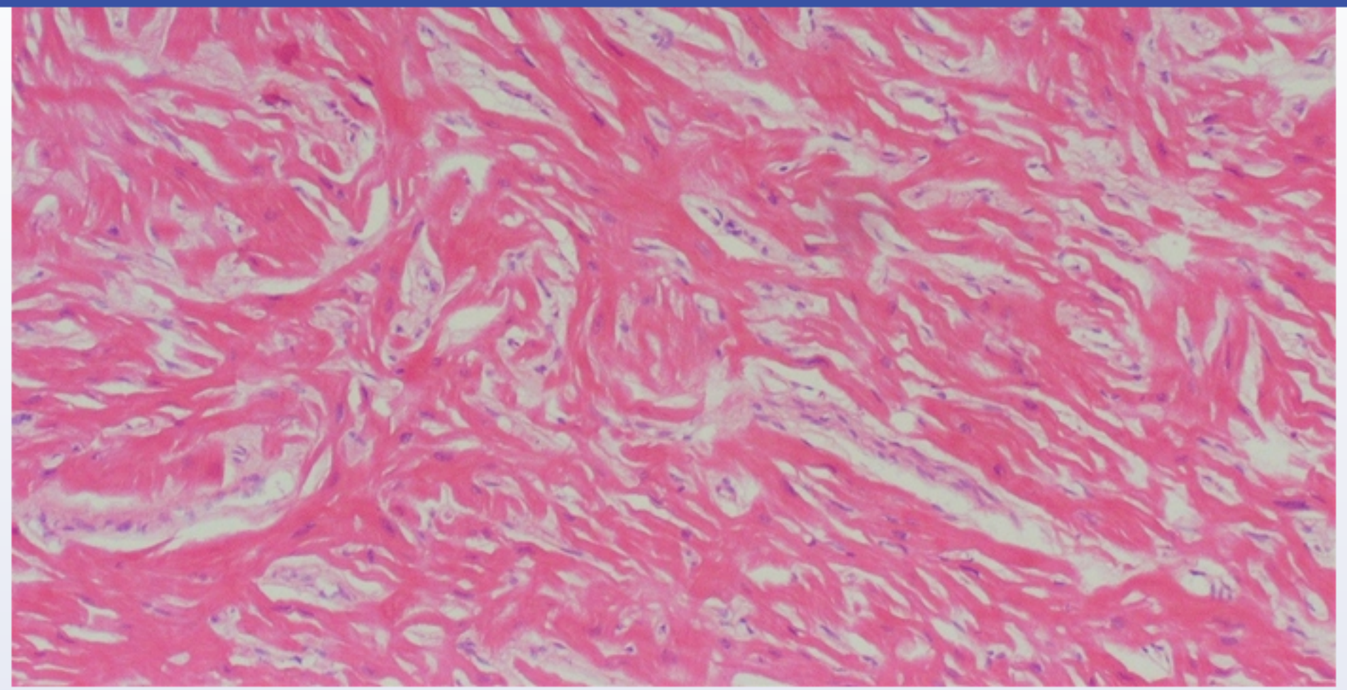

A. Cell junction complex

B. Ion channel

C. Mitochondria

D. Nuclear envelope

E. Sarcomere

Submit

1
2
3
4
5
6
7
8
9
10
11
12
13
14
15
16
17
18
19
20
21
22
23

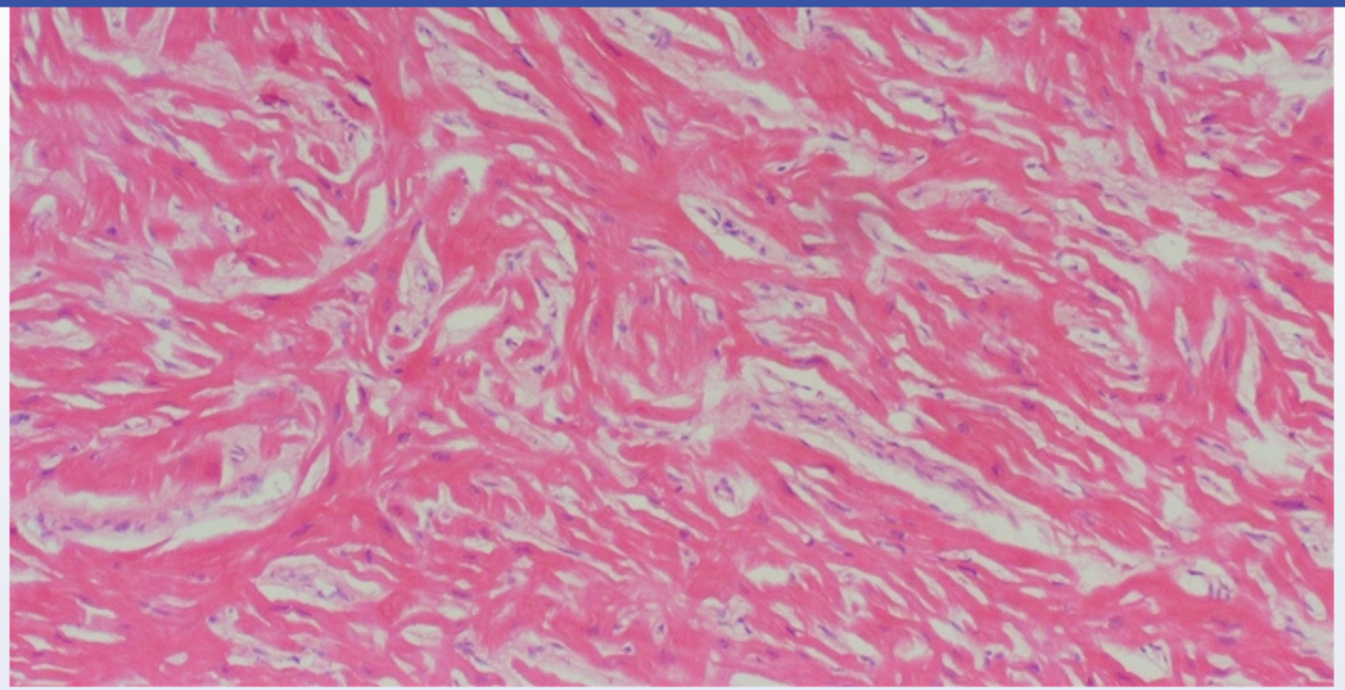

A. Cell junction complex (6%)

B. Ion channel (4%)

C. Mitochondria (3%)

D. Nuclear envelope (0%)

✓ E. Sarcomere (85%)

Omitted
Correct answer

85%
Answered correctly

07 secs
Time Spent

01/05/2020
Last Updated

Histologic examination of this patient's myocardium shows **cardiomyocyte hypertrophy** with **haphazard cellular arrangement** and prominent interstitial spacing with fibrosis; these findings are consistent with **hypertrophic cardiomyopathy** (HCM). HCM is caused by genetic mutations affecting structural proteins of the **cardiac sarcomere**, most commonly beta-myosin heavy chain and myosin-binding protein C. Approximately 50% of cases result from recognized familial mutations with autosomal dominant inheritance and variable expression.

HCM is one of the most common causes of **sudden cardiac death** (SCD) in young adults. Although SCD due to HCM often occurs with exertion, it can occur at rest. It is believed that cardiomyocyte disarray and fibrosis alters the spatial relationship of intercalated discs (the primary mediators of organized cardiac conduction), increasing susceptibility to **ventricular arrhythmia** (eg, ventricular tachycardia, ventricular fibrillation). Chronic myocardial ischemia, which can occur due to insufficient blood supply to hypertrophied myocardium, also contributes to interstitial fibrosis and the risk of arrhythmia.

(Choice A) Arrhythmogenic right ventricular cardiomyopathy results from mutations affecting proteins that make up desmosomes (eg, plakoglobin, desmoplakin). There is fibrosis and scarring of the right ventricle that predisposes to ventricular arrhythmias and SCD; however, histology does not demonstrate the cardiomyocyte hypertrophy or marked cellular disarray seen in HCM.

(Choice B) Long QT syndrome and Brugada syndrome result from mutations affecting cardiac ion channels. Both disorders can lead to ventricular arrhythmias and SCD; however, they do not involve structural derangement of the myocardium.

(Choices C and D) Mutations affecting mitochondria typically interfere with energy production via aerobic metabolism and a number of such diseases (eg, myoclonic epilepsy with ragged red fibers, Barth syndrome) can lead to dilated cardiomyopathy and SCD. Mutations affecting components of the nuclear envelope (eg, lamin A) are also a potential cause of dilated cardiomyopathy complicated by conduction defects and SCD. However, these cardiomyopathies are far less prevalent and do not involve the same structural derangement seen in HCM.

Educational objective:
Hypertrophic cardiomyopathy is caused by genetic mutations affecting structural proteins of the cardiac sarcomere (eg, beta-myosin heavy chain, myosin-binding protein C) and is one of the most common causes of sudden cardiac death (SCD) in young adults. Histologically, it is characterized by cardiomyocyte hypertrophy with haphazard cellular arrangement and interstitial fibrosis.

References

- Sudden cardiac death in hypertrophic cardiomyopathy.

1
2
3
4
5
6
7
8
9
10
11
12
13
14
15
16
17
18
19
20
21
22
23

Exhibit Display

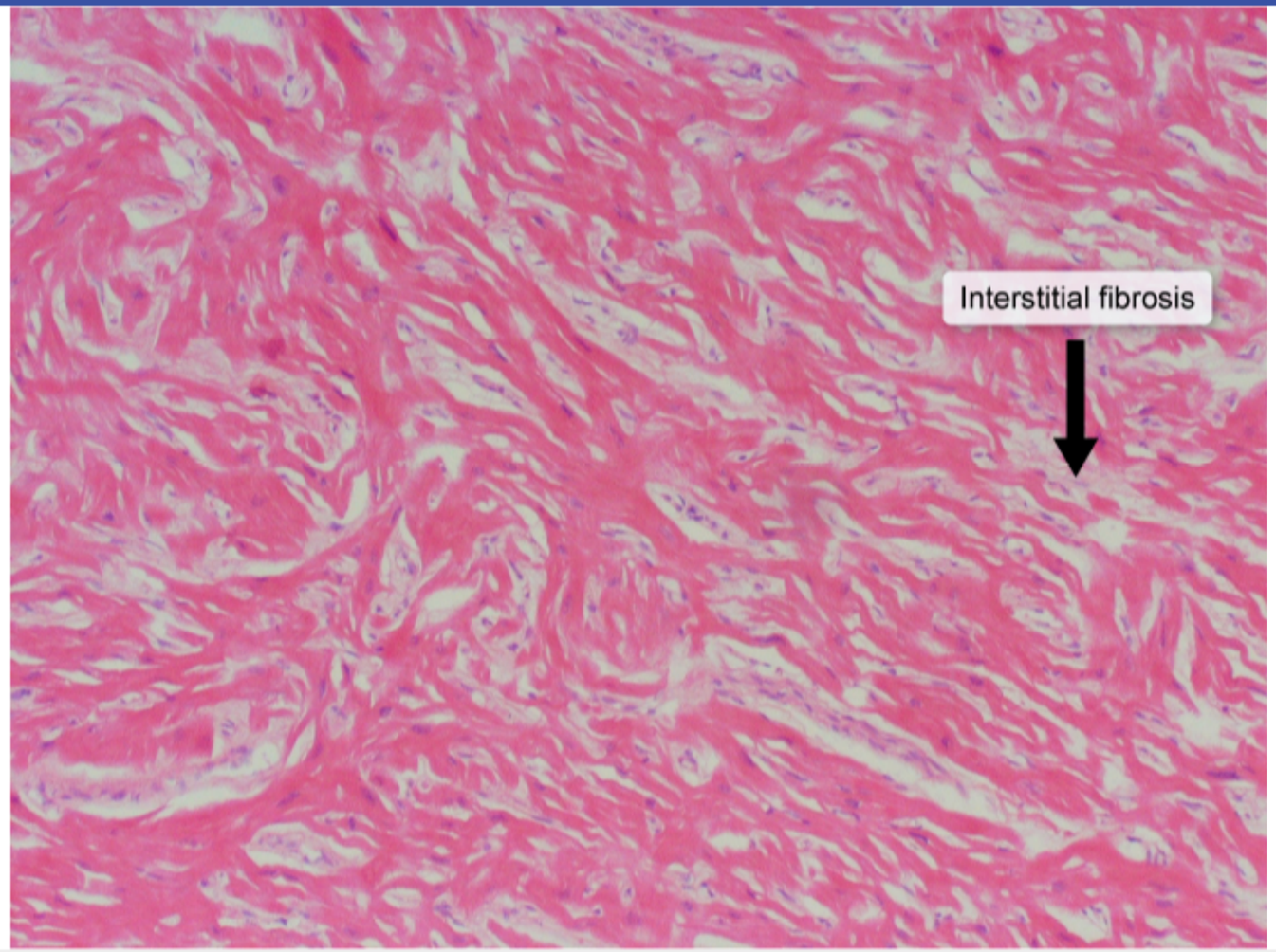

Zoom In Zoom Out Reset Add To New Card | Existing Card

1
2
3
4
5
6
7
8
9
10
11
12
13
14
15
16
17
18
19
20
21
22
23

Exhibit Display

Cardiac sarcomere protein structure

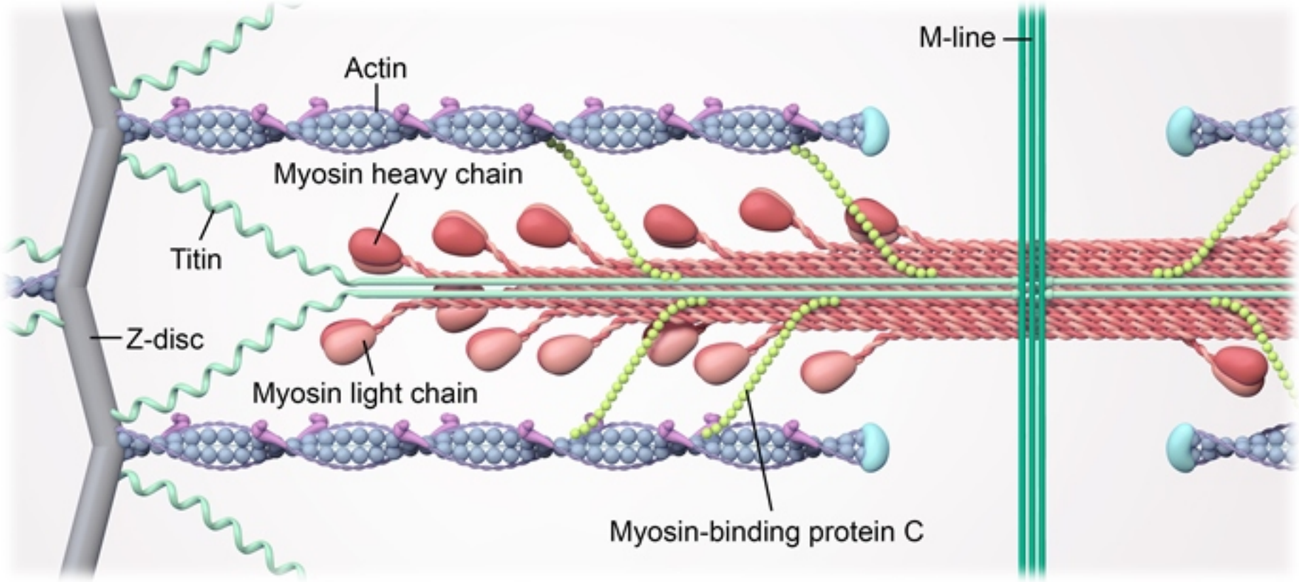

©UWorld

A 64-year-old man dies suddenly while playing tennis. In the preceding months, he experienced fatigue and some exertional dyspnea. Autopsy is performed. The heart examination shows left ventricular septal thickness of 1.6 cm (normal: <1.1), posterior wall thickness of 1.6 cm (normal: <1.1), and an internal left ventricular diameter of 3.2 cm (normal: 3.5-5.9). No focal myocardial scarring is seen. Which of the following is the most likely cause of the cardiac findings seen in this individual?

A. Aortic stenosis
B. Dilated cardiomyopathy
C. Mitral regurgitation
D. Obstructive coronary artery disease
E. Rheumatic mitral stenosis

Submit

A 64-year-old man dies suddenly while playing tennis. In the preceding months, he experienced fatigue and some exertional dyspnea. Autopsy is performed. The heart examination shows left ventricular septal thickness of 1.6 cm (normal: <1.1), posterior wall thickness of 1.6 cm (normal: <1.1), and an internal left ventricular diameter of 3.2 cm (normal: 3.5-5.9). No focal myocardial scarring is seen. Which of the following is the most likely cause of the cardiac findings seen in this individual?

- ✓ A. Aortic stenosis (87%)
- B. Dilated cardiomyopathy (4%)
- C. Mitral regurgitation (3%)
- D. Obstructive coronary artery disease (3%)
- E. Rheumatic mitral stenosis (0%)

Omitted
Correct answer
A

87%
Answered correctly

02 secs
Time Spent

05/09/2020
Last Updated

Explanation

1
2
3
4
5
6
7
8
9
10
11
12
13
14
15
16
17
18
19
20
21
22
23

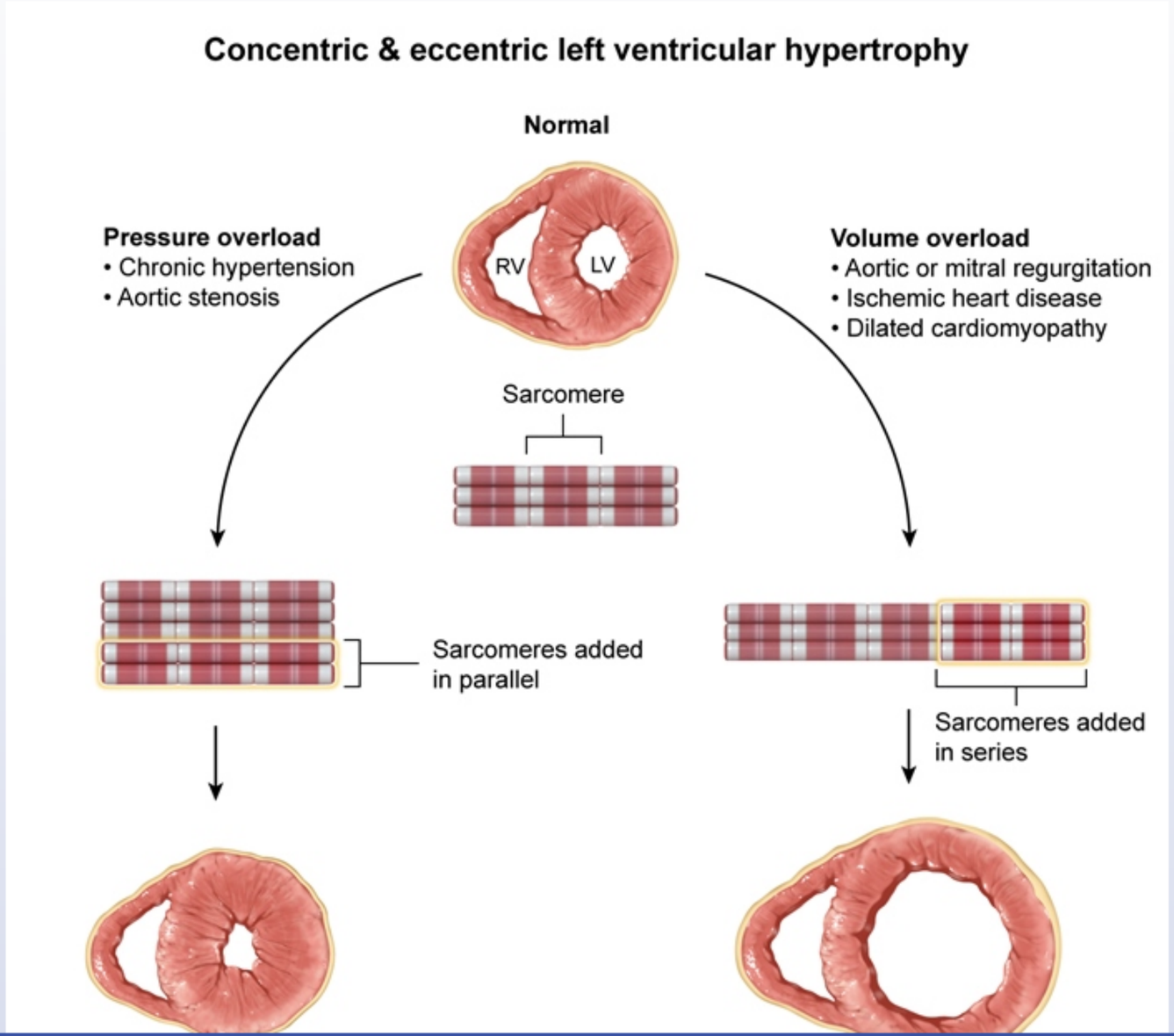

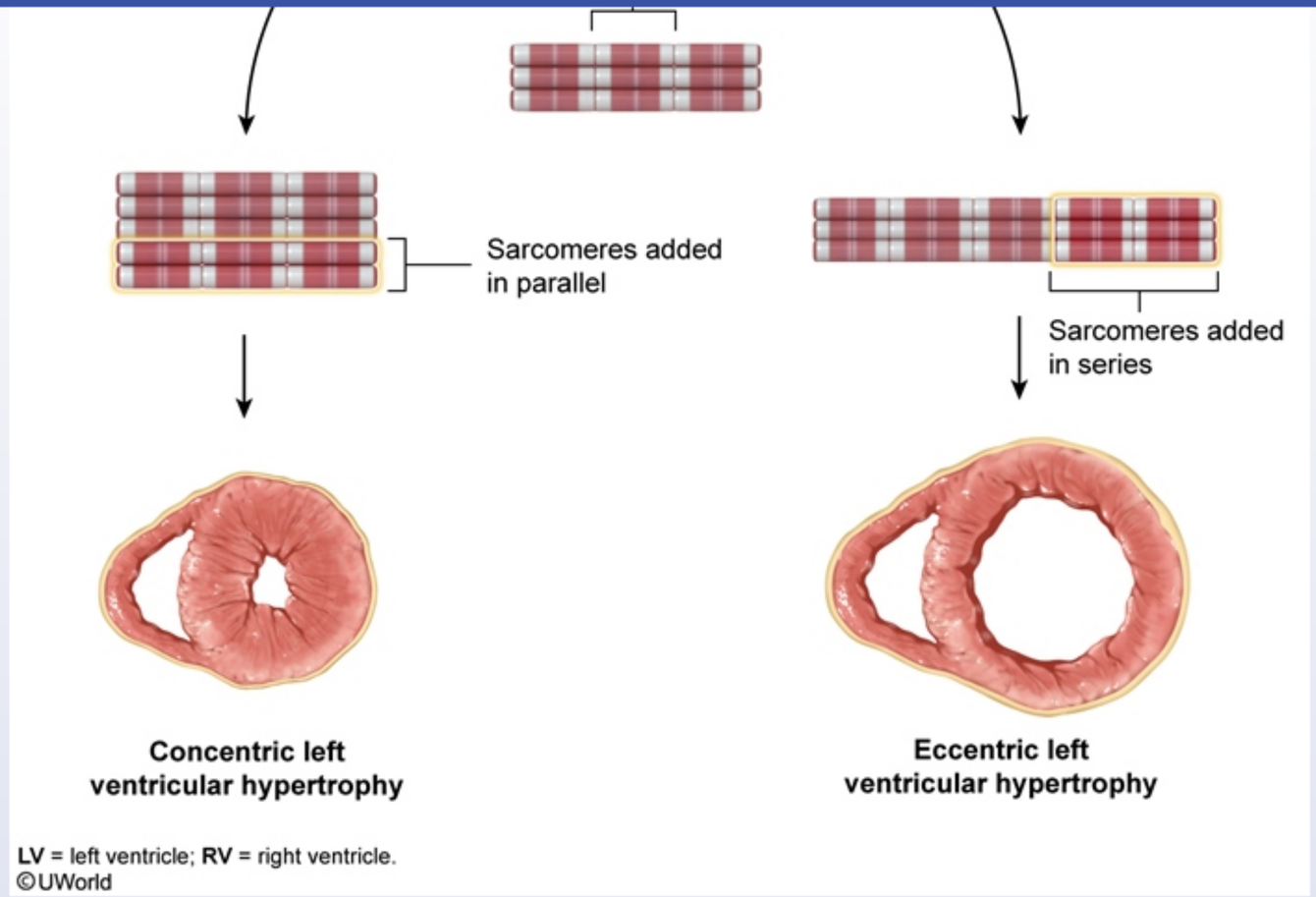

LV = left ventricle; RV = right ventricle.
©UWorld

This individual's autopsy reveals **thickened left ventricular walls** and a small left ventricular cavity consistent with **concentric hypertrophy**. Concentric hypertrophy results from the addition of myocardial contractile fibers in parallel in response to chronic **pressure overload**. The adaptation allows for increased contractile force but causes impaired diastolic filling and can lead to heart failure with preserved ejection fraction (diastolic failure). Common causes of concentric hypertrophy include prolonged systemic hypertension and **aortic stenosis**.

Patients with severe aortic stenosis typically experience exertional symptoms, including fatigue, shortness of breath, angina, and presyncope or syncope. **Sudden cardiac death** can result from the inability to increase cardiac output with exertion due to left ventricular outflow obstruction.

LV = left ventricle; RV = right ventricle.
©UWorld

This individual's autopsy reveals **thickened left ventricular walls** and a small left ventricular cavity consistent with **concentric hypertrophy**. Concentric hypertrophy results from the addition of myocardial contractile fibers in parallel in response to chronic **pressure overload**. The adaptation allows for increased contractile force but causes impaired diastolic filling and can lead to heart failure with preserved ejection fraction (diastolic failure). Common causes of concentric hypertrophy include prolonged systemic hypertension and **aortic stenosis**.

Patients with severe aortic stenosis typically experience exertional symptoms, including fatigue, shortness of breath, angina, and presyncope or syncope. **Sudden cardiac death** can result from the inability to increase cardiac output with exertion due to left ventricular outflow obstruction.

(Choice B) Dilated cardiomyopathy results from a primary insult to cardiomyocytes (eg, viral infection, chemical toxicity, inherited disease) that causes myocardial contractile dysfunction, left ventricular volume overload, and eventual eccentric hypertrophy.

(Choice C) Severe mitral regurgitation causes left ventricular volume overload and eccentric hypertrophy.

(Choice D) Obstructive coronary artery disease can lead to eccentric hypertrophy via myocardial contractile dysfunction and consequent left ventricular volume overload (ie, ischemic heart disease). The development of concentric hypertrophy is not typical.

(Choice E) Rheumatic mitral stenosis causes impaired diastolic filling of the left ventricle. It does not increase the pressure or volume load on the left ventricle and does not cause ventricular hypertrophy.

Educational objective:
Concentric left ventricular hypertrophy involves thickening of the ventricular walls and reduction in the ventricular cavity size. It occurs via the addition of myocardial contractile fibers in parallel in response to chronic pressure overload. Aortic stenosis and prolonged systemic hypertension are common causes of concentric left ventricular hypertrophy.

Pathology	Cardiovascular System	Aortic stenosis
Subject	System	Topic

Copyright © UWorld. All rights reserved.

A 36-year-old man comes to the emergency department after briefly losing consciousness while watching television half an hour ago. The patient had no preceding chest pain or shortness of breath, but he has been having recurrent palpitations over the past several days. Two weeks ago, he noticed a non-itchy rash on his thigh that he treated with an over-the-counter steroid cream. Medical history is otherwise unremarkable. There is no family history of heart disease or sudden cardiac death. The patient recently began working as a forest ranger in Pennsylvania. He does not use tobacco, alcohol, or illicit drugs. Blood pressure is 130/80 mm Hg and pulse is 46/min. The lungs are clear on auscultation and heart sounds are normal. The remainder of the examination shows no abnormalities. ECG reveals sinus rhythm with complete atrioventricular block. Echocardiography shows normal ventricular function with no major valvular disease. Which of the following is the most likely underlying cause of this patient's current condition?

- A. Disseminated spirochetal infection
- B. Granulomatous myocardial inflammation
- C. Missense mutation of a sarcomere protein
- D. Myocyte potassium channel mutation
- E. Viral infection–induced cardiac injury

Submit

A 36-year-old man comes to the emergency department after briefly losing consciousness while watching television half an hour ago. The patient had no preceding chest pain or shortness of breath, but he has been having recurrent palpitations over the past several days. Two weeks ago, he noticed a non-itchy rash on his thigh that he treated with an over-the-counter steroid cream. Medical history is otherwise unremarkable. There is no family history of heart disease or sudden cardiac death. The patient recently began working as a forest ranger in Pennsylvania. He does not use tobacco, alcohol, or illicit drugs. Blood pressure is 130/80 mm Hg and pulse is 46/min. The lungs are clear on auscultation and heart sounds are normal. The remainder of the examination shows no abnormalities. ECG reveals sinus rhythm with complete atrioventricular block. Echocardiography shows normal ventricular function with no major valvular disease. Which of the following is the most likely underlying cause of this patient's current condition?

- ✓ A. Disseminated spirochetal infection (84%)
- B. Granulomatous myocardial inflammation (4%)
- C. Missense mutation of a sarcomere protein (0%)
- D. Myocyte potassium channel mutation (2%)
- E. Viral infection–induced cardiac injury (7%)

Omitted
Correct answer
A

84%
Answered correctly

04 secs
Time Spent

03/16/2020
Last Updated

Explanation

This patient most likely has **early disseminated Lyme disease**. Lyme disease is caused by the bacterial spirochete *Borrelia burgdorferi*, which is transmitted by the *Ixodes* tick that is endemic to the northeastern and parts of the midwestern United States. Most cases initially present with a

This patient most likely has **early disseminated Lyme disease**. Lyme disease is caused by the bacterial spirochete *Borrelia burgdorferi*, which is transmitted by the *Ixodes* tick that is endemic to the northeastern and parts of the midwestern United States. Most cases initially present with a non-itchy, bull's-eye-shaped rash, known as erythema migrans, at the site of infection. Left untreated for several weeks or more, a small percentage of those infected will develop cardiac involvement **(Lyme carditis)**.

Lyme carditis most commonly manifests with varying degrees of **atrioventricular (AV) conduction block**. Many patients remain asymptomatic; however, patients who develop complete AV block are likely to have symptoms of dyspnea, **lightheadedness**, or **syncope**. Treatment for symptomatic AV block due to Lyme carditis typically requires hospitalization with temporary pacing and the administration of intravenous antibiotics (ceftriaxone is the drug of choice).

(Choice B) Granulomatous myocardial inflammation occurs in cardiac sarcoidosis, and AV conduction block is the most common disease manifestation. However, this patient's recent rash and residence in an endemic area make Lyme carditis more likely.

(Choice C) A missense mutation affecting the cardiac sarcomere protein beta-myosin heavy chain is a common cause of hypertrophic cardiomyopathy. Myocardial disarray creates a propensity for ventricular arrhythmias, but AV conduction block is not typical.

(Choice D) Congenital long QT syndrome results from a mutation affecting cardiomyocyte potassium channels. It can cause syncope or sudden cardiac death, typically via the triggering of torsades de pointes (polymorphic ventricular tachycardia). AV conduction block would be an unusual manifestation.

(Choice E) Viral infection of the heart typically manifests as myocarditis. The most common symptomatic presentation is decompensated heart failure due to dilated cardiomyopathy. AV conduction block is not typical.

Educational objective:
Early disseminated Lyme disease can have cardiac involvement (Lyme carditis) that most commonly manifests with varying degrees of atrioventricular (AV) conduction block. Patients may be asymptomatic, but those with complete AV conduction block are likely to have dyspnea, lightheadedness, or syncope.

Pathology	Cardiovascular System	Lyme disease
Subject	System	Topic

Exhibit Display

Lyme Disease: Endemic Areas in the United States

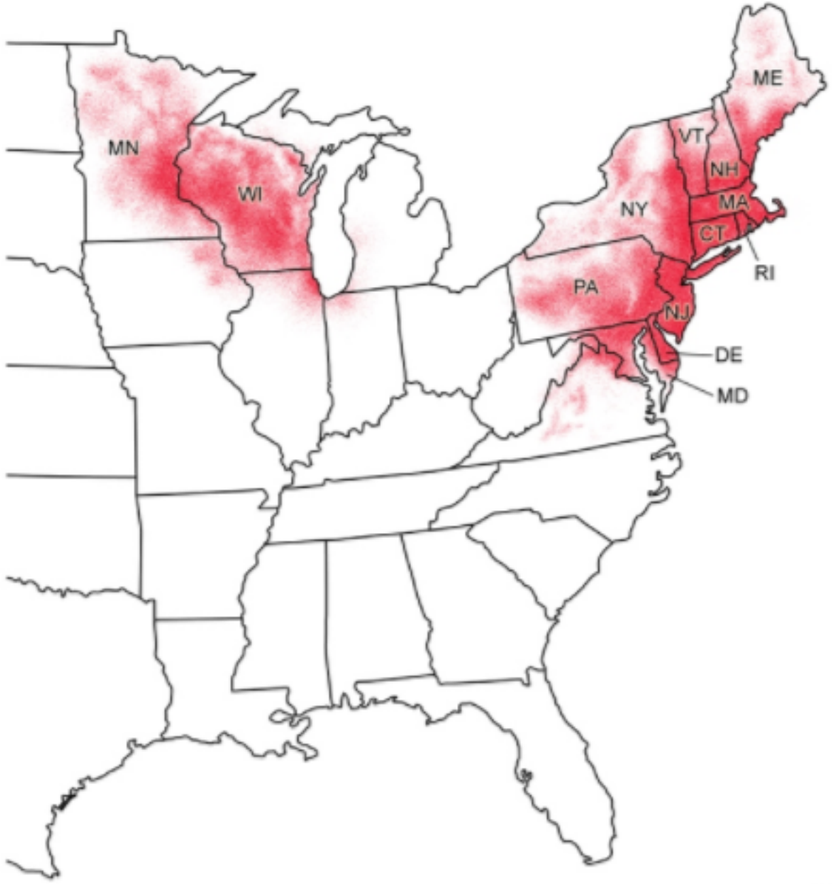

©UWorld

1
2
3
4
5
6
7
8
9
10
11
12
13
14
15
16
17
18
19
20
21
22
23

Exhibit Display

Zoom In
Zoom Out
Reset
Add To New Card | Existing Card

1
2
3
4
5
6
7
8
9
10
11
12
13
14
15
16
17
18
19
20
21
22
23

Exhibit Display

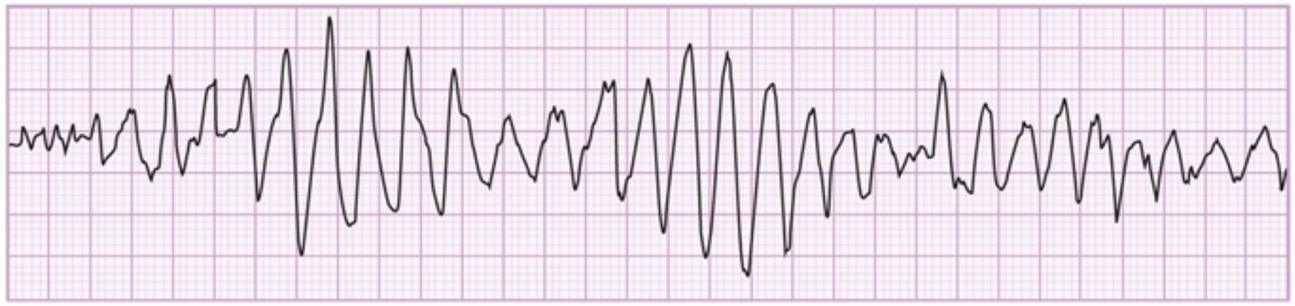

©UWorld

Zoom In | Zoom Out | Reset | Add To New Card | Existing Card

1
2
3
4
5
6
7
8
9
10
11
12
13
14
15
16
17
18
19
20
21
22
23

A newborn has a small, bright red, slightly elevated lesion over the buttocks.

You inform the parents that the lesion is a benign vascular tumor that over time will most likely:

- A. Progressively increase in size
- B. First increase in size and then regress
- C. First regress and then increase in size
- D. Progressively regress
- E. Stay stable with little growth or regression

You inform the parents that the lesion is a benign vascular tumor that over time will most likely:

- A. Progressively increase in size (2%)
- ✓ B. First increase in size and then regress (45%)
- C. First regress and then increase in size (1%)
- D. Progressively regress (42%)
- E. Stay stable with little growth or regression (7%)

Omitted
Correct answer

45%
Answered correctly

05 secs
Time Spent

02/03/2020
Last Updated

D. Progressively regress (42%)

E. Stay stable with little growth or regression (7%)

Omitted
Correct answer
B

45%
Answered correctly

05 secs
Time Spent

02/03/2020
Last Updated

Explanation

This child has a cutaneous, strawberry-type capillary hemangioma (juvenile hemangioma). These lesions consist of unencapsulated aggregates of closely packed, thin-walled capillaries. Strawberry hemangiomas are benign and quite common, occurring in 1/200 births. They may be multiple, and can be found in the skin, subcutaneous tissues, oral mucous membranes, or lips. Capillary hemangiomas may also occur in the liver, spleen, and kidneys. Like most hemangiomas, these are present at birth, and initially grow in proportion to the child. These lesions regress spontaneously at or before puberty. Typically, capillary hemangiomas begin to fade between the ages of 1 to 3 years. In 75-95% of cases, these hemangiomas will have regressed completely by age 7.

Educational Objective:
Cutaneous, strawberry-type capillary hemangiomas are common, benign, congenital tumors, which are composed of unencapsulated aggregates of closely packed, thin-walled capillaries. Initially, strawberry hemangiomas grow in proportion to the growth of the child, before eventually regressing. In 75-95% of cases, the vascular tumor will regress completely by age 7.

Pathology	Cardiovascular System	Hemangioma
Subject	System	Topic

Copyright © UWorld. All rights reserved.

A 64-year-old man has had difficulty walking for 6 months, experiencing muscle cramps in his right thigh after walking a block on level ground. The cramps subside quickly with rest. He has also had decreased sexual performance. Medical history is significant for hypercholesterolemia and myocardial infarction. The patient smokes a pack of cigarettes daily but does not use alcohol or illicit drugs. He is afebrile. Blood pressure is 128/78 mm Hg, pulse is 76/min, and respirations are 16/min. Cardiac auscultation reveals normal S1 and S2, and equal vesicular breath sounds are heard over the bilateral lungs. The abdomen is soft and without masses. There is no peripheral edema, muscle tenderness, or muscle weakness. Which of the following is the most likely cause of this patient's symptoms?

- A. Granulomatous inflammation of the arterial media
- B. Homogenous acellular thickening of the arteriolar walls
- C. Lipid-filled arterial intimal plaques
- D. Medial band–like arterial calcification
- E. Onion-like concentric thickening of the arteriolar walls

Submit

A 64-year-old man has had difficulty walking for 6 months, experiencing muscle cramps in his right thigh after walking a block on level ground. The cramps subside quickly with rest. He has also had decreased sexual performance. Medical history is significant for hypercholesterolemia and myocardial infarction. The patient smokes a pack of cigarettes daily but does not use alcohol or illicit drugs. He is afebrile. Blood pressure is 128/78 mm Hg, pulse is 76/min, and respirations are 16/min. Cardiac auscultation reveals normal S1 and S2, and equal vesicular breath sounds are heard over the bilateral lungs. The abdomen is soft and without masses. There is no peripheral edema, muscle tenderness, or muscle weakness. Which of the following is the most likely cause of this patient's symptoms?

- A. Granulomatous inflammation of the arterial media (5%)
- B. Homogenous acellular thickening of the arteriolar walls (5%)
- ✓ C. Lipid-filled arterial intimal plaques (74%)
- D. Medial band–like arterial calcification (6%)
- E. Onion-like concentric thickening of the arteriolar walls (7%)

Omitted
Correct answer
C

74%
Answered correctly

02 secs
Time Spent

01/26/2020
Last Updated

Explanation

This patient's muscle pain, which occurs with exercise and remits with rest, is consistent with **intermittent claudication**; smoking is an important risk factor. Claudication is usually due to atherosclerosis of the large arteries, specifically resulting from fixed stenoses caused by lipid-filled intimal plaques that bulge into the arterial lumen (**atheromas**). These stenoses prevent a sufficient increase in blood flow to muscles during exercise, leading to ischemic muscle pain. The pain is rapidly **relieved by rest**, as residual blood flow is adequate to meet the metabolic

The cramps subside quickly with rest. He has also had decreased sexual performance. Medical history is significant for hypercholesterolemia and myocardial infarction. The patient smokes a pack of cigarettes daily but does not use alcohol or illicit drugs. He is afebrile. Blood pressure is 128/78 mm Hg, pulse is 76/min, and respirations are 16/min. Cardiac auscultation reveals normal S1 and S2, and equal vesicular breath sounds are heard over the bilateral lungs. The abdomen is soft and without masses. There is no peripheral edema, muscle tenderness, or muscle weakness. Which of the following is the most likely cause of this patient's symptoms?

- A. Granulomatous inflammation of the arterial media (5%)
- B. Homogenous acellular thickening of the arteriolar walls (5%)
- ✓ C. Lipid-filled arterial intimal plaques (74%)
- D. Medial band–like arterial calcification (6%)
- E. Onion-like concentric thickening of the arteriolar walls (7%)

Omitted
Correct answer
C

74%
Answered correctly

02 secs
Time Spent

01/26/2020
Last Updated

Explanation

This patient's muscle pain, which occurs with exercise and remits with rest, is consistent with **intermittent claudication**; smoking is an important risk factor. Claudication is usually due to atherosclerosis of the large arteries, specifically resulting from fixed stenoses caused by lipid-filled intimal plaques that bulge into the arterial lumen (**atheromas**). These stenoses prevent a sufficient increase in blood flow to muscles during exercise, leading to ischemic muscle pain. The pain is rapidly **relieved by rest**, as residual blood flow is adequate to meet the metabolic demands of resting, but not exercising, muscle.

Thigh claudication is suggestive of occlusive disease of the ipsilateral **external iliac** artery or its more distal branches (ie, common femoral

D. Medial band–like arterial calcification (6%)

Exhibit Display

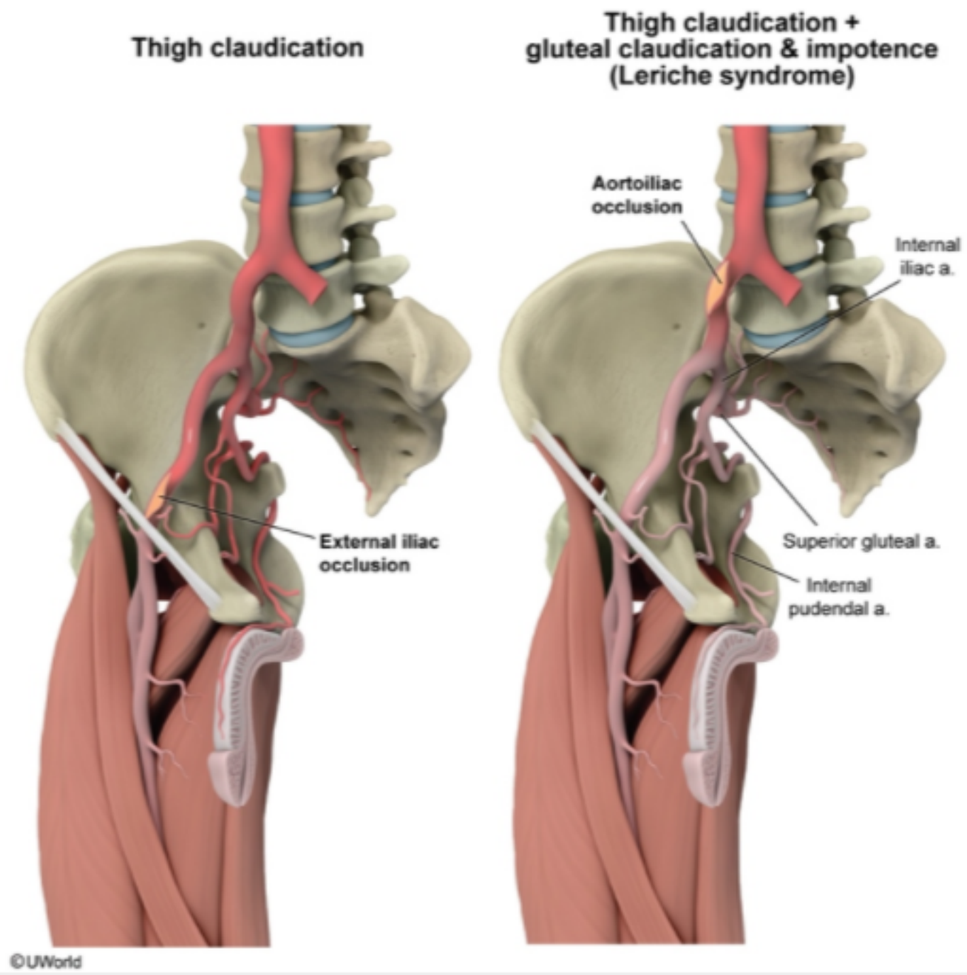

Zoom In | Zoom Out | Reset | Add To New Card | Existing Card

(Choice D) Medial band–like calcifications occur in medial calcific sclerosis (Mönckeberg arteriosclerosis). The condition is characterized by

1
2
3
4
5
6
7
8
9
10
11
12
13
14
15
16
17
18
19
20
21
22
23

risk factor. Claudication is usually due to atherosclerosis of the large arteries, specifically resulting from fixed stenoses caused by lipid-filled

Exhibit Display

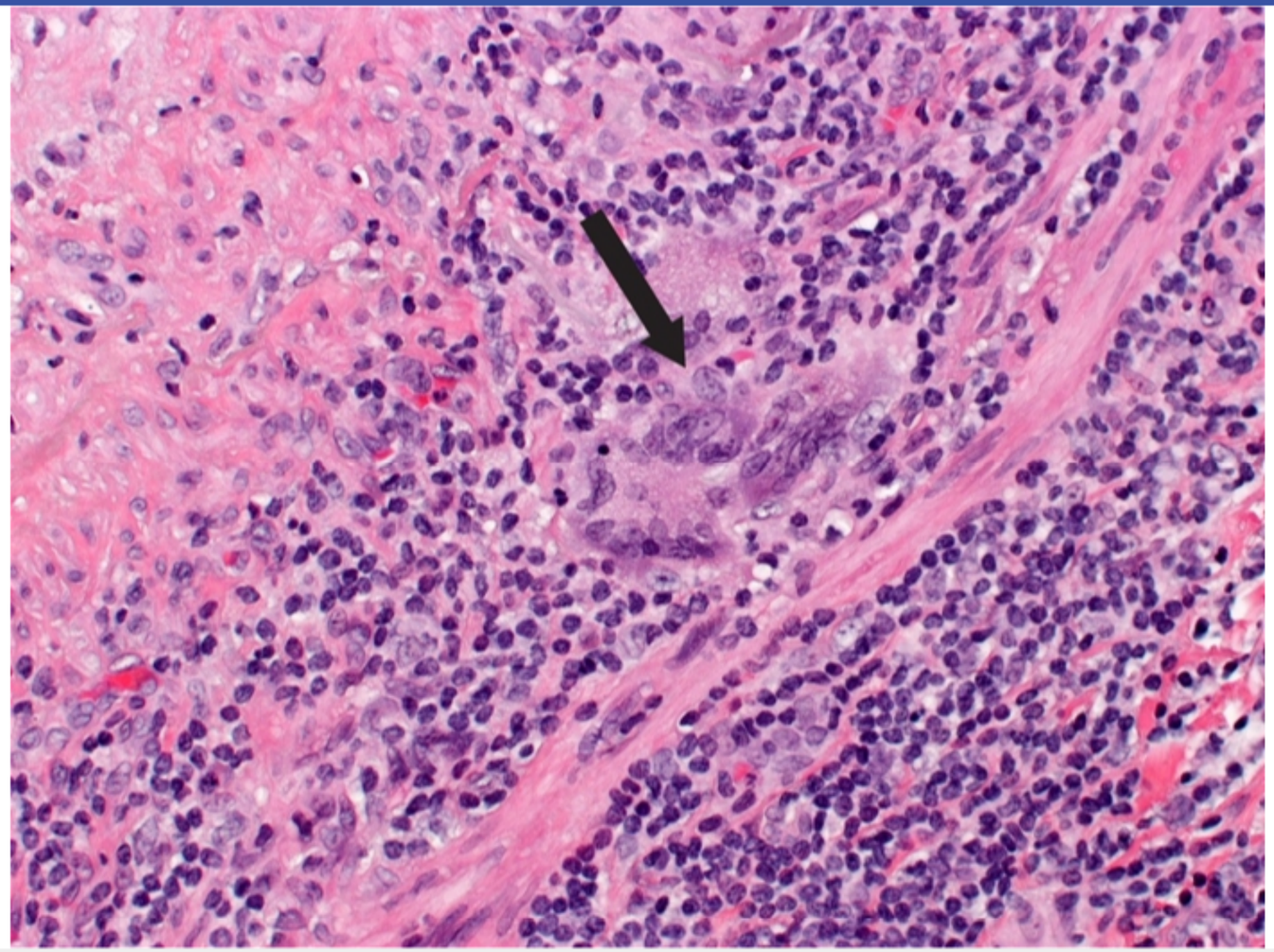

Zoom In | Zoom Out | Reset | Add To New Card | Existing Card

risk factor. Claudication is usually due to atherosclerosis of the large arteries, specifically resulting from fixed stenoses caused by lipid-filled

Exhibit Display

Zoom In Zoom Out Reset Add To New Card | Existing Card

risk factor. Claudication is usually due to atherosclerosis of the large arteries, specifically resulting from fixed stenoses caused by lipid-filled

Exhibit Display

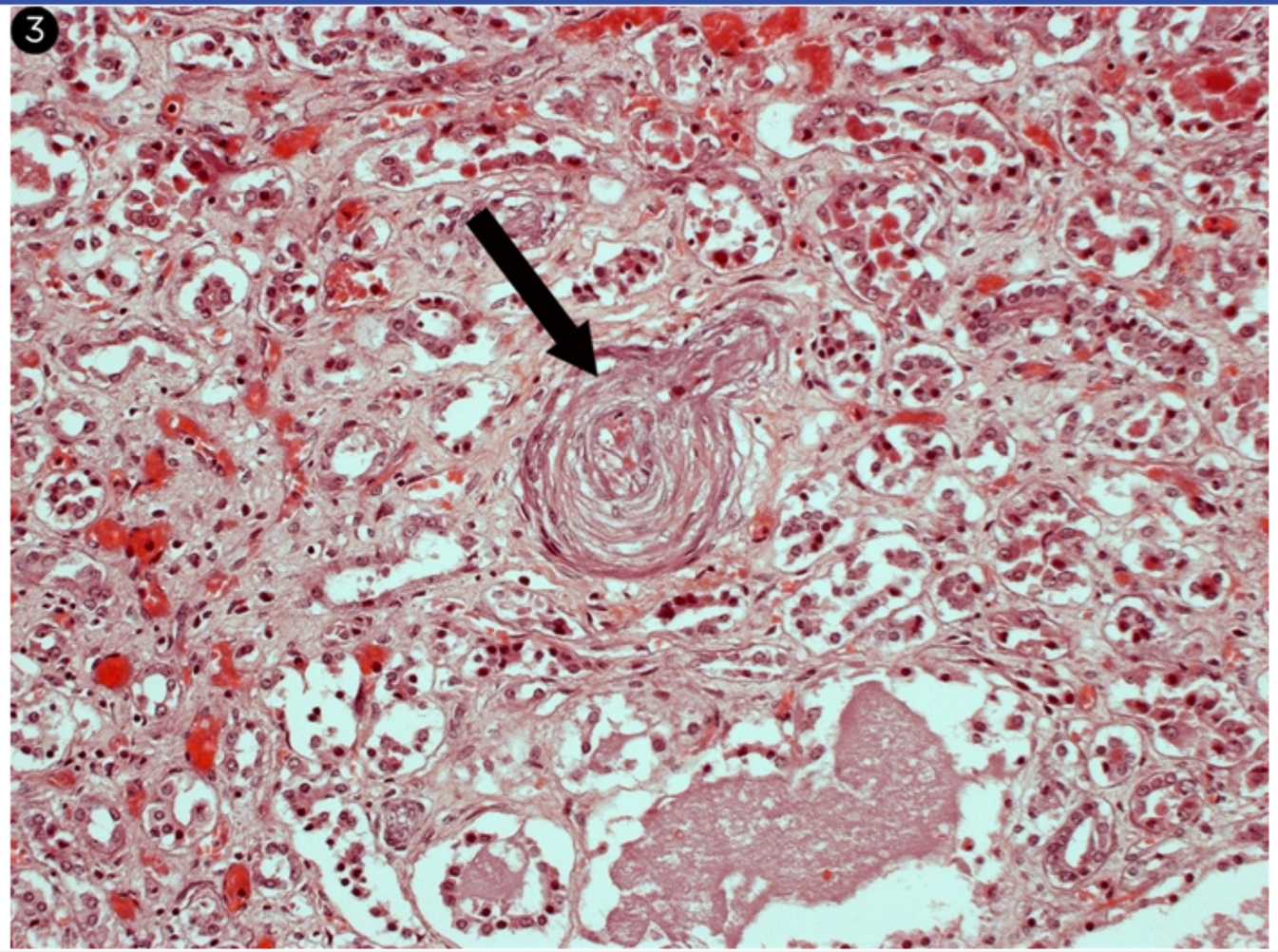

Zoom In Zoom Out Reset Add To New Card | Existing Card

A 30-year-old man is brought to the emergency department due to left-sided weakness. His left arm was sluggish after awakening, and he had difficulty walking to the bathroom. The patient has no known medical conditions but has a 2-month history of positional dyspnea. Vital signs are within normal limits. On examination, strength of the left upper and left lower extremity is reduced, and touch/temperature sensation is similarly diminished. Cardiovascular examination reveals an intermittent murmur at the apex without carotid bruits. Echocardiography shows a mobile, 3-cm left atrial mass obstructing the mitral opening during diastole. Histologic examination of this mass would most likely show which of the following findings?

A. Amorphous extracellular matrix

B. Malignant epithelial cells with necrotic debris

C. Malignant vascular spindle cells

D. Organized thrombus

E. Well-organized, mature adipocytes

Submit

A 30-year-old man is brought to the emergency department due to left-sided weakness. His left arm was sluggish after awakening, and he had difficulty walking to the bathroom. The patient has no known medical conditions but has a 2-month history of positional dyspnea. Vital signs are within normal limits. On examination, strength of the left upper and left lower extremity is reduced, and touch/temperature sensation is similarly diminished. Cardiovascular examination reveals an intermittent murmur at the apex without carotid bruits. Echocardiography shows a mobile, 3-cm left atrial mass obstructing the mitral opening during diastole. Histologic examination of this mass would most likely show which of the following findings?

- ✓ A. Amorphous extracellular matrix (66%)
- B. Malignant epithelial cells with necrotic debris (7%)
- C. Malignant vascular spindle cells (8%)
- D. Organized thrombus (14%)
- E. Well-organized, mature adipocytes (2%)

Omitted
Correct answer
A

66%
Answered correctly

03 secs
Time Spent

04/28/2020
Last Updated

Explanation

1
2
3
4
5
6
7
8
9
10
11
12
13
14
15
16
17
18
19
20
21
22
23

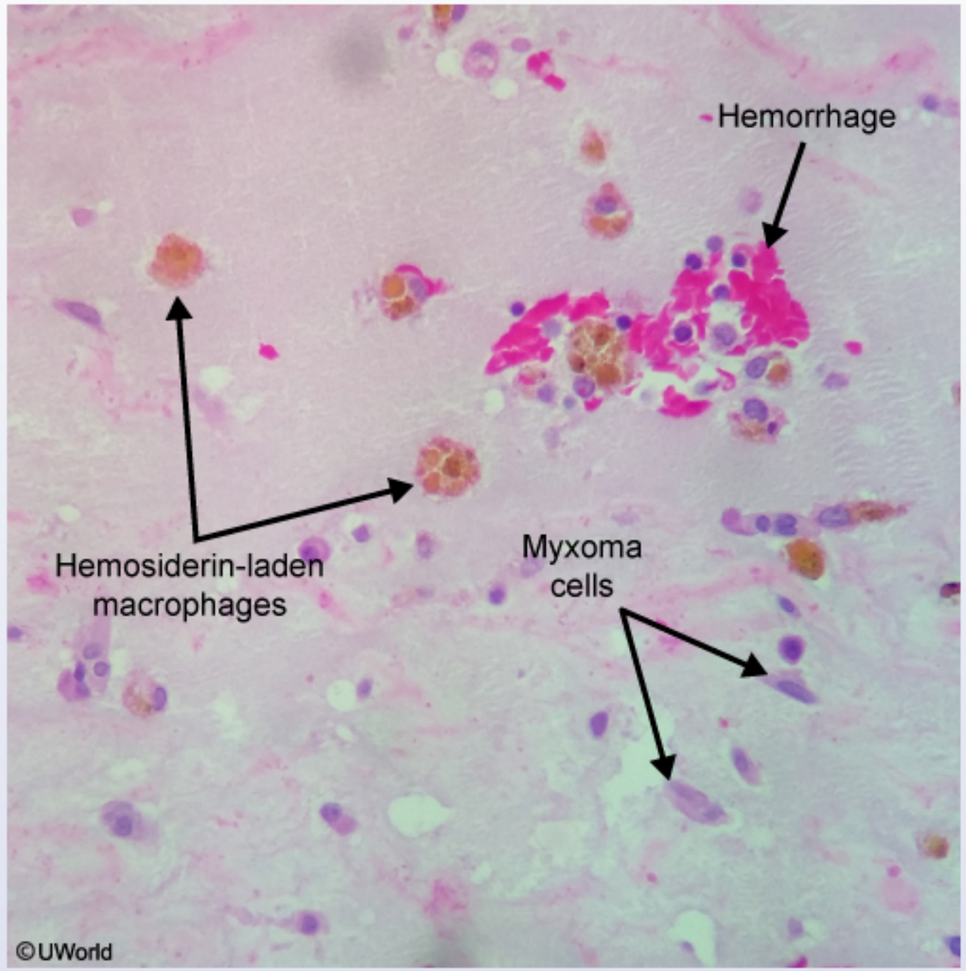

This patient's left atrial mass on echocardiography is consistent with an **atrial myxoma**; this benign tumor is the most common primary cardiac neoplasm. Approximately 80% originate in the **left atrium**, and they can present with **systemic embolization** (eg, stroke) from tumor fragments passing into the systemic circulation. The tumors may also lead to constitutional symptoms (eg, fatigue, weight loss, low-grade fever) resulting from cytokine release, and they may cause transient mitral valve obstruction, leading to symptoms that can **mimic mitral valve stenosis** (eg,

©UWorld

This patient's left atrial mass on echocardiography is consistent with an **atrial myxoma**; this benign tumor is the most common primary cardiac neoplasm. Approximately 80% originate in the **left atrium**, and they can present with **systemic embolization** (eg, stroke) from tumor fragments passing into the systemic circulation. The tumors may also lead to constitutional symptoms (eg, fatigue, weight loss, low-grade fever) resulting from cytokine release, and they may cause transient mitral valve obstruction, leading to symptoms that can **mimic mitral valve stenosis** (eg, dyspnea, orthopnea, hemoptysis).

Physical examination often reveals an intermittent or positional **mid-diastolic murmur** ("tumor plop") that results from the motion of the tumor mass obstructing the mitral valve orifice. Histopathologic examination of a myxoma reveals **amorphous extracellular matrix** with scattered stellate or globular myxoma cells within abundant mucopolysaccharide (myxoid) ground substance containing chondroitin sulfate and hyaluronic acid. Because of their high vascularity, these tumors often demonstrate areas of hemorrhage accompanied by brown, hemosiderin-laden macrophages.

(Choices B and C) Primary malignant cardiac tumors are quite rare; those that occur are usually either sarcomas or lymphomas. Malignant vascular spindle cells suggest primary cardiac angiosarcoma, which usually arises in the right atrium and is exceedingly rare. Malignant epithelial cells with necrotic debris suggest secondary involvement of the heart from a metastatic malignancy (eg, melanoma, lung cancer, breast cancer).

(Choice D) An organized thrombus can form in the left atrium or left atrial appendage in patients with atrial flutter or fibrillation and may cause stroke due to systemic embolization. However, thrombi are typically adherent to the cardiac endothelium; a mobile mass in the left atrium is more characteristic of a myxoma.

(Choice E) Lipomas are benign tumors composed of well-organized, mature adipocytes. They are the second most common type of primary cardiac neoplasm; however, unlike myxomas, lipomas rarely embolize.

Educational objective:
Myxomas are the most common primary cardiac neoplasm, and approximately 80% originate in the left atrium. Patients may have systemic embolization (eg, stroke) or symptomatic mitral valve obstruction that may be worse with certain body positions. Histopathologic examination reveals amorphous extracellular matrix with scattered stellate or globular myxoma cells within abundant mucopolysaccharide ground substance.

References

- Histopathologic and clinical characterization of cardiac myxoma: review of 53 cases from a single institution.

A 60-year-old man comes to the office with a 6-month history of exertional chest pain that remits with rest. His other medical conditions include hypertension, diabetes mellitus, and hypercholesterolemia. An exercise stress test is positive for inducible ischemia. Cardiac catheterization shows 80% occlusion of the right coronary artery and 60% occlusion of the left coronary artery. The first step in the pathogenesis of this patient's coronary artery disease most likely involved which of the following cell types?

- A. Endothelial cells
- B. Interstitial fibroblasts
- C. Macrophages
- D. Mast cells
- E. Pericytes
- F. Platelets
- G. Smooth muscle cells

Submit

A 60-year-old man comes to the office with a 6-month history of exertional chest pain that remits with rest. His other medical conditions include hypertension, diabetes mellitus, and hypercholesterolemia. An exercise stress test is positive for inducible ischemia. Cardiac catheterization shows 80% occlusion of the right coronary artery and 60% occlusion of the left coronary artery. The first step in the pathogenesis of this patient's coronary artery disease most likely involved which of the following cell types?

- ✓ A. Endothelial cells (76%)
- B. Interstitial fibroblasts (0%)
- C. Macrophages (16%)
- D. Mast cells (0%)
- E. Pericytes (0%)
- F. Platelets (2%)
- G. Smooth muscle cells (2%)

Omitted
Correct answer
A

76%
Answered correctly

03 secs
Time Spent

05/01/2020
Last Updated

Explanation

1
2
3
4
5
6
7
8
9
10
11
12
13
14
15
16
17
18
19
20
21
22
23

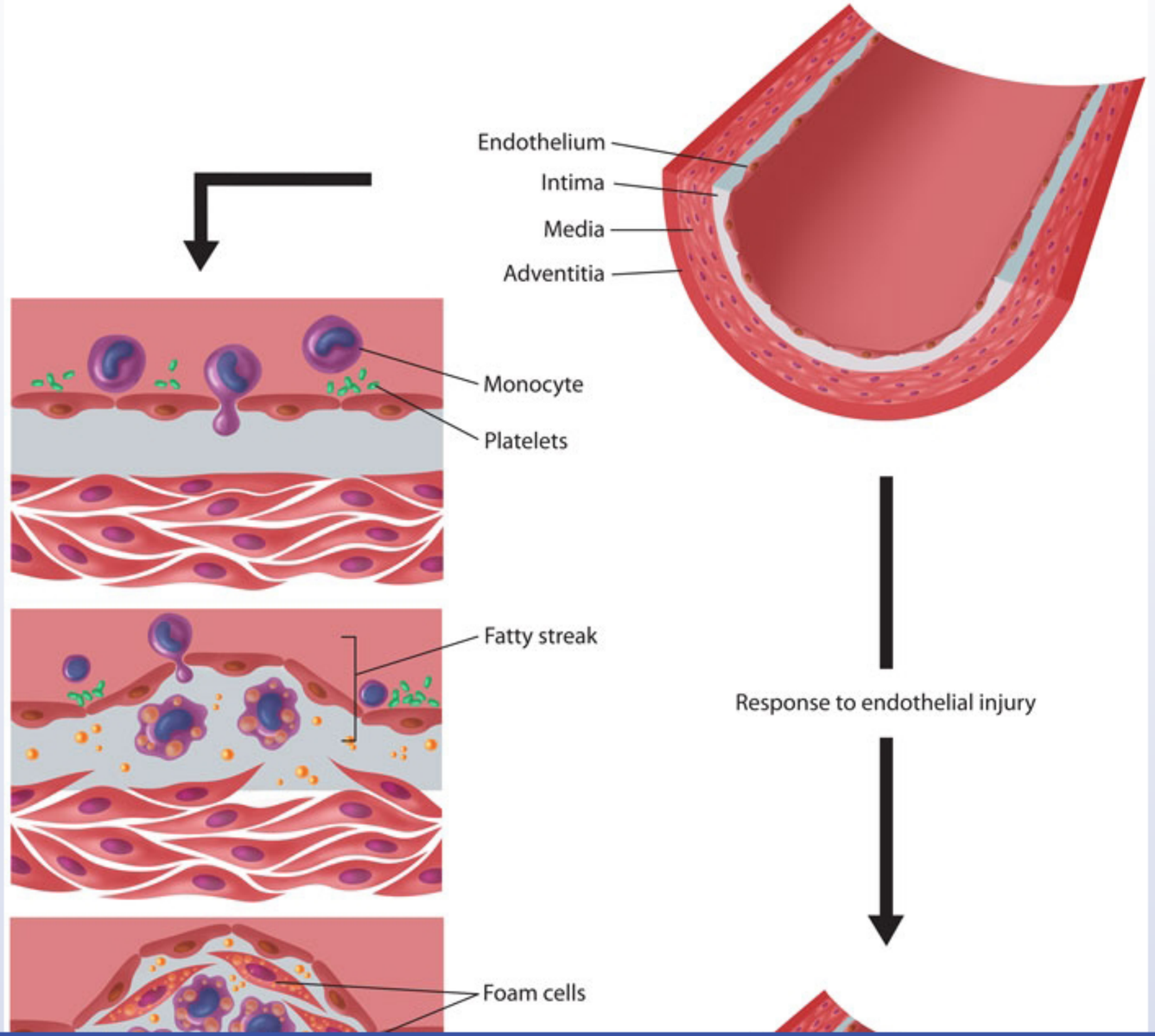

1
2
3
4
5
6
7
8
9
10
11
12
13
14
15
16
17
18
19
20
21
22
23

Exhibit Display

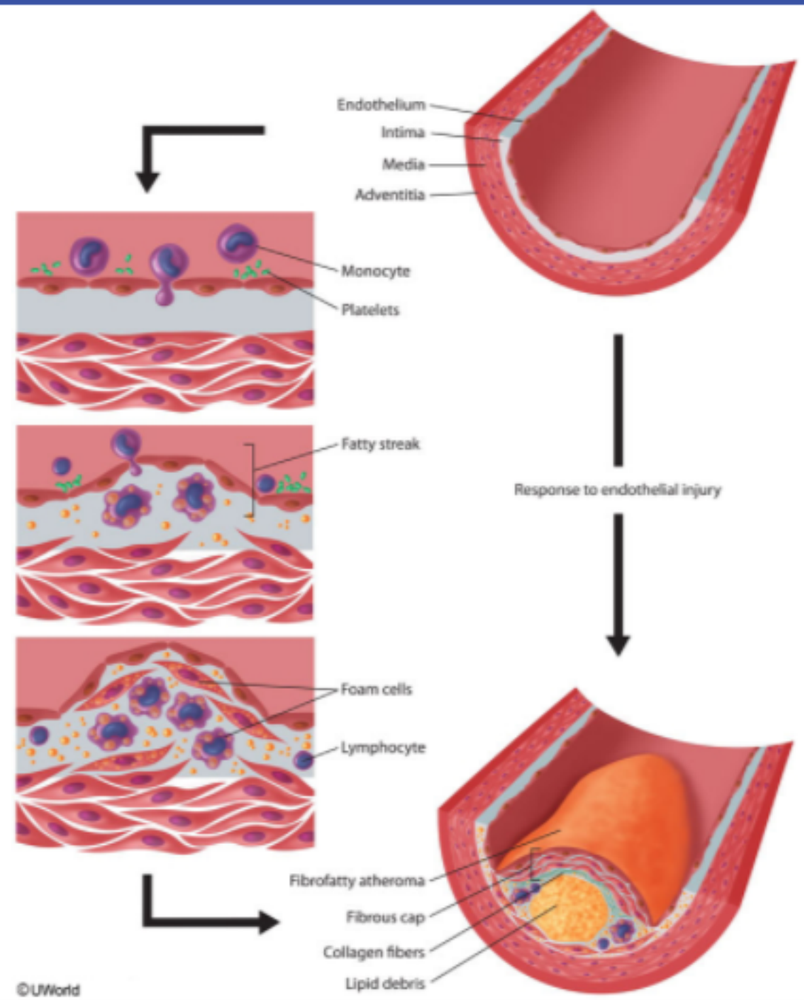

Zoom In | Zoom Out | Reset | Add To New Card | Existing Card

1
2
3
4
5
6
7
8
9
10
11
12
13
14
15
16
17
18
19
20
21
22
23

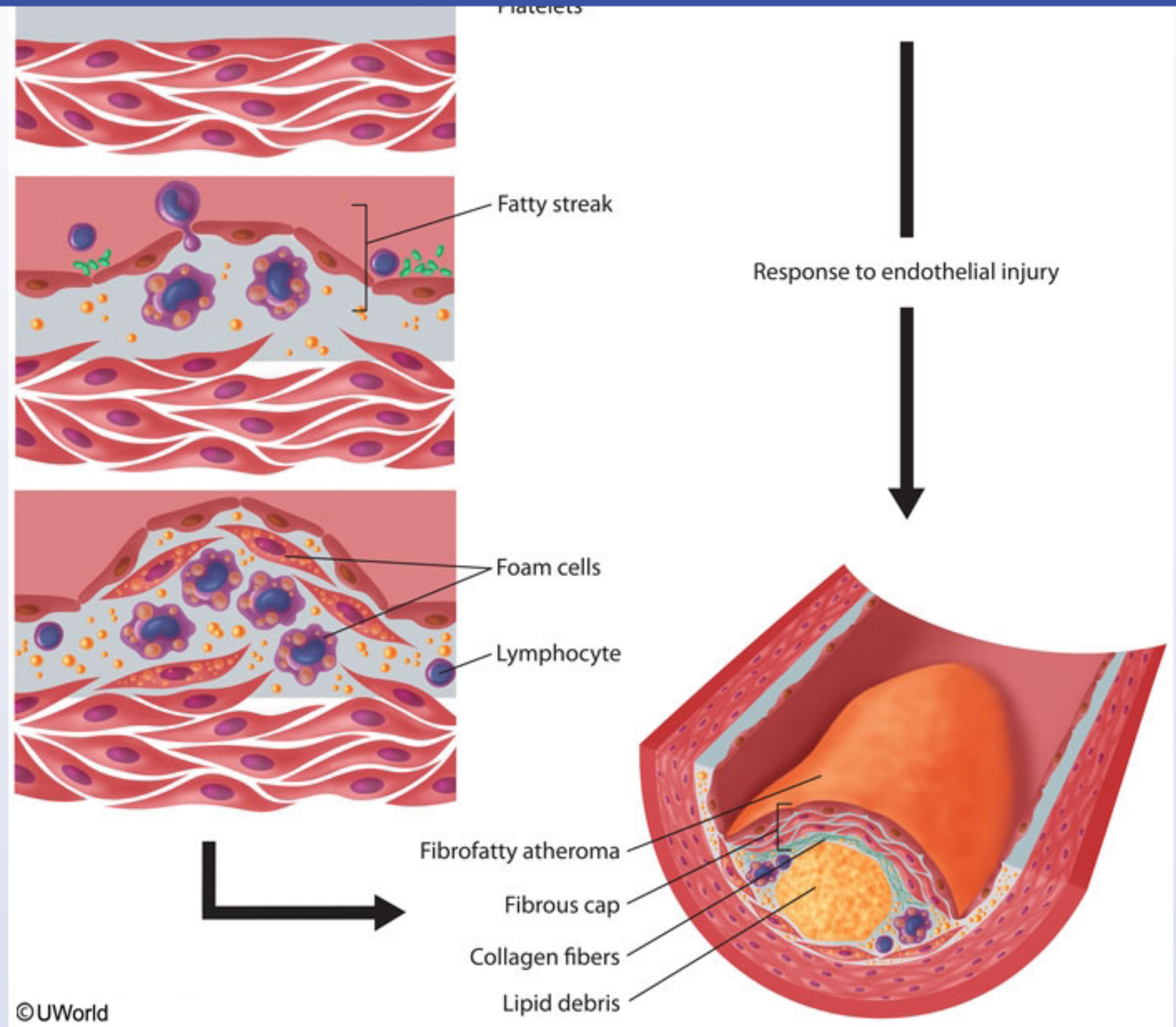

This patient's presentation is consistent with coronary artery **atherosclerosis**. The pathogenesis of atherosclerosis likely begins with **endothelial**

©UWorld

This patient's presentation is consistent with coronary artery **atherosclerosis**. The pathogenesis of atherosclerosis likely begins with **endothelial cell injury**. Chronic endothelial cell injury may result from hypertension (and related hemodynamic factors), hyperlipidemia, smoking, and diabetes mellitus. Such injury leads to endothelial cell dysfunction and/or exposure of subendothelial collagen (endothelial cell denudation).

Endothelial cell dysfunction results in monocyte and lymphocyte adhesion and migration into the intima **(Choice C)**, while exposure of subendothelial collagen promotes platelet adhesion **(Choice F)**. Growth factors produced by monocytes and platelets stimulate medial smooth muscle cell (SMC) migration into the intima **(Choice G)**. At the same time, increased vascular permeability allows LDL cholesterol into the intima, where it is phagocytosed by the accumulating macrophages and SMCs to produce lipid-laden foam cells (**fatty streak**).

The continued release of cytokines and growth factors results in a chronic inflammatory state within the underlying intima. This promotes further deposition of LDL cholesterol within the intima and stimulates SMC proliferation with increased production of collagen and proteoglycans. Necrosis of foam cells results in release of toxic oxidized LDL into the extracellular matrix, perpetuating a cycle of injury. The lesion eventually organizes into a core of lipid debris surrounded by monocytes and lymphocytes covered by a fibrous cap with intermixed SMCs (**fibrofatty atheroma**).

(Choice B) Fibroblasts do not contribute significantly to atheroma formation. The fibrous tissue, including the fibrous cap, of atheromas is synthesized by SMCs that have migrated to the intimal layer in which the plaque forms.

(Choice D) Mast cells are not significantly involved in the pathogenesis of atherosclerosis.

(Choice E) Pericytes are pluripotent cells that surround the smallest blood vessels (especially postcapillary venules). Because atherosclerosis affects the large elastic arteries and large- and medium-sized muscular arteries, these cells do not play a significant role.

Educational objective:
Atherosclerosis is initiated by repetitive endothelial cell injury, which leads to a chronic inflammatory state in the underlying intima of large elastic arteries as well as in large- and medium-sized muscular arteries.

Pathology	Cardiovascular System	Atherosclerosis
Subject	System	Topic

Copyright © UWorld. All rights reserved.

A 42-year-old woman is brought to the hospital due to right-sided weakness and difficulty speaking. She has a longstanding history of a diastolic murmur, but her medical follow-up has been poor. She does not use tobacco, alcohol, or illicit drugs. A CT scan of the brain reveals a large ischemic stroke involving the left middle cerebral artery distribution. The patient dies 2 days later due to progressive neurologic deterioration. At autopsy, exploration of the left atrium shows diffuse fibrous thickening and distortion of the mitral valve leaflets, commissural fusion at the leaflet edges, and narrowing of the mitral valve orifice. This finding is most likely the result of which of the following conditions?

- A. Congenital heart disease
- B. Degenerative valvular calcinosis
- C. Infective endocarditis
- D. Late syphilis
- E. Rheumatic fever
- F. Rheumatoid arthritis
- G. Rupture of the papillary muscle

Submit

A 42-year-old woman is brought to the hospital due to right-sided weakness and difficulty speaking. She has a longstanding history of a diastolic murmur, but her medical follow-up has been poor. She does not use tobacco, alcohol, or illicit drugs. A CT scan of the brain reveals a large ischemic stroke involving the left middle cerebral artery distribution. The patient dies 2 days later due to progressive neurologic deterioration. At autopsy, exploration of the left atrium shows diffuse fibrous thickening and distortion of the mitral valve leaflets, commissural fusion at the leaflet edges, and narrowing of the mitral valve orifice. This finding is most likely the result of which of the following conditions?

- A. Congenital heart disease (3%)
- B. Degenerative valvular calcinosis (7%)
- C. Infective endocarditis (12%)
- D. Late syphilis (1%)
- ✓ E. Rheumatic fever (72%)
- F. Rheumatoid arthritis (0%)
- G. Rupture of the papillary muscle (1%)

Omitted
Correct answer
E

72%
Answered correctly

03 secs
Time Spent

05/10/2020
Last Updated

Explanation

This patient's presentation suggests **mitral stenosis** (MS) due to rheumatic heart disease. Fibrous thickening and fusion of the valve leaflets in chronic rheumatic heart disease following acute **rheumatic fever** is the most common cause of MS, accounting for up to 99% of cases. There is

This patient's presentation suggests **mitral stenosis** (MS) due to rheumatic heart disease. Fibrous thickening and fusion of the valve leaflets in chronic rheumatic heart disease following acute **rheumatic fever** is the most common cause of MS, accounting for up to 99% of cases. There is often a latency period of 10-20 years between the initial episode of rheumatic fever and symptomatic MS, with most patients manifesting during the fourth or fifth decade of life.

Mitral stenosis can cause atrial enlargement, which may lead to **atrial fibrillation** and/or atrial **mural thromboses**. Thrombi dislodged from the wall of the left atrium may later cause an embolic stroke, which likely occurred in this patient. Cardiac auscultation in **mitral stenosis** often reveals a loud first heart sound (S1), an early diastolic sound (opening snap), followed by a **mid-diastolic murmur** from turbulent flow across the mitral valve.

(Choice A) Congenital endocardial cushion defects can result in mitral regurgitation. However, congenital mitral valve stenosis is rare and untreated newborns and infants typically have a grim prognosis.

(Choice B) Degenerative calcific deposits most commonly develop in the mitral valve annulus in women over age 60 and generally do not impair valve function. This patient's autopsy did not show any peripherally located nodular calcific deposits.

(Choice C) Embolization of vegetations due to infective endocarditis can cause a stroke or septic infarct resulting in a brain abscess. However, infective endocarditis is usually associated with large friable vegetations on the valve cusps along with destruction (rather than fibrosis) of the valve leaflets.

(Choice D) Tertiary syphilis may result in aortitis, aortic aneurysm, and/or aortic regurgitation. Mitral valve lesions are not commonly observed.

(Choice F) Although cardiac involvement is uncommon in rheumatoid arthritis, patients can develop pericarditis and myocarditis. Rheumatoid nodules can also develop in the cardiac tissues (including valvular structures), but these are rarely symptomatic.

(Choice G) Rupture of papillary muscle (whether due to bacterial endocarditis, a connective tissue disease, or myocardial infarction) leads to prolapse of the valve leaflets and mitral regurgitation (holosystolic or early systolic murmur).

Educational objective:
Rheumatic mitral stenosis is characterized by diffuse fibrous thickening and distortion of the mitral valve leaflets along with commissural fusion at the leaflet edges. Patients often present with a diastolic murmur, dyspnea, and fatigue and are at increased risk of atrial fibrillation and

wall of the left atrium may later cause an embolic stroke, which likely occurred in this patient. Cardiac auscultation in **mitral stenosis** often reveals a loud first heart sound (S1), an early diastolic sound (opening snap), followed by a **mid-diastolic murmur** from turbulent flow across the mitral valve.

(Choice A) Congenital endocardial cushion defects can result in mitral regurgitation. However, congenital mitral valve stenosis is rare and untreated newborns and infants typically have a grim prognosis.

(Choice B) Degenerative calcific deposits most commonly develop in the mitral valve annulus in women over age 60 and generally do not impair valve function. This patient's autopsy did not show any peripherally located nodular calcific deposits.

(Choice C) Embolization of vegetations due to infective endocarditis can cause a stroke or septic infarct resulting in a brain abscess. However, infective endocarditis is usually associated with large friable vegetations on the valve cusps along with destruction (rather than fibrosis) of the valve leaflets.

(Choice D) Tertiary syphilis may result in aortitis, aortic aneurysm, and/or aortic regurgitation. Mitral valve lesions are not commonly observed.

(Choice F) Although cardiac involvement is uncommon in rheumatoid arthritis, patients can develop pericarditis and myocarditis. Rheumatoid nodules can also develop in the cardiac tissues (including valvular structures), but these are rarely symptomatic.

(Choice G) Rupture of papillary muscle (whether due to bacterial endocarditis, a connective tissue disease, or myocardial infarction) leads to prolapse of the valve leaflets and mitral regurgitation (holosystolic or early systolic murmur).

Educational objective:
Rheumatic mitral stenosis is characterized by diffuse fibrous thickening and distortion of the mitral valve leaflets along with commissural fusion at the leaflet edges. Patients often present with a diastolic murmur, dyspnea, and fatigue and are at increased risk of atrial fibrillation and thromboembolism (eg, stroke).

Pathology	Cardiovascular System	Mitral stenosis
Subject	System	Topic

Copyright © UWorld. All rights reserved.

A 22-year-old Caucasian male presents to the emergency room complaining of severe headaches and vomiting. Soon after, he slips into a coma and dies. Autopsy shows a ruptured cerebral aneurysm with extensive intracranial hemorrhage. This patient's condition is most likely associated with:

- A. Primum-type atrial septal defect
- B. Secundum-type atrial septal defect
- C. Ventricular septal defect
- D. Patent ductus arteriosus
- E. Coarctation of the aorta
- F. Tetralogy of Fallot

Submit

A 22-year-old Caucasian male presents to the emergency room complaining of severe headaches and vomiting. Soon after, he slips into a coma and dies. Autopsy shows a ruptured cerebral aneurysm with extensive intracranial hemorrhage. This patient's condition is most likely associated with:

- A. Primum-type atrial septal defect (7%)
- B. Secundum-type atrial septal defect (11%)
- C. Ventricular septal defect (12%)
- D. Patent ductus arteriosus (6%)
- ✓ E. Coarctation of the aorta (58%)
- F. Tetralogy of Fallot (4%)

Omitted
Correct answer
E

58%
Answered correctly

03 secs
Time Spent

03/30/2020
Last Updated

Explanation

Since there is no history of head trauma, this patient most likely suffered a spontaneous intracranial hemorrhage (SICH). The most common causes of SICH in young adults are arteriovenous malformations, ruptured cerebral aneurysms, or abuse of sympathomimetic drugs such as cocaine.

We are told that this patient had a ruptured cerebral aneurysm, and are asked to identify an associated congenital cardiac anomaly. Although coarctation of the aorta may occur as a solitary defect, it may also be associated with other congenital cardiac anomalies or with berry aneurysms

1
2
3
4
5
6
7
8
9
10
11
12
13
14
15
16
17
18
19
20
21
22
23

E

Explanation

Since there is no history of head trauma, this patient most likely suffered a spontaneous intracranial hemorrhage (SICH). The most common causes of SICH in young adults are arteriovenous malformations, ruptured cerebral aneurysms, or abuse of sympathomimetic drugs such as cocaine.

We are told that this patient had a ruptured cerebral aneurysm, and are asked to identify an associated congenital cardiac anomaly. Although coarctation of the aorta may occur as a solitary defect, it may also be associated with other congenital cardiac anomalies or with berry aneurysms of the Circle of Willis. Berry aneurysms are particularly prone to rupture when associated with coarctation, because of hypertension in branches of the aortic arch proximal to the coarct. Subarachnoid hemorrhage is the result.

(Choices A, B, and C) Isolated atrial or ventricular septal defects are not commonly associated with spontaneous rupture of intracranial aneurysms in young adults. The incidence of intracerebral aneurysms is not increased in patients with isolated septal defects, nor are septal defects associated with severe systemic hypertension (though they may cause severe pulmonary hypertension via left-to-right intracardiac shunt flow). However, the incidence of *thromboembolic stroke* as the result of paradoxical embolism might be increased in patients with an atrial or ventricular septal defect and late-onset right-to-left shunting.

Educational Objective:
Patients with adult-type coarctation of the aorta commonly die of hypertension-associated complications, including left ventricular failure, ruptured dissecting aortic aneurysm, and intracranial hemorrhage. These patients are at increased risk for ruptured intracranial aneurysms because of the increased incidence of congenital berry aneurysms of the Circle of Willis as well as aortic arch hypertension.

Pathology	Cardiovascular System	Aortic coarctation
Subject	System	Topic

Copyright © UWorld. All rights reserved.

A 39-year-old man comes to the emergency department with anterior chest pain. He had felt well until the pain developed 4 days ago. The patient says the pain is sharp and makes it difficult to take a deep breath. Since yesterday, he has also felt out of breath. Medical history is unremarkable. The patient's father died of a heart attack at age 52, and his mother suffers from rheumatoid arthritis. He does not use alcohol or tobacco. Temperature is 37.4 C (99.3 F), blood pressure is 112/65 mm Hg, and pulse is 103/min and regular. Bedside ultrasound examination demonstrates a moderate pericardial effusion. Which of the following is the most likely cause of this patient's current condition?

A. Autoimmune disease
B. Coronary artery disease
C. Gram-positive cocci
D. Malignancy
E. Viral infection

Submit

A 39-year-old man comes to the emergency department with anterior chest pain. He had felt well until the pain developed 4 days ago. The patient says the pain is sharp and makes it difficult to take a deep breath. Since yesterday, he has also felt out of breath. Medical history is unremarkable. The patient's father died of a heart attack at age 52, and his mother suffers from rheumatoid arthritis. He does not use alcohol or tobacco. Temperature is 37.4 C (99.3 F), blood pressure is 112/65 mm Hg, and pulse is 103/min and regular. Bedside ultrasound examination demonstrates a moderate pericardial effusion. Which of the following is the most likely cause of this patient's current condition?

- A. Autoimmune disease (20%)
- B. Coronary artery disease (6%)
- C. Gram-positive cocci (4%)
- D. Malignancy (2%)
- ✓ E. Viral infection (66%)

Omitted
Correct answer
E

66%
Answered correctly

03 secs
Time Spent

01/23/2020
Last Updated

Explanation

Acute pericarditis	
Etiology	• Viral or idiopathic • Autoimmune disease (eg, SLE) • Uremia (acute or chronic renal failure)

A 39-year-old man comes to the emergency department with anterior chest pain. He had felt well until the pain developed 4 days ago. The patient says the pain is sharp and makes it difficult to take a deep breath. Since yesterday, he has also felt out of breath. Medical history is unremarkable. The patient's father died of a heart attack at age 52, and his mother suffers from rheumatoid arthritis. He does not use alcohol or tobacco. Temperature is 37.4 C (99.3 F), blood pressure is 112/65 mm Hg, and pulse is 103/min and regular. Bedside ultrasound examination demonstrates a moderate pericardial effusion. Which of the following is the most likely cause of this patient's current condition?

- A. Autoimmune disease (20%)
- B. Coronary artery disease (6%)
- C. Gram-positive cocci (4%)
- D. Malignancy (2%)
- ✓ E. Viral infection (66%)

Omitted
Correct answer
E

66%
Answered correctly

03 secs
Time Spent

01/23/2020
Last Updated

Explanation

Acute pericarditis	
Etiology	• Viral or idiopathic • Autoimmune disease (eg, SLE) • Uremia (acute or chronic renal failure)

Explanation

Acute pericarditis	

Etiology	• Viral or idiopathic
	• Autoimmune disease (eg, SLE)
	• Uremia (acute or chronic renal failure)
	• Post myocardial infarction
	  ◦ Early: peri-infarction pericarditis
	  ◦ Late: Dressler syndrome

Clinical features & diagnosis	• Pleuritic chest pain (↓ when sitting up) ± fever • Pericardial friction rub • ECG: diffuse ST elevation • Pericardial effusion on echocardiogram

SLE = systemic lupus erythematosus.

This patient most likely has **acute viral pericarditis**; viral infection is thought to be the most common cause of pericarditis and many viruses (eg, adenovirus, coxsackievirus, echovirus, influenza virus) have been implicated. Because the viral infection often cannot be confirmed, presumed viral pericarditis is sometimes referred to as **idiopathic**. Pericarditis typically presents with substernal **pleuritic chest pain** that may radiate to the bilateral scapulae posteriorly. The pain is typically worse when lying flat and improves with sitting up and leaning forward.

Cardiac auscultation in acute viral pericarditis classically reveals a triphasic **pericardial friction rub** (occurring during atrial systole, ventricular systole, and early ventricular diastole); however, the rub may be absent, especially in the presence of significant **pericardial effusion**. Mild to moderate-sized pericardial effusion is common and can rarely lead to cardiac tamponade. ECG characteristically demonstrates diffuse ST elevation caused by inflammation of the ventricular myocardium.

(Choice A) Autoimmune disease (eg, systemic lupus erythematosus, rheumatoid arthritis) is a potential cause of pericarditis, but it is less common than viral pericarditis and is unlikely in the absence of a history of joint pains or rash.

1
2
3
4
5
6
7
8
9
10
11
12
13
14
15
16
17
18
19
20
21
22
23

This patient most likely has **acute viral pericarditis**; viral infection is thought to be the most common cause of pericarditis and many viruses (eg, adenovirus, coxsackievirus, echovirus, influenza virus) have been implicated. Because the viral infection often cannot be confirmed, presumed viral pericarditis is sometimes referred to as **idiopathic**. Pericarditis typically presents with substernal **pleuritic chest pain** that may radiate to the bilateral scapulae posteriorly. The pain is typically worse when lying flat and improves with sitting up and leaning forward.

Cardiac auscultation in acute viral pericarditis classically reveals a triphasic **pericardial friction rub** (occurring during atrial systole, ventricular systole, and early ventricular diastole); however, the rub may be absent, especially in the presence of significant **pericardial effusion**. Mild to moderate-sized pericardial effusion is common and can rarely lead to cardiac tamponade. ECG characteristically demonstrates diffuse ST elevation caused by inflammation of the ventricular myocardium.

(Choice A) Autoimmune disease (eg, systemic lupus erythematosus, rheumatoid arthritis) is a potential cause of pericarditis, but it is less common than viral pericarditis and is unlikely in the absence of a history of joint pains or rash.

(Choice B) Myocardial infarction due to coronary artery disease (CAD) can lead to peri-infarction pericarditis (a localized reaction to transmural myocardial necrosis) within 2-4 days or to Dressler syndrome (an autoimmune response to infarction-induced antigens) within weeks to months. Despite a family history of CAD, myocardial infarction is relatively unlikely in this man age <40.

(Choice C) Gram-positive cocci (eg, *Staphylococcus aureus*, *Streptococcus pneumoniae*) in rare cases can cause pericarditis (purulent pericarditis) via direct extension of pneumonia or hematogenous bacterial spread. Affected patients are typically quite ill and present with high fever and sepsis.

(Choice D) Malignant pericarditis can occur in the setting of metastatic cancer (eg, lung cancer, breast cancer); however, it is less likely to present with pain and inflammation and more likely to present with symptoms of fluid accumulation (ie, dyspnea due to subacute cardiac tamponade). Malignant pericarditis is also relatively uncommon compared to viral pericarditis and less likely in this relatively young man.

Educational objective:
Viral infection is thought to be the most common cause of acute pericarditis. It causes a fibrinous or serofibrinous pericarditis that is often characterized by pleuritic chest pain, a friction rub on cardiac auscultation, diffuse ST elevation on ECG, and mild to moderate-sized pericardial effusion.

A 38-year-old woman suddenly collapses at home after experiencing severe chest pain and dies before reaching a hospital. Postmortem examination reveals an occluding thrombus overlying a ruptured atherosclerotic plaque on the left anterior descending artery. The patient is also found to have thickened mitral valve leaflets with multiple small vegetations on both valvular surfaces and fibrinoid necrosis of arterioles. Other findings include glomerular capillary basement membrane thickening with wire-loop changes. This patient was most likely suffering from which of the following conditions?

A. Bacterial endocarditis

B. Churg-Strauss syndrome

C. Granulomatosis with polyangiitis

D. Systemic lupus erythematosus

E. Thromboangiitis obliterans

Submit

A 38-year-old woman suddenly collapses at home after experiencing severe chest pain and dies before reaching a hospital. Postmortem examination reveals an occluding thrombus overlying a ruptured atherosclerotic plaque on the left anterior descending artery. The patient is also found to have thickened mitral valve leaflets with multiple small vegetations on both valvular surfaces and fibrinoid necrosis of arterioles. Other findings include glomerular capillary basement membrane thickening with wire-loop changes. This patient was most likely suffering from which of the following conditions?

- A. Bacterial endocarditis (8%)
- B. Churg-Strauss syndrome (4%)
- C. Granulomatosis with polyangiitis (8%)
- ✓ D. Systemic lupus erythematosus (74%)
- E. Thromboangiitis obliterans (3%)

Omitted
Correct answer
D

74%
Answered correctly

02 secs
Time Spent

05/31/2020
Last Updated

Explanation

1
2
3
4
5
6
7
8
9
10
11
12
13
14
15
16
17
18
19
20
21
22
23

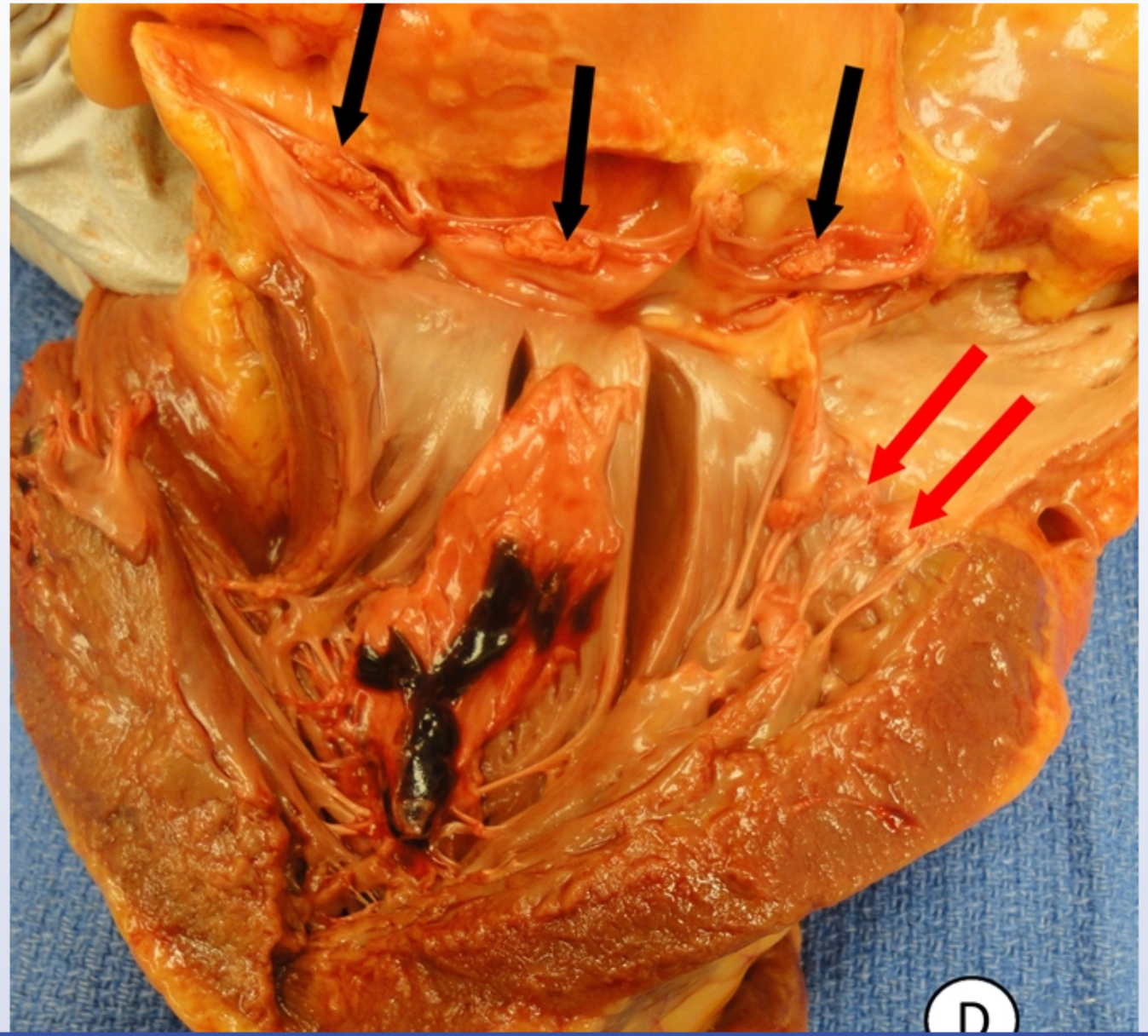

This patient's postmortem findings are consistent with systemic lupus erythematosus (SLE), an autoimmune disease that affects women of childbearing age and results in immune complex-mediated tissue injury in various organs.

Cardiovascular manifestations of SLE include **accelerated atherosclerosis** with increased risk of myocardial infarction. Small arteries and arterioles can also show evidence of vasculitis with fibrinoid necrosis in any tissue. Other cardiac features include pericarditis and less commonly **verrucous (Libman-Sacks) endocarditis**, characterized by thickened valve leaflets (typically mitral [red arrows] and/or aortic [black arrows]) with multiple small vegetations on **both surfaces**. The vegetations are composed of **sterile** platelet thrombi intertwined with strands of fibrin, immune complexes, and mononuclear cells. These vegetations are easily dislodged and can result in systemic embolization.

Renal involvement in SLE most often manifests as **diffuse proliferative glomerulonephritis**, which is characterized by proliferative and necrotizing lesions with crescent formation during active disease. Light microscopy also classically shows diffuse thickening of the glomerular capillary walls with "wire-loop" structures due to subendothelial immune complex deposition.

(Choice A) Bacterial endocarditis is characterized by large, potentially destructive vegetations on the valve cusps that contain fibrin, inflammatory cells, and bacteria (eg, staphylococci, streptococci). Renal involvement can occur with septic embolization or development of immune complex-mediated glomerulonephritis with hypercellular infiltrate and immune deposits in the glomerular capillary wall.

(Choice B) Churg-Strauss syndrome (eosinophilic granulomatosis with polyangiitis) is a small-vessel necrotizing vasculitis characterized by allergic rhinitis, asthma, and peripheral eosinophilia. Although renal involvement is not typically prominent, patients can develop necrotizing crescentic glomerulonephritis.

(Choice C) Granulomatosis with polyangiitis (Wegener granulomatosis) is a small-vessel necrotizing vasculitis characterized by upper respiratory (eg, sinusitis, otitis media) and lower respiratory (eg, dyspnea, hemoptysis) symptoms as well as renal disease. Renal involvement typically manifests as focal necrotizing, crescentic glomerulonephritis.

(Choice E) Thromboangiitis obliterans (Buerger disease) is a small- to medium-vessel vasculitis that typically occurs with cigarette smoking and causes vascular insufficiency in the extremities (eg, gangrene, autoamputation of digits). It is characterized histologically by intraluminal thrombus and prominent inflammatory cell infiltrate with relative sparing of the vessel wall.

Educational objective:
Cardiovascular manifestations of lupus include accelerated atherosclerosis, small-vessel necrotizing vasculitis, pericarditis, and Libman-Sacks

1
2
3
4
5
6
7
8
9
10
11
12
13
14
15
16
17
18
19
20
21
22
23

necrotizing lesions with crescent formation during active disease. Light microscopy also classically shows diffuse thickening of the glomerular capillary walls with "wire-loop" structures due to subendothelial immune complex deposition.

(Choice A) Bacterial endocarditis is characterized by large, potentially destructive vegetations on the valve cusps that contain fibrin, inflammatory cells, and bacteria (eg, staphylococci, streptococci). Renal involvement can occur with septic embolization or development of immune complex-mediated glomerulonephritis with hypercellular infiltrate and immune deposits in the glomerular capillary wall.

(Choice B) Churg-Strauss syndrome (eosinophilic granulomatosis with polyangiitis) is a small-vessel necrotizing vasculitis characterized by allergic rhinitis, asthma, and peripheral eosinophilia. Although renal involvement is not typically prominent, patients can develop necrotizing crescentic glomerulonephritis.

(Choice C) Granulomatosis with polyangiitis (Wegener granulomatosis) is a small-vessel necrotizing vasculitis characterized by upper respiratory (eg, sinusitis, otitis media) and lower respiratory (eg, dyspnea, hemoptysis) symptoms as well as renal disease. Renal involvement typically manifests as focal necrotizing, crescentic glomerulonephritis.

(Choice E) Thromboangiitis obliterans (Buerger disease) is a small- to medium-vessel vasculitis that typically occurs with cigarette smoking and causes vascular insufficiency in the extremities (eg, gangrene, autoamputation of digits). It is characterized histologically by intraluminal thrombus and prominent inflammatory cell infiltrate with relative sparing of the vessel wall.

Educational objective:
Cardiovascular manifestations of lupus include accelerated atherosclerosis, small-vessel necrotizing vasculitis, pericarditis, and Libman-Sacks endocarditis (small, sterile vegetations on both sides of the valve). Renal involvement classically manifests as diffuse proliferative glomerulonephritis, which is characterized by diffuse thickening of the glomerular capillary walls with "wire-loop" structures on light microscopy.

References

- The classification of glomerulonephritis in systemic lupus erythematosus revisited.
- Diagnostic histopathology of major systemic and pulmonary vasculitis syndromes.

Pathology	Cardiovascular System	SLE
Subject	System	Topic

Copyright © UWorld. All rights reserved.

Exhibit Display

Systemic lupus erythematosus

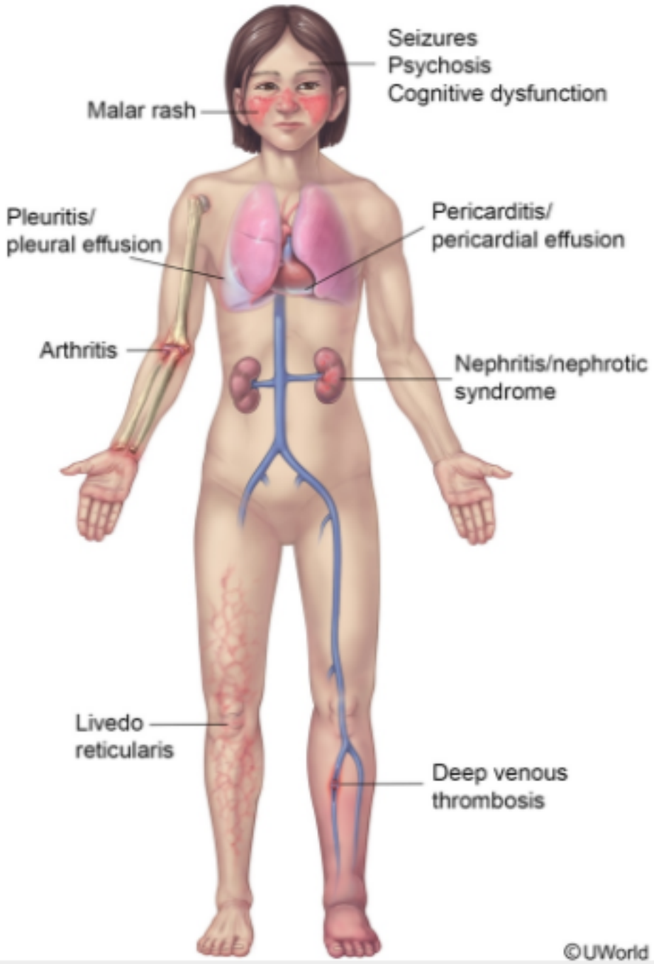

Zoom In | Zoom Out | Reset | Add To New Card | Existing Card

mediated glomerulonephritis with hypercellular infiltrate and immune deposits in the glomerular capillary wall.

1
2
3
4
5
6
7
8
9
10
11
12
13
14
15
16
17
18
19
20
21
22
23

A 1-week-old boy is brought to the office for his first primary care visit following an uncomplicated vaginal delivery at 40 weeks gestation. The boy was born to a 30-year-old woman who took prenatal vitamins throughout the pregnancy. She was diagnosed with gestational diabetes mellitus at 28 weeks gestation, which was treated with dietary modification and exercise. The nursery course was uncomplicated, and the boy was discharged at around 30 hours of life following observation of appropriate breastfeeding, voiding, and stooling. His weight, length, and head circumference are at the 50th percentile. Physical examination shows a grade II/VI harsh, holosystolic murmur best heard at the left mid to lower sternal border. Birth records show that no murmur was heard by 2 different health care providers in the newborn nursery. Which of the following is the most likely diagnosis?

- A. Coarctation of the aorta
- B. Ebstein's anomaly
- C. Patent ductus arteriosus
- D. Peripheral pulmonary stenosis
- E. Primum-type atrial septal defect
- F. Secundum-type atrial septal defect
- G. Tetralogy of Fallot
- H. Wolff-Parkinson-White syndrome
- I. Ventricular septal defect

Submit

A 1-week-old boy is brought to the office for his first primary care visit following an uncomplicated vaginal delivery at 40 weeks gestation. The boy was born to a 30-year-old woman who took prenatal vitamins throughout the pregnancy. She was diagnosed with gestational diabetes mellitus at 28 weeks gestation, which was treated with dietary modification and exercise. The nursery course was uncomplicated, and the boy was discharged at around 30 hours of life following observation of appropriate breastfeeding, voiding, and stooling. His weight, length, and head circumference are at the 50th percentile. Physical examination shows a grade II/VI harsh, holosystolic murmur best heard at the left mid to lower sternal border. Birth records show that no murmur was heard by 2 different health care providers in the newborn nursery. Which of the following is the most likely diagnosis?

A. Coarctation of the aorta (2%)
B. Ebstein's anomaly (4%)
C. Patent ductus arteriosus (13%)
D. Peripheral pulmonary stenosis (2%)
E. Primum-type atrial septal defect (3%)
F. Secundum-type atrial septal defect (5%)
G. Tetralogy of Fallot (3%)
H. Wolff-Parkinson-White syndrome (0%)
✓ I. Ventricular septal defect (63%)

Omitted
Correct answer
I

63%
Answered correctly

04 secs
Time Spent

01/29/2020
Last Updated

Congenital heart defects	
Cyanotic	**Non-cyanotic**
• Ebstein's anomaly • Tetralogy of Fallot • Tricuspid atresia • Transposition of the great vessels • Truncus arteriosus • Total anomalous pulmonary venous return	• Atrial septal defect • Ventricular septal defect • Patent ductus arteriosus • Coarctation of the aorta

©UWorld

This patient's presentation is consistent with a ventricular septal defect (VSD), the most common congenital heart lesion. **Echocardiography** should be performed to confirm the location and size of the VSD.

Patients with **small VSDs** typically have a loud, "blowing," holosystolic murmur at the mid to lower **left sternal border** and **no symptoms**. The murmur is not usually detectable at birth, but becomes audible around age 4-10 days as pulmonary vascular resistance (PVR) continues to decline, permitting significant **left-to-right shunting**. Most small VSDs are hemodynamically insignificant and close spontaneously.

In contrast, moderate to large VSDs usually present with heart failure, failure to thrive, and diaphoresis with feeding. Large VSDs may have no murmur as right ventricular pressures are similar to those of the left ventricle. In addition, large VSDs rarely close spontaneously and can result in chronic pulmonary hypertension and cyanosis (Eisenmenger syndrome) if the defect is not closed early in life.

(Choice A) Coarctation of the aorta is a non-cyanotic congenital heart disease that can present in infancy with shock when the patent ductus arteriosus closes. Children and adults who present in later life tend to have milder coarctation that manifests as upper body hypertension and collateral intercostal vessels.

(Choice B) Ebstein's anomaly is characterized by displacement of a malformed tricuspid valve into the right ventricle. Soon after birth, it presents

This patient's presentation is consistent with a ventricular septal defect (VSD), the most common congenital heart lesion. **Echocardiography** should be performed to confirm the location and size of the VSD.

Patients with **small VSDs** typically have a loud, "blowing," holosystolic murmur at the mid to lower **left sternal border** and **no symptoms**. The murmur is not usually detectable at birth, but becomes audible around age 4-10 days as pulmonary vascular resistance (PVR) continues to decline, permitting significant **left-to-right shunting**. Most small VSDs are hemodynamically insignificant and close spontaneously.

In contrast, moderate to large VSDs usually present with heart failure, failure to thrive, and diaphoresis with feeding. Large VSDs may have no murmur as right ventricular pressures are similar to those of the left ventricle. In addition, large VSDs rarely close spontaneously and can result in chronic pulmonary hypertension and cyanosis (Eisenmenger syndrome) if the defect is not closed early in life.

(Choice A) Coarctation of the aorta is a non-cyanotic congenital heart disease that can present in infancy with shock when the patent ductus arteriosus closes. Children and adults who present in later life tend to have milder coarctation that manifests as upper body hypertension and collateral intercostal vessels.

(Choice B) Ebstein's anomaly is characterized by displacement of a malformed tricuspid valve into the right ventricle. Soon after birth, it presents as cyanosis and heart failure from severe tricuspid regurgitation.

(Choices C, E, and F) Atrial septal defects (wide, fixed splitting of S2) and patent ductus arteriosus (continuous murmur) are non-cyanotic congenital heart diseases. These initially cause left-to-right intracardiac shunting, although untreated large defects may become complicated by Eisenmenger syndrome.

(Choice D) Peripheral pulmonary stenosis (ie, pulmonary branch stenosis) is a common cause of innocent murmur that is heard after the first day of life when the patent ductus arteriosus is closed. The murmur results from the relative hypoplasia of branch pulmonary arteries compared to the relatively large main pulmonary artery. Auscultation may reveal a low-grade, mid-systolic, high-pitched, or blowing ejection murmur that is best heard in the pulmonary area with radiation to the axilla and back.

(Choice G) Tetralogy of Fallot symptoms depend on the severity of right ventricular outflow obstruction. Those with severe obstruction present with profound cyanosis in infancy, but patients with moderate obstruction have "tet" spells later in childhood.

(Choice H) The hallmark of Wolff-Parkinson-White (WPW) syndrome is preexcitation, which manifests on ECG as a short PR interval, delta wave, and widening of the QRS complex. Arrhythmias are associated with WPW but not with murmurs.

This patient's presentation is consistent with a ventricular septal defect (VSD), the most common congenital heart lesion. **Echocardiography**

Exhibit Display

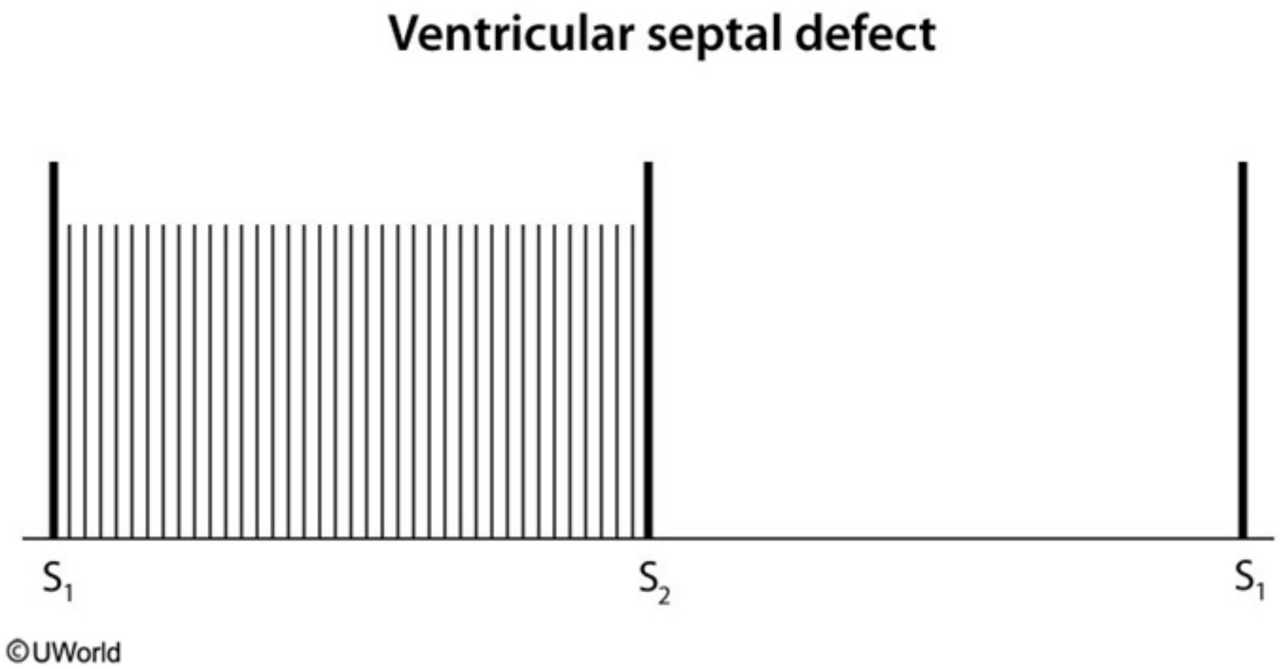

Zoom In | Zoom Out | Reset | Add To New Card | Existing Card

and widening of the QRS complex. Arrhythmias are associated with WPW but not with murmurs.

This patient's presentation is consistent with a ventricular septal defect (VSD), the most common congenital heart lesion. **Echocardiography**

Exhibit Display

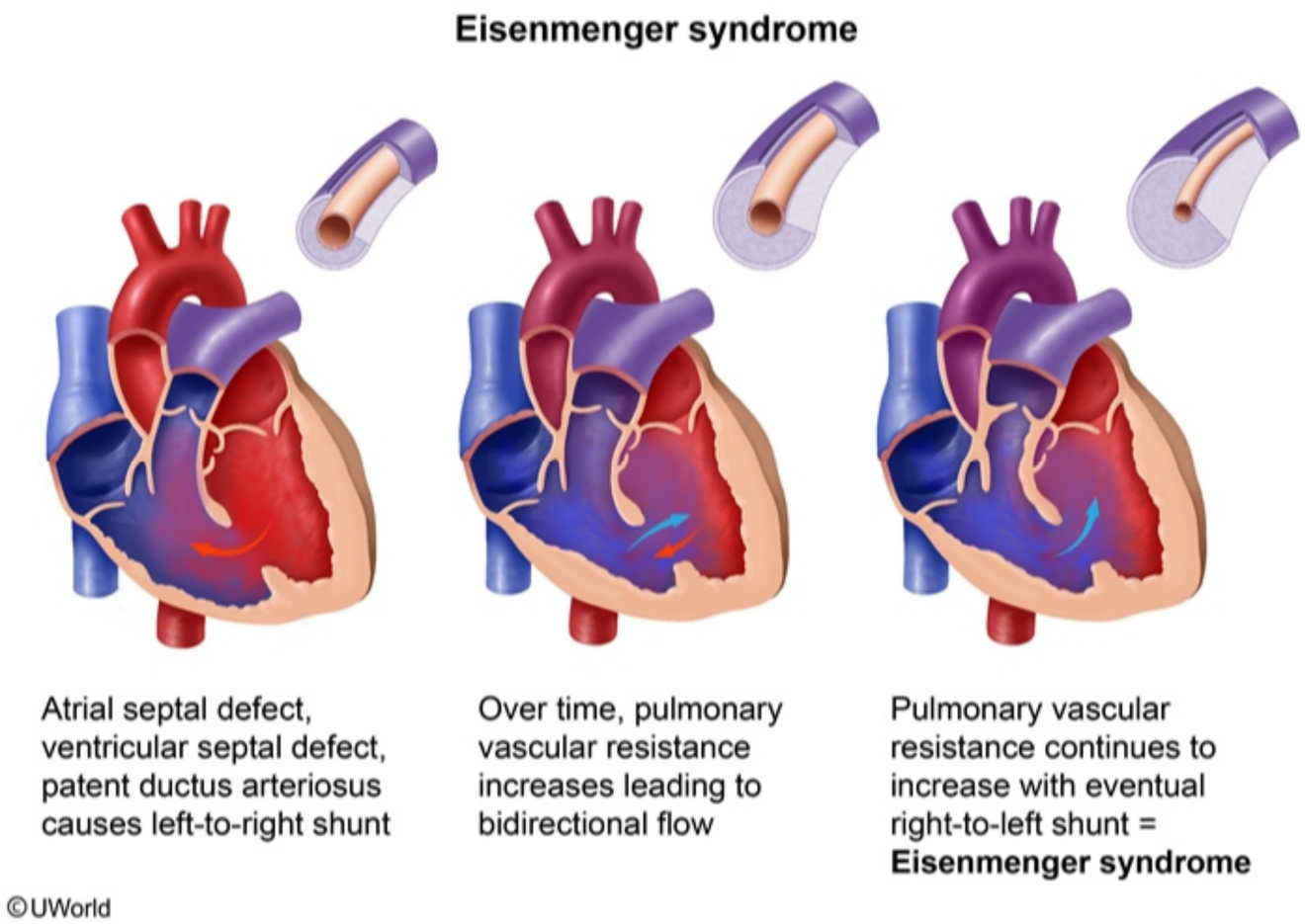

Zoom In | Zoom Out | Reset | Add To New Card | Existing Card

and widening of the QRS complex. Arrhythmias are associated with WPW but not with murmurs.

This patient's presentation is consistent with a ventricular septal defect (VSD), the most common congenital heart lesion. **Echocardiography**

Exhibit Display

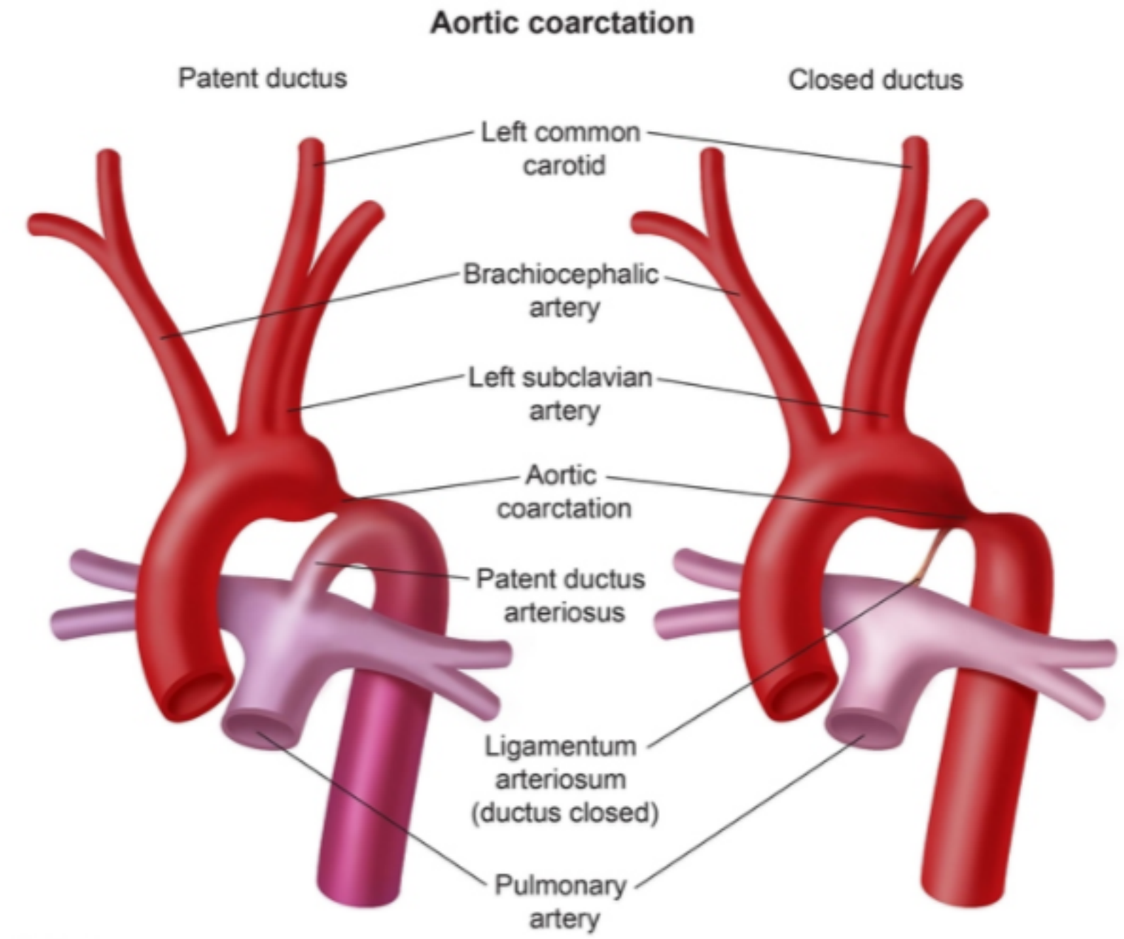

Zoom In | Zoom Out | Reset | Add To New Card | Existing Card

and widening of the QRS complex. Arrhythmias are associated with WPW but not with murmurs.

This patient's presentation is consistent with a ventricular septal defect (VSD), the most common congenital heart lesion. **Echocardiography**

Exhibit Display

Ebstein's anomaly

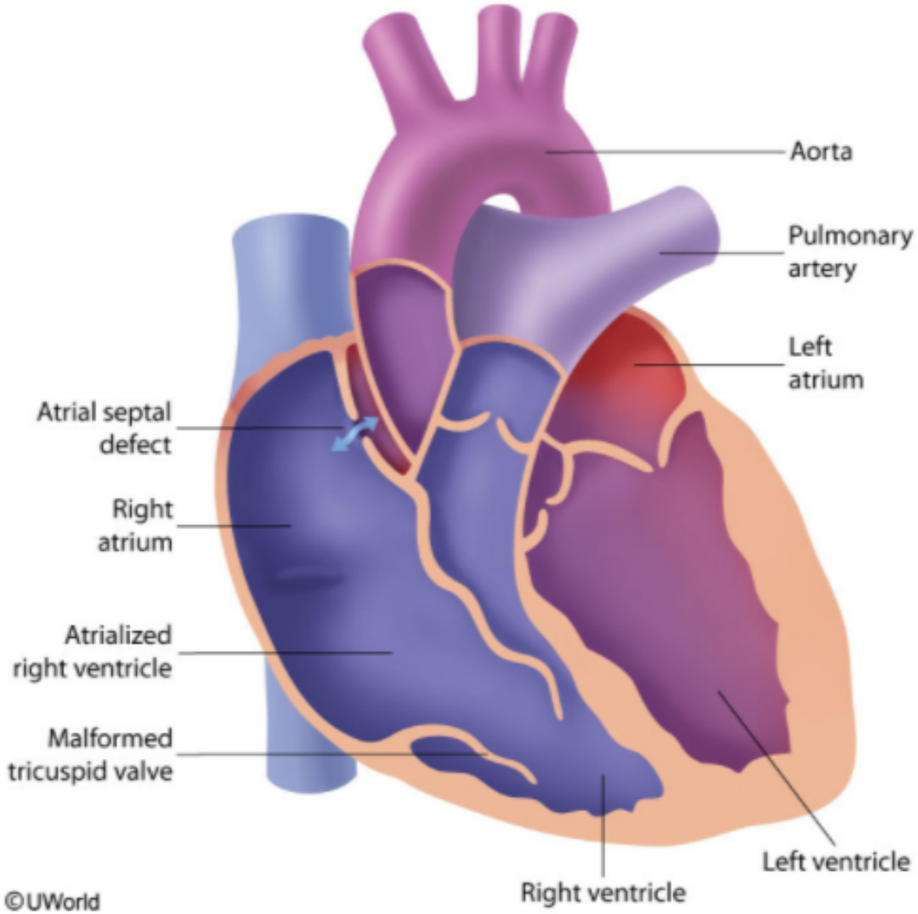

Zoom In | Zoom Out | Reset | Add To New Card | Existing Card

and widening of the QRS complex. Arrhythmias are associated with WPW but not with murmurs.

This patient's presentation is consistent with a ventricular septal defect (VSD), the most common congenital heart lesion. **Echocardiography**

Exhibit Display

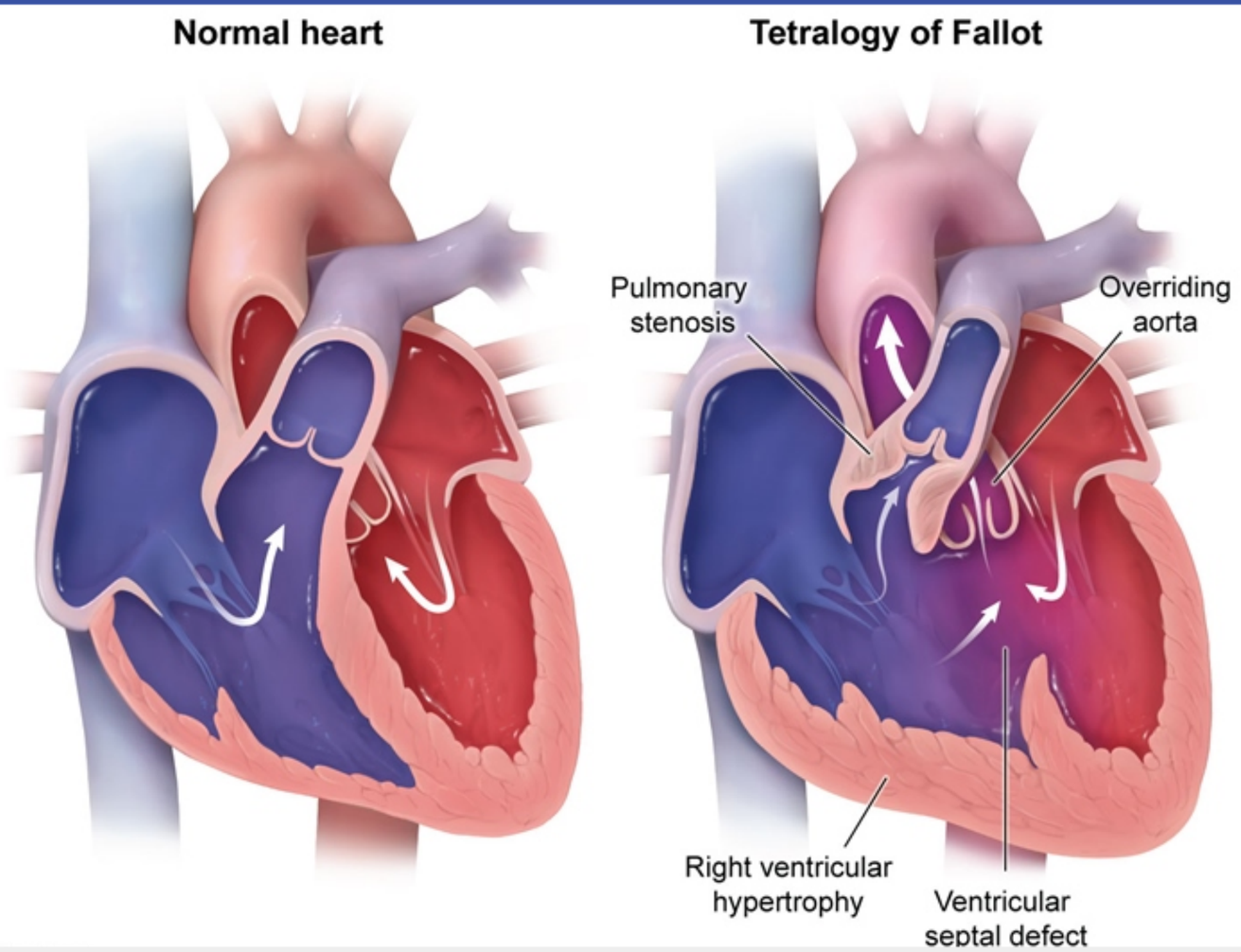

Zoom In | Zoom Out | Reset | Add To New Card | Existing Card

and widening of the QRS complex. Arrhythmias are associated with WPW but not with murmurs.

1
2
3
4
5
6
7
8
9
10
11
12
13
14
15
16
17
18
19
20
21
22
23

(Choice B) Ebstein's anomaly is characterized by displacement of a malformed tricuspid valve into the right ventricle. Soon after birth, it presents

Exhibit Display

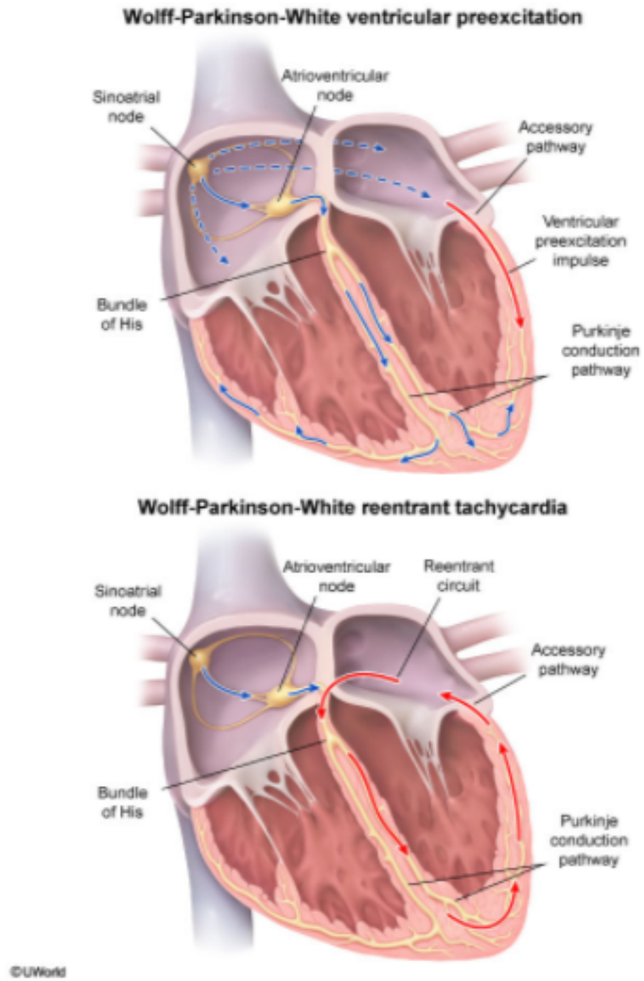

Zoom In | Zoom Out | Reset | Add To New Card | Existing Card

1
2
3
4
5
6
7
8
9
10
11
12
13
14
15
16
17
18
19
20
21
22
23

A 32-year-old man is brought to the emergency department with a several-day history of high-grade fever, dyspnea, and fatigue. The patient's temperature is 39.4 C (102.9 F), blood pressure is 122/70 mm Hg, and pulse is 102/min and regular. Physical examination reveals a new holosystolic murmur with a blowing quality that is best heard over the cardiac apex. Skin examination shows nontender lesions on the sole of the feet, as shown in the image below.

1
2
3
4
5
6
7
8
9
10
11
12
13
14
15
16
17
18
19
20
21
22
23

1
2
3
4
5
6
7
8
9
10
11
12
13
14
15
16
17
18
19
20
21
22
23

Displayed with permission from Springer Healthcare Ltd. © Copyright 1997, 2004 by Current Medicine

Which of the following do these lesions most likely represent?

- A. Areas of local vascular growth
- B. Foci of granulomatous inflammation
- C. Immune complex-mediated vascular lesions
- D. Microemboli to skin vessels
- E. Primary infection foci

Submit

1
2
3
4
5
6
7
8
9
10
11
12
13
14
15
16
17
18
19
20
21
22
23

Displayed with permission from Springer Healthcare Ltd. © Copyright 1997, 2004 by Current Medicine

Which of the following do these lesions most likely represent?

- A. Areas of local vascular growth (1%)
- B. Foci of granulomatous inflammation (1%)
- C. Immune complex-mediated vascular lesions (20%)
- ✓ D. Microemboli to skin vessels (74%)
- E. Primary infection foci (2%)

Omitted
Correct answer

74%
Answered correctly

09 secs
Time Spent

04/04/2020
Last Updated

Vascular & immunologic manifestations of infective endocarditis	
Vascular phenomena	• Systemic emboli (cerebral, pulmonary, or splenic infarcts) • Mycotic aneurysm • Janeway lesions – Macular, erythematous, **nontender** lesions on the palms & soles
Immunologic phenomena	• Osler nodes – **Painful**, violaceous nodules seen on the fingertips & toes • Roth spots – Edematous & hemorrhagic lesions of the retina

©UWorld

This patient's presentation (fever, dyspnea, and a new blowing holosystolic murmur best heard at the cardiac apex) is suggestive of mitral regurgitation likely due to **infective endocarditis** (IE). Patients with IE can develop several peripheral cutaneous or mucocutaneous stigmata of endocarditis including petechiae, splinter hemorrhages, Roth spots, Janeway lesions (see above Image), and Osler nodes.

Janeway lesions are nontender, macular, and erythematous lesions typically located on the palms and soles. They are the result of septic embolization from valvular vegetations and are composed of bacteria, neutrophils (microabscesses), necrotic material, and subcutaneous hemorrhage.

(Choice A) A neoplastic proliferation of cells of vascular origin (eg, Kaposi sarcoma) cannot be ruled out based on the appearance of this patient's skin lesions alone. However, the overall clinical presentation is highly suggestive of bacterial endocarditis as the unifying diagnosis.

(Choice B) Granulomatous inflammation can produce cutaneous lesions in miliary tuberculosis, sarcoidosis, and leprosy. However, the lesions do not localize preferentially to the soles of the feet.

(Choice C) Osler nodes are tender, violaceous nodules typically located in the pulp of fingers and toes. The pathogenesis of Osler nodes is immune-complex deposition in the skin.

1
2
3
4
5
6
7
8
9
10
11
12
13
14
15
16
17
18
19
20
21
22
23

	• Roth spots – Edematous & hemorrhagic lesions of the retina

©UWorld

This patient's presentation (fever, dyspnea, and a new blowing holosystolic murmur best heard at the cardiac apex) is suggestive of mitral regurgitation likely due to **infective endocarditis** (IE). Patients with IE can develop several peripheral cutaneous or mucocutaneous stigmata of endocarditis including petechiae, splinter hemorrhages, Roth spots, Janeway lesions (see above Image), and Osler nodes.

Janeway lesions are nontender, macular, and erythematous lesions typically located on the palms and soles. They are the result of septic embolization from valvular vegetations and are composed of bacteria, neutrophils (microabscesses), necrotic material, and subcutaneous hemorrhage.

(Choice A) A neoplastic proliferation of cells of vascular origin (eg, Kaposi sarcoma) cannot be ruled out based on the appearance of this patient's skin lesions alone. However, the overall clinical presentation is highly suggestive of bacterial endocarditis as the unifying diagnosis.

(Choice B) Granulomatous inflammation can produce cutaneous lesions in miliary tuberculosis, sarcoidosis, and leprosy. However, the lesions do not localize preferentially to the soles of the feet.

(Choice C) Osler nodes are tender, violaceous nodules typically located in the pulp of fingers and toes. The pathogenesis of Osler nodes is immune-complex deposition in the skin.

(Choice E) The lesions on the sole of the foot could represent primary foci of infection as might occur following focal skin abrasions/puncture or from sporotrichosis after walking barefoot. However, this patient's symptoms are most suggestive of mitral valve IE.

Educational objective:
Janeway lesions are nontender, macular, and erythematous lesions typically located on the palms and soles of patients with acute infective endocarditis and are the result of septic embolization from valvular vegetations.

Pathology	Cardiovascular System	Endocarditis
Subject	System	Topic

Copyright © UWorld. All rights reserved.

1
2
3
4
5
6
7
8
9
10
11
12
13
14
15
16
17
18
19
20
21
22
23

- Roth spots – Edematous & hemorrhagic lesions of the retina

Exhibit Display

Zoom In | Zoom Out | Reset | Add To New Card | Existing Card

1
2
3
4
5
6
7
8
9
10
11
12
13
14
15
16
17
18
19
20
21
22
23

A group of forensic pathologists are analyzing tissue samples of adolescents age 13-18 to study the aging process. Autopsy of a 14-year-old boy who died in a motor vehicle accident shows several minimally raised yellow spots on the inner surface of the abdominal aorta. The rest of the cardiovascular findings during the autopsy are unremarkable. He had no known medical problems. There was no family history of cardiovascular disease or sudden cardiac death. Which of the following is most likely to be the predominant cell type in these lesions on light microscopy?

A. Eosinophils
B. Fibroblasts
C. Macrophages
D. Mast cells
E. Neutrophils

Submit

A group of forensic pathologists are analyzing tissue samples of adolescents age 13-18 to study the aging process. Autopsy of a 14-year-old boy who died in a motor vehicle accident shows several minimally raised yellow spots on the inner surface of the abdominal aorta. The rest of the cardiovascular findings during the autopsy are unremarkable. He had no known medical problems. There was no family history of cardiovascular disease or sudden cardiac death. Which of the following is most likely to be the predominant cell type in these lesions on light microscopy?

- A. Eosinophils (0%)
- B. Fibroblasts (13%)
- ✓ C. Macrophages (80%)
- D. Mast cells (0%)
- E. Neutrophils (5%)

Omitted
Correct answer
C

80%
Answered correctly

03 secs
Time Spent

06/27/2020
Last Updated

Explanation

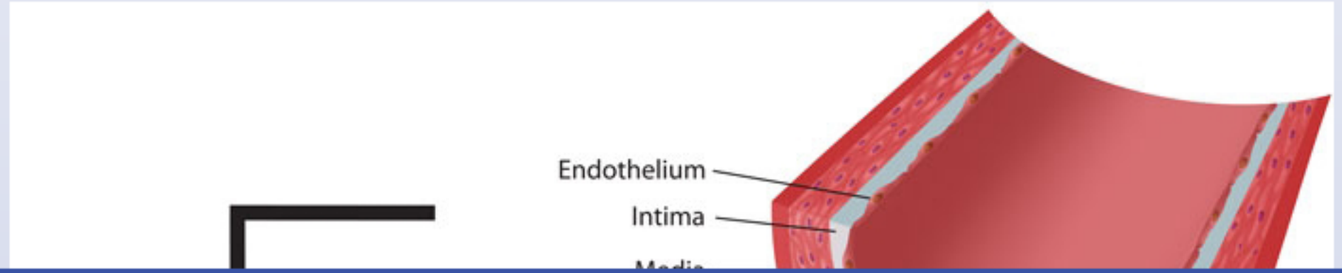

1
2
3
4
5
6
7
8
9
10
11
12
13
14
15
16
17
18
19
20
21
22
23

Exhibit Display

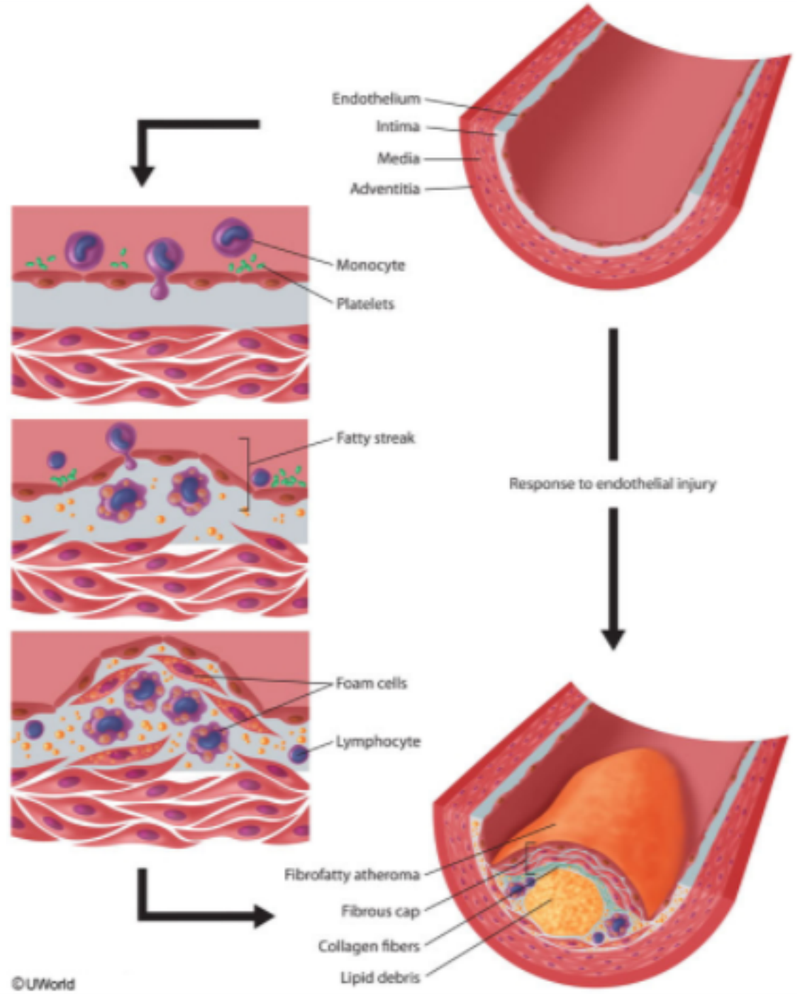

Zoom In | Zoom Out | Reset | Add To New Card | Existing Card

Foam cells



The lesions described during autopsy on the inner surface of the abdominal aorta are consistent with **fatty streaks**. These are the earliest lesions in the progression to atherosclerosis and can be seen as early as the second decade of life. Atherosclerosis is a pathophysiologic process that begins in childhood with the development of focal intimal thickening and lipid accumulation. It progresses in the following sequence:

- **Endothelial injury/dysfunction** causing increased vascular permeability and enhanced leukocyte adhesion
- Accumulation of lipoproteins (LDL) within the vessel wall
- **Monocyte adhesion** to the endothelium, followed by migration and transformation into lipid-laden **macrophages (foam cells)**
- Release of growth factors by adherent platelets, activated macrophages, and endothelial cells
- Recruitment of T cells and **smooth muscle cell proliferation**, which lead to extracellular matrix production

With advancing age, the chronic inflammatory process initiated by endothelial injury transitions from fatty streaks within the intima (composed mainly of lipid-laden foam cells) into atherosclerotic plaques, such as fibrous cap atheromas and fibrous plaques.

(Choices A, B, D, and E) Eosinophils, fibroblasts, mast cells, and neutrophils are not the predominant cell types found in fatty streaks.

Educational objective:
Fatty streaks are the earliest lesions of atherosclerosis and can be seen as early as the second decade of life. They appear as a collection of lipid-laden macrophages (foam cells) in the intima that can eventually progress to atherosclerotic plaques.

References

- Pathogenesis of atherosclerosis.

Pathology	Cardiovascular System	Atherosclerosis
Subject	System	Topic

Copyright © UWorld. All rights reserved.

A 68-year-old man comes to the office due to exertional shortness of breath and fatigue, which have progressed over the past year. The patient has a history of hypertension, but medical history is otherwise unremarkable. He is a lifetime nonsmoker. His father died of a "heart attack" at age 70. Blood pressure is 144/74 mm Hg, and pulse is 72/min and regular. Cardiac auscultation reveals a 3/6 ejection-type, late-peaking systolic murmur and a barely audible S2. The murmur diminishes in intensity during the straining phase of the Valsalva maneuver. Which of the following processes underlies this patient's current condition?

- A. Cardiomyocyte hypertrophy and disarray causing asymmetric septal thickening
- B. Differentiation of valve fibroblasts into osteoblast-like cells
- C. Myxomatous valve thickening and elastin fragmentation
- D. Subendocardial granulomatous lesions with fibrinoid necrosis and subsequent fibrosis
- E. Thrombus formation on inflamed valvular endothelium

Submit

A 68-year-old man comes to the office due to exertional shortness of breath and fatigue, which have progressed over the past year. The patient has a history of hypertension, but medical history is otherwise unremarkable. He is a lifetime nonsmoker. His father died of a "heart attack" at age 70. Blood pressure is 144/74 mm Hg, and pulse is 72/min and regular. Cardiac auscultation reveals a 3/6 ejection-type, late-peaking systolic murmur and a barely audible S2. The murmur diminishes in intensity during the straining phase of the Valsalva maneuver. Which of the following processes underlies this patient's current condition?

- A. Cardiomyocyte hypertrophy and disarray causing asymmetric septal thickening (27%)
- ✓ B. Differentiation of valve fibroblasts into osteoblast-like cells (23%)
- C. Myxomatous valve thickening and elastin fragmentation (35%)
- D. Subendocardial granulomatous lesions with fibrinoid necrosis and subsequent fibrosis (7%)
- E. Thrombus formation on inflamed valvular endothelium (5%)

Omitted
Correct answer
B

23%
Answered correctly

03 secs
Time Spent

04/15/2020
Last Updated

Explanation

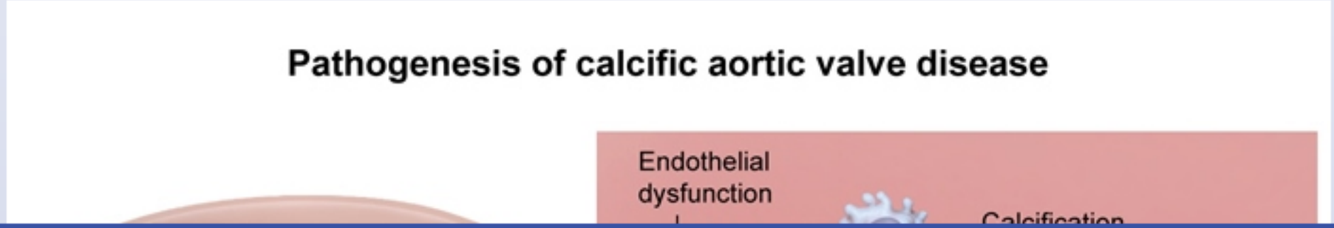

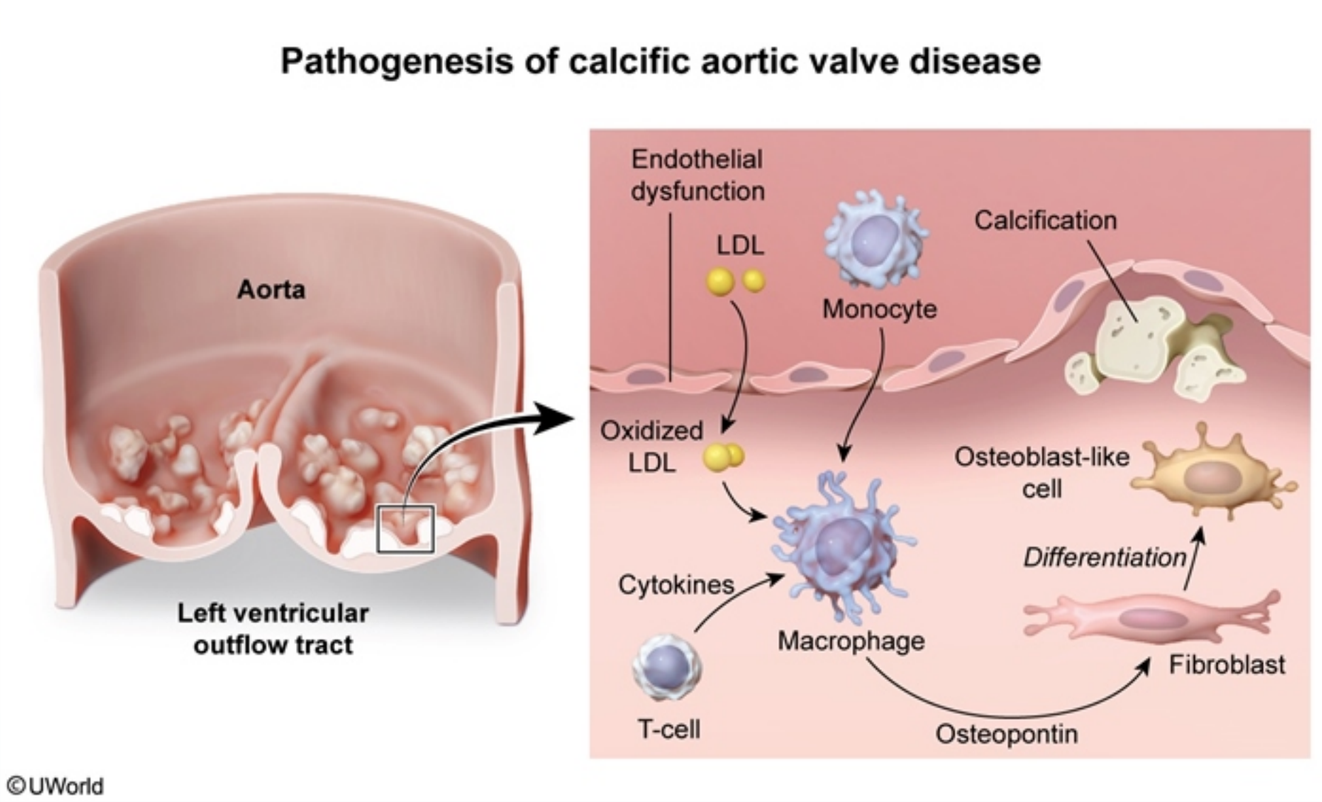

This patient's soft S2 and late-peaking systolic ejection murmur that decreases in intensity with maneuvers that decrease left ventricular blood volume (eg, abrupt standing, Valsalva straining phase) are consistent with **aortic stenosis**, which most commonly occurs due to age-related **calcific aortic valve disease** (CAVD).

The early pathogenesis of CAVD is analogous to that of **arterial atherosclerosis**. The endothelium lining the aortic side of the aortic valve cusps is exposed to the same high pressure and turbulent blood flow as the aortic vascular endothelium. As occurs with atheroma development in the vascular endothelium, these mechanical forces (along with smoking, hyperglycemia, and hyperlipidemia) over time cause damage to the **aortic valve cusp endothelium**, triggering **endothelial dysfunction** and the onset of a similar atherosclerotic process. There is subendothelial lipid deposition and infiltration of inflammatory cells (ie, macrophages, T lymphocytes) followed by the release of inflammatory mediators (eg,

©UWorld

This patient's soft S2 and late-peaking systolic ejection murmur that decreases in intensity with maneuvers that decrease left ventricular blood volume (eg, abrupt standing, Valsalva straining phase) are consistent with **aortic stenosis**, which most commonly occurs due to age-related **calcific aortic valve disease** (CAVD).

The early pathogenesis of CAVD is analogous to that of **arterial atherosclerosis**. The endothelium lining the aortic side of the aortic valve cusps is exposed to the same high pressure and turbulent blood flow as the aortic vascular endothelium. As occurs with atheroma development in the vascular endothelium, these mechanical forces (along with smoking, hyperglycemia, and hyperlipidemia) over time cause damage to the **aortic valve cusp endothelium**, triggering **endothelial dysfunction** and the onset of a similar atherosclerotic process. There is subendothelial lipid deposition and infiltration of inflammatory cells (ie, macrophages, T lymphocytes) followed by the release of inflammatory mediators (eg, interleukin-1-beta, transforming growth factor beta-1).

Subsequently, there is increased production of proteins involved in tissue calcification (eg, osteopontin). Fibroblasts differentiate into **osteoblast-like cells**, leading to aberrant bone matrix deposition with **progressive valvular calcification** and stenosis.

(Choice A) Cardiomyocyte hypertrophy and disarray with asymmetric septal thickening occurs in hypertrophic cardiomyopathy. As with aortic stenosis, patients have a harsh crescendo-decrescendo systolic murmur; however, the murmur increases (rather than decreases) in intensity with maneuvers that reduce left ventricular blood volume.

(Choice C) Myxomatous valve thickening and elastin fragmentation is typically seen in mitral valve prolapse. Patients have a nonejection systolic click and a mid-to-late systolic murmur that occurs earlier in systole with decreases in left ventricular blood volume.

(Choice D) Subendocardial granulomatous lesions with fibrinoid necrosis and subsequent fibrosis are seen in patients with rheumatic heart disease. Patients with rheumatic aortic stenosis typically have mitral valve involvement as well, which would be evidenced by a murmur of mitral stenosis or regurgitation.

(Choice E) Inflammation of valvular endothelium with deposition of sterile platelet thrombi is seen in nonbacterial thrombotic endocarditis (also known as marantic, verrucous, or Libman-Sacks endocarditis). The mitral or aortic valve is typically involved, usually leading to regurgitation rather than stenosis.

Educational objective:

1
2
3
4
5
6
7
8
9
10
11
12
13
14
15
16
17
18
19
20
21
22
23

©UWorld

Exhibit Display

Formation of atheroma

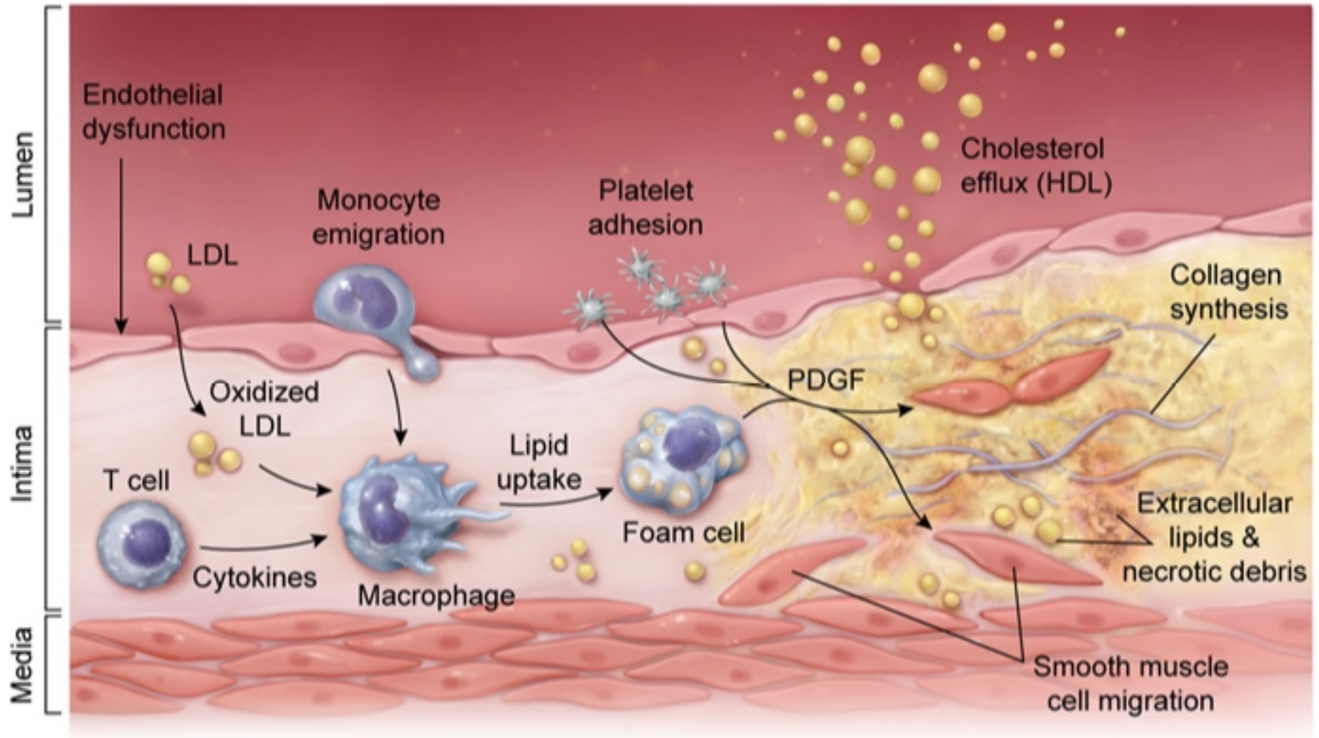

PDGF = platelet-derived growth factor.

©UWorld

Zoom In | Zoom Out | Reset | Add To New Card | Existing Card

Educational objective:

1
2
3
4
5
6
7
8
9
10
11
12
13
14
15
16
17
18
19
20
21
22
23

©UWorld

Exhibit Display

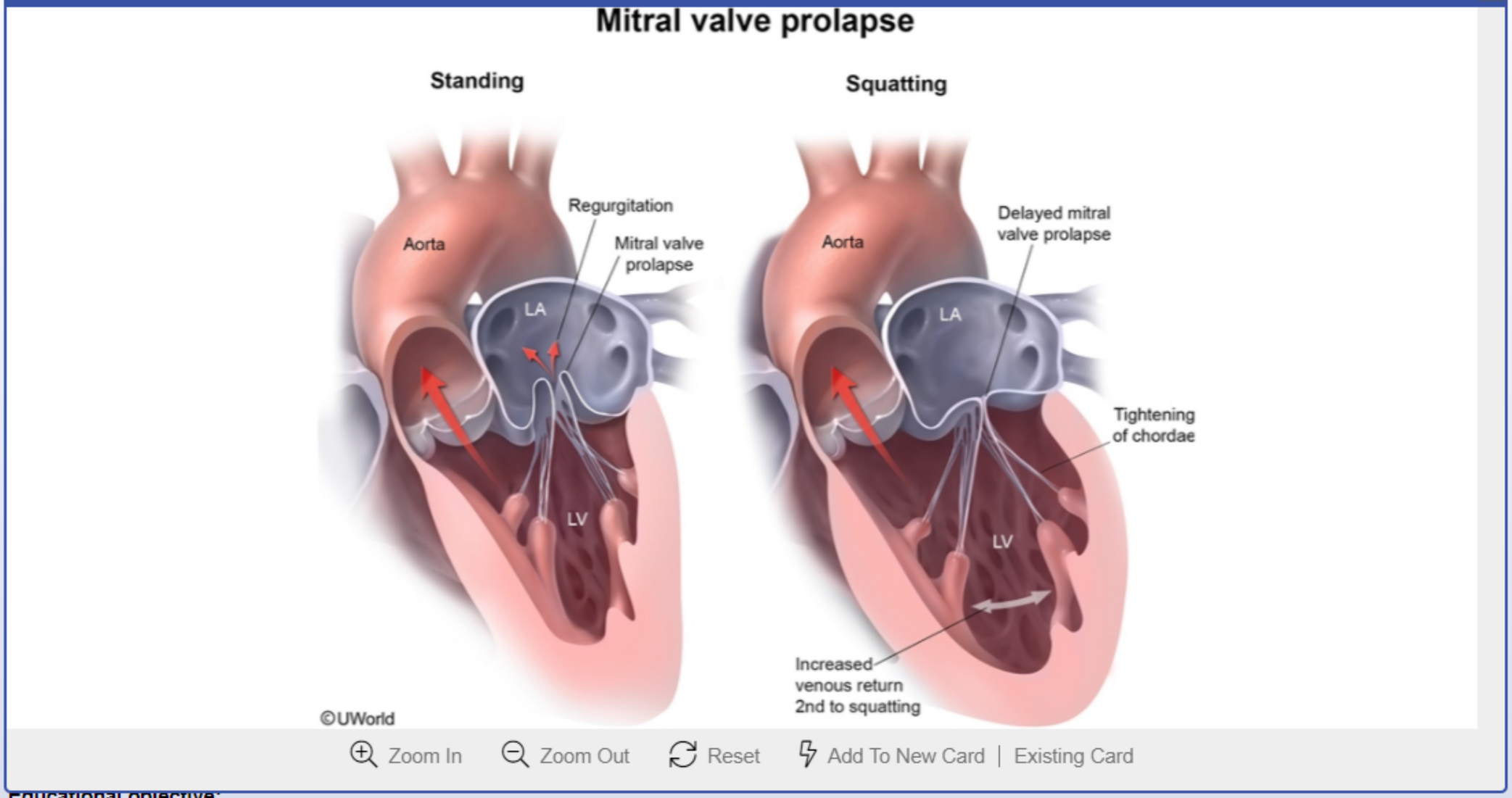

Educational objective:

A 53-year-old man comes to the physician for a follow-up visit after an acute myocardial infarction. His medications include metoprolol and low-dose aspirin. He used to smoke 2 packs of cigarettes daily but quit after his myocardial infarction. The patient's father has hypertension and his mother has type 2 diabetes mellitus. He currently weighs 100 kg (220 lb) and is 178 cm (70 in) tall. Examination shows an obese male with no other abnormalities. His total serum cholesterol level is 155 mg/dL, with an HDL level of 27 mg/dL and a triglyceride level of 92 mg/dL. Which of the following lipid-lowering agents would be most effective for preventing future cardiovascular events in this patient?

- A. Absorption inhibitor
- B. Cationic exchange resin
- C. Enzyme inhibitor
- D. Essential fatty acids
- E. Pharmacologic vitamin
- F. Transcription factor ligand

Submit

A 53-year-old man comes to the physician for a follow-up visit after an acute myocardial infarction. His medications include metoprolol and low-dose aspirin. He used to smoke 2 packs of cigarettes daily but quit after his myocardial infarction. The patient's father has hypertension and his mother has type 2 diabetes mellitus. He currently weighs 100 kg (220 lb) and is 178 cm (70 in) tall. Examination shows an obese male with no other abnormalities. His total serum cholesterol level is 155 mg/dL, with an HDL level of 27 mg/dL and a triglyceride level of 92 mg/dL. Which of the following lipid-lowering agents would be most effective for preventing future cardiovascular events in this patient?

- A. Absorption inhibitor (4%)
- B. Cationic exchange resin (2%)
- ✓ C. Enzyme inhibitor (55%)
- D. Essential fatty acids (5%)
- E. Pharmacologic vitamin (28%)
- F. Transcription factor ligand (4%)

Omitted
Correct answer
C

55%
Answered correctly

07 secs
Time Spent

01/15/2020
Last Updated

Explanation

Lipid-lowering therapy			
	LDL	HDL	Serum

Explanation

Lipid-lowering therapy

	LDL cholesterol	HDL cholesterol	Serum triglycerides
Statins (atorvastatin, rosuvastatin, simvastatin)	↓↓	↑	↓
Fibrates (fenofibrate, gemfibrozil)	↓	↑	↓↓
Bile acid sequestrants (cholestyramine, colesevelam, colestipol)	↓	-	↑
Niacin	↓	↑↑	↓
Ezetimibe	↓	-	↓
Omega-3 fatty acids	-	↑	↓
Exercise & weight loss	↓	↑	↓↓

©UWorld

Patients with **low high-density lipoprotein (HDL) levels** (men <40 mg/dL, women <50 mg/dL) are at **increased risk for cardiovascular disease**. HDL is involved in reverse cholesterol transport; it helps to remove cholesterol from peripheral tissues and transports it to the liver for metabolism. This is accomplished through 2 different pathways. In the direct pathway, HDL delivers cholesterol esters directly to the liver via a scavenger receptor (SCARB1) on the hepatocyte cell membrane. In the indirect pathway, the cholesterol in HDL is transferred to low-density lipoprotein (LDL) and very low-density lipoprotein (VLDL) by the cholesteryl ester transfer protein.

©UWorld

Patients with **low high-density lipoprotein (HDL) levels** (men <40 mg/dL, women <50 mg/dL) are at **increased risk for cardiovascular disease**. HDL is involved in reverse cholesterol transport; it helps to remove cholesterol from peripheral tissues and transports it to the liver for metabolism. This is accomplished through 2 different pathways. In the direct pathway, HDL delivers cholesterol esters directly to the liver via a scavenger receptor (SCARB1) on the hepatocyte cell membrane. In the indirect pathway, the cholesterol in HDL is transferred to low-density lipoprotein (LDL) and very low-density lipoprotein (VLDL) by the cholesteryl ester transfer protein.

Nonpharmacologic measures such as exercise, weight loss, and smoking cessation help to raise HDL levels and have significant cardiovascular benefits. In contrast, use of medications to raise HDL levels does **not** improve cardiovascular outcomes. Pharmacologic treatment of patients with low HDL levels should focus on lowering LDL cholesterol with **HMG-CoA reductase inhibitors** (statins), as these are the most effective lipid-lowering drugs for preventing cardiovascular events. Statins are indicated for secondary prevention in all patients with known atherosclerotic cardiovascular disease, **regardless** of baseline lipid levels.

(Choice A) Ezetimibe inhibits cholesterol absorption from the gastrointestinal tract, but evidence for reduction in cardiovascular events is mixed, and benefits over statin monotherapy are likely minimal. It may be considered for patients who cannot take statins due to significant hepatotoxicity or myopathy, or who have very high LDL levels despite statin therapy.

(Choice B) Cationic exchange resins (eg, cholestyramine) decrease LDL cholesterol by interfering with the enterohepatic circulation of bile acids. Bile acid binding resins can significantly increase triglyceride levels in patients with pre-existing hypertriglyceridemia. In addition, cationic exchange resins have not been proven to prevent cardiac events.

(Choice D) Omega-3 essential fatty acids are sometimes used for hyperlipidemia treatment. They cause a decrease in serum triglycerides and a slight increase in HDL concentration but do not appear to significantly reduce cardiovascular events.

(Choice E) Niacin (vitamin B_3) given in pharmacologic doses is the most effective agent for raising HDL levels, but does not reduce the risk of cardiovascular events and is associated with adverse effects (eg, flushing, hyperglycemia). It is primarily used for patients who have failed other lipid-lowering drugs.

(Choice F) Fibrates activate peroxisomal proliferator-activated receptor alpha, a transcription factor that increases lipoprotein lipase activity. Fibrates decrease triglyceride levels and raise HDL levels. However, fibrates are inferior to statins for reducing cardiovascular events and are

lowering drugs for preventing cardiovascular events. Statins are indicated for secondary prevention in all patients with known atherosclerotic cardiovascular disease, **regardless** of baseline lipid levels.

(Choice A) Ezetimibe inhibits cholesterol absorption from the gastrointestinal tract, but evidence for reduction in cardiovascular events is mixed, and benefits over statin monotherapy are likely minimal. It may be considered for patients who cannot take statins due to significant hepatotoxicity or myopathy, or who have very high LDL levels despite statin therapy.

(Choice B) Cationic exchange resins (eg, cholestyramine) decrease LDL cholesterol by interfering with the enterohepatic circulation of bile acids. Bile acid binding resins can significantly increase triglyceride levels in patients with pre-existing hypertriglyceridemia. In addition, cationic exchange resins have not been proven to prevent cardiac events.

(Choice D) Omega-3 essential fatty acids are sometimes used for hyperlipidemia treatment. They cause a decrease in serum triglycerides and a slight increase in HDL concentration but do not appear to significantly reduce cardiovascular events.

(Choice E) Niacin (vitamin B_3) given in pharmacologic doses is the most effective agent for raising HDL levels, but does not reduce the risk of cardiovascular events and is associated with adverse effects (eg, flushing, hyperglycemia). It is primarily used for patients who have failed other lipid-lowering drugs.

(Choice F) Fibrates activate peroxisomal proliferator-activated receptor alpha, a transcription factor that increases lipoprotein lipase activity. Fibrates decrease triglyceride levels and raise HDL levels. However, fibrates are inferior to statins for reducing cardiovascular events and are primarily used to prevent pancreatitis in patients with very high triglyceride levels.

Educational objective:
Although low HDL concentration is associated with increased cardiovascular risk, the use of medications to raise HDL levels does not improve cardiovascular outcomes. HMG-CoA reductase inhibitors (statins) lower total cholesterol and LDL levels. Statins are the most effective lipid-lowering drugs for primary and secondary prevention of cardiovascular events, regardless of baseline lipid levels.

References

- Beyond statins: lipid management to reduce cardiovascular risk.

Pharmacology	Cardiovascular System	Dyslipidemia
Subject	System	Topic

A 56-year-old man comes to the emergency department due to palpitations and lightheadedness over the last 2 hours. He has a history of hypertension but no other cardiac conditions and never before had similar symptoms. The patient drinks 1 to 2 alcoholic beverages daily but does not smoke cigarettes or use illicit drugs. Blood pressure is 132/76 mm Hg and pulse is 116/min and irregular. Cardiopulmonary examination is normal, except for tachycardia. Resting ECG shows atrial fibrillation. The patient undergoes transesophageal echocardiography, which reveals normal cardiac anatomy and no intracardiac thrombi. Electrical cardioversion is performed. After the intervention, sinus rhythm is restored, and amiodarone therapy is begun to maintain normal sinus rhythm. Which of the following cardiac electrophysiologic changes are most likely to occur in this patient due to the medication?

	Sinus rate	PR interval	QRS duration	QT interval
A.	Decreased	Prolonged	No change	No change
B.	Decreased	Prolonged	Prolonged	Prolonged
C.	No change	No change	No change	No change
D.	No change	No change	Prolonged	No change
E.	No change	No change	Prolonged	Prolonged

Submit

A 56-year-old man comes to the emergency department due to palpitations and lightheadedness over the last 2 hours. He has a history of hypertension but no other cardiac conditions and never before had similar symptoms. The patient drinks 1 to 2 alcoholic beverages daily but does not smoke cigarettes or use illicit drugs. Blood pressure is 132/76 mm Hg and pulse is 116/min and irregular. Cardiopulmonary examination is normal, except for tachycardia. Resting ECG shows atrial fibrillation. The patient undergoes transesophageal echocardiography, which reveals normal cardiac anatomy and no intracardiac thrombi. Electrical cardioversion is performed. After the intervention, sinus rhythm is restored, and amiodarone therapy is begun to maintain normal sinus rhythm. Which of the following cardiac electrophysiologic changes are most likely to occur in this patient due to the medication?

	Sinus rate	PR interval	QRS duration	QT interval
A.	Decreased (8%)	Prolonged	No change	No change
✓ B.	Decreased (36%)	Prolonged	Prolonged	Prolonged
C.	No change (4%)	No change	No change	No change
D.	No change (10%)	No change	Prolonged	No change
E.	No change (40%)	No change	Prolonged	Prolonged

Omitted
Correct answer
B

36%
Answered correctly

02 secs
Time Spent

06/26/2020
Last Updated

ECG effects of antiarrhythmic drugs			
	PR interval (prolonged via Ca^{2+} channel inhibition or sympathetic blockade)	**QRS duration** (prolonged via Na^{+} channel inhibition)	**QT interval** (prolonged via K^{+} channel inhibition)
Class IA (eg, procainamide)	–	↑	↑
Class IB (eg, lidocaine)	–	–	–
Class IC (eg, flecainide)	–	↑	–
Class II (eg, metoprolol)	↑	–	–
Amiodarone	↑	↑	↑
Sotalol	↑	–	↑
Other class III (eg, dofetilide)	–	–	↑
Class IV (eg, verapamil)	↑	–	–

Amiodarone is a commonly used antiarrhythmic drug with wide-ranging antiarrhythmic effects and corresponding ECG manifestations. It primarily functions as a **class III antiarrhythmic** by **inhibiting** the rapid component of the delayed rectifier **potassium current**, which is responsible for ventricular repolarization. This prolongs action potential duration and the effective refractory period, suppressing electrical foci that stimulate atrial and ventricular arrhythmias. It also **prolongs the QT interval** on ECG, which increases the risk of torsade de pointes; however, compared to

Amiodarone is a commonly used antiarrhythmic drug with wide-ranging antiarrhythmic effects and corresponding ECG manifestations. It primarily functions as a **class III antiarrhythmic** by **inhibiting** the rapid component of the delayed rectifier **potassium current**, which is responsible for ventricular repolarization. This prolongs action potential duration and the effective refractory period, suppressing electrical foci that stimulate atrial and ventricular arrhythmias. It also **prolongs the QT interval** on ECG, which increases the risk of torsade de pointes; however, compared to other class III antiarrhythmics (eg, dofetilide, ibutilide), the risk of torsade de pointes with amiodarone is low.

Amiodarone also has the following effects:

- Class I effect: Amiodarone somewhat **inhibits** the **fast sodium channels** responsible for cardiomyocyte depolarization (phase 0). This slows ventricular depolarization to suppress arrhythmogenic foci, and it **prolongs QRS complex duration** on ECG.
- Class II and IV effects: Amiodarone has beta-blocking properties that inhibit sympathetic stimulation of the conduction system. The drug also **inhibits** the **slow L-type calcium channels** responsible for depolarization of the sinus node and atrioventricular node. Both effects prolong the refractory period of the conduction system to suppress arrhythmogenic foci and in doing so contribute to a **decreased sinus rate** (ie, slowed heart rate) and a **prolonged PR interval** on ECG.

(Choice A) Both class II (ie, beta blockers) and class IV (ie, nondihydropyridine calcium channel blockers) antiarrhythmics slow the sinus rate and prolong the PR interval, but have no effect on QRS duration or the QT interval.

(Choices C, D, and E) Class I antiarrhythmics inhibit fast sodium channels to slow depolarization and prolong QRS duration. However, the effects of class IB antiarrhythmics (eg, lidocaine) occur only at rapid heart rates, and no change in QRS duration is seen on resting ECG. Class IA antiarrhythmics (eg, procainamide) also inhibit the delayed rectifier potassium current to prolong the QT interval.

Educational objective:
Amiodarone primarily functions as a class III antiarrhythmic, inhibiting the delayed rectifier potassium current to slow ventricular repolarization and prolong the QT interval. It also inhibits fast sodium channels (class I effect) to slow ventricular depolarization and prolong QRS complex duration. Beta blockade (class II effect) and inhibition of slow L-type calcium channels (class IV effect) slow conduction in the sinus node and atrioventricular node causing decreased sinus rate and a prolonged PR interval.

Pharmacology	Cardiovascular System	Antiarrhythmic drugs
Subject	System	Topic

A 60-year-old man comes to the emergency department with dizziness and palpitations. He woke up this morning with an intermittent pounding sensation in his chest. The patient has occasionally experienced a similar sensation in the past and did not think it was serious. Later, while mowing the lawn, he became lightheaded and had to sit down to avoid passing out. After receiving the appropriate workup, the patient is diagnosed with a cardiac arrhythmia and started on a medication known to prolong the QT interval. However, the drug is associated with a lower incidence of torsade de pointes than other QT-prolonging agents. Which of the following medications was most likely used in this patient?

- A. Adenosine
- B. Amiodarone
- C. Digoxin
- D. Esmolol
- E. Lidocaine
- F. Procainamide
- G. Verapamil

Submit

A 60-year-old man comes to the emergency department with dizziness and palpitations. He woke up this morning with an intermittent pounding sensation in his chest. The patient has occasionally experienced a similar sensation in the past and did not think it was serious. Later, while mowing the lawn, he became lightheaded and had to sit down to avoid passing out. After receiving the appropriate workup, the patient is diagnosed with a cardiac arrhythmia and started on a medication known to prolong the QT interval. However, the drug is associated with a lower incidence of torsade de pointes than other QT-prolonging agents. Which of the following medications was most likely used in this patient?

- A. Adenosine (5%)
- ✓ B. Amiodarone (48%)
- C. Digoxin (3%)
- D. Esmolol (5%)
- E. Lidocaine (7%)
- F. Procainamide (20%)
- G. Verapamil (7%)

Omitted
Correct answer
B

48%
Answered correctly

02 secs
Time Spent

03/26/2020
Last Updated

Explanation

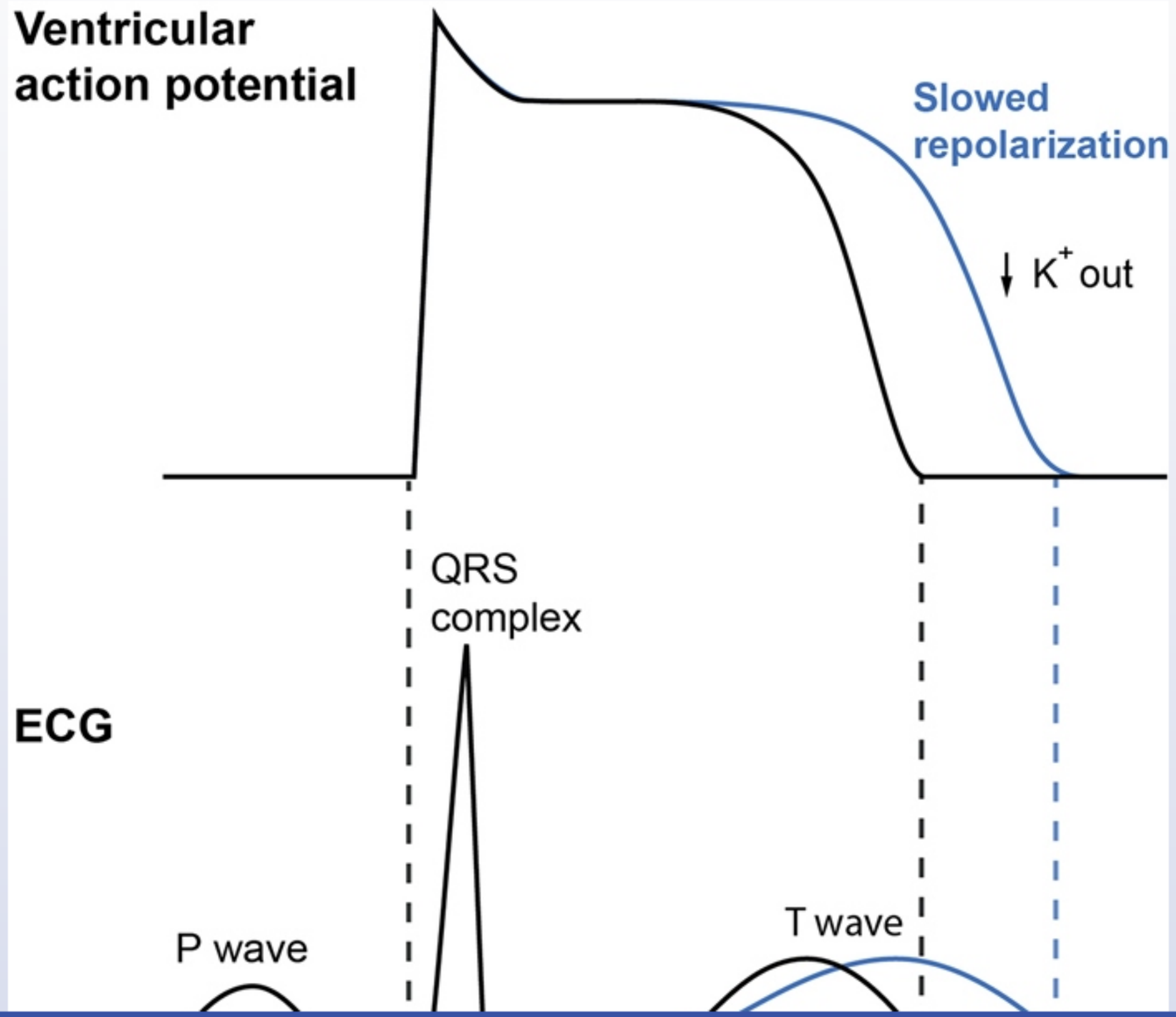
Ventricular action potential
Slowed repolarization
↓ K+ out
QRS complex
ECG
P wave
T wave

1
2
3
4
5
6
7
8
9
10
11
12
13
14
15
16
17
18
19
20
21
22
23
24
25
26
27
28
29
30
31

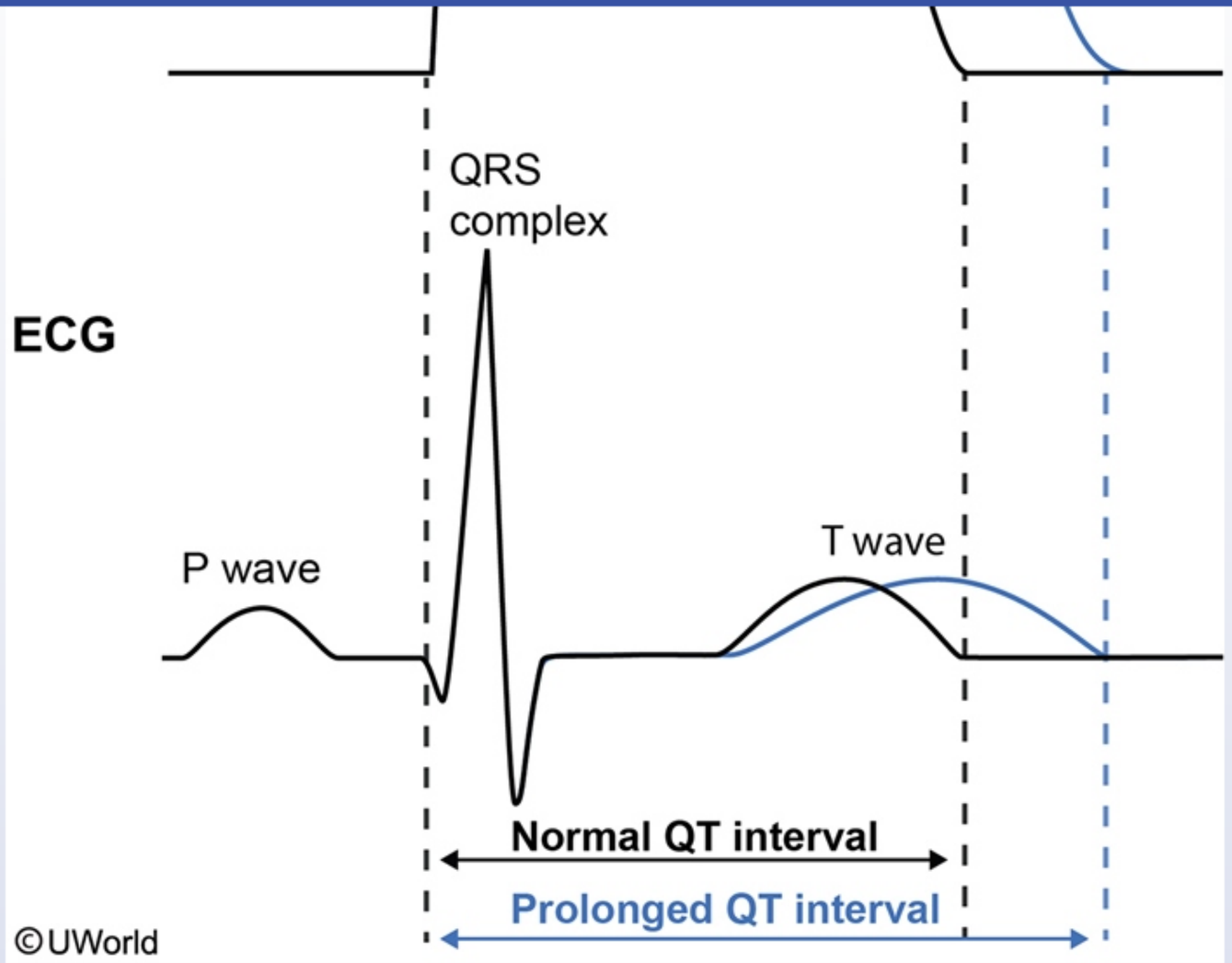

Amiodarone is a class III antiarrhythmic drug used for the management of a variety of supraventricular and ventricular arrhythmias. Class III drugs predominantly block **potassium channels** and inhibit the outward potassium currents during phase 3 of the cardiac action potential, prolonging repolarization and total action potential duration (APD).

Amiodarone is a class III antiarrhythmic drug used for the management of a variety of supraventricular and ventricular arrhythmias. Class III drugs predominantly block **potassium channels** and inhibit the outward potassium currents during phase 3 of the cardiac action potential, prolonging repolarization and total action potential duration (APD).

The **QT interval** represents the time required for ventricular depolarization and repolarization; it can be regarded as a rough estimate of the APD. Drugs that significantly prolong the cardiac action potential (eg, class IA and III antiarrhythmics) cause prolongation of the QT interval. Prolonged QT is associated with a form of ventricular tachycardia called torsades de pointes (polymorphic ventricular tachycardia). However, unlike other drugs that cause QT prolongation, amiodarone has **very little risk** of inducing torsades de pointes. This effect is thought to be due to it having a more homogeneous effect on ventricular repolarization compared to other drugs (ie, less QT dispersion).

(Choice A) Adenosine interacts with A1 receptors on cardiac cells and activates potassium channels, increasing potassium conductance. It causes a transient conduction delay through the atrioventricular (AV) node and is used for acute termination of paroxysmal supraventricular tachycardia (PSVT). Adenosine is rapidly metabolized in the blood and tissues and has a very brief duration of action.

(Choice C) Digoxin slows AV nodal conduction speed by augmenting vagal parasympathetic tone and increases cardiac contractility by inhibiting Na^+/K^+-ATPase (increases intracellular calcium). It also decreases the APD and can cause QT interval shortening.

(Choice D) Esmolol is a rapidly acting, short-duration beta blocker (class II antiarrhythmic) that slows the rate of discharge of sinus or ectopic pacemakers and increases the refractory period of the AV node. It has no effect on QT interval.

(Choice E) Lidocaine is a class IB antiarrhythmic drug that acts by blocking sodium channels and inhibiting phase 0 depolarization. It does not prolong the QT interval.

(Choice F) Procainamide is a class IA antiarrhythmic drug that inhibits sodium-dependent (phase 0) depolarization. It also has moderate potassium channel blocking activity, leading to prolongation of APD and the QT interval with an increased risk of torsades de pointes.

(Choice G) Verapamil is a cardio-selective calcium channel blocker (class IV antiarrhythmic drug). It slows the sinus rate and prolongs the PR interval by slowing conduction through the AV node. It does not prolong the QT interval.

Educational objective:
Amiodarone (and other class III and class IA antiarrhythmic agents) causes lengthening of the cardiac action potential, which manifests as QT interval prolongation on ECG. QT prolongation caused by amiodarone, in contrast to other drugs, is associated with a very low risk of torsades de pointes.

(Choice A) Adenosine interacts with A1 receptors on cardiac cells and activates potassium channels, increasing potassium conductance. It causes a transient conduction delay through the atrioventricular (AV) node and is used for acute termination of paroxysmal supraventricular tachycardia (PSVT). Adenosine is rapidly metabolized in the blood and tissues and has a very brief duration of action.

(Choice C) Digoxin slows AV nodal conduction speed by augmenting vagal parasympathetic tone and increases cardiac contractility by inhibiting Na^+/K^+-ATPase (increases intracellular calcium). It also decreases the APD and can cause QT interval shortening.

(Choice D) Esmolol is a rapidly acting, short-duration beta blocker (class II antiarrhythmic) that slows the rate of discharge of sinus or ectopic pacemakers and increases the refractory period of the AV node. It has no effect on QT interval.

(Choice E) Lidocaine is a class IB antiarrhythmic drug that acts by blocking sodium channels and inhibiting phase 0 depolarization. It does not prolong the QT interval.

(Choice F) Procainamide is a class IA antiarrhythmic drug that inhibits sodium-dependent (phase 0) depolarization. It also has moderate potassium channel blocking activity, leading to prolongation of APD and the QT interval with an increased risk of torsades de pointes.

(Choice G) Verapamil is a cardio-selective calcium channel blocker (class IV antiarrhythmic drug). It slows the sinus rate and prolongs the PR interval by slowing conduction through the AV node. It does not prolong the QT interval.

Educational objective:
Amiodarone (and other class III and class IA antiarrhythmic agents) causes lengthening of the cardiac action potential, which manifests as QT interval prolongation on ECG. QT prolongation caused by amiodarone, in contrast to other drugs, is associated with a very low risk of torsades de pointes.

References

- Chronic amiodarone evokes no torsade de pointes arrhythmias despite QT lengthening in an animal model of acquired long-QT syndrome.

Pharmacology	Cardiovascular System	Antiarrhythmic drugs
Subject	System	Topic

Copyright © UWorld. All rights reserved.

complex

Exhibit Display

Antiarrhythmic drugs – Vaughan Williams classification

Class	Drugs	Predominant actions
IA	**Sodium channel blockers** • Disopyramide • Procainamide • Quinidine	• Slows AP conduction velocity • Prolongs APD
IB	• Lidocaine • Mexiletine • Phenytoin	• No effect on AP conduction velocity • Shortens APD
IC	• Flecainide • Propafenone	• Slows AP conduction velocity • Minimal effect on APD
II	**Beta receptor blockers** • Atenolol • Metoprolol • Esmolol • Carvedilol	• Slows sinus node discharge rate • Slows AV nodal conduction & prolongs refractoriness
III	**Potassium channel blockers** • Amiodarone • Dronedarone • Dofetilide • Sotalol (also class II)	• No effect on AP conduction velocity • Prolongs APD
IV	**Non-dihydropyridine calcium channel blockers** • Verapamil • Diltiazem	• Slows sinus node discharge rate • Slows AV nodal conduction & prolongs refractoriness

AP = action potential; APD = action potential duration; AV = atrioventricular.

©UWorld

Zoom In | Zoom Out | Reset | Add To New Card | Existing Card

more homogeneous effect on ventricular repolarization compared to other drugs (ie, less QT dispersion).

1
2
3
4
5
6
7
8
9
10
11
12
13
14
15
16
17
18
19
20
21
22
23
24
25
26
27
28
29
30
31

Prolonged QT interval

Exhibit Display

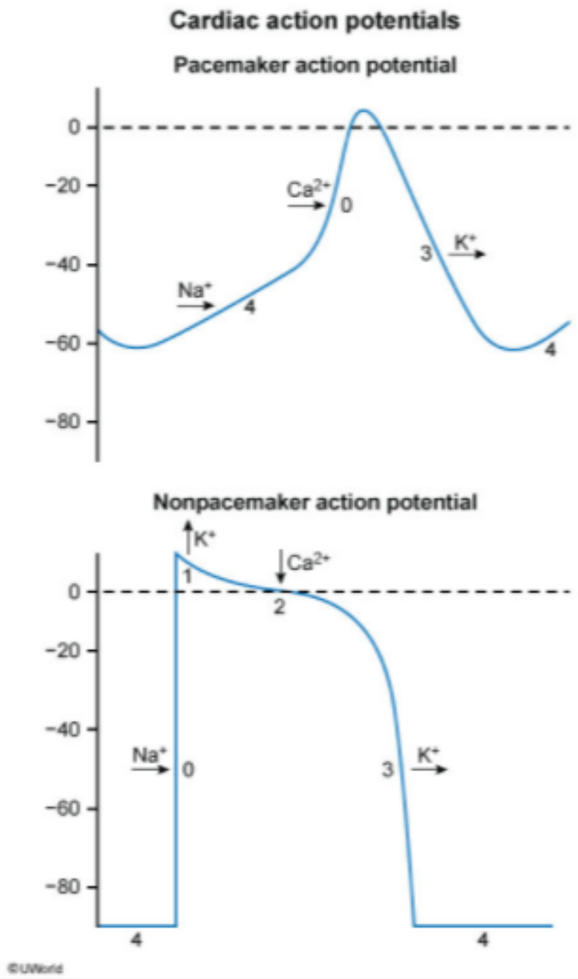

Zoom In | Zoom Out | Reset | Add To New Card | Existing Card

Amiodarone (and other class III and class IA antiarrhythmic agents) causes lengthening of the cardiac action potential, which manifests as QT

An experiment is conducted to assess the effects of drug A on the hemodynamic actions of epinephrine. Two groups of healthy volunteers are selected. The first group receives only low-dose epinephrine, and its effects on diastolic blood pressure and heart rate are monitored and shown below (epinephrine group). The second group is pretreated with drug A and then infused with low-dose epinephrine to produce a new set of curves (epinephrine + drug A group).

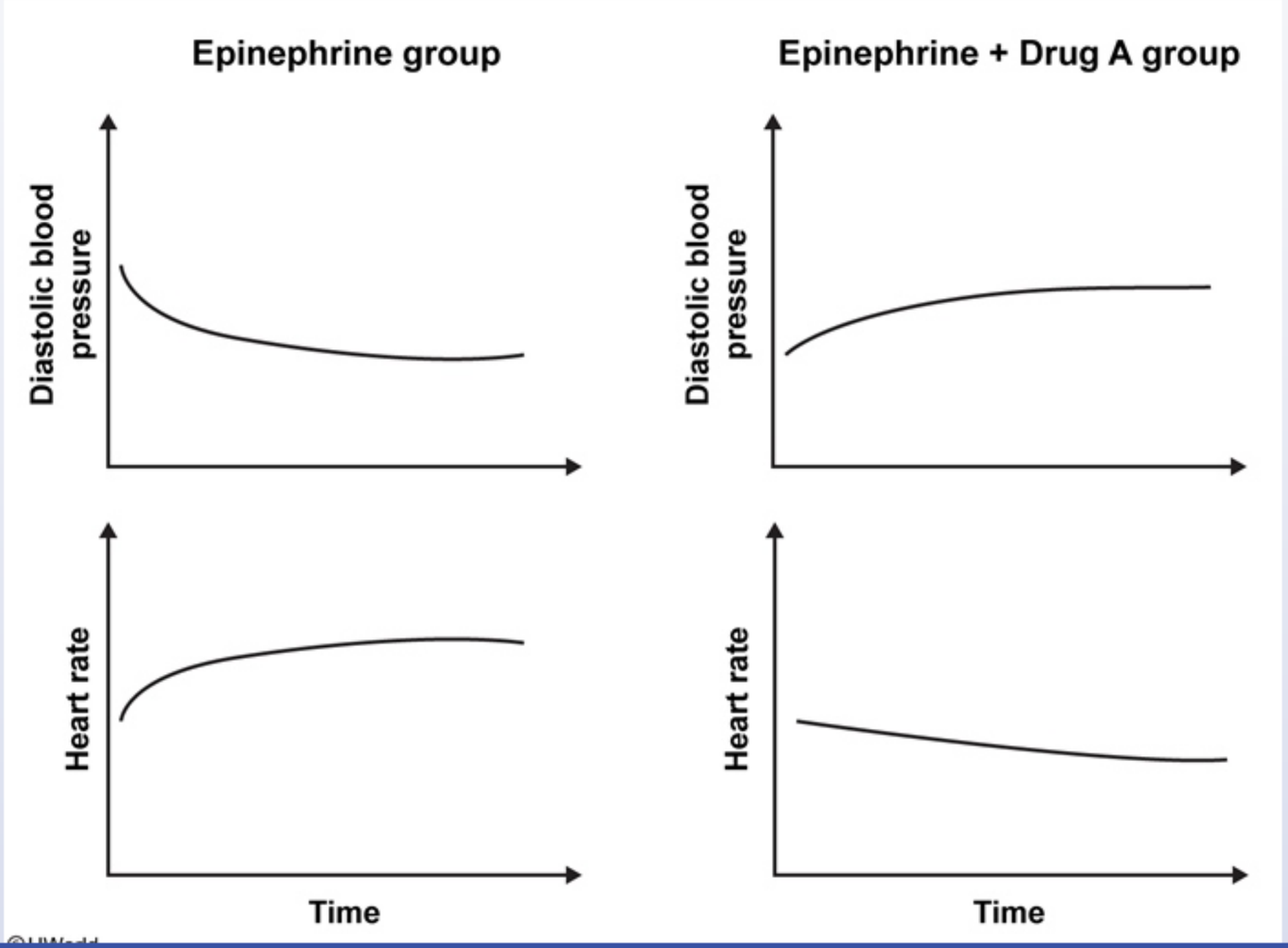

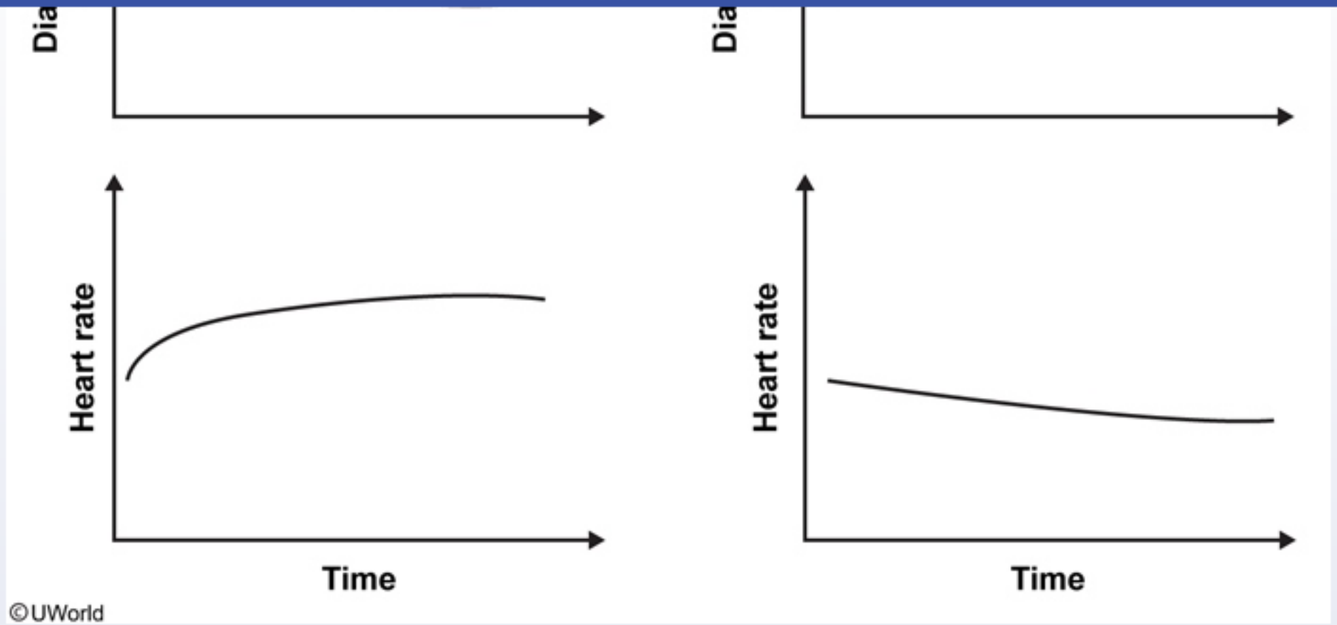

Which of the following medications is most likely to be drug A?

- A. Atropine
- B. Isoproterenol
- C. Phentolamine
- D. Phenylephrine
- E. Propranolol

Submit

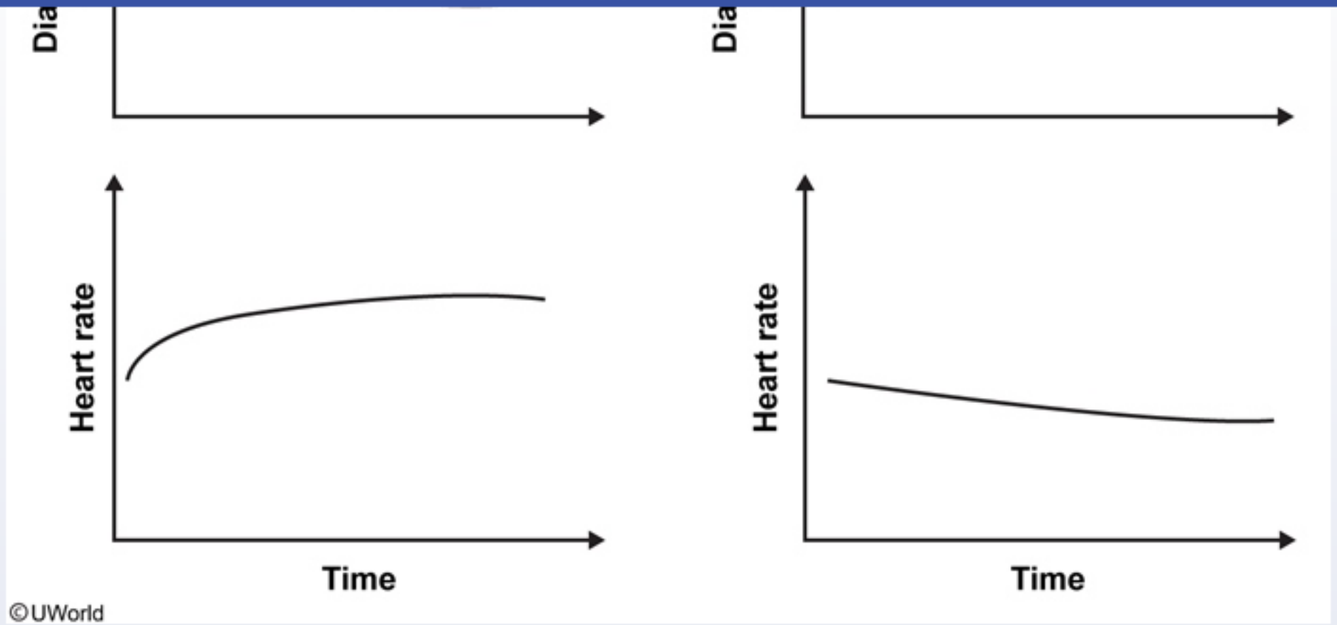

Which of the following medications is most likely to be drug A?

- A. Atropine (3%)
- B. Isoproterenol (15%)
- C. Phentolamine (11%)
- D. Phenylephrine (14%)
- ✓ E. Propranolol (55%)

Omitted
Correct answer

55%
Answered correctly

05 secs
Time Spent

06/06/2020
Last Updated

Hemodynamic actions of epinephrine		
	Effect	**Involved receptors**
Heart rate & contractility	↑	β_1
Systolic blood pressure	↑↑	$\beta_1 + \alpha_1$
Diastolic blood pressure	↓ (low-dose)	$\beta_2 > \alpha_1$
	↑ (high-dose)	$\alpha_1 > \beta_2$

The hemodynamic actions of **epinephrine** occur secondary to agonistic effects at α1, β1, and β2 adrenoreceptors (relative strength: $\boldsymbol{\beta_1 = \beta_2 > \alpha_1}$). Stimulation of β1 receptors in the heart increases cardiac rate and contractility, which increases systolic blood pressure due to the rise in cardiac output. Stimulation of β2 receptors in the skeletal muscle vasculature produces vasodilation and decreased diastolic blood pressure, while activation of α1 receptors on vascular smooth muscle in the skin and viscera increases peripheral resistance and raises diastolic blood pressure. At **low doses**, β2-mediated **vasodilation predominates**, whereas at high doses α1-induced vasoconstriction becomes more pronounced.

In this experiment, low-dose epinephrine by itself caused **increased heart rate** (β1 response) and **decreased diastolic blood pressure** (β2 response). However, after pretreatment with drug A, the heart rate *fails* to increase and there is a marked *rise* in diastolic blood pressure. These effects are best explained by pretreatment with a **nonselective beta antagonist** such as propranolol. When administered alone, propranolol produces peripheral vasoconstriction (β2 antagonism) without significantly increasing blood pressure (due to concomitant β1 blockade). However, in combination with epinephrine, propranolol will counteract epinephrine's β2-mediated vasodilation and β1-mediated heart rate increase while leaving the α1 effect (vasoconstriction) intact. This will increase diastolic blood pressure and cause a slight reflexive reduction in heart rate.

(Choice A) Atropine is a competitive antagonist of cholinergic muscarinic receptors in the heart (M_2). Atropine increases the heart rate by blocking parasympathetic vagal influence; after pretreatment with atropine, epinephrine-mediated tachycardia would increase.

(Choice B) Isoproterenol is a nonselective β-adrenergic agonist that stimulates both β2 receptors on vascular smooth muscle (leading to vasodilatation) and cardiac β1 receptors (leading to increases in cardiac rate and contractility). A combination of isoproterenol and epinephrine

	(high-dose)	$\alpha_1 > \beta_2$

The hemodynamic actions of **epinephrine** occur secondary to agonistic effects at α1, β1, and β2 adrenoreceptors (relative strength: $\boldsymbol{\beta_1 = \beta_2 > \alpha_1}$). Stimulation of β1 receptors in the heart increases cardiac rate and contractility, which increases systolic blood pressure due to the rise in cardiac output. Stimulation of β2 receptors in the skeletal muscle vasculature produces vasodilation and decreased diastolic blood pressure, while activation of α1 receptors on vascular smooth muscle in the skin and viscera increases peripheral resistance and raises diastolic blood pressure. At **low doses**, β2-mediated **vasodilation predominates**, whereas at high doses α1-induced vasoconstriction becomes more pronounced.

In this experiment, low-dose epinephrine by itself caused **increased heart rate** (β1 response) and **decreased diastolic blood pressure** (β2 response). However, after pretreatment with drug A, the heart rate *fails* to increase and there is a marked *rise* in diastolic blood pressure. These effects are best explained by pretreatment with a **nonselective beta antagonist** such as propranolol. When administered alone, propranolol produces peripheral vasoconstriction (β2 antagonism) without significantly increasing blood pressure (due to concomitant β1 blockade). However, in combination with epinephrine, propranolol will counteract epinephrine's β2-mediated vasodilation and β1-mediated heart rate increase while leaving the α1 effect (vasoconstriction) intact. This will increase diastolic blood pressure and cause a slight reflexive reduction in heart rate.

(Choice A) Atropine is a competitive antagonist of cholinergic muscarinic receptors in the heart (M_2). Atropine increases the heart rate by blocking parasympathetic vagal influence; after pretreatment with atropine, epinephrine-mediated tachycardia would increase.

(Choice B) Isoproterenol is a nonselective β-adrenergic agonist that stimulates both β2 receptors on vascular smooth muscle (leading to vasodilatation) and cardiac β1 receptors (leading to increases in cardiac rate and contractility). A combination of isoproterenol and epinephrine would further decrease diastolic blood pressure and exacerbate the tachycardia.

(Choice C) Phentolamine is a nonspecific alpha-1 and alpha-2 blocker with no beta-blocking effects that cause a profound fall in diastolic blood pressure and reflex tachycardia. If this were drug A, blood pressure would have decreased further in the pretreatment group and the rise in heart rate would have been exacerbated.

(Choice D) Phenylephrine is a selective α-adrenergic agonist. Administration by itself may cause elevated systolic and diastolic blood pressures, which may be associated with reflex bradycardia. However, after pretreatment, epinephrine would still produce an *initial rise* in heart rate due to unopposed β1 stimulation.

Educational objective:
Epinephrine increases systolic blood pressure ($\alpha_1 + \beta_1$) and heart rate (β1), and either increases or decreases diastolic blood pressure depending

response). However, after pretreatment with drug A, the heart rate *fails* to increase and there is a marked *rise* in diastolic blood pressure. These effects are best explained by pretreatment with a **nonselective beta antagonist** such as propranolol. When administered alone, propranolol produces peripheral vasoconstriction (β2 antagonism) without significantly increasing blood pressure (due to concomitant β1 blockade). However, in combination with epinephrine, propranolol will counteract epinephrine's β2-mediated vasodilation and β1-mediated heart rate increase while leaving the α1 effect (vasoconstriction) intact. This will increase diastolic blood pressure and cause a slight reflexive reduction in heart rate.

(Choice A) Atropine is a competitive antagonist of cholinergic muscarinic receptors in the heart (M_2). Atropine increases the heart rate by blocking parasympathetic vagal influence; after pretreatment with atropine, epinephrine-mediated tachycardia would increase.

(Choice B) Isoproterenol is a nonselective β-adrenergic agonist that stimulates both β2 receptors on vascular smooth muscle (leading to vasodilatation) and cardiac β1 receptors (leading to increases in cardiac rate and contractility). A combination of isoproterenol and epinephrine would further decrease diastolic blood pressure and exacerbate the tachycardia.

(Choice C) Phentolamine is a nonspecific alpha-1 and alpha-2 blocker with no beta-blocking effects that cause a profound fall in diastolic blood pressure and reflex tachycardia. If this were drug A, blood pressure would have decreased further in the pretreatment group and the rise in heart rate would have been exacerbated.

(Choice D) Phenylephrine is a selective α-adrenergic agonist. Administration by itself may cause elevated systolic and diastolic blood pressures, which may be associated with reflex bradycardia. However, after pretreatment, epinephrine would still produce an *initial rise* in heart rate due to unopposed β1 stimulation.

Educational objective:
Epinephrine increases systolic blood pressure ($\alpha_1 + \beta_1$) and heart rate (β1), and either increases or decreases diastolic blood pressure depending on the dose (either α1 or β2 predominates). Pretreatment with propranolol eliminates the β effects of epinephrine (vasodilatation and tachycardia), leaving only the α effect (vasoconstriction).

Pharmacology	Cardiovascular System	Sympathomimetic agents
Subject	System	Topic

Copyright © UWorld. All rights reserved.

A 72-year-old man is brought to the emergency department with waxing and waning chest pressure over the past several hours. The patient says he occasionally gets a similar sensation that lasts 5-10 minutes when he walks briskly up the stairs. Medical history is significant for hypertension and hyperlipidemia; he has been nonadherent with prescribed medical therapy and follow-up visits. The patient has a 25-pack-year smoking history. Blood pressure is 211/105 mm Hg, and pulse is 88/min and regular. Chest examination reveals no heart murmurs, and the lungs are clear. ECG shows sinus rhythm and nonspecific ST-segment changes. A medication is administered intravenously and produces the following hemodynamic effects compared to baseline:

Stroke volume	unchanged
Systemic vascular resistance	decreased
Heart rate	decreased

Which of the following medications was most likely used in this patient?

- A. Hydralazine
- B. Labetalol
- C. Metoprolol
- D. Nitroprusside
- E. Phentolamine

Submit

A 72-year-old man is brought to the emergency department with waxing and waning chest pressure over the past several hours. The patient says he occasionally gets a similar sensation that lasts 5-10 minutes when he walks briskly up the stairs. Medical history is significant for hypertension and hyperlipidemia; he has been nonadherent with prescribed medical therapy and follow-up visits. The patient has a 25-pack-year smoking history. Blood pressure is 211/105 mm Hg, and pulse is 88/min and regular. Chest examination reveals no heart murmurs, and the lungs are clear. ECG shows sinus rhythm and nonspecific ST-segment changes. A medication is administered intravenously and produces the following hemodynamic effects compared to baseline:

Stroke volume	unchanged
Systemic vascular resistance	decreased
Heart rate	decreased

Which of the following medications was most likely used in this patient?

A. Hydralazine (11%)
✓ B. Labetalol (59%)
C. Metoprolol (9%)
D. Nitroprusside (14%)
E. Phentolamine (4%)

Omitted
Correct answer
B

59%
Answered correctly

01 sec
Time Spent

06/15/2020
Last Updated

Explanation

Systolic blood pressure **≥180 mm Hg** (or diastolic pressure ≥120 mm Hg) along with evidence of associated end-organ damage (eg, chest pressure, ST-segment changes on ECG) constitutes a **hypertensive emergency**. This patient likely has underlying coronary artery disease and is experiencing myocardial ischemia due to increased myocardial oxygen demand caused by markedly elevated blood pressure and increased left ventricular afterload.

Management of hypertensive emergency involves prompt and controlled blood pressure reduction to reduce the risk of complications (eg, stroke, aortic dissection, myocardial infarction). **Labetalol** is a **nonselective vasodilatory beta blocker** that blocks beta-1, beta-2, and alpha-1 adrenergic receptors and reduces blood pressure. The **alpha-1 receptor blockade** outweighs beta-2 receptor blockade in vascular smooth muscle to cause **peripheral vasodilation** of both venules and arterioles. Venular vasodilation decreases venous return and arteriolar vasodilation **decreases systemic vascular resistance** (SVR); because the vasodilation is relatively balanced, blood pressure is reduced with **stroke volume unchanged**. Normally, reduced blood pressure stimulates a baroreceptor reflex-mediated increase in heart rate, but the strong beta-1 receptor blockade of labetalol overrides this response, causing overall **decreased heart rate**.

(Choices A, D, and E) Hydralazine is an arterial vasodilator that has little effect on veins. Nitroprusside is a nitric oxide donor that causes balanced arterial and venous vasodilation. Phentolamine is a nonselective alpha receptor blocker that also causes balanced vasodilation. All these drugs reduce blood pressure primarily via a reduction in SVR, but they have no negative chronotropic effects and are associated with a baroreceptor reflex-mediated increase in heart rate. Stroke volume is increased with hydralazine, and unchanged with the balanced vasodilation that occurs with nitroprusside and phentolamine.

(Choice C) Metoprolol is a cardioselective beta blocker that primarily blocks beta-1 receptors; it causes slight blockade of beta-2 receptors and has no effect on alpha receptors. Metoprolol causes no significant change in SVR but facilitates a mild reduction in blood pressure due to a decrease in contractility and heart rate that reduces stroke volume and cardiac output.

Educational objective:
Labetalol is a nonselective vasodilatory beta blocker that blocks beta-1, beta-2, and alpha-1 adrenergic receptors. Alpha-1 receptor blockade outweighs beta-2 receptor blockade to cause peripheral vasodilation with decreased venous return and lower systemic vascular resistance. The relatively balanced vasodilation reduces blood pressure without changing stroke volume. Beta-1 receptor blockade overrides the expected baroreflex-mediated increase in heart rate, resulting in overall decreased heart rate.

ventricular afterload.

Management of hypertensive emergency involves prompt and controlled blood pressure reduction to reduce the risk of complications (eg, stroke, aortic dissection, myocardial infarction). **Labetalol** is a **nonselective vasodilatory beta blocker** that blocks beta-1, beta-2, and alpha-1 adrenergic receptors and reduces blood pressure. The **alpha-1 receptor blockade** outweighs beta-2 receptor blockade in vascular smooth muscle to cause **peripheral vasodilation** of both venules and arterioles. Venular vasodilation decreases venous return and arteriolar vasodilation **decreases systemic vascular resistance** (SVR); because the vasodilation is relatively balanced, blood pressure is reduced with **stroke volume unchanged**. Normally, reduced blood pressure stimulates a baroreceptor reflex-mediated increase in heart rate, but the strong beta-1 receptor blockade of labetalol overrides this response, causing overall **decreased heart rate**.

(Choices A, D, and E) Hydralazine is an arterial vasodilator that has little effect on veins. Nitroprusside is a nitric oxide donor that causes balanced arterial and venous vasodilation. Phentolamine is a nonselective alpha receptor blocker that also causes balanced vasodilation. All these drugs reduce blood pressure primarily via a reduction in SVR, but they have no negative chronotropic effects and are associated with a baroreceptor reflex-mediated increase in heart rate. Stroke volume is increased with hydralazine, and unchanged with the balanced vasodilation that occurs with nitroprusside and phentolamine.

(Choice C) Metoprolol is a cardioselective beta blocker that primarily blocks beta-1 receptors; it causes slight blockade of beta-2 receptors and has no effect on alpha receptors. Metoprolol causes no significant change in SVR but facilitates a mild reduction in blood pressure due to a decrease in contractility and heart rate that reduces stroke volume and cardiac output.

Educational objective:
Labetalol is a nonselective vasodilatory beta blocker that blocks beta-1, beta-2, and alpha-1 adrenergic receptors. Alpha-1 receptor blockade outweighs beta-2 receptor blockade to cause peripheral vasodilation with decreased venous return and lower systemic vascular resistance. The relatively balanced vasodilation reduces blood pressure without changing stroke volume. Beta-1 receptor blockade overrides the expected baroreflex-mediated increase in heart rate, resulting in overall decreased heart rate.

Pharmacology	Cardiovascular System	Malignant hypertension
Subject	System	Topic

Copyright © UWorld. All rights reserved.

B. Labetalol (59%)
C. Metoprolol (9%)
D. Nitroprusside
E. Phentolamin

Omitted
Correct answer
B

Explanation

Systolic blood pressure ≥1
pressure, ST-segment cha
is experiencing myocardia
ventricular afterload.

Management of hypertens
aortic dissection, myocard
adrenergic receptors and
muscle to cause **peripher**
decreases systemic vas
unchanged. Normally, re
blockade of labetalol over

(Choices A, D, and E) Hydralazine is an arterial vasodilator that has little effect on veins. Nitroprusside is a nitric oxide donor that causes balanced arterial and venous vasodilation. Phentolamine is a nonselective alpha receptor blocker that also causes balanced vasodilation. All

Exhibit Display

Hypertensive crisis	
Hypertensive urgency	• Severe hypertension (≥180/120 mm Hg) • No evidence of end-organ damage
Hypertensive emergency	• Severe hypertension with **end-organ damage**: ○ Cardiovascular: angina, myocardial infarction, aortic dissection ○ CNS: encephalopathy, cerebral infarct/hemorrhage ○ Kidney: acute hypertensive nephrosclerosis ○ Lung: pulmonary edema ○ Retina: papilledema, flame-shaped hemorrhages, exudates

Add To Flash Card

Correct answer
Answered correctly
Time Spent
Last Updated

Exhibit Display

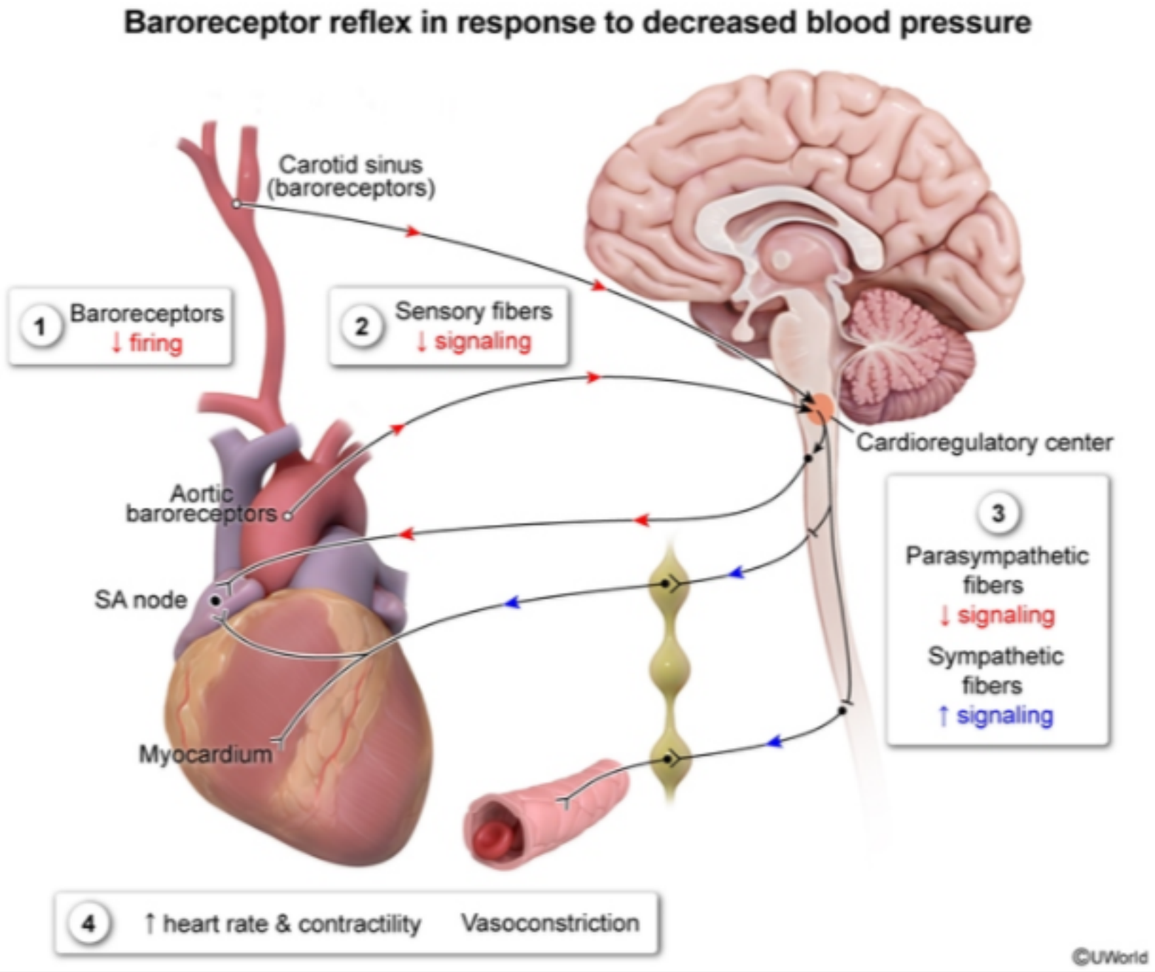

Zoom In Zoom Out Reset Add To Flash Card

Labetalol is a nonselective vasodilatory beta blocker that blocks beta-1, beta-2, and alpha-1 adrenergic receptors. Alpha-1 receptor blockade

A 65-year-old man comes to the physician after missing a follow-up appointment for congestive heart failure. He missed his appointment due to an upset stomach that will not go away. A detailed history reveals disturbed color perception, anorexia, nausea, vomiting, and diarrhea that have worsened over the past 2 weeks. His congestive heart failure has thus far been controlled effectively with multiple medications. If the cause of this patient's current symptoms is not corrected, which of the following complications is most likely to develop?

A. Angioedema
B. Arrhythmia
C. Bronchoconstriction
D. Hypotension
E. Pulmonary edema

Submit

A 65-year-old man comes to the physician after missing a follow-up appointment for congestive heart failure. He missed his appointment due to an upset stomach that will not go away. A detailed history reveals disturbed color perception, anorexia, nausea, vomiting, and diarrhea that have worsened over the past 2 weeks. His congestive heart failure has thus far been controlled effectively with multiple medications. If the cause of this patient's current symptoms is not corrected, which of the following complications is most likely to develop?

- A. Angioedema (2%)
- ✓ B. Arrhythmia (72%)
- C. Bronchoconstriction (1%)
- D. Hypotension (15%)
- E. Pulmonary edema (7%)

Omitted
Correct answer
B

72%
Answered correctly

02 secs
Time Spent

04/09/2020
Last Updated

Explanation

Symptoms of digoxin toxicity	
Cardiac	• **Life-threatening arrhythmias**
Gastrointestinal	• Anorexia • Nausea & vomiting • Abdominal pain

Symptoms of digoxin toxicity	
Cardiac	• **Life-threatening arrhythmias**
Gastrointestinal	• Anorexia • Nausea & vomiting • Abdominal pain
Neurologic	• Fatigue • Confusion • Weakness • **Color vision alterations**

This patient most likely has chronic **digoxin toxicity**, which can cause nonspecific gastrointestinal and neurologic symptoms. Although rare, **changes in color vision** are particularly associated with digoxin overdose. The most serious complication of digoxin toxicity is the development of potentially fatal **cardiac arrhythmias** of virtually any type.

Digoxin has a narrow therapeutic index, making toxicity relatively common. Precipitating causes include hypokalemia (increased digoxin binding), hypovolemia, and renal failure. Patients with severe toxicity (eg, life-threatening arrhythmias, end-organ dysfunction) are treated with anti-digoxin antibody fragments.

(Choice A) Angioedema is a severe side effect that manifests as rapidly developing edema that often affects the lips and larynx. Of the drugs used to treat heart failure, angiotensin-converting enzyme inhibitors are most commonly associated with angioedema.

(Choice C) Bronchoconstriction can be caused by nonspecific beta-adrenergic blockers (eg, propranolol) in patients with chronic obstructive pulmonary disease or asthma. Selective beta blockers (eg, metoprolol) are commonly used to treat patients with congestive heart failure and are less likely to cause bronchoconstriction.

(Choice D) Hypotension can occur with digoxin toxicity due to bradyarrhythmias and severe vomiting and diarrhea that lead to hypovolemia. However, digoxin is also an inotropic agent that causes increased cardiac output. Therefore, hypotension is a variable manifestation of digoxin toxicity.

This patient most likely has chronic **digoxin toxicity**, which can cause nonspecific gastrointestinal and neurologic symptoms. Although rare, **changes in color vision** are particularly associated with digoxin overdose. The most serious complication of digoxin toxicity is the development of potentially fatal **cardiac arrhythmias** of virtually any type.

Digoxin has a narrow therapeutic index, making toxicity relatively common. Precipitating causes include hypokalemia (increased digoxin binding), hypovolemia, and renal failure. Patients with severe toxicity (eg, life-threatening arrhythmias, end-organ dysfunction) are treated with anti-digoxin antibody fragments.

(Choice A) Angioedema is a severe side effect that manifests as rapidly developing edema that often affects the lips and larynx. Of the drugs used to treat heart failure, angiotensin-converting enzyme inhibitors are most commonly associated with angioedema.

(Choice C) Bronchoconstriction can be caused by nonspecific beta-adrenergic blockers (eg, propranolol) in patients with chronic obstructive pulmonary disease or asthma. Selective beta blockers (eg, metoprolol) are commonly used to treat patients with congestive heart failure and are less likely to cause bronchoconstriction.

(Choice D) Hypotension can occur with digoxin toxicity due to bradyarrhythmias and severe vomiting and diarrhea that lead to hypovolemia. However, digoxin is also an inotropic agent that causes increased cardiac output. Therefore, hypotension is a variable manifestation of digoxin toxicity.

(Choice E) Pulmonary edema may occur with uncontrolled heart failure due to poor forward flow that causes blood to pool in the lungs. It can be caused by both systolic and diastolic left ventricular dysfunction due to decreased forward ejection of blood and impaired ventricular filling, respectively.

Educational objective:
Digoxin toxicity presents with nonspecific gastrointestinal (eg, anorexia, nausea, vomiting) and neurologic (eg, fatigue, confusion, weakness) symptoms. Changes in color vision are a more specific, but rarer, finding. Life-threatening ventricular arrhythmias are the most serious complication.

References

- Diagnosis and treatment of digoxin toxicity.
- Digitalis toxicity: a fading but crucial complication to recognize.

Digoxin has a narrow therapeutic index, making toxicity relatively common. Precipitating causes include hypokalemia (increased digoxin binding), hypovolemia, and renal failure. Patients with severe toxicity (eg, life-threatening arrhythmias, end-organ dysfunction) are treated with anti-digoxin antibody fragments.

(Choice A) Angioedema is a severe side effect that manifests as rapidly developing edema that often affects the lips and larynx. Of the drugs used to treat heart failure, angiotensin-converting enzyme inhibitors are most commonly associated with angioedema.

(Choice C) Bronchoconstriction can be caused by nonspecific beta-adrenergic blockers (eg, propranolol) in patients with chronic obstructive pulmonary disease or asthma. Selective beta blockers (eg, metoprolol) are commonly used to treat patients with congestive heart failure and are less likely to cause bronchoconstriction.

(Choice D) Hypotension can occur with digoxin toxicity due to bradyarrhythmias and severe vomiting and diarrhea that lead to hypovolemia. However, digoxin is also an inotropic agent that causes increased cardiac output. Therefore, hypotension is a variable manifestation of digoxin toxicity.

(Choice E) Pulmonary edema may occur with uncontrolled heart failure due to poor forward flow that causes blood to pool in the lungs. It can be caused by both systolic and diastolic left ventricular dysfunction due to decreased forward ejection of blood and impaired ventricular filling, respectively.

Educational objective:
Digoxin toxicity presents with nonspecific gastrointestinal (eg, anorexia, nausea, vomiting) and neurologic (eg, fatigue, confusion, weakness) symptoms. Changes in color vision are a more specific, but rarer, finding. Life-threatening ventricular arrhythmias are the most serious complication.

References

- Diagnosis and treatment of digoxin toxicity.
- Digitalis toxicity: a fading but crucial complication to recognize.

Pharmacology	Cardiovascular System	Digoxin
Subject	System	Topic

A 66-year-old Caucasian male presents to your office with a several month history of straining during urination, hesitancy and intermittent urinary flow. Upon reviewing his medical record, you also note that his blood pressure was high (160-170/95-100 mmHg) during his last several check-ups. He is not taking any medications. Which of the following drugs would address both of this patient's current problems?

- A. Doxazosin
- B. Metoprolol
- C. Ramipril
- D. Hydrochlorothiazide
- E. Eplerenone
- F. Amlodipine

Submit

A 66-year-old Caucasian male presents to your office with a several month history of straining during urination, hesitancy and intermittent urinary flow. Upon reviewing his medical record, you also note that his blood pressure was high (160-170/95-100 mmHg) during his last several check-ups. He is not taking any medications. Which of the following drugs would address both of this patient's current problems?

- ✓ A. Doxazosin (82%)
- B. Metoprolol (4%)
- C. Ramipril (2%)
- D. Hydrochlorothiazide (4%)
- E. Eplerenone (3%)
- F. Amlodipine (2%)

Omitted
Correct answer
A

82%
Answered correctly

02 secs
Time Spent

06/11/2020
Last Updated

Explanation

In medical practice, patients are often prescribed so many medications that they have trouble keeping track of them. In order to give them an opportunity for best compliance with your medical treatment, it is desirable to choose medications which can address multiple issues at once by taking advantage of the multiple effects of certain drugs on the body.

Alpha1-blockers such as Doxazosin, Prazosin and Terazosin are useful for the treatment of both benign prostatic hyperplasia and hypertension. They act by blocking the alpha-1 adrenergic receptor leading to a relaxation of smooth muscle in arterial and venous walls leading to a decrease

In medical practice, patients are often prescribed so many medications that they have trouble keeping track of them. In order to give them an opportunity for best compliance with your medical treatment, it is desirable to choose medications which can address multiple issues at once by taking advantage of the multiple effects of certain drugs on the body.

Alpha1-blockers such as Doxazosin, Prazosin and Terazosin are useful for the treatment of both benign prostatic hyperplasia and hypertension. They act by blocking the alpha-1 adrenergic receptor leading to a relaxation of smooth muscle in arterial and venous walls leading to a decrease in peripheral vascular resistance. They do not have an effect on the chronotropy or inotropy of the heart. Additionally, via their blockade of the alpha-1 adrenergic receptor, these drugs induce relaxation of smooth muscle in the bladder neck and prostate leading to a decrease in urinary obstruction caused by benign prostatic hyperplasia (BPH). Thus, they are useful both as a treatment for hypertension and as a medical treatment for BPH. Decreased peripheral vascular resistance can lead to orthostatic hypotension and vertigo which are common side effects of this class of drugs. The most notable issue with these medications is their tendency to cause hypotension when treatment is first started; this is known as a first-dose effect and can be ameliorated by starting with a very small first dose.

(Choice B) Beta blockers are indicated in hypertensive patients who also have evidence of coronary artery disease and congestive heart failure.

(Choice C) Ramipril is an angiotensin converting enzyme inhibitor (ACE-I). ACE-Is are the drugs of choice for patients with diabetes and hypertension. ACE-Is have no effect on BPH.

(Choice D) Hydrochlorothiazide is presently the first-line medication for the treatment of essential hypertension in the general population. It is a diuretic that functions at the distal convoluted tubule of the nephron and prevents the reabsorption of sodium, chloride and water by blocking a Na/Cl cotransporter (Remember: wherever sodium goes water follows!). Thiazides can cause elevation of glucose, uric acid and calcium and thus are not recommended for diabetic patients, patients with gout or patients with hypercalcemia. They can also cause hyponatremia.

(Choice E) Eplerenone is a newer aldosterone antagonist and functions similarly to spironolactone as a potassium-sparing diuretic. These drugs are weak diuretics and are frequently used in conjunction with other diuretics for their potassium-sparing effect or for hyperaldosterone states such as with an aldosterone-secreting tumor. The most frequently mentioned side effect of these medications is their ability to cause gynecomastia (approximately 1% with Eplerenone, 9% with spironolactone).

(Choice F) Amlodipine is a dihydropyridine calcium channel blocker and differs from verapamil in that amlodipine is selective for the vascular smooth muscle and does not affect the heart as verapamil does. It is often used as an antihypertensive agent but is second line for most patients. Calcium channel blockers are particularly useful for patients with evidence of vasospasm such as Raynaud phenomenon, Prinzmetal angina etc.

(Choice B) Beta blockers are indicated in hypertensive patients who also have evidence of coronary artery disease and congestive heart failure.

(Choice C) Ramipril is an angiotensin converting enzyme inhibitor (ACE-I). ACE-Is are the drugs of choice for patients with diabetes and hypertension. ACE-Is have no effect on BPH.

(Choice D) Hydrochlorothiazide is presently the first-line medication for the treatment of essential hypertension in the general population. It is a diuretic that functions at the distal convoluted tubule of the nephron and prevents the reabsorption of sodium, chloride and water by blocking a Na/Cl cotransporter (Remember: wherever sodium goes water follows!). Thiazides can cause elevation of glucose, uric acid and calcium and thus are not recommended for diabetic patients, patients with gout or patients with hypercalcemia. They can also cause hyponatremia.

(Choice E) Eplerenone is a newer aldosterone antagonist and functions similarly to spironolactone as a potassium-sparing diuretic. These drugs are weak diuretics and are frequently used in conjunction with other diuretics for their potassium-sparing effect or for hyperaldosterone states such as with an aldosterone-secreting tumor. The most frequently mentioned side effect of these medications is their ability to cause gynecomastia (approximately 1% with Eplerenone, 9% with spironolactone).

(Choice F) Amlodipine is a dihydropyridine calcium channel blocker and differs from verapamil in that amlodipine is selective for the vascular smooth muscle and does not affect the heart as verapamil does. It is often used as an antihypertensive agent but is second line for most patients. Calcium channel blockers are particularly useful for patients with evidence of vasospasm such as Raynaud phenomenon, Prinzmetal angina etc.

Educational objective:

1. Alpha1-blockers such as Doxazosin, Prazosin and Terazosin are useful for the treatment of both benign prostatic hyperplasia and hypertension.
2. Patients with coronary artery disease and heart failure along with hypertension will benefit from cardioselective beta-blockers.
3. Hydrochlorothiazide is presently the first-line medication for the treatment of essential hypertension in the general population.

Pharmacology	Cardiovascular System	Primary hypertension
Subject	System	Topic

Copyright © UWorld. All rights reserved.

A 65-year-old woman with type 2 diabetes mellitus and hypertension comes to the office for routine follow-up. She has occasional numbness in her feet. The patient takes ibuprofen for chronic back pain along with hydrochlorothiazide, metformin, atorvastatin, and insulin detemir. Her blood pressure is 120/76 mm Hg supine and 122/80 mm Hg standing. Laboratory evaluation shows a serum potassium level of 4.2 mEq/L and a creatinine level of 0.8 mg/dL. Urinalysis shows albuminuria. Lisinopril therapy is initiated. The next day, the patient returns due to lightheadedness and near-syncope. Her blood pressure is 102/66 mm Hg supine and 80/45 mm Hg standing. Her pulse is 94/min. Cardiopulmonary examination is normal. Which of the following is most likely the major factor contributing to this patient's current symptoms?

- A. Autonomic neuropathy
- B. Chronic nonsteroidal anti-inflammatory drug use
- C. Diabetic nephropathy
- D. Diuretic therapy
- E. Unilateral renal artery stenosis

Submit

A 65-year-old woman with type 2 diabetes mellitus and hypertension comes to the office for routine follow-up. She has occasional numbness in her feet. The patient takes ibuprofen for chronic back pain along with hydrochlorothiazide, metformin, atorvastatin, and insulin detemir. Her blood pressure is 120/76 mm Hg supine and 122/80 mm Hg standing. Laboratory evaluation shows a serum potassium level of 4.2 mEq/L and a creatinine level of 0.8 mg/dL. Urinalysis shows albuminuria. Lisinopril therapy is initiated. The next day, the patient returns due to lightheadedness and near-syncope. Her blood pressure is 102/66 mm Hg supine and 80/45 mm Hg standing. Her pulse is 94/min. Cardiopulmonary examination is normal. Which of the following is most likely the major factor contributing to this patient's current symptoms?

- A. Autonomic neuropathy (17%)
- B. Chronic nonsteroidal anti-inflammatory drug use (8%)
- C. Diabetic nephropathy (9%)
- ✓ D. Diuretic therapy (49%)
- E. Unilateral renal artery stenosis (15%)

Omitted
Correct answer
D

49%
Answered correctly

02 secs
Time Spent

02/02/2020
Last Updated

Explanation

This patient with albuminuria was started on an **ACE inhibitor** for treatment of early diabetic nephropathy. Although most patients remain asymptomatic with only a mild reduction in blood pressure, **first-dose hypotension** can be a potential limiting factor when initiating ACE inhibitors. Significant hypotension is most likely to occur in patients with high plasma renin activity, such as those with **volume depletion** (eg, from diuretic use [**hydrochlorothiazide** in this patient]) or heart failure. Initiation of ACE inhibitor therapy causes abrupt removal of the vasoconstrictive

Explanation

This patient with albuminuria was started on an **ACE inhibitor** for treatment of early diabetic nephropathy. Although most patients remain asymptomatic with only a mild reduction in blood pressure, **first-dose hypotension** can be a potential limiting factor when initiating ACE inhibitors. Significant hypotension is most likely to occur in patients with high plasma renin activity, such as those with **volume depletion** (eg, from diuretic use [**hydrochlorothiazide** in this patient]) or heart failure. Initiation of ACE inhibitor therapy causes abrupt removal of the vasoconstrictive effects of angiotensin II, resulting in decreased peripheral vascular tone and a precipitous drop in blood pressure in susceptible patients. To prevent the development of first-dose hypotension, therapy should be started at low doses and slowly titrated upward as needed.

(Choice A) Numbness in the feet is suggestive of diabetic peripheral neuropathy. Such patients are at risk of developing autonomic neuropathy, which can present with orthostatic hypotension. However, this patient had no evidence of orthostatic hypotension on initial examination before ACE therapy initiation.

(Choices B and C) This patient has albuminuria, suggesting early diabetic nephropathy that can be exacerbated by chronic use of nonsteroidal anti-inflammatory drugs (reduce prostaglandin synthesis and increase preglomerular resistance). ACE inhibitors cause further reduction in glomerular filtration rate and can precipitate acute renal failure in patients with underlying renal insufficiency. However, this patient's normal serum creatinine indicates relatively intact renal function.

(Choice E) ACE inhibitors can worsen renal impairment in patients with bilateral renal artery stenosis but usually not in those with unilateral renal artery stenosis.

Educational objective:
ACE inhibitors can cause significant first-dose hypotension in patients with volume depletion (eg, from diuretic use) or heart failure. To reduce the risk of first-dose hypotension, ACE inhibitor therapy should be initiated at low dosages.

Pharmacology	Cardiovascular System	ACE inhibitors
Subject	System	Topic

Copyright © UWorld. All rights reserved.

1
2
3
4
5
6
7
8
9
10
11
12
13
14
15
16
17
18
19
20
21
22
23
24
25
26
27
28
29
30
31

A 45-year-old man who was recently started on medication for paroxysmal atrial fibrillation undergoes stress ECG testing. The patient exercises on a treadmill for 9 minutes and reaches 98% of age-predicted maximal heart rate without chest pain or ST-segment changes. His pre-test resting QRS complex duration is 95 msec (normal: 80-120 msec) and corrected QT (QTc) interval duration is 410 msec (normal ≤440 msec). ECG findings recorded at his maximally achieved heart rate show a QRS complex duration of 125 msec and QTc interval duration of 400 msec. Based on the patient's test results, which of the following medications is most likely being used to treat his atrial fibrillation?

A. Atenolol
B. Digoxin
C. Dofetilide
D. Flecainide
E. Verapamil

Submit

1
2
3
4
5
6
7
8
9
10
11
12
13
14
15
16
17
18
19
20
21
22
23
24
25
26
27
28
29
30
31

A 45-year-old man who was recently started on medication for paroxysmal atrial fibrillation undergoes stress ECG testing. The patient exercises on a treadmill for 9 minutes and reaches 98% of age-predicted maximal heart rate without chest pain or ST-segment changes. His pre-test resting QRS complex duration is 95 msec (normal: 80-120 msec) and corrected QT (QTc) interval duration is 410 msec (normal ≤440 msec). ECG findings recorded at his maximally achieved heart rate show a QRS complex duration of 125 msec and QTc interval duration of 400 msec. Based on the patient's test results, which of the following medications is most likely being used to treat his atrial fibrillation?

A. Atenolol (10%)
B. Digoxin (10%)
C. Dofetilide (18%)
✓ D. Flecainide (44%)
E. Verapamil (15%)

Omitted
Correct answer
D

44%
Answered correctly

02 secs
Time Spent

03/04/2020
Last Updated

Explanation

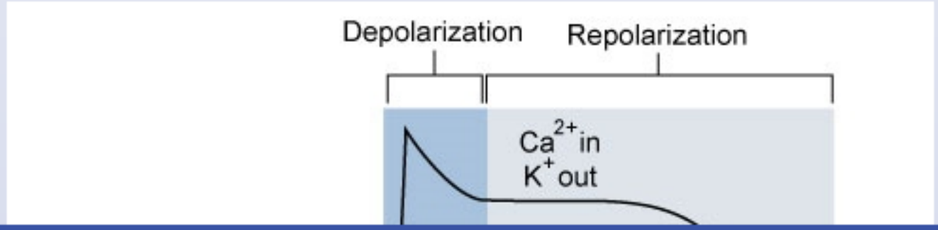

Explanation

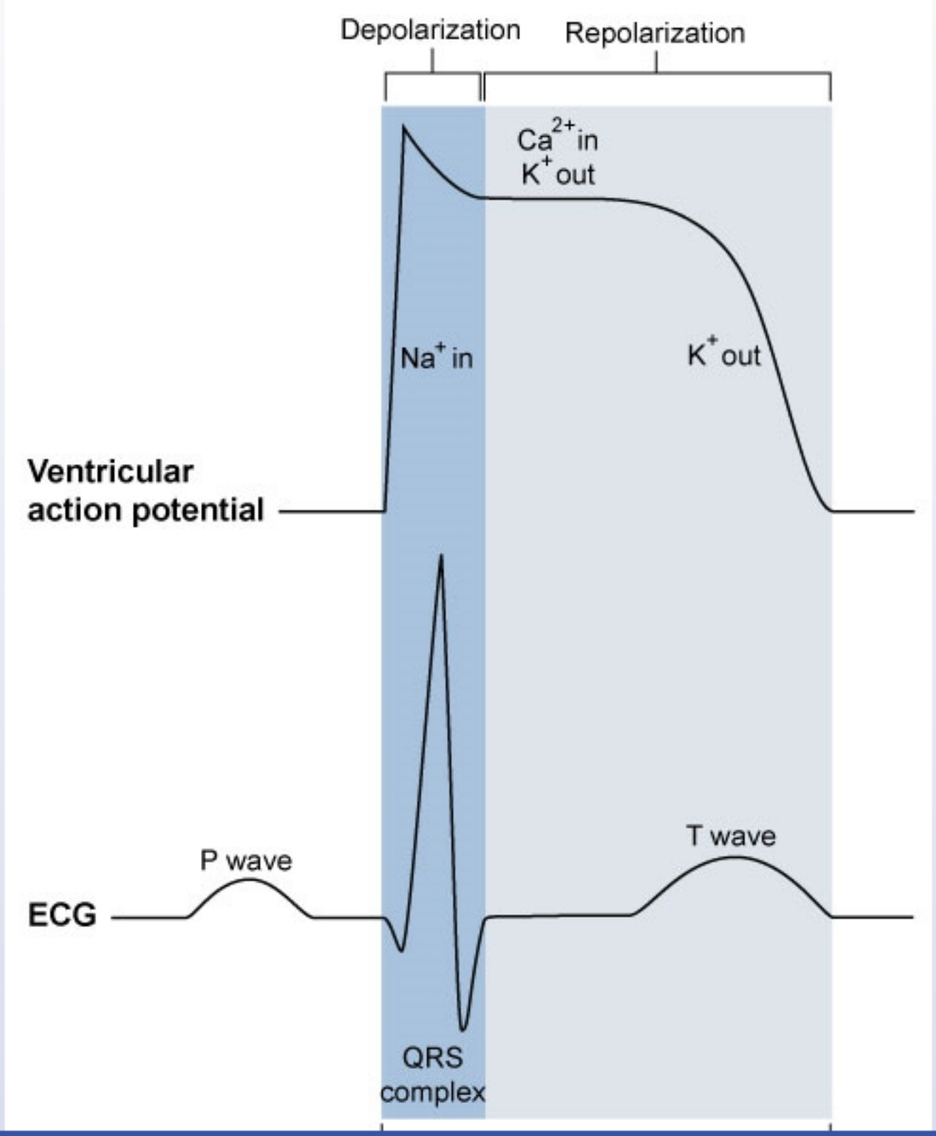

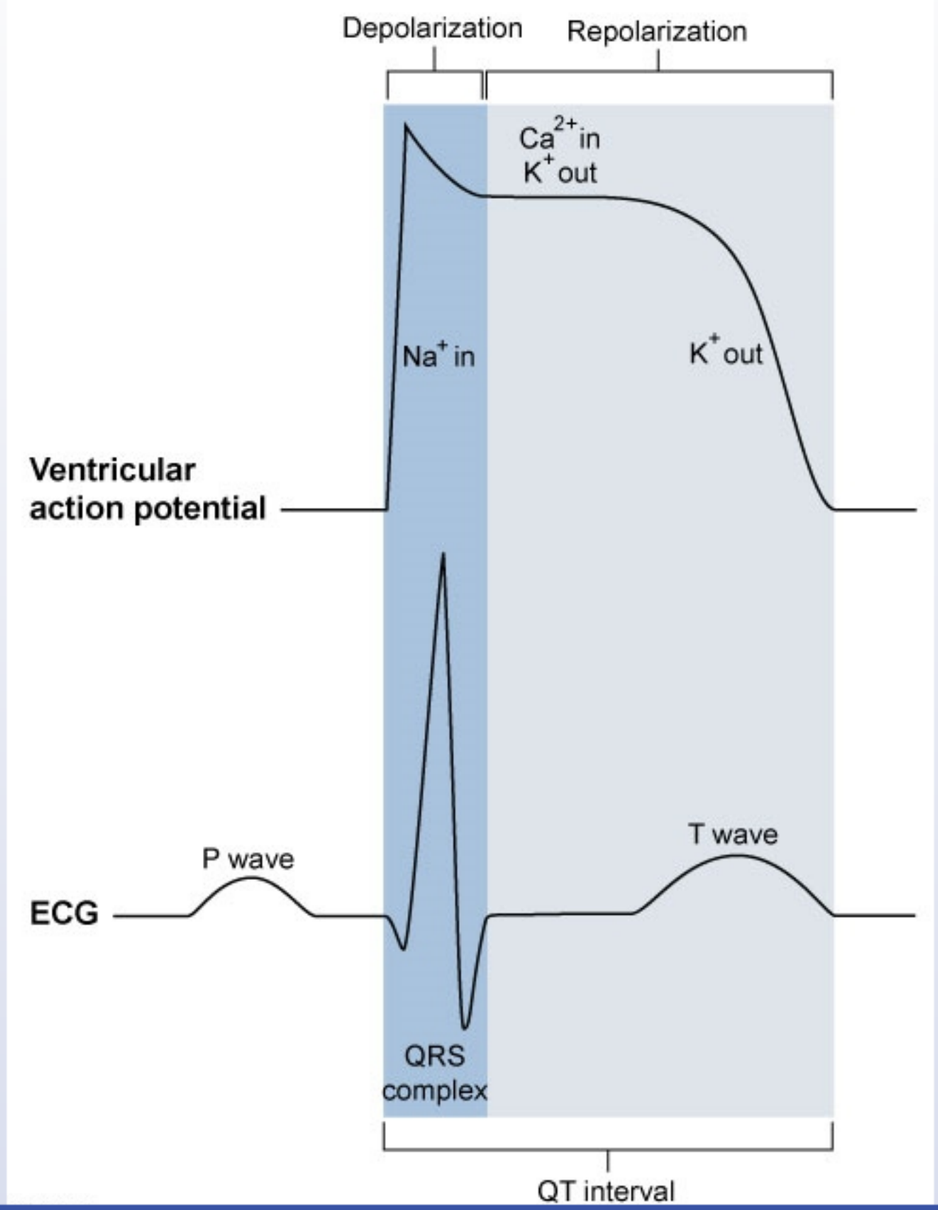
Depolarization
Repolarization
Ca^{2+} in
K^+ out
Na^+ in
K^+ out
Ventricular action potential
P wave
T wave
ECG
QRS complex
QT interval

©UWorld

The **QRS complex duration** is typically slightly **reduced during exercise** in response to the increase in cardiac conduction velocity that accompanies faster heart rates. However, this patient's QRS duration is normal at rest and prolonged at near-maximal heart rate. This suggests that the drug used to treat his atrial fibrillation lengthens the QRS duration in a rate-dependent manner, which is consistent with a drug exhibiting strong use-dependence such as flecainide.

Flecainide is a class 1C antiarrhythmic that is typically used to treat supraventricular tachycardias such as those caused by atrial fibrillation. Class 1C antiarrhythmics bind to the fast sodium channels responsible for phase 0 depolarization of cardiac myocytes, blocking the inward sodium current. This **prolongs the QRS duration** with little effect on total action potential or QT interval duration. Class 1C drugs are the slowest of the class 1 agents to dissociate from the sodium channel, and do so primarily during diastole. This results in a phenomenon known as **use-dependence**, in which their sodium-blocking effects intensify as the heart rate increases due to less time for the medication to dissociate from the receptor.

(Choice A) Selective β1 blockers such as atenolol do not significantly affect QRS duration. However, their use during exercise ECG testing can limit the maximal heart rate that is achieved.

(Choice B) Digoxin can cause false-positive ST-segment depression during exercise ECG testing as well as lower the maximal achievable heart rate. It does not significantly affect QRS duration.

(Choice C) Dofetilide is a class III antiarrhythmic drug that blocks the outward potassium current during repolarization. As a result, it increases the QT interval duration but does not affect QRS duration. Class III agents demonstrate reverse use-dependence (the slower the heart rate, the more the QT interval is prolonged).

(Choice E) Verapamil (a class IV antiarrhythmic) is a calcium channel blocker that slows sinoatrial and atrioventricular nodal conduction. It also increases coronary blood flow and reduces myocardial oxygen demand, which can mask ischemia during stress testing. Verapamil does not affect QRS duration.

Educational objective:
Class 1C antiarrhythmics such as flecainide are potent sodium channel blockers that have increased effect at faster heart rates (use-dependence). This makes them more effective at treating tachyarrhythmias, but can also cause prolonged QRS duration (a proarrhythmic effect) at higher heart rates.

Flecainide is a class 1C antiarrhythmic that is typically used to treat supraventricular tachycardias such as those caused by atrial fibrillation. Class 1C antiarrhythmics bind to the fast sodium channels responsible for phase 0 depolarization of cardiac myocytes, blocking the inward sodium current. This **prolongs the QRS duration** with little effect on total action potential or QT interval duration. Class 1C drugs are the slowest of the class 1 agents to dissociate from the sodium channel, and do so primarily during diastole. This results in a phenomenon known as **use-dependence**, in which their sodium-blocking effects intensify as the heart rate increases due to less time for the medication to dissociate from the receptor.

(Choice A) Selective β1 blockers such as atenolol do not significantly affect QRS duration. However, their use during exercise ECG testing can limit the maximal heart rate that is achieved.

(Choice B) Digoxin can cause false-positive ST-segment depression during exercise ECG testing as well as lower the maximal achievable heart rate. It does not significantly affect QRS duration.

(Choice C) Dofetilide is a class III antiarrhythmic drug that blocks the outward potassium current during repolarization. As a result, it increases the QT interval duration but does not affect QRS duration. Class III agents demonstrate reverse use-dependence (the slower the heart rate, the more the QT interval is prolonged).

(Choice E) Verapamil (a class IV antiarrhythmic) is a calcium channel blocker that slows sinoatrial and atrioventricular nodal conduction. It also increases coronary blood flow and reduces myocardial oxygen demand, which can mask ischemia during stress testing. Verapamil does not affect QRS duration.

Educational objective:
Class 1C antiarrhythmics such as flecainide are potent sodium channel blockers that have increased effect at faster heart rates (use-dependence). This makes them more effective at treating tachyarrhythmias, but can also cause prolonged QRS duration (a proarrhythmic effect) at higher heart rates.

Pharmacology	Cardiovascular System	Antiarrhythmic drugs
Subject	System	Topic

Copyright © UWorld. All rights reserved.

Flecainide is a class 1C antiarrhythmic that is typically used to treat supraventricular tachycardias such as those caused by atrial fibrillation.

Exhibit Display

Class I (sodium channel-blocking) antiarrhythmics			
	Specific agents	**Inhibition of phase 0 depolarization**	**Effect on length of action potential**
Class IA	Quinidine, procainamide, disopyramide	Intermediate	Prolonged
Class IB	Lidocaine, mexiletine	Weak	Shortened
Class IC	Flecainide, propafenone	Strong	No change

©UWorld

Flecainide is a class 1C antiarrhythmic that is typically used to treat supraventricular tachycardias such as those caused by atrial fibrillation.

Exhibit Display

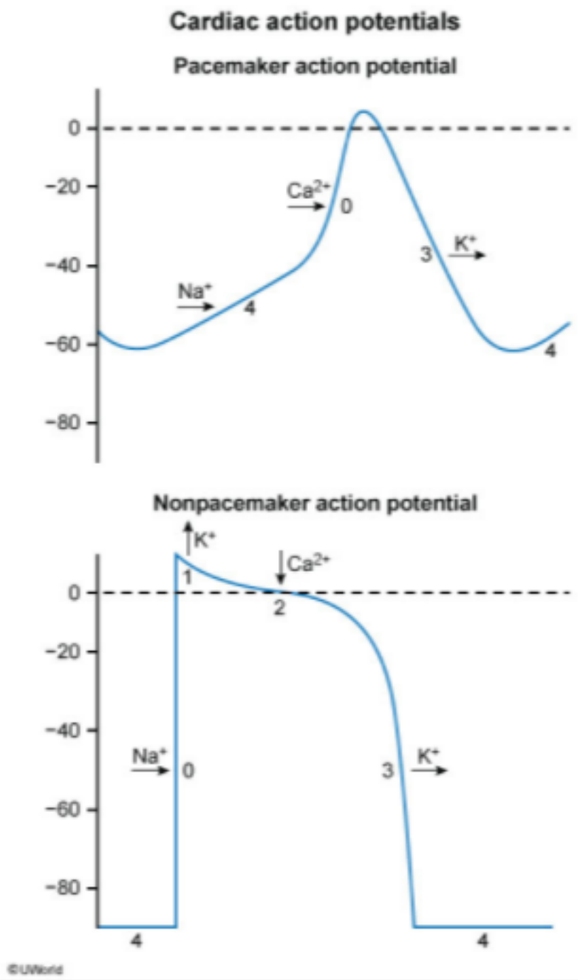

Zoom In | Zoom Out | Reset | Add To New Card | Existing Card

A 47-year-old man comes to the office for follow-up of his elevated blood pressure. The patient's medical history is significant for stable angina pectoris, for which he takes sublingual nitroglycerin as needed. He has no orthopnea, paroxysmal nocturnal dyspnea, or lower extremity swelling. His blood pressure is 154/107 mm Hg and pulse is 86/min. Physical examination shows no abnormalities. The patient is started on a low dose of atenolol. Which of the following cellular changes will most likely occur as a direct effect of this medication?

	Cardiomyocyte [cAMP]	Juxtaglomerular cell [cAMP]	Vascular smooth muscle [cAMP]
A.	Decreased	Decreased	Decreased
B.	Decreased	Decreased	No significant change
C.	Decreased	No significant change	Decreased
D.	Decreased	No significant change	No significant change
E.	No significant change	No significant change	No significant change

Submit

A 47-year-old man comes to the office for follow-up of his elevated blood pressure. The patient's medical history is significant for stable angina pectoris, for which he takes sublingual nitroglycerin as needed. He has no orthopnea, paroxysmal nocturnal dyspnea, or lower extremity swelling. His blood pressure is 154/107 mm Hg and pulse is 86/min. Physical examination shows no abnormalities. The patient is started on a low dose of atenolol. Which of the following cellular changes will most likely occur as a direct effect of this medication?

	Cardiomyocyte [cAMP]	Juxtaglomerular cell [cAMP]	Vascular smooth muscle [cAMP]
A. (13%)	Decreased	Decreased	Decreased
✓ B. (54%)	Decreased	Decreased	No significant change
C. (13%)	Decreased	No significant change	Decreased
D. (17%)	Decreased	No significant change	No significant change
E. (1%)	No significant change	No significant change	No significant change

Omitted
Correct answer
B

54%
Answered correctly

02 secs
Time Spent

01/23/2020
Last Updated

Explanation

G protein-coupled receptors & their signal transducers		
Adrenergic	α_1	G_q
	α_2	G_i
	β_1	G_s
	β_2	G_s
Cholinergic	M_1	G_q
	M_2	G_i
	M_3	G_q
Dopaminergic	D_1	G_s
	D_2	G_i

©UWorld

Beta blockers are the preferred treatment for patients with chronic stable angina and hypertension. They relieve anginal symptoms by inhibiting sympathetic stimulation of the heart, reducing both heart rate and contractility. Because beta blockers reduce heart rate and blood pressure during rest and exercise, the onset of angina is avoided or delayed.

At low doses, **atenolol** is a **selective β1 adrenergic antagonist**. β_1 receptors are found in **cardiac tissue** and on **renal juxtaglomerular cells**,

Beta blockers are the preferred treatment for patients with chronic stable angina and hypertension. They relieve anginal symptoms by inhibiting sympathetic stimulation of the heart, reducing both heart rate and contractility. Because beta blockers reduce heart rate and blood pressure during rest and exercise, the onset of angina is avoided or delayed.

At low doses, **atenolol** is a **selective β1 adrenergic antagonist**. β_1 receptors are found in **cardiac tissue** and on **renal juxtaglomerular cells**, but not in vascular smooth muscle. The β_1 receptor is a G protein-coupled receptor (GPCR) associated with **Gs**, which increases intracellular cAMP levels. Blockade of the β_1 receptor leads to **decreased cAMP levels** in cardiac and renal tissue without significantly affecting cAMP levels in vascular smooth muscle **(Choices C and D)**.

GPCRs comprise a large family of 7 transmembrane domain receptors that activate intracellular second messenger systems. There are 2 principal second messenger systems involving GPCRs:

1. cAMP signaling pathway: The activated G_s α subunit activates the enzyme adenylyl cyclase, which catalyzes the conversion of ATP into cAMP. Elevated cAMP leads to the activation of protein kinase A. Conversely, the G_i α subunit inhibits adenylyl cyclase, thereby reducing cAMP levels.
2. Phosphatidylinositol signaling pathway: The activated G_q α subunit activates phospholipase C, which degrades membrane lipids into diacylglycerol (DAG) and inositol triphosphate (IP3). Protein kinase C is activated by DAG, and calcium is released from the sarcoplasmic reticulum under the influence of IP3.

(Choice A) Propranolol is a nonselective beta blocker that blocks both β1 and β2 adrenergic receptors. β2 receptors are found in vascular and bronchial smooth muscle. Blockade of β1and β2 receptors would therefore result in decreased cAMP levels in cardiac myocytes, renal juxtaglomerular cells, and vascular smooth muscle.

(Choice E) A medication such as diltiazem, a non-dihydropyridine calcium channel blocker, would not directly affect cAMP levels.

Educational objective:
β_1 adrenergic receptors are found in cardiac tissue and on renal juxtaglomerular cells, but not in vascular smooth muscle. Selective blockade of the β_1 receptor (eg, with atenolol) leads to decreased cAMP levels in cardiac and renal tissue without significantly affecting cAMP levels in vascular smooth muscle.

References

1
2
3
4
5
6
7
8
9
10
11
12
13
14
15
16
17
18
19
20
21
22
23
24
25
26
27
28
29
30
31

Exhibit Display

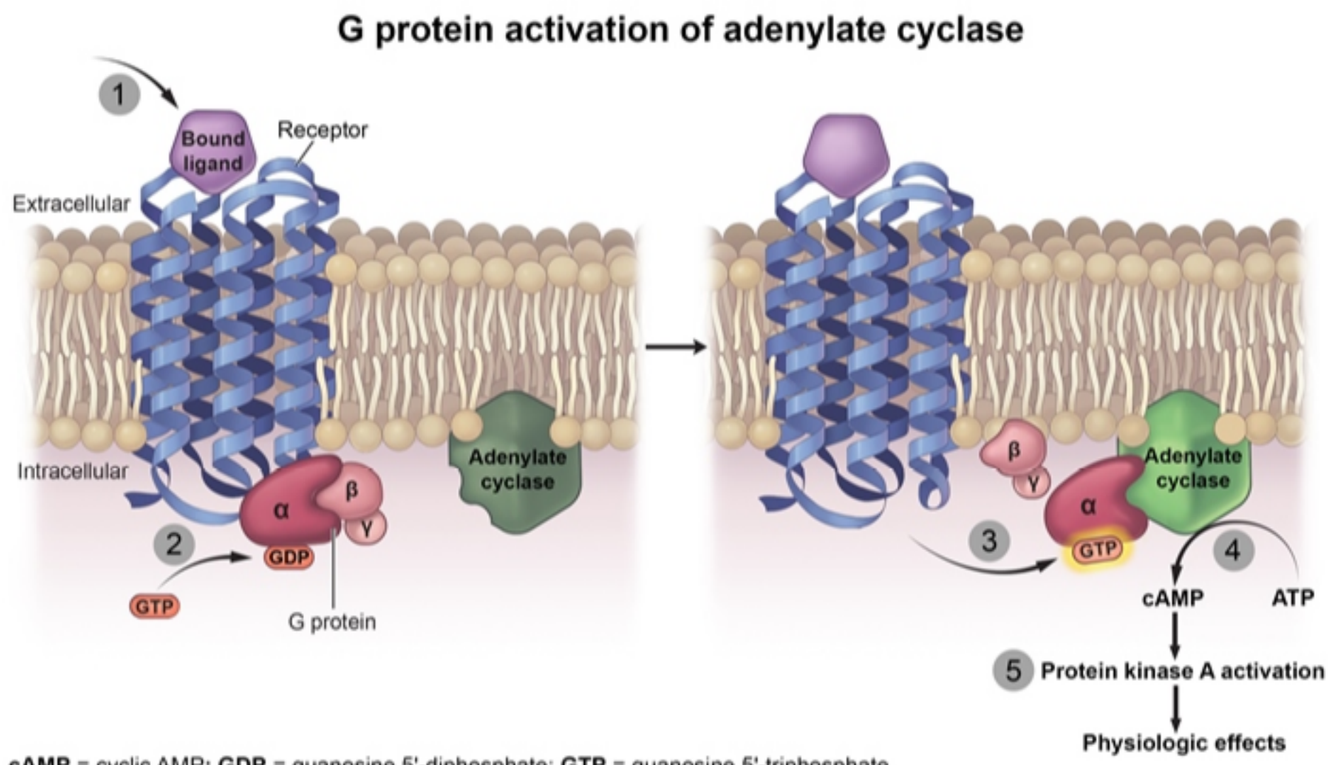

cAMP = cyclic AMP; **GDP** = guanosine 5'-diphosphate; **GTP** = guanosine 5'-triphosphate.

©UWorld

Zoom In | Zoom Out | Reset | Add To New Card | Existing Card

References

cAMP levels. Blockade of the β_1 receptor leads to **decreased cAMP levels** in cardiac and renal tissue without significantly affecting cAMP levels in vascular smooth muscle **(Choices C and D)**.

GPCRs comprise a large family of 7 transmembrane domain receptors that activate intracellular second messenger systems. There are 2 principal second messenger systems involving GPCRs:

1. cAMP signaling pathway: The activated G_s α subunit activates the enzyme adenylyl cyclase, which catalyzes the conversion of ATP into cAMP. Elevated cAMP leads to the activation of protein kinase A. Conversely, the G_i α subunit inhibits adenylyl cyclase, thereby reducing cAMP levels.
2. Phosphatidylinositol signaling pathway: The activated G_q α subunit activates phospholipase C, which degrades membrane lipids into diacylglycerol (DAG) and inositol triphosphate (IP3). Protein kinase C is activated by DAG, and calcium is released from the sarcoplasmic reticulum under the influence of IP3.

(Choice A) Propranolol is a nonselective beta blocker that blocks both β1 and β2 adrenergic receptors. β2 receptors are found in vascular and bronchial smooth muscle. Blockade of β1and β2 receptors would therefore result in decreased cAMP levels in cardiac myocytes, renal juxtaglomerular cells, and vascular smooth muscle.

(Choice E) A medication such as diltiazem, a non-dihydropyridine calcium channel blocker, would not directly affect cAMP levels.

Educational objective:
β_1 adrenergic receptors are found in cardiac tissue and on renal juxtaglomerular cells, but not in vascular smooth muscle. Selective blockade of the β_1 receptor (eg, with atenolol) leads to decreased cAMP levels in cardiac and renal tissue without significantly affecting cAMP levels in vascular smooth muscle.

References

- ß-adrenergic receptor signaling in cardiac function and heart failure.

Pharmacology	Cardiovascular System	Beta blockers
Subject	System	Topic

Copyright © UWorld. All rights reserved.

A 60-year-old man comes to the hospital with chest pain. He has had intermittent, squeezing substernal pain over the last 3 days that is now sustained. The patient has no associated palpitations, lightheadedness, or shortness of breath. Medical history is notable for moderate chronic obstructive pulmonary disease with a recent admission for an exacerbation. Blood pressure is 145/90 mm Hg and pulse is 93/min. Oxygen saturation by pulse oximetry is 98% on room air. Physical examination shows no heart murmurs, and lungs are clear to auscultation. ECG shows sinus rhythm with 2-mm anterior ST segment elevation. Cardiac troponin I levels are elevated. Which of the following is the most appropriate treatment for this patient?

- A. Ibutilide
- B. Metoprolol
- C. Nadolol
- D. Propranolol
- E. Sotalol

Submit

A 60-year-old man comes to the hospital with chest pain. He has had intermittent, squeezing substernal pain over the last 3 days that is now sustained. The patient has no associated palpitations, lightheadedness, or shortness of breath. Medical history is notable for moderate chronic obstructive pulmonary disease with a recent admission for an exacerbation. Blood pressure is 145/90 mm Hg and pulse is 93/min. Oxygen saturation by pulse oximetry is 98% on room air. Physical examination shows no heart murmurs, and lungs are clear to auscultation. ECG shows sinus rhythm with 2-mm anterior ST segment elevation. Cardiac troponin I levels are elevated. Which of the following is the most appropriate treatment for this patient?

- A. Ibutilide (8%)
- ✓ B. Metoprolol (68%)
- C. Nadolol (3%)
- D. Propranolol (11%)
- E. Sotalol (7%)

Omitted
Correct answer
B

68%
Answered correctly

02 secs
Time Spent

01/06/2020
Last Updated

Explanation

Effects of adrenergic blockade			
Receptor	Target organ	Effect	Potential adverse effects
		↓ Heart rate	

Effects of adrenergic blockade			
Receptor	**Target organ**	**Effect**	**Potential adverse effects**
B1-adrenergic blockade	Heart	↓ Heart rate ↓ Contractility ↓ O_2 consumption	Worsening of heart failure Bradycardia/heart block
	Kidney	↓ Renin release	
B2-adrenergic blockade	Muscle vasculature	Vasospasm	Exacerbation of peripheral artery disease
	Lungs	Bronchoconstriction	Worsening of obstructive lung disease
	Liver	↓ Glycogenolysis & gluconeogenesis	May cause hypoglycemia in diabetic patients
	Most tissues	↓ Potassium entry into cells	Hyperkalemia

This patient's clinical presentation—chest discomfort, ST elevation on ECG, elevated troponin I level—is consistent with **acute myocardial infarction** (AMI). Beta blockers are used in AMI to reduce myocardial oxygen demand by lowering heart rate, cardiac contractility, and afterload. They have been shown to reduce short-term morbidity (eg, recurrent symptoms or reinfarction), minimize infarct size, and improve long-term survival.

Contraindications to beta blockers include bradycardia or heart block, hypotension, and overt heart failure (eg, pulmonary edema). Also, **non-cardioselective beta blockers** (eg, propranolol, nadolol) can **trigger bronchospasm** in patients with underlying obstructive lung disease (asthma, **chronic obstructive pulmonary disease** [COPD]) due to beta-2 receptor blockade and should be avoided **(Choices C and D)**.

Cardioselective beta blockers with predominant action on beta-1 receptors (eg, **metoprolol**, atenolol, bisoprolol, nebivolol) are **safe** in patients with stable obstructive lung disease and are the beta blocker of choice in these patients. Combined beta and alpha receptor blockers (eg, carvedilol, labetalol) are also well tolerated and have been used safely in patients with COPD.

(Choice A) Ibutilide is a class III antiarrhythmic drug (potassium channel blocker) used for acute termination of atrial flutter or atrial fibrillation.

This patient's clinical presentation—chest discomfort, ST elevation on ECG, elevated troponin I level—is consistent with **acute myocardial infarction** (AMI). Beta blockers are used in AMI to reduce myocardial oxygen demand by lowering heart rate, cardiac contractility, and afterload. They have been shown to reduce short-term morbidity (eg, recurrent symptoms or reinfarction), minimize infarct size, and improve long-term survival.

Contraindications to beta blockers include bradycardia or heart block, hypotension, and overt heart failure (eg, pulmonary edema). Also, **non-cardioselective beta blockers** (eg, propranolol, nadolol) can **trigger bronchospasm** in patients with underlying obstructive lung disease (asthma, **chronic obstructive pulmonary disease** [COPD]) due to beta-2 receptor blockade and should be avoided **(Choices C and D)**.

Cardioselective beta blockers with predominant action on beta-1 receptors (eg, **metoprolol**, atenolol, bisoprolol, nebivolol) are **safe** in patients with stable obstructive lung disease and are the beta blocker of choice in these patients. Combined beta and alpha receptor blockers (eg, carvedilol, labetalol) are also well tolerated and have been used safely in patients with COPD.

(Choice A) Ibutilide is a class III antiarrhythmic drug (potassium channel blocker) used for acute termination of atrial flutter or atrial fibrillation. Like other class III antiarrhythmics, ibutilide causes prolonged QT interval that can precipitate a deadly arrhythmia (torsade de pointes).

(Choice E) Sotalol is a class III antiarrhythmic drug with beta blocker properties and is primarily used for the treatment of atrial and ventricular arrhythmias. It would not be indicated in a patient with a recent myocardial infarction who is in sinus rhythm.

Educational objective:
Beta blockers are used in acute myocardial infarction to reduce morbidity and mortality by decreasing cardiac output and myocardial oxygen demand. Non-cardioselective beta blockers (eg, propranolol, nadolol) can trigger bronchospasm in patients with underlying asthma or chronic obstructive pulmonary disease. Cardioselective beta blockers (eg, metoprolol) predominantly affect beta-1 receptors and are preferred in such patients.

References

- Use of cardioselective ß-blockers in patients with chronic obstructive pulmonary disease: a meta-analysis of randomized, placebo-controlled, blinded trials.

Pharmacology	Cardiovascular System	Myocardial infarction
Subject	System	Topic

1
2
3
4
5
6
7
8
9
10
11
12
13
14
15
16
17
18
19
20
21
22
23
24
25
26
27
28
29
30
31

A 36-year-old man comes to the office after he was found to have an abnormal lipid panel during employee wellness testing at his company. He has no prior medical problems and takes no medications. The patient is a software technician and has a sedentary lifestyle. He eats mostly fast foods, rarely exercises, and drinks 2-3 cans of beer daily. His BMI is 31 kg/m^2. Physical examination is unremarkable. Results of laboratory studies performed in the office are as follows:

Total cholesterol	290 mg/dL
High-density lipoprotein	45 mg/dL
Low-density lipoprotein	110 mg/dL
Triglycerides	675 mg/dL

Lifestyle modification with a balanced diet, regular exercise, and reduced alcohol intake is advised. He is also started on fenofibrate therapy. This medication is most likely to help the patient by which of the following mechanisms?

A. Blocking intestinal cholesterol absorption
B. Decreasing hepatic cholesterol synthesis
C. Increasing fecal loss of cholesterol derivatives
D. Inhibiting LDL receptor degradation
E. Reducing hepatic VLDL production

Submit

A 36-year-old man comes to the office after he was found to have an abnormal lipid panel during employee wellness testing at his company. He has no prior medical problems and takes no medications. The patient is a software technician and has a sedentary lifestyle. He eats mostly fast foods, rarely exercises, and drinks 2-3 cans of beer daily. His BMI is 31 kg/m^2. Physical examination is unremarkable. Results of laboratory studies performed in the office are as follows:

Total cholesterol	290 mg/dL
High-density lipoprotein	45 mg/dL
Low-density lipoprotein	110 mg/dL
Triglycerides	675 mg/dL

Lifestyle modification with a balanced diet, regular exercise, and reduced alcohol intake is advised. He is also started on fenofibrate therapy. This medication is most likely to help the patient by which of the following mechanisms?

A. Blocking intestinal cholesterol absorption (14%)

B. Decreasing hepatic cholesterol synthesis (8%)

C. Increasing fecal loss of cholesterol derivatives (16%)

D. Inhibiting LDL receptor degradation (15%)

✓ E. Reducing hepatic VLDL production (45%)

Omitted
Correct answer
E

45%
Answered correctly

01 sec
Time Spent

06/27/2020
Last Updated

1
2
3
4
5
6
7
8
9
10
11
12
13
14
15
16
17
18
19
20
21
22
23
24
25
26
27
28
29
30
31

Antihyperlipidemic agents

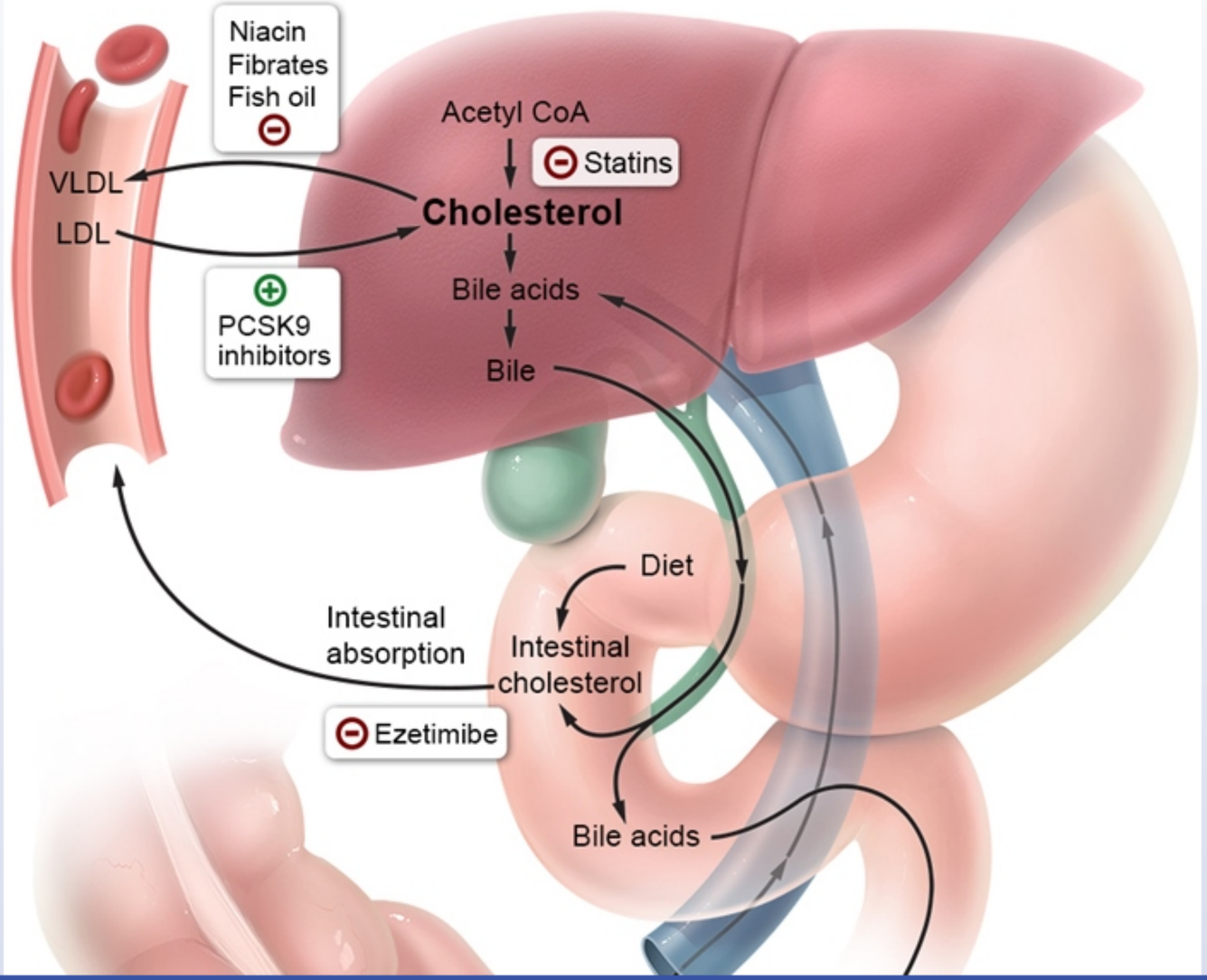

Antihyperlipidemic agents

Exhibit Display

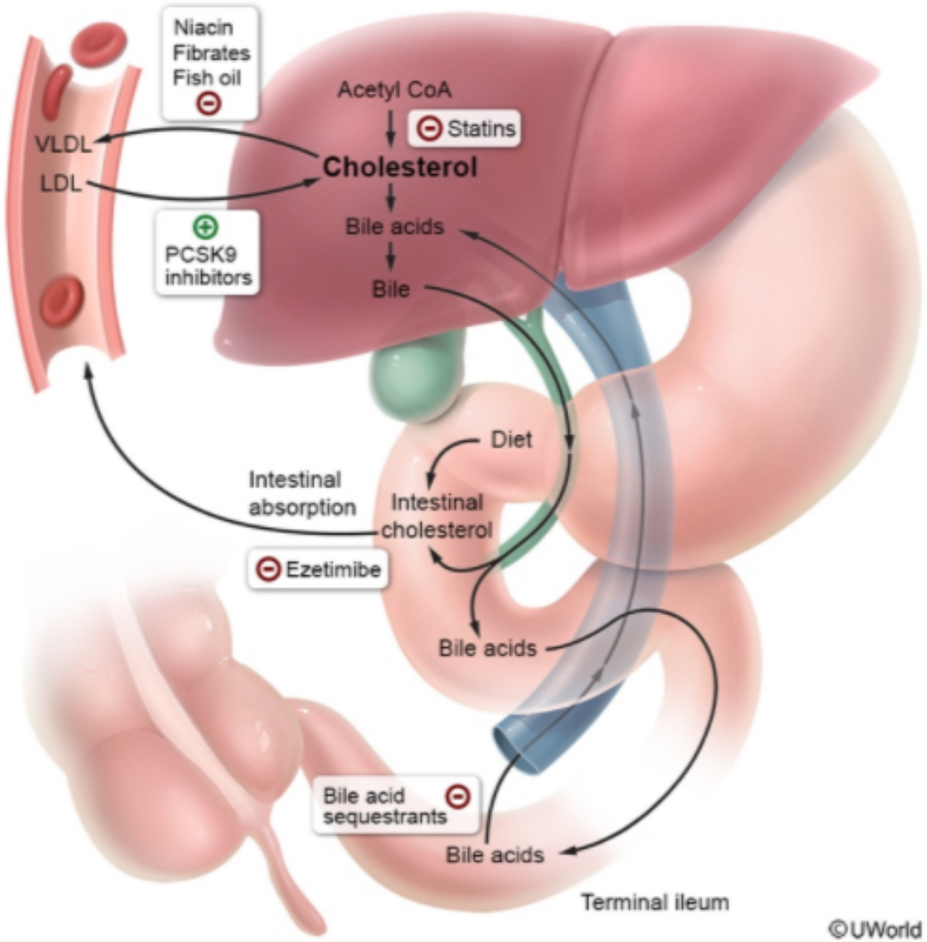

Zoom In | Zoom Out | Reset | Add To New Card | Existing Card

Bile acid

©UWorld

This patient has a moderately elevated (>500 mg/dL) triglyceride level, which is associated with an increased risk of cardiovascular disease. Lifestyle modifications (increased aerobic exercise, decreased alcohol and total caloric intake) can decrease triglycerides, but moderate (or worse) hypertriglyceridemia usually requires pharmacologic therapy.

Lipoprotein lipase (LPL) hydrolyzes triglycerides in chylomicrons and VLDL to release free fatty acids, which can be used for energy or converted back to triglycerides for storage in adipose tissue. It also facilitates the transfer of triglycerides from these lipoproteins to HDL. **Fibrates** (eg, gemfibrozil, fenofibrate) activate **peroxisome proliferator-activated receptor alpha** (PPAR-α), which leads to **decreased hepatic VLDL** production and increased LPL activity. They are able to decrease triglyceride levels by 25%-50% and increase HDL by 5%-20%. Fish oil supplements containing high concentrations of **omega-3 fatty acids** also decrease **VLDL production**, and inhibit synthesis of apolipoprotein B as well. These supplements lower triglycerides and can be used as an alternate treatment for patients with moderate hypertriglyceridemia.

(Choices A, C, and D) Ezetimibe selectively blocks intestinal cholesterol absorption. Bile acid-binding resins (eg, cholestyramine) increase fecal loss of cholesterol derivatives by binding bile acids in the intestine and disrupting enterohepatic bile acid circulation. Proprotein convertase subtilisin kexin 9 (PCSK9) inhibitors are monoclonal antibodies that reduce LDL receptor degradation in the liver. These drugs are used primarily in patients with elevated cholesterol levels but have minimal effect on triglyceride levels.

(Choice B) Statins (eg, atorvastatin) decrease hepatic cholesterol synthesis by inhibiting HMG-CoA reductase. Statins have a modest effect on triglyceride levels and are recommended for patients with mild to moderate hypertriglyceridemia.

Educational objective:
Fibrates lower triglyceride levels by activating peroxisome proliferator-activated receptor alpha, which leads to decreased hepatic VLDL production and increased lipoprotein lipase activity. Fish oil supplements containing high concentrations of omega-3 fatty acids lower triglycerides by decreasing production of VLDL and apolipoprotein B.

References

- Fenofibrate: a review of its use in dyslipidaemia.

Pharmacology	Cardiovascular System	Dyslipidemia
Subject	System	Topic

1
2
3
4
5
6
7
8
9
10
11
12
13
14
15
16
17
18
19
20
21
22
23
24
25
26
27
28
29
30
31

A 64-year-old man with a long-standing history of hypertension is brought to the emergency department with a dry cough and shortness of breath. The patient has been unable to sleep in the flat position for the past 2 days. Blood pressure is 192/102 mm Hg and pulse is 92/min and regular. Physical examination reveals an S4 and bibasilar crackles. He is started on intravenous nitroglycerin infusion and soon after reports significant symptomatic relief. Which of the following physiologic changes are most likely to occur following administration of this medication?

	Left ventricular end-diastolic pressure	Peripheral venous capacitance	Systemic vascular resistance
A.	No effect	↑	↓
B.	↓	↑	No effect
C.	↑	↓	↑
D.	↓	↑	↓
E.	↓	↓	↓
F.	↑	No effect	↓
G.	↑	↑	↑

Submit

A 64-year-old man with a long-standing history of hypertension is brought to the emergency department with a dry cough and shortness of breath. The patient has been unable to sleep in the flat position for the past 2 days. Blood pressure is 192/102 mm Hg and pulse is 92/min and regular. Physical examination reveals an S4 and bibasilar crackles. He is started on intravenous nitroglycerin infusion and soon after reports significant symptomatic relief. Which of the following physiologic changes are most likely to occur following administration of this medication?

	Left ventricular end-diastolic pressure	Peripheral venous capacitance	Systemic vascular resistance
A. (8%)	No effect	↑	↓
B. (27%)	↓	↑	No effect
C. (1%)	↑	↓	↑
✓ D. (54%)	↓	↑	↓
E. (5%)	↓	↓	↓
F. (2%)	↑	No effect	↓
G. (0%)	↑	↑	↑

Omitted
Correct answer

54%

02 secs

06/21/2020

Omitted
Correct answer
D

54%
Answered correctly

02 secs
Time Spent

06/21/2020
Last Updated

Explanation

This patient's clinical presentation is consistent with acute pulmonary edema due to severely elevated blood pressure (hypertensive emergency). Intravenous vasodilators (eg, nitroglycerine, sodium nitroprusside) are often used in management of acute heart failure due to severe hypertension.

Nitrates are primarily **venodilators** that **increase peripheral venous capacitance**, thereby reducing cardiac preload and left ventricular end-diastolic pressure (LVEDP) and volume. This is the primary mechanism of action for symptom relief in patients with acute pulmonary edema. **Lower LVEDP** also leads to a reduction in LV systolic wall stress and a decrease in myocardial oxygen demand, resulting in relief of angina symptoms. Although the vasodilatory effects of nitrates act primarily on the venous system, they also have a **modest** effect on **arteriolar dilation**. Higher doses can lead to a significant drop in systemic blood pressure, thereby decreasing cardiac afterload, reducing left ventricle wall stress, and causing a further decrease in myocardial oxygen demand.

Educational objective:
Nitrates are primarily venodilators and increase peripheral venous capacitance, thereby reducing cardiac preload and left ventricular end-diastolic volume and pressure. Nitrates also have a modest effect on arteriolar dilation and cause a decrease in systemic vascular resistance and cardiac afterload.

References

- Mechanisms of action of nitrates.

Pharmacology	Cardiovascular System	Nitrates
Subject	System	Topic

Copyright © UWorld. All rights reserved.

1
2
3
4
5
6
7
8
9
10
11
12
13
14
15
16
17
18
19
20
21
22
23
24
25
26
27
28
29
30
31

A physician is conducting a clinical trial for a new hemodynamic drug developed for a variety of indications. The drug's pharmacodynamic profile indicates that it is a pure adrenergic agonist with no significant antagonistic properties. It is infused into a volunteer, and hemodynamic parameters are recorded in the graphs below.

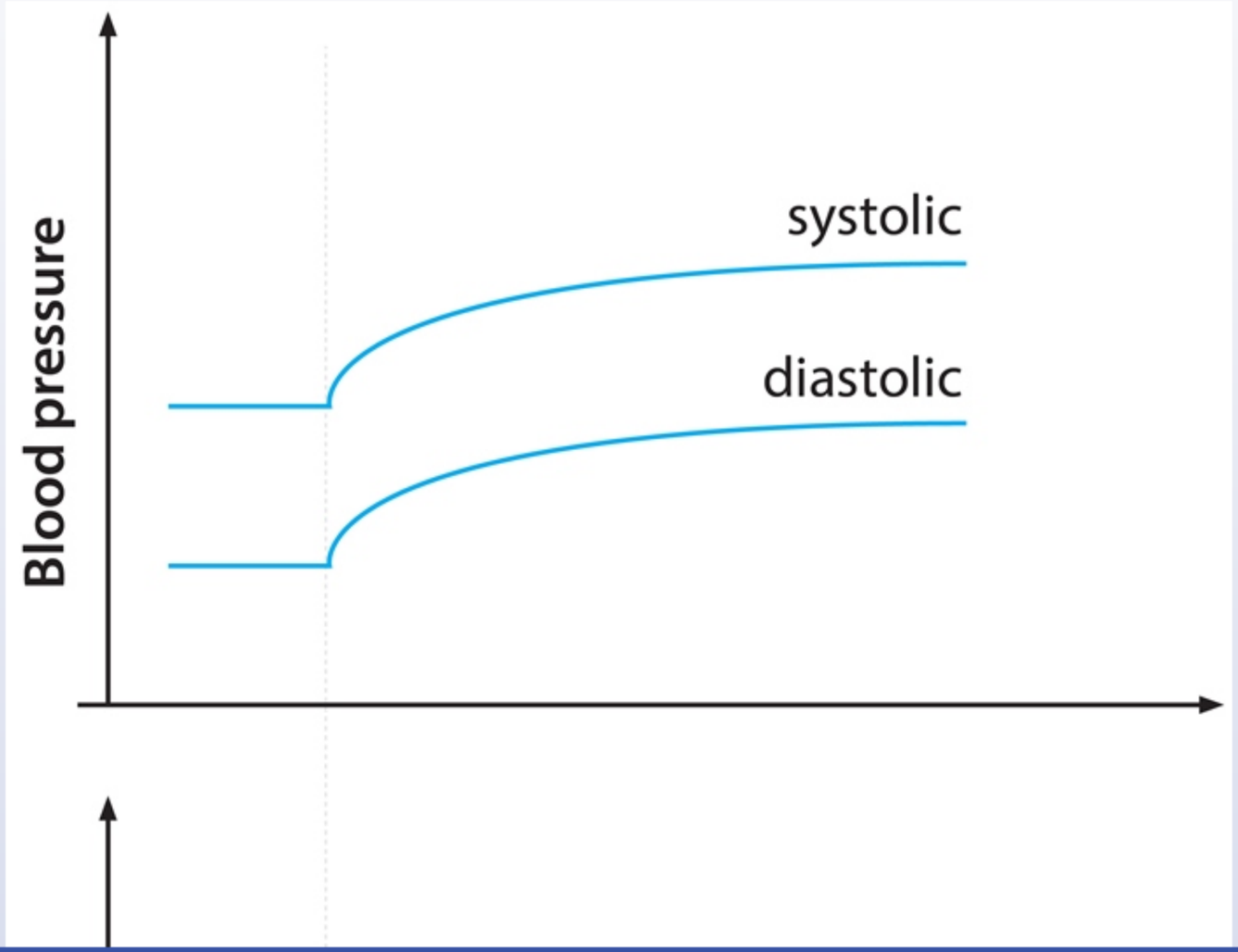

1
2
3
4
5
6
7
8
9
10
11
12
13
14
15
16
17
18
19
20
21
22
23
24
25
26
27
28
29
30
31

Exhibit Display

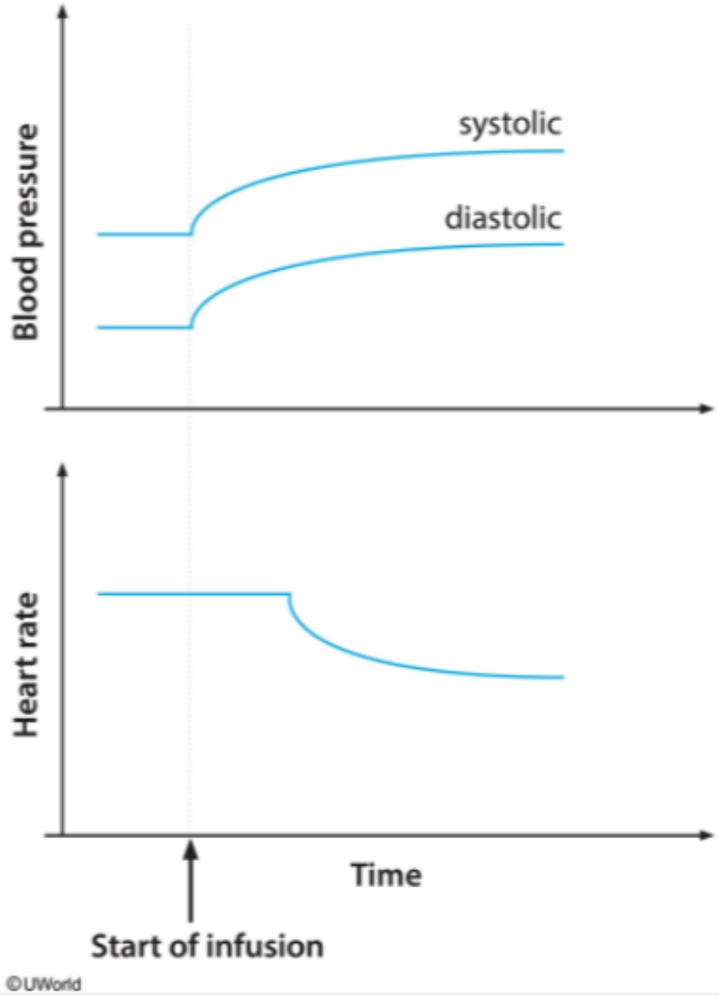

Zoom In | Zoom Out | Reset | Add To New Card | Existing Card

1
2
3
4
5
6
7
8
9
10
11
12
13
14
15
16
17
18
19
20
21
22
23
24
25
26
27
28
29
30
31

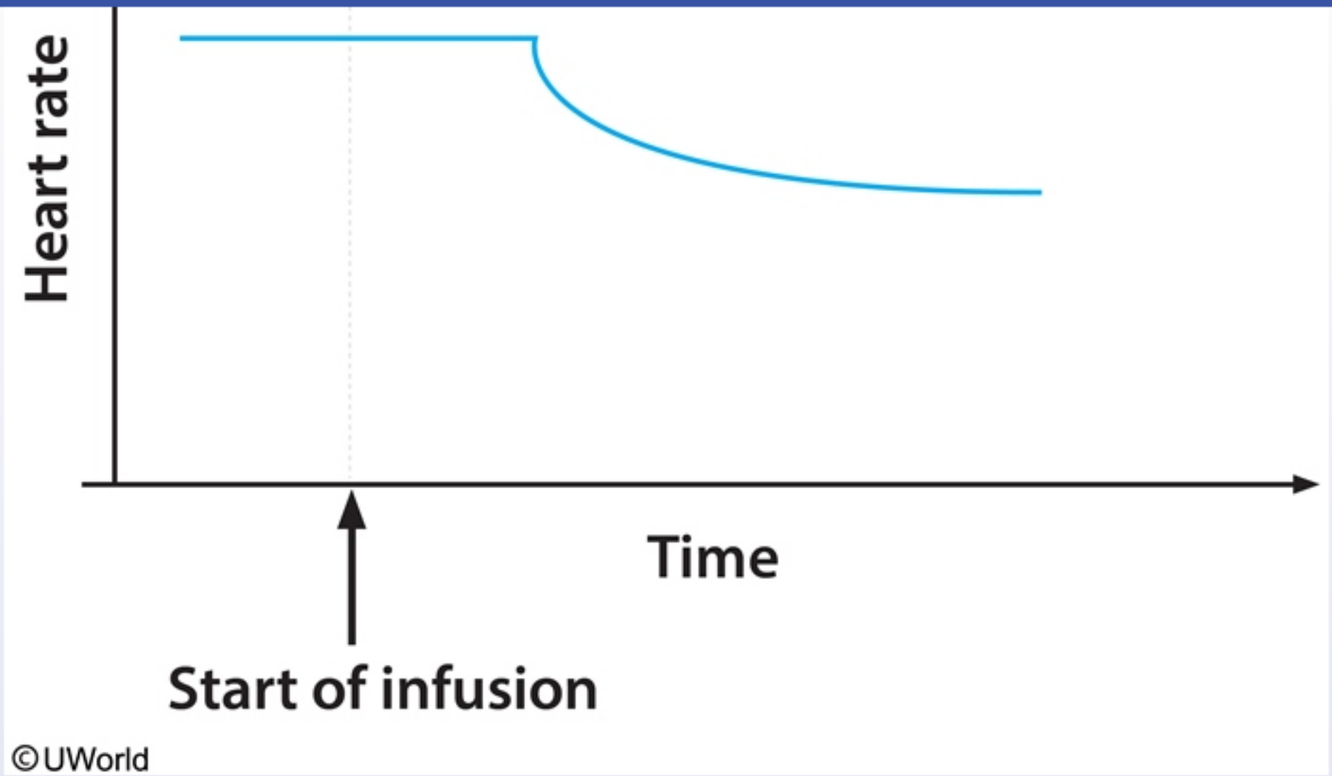

Administration of the drug to healthy individuals would most likely result in which of the following physiologic changes?

A. Decreased atrioventricular node conduction velocity

B. Decreased cardiac afterload

C. Decreased pulmonary capillary wedge pressure

D. Decreased venous tone

E. Increased renal perfusion

1
2
3
4
5
6
7
8
9
10
11
12
13
14
15
16
17
18
19
20
21
22
23
24
25
26
27
28
29
30
31

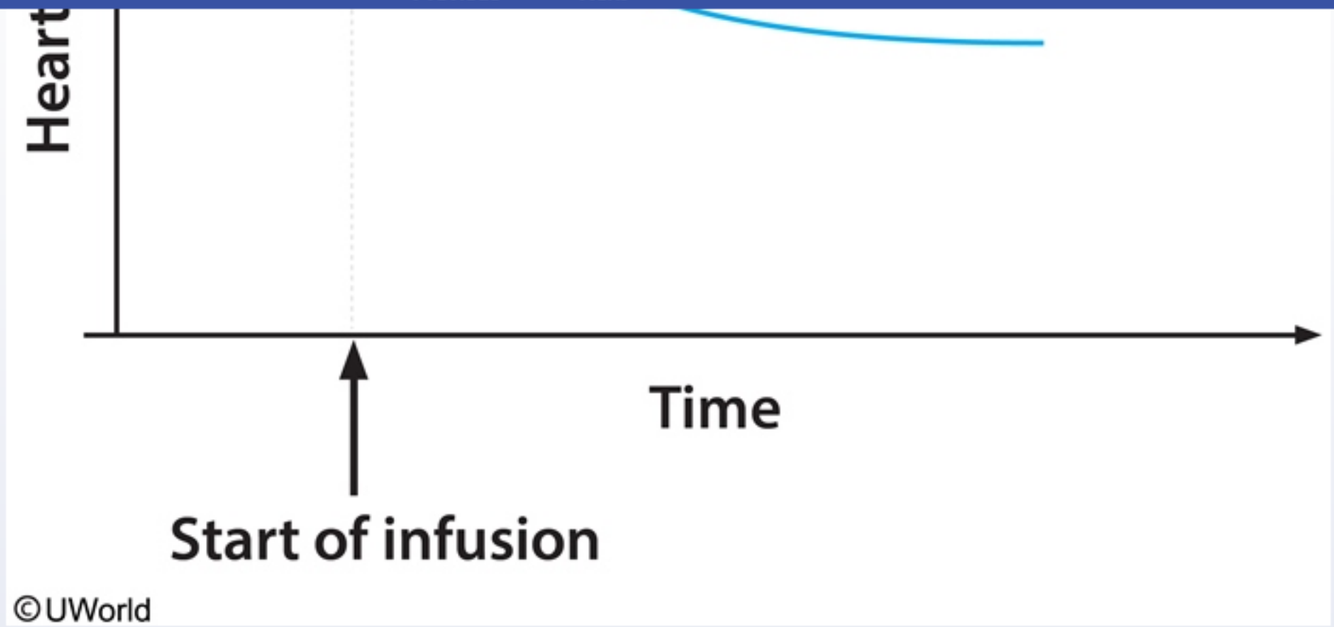

Administration of the drug to healthy individuals would most likely result in which of the following physiologic changes?

- ✓ A. Decreased atrioventricular node conduction velocity (56%)
- B. Decreased cardiac afterload (7%)
- C. Decreased pulmonary capillary wedge pressure (7%)
- D. Decreased venous tone (7%)
- E. Increased renal perfusion (20%)

Omitted
Correct answer

56%
Answered correctly

14 secs
Time Spent

01/07/2020
Last Updated

Direct effects of α-adrenergic agonists	
α_1-mediated	**α_2-mediated**
• Vascular smooth muscle contraction • Mydriasis • ↑ Internal urethral sphincter tone & prostate contraction	• CNS-mediated ↓ in blood pressure • ↓ Intraocular pressure • ↓ Lipolysis • ↓ Presynaptic norepinephrine release • ↑ Platelet aggregation

©UWorld

Administration of the drug caused an increase in systolic and diastolic blood pressures and a reflexive (delayed) decrease in heart rate; these are the typical effects of a **selective α_1-adrenergic agonist** (eg, phenylephrine, methoxamine). Activation of α_1-adrenoreceptors (in blood vessels of skin and viscera) leads to **vasoconstriction** and increased systemic blood pressure. Stimulation of baroreceptors in the carotid sinus and aortic arch causes a **reflexive increase in vagal influence** on the heart. The increased vagal tone results in inhibition of pacemaker activity of the sinoatrial node, slowed conduction through the atrioventricular node, and decreased myocardial contractility.

(Choice B) The vasoconstriction caused by α_1-adrenergic agonists increases blood pressure and cardiac afterload, requiring increased myocardial effort to expel the blood.

(Choices C and D) Pulmonary capillary wedge pressure reflects left atrial pressure. It is increased after administration of α_1-adrenergic agonists due to increases in cardiac afterload (elevates left ventricular end-diastolic pressure) and venous tone (results in augmented venous return).

(Choice E) α_1-adrenergic agonists cause vasoconstriction of the renal and splanchnic arteries, decreasing perfusion to the kidneys and other viscera.

Educational objective:
α-adrenergic agonists increase systolic and diastolic blood pressure by stimulating α_1-adrenoreceptors in the vascular walls, causing vasoconstriction. The elevated systemic blood pressure then causes a reflexive increase in vagal tone, resulting in decreased heart rate and

©UWorld

Administration of the drug caused an increase in systolic and diastolic blood pressures and a reflexive (delayed) decrease in heart rate; these are the typical effects of a **selective α_1-adrenergic agonist** (eg, phenylephrine, methoxamine). Activation of α_1-adrenoreceptors (in blood vessels of skin and viscera) leads to **vasoconstriction** and increased systemic blood pressure. Stimulation of baroreceptors in the carotid sinus and aortic arch causes a **reflexive increase in vagal influence** on the heart. The increased vagal tone results in inhibition of pacemaker activity of the sinoatrial node, slowed conduction through the atrioventricular node, and decreased myocardial contractility.

(Choice B) The vasoconstriction caused by α_1-adrenergic agonists increases blood pressure and cardiac afterload, requiring increased myocardial effort to expel the blood.

(Choices C and D) Pulmonary capillary wedge pressure reflects left atrial pressure. It is increased after administration of α_1-adrenergic agonists due to increases in cardiac afterload (elevates left ventricular end-diastolic pressure) and venous tone (results in augmented venous return).

(Choice E) α_1-adrenergic agonists cause vasoconstriction of the renal and splanchnic arteries, decreasing perfusion to the kidneys and other viscera.

Educational objective:
α-adrenergic agonists increase systolic and diastolic blood pressure by stimulating α_1-adrenoreceptors in the vascular walls, causing vasoconstriction. The elevated systemic blood pressure then causes a reflexive increase in vagal tone, resulting in decreased heart rate and slowed atrioventricular node conduction.

References

- Sympathetic neural mechanisms in human cardiovascular health and disease.
- Neural control of the circulation.
- WB4101- and CEC-sensitive positive inotropic actions of phenylephrine in rat cardiac muscle.

Pharmacology	Cardiovascular System	Sympathomimetic agents
Subject	System	Topic

1
2
3
4
5
6
7
8
9
10
11
12
13
14
15
16
17
18
19
20
21
22
23
24
25
26
27
28
29
30
31

A 56-year-old woman comes to the emergency department with facial swelling and difficulty breathing. She woke up today with a "feeling of fullness" in her lips, and 2 hours later her husband said that her lips looked puffy. There is no itching or skin rash. The patient has had no similar symptoms before. She has a history of gastroesophageal reflux disease and takes lansoprazole daily. She also began taking lisinopril 2 months ago for hypertension. The patient's blood pressure is 135/75 mm Hg. On examination, there is moderate swelling of her lips and tongue. Mild audible stridor without wheezing is present. Which of the following is the most likely mechanism responsible for this patient's symptoms?

- A. Bradykinin accumulation
- B. Hereditary C1-esterase inhibitor deficiency
- C. IgE-dependent mast cell degranulation
- D. Increased renin secretion
- E. Nonimmune mediated mast cell degranulation

Submit

1
2
3
4
5
6
7
8
9
10
11
12
13
14
15
16
17
18
19
20
21
22
23
24
25
26
27
28
29
30
31

A 56-year-old woman comes to the emergency department with facial swelling and difficulty breathing. She woke up today with a "feeling of fullness" in her lips, and 2 hours later her husband said that her lips looked puffy. There is no itching or skin rash. The patient has had no similar symptoms before. She has a history of gastroesophageal reflux disease and takes lansoprazole daily. She also began taking lisinopril 2 months ago for hypertension. The patient's blood pressure is 135/75 mm Hg. On examination, there is moderate swelling of her lips and tongue. Mild audible stridor without wheezing is present. Which of the following is the most likely mechanism responsible for this patient's symptoms?

- ✓ A. Bradykinin accumulation (61%)
- B. Hereditary C1-esterase inhibitor deficiency (22%)
- C. IgE-dependent mast cell degranulation (6%)
- D. Increased renin secretion (1%)
- E. Nonimmune mediated mast cell degranulation (7%)

Omitted
Correct answer
A

61%
Answered correctly

03 secs
Time Spent

02/01/2020
Last Updated

Explanation

Causes of angioedema		
Mast cell activation	• Type 1 hypersensitivity reactions (IgE-mediated) • Direct mast cell activation (eg, opioids)	Associated pruritus & urticaria

Causes of angioedema		
Mast cell activation	• Type 1 hypersensitivity reactions (IgE-mediated) • Direct mast cell activation (eg, opioids)	Associated pruritus & urticaria
Excess bradykinin	• ACE inhibitors • C1 inhibitor deficiency (hereditary/acquired)	No pruritus or urticaria

©UWorld

Angioedema is a rare and potentially serious adverse effect of **ACE inhibitor therapy**. Symptoms typically appear within days of initiation but can also occur after weeks to years of therapy. Although angioedema can affect any tissue, it most commonly involves the tongue, lips, or eyelids. Laryngeal edema and difficulty breathing may also occur.

ACE inhibitor-induced angioedema is due to bradykinin accumulation. Normally, ACE is responsible for bradykinin breakdown. ACE inhibitors prevent bradykinin degradation, leading to increased levels. Bradykinin is a potent **vasodilator** that ultimately increases **vascular permeability**, causing significant angioedema. ACE inhibitors should be **discontinued** in patients who develop angioedema.

(Choice B) Hereditary C1-esterase inhibitor deficiency also causes bradykinin-mediated angioedema, but it usually presents in childhood and early adolescence. This patient's age and history make ACE inhibitor-induced bradykinin accumulation more likely.

(Choice C) Even though IgE-dependent mast cell degranulation can cause angioedema, it is more commonly associated with urticaria and pruritus. True hypersensitivity or an allergy to ACE inhibitors is very rare and not likely in this patient.

(Choice D) ACE inhibitors decrease production of angiotensin II, which reduces negative feedback on the renin-angiotensin-aldosterone system, thereby promoting renin release. Increased renin levels are a natural compensatory response to ACE inhibitor therapy and have no role in causing angioedema.

(Choice E) In nonimmune mediated mast cell degranulation, there is direct activation of mast cells independent of IgE cross-linking. These pseudoallergic reactions can be caused by chemicals, heat, and certain drugs (eg, opiates, vancomycin) and are clinically similar to

©UWorld

Angioedema is a rare and potentially serious adverse effect of **ACE inhibitor therapy**. Symptoms typically appear within days of initiation but can also occur after weeks to years of therapy. Although angioedema can affect any tissue, it most commonly involves the tongue, lips, or eyelids. Laryngeal edema and difficulty breathing may also occur.

ACE inhibitor-induced angioedema is due to bradykinin accumulation. Normally, ACE is responsible for bradykinin breakdown. ACE inhibitors prevent bradykinin degradation, leading to increased levels. Bradykinin is a potent **vasodilator** that ultimately increases **vascular permeability**, causing significant angioedema. ACE inhibitors should be **discontinued** in patients who develop angioedema.

(Choice B) Hereditary C1-esterase inhibitor deficiency also causes bradykinin-mediated angioedema, but it usually presents in childhood and early adolescence. This patient's age and history make ACE inhibitor-induced bradykinin accumulation more likely.

(Choice C) Even though IgE-dependent mast cell degranulation can cause angioedema, it is more commonly associated with urticaria and pruritus. True hypersensitivity or an allergy to ACE inhibitors is very rare and not likely in this patient.

(Choice D) ACE inhibitors decrease production of angiotensin II, which reduces negative feedback on the renin-angiotensin-aldosterone system, thereby promoting renin release. Increased renin levels are a natural compensatory response to ACE inhibitor therapy and have no role in causing angioedema.

(Choice E) In nonimmune mediated mast cell degranulation, there is direct activation of mast cells independent of IgE cross-linking. These pseudoallergic reactions can be caused by chemicals, heat, and certain drugs (eg, opiates, vancomycin) and are clinically similar to hypersensitivity and allergic reactions.

Educational objective:
Angioedema is a rare and serious adverse effect of ACE inhibitor therapy. ACE inhibition increases bradykinin levels, which increase vascular permeability and lead to angioedema. Symptoms include tongue, lips, or eyelid swelling and, less frequently, laryngeal edema and difficulty breathing. ACE inhibitors should be discontinued in affected patients.

References

- Bradykinin and the pathophysiology of angioedema.
- Angioedema from angiotensin-converting enzyme (ACE) inhibitor treated with complement 1 (C1) inhibitor concentrate.

©UWorld

Exhibit Display

Zoom In | Zoom Out | Reset | Add To New Card | Existing Card

- Angioedema from angiotensin-converting enzyme (ACE) inhibitor treated with complement 1 (C1) inhibitor concentrate.

A 65-year-old immigrant from Eastern Europe comes to the physician because of a four-week history of low-grade fever, multiple joint pains, and a well-demarcated erythematous rash on his face and trunk. The patient denies hair loss, mucosal ulceration, or photosensitivity. His serum test is positive for the presence of anti-nuclear antibody (ANA) in very high titers. The patient reports a past medical history of coronary artery disease, congestive heart failure, and "cardiac rhythm abnormalities." This patient should be specifically questioned about the intake of which of the following medications?

- A. Amiodarone
- B. Propranolol
- C. Lidocaine
- D. Procainamide
- E. Verapamil
- F. Adenosine

Submit

1
2
3
4
5
6
7
8
9
10
11
12
13
14
15
16
17
18
19
20
21
22
23
24
25
26
27
28
29
30
31

A 65-year-old immigrant from Eastern Europe comes to the physician because of a four-week history of low-grade fever, multiple joint pains, and a well-demarcated erythematous rash on his face and trunk. The patient denies hair loss, mucosal ulceration, or photosensitivity. His serum test is positive for the presence of anti-nuclear antibody (ANA) in very high titers. The patient reports a past medical history of coronary artery disease, congestive heart failure, and "cardiac rhythm abnormalities." This patient should be specifically questioned about the intake of which of the following medications?

A. Amiodarone (14%)
B. Propranolol (1%)
C. Lidocaine (1%)
✓ D. Procainamide (76%)
E. Verapamil (3%)
F. Adenosine (2%)

Omitted
Correct answer
D

76%
Answered correctly

02 secs
Time Spent

06/24/2020
Last Updated

Explanation

Features of drug-induced lupus erythematosus
• New onset lupus symptoms • Anti-nuclear antibodies (ANA) and **anti-histone**

Features of drug-induced lupus erythematosus

• New onset lupus symptoms
• Anti-nuclear antibodies (ANA) and **anti-histone antibodies** present in > 95% of cases
• Anti-dsDNA antibodies are rarely seen
• Exposure to implicated drugs
  ◦ **Hydralazine**
  ◦ **Procainamide**
  ◦ **Isoniazid**
  ◦ Minocycline
  ◦ Quinidine

Drug-induced lupus erythematosus (DILE) should be considered in patients presenting with signs and symptoms of systemic lupus erythematosus (SLE). Both hydralazine and procainamide are categorized as high-risk drugs for the development of DILE. Procainamide is metabolized via hepatic acetylation. Individuals who are "slow acetylators" are at greatest risk for DILE, while individuals who metabolize the drug more rapidly are less likely to experience this adverse effect. Drug-induced lupus erythematosus occurs in up to 20% of patients taking procainamide.

The presence of autoantibodies can be used to help differentiate DILE from SLE. Although anti-histone antibodies are very common in DILE, they are seen in only 50% of SLE patients. Likewise, anti-dsDNA antibodies are present in 80% of SLE patients, but are rarely seen in DILE. Anti-nuclear antibodies are frequently positive in both diseases.

(Choice A) The most notable side effects of amiodarone include thyroid dysfunction, lung fibrosis, and liver toxicity, as well as a blue or grey discoloration of the skin.

(Choice B) The most frequently encountered adverse effects of nonselective beta-blockers are negative inotropy and bronchoconstriction in patients with asthma or COPD.

(Choice C) The adverse effects of lidocaine are characteristically nonfocal neurologic signs such as tremor, drowsiness, and change in mental status, although lidocaine can also lead to generalized seizures.

Drug-induced lupus erythematosus (DILE) should be considered in patients presenting with signs and symptoms of systemic lupus erythematosus (SLE). Both hydralazine and procainamide are categorized as high-risk drugs for the development of DILE. Procainamide is metabolized via hepatic acetylation. Individuals who are "slow acetylators" are at greatest risk for DILE, while individuals who metabolize the drug more rapidly are less likely to experience this adverse effect. Drug-induced lupus erythematosus occurs in up to 20% of patients taking procainamide.

The presence of autoantibodies can be used to help differentiate DILE from SLE. Although anti-histone antibodies are very common in DILE, they are seen in only 50% of SLE patients. Likewise, anti-dsDNA antibodies are present in 80% of SLE patients, but are rarely seen in DILE. Anti-nuclear antibodies are frequently positive in both diseases.

(Choice A) The most notable side effects of amiodarone include thyroid dysfunction, lung fibrosis, and liver toxicity, as well as a blue or grey discoloration of the skin.

(Choice B) The most frequently encountered adverse effects of nonselective beta-blockers are negative inotropy and bronchoconstriction in patients with asthma or COPD.

(Choice C) The adverse effects of lidocaine are characteristically nonfocal neurologic signs such as tremor, drowsiness, and change in mental status, although lidocaine can also lead to generalized seizures.

(Choice E) Verapamil is a calcium channel blocker and class 4 antiarrhythmic. The most frequently noted adverse reactions include negative inotropy, constipation, and gingival hyperplasia.

(Choice F) Adenosine is used as a vasodilator in chemical cardiac stress tests and as a fast acting antiarrhythmic for stopping acute supraventricular tachycardias. Adenosine has an extremely short half-life, and its immediate adverse effects include chest burning, flushing, and transient hypotension.

Educational objective:
Procainamide and hydralazine have the highest risk of causing drug-induced lupus erythematosus (DILE), which is characterized by the development of lupus-like symptoms in addition to positive ANA and anti-histone antibodies. Unlike with SLE, anti-dsDNA antibodies are rarely seen.

References

- Drug-induced lupus

The presence of autoantibodies can be used to help differentiate DILE from SLE. Although anti-histone antibodies are very common in DILE, they are seen in only 50% of SLE patients. Likewise, anti-dsDNA antibodies are present in 80% of SLE patients, but are rarely seen in DILE. Anti-nuclear antibodies are frequently positive in both diseases.

(Choice A) The most notable side effects of amiodarone include thyroid dysfunction, lung fibrosis, and liver toxicity, as well as a blue or grey discoloration of the skin.

(Choice B) The most frequently encountered adverse effects of nonselective beta-blockers are negative inotropy and bronchoconstriction in patients with asthma or COPD.

(Choice C) The adverse effects of lidocaine are characteristically nonfocal neurologic signs such as tremor, drowsiness, and change in mental status, although lidocaine can also lead to generalized seizures.

(Choice E) Verapamil is a calcium channel blocker and class 4 antiarrhythmic. The most frequently noted adverse reactions include negative inotropy, constipation, and gingival hyperplasia.

(Choice F) Adenosine is used as a vasodilator in chemical cardiac stress tests and as a fast acting antiarrhythmic for stopping acute supraventricular tachycardias. Adenosine has an extremely short half-life, and its immediate adverse effects include chest burning, flushing, and transient hypotension.

Educational objective:
Procainamide and hydralazine have the highest risk of causing drug-induced lupus erythematosus (DILE), which is characterized by the development of lupus-like symptoms in addition to positive ANA and anti-histone antibodies. Unlike with SLE, anti-dsDNA antibodies are rarely seen.

References

- Drug-induced lupus.
- Drug-induced lupus erythematosus: incidence, management and prevention.

Pharmacology	Cardiovascular System	SLE
Subject	System	Topic

1
2
3
4
5
6
7
8
9
10
11
12
13
14
15
16
17
18
19
20
21
22
23
24
25
26
27
28
29
30
31

A 54-year-old man with nonischemic cardiomyopathy comes to the office for a follow-up visit. He has been hospitalized frequently for acute decompensated heart failure, and currently has dyspnea on mild exertion. The patient also has a history of hypertension and takes multiple medications. Blood pressure is 116/70 mm Hg, and pulse is 72/min and regular. Physical examination shows elevated jugular venous pressure, bibasilar lung crackles, and lower extremity edema. Serum creatinine is 1.0 mg/dL and serum potassium is 4.2 mEq/L. Three weeks after starting digoxin therapy, the patient reports symptomatic improvement. Which of the following is the initial cellular event triggering this response to the new medication?

A. Decreased sodium efflux from myocardial cells

B. Increased intracellular calcium concentration

C. Increased intracellular cyclic AMP concentration

D. Increased potassium influx into myocardial cells

E. Troponin sensitization to calcium

Submit

1
2
3
4
5
6
7
8
9
10
11
12
13
14
15
16
17
18
19
20
21
22
23
24
25
26
27
28
29
30
31

A 54-year-old man with nonischemic cardiomyopathy comes to the office for a follow-up visit. He has been hospitalized frequently for acute decompensated heart failure, and currently has dyspnea on mild exertion. The patient also has a history of hypertension and takes multiple medications. Blood pressure is 116/70 mm Hg, and pulse is 72/min and regular. Physical examination shows elevated jugular venous pressure, bibasilar lung crackles, and lower extremity edema. Serum creatinine is 1.0 mg/dL and serum potassium is 4.2 mEq/L. Three weeks after starting digoxin therapy, the patient reports symptomatic improvement. Which of the following is the initial cellular event triggering this response to the new medication?

- ✓ A. Decreased sodium efflux from myocardial cells (59%)
- B. Increased intracellular calcium concentration (31%)
- C. Increased intracellular cyclic AMP concentration (4%)
- D. Increased potassium influx into myocardial cells (4%)
- E. Troponin sensitization to calcium (0%)

Omitted
Correct answer
A

59%
Answered correctly

02 secs
Time Spent

06/09/2020
Last Updated

Explanation

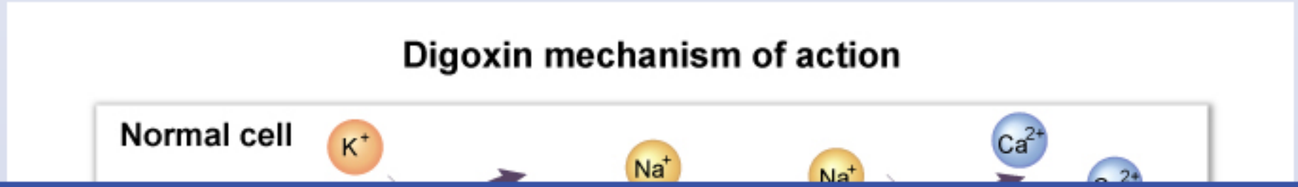

1
2
3
4
5
6
7
8
9
10
11
12
13
14
15
16
17
18
19
20
21
22
23
24
25
26
27
28
29
30
31

Digoxin mechanism of action

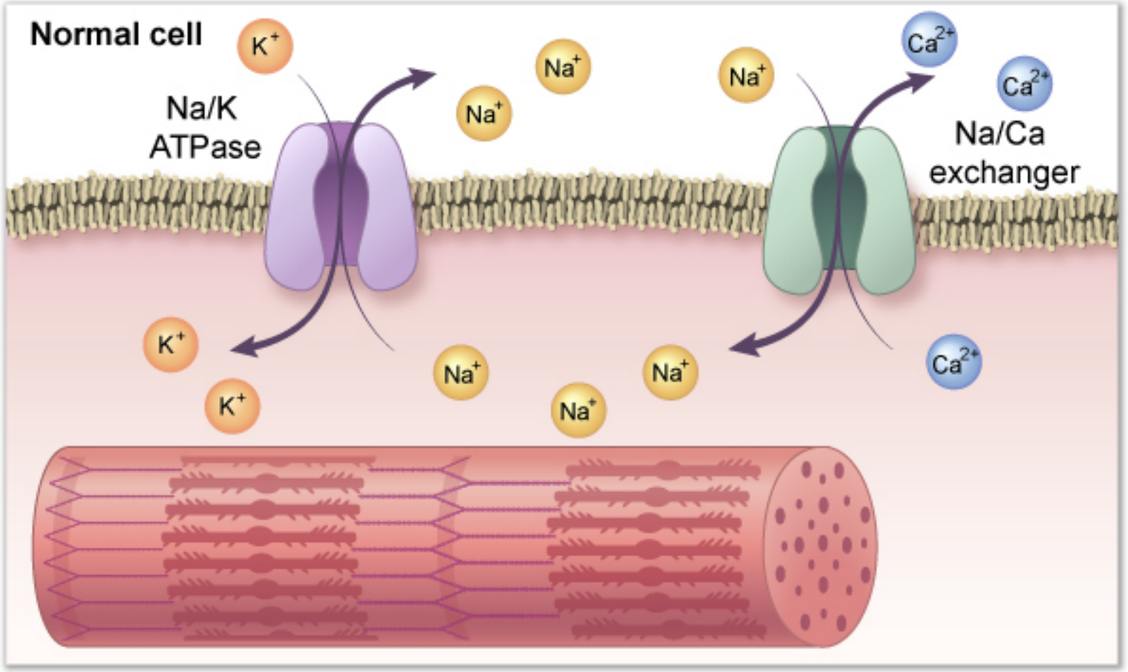

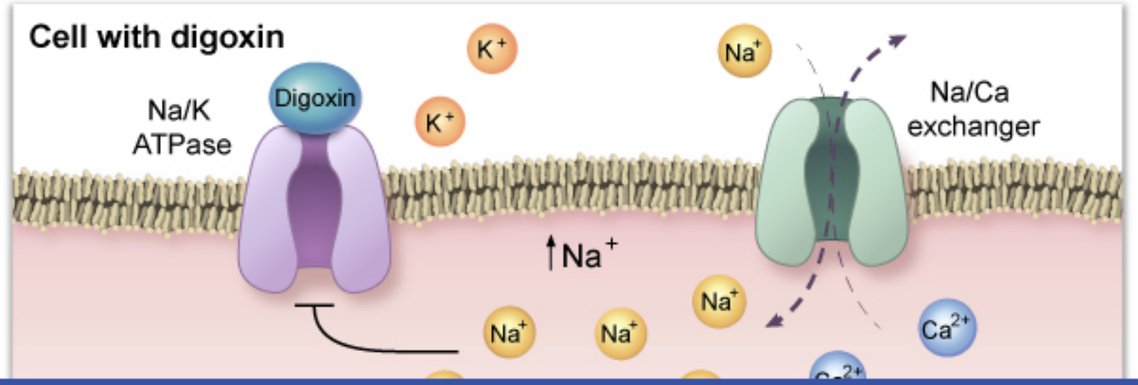

Digoxin mechanism of action

Exhibit Display

Digoxin mechanism of action

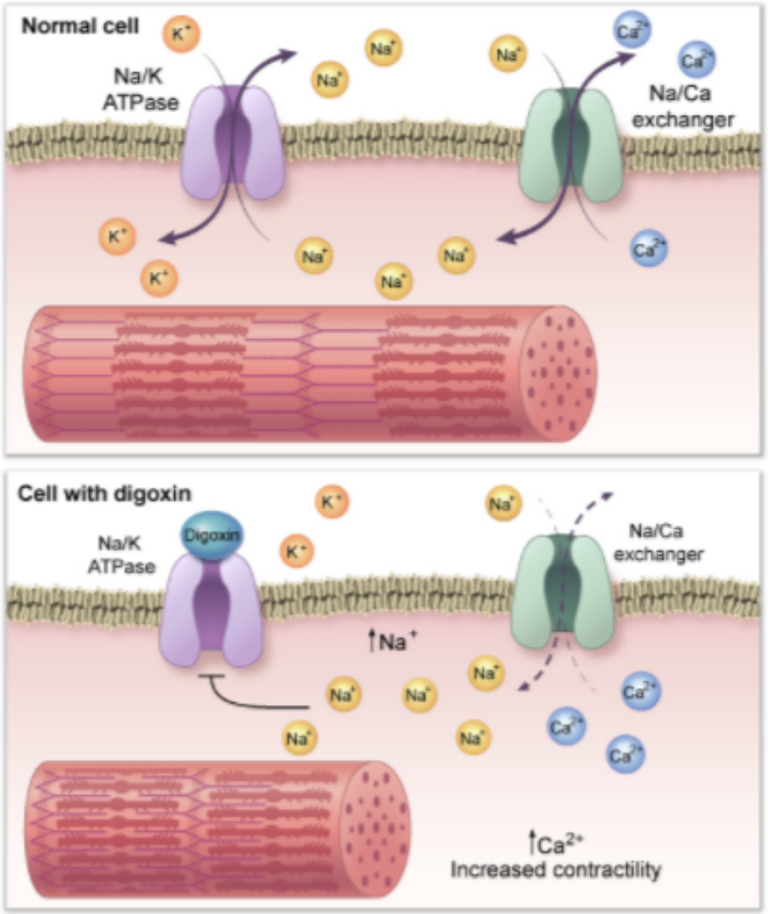

©UWorld

Zoom In | Zoom Out | Reset | Add To New Card | Existing Card

Digoxin is a **positive inotropic agent** that provides symptomatic relief in patients with acute decompensated heart failure due to left ventricular systolic dysfunction. It also increases parasympathetic tone and slows conduction through the atrioventricular node, which can help improve cardiac function in patients with a rapid ventricular rate.

Digoxin directly **inhibits the Na-K-ATPase pump** in myocardial cells, leading to **decreased sodium efflux** and an increase in intracellular sodium levels. The decreased transmembrane sodium gradient reduces the forward activity of the sodium-calcium exchanger, leading to a secondary **decrease in calcium efflux** from the cells. Increased intracellular calcium concentration stimulates the binding of calcium to troponin C and subsequent actin-myosin cross-bridge formation, resulting in **improved myocyte contractility** and left ventricular systolic function.

(Choice B) The increase in intracellular sodium caused by digoxin reduces the forward activity of the sodium-calcium exchanger, resulting in increased intracellular calcium concentration. However, the calcium increase is a secondary effect of digoxin that occurs after the increase in intracellular sodium.

(Choice C) Cyclic AMP (cAMP), an important second messenger in excitation-contraction coupling, is formed from ATP by adenylyl cyclase. Adenylyl cyclase activity is stimulated by beta agonists and inhibited by acetylcholine. cAMP increases the conductance of the calcium channels in the sarcoplasmic reticulum. As a result, more calcium is available to bind to troponin C, strengthening the force of contraction.

(Choice D) Inhibition of the Na-K-ATPase pump by digoxin leads to a decrease in potassium influx into myocardial cells.

(Choice E) Digoxin does not cause increased troponin sensitivity to calcium; instead, it increases the amount of intracellular calcium available for troponin binding.

Educational objective:
Digoxin directly inhibits the Na-K-ATPase pump in myocardial cells, leading to a decrease in sodium efflux and an increase in intracellular sodium levels. This reduces the forward activity of the sodium-calcium exchanger, causing increased intracellular calcium concentration and improved myocyte contractility.

Pharmacology	Cardiovascular System	Digoxin
Subject	System	Topic

Copyright © UWorld. All rights reserved.

1
2
3
4
5
6
7
8
9
10
11
12
13
14
15
16
17
18
19
20
21
22
23
24
25
26
27
28
29
30
31

A 65-year-old man is brought to the emergency department due to central chest pain for the past 2 hours. The patient describes the pain as "very severe" and "going back all the way to my spine." He has never had similar pain. Medical history is significant for hypertension; the patient has been nonadherent with prescribed medical therapy and follow-up visits. He has a 20-pack-year smoking history. Blood pressure is 195/101 mm Hg, and pulse is 93/min and regular. Chest examination reveals clear lungs. ECG shows sinus rhythm and voltage criteria for left ventricular hypertrophy. Portable chest x-ray reveals a widened mediastinum. The patient is immediately treated with intravenous esmolol. Which of the following is the most likely purpose of this patient's current therapy?

A. Decreasing left ventricular contraction velocity
B. Decreasing myocardial oxygen demand
C. Decreasing peripheral vascular resistance
D. Increasing left ventricular filling pressure
E. Increasing left ventricular stroke volume

Submit

A 65-year-old man is brought to the emergency department due to central chest pain for the past 2 hours. The patient describes the pain as "very severe" and "going back all the way to my spine." He has never had similar pain. Medical history is significant for hypertension; the patient has been nonadherent with prescribed medical therapy and follow-up visits. He has a 20-pack-year smoking history. Blood pressure is 195/101 mm Hg, and pulse is 93/min and regular. Chest examination reveals clear lungs. ECG shows sinus rhythm and voltage criteria for left ventricular hypertrophy. Portable chest x-ray reveals a widened mediastinum. The patient is immediately treated with intravenous esmolol. Which of the following is the most likely purpose of this patient's current therapy?

- ✓ A. Decreasing left ventricular contraction velocity (43%)
- B. Decreasing myocardial oxygen demand (42%)
- C. Decreasing peripheral vascular resistance (9%)
- D. Increasing left ventricular filling pressure (1%)
- E. Increasing left ventricular stroke volume (3%)

Omitted
Correct answer
A

43%
Answered correctly

02 secs
Time Spent

06/17/2020
Last Updated

Explanation

This patient's severe chest pain **radiating to the back** and a **widened mediastinum** on chest x-ray are consistent with **acute aortic dissection**. Uncontrolled **hypertension**, suggested by the patient's nonadherence with medical therapy and ECG evidence of left ventricular (LV) hypertrophy, is the strongest risk factor for aortic dissection.

With each LV contraction, the ejected stroke volume rapidly increases aortic pressure and generates shear stress on the aortic wall. Medical

This patient's severe chest pain **radiating to the back** and a **widened mediastinum** on chest x-ray are consistent with **acute aortic dissection**. Uncontrolled **hypertension**, suggested by the patient's nonadherence with medical therapy and ECG evidence of left ventricular (LV) hypertrophy, is the strongest risk factor for aortic dissection.

With each LV contraction, the ejected stroke volume rapidly increases aortic pressure and generates shear stress on the aortic wall. Medical therapy for aortic dissection is aimed at **reducing aortic wall shear stress** to limit extension of the dissection. This is accomplished via **anti-impulse therapy** to decrease the rate of change in aortic blood pressure per time (ie, reduce dP/dt).

Esmolol is a selective **beta-1 receptor blocker** that is given by intravenous infusion. It is first-line therapy for acute aortic dissection as it has a short half-life (allowing for easy dose titration) and reduces shear stress in 2 ways:

- Negative inotropy **decreases LV contraction velocity**. This decreases the rate of blood ejection and reduces stroke volume **(Choice E)** to decrease the rise in blood pressure with each contraction (ie, decreased rate and magnitude of blood pressure change).
- Negative chronotropy **decreases heart rate**, subjecting the aortic wall to fewer LV contractions per minute (ie, decreased number of blood pressure changes).

Once shear stress has been minimized with adequate reduction in LV contractility and heart rate, decreasing peripheral vascular resistance (PVR) to further reduce blood pressure is also beneficial. Because esmolol has little effect on PVR **(Choice C)**, vasodilators (eg, nitroprusside, nicardipine) may be added for this purpose. Vasodilators should never be given prior to a negative chronotropic agent because vasodilation causes reflex tachycardia that increases aortic wall shear stress.

(Choice B) Reduced LV contractility and heart rate decrease myocardial oxygen demand. Although this is the major goal of medical therapy for treating myocardial ischemia, reducing aortic wall shear stress is much more important for treating aortic dissection.

(Choice D) Reduced LV contractility and heart rate may slightly increase LV filling pressure (due to less blood being ejected with each contraction and increased LV filling time), but this effect is of minimal consequence in treating aortic dissection.

Educational objective:
The primary goal of medical therapy for acute aortic dissection is to reduce aortic wall shear stress by minimizing the change in aortic blood pressure per time (dP/dt). Esmolol, a selective beta-1 receptor blocker, decreases left ventricular contraction velocity and heart rate to reduce dP/dt.

short half-life (allowing for easy dose titration) and reduces shear stress in 2 ways:

- Negative inotropy **decreases LV contraction velocity**. This decreases the rate of blood ejection and reduces stroke volume **(Choice E)** to decrease the rise in blood pressure with each contraction (ie, decreased rate and magnitude of blood pressure change).
- Negative chronotropy **decreases heart rate**, subjecting the aortic wall to fewer LV contractions per minute (ie, decreased number of blood pressure changes).

Once shear stress has been minimized with adequate reduction in LV contractility and heart rate, decreasing peripheral vascular resistance (PVR) to further reduce blood pressure is also beneficial. Because esmolol has little effect on PVR **(Choice C)**, vasodilators (eg, nitroprusside, nicardipine) may be added for this purpose. Vasodilators should never be given prior to a negative chronotropic agent because vasodilation causes reflex tachycardia that increases aortic wall shear stress.

(Choice B) Reduced LV contractility and heart rate decrease myocardial oxygen demand. Although this is the major goal of medical therapy for treating myocardial ischemia, reducing aortic wall shear stress is much more important for treating aortic dissection.

(Choice D) Reduced LV contractility and heart rate may slightly increase LV filling pressure (due to less blood being ejected with each contraction and increased LV filling time), but this effect is of minimal consequence in treating aortic dissection.

Educational objective:
The primary goal of medical therapy for acute aortic dissection is to reduce aortic wall shear stress by minimizing the change in aortic blood pressure per time (dP/dt). Esmolol, a selective beta-1 receptor blocker, decreases left ventricular contraction velocity and heart rate to reduce dP/dt.

References

- Managing dissections of the thoracic aorta.

Pharmacology	Cardiovascular System	Aortic dissection
Subject	System	Topic

Copyright © UWorld. All rights reserved.

1
2
3
4
5
6
7
8
9
10
11
12
13
14
15
16
17
18
19
20
21
22
23
24
25
26
27
28
29
30
31

A 43-year-old man comes to the emergency department due to a 3-day history of persistent headaches. The patient has a history of hypertension and has had poor medical follow-up. Blood pressure is 224/115 mm Hg and pulse is 67/min. He appears mildly confused during the physical examination, but no focal neurologic deficits are noted. Funduscopic examination shows bilateral papilledema. Serum creatinine is 1.4 mg/dL. An intravenous medication is initiated that causes arteriolar dilation while also improving renal perfusion and increasing natriuresis. Which of the following agents is most likely being used in this patient?

A. Esmolol
B. Fenoldopam
C. Hydralazine
D. Nitroglycerin
E. Phenylephrine

Submit

1 2 3 4 5 6 7 8 9 10 11 12 13 14 15 16 17 18 19 20 21 22 23 24 25 26 27 28 29 30 31

A 43-year-old man comes to the emergency department due to a 3-day history of persistent headaches. The patient has a history of hypertension and has had poor medical follow-up. Blood pressure is 224/115 mm Hg and pulse is 67/min. He appears mildly confused during the physical examination, but no focal neurologic deficits are noted. Funduscopic examination shows bilateral papilledema. Serum creatinine is 1.4 mg/dL. An intravenous medication is initiated that causes arteriolar dilation while also improving renal perfusion and increasing natriuresis. Which of the following agents is most likely being used in this patient?

A. Esmolol (5%)
✓ B. Fenoldopam (52%)
C. Hydralazine (34%)
D. Nitroglycerin (6%)
E. Phenylephrine (1%)

Omitted
Correct answer
B

52%
Answered correctly

02 secs
Time Spent

02/24/2020
Last Updated

Explanation

Hypertensive crisis	
Hypertensive urgency	• Severe hypertension (≥180/120 mm Hg) • No evidence of end-organ damage
	• Severe hypertension with **end-organ damage**:

Hypertensive crisis	
Hypertensive urgency	• Severe hypertension (≥180/120 mm Hg) • No evidence of end-organ damage
Hypertensive emergency	• Severe hypertension with **end-organ damage**: ◦ Cardiovascular: angina, myocardial infarction, aortic dissection ◦ CNS: encephalopathy, cerebral infarct/hemorrhage ◦ Kidney: acute hypertensive nephrosclerosis ◦ Lung: pulmonary edema ◦ Retina: papilledema, flame-shaped hemorrhages, exudates

This patient has **severe hypertension**. In addition, he has clinical evidence of secondary **end-organ damage**, including encephalopathy (eg, confusion), papilledema, and acute kidney injury (eg, elevated creatinine). This presentation is consistent with **hypertensive emergency** and requires aggressive treatment with immediate but controlled blood pressure reduction to minimize organ damage. Intravenous agents are preferred in hypertensive emergency due to their rapid action and dose titration ability.

Fenoldopam is a short-acting, selective, peripheral **dopamine-1 receptor agonist** with little to no effect on alpha- or beta-adrenergic receptors. Dopamine-1 receptor stimulation activates adenylyl cyclase and raises intracellular cyclic AMP, resulting in vasodilation of most arterial beds with a corresponding decrease in systemic blood pressure. **Renal vasodilation** is particularly prominent and leads to **increased renal perfusion**, increased urine output, and **natriuresis** (ie, sodium excretion). This makes fenoldopam especially beneficial in patients with hypertensive emergency and renal insufficiency.

(Choice A) Esmolol is a short-acting, cardioselective beta-1 receptor antagonist. It works by reducing heart rate and myocardial contractility. Esmolol is not a vasodilator and does not increase renal perfusion.

(Choice C) Hydralazine is a direct arteriolar vasodilator; however, it does not dilate renal arterioles and may decrease renal perfusion and encourage sodium and fluid retention. It is not often used in hypertensive emergency because it is associated with reflex sympathetic activation, resulting in increased heart rate and contractility.

(Choice D) Nitroglycerin is a rapid-acting venodilator that decreases preload and cardiac output. It causes only minimal arterial dilation and does

This patient has **severe hypertension**. In addition, he has clinical evidence of secondary **end-organ damage**, including encephalopathy (eg, confusion), papilledema, and acute kidney injury (eg, elevated creatinine). This presentation is consistent with **hypertensive emergency** and requires aggressive treatment with immediate but controlled blood pressure reduction to minimize organ damage. Intravenous agents are preferred in hypertensive emergency due to their rapid action and dose titration ability.

Fenoldopam is a short-acting, selective, peripheral **dopamine-1 receptor agonist** with little to no effect on alpha- or beta-adrenergic receptors. Dopamine-1 receptor stimulation activates adenylyl cyclase and raises intracellular cyclic AMP, resulting in vasodilation of most arterial beds with a corresponding decrease in systemic blood pressure. **Renal vasodilation** is particularly prominent and leads to **increased renal perfusion**, increased urine output, and **natriuresis** (ie, sodium excretion). This makes fenoldopam especially beneficial in patients with hypertensive emergency and renal insufficiency.

(Choice A) Esmolol is a short-acting, cardioselective beta-1 receptor antagonist. It works by reducing heart rate and myocardial contractility. Esmolol is not a vasodilator and does not increase renal perfusion.

(Choice C) Hydralazine is a direct arteriolar vasodilator; however, it does not dilate renal arterioles and may decrease renal perfusion and encourage sodium and fluid retention. It is not often used in hypertensive emergency because it is associated with reflex sympathetic activation, resulting in increased heart rate and contractility.

(Choice D) Nitroglycerin is a rapid-acting venodilator that decreases preload and cardiac output. It causes only minimal arterial dilation and does not improve renal perfusion. Nitroglycerin is primarily used to reduce myocardial oxygen demand in acute coronary syndrome.

(Choice E) Phenylephrine is an alpha-adrenergic agonist that causes an increase in systemic vascular resistance due to arterial vasoconstriction. It is used in patients with hypotension or shock and is contraindicated in hypertensive emergency.

Educational objective:
Fenoldopam is a selective peripheral dopamine-1 receptor agonist. It causes vasodilation of systemic and renal arterioles to lower blood pressure while also increasing renal perfusion, urine output, and natriuresis, making it useful in the treatment of hypertensive emergency in patients with renal insufficiency.

References

- Fenoldopam.

1
2
3
4
5
6
7
8
9
10
11
12
13
14
15
16
17
18
19
20
21
22
23
24
25
26
27
28
29
30
31

A 76-year-old woman is brought to the emergency department by her son due to lethargy and confusion over the past 2 days. The patient has persistent atrial fibrillation and congestive heart failure and is on multiple medications. Recently, she has had nausea and decreased appetite. Today, she had 3 episodes of vomiting. The patient also reports vision difficulties. Temperature is 36.7 C (98 F) and blood pressure is 133/80 mm Hg. Laboratory results are as follows:

Sodium	140 mEq/L
Potassium	5.7 mEq/L
Calcium	9.3 mg/dL
Creatinine	1.2 mg/dL
Glucose	85 mg/dL

ECG shows junctional escape rhythm at a rate of 48/min with occasional ventricular premature beats. Increased blood level of which of the following medications is most likely responsible for her symptoms?

- A. Amiodarone
- B. Aspirin
- C. Digoxin
- D. Diltiazem
- E. Furosemide
- F. Metoprolol
- G. Spironolactone
- H. Valsartan

1
2
3
4
5
6
7
8
9
10
11
12
13
14
15
16
17
18
19
20
21
22
23
24
25
26
27
28
29
30
31

persistent atrial fibrillation and congestive heart failure and is on multiple medications. Recently, she has had nausea and decreased appetite. Today, she had 3 episodes of vomiting. The patient also reports vision difficulties. Temperature is 36.7 C (98 F) and blood pressure is 133/80 mm Hg. Laboratory results are as follows:

Sodium	140 mEq/L
Potassium	5.7 mEq/L
Calcium	9.3 mg/dL
Creatinine	1.2 mg/dL
Glucose	85 mg/dL

ECG shows junctional escape rhythm at a rate of 48/min with occasional ventricular premature beats. Increased blood level of which of the following medications is most likely responsible for her symptoms?

A. Amiodarone
B. Aspirin
C. Digoxin
D. Diltiazem
E. Furosemide
F. Metoprolol
G. Spironolactone
H. Valsartan

1
2
3
4
5
6
7
8
9
10
11
12
13
14
15
16
17
18
19
20
21
22
23
24
25
26
27
28
29
30
31

Hg. Laboratory results are as follows:

Sodium	140 mEq/L
Potassium	5.7 mEq/L
Calcium	9.3 mg/dL
Creatinine	1.2 mg/dL
Glucose	85 mg/dL

ECG shows junctional escape rhythm at a rate of 48/min with occasional ventricular premature beats. Increased blood level of which of the following medications is most likely responsible for her symptoms?

- A. Amiodarone (10%)
- B. Aspirin (0%)
- ✓ C. Digoxin (59%)
- D. Diltiazem (2%)
- E. Furosemide (2%)
- F. Metoprolol (2%)
- G. Spironolactone (21%)
- H. Valsartan (1%)

Omitted
Correct answer

59%
Answered correctly

04 secs
Time Spent

05/05/2020
Last Updated

Symptoms of digoxin toxicity	
Cardiac	• **Life-threateningarrhythmias**
Gastrointestinal	• Anorexia • Nausea & vomiting • Abdominal pain
Neurologic	• Fatigue • Confusion • Weakness • **Color vision alterations**

This patient with atrial fibrillation and congestive heart failure has signs and symptoms of **digoxin toxicity**. Although calcium channel blockers and beta blockers are the preferred treatments for patients with atrial fibrillation with rapid ventricular response, digoxin is a common second-line treatment that is particularly useful in patients with underlying systolic cardiac dysfunction. Its major effects are:

1. **Increased vagal tone**, causing slowing of conduction through the atrioventricular (AV) node (rate-control effect)
2. Na-K-ATPase inhibition, causing increased intracellular sodium and calcium (increases cardiac contractility)

Digoxin has a narrow therapeutic index, making toxicity relatively common. Symptoms of digoxin intoxication are fairly **nonspecific** and include nausea, abdominal pain, fatigue, dizziness, confusion, blurred vision, and abnormal color perception. Digoxin toxicity can cause a wide range of **cardiac arrhythmias**, including bradycardia and junctional escape beats due to increased AV nodal block. Hypokalemia can precipitate toxicity by increasing digoxin binding to Na-K-ATPase. However, **elevated potassium** is a sign of digoxin toxicity as inhibition of Na-K-ATPase pumps increases extracellular potassium.

(Choice A) Amiodarone can cause pulmonary toxicity, thyroid dysfunction, cardiac arrhythmias, elevated liver enzymes, and visual disturbances. However, it does not cause hyperkalemia.

(Choice B) Acute aspirin overdose presents with vertigo, tinnitus, vomiting, and diarrhea, whereas severe intoxication can lead to coma, hyperpyrexia, pulmonary edema, and death.

1
2
3
4
5
6
7
8
9
10
11
12
13
14
15
16
17
18
19
20
21
22
23
24
25
26
27
28
29
30
31

This patient with atrial fibrillation and congestive heart failure has signs and symptoms of **digoxin toxicity**. Although calcium channel blockers and beta blockers are the preferred treatments for patients with atrial fibrillation with rapid ventricular response, digoxin is a common second-line treatment that is particularly useful in patients with underlying systolic cardiac dysfunction. Its major effects are:

1. **Increased vagal tone**, causing slowing of conduction through the atrioventricular (AV) node (rate-control effect)
2. Na-K-ATPase inhibition, causing increased intracellular sodium and calcium (increases cardiac contractility)

Digoxin has a narrow therapeutic index, making toxicity relatively common. Symptoms of digoxin intoxication are fairly **nonspecific** and include nausea, abdominal pain, fatigue, dizziness, confusion, blurred vision, and abnormal color perception. Digoxin toxicity can cause a wide range of **cardiac arrhythmias**, including bradycardia and junctional escape beats due to increased AV nodal block. Hypokalemia can precipitate toxicity by increasing digoxin binding to Na-K-ATPase. However, **elevated potassium** is a sign of digoxin toxicity as inhibition of Na-K-ATPase pumps increases extracellular potassium.

(Choice A) Amiodarone can cause pulmonary toxicity, thyroid dysfunction, cardiac arrhythmias, elevated liver enzymes, and visual disturbances. However, it does not cause hyperkalemia.

(Choice B) Acute aspirin overdose presents with vertigo, tinnitus, vomiting, and diarrhea, whereas severe intoxication can lead to coma, hyperpyrexia, pulmonary edema, and death.

(Choices D and F) Beta blocker and/or calcium channel blocker overdose usually cause profound bradycardia and hypotension (absent in this patient). In addition, nausea and vomiting are more common in digoxin overdose than in beta blocker overdose, which typically causes bronchospasm and hypoglycemia.

(Choice E) Furosemide overdose causes volume depletion, along with electrolyte abnormalities such as hypokalemia and hypomagnesemia.

(Choice G) Excess spironolactone can cause hyperkalemia, gynecomastia, impotence, and decreased libido.

(Choice H) Valsartan is an angiotensin II receptor blocker. Overdose usually causes hypotension, renal failure, and hyperkalemia.

Educational objective:
Digoxin toxicity typically presents with cardiac arrhythmias and nonspecific gastrointestinal (nausea, vomiting), neurological (confusion, weakness), and visual symptoms. Elevated potassium is another sign of digoxin toxicity and is caused by inhibition of Na-K-ATPase pumps.

This patient with atrial fibrillation and congestive heart failure has signs and symptoms of **digoxin toxicity**. Although calcium channel blockers

Exhibit Display

Digoxin mechanism of action

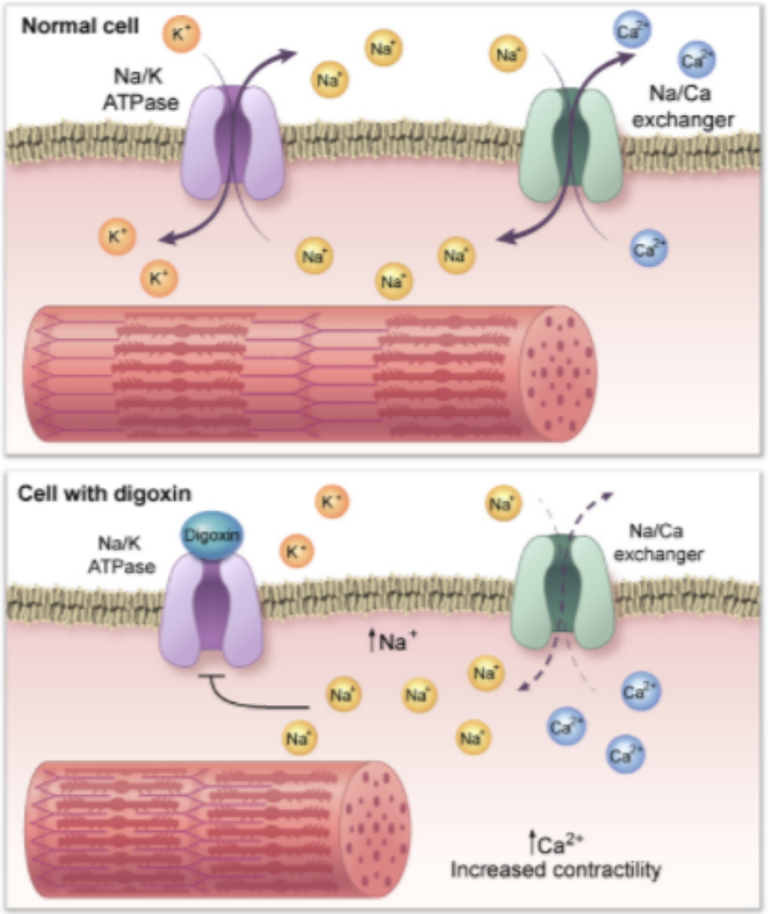

©UWorld

Zoom In | Zoom Out | Reset | Add To New Card | Existing Card

treatment), and medical symptoms. Elevated potassium is another sign of digoxin toxicity and is caused by inhibition of Na/K ATPase pumps.

1
2
3
4
5
6
7
8
9
10
11
12
13
14
15
16
17
18
19
20
21
22
23
24
25
26
27
28
29
30
31

nausea, abdominal pain, fatigue, dizziness, confusion, blurred vision, and abnormal color perception. Digoxin toxicity can cause a wide range of **cardiac arrhythmias**, including bradycardia and junctional escape beats due to increased AV nodal block. Hypokalemia can precipitate toxicity by increasing digoxin binding to Na-K-ATPase. However, **elevated potassium** is a sign of digoxin toxicity as inhibition of Na-K-ATPase pumps increases extracellular potassium.

(Choice A) Amiodarone can cause pulmonary toxicity, thyroid dysfunction, cardiac arrhythmias, elevated liver enzymes, and visual disturbances. However, it does not cause hyperkalemia.

(Choice B) Acute aspirin overdose presents with vertigo, tinnitus, vomiting, and diarrhea, whereas severe intoxication can lead to coma, hyperpyrexia, pulmonary edema, and death.

(Choices D and F) Beta blocker and/or calcium channel blocker overdose usually cause profound bradycardia and hypotension (absent in this patient). In addition, nausea and vomiting are more common in digoxin overdose than in beta blocker overdose, which typically causes bronchospasm and hypoglycemia.

(Choice E) Furosemide overdose causes volume depletion, along with electrolyte abnormalities such as hypokalemia and hypomagnesemia.

(Choice G) Excess spironolactone can cause hyperkalemia, gynecomastia, impotence, and decreased libido.

(Choice H) Valsartan is an angiotensin II receptor blocker. Overdose usually causes hypotension, renal failure, and hyperkalemia.

Educational objective:
Digoxin toxicity typically presents with cardiac arrhythmias and nonspecific gastrointestinal (nausea, vomiting), neurological (confusion, weakness), and visual symptoms. Elevated potassium is another sign of digoxin toxicity and is caused by inhibition of Na-K-ATPase pumps.

References

- Mechanisms, manifestations, and management of digoxin toxicity in the modern era.

Pharmacology	Cardiovascular System	Digoxin
Subject	System	Topic

Copyright © UWorld. All rights reserved.

1
2
3
4
5
6
7
8
9
10
11
12
13
14
15
16
17
18
19
20
21
22
23
24
25
26
27
28
29
30
31

A 34-year-old man diagnosed with advanced non-Hodgkin lymphoma undergoes doxorubicin-containing chemotherapy with good clinical response. Several weeks after the last chemotherapy cycle, the patient comes to the office with progressive exertional dyspnea. He has difficulty sleeping flat at night and needs to use multiple pillows to fall asleep. The patient is a lifetime nonsmoker and has no family history of heart disease. Blood pressure is 124/72 mm Hg, pulse is 86/min, and respirations are 16/min. Oxygen saturation on room air is 96%. Which of the following is most likely responsible for this patient's current symptoms?

A. Dilated cardiomyopathy
B. Focal myocardial scarring
C. Hypertrophic cardiomyopathy
D. Pericardial thickening and fibrosis
E. Restrictive cardiomyopathy
F. Right ventricular pressure overload

Submit

A 34-year-old man diagnosed with advanced non-Hodgkin lymphoma undergoes doxorubicin-containing chemotherapy with good clinical response. Several weeks after the last chemotherapy cycle, the patient comes to the office with progressive exertional dyspnea. He has difficulty sleeping flat at night and needs to use multiple pillows to fall asleep. The patient is a lifetime nonsmoker and has no family history of heart disease. Blood pressure is 124/72 mm Hg, pulse is 86/min, and respirations are 16/min. Oxygen saturation on room air is 96%. Which of the following is most likely responsible for this patient's current symptoms?

- ✓ A. Dilated cardiomyopathy (75%)
- B. Focal myocardial scarring (1%)
- C. Hypertrophic cardiomyopathy (2%)
- D. Pericardial thickening and fibrosis (6%)
- E. Restrictive cardiomyopathy (10%)
- F. Right ventricular pressure overload (3%)

Omitted
Correct answer
A

75%
Answered correctly

02 secs
Time Spent

01/23/2020
Last Updated

Explanation

Specific toxicities of common chemotherapeutic agents		
Chemotherapy agent	Mechanism of Action	Toxicity

Specific toxicities of common chemotherapeutic agents		
Chemotherapy agent	**Mechanism of Action**	**Toxicity**
Anthracyclines (eg, doxorubicin)	• Binds with topoisomerase II to cleave DNA • Binds with iron to generate free radicals	• Dilated cardiomyopathy
Bleomycin	• Induces free radical formation	• Pulmonary fibrosis
Cisplatin	• Cross-links DNA to inhibit DNA synthesis	• Nephrotoxicity • Ototoxicity • Peripheral neuropathy
Cyclophosphamide	• Cross-links DNA to inhibit DNA synthesis	• Hemorrhagic cystitis • Bladder cancer
Paclitaxel	• Inhibits microtubule disassembly	• Neuropathy
Vincristine/ vinblastine	• Binds beta-tubulin to inhibit microtubule formation	• Neuropathy

Anthracyclines (eg, daunorubicin, doxorubicin) are chemotherapeutic agents associated with severe cardiotoxicity that manifests as **dilated cardiomyopathy**. The toxicity is dependent on the cumulative dose of anthracycline; affected patients develop symptoms of heart failure (eg, dyspnea on exertion, orthopnea, peripheral edema) anywhere from several weeks to years following treatment.

Anthracyclines exert their antitumor effect by binding to the **topoisomerase II** enzyme in cancer cells to create DNA cleavage complexes that **break DNA** and cause cell death. Anthracycline cardiotoxicity results from a similar anthracycline–topoisomerase II complex that forms in healthy cardiomyocytes. In addition, anthracycline can form iron-containing complexes that produce DNA-damaging free radicals, which likely also plays a role in cardiotoxicity.

The most effective method of preventing anthracycline-induced cardiomyopathy is the administration of **dexrazoxane**, a chelating agent thought to both block the formation of iron-associated free radicals and inhibit the formation of anthracycline–topoisomerase II complexes in healthy cardiomyocytes.

Anthracyclines (eg, daunorubicin, doxorubicin) are chemotherapeutic agents associated with severe cardiotoxicity that manifests as **dilated cardiomyopathy**. The toxicity is dependent on the cumulative dose of anthracycline; affected patients develop symptoms of heart failure (eg, dyspnea on exertion, orthopnea, peripheral edema) anywhere from several weeks to years following treatment.

Anthracyclines exert their antitumor effect by binding to the **topoisomerase II** enzyme in cancer cells to create DNA cleavage complexes that **break DNA** and cause cell death. Anthracycline cardiotoxicity results from a similar anthracycline–topoisomerase II complex that forms in healthy cardiomyocytes. In addition, anthracycline can form iron-containing complexes that produce DNA-damaging free radicals, which likely also plays a role in cardiotoxicity.

The most effective method of preventing anthracycline-induced cardiomyopathy is the administration of **dexrazoxane**, a chelating agent thought to both block the formation of iron-associated free radicals and inhibit the formation of anthracycline–topoisomerase II complexes in healthy cardiomyocytes.

(Choice B) Focal myocardial scarring commonly results following a myocardial infarction.

(Choice C) Hypertrophic cardiomyopathy is an autosomal dominant disorder often caused by mutation of the beta-myosin heavy chain.

(Choice D) Pericardial thickening and fibrosis usually follow cardiac surgery, radiation therapy, or viral infections of the pericardium.

(Choice E) Restrictive cardiomyopathy often occurs as the initial cardiac manifestation of infiltrative disease (eg, hemochromatosis, amyloidosis, sarcoidosis) or may occur with radiation therapy.

(Choice F) Right ventricular pressure overload can occur with acute pulmonary embolism. Although this patient with malignancy is at increased risk for venous thromboembolic disease, orthopnea is not explained by acute pulmonary embolism and is more consistent with heart failure.

Educational objective:
Anthracycline chemotherapeutic agents (eg, doxorubicin, daunorubicin) cause cardiotoxicity mainly through the formation of anthracycline–topoisomerase II DNA cleavage complexes that affect healthy cardiomyocytes. The cardiotoxicity is dependent on the cumulative dose of anthracycline received, and it manifests as dilated cardiomyopathy.

References

- Anthracycline chemotherapy and cardiotoxicity.

1
2
3
4
5
6
7
8
9
10
11
12
13
14
15
16
17
18
19
20
21
22
23
24
25
26
27
28
29
30
31

A 40-year-old female with a history of depression and hypertension is brought to the ER after being found obtunded in her apartment. She is hypotensive and bradycardic on physical examination. Intravenous glucagon is administered, and her condition improves. Which of the following intracellular changes is most likely responsible for the improvement in her condition?

A. Increased synaptic release of glutamate

B. Decreased cAMP in vascular smooth muscle

C. Decreased DAG in vascular smooth muscle

D. Increased cAMP in cardiac myocytes

E. Increased IP_3 in cardiac myocytes

Submit

1
2
3
4
5
6
7
8
9
10
11
12
13
14
15
16
17
18
19
20
21
22
23
24
25
26
27
28
29
30
31

A 40-year-old female with a history of depression and hypertension is brought to the ER after being found obtunded in her apartment. She is hypotensive and bradycardic on physical examination. Intravenous glucagon is administered, and her condition improves. Which of the following intracellular changes is most likely responsible for the improvement in her condition?

A. Increased synaptic release of glutamate (3%)

B. Decreased cAMP in vascular smooth muscle (12%)

C. Decreased DAG in vascular smooth muscle (3%)

✓ D. Increased cAMP in cardiac myocytes (67%)

E. Increased IP_3 in cardiac myocytes (12%)

Omitted
Correct answer
D

67%
Answered correctly

02 secs
Time Spent

02/03/2020
Last Updated

Explanation

This patient has most likely overdosed on beta blocker medications. Beta blocker overdose causes diffuse non-selective blockade of peripheral beta adrenergic receptors, causing depression of myocardial contractility, bradycardia, and varying degrees of AV block. The result is a low cardiac output state.

Glucagon is the drug of choice for beta blocker overdose. Glucagon acts on G protein-coupled receptors, increasing intracellular cAMP and thus increasing the release of intracellular calcium during muscle contraction. This increases heart rate and cardiac contractility. Improvements in heart rate and blood pressure may be observed within minutes.

Educational Objective:

D. Increased cAMP in cardiac myocytes (67%)

E. Increased IP_3 in cardiac myocytes (12%)

Omitted
Correct answer
D

67%
Answered correctly

02 secs
Time Spent

02/03/2020
Last Updated

Explanation

This patient has most likely overdosed on beta blocker medications. Beta blocker overdose causes diffuse non-selective blockade of peripheral beta adrenergic receptors, causing depression of myocardial contractility, bradycardia, and varying degrees of AV block. The result is a low cardiac output state.

Glucagon is the drug of choice for beta blocker overdose. Glucagon acts on G protein-coupled receptors, increasing intracellular cAMP and thus increasing the release of intracellular calcium during muscle contraction. This increases heart rate and cardiac contractility. Improvements in heart rate and blood pressure may be observed within minutes.

Educational Objective:
Patients who have overdosed on beta blockers should be treated with glucagon, which increases heart rate and contractility independent of adrenergic receptors. Glucagon activates G-protein-coupled receptors on cardiac myocytes, causing activation of adenylate cyclase and raising intracellular cAMP. The result is calcium release from intracellular stores and increased sinoatrial node firing.

Pharmacology	Cardiovascular System	Beta blocker poisoning
Subject	System	Topic

Copyright © UWorld. All rights reserved.

1
2
3
4
5
6
7
8
9
10
11
12
13
14
15
16
17
18
19
20
21
22
23
24
25
26
27
28
29
30
31

A 25-year-old man comes to the office due to shortness of breath. He states that even moderate exertion forces him to stop to catch his breath. The patient has no family history of sudden cardiac death. He does not use tobacco or illicit drugs. On examination, the patient has a faint systolic murmur at the left sternal border in the supine position that increases to 3/6 in intensity with Valsalva maneuver. Echocardiogram shows interventricular septal hypertrophy and increased left ventricular mass. The patient is started on high-dose beta blocker therapy. On follow-up 4 weeks later, he reports significant improvement in his shortness of breath. Physical examination reveals no murmurs supine or with Valsalva. Which of the following best accounts for improvement of this patient's symptoms?

A. Dilation of epicardial coronary arteries

B. Increase in left ventricular outflow tract flow velocity

C. Reduction in left ventricular contractility

D. Reduction in left ventricular mass

E. Reduction in left ventricular preload

Submit

1
2
3
4
5
6
7
8
9
10
11
12
13
14
15
16
17
18
19
20
21
22
23
24
25
26
27
28
29
30
31

A 25-year-old man comes to the office due to shortness of breath. He states that even moderate exertion forces him to stop to catch his breath. The patient has no family history of sudden cardiac death. He does not use tobacco or illicit drugs. On examination, the patient has a faint systolic murmur at the left sternal border in the supine position that increases to 3/6 in intensity with Valsalva maneuver. Echocardiogram shows interventricular septal hypertrophy and increased left ventricular mass. The patient is started on high-dose beta blocker therapy. On follow-up 4 weeks later, he reports significant improvement in his shortness of breath. Physical examination reveals no murmurs supine or with Valsalva. Which of the following best accounts for improvement of this patient's symptoms?

- A. Dilation of epicardial coronary arteries (2%)
- B. Increase in left ventricular outflow tract flow velocity (16%)
- ✓ C. Reduction in left ventricular contractility (63%)
- D. Reduction in left ventricular mass (4%)
- E. Reduction in left ventricular preload (13%)

Omitted
Correct answer
C

63%
Answered correctly

02 secs
Time Spent

01/23/2020
Last Updated

Explanation

This patient's echocardiogram shows increased left ventricular (LV) mass with predominant **interventricular septal hypertrophy**, which are classic findings for **hypertrophic cardiomyopathy** (HCM). Many patients with HCM have LV outflow tract obstruction that can lead to symptoms of poor cardiac output (eg, dyspnea, syncope). The outflow tract **obstruction worsens with decreased LV blood volume** (as can occur during exercise due to decreased LV filling time and increased LV contractility); on physical examination, this effect is evidenced by a systolic murmur that

This patient's echocardiogram shows increased left ventricular (LV) mass with predominant **interventricular septal hypertrophy**, which are classic findings for **hypertrophic cardiomyopathy** (HCM). Many patients with HCM have LV outflow tract obstruction that can lead to symptoms of poor cardiac output (eg, dyspnea, syncope). The outflow tract **obstruction worsens with decreased LV blood volume** (as can occur during exercise due to decreased LV filling time and increased LV contractility); on physical examination, this effect is evidenced by a systolic murmur that increases in intensity with maneuvers that decrease LV blood volume (eg, Valsalva strain phase, abrupt standing).

In patients with HCM and symptomatic LV outflow tract obstruction, **beta blockers** (eg, metoprolol, nadolol) **improve symptoms** mostly via an **increase in LV volume** that reduces LV outflow tract obstruction and improves cardiac output. This occurs via the following 2 mechanisms:

- Beta blockers **reduce heart rate**, which lengthens diastolic filling time and increases the amount of blood that can enter the heart during each beat (increasing end-diastolic volume)
- Beta blockers also **reduce LV contractility**, which reduces the amount of blood ejected during systole (increasing end-systolic volume)

(Choice A) Some patients with HCM may experience anginal symptoms due to inadequate blood supply to the increased myocardial mass. Beta blockers may help alleviate these symptoms by decreasing LV wall stress to reduce myocardial oxygen demand and improve the coronary artery perfusion gradient; however, they have minimal dilatory effect on the coronary arteries.

(Choice B) By increasing the cross-sectional area of the LV outflow tract, beta blockers tend to decrease flow velocity (flow velocity = volumetric flow rate / cross-sectional area). Consequently, the intensity of the HCM murmur is also decreased.

(Choice D) Over time, beta blockers may reduce the compensatory LV hypertrophy that can occur in HCM due to prolonged contraction against the outflow tract obstruction (similar to aortic stenosis); however, this effect would not be evident within 4 weeks.

(Choice E) Beta blockers increase LV preload to reduce LV outflow tract obstruction and improve symptoms.

Educational objective:
Many patients with hypertrophic cardiomyopathy have poor cardiac reserve (eg, exercise intolerance) due to left ventricular (LV) outflow tract obstruction. This outflow obstruction is worsened by decreased LV blood volume. Beta blockers decrease heart rate and LV contractility to increase LV blood volume, reduce LV outflow tract obstruction, and improve symptoms.

1
2
3
4
5
6
7
8
9
10
11
12
13
14
15
16
17
18
19
20
21
22
23
24
25
26
27
28
29
30
31

This patient's echocardiogram shows increased left ventricular (LV) mass with predominant **interventricular septal hypertrophy**, which are classic findings for **hypert** ms
of poor cardiac output (eg ng
exercise due to decreased that
increases in intensity with

In patients with HCM and
increase in LV volume th

- Beta blockers **reduc**
  each beat (increasir
- Beta blockers also r

(Choice A) Some patient Beta
blockers may help alleviat ry
perfusion gradient; howev

(Choice B) By increasing ric
flow rate / cross-sectional

(Choice D) Over time, be st
the outflow tract obstructic

(Choice E) Beta blockers

Educational objective:
Many patients with hypert
obstruction. This outflow
increase LV blood volume

Exhibit Display

0:00

exercise due to decreased LV filling time and increased LV contractility); on physical examination, this effect is evidenced by a systolic murmur that increases in intensity with maneuvers that decrease LV blood volume (eg, Valsalva strain phase, abrupt standing).

In patients with HCM and symptomatic LV outflow tract obstruction, **beta blockers** (eg, metoprolol, nadolol) **improve symptoms** mostly via an **increase in LV volume** that reduces LV outflow tract obstruction and improves cardiac output. This occurs via the following 2 mechanisms:

- Beta blockers **reduce heart rate**, which lengthens diastolic filling time and increases the amount of blood that can enter the heart during each beat (increasing end-diastolic volume)
- Beta blockers also **reduce LV contractility**, which reduces the amount of blood ejected during systole (increasing end-systolic volume)

(Choice A) Some patients with HCM may experience anginal symptoms due to inadequate blood supply to the increased myocardial mass. Beta blockers may help alleviate these symptoms by decreasing LV wall stress to reduce myocardial oxygen demand and improve the coronary artery perfusion gradient; however, they have minimal dilatory effect on the coronary arteries.

(Choice B) By increasing the cross-sectional area of the LV outflow tract, beta blockers tend to decrease flow velocity (flow velocity = volumetric flow rate / cross-sectional area). Consequently, the intensity of the HCM murmur is also decreased.

(Choice D) Over time, beta blockers may reduce the compensatory LV hypertrophy that can occur in HCM due to prolonged contraction against the outflow tract obstruction (similar to aortic stenosis); however, this effect would not be evident within 4 weeks.

(Choice E) Beta blockers increase LV preload to reduce LV outflow tract obstruction and improve symptoms.

Educational objective:
Many patients with hypertrophic cardiomyopathy have poor cardiac reserve (eg, exercise intolerance) due to left ventricular (LV) outflow tract obstruction. This outflow obstruction is worsened by decreased LV blood volume. Beta blockers decrease heart rate and LV contractility to increase LV blood volume, reduce LV outflow tract obstruction, and improve symptoms.

Pharmacology	Cardiovascular System	Hypertrophic cardiomyopathy
Subject	System	Topic

Copyright © UWorld. All rights reserved.

1
2
3
4
5
6
7
8
9
10
11
12
13
14
15
16
17
18
19
20
21
22
23
24
25
26
27
28
29
30
31

A 23-year-old man comes to the office with chest discomfort that usually occurs during exercise, such as when jogging or climbing stairs. The symptoms go away 5 to 10 minutes after he stops. The patient has not had syncope but mentions some shortness of breath that accompanies the chest pain. Family history includes an uncle who died suddenly at the age of 35 years. Blood pressure is 122/70 mm Hg and pulse is 70/min and regular. Apical impulse is strong and sustained. He has a soft crescendo-decrescendo systolic murmur at the apex and left sternal border while supine that becomes quite pronounced when he stands up. Which of the following medications should be avoided while treating this patient's condition?

A. Amiodarone
B. Disopyramide
C. Isosorbide dinitrate
D. Metoprolol
E. Verapamil

Submit

A 23-year-old man comes to the office with chest discomfort that usually occurs during exercise, such as when jogging or climbing stairs. The symptoms go away 5 to 10 minutes after he stops. The patient has not had syncope but mentions some shortness of breath that accompanies the chest pain. Family history includes an uncle who died suddenly at the age of 35 years. Blood pressure is 122/70 mm Hg and pulse is 70/min and regular. Apical impulse is strong and sustained. He has a soft crescendo-decrescendo systolic murmur at the apex and left sternal border while supine that becomes quite pronounced when he stands up. Which of the following medications should be avoided while treating this patient's condition?

- A. Amiodarone (16%)
- B. Disopyramide (11%)
- ✓ C. Isosorbide dinitrate (42%)
- D. Metoprolol (15%)
- E. Verapamil (13%)

Omitted
Correct answer
C

42%
Answered correctly

02 secs
Time Spent

01/08/2020
Last Updated

Explanation

This patient's presentation, family history of premature sudden death, and systolic murmur that accentuates with standing from a supine position is consistent with **hypertrophic cardiomyopathy** (HCM). Patients with HCM have dynamic left ventricular outflow tract (LVOT) obstruction that worsens with decreased left ventricular (LV) volume (as can be caused by decreased preload and/or reduced systemic vascular resistance). As such, medications that generally should be **avoided** in patients with HCM include:

1
2
3
4
5
6
7
8
9
10
11
12
13
14
15
16
17
18
19
20
21
22
23
24
25
26
27
28
29
30
31

Explanation

This patient's presentation, family history of premature sudden death, and systolic murmur that accentuates with standing from a supine position is consistent with **hypertrophic cardiomyopathy** (HCM). Patients with HCM have dynamic left ventricular outflow tract (LVOT) obstruction that worsens with decreased left ventricular (LV) volume (as can be caused by decreased preload and/or reduced systemic vascular resistance). As such, medications that generally should be **avoided** in patients with HCM include:

- **Vasodilators** (eg, dihydropyridine calcium channel blockers, nitroglycerin, and ACE inhibitors) decrease systemic vascular resistance, leading to decreased afterload and lower LV volumes.
- **Diuretics** decrease LV venous filling (preload) and also result in greater outflow obstruction.

In contrast, **negative inotropic agents** such as beta blockers (metoprolol), nondihydropyridine calcium channel blockers (verapamil), and disopyramide **reduce LVOT obstruction** and are helpful in symptomatic patients with HCM **(Choices B, D, and E)**. In addition, beta blockers may also help reduce anginal symptoms by decreasing myocardial oxygen demand.

(Choice A) Amiodarone can be used occasionally to manage symptomatic atrial or ventricular arrhythmias in patients with hypertrophic cardiomyopathy. It has no specific role in the management of asymptomatic patients with HCM.

Educational objective:
The dynamic left ventricular (LV) outflow tract obstruction that occurs in hypertrophic cardiomyopathy worsens with decreased LV volume, which can be caused by reduction in cardiac preload and/or afterload. Therefore, medications that decrease venous return or systemic vascular resistance (dihydropyridine calcium channel blockers, nitroglycerin) should generally be avoided.

References

- Hypertrophic cardiomyopathy: a systematic review.

Pharmacology	Cardiovascular System	Hypertrophic cardiomyopathy
Subject	System	Topic

Copyright © UWorld. All rights reserved.

1
2
3
4
5
6
7
8
9
10
11
12
13
14
15
16
17
18
19
20
21
22
23
24
25
26
27
28
29
30
31

A 37-year-old man comes the emergency department due to fever, chills, and malaise. He has no significant medical history but he uses illicit intravenous drugs on a regular basis. The patient is febrile, tachycardic, and hypotensive. Auscultation reveals a heart murmur. A preliminary diagnosis of infective endocarditis is established. Blood cultures grow methicillin-resistant *Staphylococcus aureus*, and the patient is prescribed an intravenous antibiotic administered every 12 hours. Calculation of the maintenance dose will most likely require which of the following parameters?

A. Drug clearance rate

B. Number of doses needed to reach steady state

C. Size of the loading dose

D. Total body weight of the patient

E. Volume of distribution of the drug

Submit

1 2 3 4 5 6 7 8 9 10 11 12 13 14 15 16 17 18 19 20 21 22 23 24 25 26 27 28 29 30 31

A 37-year-old man comes the emergency department due to fever, chills, and malaise. He has no significant medical history but he uses illicit intravenous drugs on a regular basis. The patient is febrile, tachycardic, and hypotensive. Auscultation reveals a heart murmur. A preliminary diagnosis of infective endocarditis is established. Blood cultures grow methicillin-resistant *Staphylococcus aureus*, and the patient is prescribed an intravenous antibiotic administered every 12 hours. Calculation of the maintenance dose will most likely require which of the following parameters?

- ✓ A. Drug clearance rate (59%)
- B. Number of doses needed to reach steady state (6%)
- C. Size of the loading dose (9%)
- D. Total body weight of the patient (7%)
- E. Volume of distribution of the drug (16%)

Omitted
Correct answer
A

Collecting Statistics

02 secs
Time Spent

07/01/2020
Last Updated

Explanation

Pharmacokinetic parameter	Formula	Note
Half life	$V_d \times 0.7 / CL$	Steady-state concentration is achieved in 4-5 half-lives.

Pharmacokinetic parameter	Formula	Note
Half life	$V_d \times 0.7 / CL$	Steady-state concentration is achieved in 4-5 half-lives.
Maintenance dose	$C_{ss} \times CL \times$ dosing interval	Maintenance dose is decreased in patients with renal or hepatic impairment.
Loading dose	$V_d \times C_{ss}$	Loading dose is affected by body weight and composition.

CL = drug clearance; **Css** = steady-state plasma concentration; **Vd** = volume of distribution.

Most drugs are administered in the form of repetitive, intermittent doses designed to achieve a steady-state plasma concentration within a targeted therapeutic range. The amount of each dose is calculated so that the administered dose is just enough to replace the amount of drug eliminated by the body since the last dose. This replacement dose **(maintenance dose)** depends on both of the following:

- **Steady-state plasma concentration (C_{ss})**
- **Drug clearance (CL)**, or volume of plasma cleared of drug per unit time (eg, mL/min)

Multiplying these two parameters gives the elimination rate, or the amount of drug eliminated from the body per unit of time:

$$\text{Elimination rate} = C_{ss} \times CL$$

The maintenance dose can then be calculated for the appropriate dosing interval (eg, 12 hr) by multiplying the elimination rate ($C_{ss} \times CL$) by the **time between doses**:

$$\textbf{Maintenance dose} = C_{ss} \times CL \times \textbf{dosing interval}$$

(Choice B) When a drug is administered more quickly than it can be eliminated from the body, it accumulates until a steady-state level is reached; as plasma concentration increases, the amount of drug eliminated also increases until the amount administered equals the amount eliminated. When a drug is administered at regular intervals, the time needed to reach the steady state level depends only on the drug half-life (ie, it takes 5

- Steady-state plasma concentration (C_{ss})
- **Drug clearance (CL)**, or volume of plasma cleared of drug per unit time (eg, mL/min)

Multiplying these two parameters gives the elimination rate, or the amount of drug eliminated from the body per unit of time:

$$\text{Elimination rate} = C_{SS} \times CL$$

The maintenance dose can then be calculated for the appropriate dosing interval (eg, 12 hr) by multiplying the elimination rate ($C_{SS} \times CL$) by the **time between doses**:

$$\textbf{Maintenance dose} = C_{SS} \times CL \times \textbf{dosing interval}$$

(Choice B) When a drug is administered more quickly than it can be eliminated from the body, it accumulates until a steady-state level is reached; as plasma concentration increases, the amount of drug eliminated also increases until the amount administered equals the amount eliminated. When a drug is administered at regular intervals, the time needed to reach the steady state level depends only on the drug half-life (ie, it takes 5 half-lives to reach 97% of the steady-state level); the exact size of each dose or interval between doses does not matter.

(Choices C, D, and E) Loading doses are larger than maintenance doses and can be used during treatment initiation to shorten the time needed to reach target steady-state plasma concentrations. They are most useful when an immediate therapeutic response is needed (eg, life-saving antibiotics) or when using drugs with large volumes of distribution (eg, amiodarone). Total body weight influences the volume of distribution and is often used when calculating the loading dose. However, these parameters are not needed when calculating the maintenance dose because the amount of drug lost per unit of time depends only on the steady-state plasma concentration and drug clearance.

Educational objective:
Clearance (CL) determines the dose rate required to maintain a given steady-state plasma concentration (C_{ss}):

$$\text{Maintenance dose} = C_{SS} \times CL \times \text{dosing interval}$$

Pharmacology	Cardiovascular System	Serum drug levels and half-life
Subject	System	Topic

Copyright © UWorld. All rights reserved.

1
2
3
4
5
6
7
8
9
10
11
12
13
14
15
16
17
18
19
20
21
22
23
24
25
26
27
28
29
30
31

A 46-year-old man is diagnosed with resistant hypertension. He had a comprehensive workup for secondary hypertension, which was unrevealing. The patient has tried multiple antihypertensive medications without significant effect. Past medical history is otherwise unremarkable. He agrees to enroll in a trial of a new long-acting medication that causes selective direct relaxation of the smooth muscle of arterioles but does not affect the veins. Which of the following adverse effects is most likely to be caused by the drug during the clinical trial?

- A. Angioedema
- B. Bradycardia
- C. Cold extremities
- D. Decreased cardiac output
- E. Persistent cough
- F. Sodium and fluid retention
- G. Transient hypertension

Submit

1
2
3
4
5
6
7
8
9
10
11
12
13
14
15
16
17
18
19
20
21
22
23
24
25
26
27
28
29
30
31

A 46-year-old man is diagnosed with resistant hypertension. He had a comprehensive workup for secondary hypertension, which was unrevealing. The patient has tried multiple antihypertensive medications without significant effect. Past medical history is otherwise unremarkable. He agrees to enroll in a trial of a new long-acting medication that causes selective direct relaxation of the smooth muscle of arterioles but does not affect the veins. Which of the following adverse effects is most likely to be caused by the drug during the clinical trial?

- A. Angioedema (18%)
- B. Bradycardia (9%)
- C. Cold extremities (8%)
- D. Decreased cardiac output (14%)
- E. Persistent cough (6%)
- ✓ F. Sodium and fluid retention (33%)
- G. Transient hypertension (9%)

Omitted
Correct answer
F

33%
Answered correctly

02 secs
Time Spent

01/30/2020
Last Updated

Explanation

Selective **arteriolar vasodilators** (eg, hydralazine, minoxidil) lower blood pressure by reducing systemic vascular resistance. However, this effect is limited by subsequent stimulation of baroreceptors with resulting reflex **sympathetic activation**. This leads to increased heart rate, contractility, and cardiac output **(Choices B and D)**. In addition, sympathetic stimulation of the **renin-angiotensin-aldosterone** axis results in **sodium and fluid retention** with peripheral edema. These effects offset much of the blood pressure lowering effect of these drugs and limit their long-term

1
2
3
4
5
6
7
8
9
10
11
12
13
14
15
16
17
18
19
20
21
22
23
24
25
26
27
28
29
30
31

Explanation

Selective **arteriolar vasodilators** (eg, hydralazine, minoxidil) lower blood pressure by reducing systemic vascular resistance. However, this effect is limited by subsequent stimulation of baroreceptors with resulting reflex **sympathetic activation**. This leads to increased heart rate, contractility, and cardiac output **(Choices B and D)**. In addition, sympathetic stimulation of the **renin-angiotensin-aldosterone** axis results in **sodium and fluid retention** with peripheral edema. These effects offset much of the blood pressure lowering effect of these drugs and limit their long-term efficacy.

These agents are rarely used as monotherapy for chronic management of hypertension. However, they are useful acutely for patients with severely elevated blood pressure. They can also be given in combination with sympatholytics and diuretics to mitigate the side effects and provide synergistic blood pressure lowering in patients with resistant hypertension.

(Choices A and E) Persistent cough and angioedema are well recognized side effects of ACE inhibitors. Angioedema refers to acute, localized subcutaneous or submucosal edema caused by increased vascular permeability. It differs from the chronic peripheral edema due to sodium retention seen with arteriolar dilators.

(Choice C) Beta blockers decrease cardiac output, leading to peripheral vasoconstriction and resulting in cold hands and feet. However, direct arteriolar vasodilators enhance blood flow to peripheral tissues, including skin and muscle, and they can be used to relieve symptoms in patients with Raynaud phenomenon.

(Choice G) Although selective arteriolar vasodilators trigger reflex sympathetic activation, this does not raise blood pressure above baseline unless they are discontinued abruptly.

Educational objective:
Direct arteriolar vasodilators lower blood pressure but trigger reflex sympathetic activation and stimulate the renin-angiotensin-aldosterone axis. This results in tachycardia and edema. To counteract such compensatory effects, these agents are often given in combination with sympatholytics and diuretics.

Pharmacology	Cardiovascular System	Primary hypertension
Subject	System	Topic

1
2
3
4
5
6
7
8
9
10
11
12
13
14
15
16
17
18
19
20
21
22
23
24
25
26
27
28
29
30
31

A 55-year-old man comes to the emergency department with recurrent episodes of retrosternal chest pain. The episodes occur during physical activity, usually when he climbs stairs or walks uphill. The patient has no known medical problems and does not use tobacco, alcohol, or illicit drugs. He is given a sublingual tablet and reports rapid relief of the pain. This drug most likely improved this patient's symptoms by causing which of the following hemodynamic changes?

A. Decrease in arteriolar resistance

B. Decrease in heart rate

C. Decrease in left ventricular end-diastolic volume

D. Increase in coronary blood flow

E. Increase in coronary perfusion pressure

Submit

1
2
3
4
5
6
7
8
9
10
11
12
13
14
15
16
17
18
19
20
21
22
23
24
25
26
27
28
29
30
31

A 55-year-old man comes to the emergency department with recurrent episodes of retrosternal chest pain. The episodes occur during physical activity, usually when he climbs stairs or walks uphill. The patient has no known medical problems and does not use tobacco, alcohol, or illicit drugs. He is given a sublingual tablet and reports rapid relief of the pain. This drug most likely improved this patient's symptoms by causing which of the following hemodynamic changes?

- A. Decrease in arteriolar resistance (17%)
- B. Decrease in heart rate (1%)
- ✓ C. Decrease in left ventricular end-diastolic volume (48%)
- D. Increase in coronary blood flow (29%)
- E. Increase in coronary perfusion pressure (2%)

Omitted
Correct answer
C

48%
Answered correctly

02 secs
Time Spent

03/17/2020
Last Updated

Explanation

Mechanisms of action of antianginal therapy

Exhibit Display

Mechanisms of action of antianginal therapy

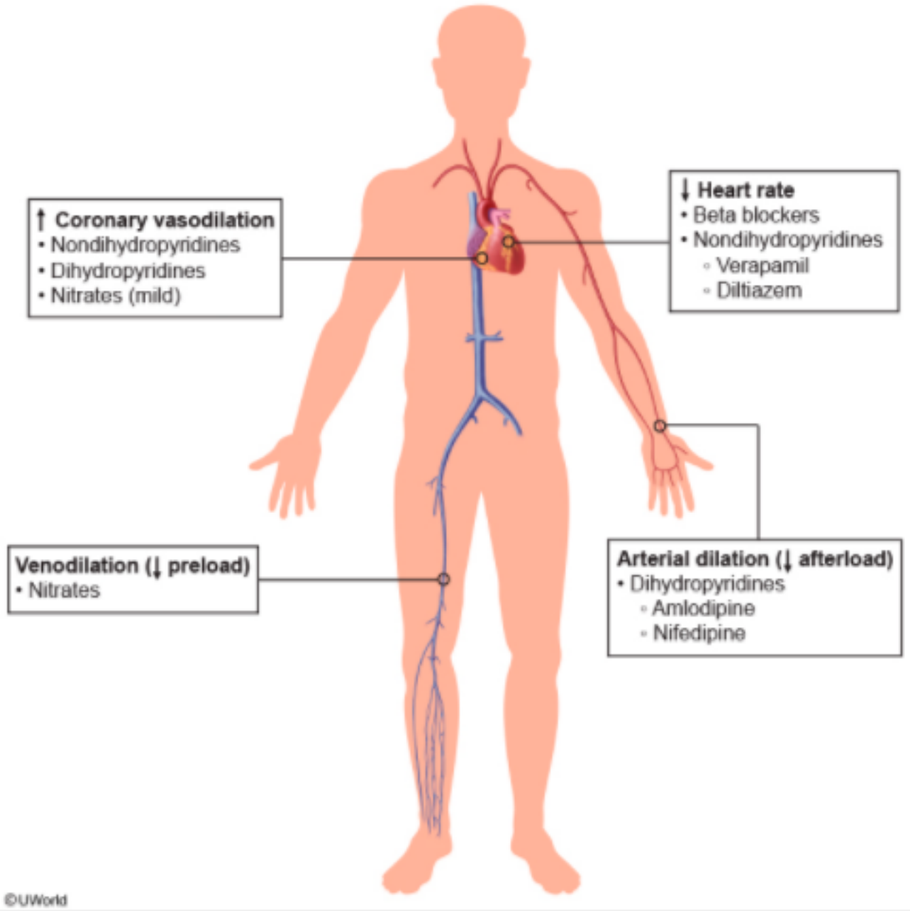

Zoom In | Zoom Out | Reset | Add To New Card | Existing Card

©UWorld

This patient has a classic presentation of **chronic stable angina**, which is characterized by chest pain that occurs with activity and is relieved with rest or sublingual nitroglycerin. **Nitrates** exert their effect by direct vascular smooth muscle relaxation that results in:

- Vasodilation of the peripheral veins and arteries, predominantly **venodilation**
- Decreased left ventricular wall stress due to **reduced preload** (decreased left ventricular end-diastolic volume and pressure)
- Modest reduction in afterload due to systemic arterial vasodilation
- Mild coronary artery dilation and reduction of coronary vasospasm

This results in **decreased myocardial oxygen demand**, leading to improved exercise tolerance and relief of angina symptoms.

(Choices A and D) Nitrates dilate the large epicardial arteries more than the smaller resistance vessels (eg, arterioles). Furthermore, coronary arterioles in an area of flow-limited stenosis are typically dilated maximally to maintain resting blood flow, limiting the ability of nitrates to significantly increase blood flow in stenotic coronary arteries.

(Choice B) Nitrates do not directly affect cardiac chronotropy and/or inotropy but can increase the heart rate as a reflex response to reduced blood pressure. Beta blockers and nondihydropyridine calcium channel blockers may exert their antianginal effect in part via a decrease in the heart rate (negative chronotropic effect).

(Choice E) Coronary perfusion pressure is the pressure gradient that drives coronary perfusion during diastole and is equal to the difference between the end-diastolic aortic pressure and the left ventricular end-diastolic pressure. Nitrates may slightly reduce coronary perfusion pressure as they lower systemic arterial pressure; however, the overall hemodynamic effects of nitrates are beneficial during angina as they lead to decreased myocardial oxygen demand.

Educational objective:
Sublingual nitroglycerin is used for rapid symptom relief in patients with stable angina. The primary anti-ischemic effect of nitrates is mediated by venodilation with a decrease in left ventricular end-diastolic volume and wall stress, resulting in decreased myocardial oxygen demand and relief of angina symptoms.

References

- Hemodynamic effects of nitroglycerin and long-acting nitrates.

1
2
3
4
5
6
7
8
9
10
11
12
13
14
15
16
17
18
19
20
21
22
23
24
25
26
27
28
29
30
31

A new drug has been developed to treat cardiac arrhythmias. The drug has high affinity for activated and inactivated sodium channels but relatively little affinity for resting sodium channels. An experiment is devised to maintain sodium channels in the inactivated state for a prolonged period, during which they are exposed to the new drug. After allowing the sodium channels to return to the resting state, the speed of the drug's dissociation from the sodium channels is recorded and shown below. The dissociation curve for quinidine is given for comparison.

The pharmacologic action of the new drug is most similar to which of the following drugs?

- A. Disopyramide
- B. Flecainide
- C. Lidocaine
- D. Propranolol
- E. Sotalol
- F. Verapamil

Submit

1
2
3
4
5
6
7
8
9
10
11
12
13
14
15
16
17
18
19
20
21
22
23
24
25
26
27
28
29
30
31

A new drug has been developed to treat cardiac arrhythmias. The drug has high affinity for activated and inactivated sodium channels but relatively little affinity for resting sodium channels. An experiment is devised to maintain sodium channels in the inactivated state for a prolonged period, during which they are exposed to the new drug. After allowing the sodium channels to return to the resting state, the speed of the drug's dissociation from the sodium channels is recorded and shown below. The dissociation curve for quinidine is given for comparison.

The pharmacologic action of the new drug is most similar to which of the following drugs?

A. Disopyramide (10%)
B. Flecainide (28%)
✓ C. Lidocaine (56%)
D. Propranolol (1%)
E. Sotalol (1%)
F. Verapamil (1%)

Omitted
Correct answer
C

56%
Answered correctly

54 mins, 22 secs
Time Spent

03/24/2020
Last Updated

Explanation

The drug described is representative of **a class I antiarrhythmic** medication, which blocks voltage-gated Na^+ channels. Most of the clinically useful agents bind within the pore of the channel during the open and/or inactivated states; dissociation of the drug occurs during the resting state. This state-dependent manner of binding causes a phenomenon in which tissues undergoing frequent depolarization become more

The drug described is representative of **a class I antiarrhythmic** medication, which blocks voltage-gated Na^+ channels. Most of the clinically useful agents bind within the pore of the channel during the open and/or inactivated states; dissociation of the drug occurs during the resting state. This state-dependent manner of binding causes a phenomenon in which tissues undergoing frequent depolarization become more susceptible to blockage (**use dependence**). The faster the heart rate, the more time the Na^+ channels spend in the open and inactivated states and the more that become blocked.

The binding strength of class I antiarrhythmics varies between the different subclasses, with **Class IB** agents (eg, lidocaine) having the **weakest binding** compared to other class I antiarrhythmics. Dissociation from the channels occurs so rapidly that there is minimal cumulative effect over multiple cardiac cycles, resulting in little use dependence. These drugs are more **selective for ischemic myocardium** because the elevated (less negative) resting membrane potential delays Na^+ channel transition from the inactivated to the resting state, resulting in increased drug binding. As such, class IB antiarrhythmics are useful for treating **ischemia-induced ventricular arrhythmias**.

In contrast, **class IC** agents (eg, propafenone, flecainide) have the strongest binding **(Choice B)**. They are the **slowest to dissociate** from the channel, which allows their blocking effects to accumulate over multiple cardiac cycles. This leads to substantially greater blockade at higher heart rates (**high use dependence**), making them particularly effective at **terminating tachyarrhythmias**. However, the prominent use-dependent effects of class IC drugs can cause an excessive delay in conduction speed that can promote arrhythmias, especially in patients with ischemic or structural heart disease.

(Choice A) Disopyramide, quinidine, and procainamide are class IA antiarrhythmic drugs that have an intermediate dissociation speed. The dissociation curve for the new drug shows that drug-channel dissociation is faster than with quinidine, indicating that it is most similar to a class IB antiarrhythmic agent such as lidocaine.

(Choice D) Propranolol is a nonselective beta-adrenergic blocker (class II antiarrhythmic). It causes decreased chronotropy and inotropy via beta-1 blockade.

(Choice E) Class III antiarrhythmic drugs (amiodarone, sotalol, dofetilide) act predominantly by blocking potassium channels and prolonging phase 3 repolarization. Sotalol also has beta-blocking activity.

(Choice F) Verapamil and diltiazem are calcium channel blockers that function as class IV antiarrhythmics due to their effects on cardiac slow-response tissue. Although nifedipine is a calcium channel blocker as well, it is selective for vascular smooth muscle and does not have a notable effect on the heart.

1
2
3
4
5
6
7
8
9
10
11
12
13
14
15
16
17
18
19
20
21
22
23
24
25
26
27
28
29
30
31

In contrast, **class IC** agents (eg, propafenone, flecainide) have the strongest binding **(Choice B)**. They are the **slowest to dissociate** from the channel, which allows their blocking effects to accumulate over multiple cardiac cycles. This leads to substantially greater blockade at higher heart rates (**high use dependence**), making them particularly effective at **terminating tachyarrhythmias**. However, the prominent use-dependent effects of class IC drugs can cause an excessive delay in conduction speed that can promote arrhythmias, especially in patients with ischemic or structural heart disease.

(Choice A) Disopyramide, quinidine, and procainamide are class IA antiarrhythmic drugs that have an intermediate dissociation speed. The dissociation curve for the new drug shows that drug-channel dissociation is faster than with quinidine, indicating that it is most similar to a class IB antiarrhythmic agent such as lidocaine.

(Choice D) Propranolol is a nonselective beta-adrenergic blocker (class II antiarrhythmic). It causes decreased chronotropy and inotropy via beta-1 blockade.

(Choice E) Class III antiarrhythmic drugs (amiodarone, sotalol, dofetilide) act predominantly by blocking potassium channels and prolonging phase 3 repolarization. Sotalol also has beta-blocking activity.

(Choice F) Verapamil and diltiazem are calcium channel blockers that function as class IV antiarrhythmics due to their effects on cardiac slow-response tissue. Although nifedipine is a calcium channel blocker as well, it is selective for vascular smooth muscle and does not have a notable effect on the heart.

Educational objective:
For class I antiarrhythmics, sodium-channel-binding strength is **IC > IA > IB**. Use dependence describes the phenomenon in which higher heart rates lead to increased sodium channel blockade due to cumulative blocking effects over multiple cardiac cycles. Class IC antiarrhythmics demonstrate the most use dependence due to their slow dissociation from the receptor, and class IB drugs have the least use dependence as they rapidly dissociate.

Pharmacology	Cardiovascular System	Antiarrhythmic drugs
Subject	System	Topic

Copyright © UWorld. All rights reserved.

F. Verapamil (1%)

Exhibit Display

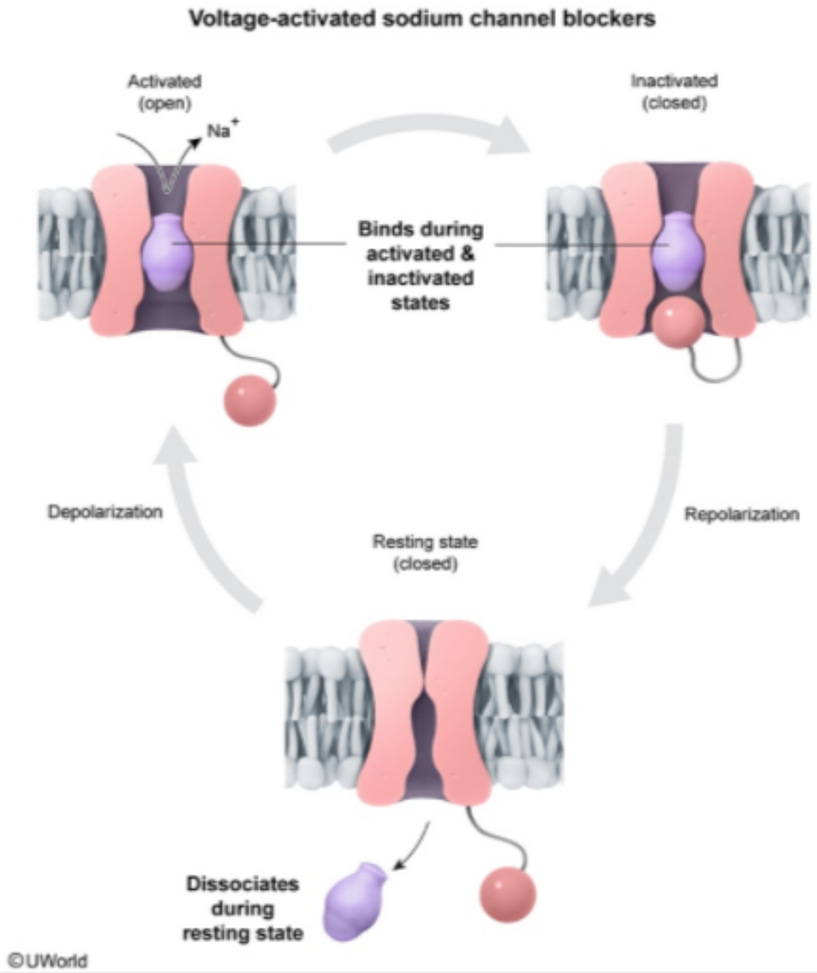

Zoom In | Zoom Out | Reset | Add To New Card | Existing Card

1
2
3
4
5
6
7
8
9
10
11
12
13
14
15
16
17
18
19
20
21
22
23
24
25
26
27
28
29
30
31

A new antiarrhythmic medication (drug A) is tested in a series of experiments that measure the flow of ions responsible for producing an action potential in cardiac muscle cells. Ion flow is measured before and after the drug is administered, and the results are shown in the chart below (each colored line represents a different type of ion).

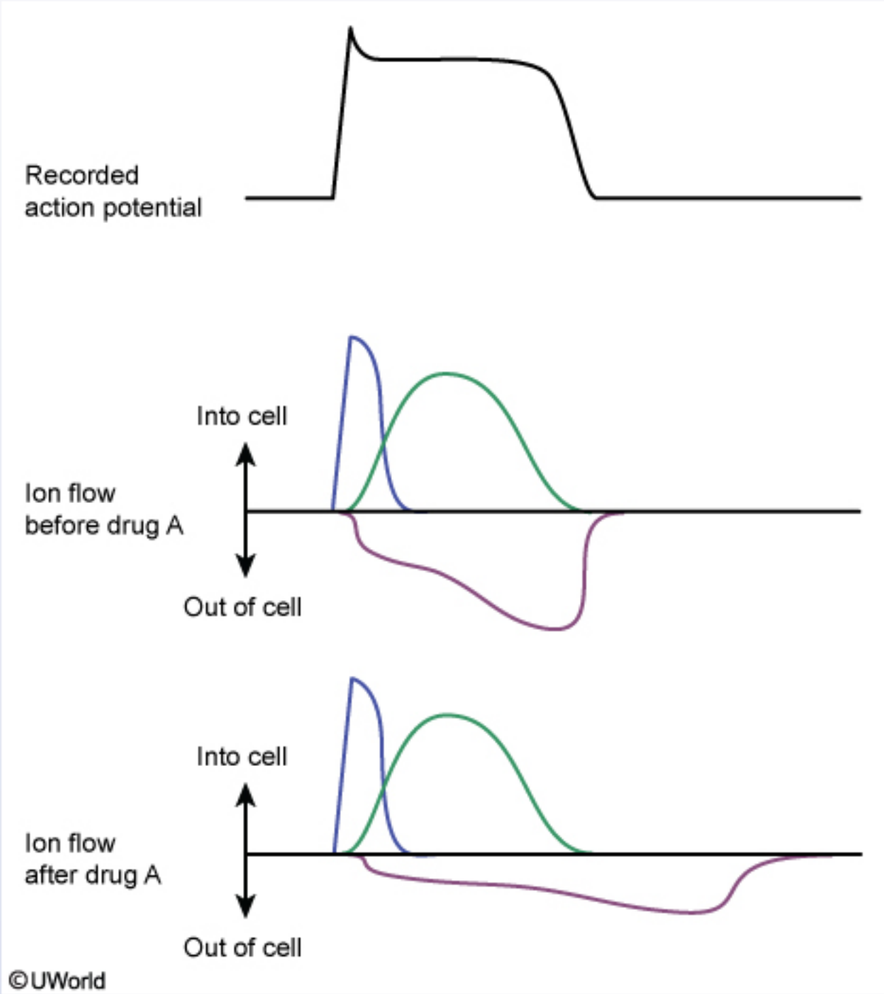

1
2
3
4
5
6
7
8
9
10
11
12
13
14
15
16
17
18
19
20
21
22
23
24
25
26
27
28
29
30
31

potential in cardiac muscle cells. Ion flow is measured before and after the drug is administered, and the results are shown in the chart below (each colored line represents a different type of ion).

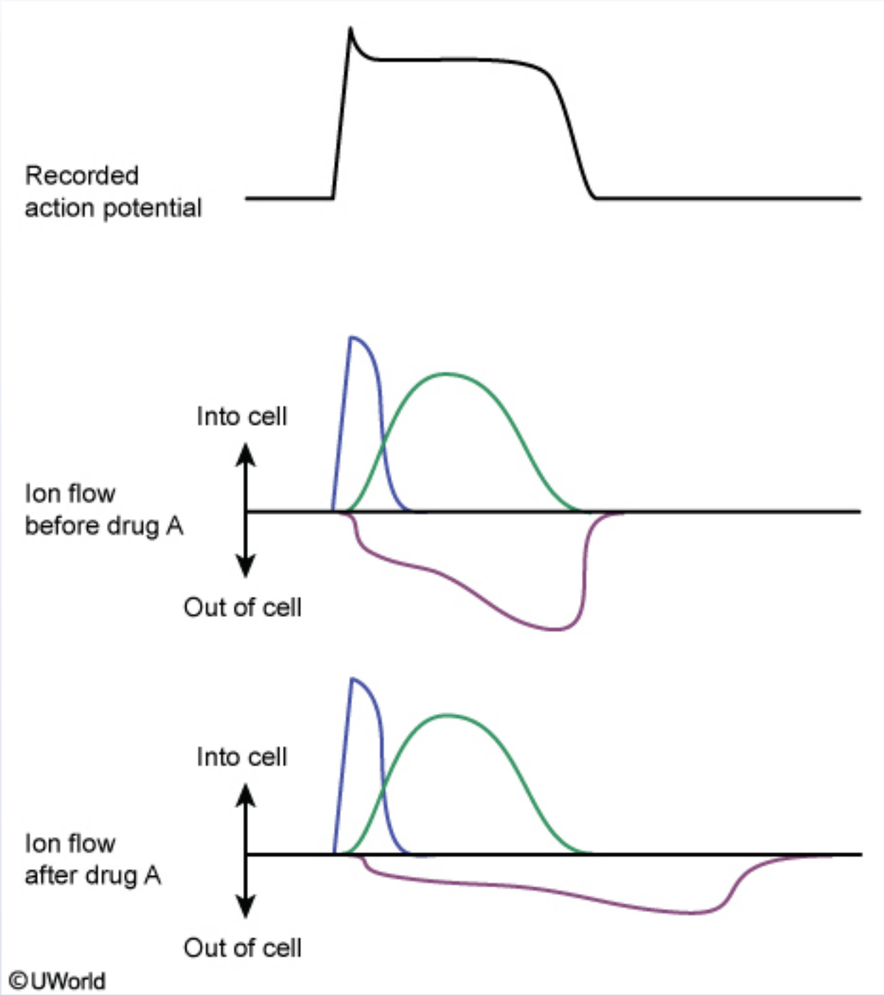

Drug A has an antiarrhythmic effect most similar to which of the following drugs?

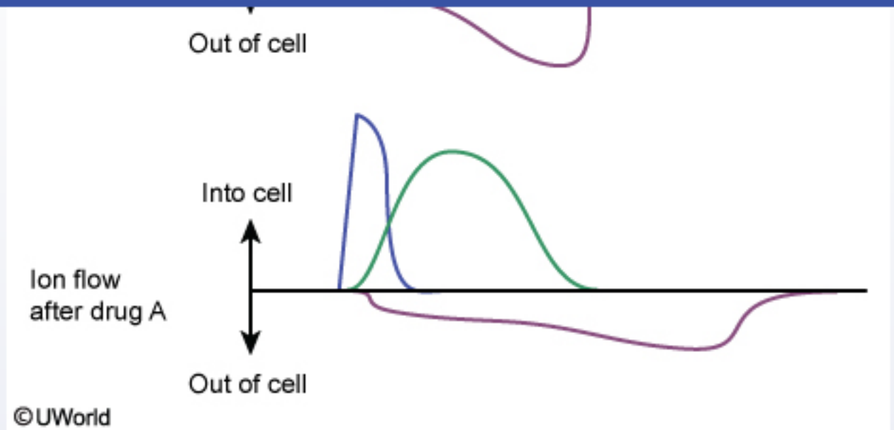

Drug A has an antiarrhythmic effect most similar to which of the following drugs?

- A. Adenosine
- B. Digoxin
- C. Dofetilide
- D. Esmolol
- E. Flecainide
- F. Lidocaine
- G. Quinidine
- H. Verapamil

Submit

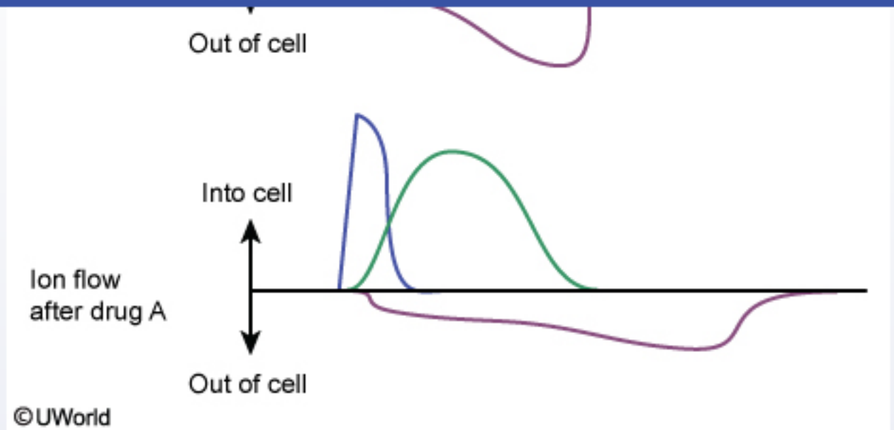

Drug A has an antiarrhythmic effect most similar to which of the following drugs?

- A. Adenosine (8%)
- B. Digoxin (5%)
- ✓ C. Dofetilide (59%)
- D. Esmolol (4%)
- E. Flecainide (5%)
- F. Lidocaine (3%)
- G. Quinidine (7%)
- H. Verapamil (5%)

Omitted
Correct answer

59%
Answered correctly

08 secs
Time Spent

04/25/2020
Last Updated

1
2
3
4
5
6
7
8
9
10
11
12
13
14
15
16
17
18
19
20
21
22
23
24
25
26
27
28
29
30
31

Cardiac action potentials

Pacemaker action potential

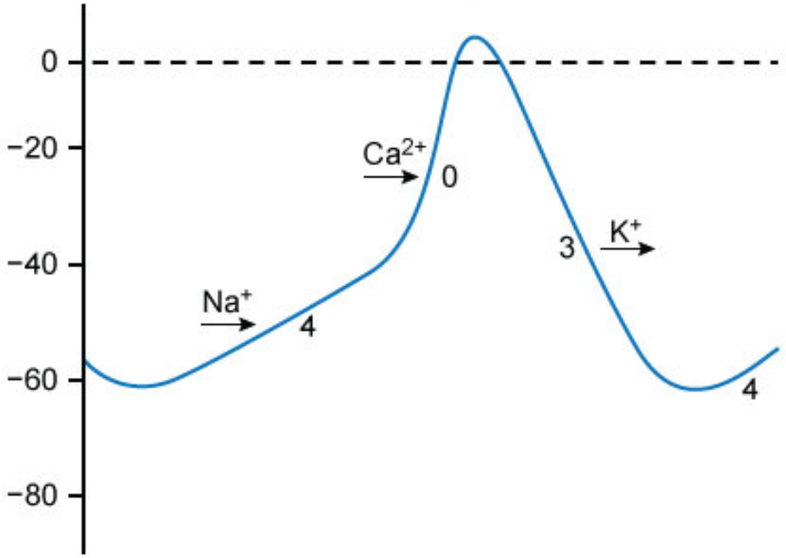

Nonpacemaker action potential

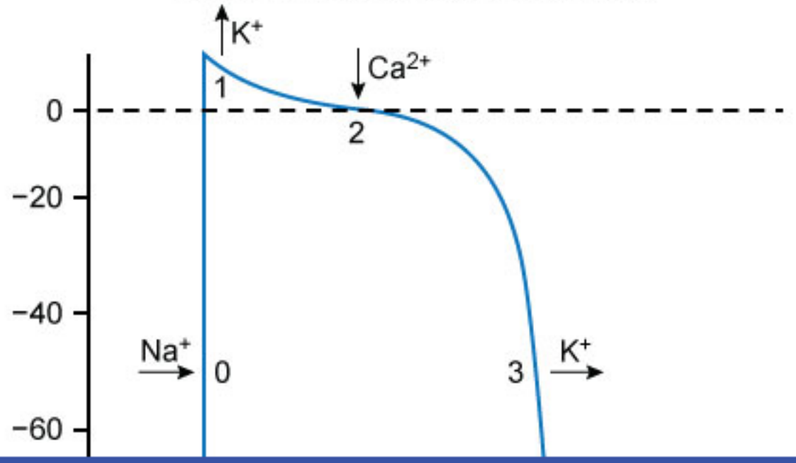

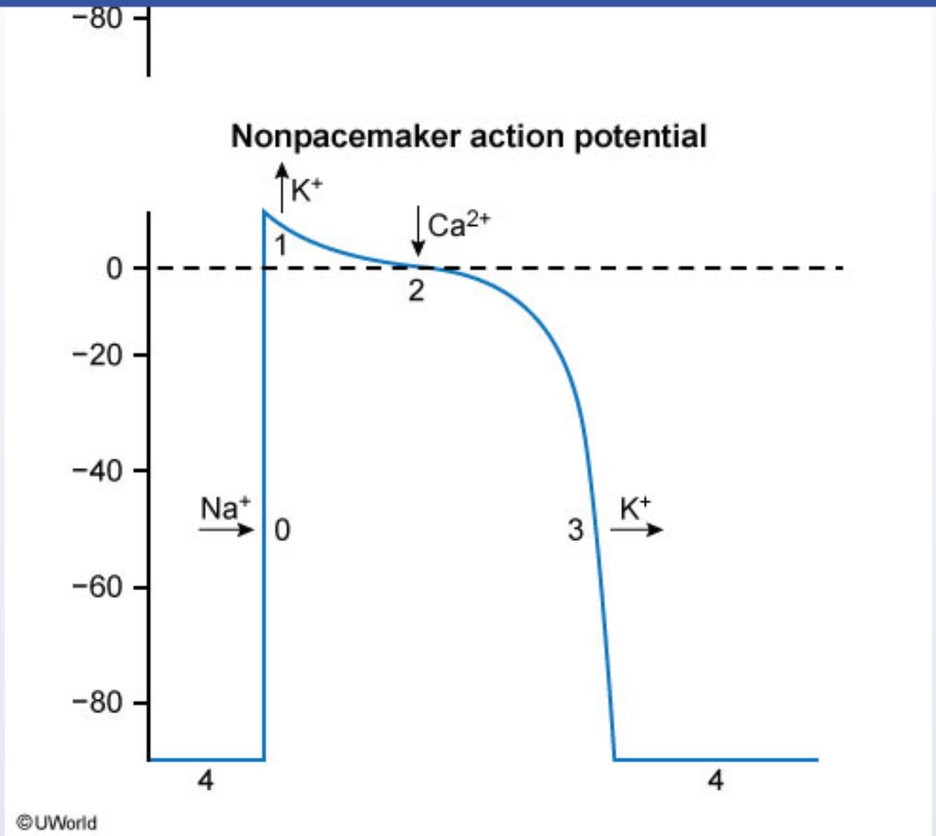

The recorded action potential shows the typical profile of **non-pacemaker** cardiac cells, which includes the following phases:

1. **Phase 0 (rapid depolarization)** – occurs when the resting membrane potential reaches threshold; is characterized by rapid sodium entry into the cell due to activation and opening of voltage-dependent sodium channels.
2. **Phase 1 (early repolarization)** – caused primarily by activation of transient outward potassium currents along with a rapid decline in inward sodium current.
3. **Phase 2 (plateau phase)** – stable membrane potential due to a balance of late inward calcium current (L-type channels) and outward potassium current.
4. **Phase 3 (late repolarization)** – characterized by the opening of additional potassium channels (delayed-rectifier potassium currents) and

The recorded action potential shows the typical profile of **non-pacemaker** cardiac cells, which includes the following phases:

1. **Phase 0 (rapid depolarization)** – occurs when the resting membrane potential reaches threshold; is characterized by rapid sodium entry into the cell due to activation and opening of voltage-dependent sodium channels.
2. **Phase 1 (early repolarization)** – caused primarily by activation of transient outward potassium currents along with a rapid decline in inward sodium current.
3. **Phase 2 (plateau phase)** – stable membrane potential due to a balance of late inward calcium current (L-type channels) and outward potassium current.
4. **Phase 3 (late repolarization)** – characterized by the opening of additional potassium channels (delayed-rectifier potassium currents) and continued efflux of potassium ions from the cell; this is in conjunction with the decay of inward calcium current.
5. **Phase 4 (resting)** – normal resting membrane potential is between −80 mV and −95 mV, and it is generated by outward potassium flow through potassium leak channels open at rest. The Na^+-K^+-ATPase pump allows the potassium and sodium gradients to be maintained across the membrane.

The ion flow graph after drug A administration shows a **decrease in outward potassium flow** from the myocyte during phase 3 repolarization of the myocardial action potential. Class III antiarrhythmic drugs (eg, amiodarone, sotalol, **dofetilide**) predominantly block potassium channels and inhibit the outward potassium currents during phase 3 of the cardiac action potential, thereby prolonging repolarization and total action potential duration.

(Choice A) Adenosine stimulates A1 receptors on the surface of cardiac cells, activating potassium channels and increasing potassium conductance, which causes the membrane potential to remain negative for a longer period. This results in transient slowing of the sinus rate and increased atrioventricular (AV) nodal conduction delay.

(Choice B) Digoxin inhibits the Na^+-K^+-ATPase pump in myocardial cells, resulting in an increase in intracellular sodium, which leads in turn to a rise in intracellular calcium concentration. Digoxin does not affect potassium channels and has minimal effect on potassium efflux from myocardial cells during the action potential.

(Choice D) Esmolol is a rapid-acting, short-duration beta blocker (class II antiarrhythmic) that slows the rate of discharge of sinus or ectopic pacemakers and increases the refractory period of the AV node. It has no effect on potassium efflux from myocardial cells.

(Choices E, F, and G) Class IA (procainamide, quinidine), IB (lidocaine), and IC (flecainide) antiarrhythmic drugs inhibit sodium-dependent

across the membrane.

The ion flow graph after drug A administration shows a **decrease in outward potassium flow** from the myocyte during phase 3 repolarization of the myocardial action potential. Class III antiarrhythmic drugs (eg, amiodarone, sotalol, **dofetilide**) predominantly block potassium channels and inhibit the outward potassium currents during phase 3 of the cardiac action potential, thereby prolonging repolarization and total action potential duration.

(Choice A) Adenosine stimulates A1 receptors on the surface of cardiac cells, activating potassium channels and increasing potassium conductance, which causes the membrane potential to remain negative for a longer period. This results in transient slowing of the sinus rate and increased atrioventricular (AV) nodal conduction delay.

(Choice B) Digoxin inhibits the Na^+-K^+-ATPase pump in myocardial cells, resulting in an increase in intracellular sodium, which leads in turn to a rise in intracellular calcium concentration. Digoxin does not affect potassium channels and has minimal effect on potassium efflux from myocardial cells during the action potential.

(Choice D) Esmolol is a rapid-acting, short-duration beta blocker (class II antiarrhythmic) that slows the rate of discharge of sinus or ectopic pacemakers and increases the refractory period of the AV node. It has no effect on potassium efflux from myocardial cells.

(Choices E, F, and G) Class IA (procainamide, quinidine), IB (lidocaine), and IC (flecainide) antiarrhythmic drugs inhibit sodium-dependent (phase 0) depolarization and slow conduction. Class IA and IC agents also have some potassium-blocking activity and can cause prolongation of the action potential (seen mostly with class IA agents). However, all class I drugs have prominent sodium channel-blocking activity, which would blunt the blue tracing in the above graph.

(Choice H) Calcium channel blockers (eg, verapamil, diltiazem) inhibit the L-type calcium channels during phase 2 of the myocardial action potential and phase 0 of the pacemaker action potential. They slow the sinus rate, prolong conduction through the AV node, and depress myocardial contractility.

Educational objective:
Class III antiarrhythmic drugs (eg, amiodarone, sotalol, dofetilide) predominantly block potassium channels and inhibit the outward potassium currents during phase 3 of the cardiac action potential, thereby prolonging repolarization and total action potential duration.

Pharmacology Cardiovascular System Antiarrhythmic drugs

1
2
3
4
5
6
7
8
9
10
11
12
13
14
15
16
17
18
19
20
21
22
23
24
25
26
27
28
29
30
31

A 56-year-old Caucasian female presents to your office with chronic cough. She says that the cough is dry and affects quality of her life significantly. She denies chest pain, hemoptysis and shortness of breath. Her past medical history is significant for long-standing hypertension, diabetes and myocardial infarction experienced two months ago. She does not smoke or consume alcohol. Her blood pressure is 130/70 mmHg and heart rate is 70/min. Which of the following is the best next step in the management of this patient?

A. Careful review of family history

B. Careful review of past allergic episodes

C. Careful review of current medications

D. Careful review of diet and physical activity

E. Chest x-ray

Submit

1
2
3
4
5
6
7
8
9
10
11
12
13
14
15
16
17
18
19
20
21
22
23
24
25
26
27
28
29
30
31

A 56-year-old Caucasian female presents to your office with chronic cough. She says that the cough is dry and affects quality of her life significantly. She denies chest pain, hemoptysis and shortness of breath. Her past medical history is significant for long-standing hypertension, diabetes and myocardial infarction experienced two months ago. She does not smoke or consume alcohol. Her blood pressure is 130/70 mmHg and heart rate is 70/min. Which of the following is the best next step in the management of this patient?

A. Careful review of family history (1%)

B. Careful review of past allergic episodes (1%)

✓ C. Careful review of current medications (90%)

D. Careful review of diet and physical activity (1%)

E. Chest x-ray (5%)

Omitted
Correct answer
C

90%
Answered correctly

01 sec
Time Spent

02/03/2020
Last Updated

Explanation

With a history of hypertension, diabetes, and coronary heart disease, the likelihood that this patient is on standard ACE inhibitor therapy is very high. A dry, nonproductive, and persistent cough is one of the most well-known side effects of ACE inhibitor therapy.

The mechanism of ACE inhibitor induced cough is believed to involve increased bradykinin, substance P, or prostaglandins. ACE is a very nonspecific enzyme responsible for the breakdown of many substrates. By blocking ACE, ACE inhibitors block degradation of bradykinin and substance P. Bradykinin and substance P accumulation can cause inflammation and stimulate lung irritation.

With a history of hypertension, diabetes, and coronary heart disease, the likelihood that this patient is on standard ACE inhibitor therapy is very high. A dry, nonproductive, and persistent cough is one of the most well-known side effects of ACE inhibitor therapy.

The mechanism of ACE inhibitor induced cough is believed to involve increased bradykinin, substance P, or prostaglandins. ACE is a very nonspecific enzyme responsible for the breakdown of many substrates. By blocking ACE, ACE inhibitors block degradation of bradykinin and substance P. Bradykinin and substance P accumulation can cause inflammation and stimulate lung irritation.

Because angiotensin receptor blockers (ARBs) do not affect ACE activity, they theoretically should not cause cough.

(Choice A) Chronic cough is one of the early signs of cancer. Screening family history will allow risk assessment for cancer, but since patient does not complain of any other symptoms of cancer (unexplained fatigue, weight loss, change in bowel habits, etc.), suspicion for cancer is low.

(Choice B) Although cough can occur secondary to post nasal drip in patients with allergies, the patient describes no other allergy type symptoms (itchy and watery eyes, runny nose, sneezing, etc.).

(Choice D) Diet and physical activity are not linked to causing cough.

(Choice E) Cough may be linked to pulmonary infection or disease. Chest x-ray would be helpful in diagnosis if suspicion for pneumonia, TB, bronchitis, or emphysema were high. However, patient has no symptoms associated with any infection and her risk for emphysema is low since she does not smoke.

Educational Objective:
Cough is a very well recognized side effect of ACE inhibitor therapy. Cough secondary to ACE inhibitor therapy is characterized as dry, nonproductive, and persistent. The mechanism behind ACE inhibitor induced cough is accumulation of bradykinin, substance P, or prostaglandins. Because angiotensin receptor blockers (ARBs) do not affect ACE activity, they theoretically should not cause cough.

Pharmacology	Cardiovascular System	Chronic cough
Subject	System	Topic

Copyright © UWorld. All rights reserved.

In an experiment investigating vasoconstriction of the arterial wall, two samples of isolated porcine arterial vessels are studied. Vascular tone is measured in the control vessel during infusion of increasing doses of norepinephrine. The other vessel is pretreated with experimental drug A prior to infusion of norepinephrine. A graph of the study results is depicted below.

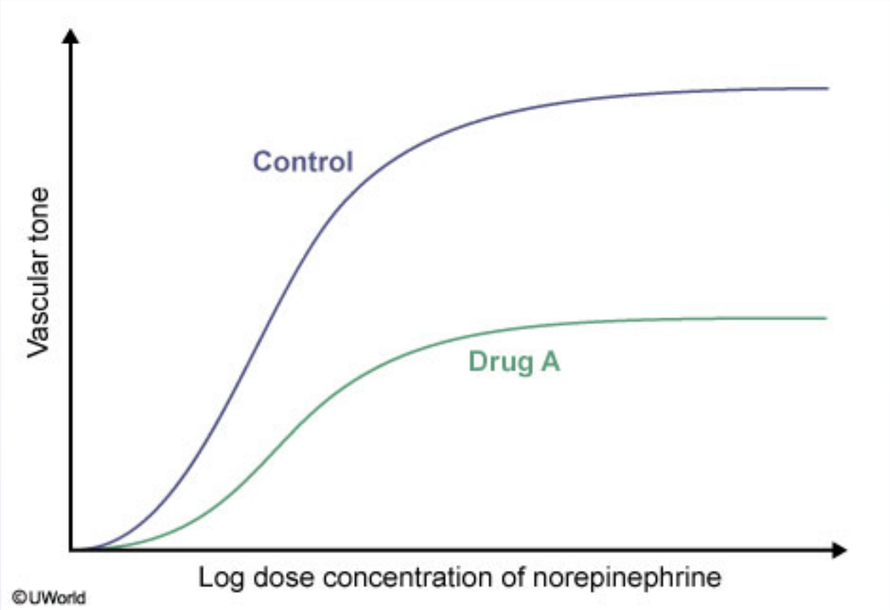

Drug A is most similar to which of the following agents?

A. Atropine
B. Labetalol
C. Phenoxybenzamine
D. Phentolamine
E. Propranolol

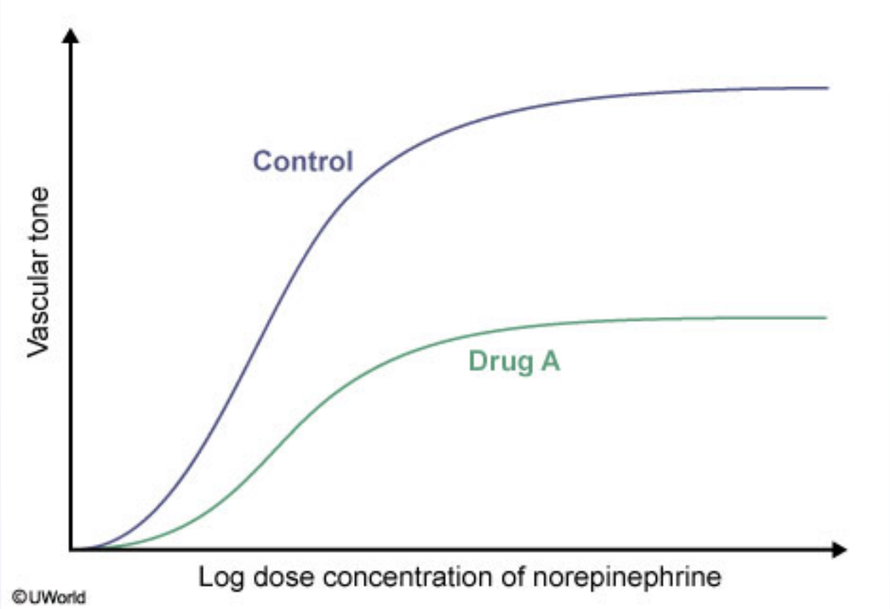

Drug A is most similar to which of the following agents?

- A. Atropine
- B. Labetalol
- C. Phenoxybenzamine
- D. Phentolamine
- E. Propranolol

Submit

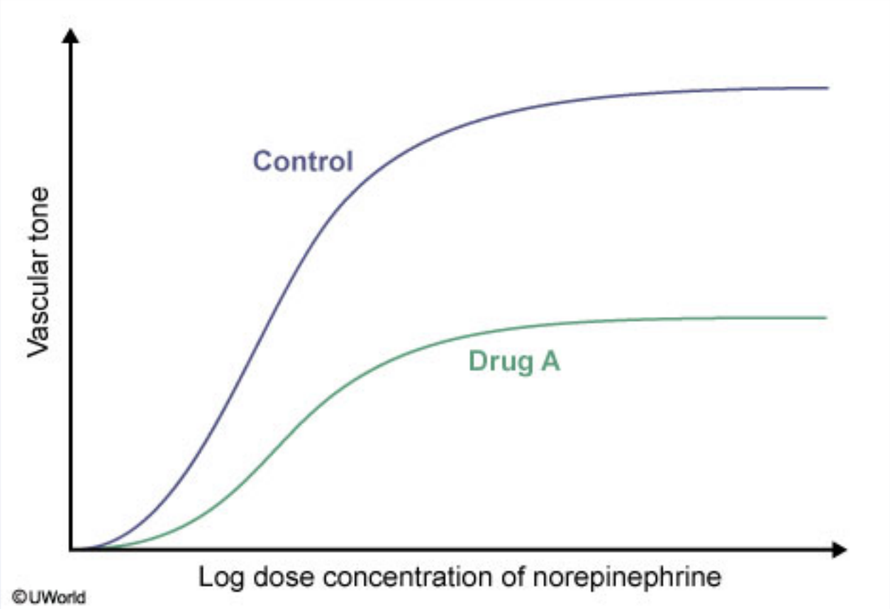

Drug A is most similar to which of the following agents?

- A. Atropine (5%)
- B. Labetalol (11%)
- ✓ C. Phenoxybenzamine (48%)
- D. Phentolamine (24%)
- E. Propranolol (9%)

Omitted
Correct answer

48%
Answered correctly

04 secs
Time Spent

02/28/2020
Last Updated

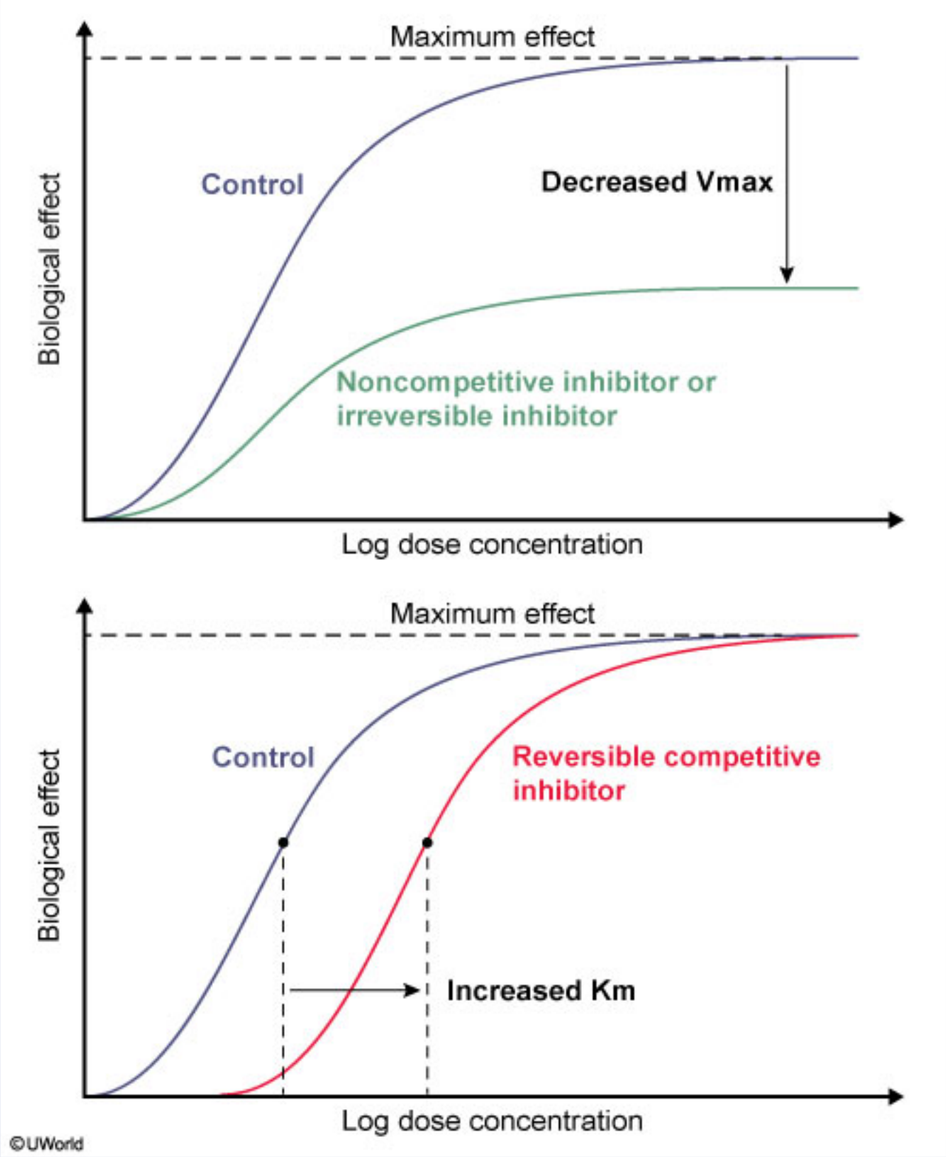
Maximum effect
Control
Decreased Vmax
Noncompetitive inhibitor or
irreversible inhibitor
Biological effect
Log dose concentration
Maximum effect
Control
Reversible competitive
inhibitor
Increased Km
Biological effect
Log dose concentration
©UWorld

Alpha-1 adrenergic receptors mediate arterial vasoconstriction whereas β2 receptors mediate vasodilation. **Norepinephrine** is an agonist at α1 and β1 receptors but has significantly less action at β2 receptors; it is therefore a potent vasoconstrictor. This experiment is testing the efficacy of drug A at blocking the **α1-mediated vasoconstriction** caused by norepinephrine administration.

The results show that pretreatment with drug A results in **decreased maximal effect** (V_{max}) of norepinephrine without a significant change in the affinity (K_m) of norepinephrine for α1 receptors. This suggests that drug A is acting as either a **noncompetitive** antagonist or an **irreversible antagonist** of α1 adrenergic receptors. **Phenoxybenzamine** is an irreversible α1 and α2 receptor antagonist that would produce results similar to those observed. It is primarily used in the treatment of pheochromocytoma, in which a tumor of the adrenal medulla overproduces norepinephrine, causing systemic arterial vasoconstriction.

(Choice A) Atropine is a competitive muscarinic acetylcholine receptor antagonist. Pretreatment with atropine would not alter norepinephrine's effects on vascular tone.

(Choices B and D) Labetalol is a reversible, competitive antagonist of α1 and β adrenergic receptors with partial β2 agonist activity that is used to treat hypertension. Phentolamine is a reversible, competitive α-adrenergic antagonist used in the management of catecholamine-induced hypertensive crises (eg, pheochromocytoma, monoamine oxidase inhibitor toxicity, cocaine intoxication). High doses of norepinephrine can overcome the α-adrenergic inhibition of these drugs.

(Choice E) Propranolol is a nonspecific β-adrenergic antagonist. Pretreatment with a β antagonist would potentiate the vasoconstrictive effects of norepinephrine due to unopposed α-adrenergic stimulation.

Educational objective:
Phenoxybenzamine is an irreversible α1 and α2 adrenergic antagonist that effectively reduces the arterial vasoconstriction induced by norepinephrine. Because phenoxybenzamine is an irreversible antagonist, even very high concentrations of norepinephrine, such as those seen in pheochromocytoma, cannot overcome its effects.

Pharmacology	Cardiovascular System	Dose response curves
Subject	System	Topic

Copyright © UWorld. All rights reserved.

A 55-year-old man comes to the emergency department due to an hour of intense substernal chest burning accompanied by sweating. He has a history of obesity and diet-controlled type 2 diabetes mellitus. On initial evaluation, blood pressure is 110/70 mm Hg and pulse is 60/min and regular. Oxygen saturation is 98% on room air. The patient is comfortable lying flat and no heart murmurs are heard. Lungs are clear on auscultation. Immediate ECG shows normal sinus rhythm with a 2-mm ST-segment elevation in leads II, III, and aVF. Aspirin and morphine are administered. As the patient is about to be transported to the catheterization lab for urgent percutaneous coronary intervention, he develops dizziness and the telemetry monitor shows sinus bradycardia at 40/min. The patient appears pale and diaphoretic and peripheral pulses are faint. Blood pressure is 70/40 mm Hg. Which of the following is the best immediate step for managing this patient's condition?

- A. Adenosine
- B. Alteplase
- C. Amiodarone
- D. Atropine
- E. Naloxone
- F. Physostigmine

Submit

A 55-year-old man comes to the emergency department due to an hour of intense substernal chest burning accompanied by sweating. He has a history of obesity and diet-controlled type 2 diabetes mellitus. On initial evaluation, blood pressure is 110/70 mm Hg and pulse is 60/min and regular. Oxygen saturation is 98% on room air. The patient is comfortable lying flat and no heart murmurs are heard. Lungs are clear on auscultation. Immediate ECG shows normal sinus rhythm with a 2-mm ST-segment elevation in leads II, III, and aVF. Aspirin and morphine are administered. As the patient is about to be transported to the catheterization lab for urgent percutaneous coronary intervention, he develops dizziness and the telemetry monitor shows sinus bradycardia at 40/min. The patient appears pale and diaphoretic and peripheral pulses are faint. Blood pressure is 70/40 mm Hg. Which of the following is the best immediate step for managing this patient's condition?

- A. Adenosine (14%)
- B. Alteplase (13%)
- C. Amiodarone (3%)
- ✓ D. Atropine (54%)
- E. Naloxone (13%)
- F. Physostigmine (1%)

Omitted
Correct answer
D

54%
Answered correctly

02 secs
Time Spent

05/15/2020
Last Updated

Explanation

This patient with ST elevation in leads II, III, and aVF has an acute **inferior wall myocardial infarction** (MI), which most commonly occurs due to occlusion of the right coronary artery (RCA). The RCA usually supplies blood to the sinoatrial node, the atrioventricular node, and most of the

This patient with ST elevation in leads II, III, and aVF has an acute **inferior wall myocardial infarction** (MI), which most commonly occurs due to occlusion of the right coronary artery (RCA). The RCA usually supplies blood to the sinoatrial node, the atrioventricular node, and most of the bundle of His; therefore, **conduction impairment** (eg, sinus bradycardia, atrioventricular block) is common in patients with inferior wall MI.

Sinus bradycardia is the most common arrhythmia in those with inferior wall MI (nearly 50% of patients); it occurs due to both nodal ischemia and **enhanced vagal tone** triggered by infarction of myocardial tissue. The bradycardia is usually transient and resolves with restoration of coronary blood flow; however, patients with hypotension or symptoms of bradycardia (eg, lightheadedness, syncope) should be managed with **intravenous atropine**. The **anticholinergic** effects of atropine counteract the enhanced vagal tone to increase heart rate and improve symptoms.

(Choice A) Adenosine hyperpolarizes the atrioventricular node to cause transient atrioventricular conduction delay. It is useful in the treatment of paroxysmal supraventricular tachycardia, but it is likely to worsen bradycardia.

(Choice B) Alteplase is a fibrinolytic agent indicated for the acute management of patients with ST-elevation MI who cannot undergo percutaneous coronary intervention (PCI) in a timely manner. PCI is associated with reduced mortality and a lower rate of complications (eg, cerebral hemorrhage) compared with fibrinolytic therapy and is the preferred intervention whenever possible.

(Choice C) Amiodarone is a class III antiarrhythmic agent that can be used for the management of ventricular arrhythmia (eg, ventricular tachycardia) in patients with acute MI. However, the drug causes negative chronotropy and is not used to treat bradyarrhythmias.

(Choice E) Naloxone, an opioid-receptor antagonist, is used to reverse the effects of opioid overdose (eg, somnolence, respiratory and cardiac depression). Although morphine may cause bradycardia, this patient's bradycardia is more likely due to his inferior wall MI.

(Choice F) Physostigmine, an acetylcholinesterase inhibitor that prolongs the effects of acetylcholine, is used in the treatment of myasthenia gravis. Its effects essentially oppose those of atropine; it would worsen the bradycardia in this patient.

Educational objective:
Conduction impairment is common with acute inferior wall myocardial infarction. Sinus bradycardia often occurs due to nodal ischemia and an increase in vagal tone triggered by infarction of myocardial tissue; the enhanced vagal tone can be counteracted by the anticholinergic effects of atropine.

References

- Early and late atrioventricular block in acute inferior myocardial infarction.

This patient with ST elevation in leads II, III, and aVF has an acute **inferior wall myocardial infarction** (MI), which most commonly occurs due to

Exhibit Display

Blood supply to the cardiac conduction system

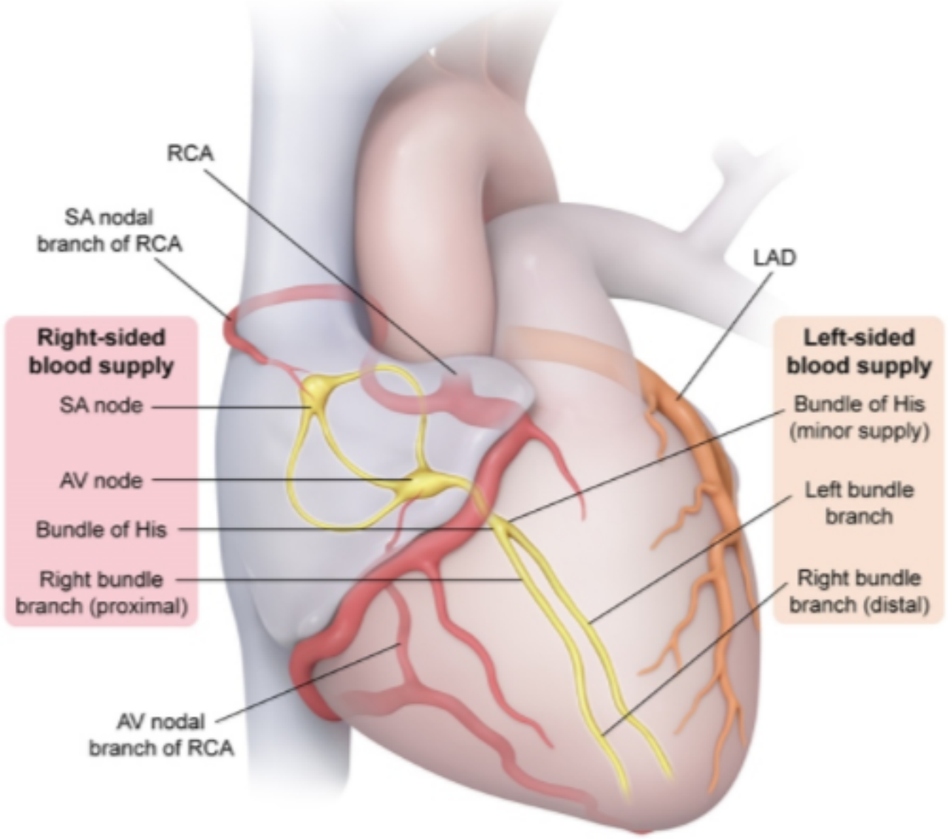

AV = atrioventricular; **LAD** = left anterior descending artery; **RCA** = right coronary artery; **SA** = sinoatrial.

©UWorld

Zoom In | Zoom Out | Reset | Add To New Card | Existing Card

A 77-year-old man comes to the office after he was found to have high blood pressure during a health fair. The patient denies any medical problems and feels proud that he has not needed to see a doctor for many years. His blood pressure is 170/70 mm Hg and pulse is 74/min. Other physical examination findings are normal. The patient is started on a medication to treat his hypertension. During his follow-up visit 3 weeks later, he reports bilateral leg swelling. He has no chest pain, shortness of breath, or abdominal symptoms. His blood pressure is 135/65 mm Hg and pulse is 80/min. Cardiopulmonary examination is normal, but there is bilateral, symmetrical, 2+ pitting lower extremity edema. Laboratory studies show serum creatinine of 0.8 mg/dL, and urinalysis is negative for proteinuria. Which of the following was most likely prescribed to treat this patient's hypertension?

- A. Amlodipine
- B. Eplerenone
- C. Hydrochlorothiazide
- D. Ramipril
- E. Torsemide
- F. Valsartan

Submit

A 77-year-old man comes to the office after he was found to have high blood pressure during a health fair. The patient denies any medical problems and feels proud that he has not needed to see a doctor for many years. His blood pressure is 170/70 mm Hg and pulse is 74/min. Other physical examination findings are normal. The patient is started on a medication to treat his hypertension. During his follow-up visit 3 weeks later, he reports bilateral leg swelling. He has no chest pain, shortness of breath, or abdominal symptoms. His blood pressure is 135/65 mm Hg and pulse is 80/min. Cardiopulmonary examination is normal, but there is bilateral, symmetrical, 2+ pitting lower extremity edema. Laboratory studies show serum creatinine of 0.8 mg/dL, and urinalysis is negative for proteinuria. Which of the following was most likely prescribed to treat this patient's hypertension?

- ✓ A. Amlodipine (46%)
- B. Eplerenone (4%)
- C. Hydrochlorothiazide (15%)
- D. Ramipril (22%)
- E. Torsemide (6%)
- F. Valsartan (5%)

Omitted
Correct answer
A

46%
Answered correctly

02 secs
Time Spent

01/18/2020
Last Updated

Explanation

Adverse effects of common antihypertensive medications

Adverse effects of common antihypertensive medications	
Drugs	**Adverse effects**
Thiazide diuretics	• Acute kidney injury • Electrolyte disturbances (hyponatremia, hypokalemia) • Hyperuricemia & acute gout • Elevated glucose & cholesterol levels
ACE inhibitors	• Cough • Angioedema • Hyperkalemia
Calcium channel blockers (amlodipine, nifedipine)	• Peripheral edema • Dizziness or lightheadedness
Beta blockers	• Bronchospasm • Bradycardia • Fatigue • Sexual dysfunction

Dihydropyridine calcium channel blockers (eg, amlodipine, nifedipine) are effective antihypertensive agents commonly used as monotherapy or in combination with other agents for treatment of hypertension. The major side effects associated with use of calcium channel blockers include headache, flushing, dizziness, and **peripheral edema**. Development of peripheral edema is related to preferential dilation of precapillary vessels (arteriolar dilation), which leads to increased capillary hydrostatic pressure and fluid extravasation into the interstitium. Renin-angiotensin system blockers (eg, ACE inhibitors or angiotensin II receptor blockers [ARBs]) cause postcapillary venodilation and can normalize the increased capillary hydrostatic pressure, reducing the risk of peripheral edema in patients taking calcium channel blockers.

(Choice B) Eplerenone is an aldosterone antagonist and functions similarly to spironolactone as a potassium-sparing diuretic. The most frequent side effects of eplerenone are hyperkalemia, increased creatinine, and gynecomastia (~1% versus 10% with spironolactone).

	• Sexual dysfunction

Dihydropyridine calcium channel blockers (eg, amlodipine, nifedipine) are effective antihypertensive agents commonly used as monotherapy or in combination with other agents for treatment of hypertension. The major side effects associated with use of calcium channel blockers include headache, flushing, dizziness, and **peripheral edema**. Development of peripheral edema is related to preferential dilation of precapillary vessels (arteriolar dilation), which leads to increased capillary hydrostatic pressure and fluid extravasation into the interstitium. Renin-angiotensin system blockers (eg, ACE inhibitors or angiotensin II receptor blockers [ARBs]) cause postcapillary venodilation and can normalize the increased capillary hydrostatic pressure, reducing the risk of peripheral edema in patients taking calcium channel blockers.

(Choice B) Eplerenone is an aldosterone antagonist and functions similarly to spironolactone as a potassium-sparing diuretic. The most frequent side effects of eplerenone are hyperkalemia, increased creatinine, and gynecomastia (~1% versus 10% with spironolactone).

(Choices C and E) The most common side effects of thiazide (eg, hydrochlorothiazide) and loop diuretics (eg, torsemide) are electrolyte abnormalities such as hypokalemia, hyponatremia, and hypomagnesemia. They do not cause peripheral edema.

(Choices D and F) The potential side effects of ACE inhibitors (eg, ramipril) and ARBs (eg, valsartan) include cough, hypotension, hyperkalemia, and angioedema. The risk of cough and angioedema is much lower with ARBs. These medications do not cause peripheral edema.

Educational objective:
Amlodipine is a dihydropyridine calcium channel blocker commonly used as monotherapy or in combination with other agents for treatment of hypertension. Major side effects include headache, flushing, dizziness, and peripheral edema.

References

- Vasodilatory edema: a common side effect of antihypertensive therapy.
- Peripheral edema associated with calcium channel blockers: incidence and withdrawal rate - a meta-analysis of randomized trials.

Pharmacology	Cardiovascular System	Calcium channel blocker
Subject	System	Topic

Copyright © UWorld. All rights reserved.

A 58-year-old man comes to the office due to progressive fatigue, dyspnea on exertion, and orthopnea. Medical history is significant for hypertension, hyperlipidemia, and a myocardial infarction 2 years ago. The patient says he has not taken his medications in several months because he was "feeling well." Blood pressure is 160/95 mm Hg and pulse is 94/min and regular. Physical examination shows bilateral lung crackles and lower extremity edema. The point of maximal impulse is displaced toward the axilla, and an S3 is heard. Serum creatinine is 0.9 mg/dL and serum potassium is 4.2 mEq/L. After this patient's condition has stabilized, long-term use of which of the following medications will most likely reduce mortality?

A. Amlodipine
B. Digoxin
C. Diltiazem
D. Furosemide
E. Hydrochlorothiazide
F. Lisinopril
G. Triamterene

Submit

A 58-year-old man comes to the office due to progressive fatigue, dyspnea on exertion, and orthopnea. Medical history is significant for hypertension, hyperlipidemia, and a myocardial infarction 2 years ago. The patient says he has not taken his medications in several months because he was "feeling well." Blood pressure is 160/95 mm Hg and pulse is 94/min and regular. Physical examination shows bilateral lung crackles and lower extremity edema. The point of maximal impulse is displaced toward the axilla, and an S3 is heard. Serum creatinine is 0.9 mg/dL and serum potassium is 4.2 mEq/L. After this patient's condition has stabilized, long-term use of which of the following medications will most likely reduce mortality?

- A. Amlodipine (1%)
- B. Digoxin (2%)
- C. Diltiazem (1%)
- D. Furosemide (5%)
- E. Hydrochlorothiazide (5%)
- ✓ F. Lisinopril (79%)
- G. Triamterene (4%)

Omitted
Correct answer
F

79%
Answered correctly

02 secs
Time Spent

03/18/2020
Last Updated

Explanation

Pharmacotherapy for chronic heart failure with reduced ejection fraction

Pharmacotherapy for chronic heart failure with reduced ejection fraction	
Agent	**Mortality benefit**
ACE inhibitor (eg, lisinopril) or **Angiotensin receptor blocker** (eg, losartan) or **Neprilysin inhibitor-angiotensin receptor blocker** (eg, sacubitril-valsartan)	Yes
Beta blocker (eg, metoprolol)	Yes
Mineralocorticoid receptor antagonist (eg, spironolactone)	Yes
Diuretics (eg, furosemide, metolazone)	No*
Digoxin	No**

*Improves symptoms & reduces hospitalization.

**Reduces hospitalization.

This patient with a previous myocardial infarction has most likely developed chronic **heart failure with reduced ejection fraction** (HFrEF). Appropriate pharmacologic management is important in such patients because it has been shown to reduce mortality. Much of this **mortality benefit** is likely related to a **reduction** in deleterious **cardiac remodeling**.

**Reduces hospitalization.

This patient with a previous myocardial infarction has most likely developed chronic **heart failure with reduced ejection fraction** (HFrEF). Appropriate pharmacologic management is important in such patients because it has been shown to reduce mortality. Much of this **mortality benefit** is likely related to a **reduction** in deleterious **cardiac remodeling**.

Neurohormonal pathways involving norepinephrine, angiotensin II, and aldosterone all have a demonstrated role in cardiac remodeling. In particular, elevated angiotensin II and aldosterone levels increase pathologic cardiomyocyte hypertrophy and stimulate collagen deposition by fibroblasts (cardiac fibrosis). Accordingly, **ACE inhibitors** (eg, lisinopril), **angiotensin-receptor blockers** (eg, losartan), and **mineralocorticoid receptor antagonists** (eg, spironolactone, epleronone) reduce mortality in patients with HFrEF via a reduction in angiotensin II–mediated (and downstream aldosterone-mediated) cardiac remodeling.

Beta blockers (eg, metoprolol, carvedilol) also reduce mortality in patients with chronic HFrEF, likely through similar inhibition of neurohormonal mechanisms. Potentiation of the natriuretic peptide neurohormonal pathway (eg, with sacubitril-valsartan) also has mortality benefit in these patients.

(Choice A) Blood pressure control is important for patients with heart failure because it slows the progression of coronary artery disease and may reduce cardiac remodeling that is triggered by increased left ventricular pressure load. However, aside from the benefit of blood pressure reduction, dihydropyridine calcium channel blockers (eg, amlodipine) provide no additional mortality benefit in patients with HFrEF.

(Choice B) Digoxin is used as an adjunctive therapy in patients with HFrEF. It improves symptoms and reduces the rate of hospitalization but does not reduce mortality.

(Choice C) Nondihydropyridine calcium channel blockers (eg, verapamil, diltiazem) can depress cardiac contractility and are usually contraindicated in patients with HFrEF.

(Choices D and E) Loop (eg, furosemide) and thiazide (eg, hydrochlorothiazide) diuretics reduce cardiac preload and are useful for symptomatic management of patients with HFrEF; however, these drugs do not provide a clear mortality benefit.

(Choice G) Although potassium-sparing diuretics that function via blockade of mineralocorticoid receptors have shown mortality benefit for HFrEF, those that act via blockade of the epithelial sodium channel (ENaC) (eg, triamterene, amiloride) have minimal neurohormonal effects and no demonstrated benefit.

Beta blockers (eg, metoprolol, carvedilol) also reduce mortality in patients with chronic HFrEF, likely through similar inhibition of neurohormonal mechanisms. Potentiation of the natriuretic peptide neurohormonal pathway (eg, with sacubitril-valsartan) also has mortality benefit in these patients.

(Choice A) Blood pressure control is important for patients with heart failure because it slows the progression of coronary artery disease and may reduce cardiac remodeling that is triggered by increased left ventricular pressure load. However, aside from the benefit of blood pressure reduction, dihydropyridine calcium channel blockers (eg, amlodipine) provide no additional mortality benefit in patients with HFrEF.

(Choice B) Digoxin is used as an adjunctive therapy in patients with HFrEF. It improves symptoms and reduces the rate of hospitalization but does not reduce mortality.

(Choice C) Nondihydropyridine calcium channel blockers (eg, verapamil, diltiazem) can depress cardiac contractility and are usually contraindicated in patients with HFrEF.

(Choices D and E) Loop (eg, furosemide) and thiazide (eg, hydrochlorothiazide) diuretics reduce cardiac preload and are useful for symptomatic management of patients with HFrEF; however, these drugs do not provide a clear mortality benefit.

(Choice G) Although potassium-sparing diuretics that function via blockade of mineralocorticoid receptors have shown mortality benefit for HFrEF, those that act via blockade of the epithelial sodium channel (ENaC) (eg, triamterene, amiloride) have minimal neurohormonal effects and no demonstrated benefit.

Educational objective:
Neurohormones (eg, norepinephrine, angiotensin II, and aldosterone) play a large role in the deleterious cardiac remodeling that occurs in heart failure with reduced ejection fraction. ACE inhibitors, angiotensin-receptor blockers, mineralocorticoid receptor antagonists, and beta blockers reduce mortality in these patients by reducing neurohormonal-mediated cardiac remodeling.

References

- 2013 ACCF/AHA guideline for the management of heart failure: executive summary: a report of the American College of Cardiology Foundation/American Heart Association Task Force on practice guidelines.

Pharmacology	Cardiovascular System	Chronic heart failure
Subject	System	Topic

A 42-year-old man comes to the emergency department due to an episode of syncope. He was standing in his kitchen this morning when he felt palpitations for about 3 seconds; the next thing he remembers is waking up on the floor. The patient has had intermittent palpitations for the last few weeks, sometimes with associated lightheadedness. He has no significant medical history other than chronic lower back pain that began following a fall from a ladder 3 years ago. The patient fractured several lumbar vertebrae in that fall and required a surgical lumbar fusion. His back pain was uncontrolled with conservative measures, and he has been treated with escalating doses of methadone for the past year. He does not smoke or drink alcohol. The patient has a remote history of intravenous heroin abuse but has not used it for 20 years. He has no family history of early-onset heart disease, blood clots, or sudden death. Blood pressure is 120/70 mm Hg when supine and 125/75 mm Hg when standing. Physical examination is unremarkable. Which of the following ECG findings is most likely in this patient?

- A. Atrioventricular block
- B. Deep Q waves
- C. QT interval prolongation
- D. Sinus pauses
- E. Ventricular preexcitation

Submit

A 42-year-old man comes to the emergency department due to an episode of syncope. He was standing in his kitchen this morning when he felt palpitations for about 3 seconds; the next thing he remembers is waking up on the floor. The patient has had intermittent palpitations for the last few weeks, sometimes with associated lightheadedness. He has no significant medical history other than chronic lower back pain that began following a fall from a ladder 3 years ago. The patient fractured several lumbar vertebrae in that fall and required a surgical lumbar fusion. His back pain was uncontrolled with conservative measures, and he has been treated with escalating doses of methadone for the past year. He does not smoke or drink alcohol. The patient has a remote history of intravenous heroin abuse but has not used it for 20 years. He has no family history of early-onset heart disease, blood clots, or sudden death. Blood pressure is 120/70 mm Hg when supine and 125/75 mm Hg when standing. Physical examination is unremarkable. Which of the following ECG findings is most likely in this patient?

A. Atrioventricular block (24%)

B. Deep Q waves (2%)

✓ C. QT interval prolongation (35%)

D. Sinus pauses (13%)

E. Ventricular preexcitation (24%)

Omitted
Correct answer
C

35%
Answered correctly

02 secs
Time Spent

02/20/2020
Last Updated

Explanation

Causes of QT prolongation	

Causes of QT prolongation	
Acquired	• Medications ◦ Macrolides & fluoroquinolones ◦ Antiemetics (eg, ondansetron) ◦ Azoles (eg, fluconazole) ◦ Antipsychotics, TCAs & methadone ◦ Class IA antiarrhythmics (eg, quinidine) ◦ Class III antiarrhythmics (eg, dofetilide) • Electrolyte abnormalities (eg, ↓ Mg, ↓ K)
Congenital	• Romano-Ward syndrome (autosomal dominant) • Jervell & Lange-Nielson syndrome (autosomal recessive)

TCAs = tricyclic antidepressants.

This patient most likely has **QT interval prolongation**, a common adverse effect of **methadone**. QT interval prolongation is the ECG manifestation of delayed ventricular repolarization, which occurs due to impairment of the voltage-gated potassium channels that control the delayed rectifier potassium current. Significant slowing of ventricular repolarization can trigger **torsade de pointes** (TdP), a form of polymorphic ventricular tachycardia named for a repetitive "twisting of the peaks" pattern. TdP is a serious arrhythmia that can cause palpitations, lightheadedness, **syncope**, and sudden cardiac death (SCD).

Many **medications**, including methadone, are known to **inhibit the delayed rectifier potassium current** to prolong the QT interval and predispose to TdP. Methadone undergoes slow and variable hepatic clearance, making consistent avoidance of toxic blood levels challenging; therefore, the use of high doses of methadone increases the risk of QT interval prolongation and TdP.

(Choice A) Advanced atrioventricular block (ie, Mobitz type II or complete atrioventricular block) can present with syncope. Common causes include infection (eg, Lyme disease), ischemia, and medications (eg, beta blockers, nondihydropyridine calcium channel blockers). Methadone is not associated with atrioventricular block.

(Choice B) Deep Q waves on ECG typically represent a previous myocardial infarction (MI). Patients with a history of MI are at risk for

This patient most likely has **QT interval prolongation**, a common adverse effect of **methadone**. QT interval prolongation is the ECG manifestation of delayed ventricular repolarization, which occurs due to impairment of the voltage-gated potassium channels that control the delayed rectifier potassium current. Significant slowing of ventricular repolarization can trigger **torsade de pointes** (TdP), a form of polymorphic ventricular tachycardia named for a repetitive "twisting of the peaks" pattern. TdP is a serious arrhythmia that can cause palpitations, lightheadedness, **syncope**, and sudden cardiac death (SCD).

Many **medications**, including methadone, are known to **inhibit the delayed rectifier potassium current** to prolong the QT interval and predispose to TdP. Methadone undergoes slow and variable hepatic clearance, making consistent avoidance of toxic blood levels challenging; therefore, the use of high doses of methadone increases the risk of QT interval prolongation and TdP.

(Choice A) Advanced atrioventricular block (ie, Mobitz type II or complete atrioventricular block) can present with syncope. Common causes include infection (eg, Lyme disease), ischemia, and medications (eg, beta blockers, nondihydropyridine calcium channel blockers). Methadone is not associated with atrioventricular block.

(Choice B) Deep Q waves on ECG typically represent a previous myocardial infarction (MI). Patients with a history of MI are at risk for monomorphic ventricular tachycardia causing syncope or SCD, but a prior MI is unlikely in this relatively young patient without significant cardiovascular risk factors (eg, hypertension, smoking, family history).

(Choice D) Sinus pauses occur with sick sinus syndrome, which most commonly results from age-related degeneration of the conduction system. Affected patients are usually age >65 and may experience progressive fatigue and episodes of syncope.

(Choice E) Ventricular preexcitation is recognized by a slurred upslope of the QRS complex (delta wave) on ECG. Patients with this characteristic Wolff-Parkinson-White (WPW) pattern may develop paroxysmal supraventricular tachycardia (ie, WPW syndrome), which can present with syncope or SCD. However, the onset of WPW syndrome is usually age <40, and this patient's methadone use makes a prolonged QT interval more likely.

Educational objective:
Methadone slows the delayed rectifier potassium current responsible for ventricular repolarization, and high doses are associated with QT interval prolongation. QT interval prolongation predisposes to the development of torsade de pointes, a serious ventricular arrhythmia that can cause syncope and sudden cardiac death.

References

Many **medications**, including methadone, are known to **inhibit the delayed rectifier potassium current** to prolong the QT interval and predispose to TdP. Methadone undergoes slow and variable hepatic clearance, making consistent avoidance of toxic blood levels challenging; therefore, the use of high doses of methadone increases the risk of QT interval prolongation and TdP.

(Choice A) Advanced atrioventricular block (ie, Mobitz type II or complete atrioventricular block) can present with syncope. Common causes include infection (eg, Lyme disease), ischemia, and medications (eg, beta blockers, nondihydropyridine calcium channel blockers). Methadone is not associated with atrioventricular block.

(Choice B) Deep Q waves on ECG typically represent a previous myocardial infarction (MI). Patients with a history of MI are at risk for monomorphic ventricular tachycardia causing syncope or SCD, but a prior MI is unlikely in this relatively young patient without significant cardiovascular risk factors (eg, hypertension, smoking, family history).

(Choice D) Sinus pauses occur with sick sinus syndrome, which most commonly results from age-related degeneration of the conduction system. Affected patients are usually age >65 and may experience progressive fatigue and episodes of syncope.

(Choice E) Ventricular preexcitation is recognized by a slurred upslope of the QRS complex (delta wave) on ECG. Patients with this characteristic Wolff-Parkinson-White (WPW) pattern may develop paroxysmal supraventricular tachycardia (ie, WPW syndrome), which can present with syncope or SCD. However, the onset of WPW syndrome is usually age <40, and this patient's methadone use makes a prolonged QT interval more likely.

Educational objective:
Methadone slows the delayed rectifier potassium current responsible for ventricular repolarization, and high doses are associated with QT interval prolongation. QT interval prolongation predisposes to the development of torsade de pointes, a serious ventricular arrhythmia that can cause syncope and sudden cardiac death.

References

- Methadone, QTc prolongation and torsades de pointes: current concepts, management, and a hidden twist in the tale?

Pharmacology	Cardiovascular System	Long QT syndrome
Subject	System	Topic

10
11
12
13
14
15
16
17
18
19
20
21
22
23
24
25
26
27
28
29
30
31
32
33
34
35
36
37
38
39
40

- Antiemetics (eg, ondansetron)

Exhibit Display

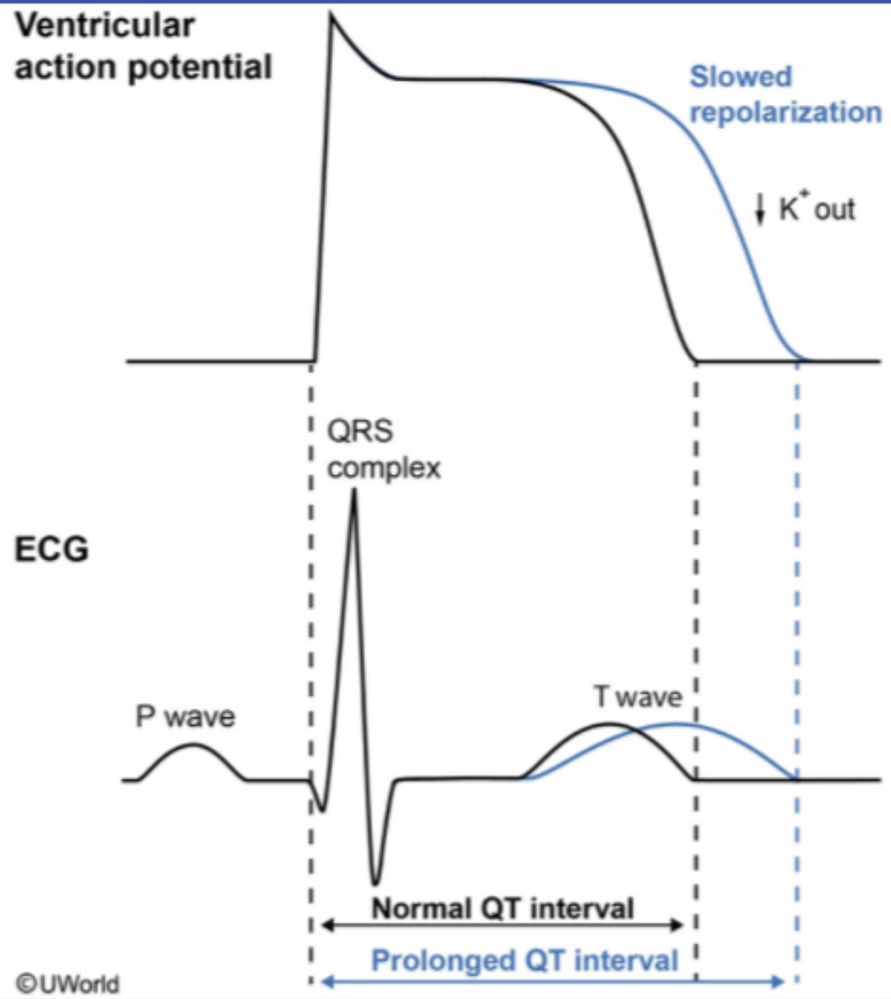

Zoom In
Zoom Out
Reset
Add To Flash Card

10
11
12
13
14
15
16
17
18
19
20
21
22
23
24
25
26
27
28
29
30
31
32
33
34
35
36
37
38
39
40

- Antiemetics (eg, ondansetron)

Exhibit Display

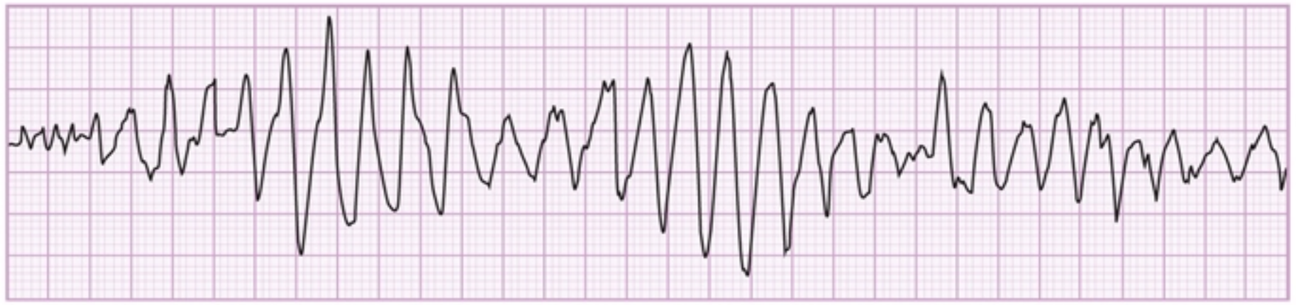

©UWorld

Zoom In Zoom Out Reset Add To Flash Card

10
11
12
13
14
15
16
17
18
19
20
21
22
23
24
25
26
27
28
29
30
31
32
33
34
35
36
37
38
39
40

- Antiemetics (eg, ondansetron)

Exhibit Display

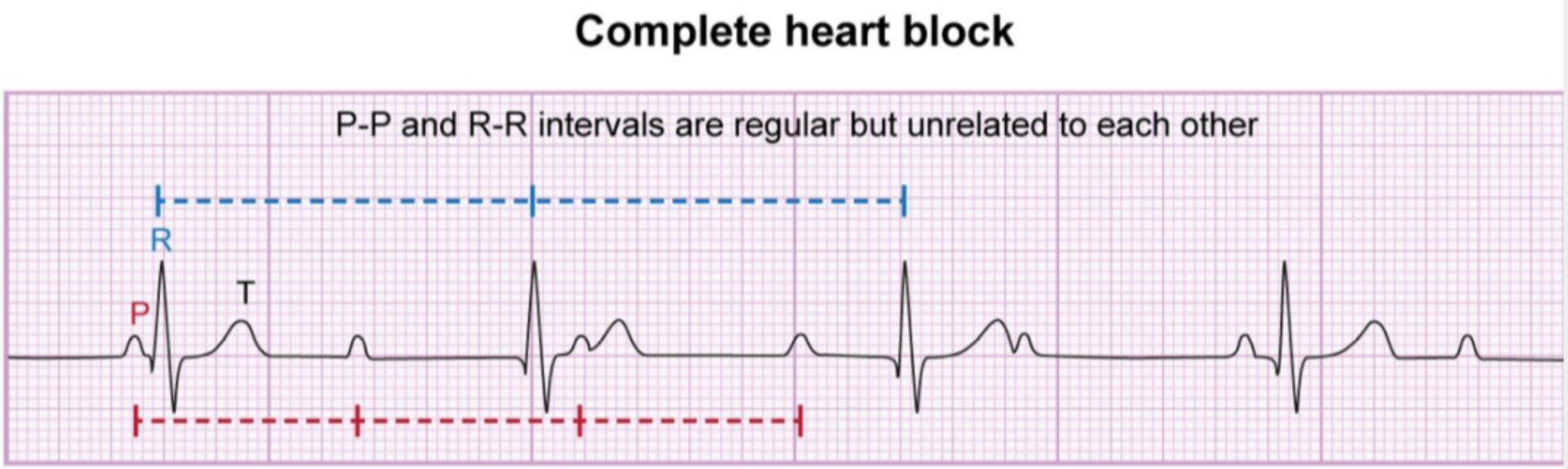

Zoom In
Zoom Out
Reset
Add To Flash Card

TCAs = tricyclic antidepressants

Exhibit Display

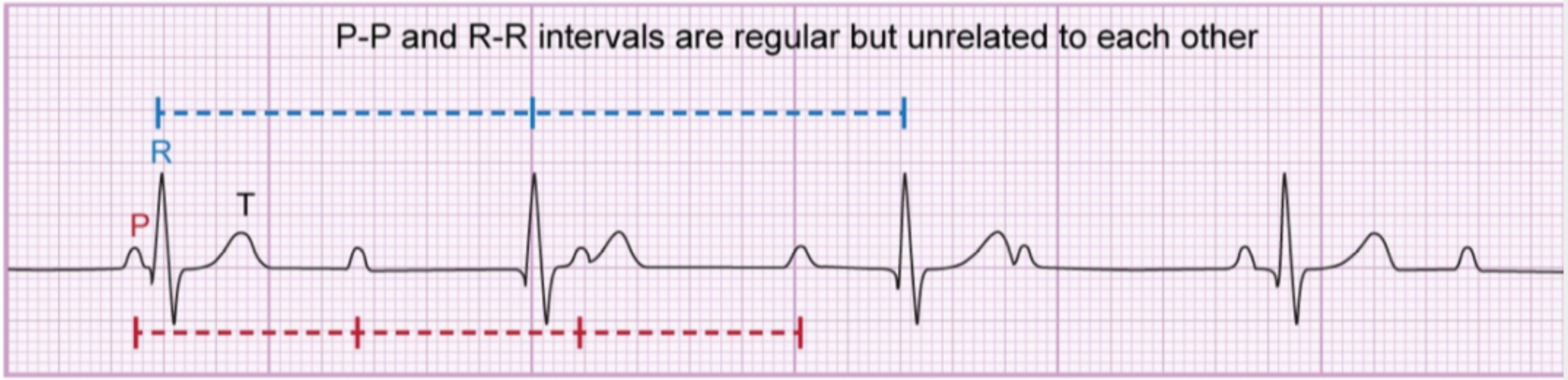

Zoom In Zoom Out Reset Add To Flash Card

prolongation. QT interval prolongation predisposes to the development of torsade de pointes, a serious ventricular arrhythmia that can cause

TCAs = tricyclic antidepressants

Exhibit Display

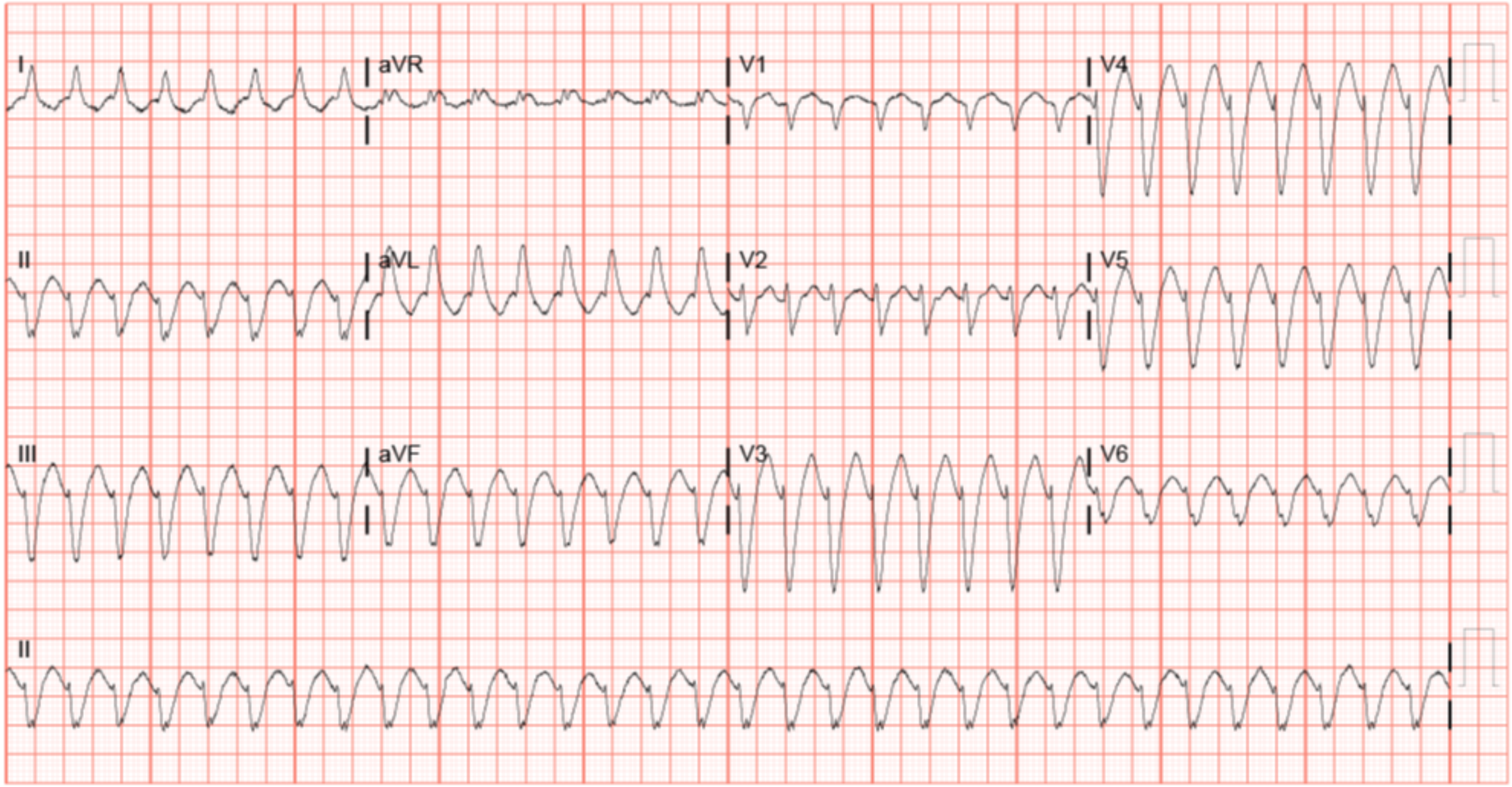

Zoom In Zoom Out Reset Add To Flash Card

prolongation. QT interval prolongation predisposes to the development of torsade de pointes, a serious ventricular arrhythmia that can cause

ventricular tachycardia named for a repetitive "twisting of the peaks" pattern. TdP is a serious arrhythmia that can cause palpitations,

Exhibit Display

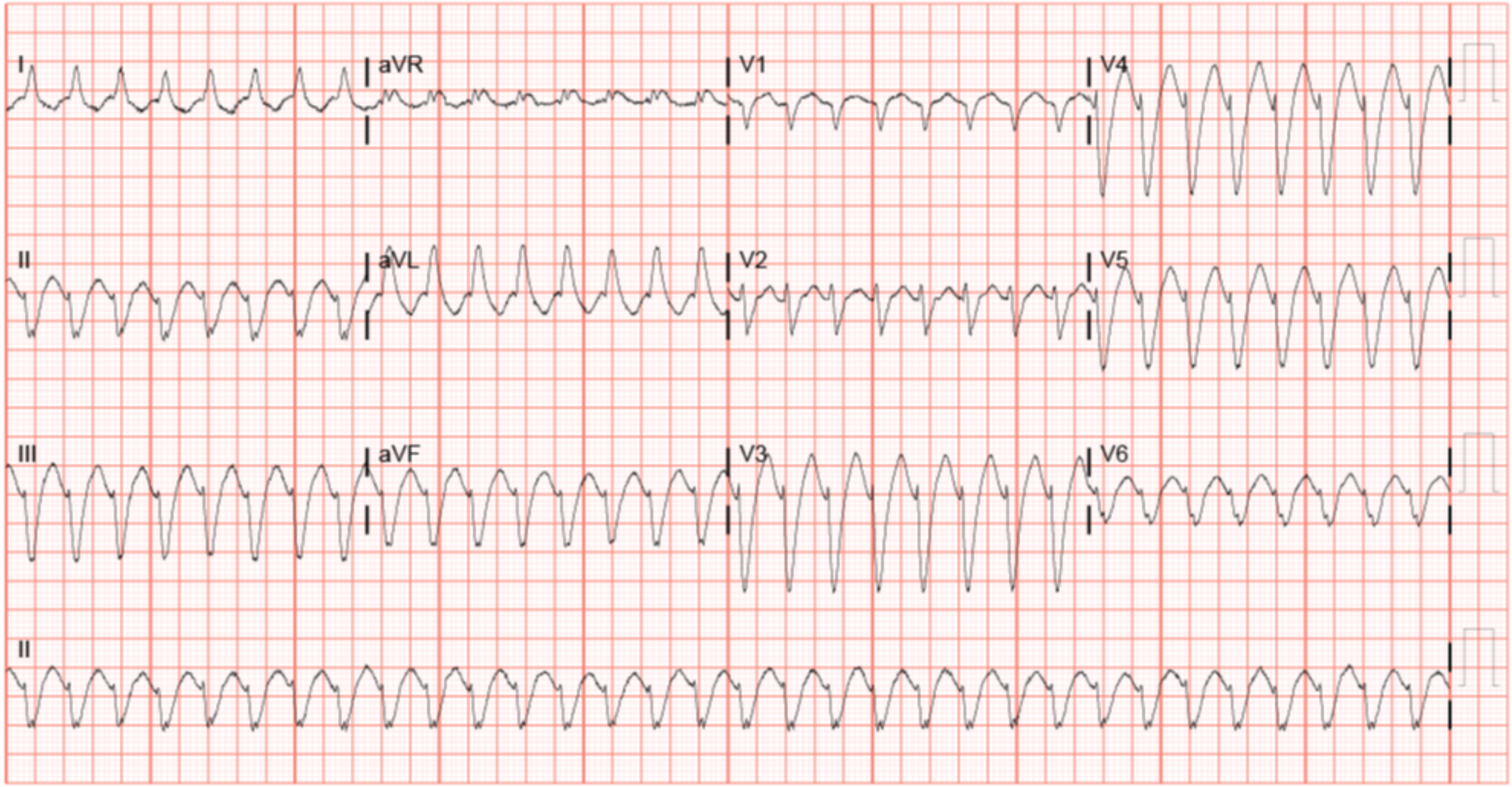

Zoom In Zoom Out Reset Add To Flash Card

Pharmacology Cardiovascular System Long QT syndrome

ventricular tachycardia named for a repetitive "twisting of the peaks" pattern. TdP is a serious arrhythmia that can cause palpitations,

Exhibit Display

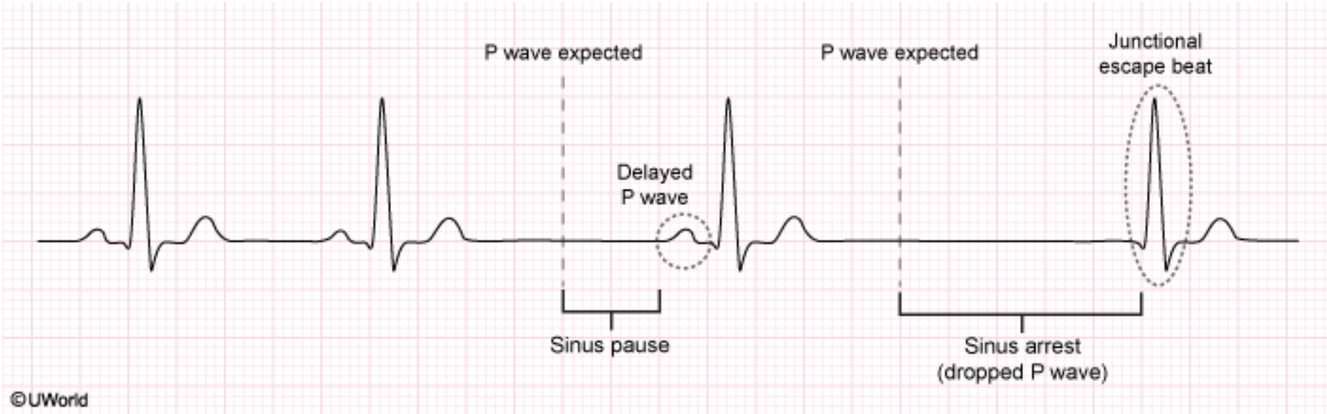

Zoom In Zoom Out Reset Add To Flash Card

Pharmacology Cardiovascular System Long QT syndrome

ventricular tachycardia named for a repetitive "twisting of the peaks" pattern. TdP is a serious arrhythmia that can cause palpitations,

Exhibit Display

Wolff-Parkinson-White pattern

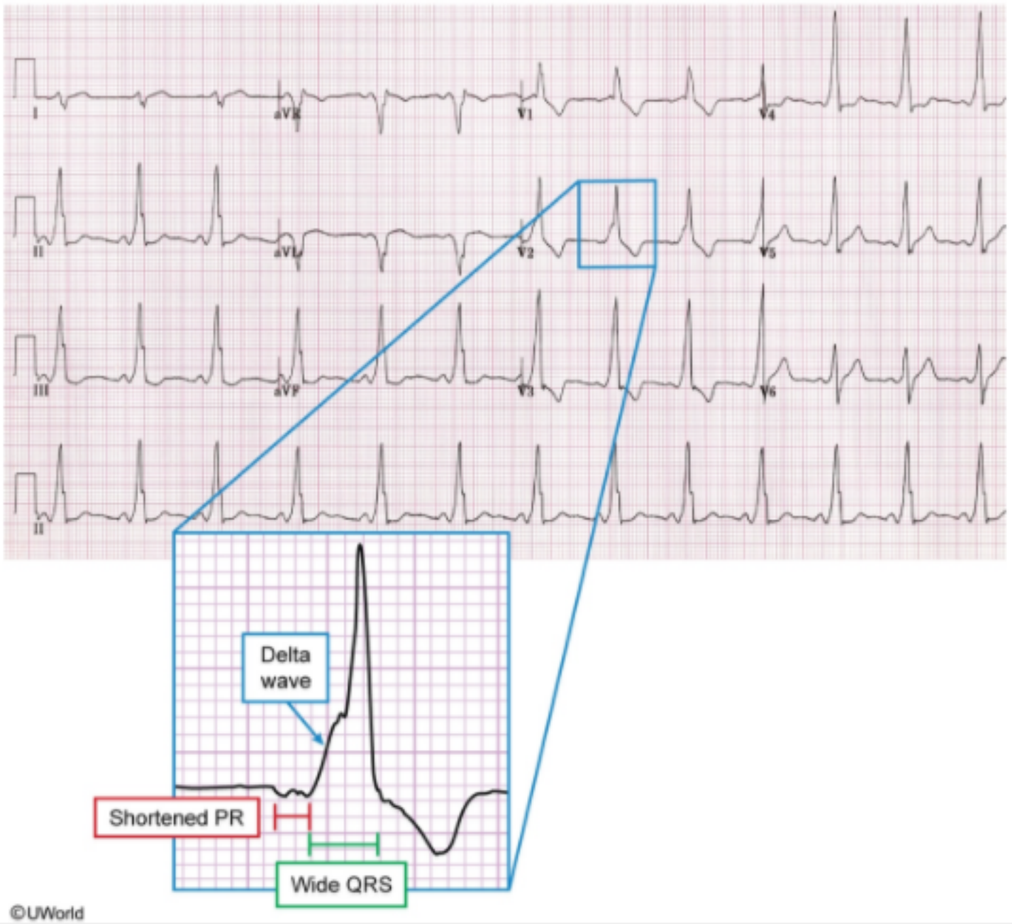

Zoom In Zoom Out Reset Add To Flash Card

Pharmacology Cardiovascular System Long QT syndrome

ventricular tachycardia named for a repetitive "twisting of the peaks" pattern. TdP is a serious arrhythmia that can cause palpitations,

Exhibit Display

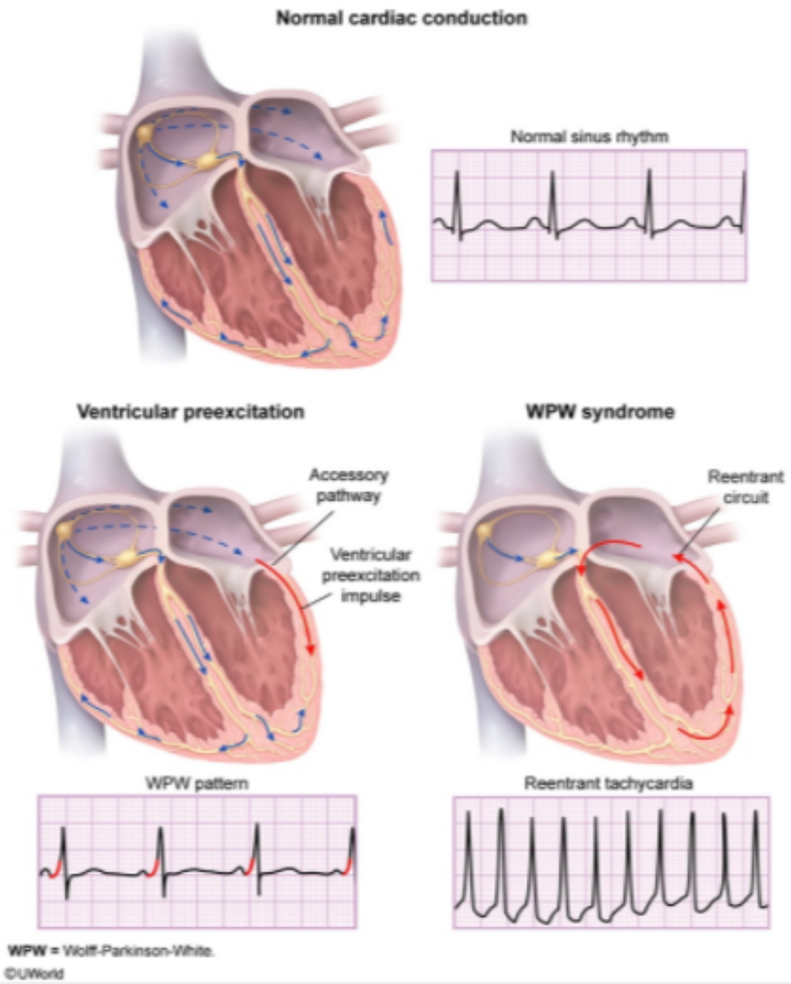

Zoom In Zoom Out Reset Add To Flash Card

Pharmacology Cardiovascular System Long QT syndrome

10
11
12
13
14
15
16
17
18
19
20
21
22
23
24
25
26
27
28
29
30
31
32
33
34
35
36
37
38
39
40

A 52-year-old woman with a history of locally advanced breast cancer comes to the office for follow-up. The patient is undergoing trastuzumab-based chemotherapy but has not received radiation therapy. She has no symptoms except mild fatigue. Blood pressure is 120/72 mm Hg and pulse is 85/min and regular. The patient is afebrile. Transthoracic echocardiography reveals a left ventricular ejection fraction of 40% with no evidence of valvular disease. Cardiac assessment prior to chemotherapy initiation was normal. Which of the following pathologic findings is most likely to be present in this patient's heart?

A. Abnormal protein accumulation in the extracellular space

B. Focal ischemic cardiomyocyte necrosis

C. Myocardial tumor cell infiltration

D. Patchy cardiomyocyte necrosis with diffuse myocardial fibrosis

E. Reduced cardiomyocyte contractility with no fibrosis

Submit

A 52-year-old woman with a history of locally advanced breast cancer comes to the office for follow-up. The patient is undergoing trastuzumab-based chemotherapy but has not received radiation therapy. She has no symptoms except mild fatigue. Blood pressure is 120/72 mm Hg and pulse is 85/min and regular. The patient is afebrile. Transthoracic echocardiography reveals a left ventricular ejection fraction of 40% with no evidence of valvular disease. Cardiac assessment prior to chemotherapy initiation was normal. Which of the following pathologic findings is most likely to be present in this patient's heart?

A. Abnormal protein accumulation in the extracellular space (11%)

B. Focal ischemic cardiomyocyte necrosis (3%)

C. Myocardial tumor cell infiltration (3%)

D. Patchy cardiomyocyte necrosis with diffuse myocardial fibrosis (27%)

✓ E. Reduced cardiomyocyte contractility with no fibrosis (53%)

Omitted
Correct answer
E

53%
Answered correctly

02 secs
Time Spent

01/29/2020
Last Updated

Explanation

Trastuzumab is a monoclonal antibody used in the treatment of **breast cancer** caused by tumor cells that overexpress human epidermal growth factor receptor-2 (**HER2**). By binding to HER2, trastuzumab blocks downstream signaling that promotes cellular proliferation and thereby encourages malignant cell apoptosis.

The major adverse effect of trastuzumab is a risk of **cardiotoxicity**, likely because HER2 signaling plays a role in minimizing oxidative stress on cardiomyocytes and preserving cardiomyocyte function. Cardiotoxicity typically manifests as a **decrease in myocardial contractility** (myocardial

Explanation

Trastuzumab is a monoclonal antibody used in the treatment of **breast cancer** caused by tumor cells that overexpress human epidermal growth factor receptor-2 (**HER2**). By binding to HER2, trastuzumab blocks downstream signaling that promotes cellular proliferation and thereby encourages malignant cell apoptosis.

The major adverse effect of trastuzumab is a risk of **cardiotoxicity**, likely because HER2 signaling plays a role in minimizing oxidative stress on cardiomyocytes and preserving cardiomyocyte function. Cardiotoxicity typically manifests as a **decrease in myocardial contractility** (myocardial stunning) **without cardiomyocyte destruction** or myocardial fibrosis. Patients usually experience an asymptomatic decline in left ventricular ejection fraction; however, overt heart failure can also occur. Unlike the cardiotoxicity that occurs with anthracyclines (eg, doxorubicin), trastuzumab-induced cardiotoxicity is not related to the cumulative chemotherapy dose and is **often reversible** with discontinuation of therapy.

(Choice A) Abnormal protein accumulation in the cardiac extracellular space is seen in patients with amyloidosis, namely with the light-chain (AL) and transthyretin (ATTR) subtypes. The disease typically manifests initially as restrictive cardiomyopathy with impaired diastolic function and preserved ejection fraction.

(Choice B) Focal ischemic cardiomyocyte necrosis leading to left ventricular systolic dysfunction is seen in patients with a prior myocardial infarction due to coronary heart disease.

(Choice C) Breast cancer is one of the most common malignancies to metastasize to the heart, typically causing pericardial effusion that may gradually progress to cardiac tamponade. However, tamponade predominantly affects diastolic filling of the right-sided heart chambers and does not decrease left ventricular ejection fraction.

(Choice D) Anthracycline-induced cardiotoxicity occurs due to oxidative damage of cellular membranes, leading to cardiomyocyte necrosis and death with eventual myocardial fibrosis.

Educational objective:
Trastuzumab is a monoclonal antibody that blocks human epidermal growth factor receptor-2 (HER2) to disrupt malignant cell signaling and encourage apoptosis. Because HER2 helps preserve cardiomyocyte function, trastuzumab can cause cardiotoxicity that manifests as a decrease in myocardial contractility without cardiomyocyte destruction or myocardial fibrosis.

References

The major adverse effect of trastuzumab is a risk of **cardiotoxicity**, likely because HER2 signaling plays a role in minimizing oxidative stress on cardiomyocytes and preserving cardiomyocyte function. Cardiotoxicity typically manifests as a **decrease in myocardial contractility** (myocardial stunning) **without cardiomyocyte destruction** or myocardial fibrosis. Patients usually experience an asymptomatic decline in left ventricular ejection fraction; however, overt heart failure can also occur. Unlike the cardiotoxicity that occurs with anthracyclines (eg, doxorubicin), trastuzumab-induced cardiotoxicity is not related to the cumulative chemotherapy dose and is **often reversible** with discontinuation of therapy.

(Choice A) Abnormal protein accumulation in the cardiac extracellular space is seen in patients with amyloidosis, namely with the light-chain (AL) and transthyretin (ATTR) subtypes. The disease typically manifests initially as restrictive cardiomyopathy with impaired diastolic function and preserved ejection fraction.

(Choice B) Focal ischemic cardiomyocyte necrosis leading to left ventricular systolic dysfunction is seen in patients with a prior myocardial infarction due to coronary heart disease.

(Choice C) Breast cancer is one of the most common malignancies to metastasize to the heart, typically causing pericardial effusion that may gradually progress to cardiac tamponade. However, tamponade predominantly affects diastolic filling of the right-sided heart chambers and does not decrease left ventricular ejection fraction.

(Choice D) Anthracycline-induced cardiotoxicity occurs due to oxidative damage of cellular membranes, leading to cardiomyocyte necrosis and death with eventual myocardial fibrosis.

Educational objective:
Trastuzumab is a monoclonal antibody that blocks human epidermal growth factor receptor-2 (HER2) to disrupt malignant cell signaling and encourage apoptosis. Because HER2 helps preserve cardiomyocyte function, trastuzumab can cause cardiotoxicity that manifests as a decrease in myocardial contractility without cardiomyocyte destruction or myocardial fibrosis.

References

- Twenty years of anti-HER2 therapy-associated cardiotoxicity.
- Cardiotoxicity associated with trastuzumab treatment of HER2+ breast cancer.

Pharmacology	Cardiovascular System	Dilated cardiomyopathy
Subject	System	Topic

A 60-year-old man comes to the office for a routine follow-up visit. He feels well overall except for an intermittent, mild, generalized headache. The patient has no known medical problems and takes no medications. He does not smoke, follows a generally healthy diet, and exercises daily. On examination, his blood pressure is 150/85 mm Hg, and he is started on lisinopril. At a follow-up visit, the patient's blood pressure is 128/78 mm Hg. He also has a dry cough that began a few weeks after starting lisinopril. This drug is stopped and losartan is now prescribed. The patient seems to be compliant with his medication; the cough resolves and he experiences no significant side effects. When compared with no treatment at all, this patient's current therapy is most likely to result in which of the following changes?

	Renin	Angiotensin I	Angiotensin II	Aldosterone	Bradykinin
A.	↓	↓	↓	↓	No change
B.	↑	↓	↓	↓	No change
C.	↑	↑	↓	↓	Increase
D.	↑	↑	↑	↓	No change
E.	↑	↑	↑	↑	No change

Submit

A 60-year-old man comes to the office for a routine follow-up visit. He feels well overall except for an intermittent, mild, generalized headache. The patient has no known medical problems and takes no medications. He does not smoke, follows a generally healthy diet, and exercises daily. On examination, his blood pressure is 150/85 mm Hg, and he is started on lisinopril. At a follow-up visit, the patient's blood pressure is 128/78 mm Hg. He also has a dry cough that began a few weeks after starting lisinopril. This drug is stopped and losartan is now prescribed. The patient seems to be compliant with his medication; the cough resolves and he experiences no significant side effects. When compared with no treatment at all, this patient's current therapy is most likely to result in which of the following changes?

	Renin	Angiotensin I	Angiotensin II	Aldosterone	Bradykinin
A. (8%)	↓	↓	↓	↓	No change
B. (9%)	↑	↓	↓	↓	No change
C. (7%)	↑	↑	↓	↓	Increase
✓ D. (65%)	↑	↑	↑	↓	No change
E. (8%)	↑	↑	↑	↑	No change

Omitted
Correct answer
D

65%
Answered correctly

02 secs
Time Spent

05/10/2020
Last Updated

10
11
12
13
14
15
16
17
18
19
20
21
22
23
24
25
26
27
28
29
30
31
32
33
34
35
36
37
38
39
40

Renin-angiotensin-aldosterone system & antihypertensives

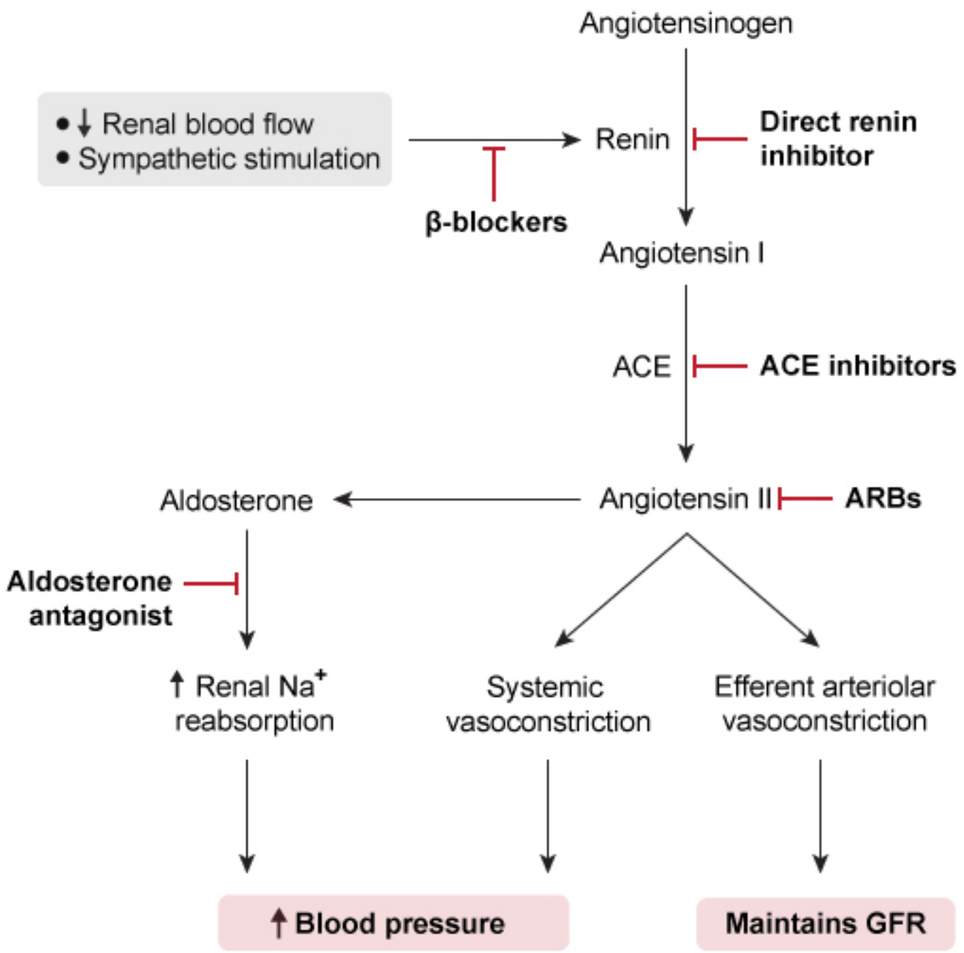

GFR = glomerular filtration rate.

©UWorld

GFR = glomerular filtration rate.
©UWorld

The renin-angiotensin-aldosterone system (RAAS) regulates arterial blood pressure and extracellular fluid balance. Renin release is stimulated by decreased sodium delivery to the distal tubule, low blood pressure (eg, low intravascular volume), and β1 sympathetic activity. Renin converts angiotensinogen to angiotensin I. Angiotensin I is then converted to angiotensin II by angiotensin-converting enzyme (ACE), which also degrades bradykinin. Angiotensin II stimulates the **type 1 angiotensin II receptors** found on vascular smooth muscle (causing vasoconstriction) and the adrenal cortex (stimulating aldosterone secretion). Systemic vasoconstriction and increased aldosterone-induced sodium reabsorption raise blood pressure, inhibiting further renin release from the kidneys (negative feedback).

Angiotensin II receptor blockers (ARBs) such as losartan competitively bind to angiotensin II receptors and block the effects of angiotensin II, resulting in **vascular smooth muscle relaxation** and **decreased aldosterone** secretion. This reduces blood pressure, stimulating renal renin production, which in turn increases conversion of angiotensin I to angiotensin II. Because ACE function remains intact with the use of ARBs, bradykinin levels are not significantly affected. This is in contrast to ACE inhibitors, which lower angiotensin II and aldosterone levels but increase bradykinin levels **(Choice C)**. Bradykinin is thought to increase prostaglandin production, which induces coughing due to bronchial irritation.

(Choice A) β1 adrenergic blockers would inhibit renin release from the juxtaglomerular apparatus, thereby suppressing the entire renin-angiotensin cascade (although lowering of the blood pressure would somewhat blunt this response). ACE activity is not regulated by renin, and so bradykinin levels are unchanged.

(Choice B) Direct renin inhibitors reduce plasma renin activity, which reduces levels of all downstream hormones. Suppression of the whole cascade lowers blood pressure, which would stimulate increased renin production. Plasma renin activity, however, is inhibited.

(Choice E) This combination of changes is seen with mineralocorticoid receptor antagonist (eg, spironolactone) or diuretic use. Mineralocorticoid receptor antagonists block aldosterone activity by binding to the mineralocorticoid receptor. Diuretics would cause a fall in blood pressure, stimulating the RAAS and increasing blood levels of all hormones.

Educational objective:
Angiotensin II receptor blockers (ARBs) work by blocking angiotensin II type 1 receptors, inhibiting the effects of angiotensin II. This results in arterial vasodilation and decreased aldosterone secretion. The resulting fall in blood pressure increases renin, angiotensin I, and angiotensin II levels. ARBs do not affect the activity of angiotensin-converting enzyme, and therefore they do not affect bradykinin degradation and do not cause cough.

10
11
12
13
14
15
16
17
18
19
20
21
22
23
24
25
26
27
28
29
30
31
32
33
34
35
36
37
38
39
40

bradykinin levels **(Choice C)**. Bradykinin is thought to increase prostaglandin production, which induces coughing due to bronchial irritation.

(Choice A) β1 adrenergic blockers would inhibit renin release from the juxtaglomerular apparatus, thereby suppressing the entire renin-angiotensin cascade (although lowering of the blood pressure would somewhat blunt this response). ACE activity is not regulated by renin, and so bradykinin levels are unchanged.

(Choice B) Direct renin inhibitors reduce plasma renin activity, which reduces levels of all downstream hormones. Suppression of the whole cascade lowers blood pressure, which would stimulate increased renin production. Plasma renin activity, however, is inhibited.

(Choice E) This combination of changes is seen with mineralocorticoid receptor antagonist (eg, spironolactone) or diuretic use. Mineralocorticoid receptor antagonists block aldosterone activity by binding to the mineralocorticoid receptor. Diuretics would cause a fall in blood pressure, stimulating the RAAS and increasing blood levels of all hormones.

Educational objective:
Angiotensin II receptor blockers (ARBs) work by blocking angiotensin II type 1 receptors, inhibiting the effects of angiotensin II. This results in arterial vasodilation and decreased aldosterone secretion. The resulting fall in blood pressure increases renin, angiotensin I, and angiotensin II levels. ARBs do not affect the activity of angiotensin-converting enzyme, and therefore they do not affect bradykinin degradation and do not cause cough.

References

- Biochemical effects of losartan, a nonpeptide angiotensin II receptor antagonist, on the renin-angiotensin-aldosterone system in hypertensive patients.
- Effects of losartan on the renin-angiotensin-aldosterone axis in essential hypertension.
- The renin-angiotensin aldosterone system: pathophysiological role and pharmacologic inhibition.

Pharmacology	Cardiovascular System	Angiotensin receptor blockers
Subject	System	Topic

Copyright © UWorld. All rights reserved.

A 45-year-old man comes to the clinic due to recurrent palpitations accompanied by chest discomfort and shortness of breath. A year ago, he was diagnosed with paroxysmal atrial fibrillation treated with rate control using a beta blocker. Past medical history is also significant for hypertension and obesity. Echocardiogram shows left atrial enlargement, normal left ventricular ejection fraction, and no significant valvular disease. 24-hour Holter monitoring reveals bursts of atrial fibrillation associated with the patient's symptoms. He is initiated on dofetilide to maintain normal sinus rhythm. This medication exerts its main effect on which portion of the action potential curve?

A. A
B. B
C. C
D. D
E. E

Submit

10
11
12
13
14
15
16
17
18
19
20
21
22
23
24
25
26
27
28
29
30
31
32
33
34
35
36
37
38
39
40

A 45-year-old man comes to the clinic due to recurrent palpitations accompanied by chest discomfort and shortness of breath. A year ago, he was diagnosed with paroxysmal atrial fibrillation treated with rate control using a beta blocker. Past medical history is also significant for hypertension and obesity. Echocardiogram shows left atrial enlargement, normal left ventricular ejection fraction, and no significant valvular disease. 24-hour Holter monitoring reveals bursts of atrial fibrillation associated with the patient's symptoms. He is initiated on dofetilide to maintain normal sinus rhythm. This medication exerts its main effect on which portion of the action potential curve?

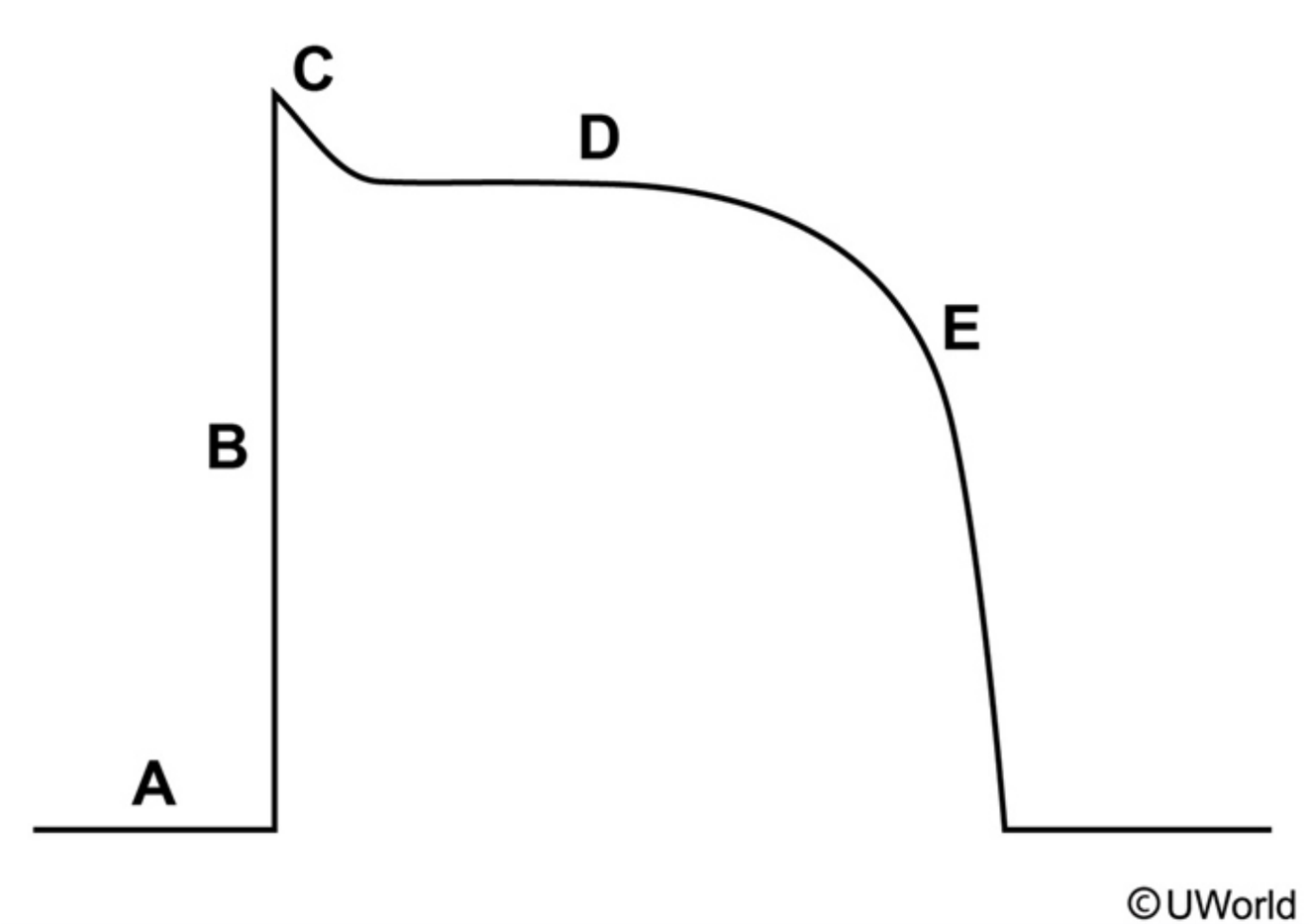

10
11
12
13
14
15
16
17
18
19
20
21
22
23
24
25
26
27
28
29
30
31
32
33
34
35
36
37
38
39
40

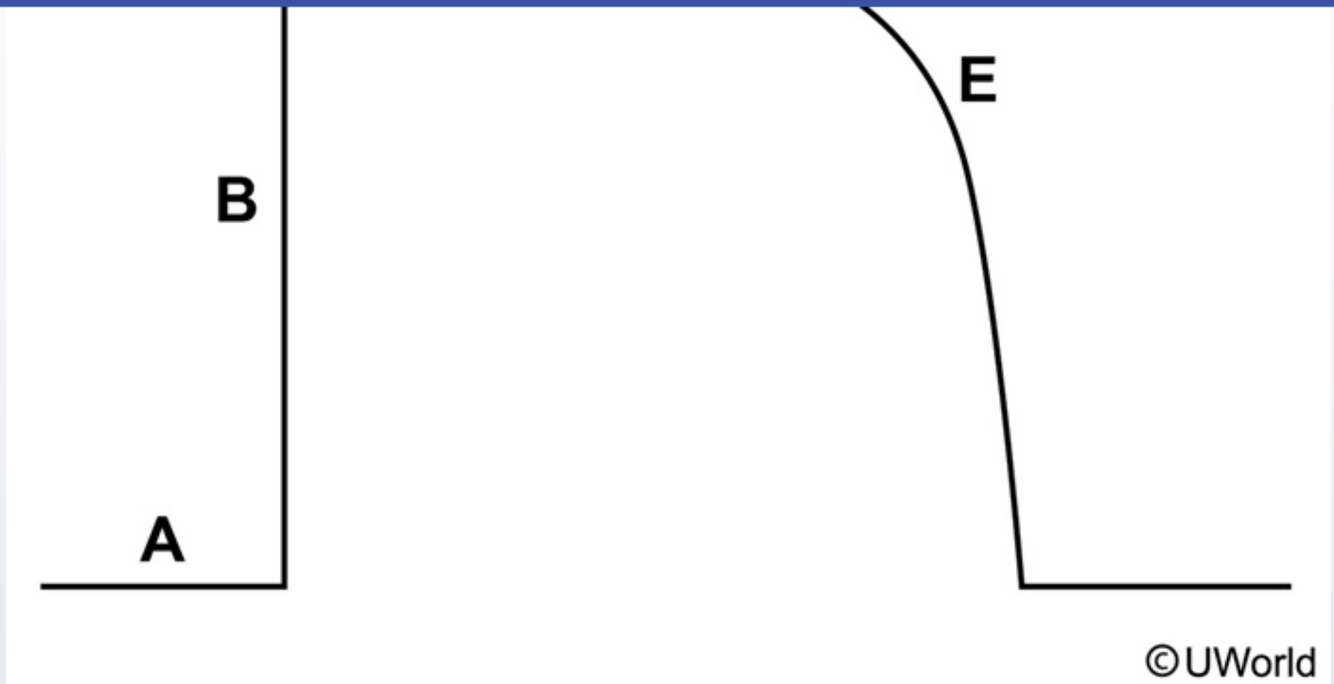

A. A
B. B
C. C
D. D
E. E

Submit

10
11
12
13
14
15
16
17
18
19
20
21
22
23
24
25
26
27
28
29
30
31
32
33
34
35
36
37
38
39
40

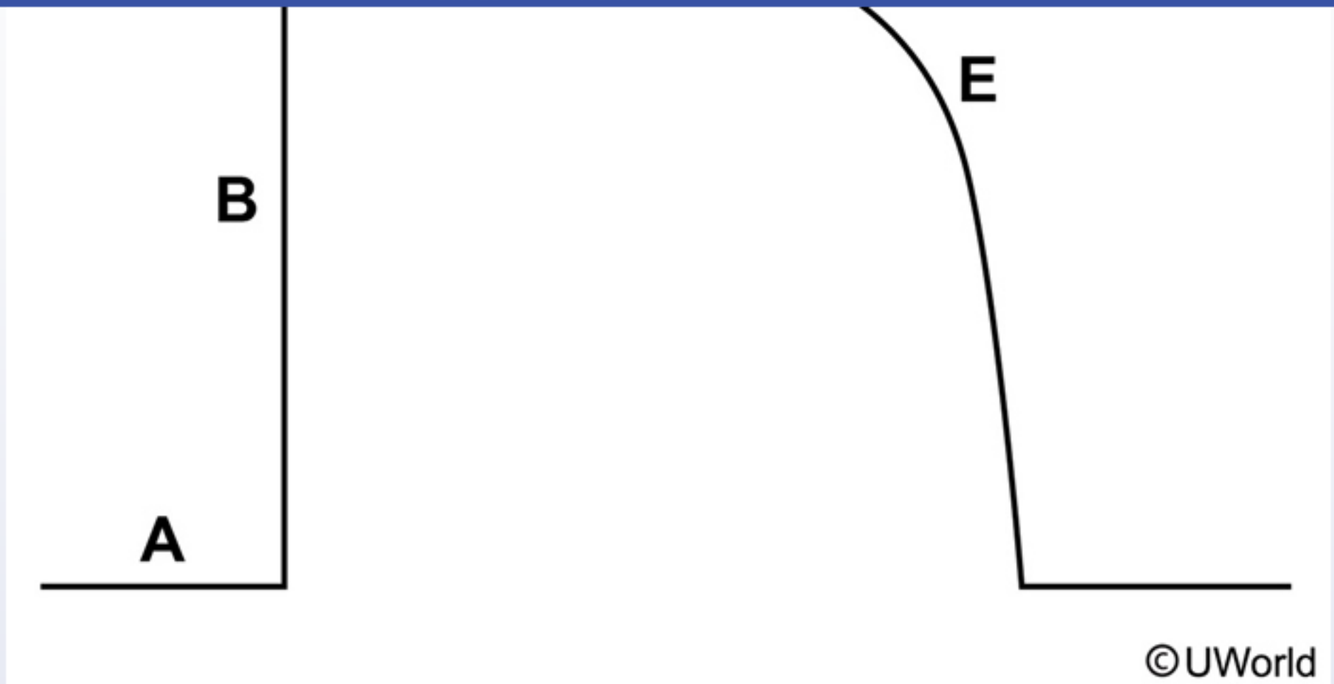

A. A (3%)
B. B (18%)
C. C (2%)
D. D (14%)
✓ E. E (61%)

Omitted
Correct answer

61%
Answered correctly

06 secs
Time Spent

03/11/2020
Last Updated

10
11
12
13
14
15
16
17
18
19
20
21
22
23
24
25
26
27
28
29
30
31
32
33
34
35
36
37
38
39
40

Cardiac action potentials

Pacemaker action potential

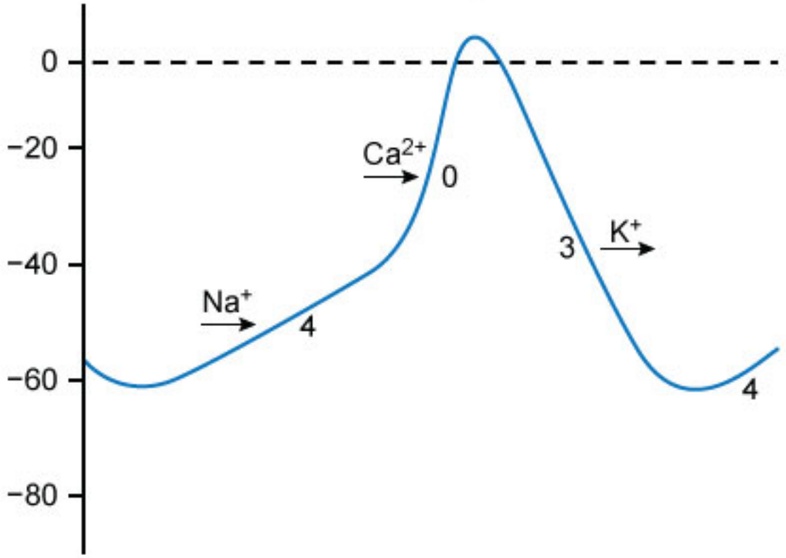

Nonpacemaker action potential

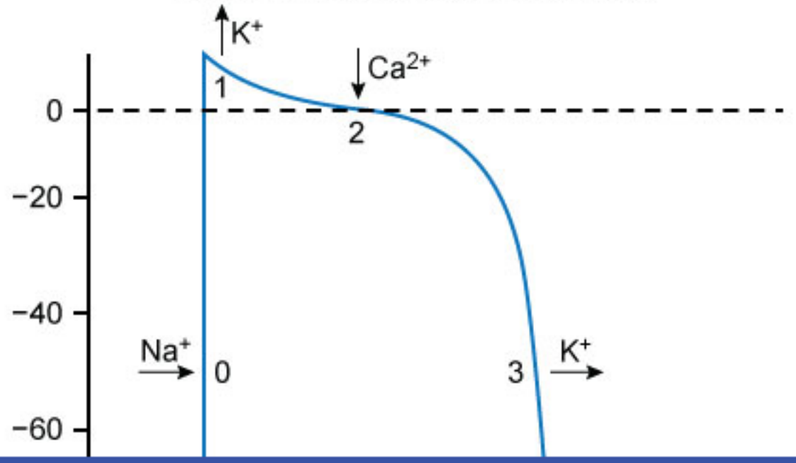

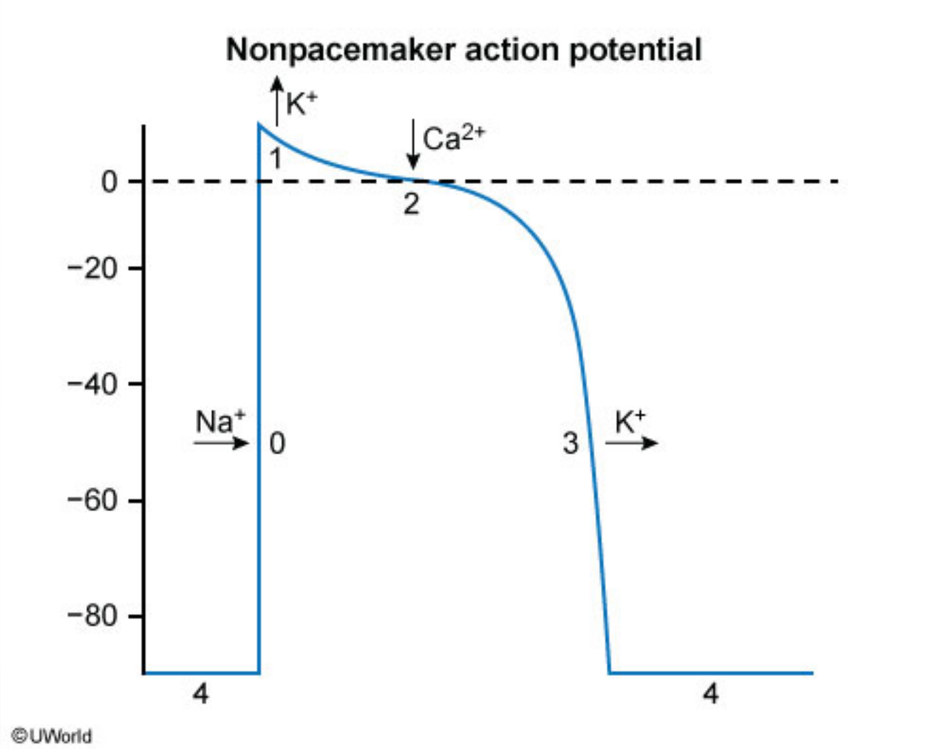

The typical myocardial action potential of "nonpacemaker" or cardiac myocytes includes several phases:

1. **Phase 0 (rapid depolarization)** – occurs when the resting membrane potential reaches threshold; it is characterized by rapid sodium entry into the cell due to activation and opening of voltage-dependent sodium channels. Class I antiarrhythmic drugs (eg, procainamide, flecainide, lidocaine) block these sodium channels and inhibit the initial depolarization phase (phase 0) of the action potential.
2. **Phase 1 (early repolarization)** – caused primarily by activation of transient outward potassium currents along with a rapid decline in inward sodium current. This phase is not modulated to an appreciable extent by antiarrhythmic medications.
3. **Phase 2 (plateau phase)** – Stable membrane potential due to a balance of "late" inward calcium current and outward potassium current. Calcium channel blockers (verapamil, diltiazem) are class IV antiarrhythmic drugs that inhibit the L-type calcium channels during this phase. These medications slow the sinus rate, prolong conduction through the atrioventricular node, and depress myocardial contractility (negative

The typical myocardial action potential of "nonpacemaker" or cardiac myocytes includes several phases:

1. **Phase 0 (rapid depolarization)** – occurs when the resting membrane potential reaches threshold; it is characterized by rapid sodium entry into the cell due to activation and opening of voltage-dependent sodium channels. Class I antiarrhythmic drugs (eg, procainamide, flecainide, lidocaine) block these sodium channels and inhibit the initial depolarization phase (phase 0) of the action potential.

2. **Phase 1 (early repolarization)** – caused primarily by activation of transient outward potassium currents along with a rapid decline in inward sodium current. This phase is not modulated to an appreciable extent by antiarrhythmic medications.

3. **Phase 2 (plateau phase)** – Stable membrane potential due to a balance of "late" inward calcium current and outward potassium current. Calcium channel blockers (verapamil, diltiazem) are class IV antiarrhythmic drugs that inhibit the L-type calcium channels during this phase. These medications slow the sinus rate, prolong conduction through the atrioventricular node, and depress myocardial contractility (negative inotropic effect).

4. **Phase 3 (late repolarization)** – characterized by the opening of **potassium channels** and the efflux of potassium ions from the cell (delayed rectifier potassium currents IKr and IKs) in conjunction with the decay of inward calcium current. **Class III** antiarrhythmic drugs (**amiodarone, sotalol, dofetilide**) predominantly block potassium channels and inhibit the outward potassium current during this phase, leading to prolongation of repolarization, action potential duration, and the QT interval on ECG. These medications are often used for **maintenance of sinus rhythm** in patients with **paroxysmal atrial fibrillation**.

5. **Phase 4 (recovery)** – normal resting membrane potential is between −80 and −95 mV and is generated by open potassium channels (inward rectifier current). Antiarrhythmic drugs do not affect phase 4 of the myocyte action potential, but beta blockers and calcium channel blockers can slow diastolic depolarization (phases 4 and 0) in pacemaker cells by decreasing the slope of depolarization.

Educational objective:
Class III antiarrhythmic drugs (amiodarone, sotalol, dofetilide) predominantly block potassium channels and inhibit the outward potassium currents during phase 3 of the cardiac action potential, thereby prolonging repolarization and total action potential duration.

Pharmacology	Cardiovascular System	Antiarrhythmic drugs
Subject	System	Topic

A 67-year-old man with nonischemic cardiomyopathy comes to the office for follow-up. He recently was hospitalized for acute decompensated heart failure. The patient's symptoms have improved with multidrug treatment, but he has persistent shortness of breath on mild exertion. He has a history of hypertension and hypercholesterolemia. Blood pressure is 115/70 mm Hg and pulse is 66/min. There is a third heart sound on heart auscultation and mild lower extremity pitting edema. A recent echocardiogram showed a left ventricular ejection fraction of 30%. Which of the following diuretics would most likely improve survival if added to this patient's current regimen?

- A. Acetazolamide
- B. Furosemide
- C. Hydrochlorothiazide
- D. Mannitol
- E. Spironolactone
- F. Triamterene

Submit

A 67-year-old man with nonischemic cardiomyopathy comes to the office for follow-up. He recently was hospitalized for acute decompensated heart failure. The patient's symptoms have improved with multidrug treatment, but he has persistent shortness of breath on mild exertion. He has a history of hypertension and hypercholesterolemia. Blood pressure is 115/70 mm Hg and pulse is 66/min. There is a third heart sound on heart auscultation and mild lower extremity pitting edema. A recent echocardiogram showed a left ventricular ejection fraction of 30%. Which of the following diuretics would most likely improve survival if added to this patient's current regimen?

- A. Acetazolamide (1%)
- B. Furosemide (27%)
- C. Hydrochlorothiazide (16%)
- D. Mannitol (1%)
- ✓ E. Spironolactone (50%)
- F. Triamterene (2%)

Omitted
Correct answer
E

50%
Answered correctly

02 secs
Time Spent

02/16/2020
Last Updated

Explanation

Mineralocorticoid receptor antagonists (eg, spironolactone, eplerenone) prevent aldosterone from binding to its receptor in the distal renal tubules. This leads to increased sodium and water excretion while conserving potassium ions (**potassium-sparing diuresis**). These antagonists also block the deleterious effect of aldosterone on the heart, causing regression of myocardial fibrosis and **improvement in ventricular remodeling**.

10
11
12
13
14
15
16
17
18
19
20
21
22
23
24
25
26
27
28
29
30
31
32
33
34
35
36
37
38
39
40

Mineralocorticoid receptor antagonists (eg, spironolactone, eplerenone) prevent aldosterone from binding to its receptor in the distal renal tubules. This leads to increased sodium and water excretion while conserving potassium ions (**potassium-sparing diuresis**). These antagonists also block the deleterious effect of aldosterone on the heart, causing regression of myocardial fibrosis and **improvement in ventricular remodeling**.

Mineralocorticoid receptor antagonists reduce morbidity and **improve survival** in patients with congestive heart failure and decreased ejection fraction. Therefore, they are recommended in addition to standard heart failure therapy (ACE inhibitors and beta blockers). They should not be used in patients with hyperkalemia or renal failure. The most common side effects are hyperkalemia and gynecomastia (spironolactone >> eplerenone).

(Choices A, C, and F) Acetazolamide (carbonic anhydrase inhibitor), hydrochlorothiazide (thiazide diuretic), and triamterene (epithelial sodium channel blocker) have a variably lower diuretic effect compared to loop diuretics and are not as efficacious for treating heart failure symptoms.

(Choice B) Furosemide is a loop diuretic frequently used for treatment of pulmonary congestion and fluid retention in heart failure patients. Although loop diuretics improve symptoms significantly, they do not provide survival benefit (ie, improved morbidity but not mortality) in these patients.

(Choice D) Mannitol is an intravenous osmotic diuretic used primarily to lower intracranial pressure and treat acute glaucoma. It is not used to treat heart failure as it can cause an initial rise in extracellular fluid volume, exacerbating pulmonary congestion and peripheral fluid retention.

Educational objective:
Mineralocorticoid receptor antagonists (eg, spironolactone, eplerenone) improve survival in patients with congestive heart failure and reduced left ventricular ejection fraction. They should not be used in patients with hyperkalemia or renal failure.

References

- The effect of spironolactone on morbidity and mortality in patients with severe heart failure. Randomized Aldactone Evaluation Study Investigators.
- Eplerenone in patients with systolic heart failure and mild symptoms.

10
11
12
13
14
15
16
17
18
19
20
21
22
23
24
25
26
27
28
29
30
31
32
33
34
35
36
37
38
39
40

A 65-year-old man with type 2 diabetes mellitus comes to the office due to decreased sexual performance over the last 6 months. The patient says his libido, muscle strength, and energy level are normal, but his erections are inconsistent, weak, and of inadequate duration for sexual activity. Past medical history is positive for hypertension, but he has no history of coronary artery disease and no suspicious chest pain. Bilateral ankle brachial index testing is within normal limits. The patient is treated with sildenafil, which gives significant improvement in his sexual performance. The intracellular signaling of this drug is most similar to that of which of the following substances?

A. 1,25-dihydroxycholecalciferol
B. Brain natriuretic peptide
C. Gamma-aminobutyric acid
D. Insulin
E. Interleukin-2
F. Platelet-derived growth factor

Submit

A 65-year-old man with type 2 diabetes mellitus comes to the office due to decreased sexual performance over the last 6 months. The patient says his libido, muscle strength, and energy level are normal, but his erections are inconsistent, weak, and of inadequate duration for sexual activity. Past medical history is positive for hypertension, but he has no history of coronary artery disease and no suspicious chest pain. Bilateral ankle brachial index testing is within normal limits. The patient is treated with sildenafil, which gives significant improvement in his sexual performance. The intracellular signaling of this drug is most similar to that of which of the following substances?

- A. 1,25-dihydroxycholecalciferol (3%)
- ✓ B. Brain natriuretic peptide (70%)
- C. Gamma-aminobutyric acid (7%)
- D. Insulin (6%)
- E. Interleukin-2 (3%)
- F. Platelet-derived growth factor (9%)

Omitted
Correct answer
B

70%
Answered correctly

02 secs
Time Spent

04/05/2020
Last Updated

Explanation

Atrial and **brain natriuretic peptides** (ANP and BNP) are polypeptide hormones that exert their effect by binding ANP receptors. These transmembrane receptors are linked to a **guanylyl cyclase** that converts guanosine 5′-triphosphate to cyclic guanosine 3′,5′-monophosphate (cGMP). cGMP then activates a downstream cGMP-dependent protein kinase, leading to relaxation of vascular smooth muscle and subsequent **vasodilation**. Nitric oxide activates the same cGMP second messenger system by binding a cytosolic guanylyl cyclase.

10
11
12
13
14
15
16
17
18
19
20
21
22
23
24
25
26
27
28
29
30
31
32
33
34
35
36
37
38
39
40

Atrial and **brain natriuretic peptides** (ANP and BNP) are polypeptide hormones that exert their effect by binding ANP receptors. These transmembrane receptors are linked to a **guanylyl cyclase** that converts guanosine 5′-triphosphate to cyclic guanosine 3′,5′-monophosphate (cGMP). cGMP then activates a downstream cGMP-dependent protein kinase, leading to relaxation of vascular smooth muscle and subsequent **vasodilation**. Nitric oxide activates the same cGMP second messenger system by binding a cytosolic guanylyl cyclase.

Penile erection is initiated by release of acetylcholine and nitric oxide (NO) from parasympathetic fibers, leading to a rise in intracellular cGMP and vasodilation of the arteries supplying the corpus cavernosum. Sildenafil is a **phosphodiesterase-5 inhibitor** that decreases degradation of cGMP, enhancing the effect of parasympathetic activation in erectile tissues. Because vasodilatory nitrates (eg, nitroglycerin, isosorbide mononitrate) work by releasing NO, coadministration of sildenafil with nitrates can lead to excessive cGMP-induced vasodilation and severe hypotension.

(Choice A) 1,25-dihydroxycholecalciferol is the active form of vitamin D; it is a sterol vitamin that freely crosses cell membranes and interacts with a receptor that primarily resides in the nucleus.

(Choice C) Gamma-aminobutyric acid is an inhibitory neurotransmitter that acts to hyperpolarize nerve cells by binding ligand-gated ion channels or metabotropic receptors.

(Choice D) The insulin receptor consists of 2 alpha and 2 beta subunits. The alpha subunits are extracellular and provide the binding site for insulin. The beta subunits are intracellular and contain tyrosine kinase domains.

(Choice E) Interleukin-2 (IL-2) receptor is a transmembrane protein complex that acts via a multipathway system, including a JAK-STAT signaling component, a MAP kinase pathway, and phosphoinositide 3-kinase.

(Choice F) Platelet-derived growth factor stimulates cell growth and division, including angiogenesis. It acts via a tyrosine kinase receptor.

Educational objective:
Atrial natriuretic peptide, brain natriuretic peptide, and nitric oxide activate guanylyl cyclase and increase conversion of guanosine 5′-triphosphate to cyclic guanosine 3′,5′-monophosphate (cGMP). Phosphodiesterase inhibitors (eg, sildenafil) decrease the degradation of cGMP. Elevated intracellular cGMP levels lead to relaxation of vascular smooth muscle and vasodilation.

References

Penile erection is initiated by release of acetylcholine and nitric oxide (NO) from parasympathetic fibers, leading to a rise in intracellular cGMP and vasodilation of the arteries supplying the corpus cavernosum. Sildenafil is a **phosphodiesterase-5 inhibitor** that decreases degradation of cGMP, enhancing the effect of parasympathetic activation in erectile tissues. Because vasodilatory nitrates (eg, nitroglycerin, isosorbide mononitrate) work by releasing NO, coadministration of sildenafil with nitrates can lead to excessive cGMP-induced vasodilation and severe hypotension.

(Choice A) 1,25-dihydroxycholecalciferol is the active form of vitamin D; it is a sterol vitamin that freely crosses cell membranes and interacts with a receptor that primarily resides in the nucleus.

(Choice C) Gamma-aminobutyric acid is an inhibitory neurotransmitter that acts to hyperpolarize nerve cells by binding ligand-gated ion channels or metabotropic receptors.

(Choice D) The insulin receptor consists of 2 alpha and 2 beta subunits. The alpha subunits are extracellular and provide the binding site for insulin. The beta subunits are intracellular and contain tyrosine kinase domains.

(Choice E) Interleukin-2 (IL-2) receptor is a transmembrane protein complex that acts via a multipathway system, including a JAK-STAT signaling component, a MAP kinase pathway, and phosphoinositide 3-kinase.

(Choice F) Platelet-derived growth factor stimulates cell growth and division, including angiogenesis. It acts via a tyrosine kinase receptor.

Educational objective:
Atrial natriuretic peptide, brain natriuretic peptide, and nitric oxide activate guanylyl cyclase and increase conversion of guanosine 5′-triphosphate to cyclic guanosine 3′,5′-monophosphate (cGMP). Phosphodiesterase inhibitors (eg, sildenafil) decrease the degradation of cGMP. Elevated intracellular cGMP levels lead to relaxation of vascular smooth muscle and vasodilation.

References

- Sildenafil: efficacy, safety, tolerability and mechanism of action in treating erectile dysfunction.

Pharmacology	Cardiovascular System	Phosphodiesterase inhibitors
Subject	System	Topic

Copyright © UWorld. All rights reserved.

An 85-year-old man is transferred to the hospital from a nursing home due to fever and confusion. On arrival, the patient is admitted directly to the intensive care unit with a presumptive diagnosis of septic shock. Antibiotic therapy is initiated. The patient is unable to provide any history, but his caretakers state that he has had nonspecific symptoms, including fever, for the past few days. The patient has a history of cardiovascular disease, diverticulitis, and dementia. Blood pressure is 60/40 mm Hg despite aggressive intravenous hydration. Intravenous norepinephrine is administered in response to the patient's hypotension. Which of the following cellular changes is most likely to occur in direct response to the medication?

A. cAMP decrease in bronchial smooth muscle cells

B. cAMP increase in cardiac muscle cells

C. cAMP increase in vascular smooth muscle cells

D. DAG decrease in vascular smooth muscle cells

E. IP_3 increase in cardiac muscle cells

Submit

An 85-year-old man is transferred to the hospital from a nursing home due to fever and confusion. On arrival, the patient is admitted directly to the intensive care unit with a presumptive diagnosis of septic shock. Antibiotic therapy is initiated. The patient is unable to provide any history, but his caretakers state that he has had nonspecific symptoms, including fever, for the past few days. The patient has a history of cardiovascular disease, diverticulitis, and dementia. Blood pressure is 60/40 mm Hg despite aggressive intravenous hydration. Intravenous norepinephrine is administered in response to the patient's hypotension. Which of the following cellular changes is most likely to occur in direct response to the medication?

- A. cAMP decrease in bronchial smooth muscle cells (2%)
- ✓ B. cAMP increase in cardiac muscle cells (38%)
- C. cAMP increase in vascular smooth muscle cells (35%)
- D. DAG decrease in vascular smooth muscle cells (9%)
- E. IP_3 increase in cardiac muscle cells (13%)

Omitted
Correct answer
B

38%
Answered correctly

02 mins, 35 secs
Time Spent

02/06/2020
Last Updated

Explanation

Receptor stimulated	Change in second messenger	Primary effects
Alpha-1	↑ IP_3	• Peripheral vasoconstriction • Urethral constriction

Receptor stimulated	Change in second messenger	Primary effects
Alpha-1	↑ IP_3	• Peripheral vasoconstriction • Urethral constriction • Pupillary dilation
Alpha-2	↓ cAMP	• CNS sympatholytic • ↓ insulin release & intestinal motility
Beta-1	↑ cAMP	• ↑ Cardiac contractility & heart rate • ↑ Renin release by JG cells of kidney
Beta-2	↑ cAMP	• Peripheral vasodilation • Bronchodilation
Muscarinic-2	↓ cAMP	• ↓ Cardiac contractility & heart rate
Muscarinic-3	↑ IP_3	• Bronchoconstriction • ↑ insulin release & intestinal motility • Bladder contraction • Pupillary constriction • Peripheral vasodilation*

*Via release of nitric oxide.

cAMP = cyclic AMP; **IP_3** = inositol 1,4,5-triphosphate; **JG** = juxtaglomerular.

Stimulation of adrenoreceptors leads to a change in concentration of a second messenger (eg, cAMP), which mediates the effects on the target organ. **Norepinephrine**, an adrenergic agonist, is the preferred pharmacologic treatment for **septic shock** as it predominately stimulates a1, a2, and B1 receptors, with little influence on B2 receptors. This leads to the following clinical effects:

1. Stimulation of **α1 adrenoreceptors** leads to **vasoconstriction** in the skin and viscera, resulting in increased systolic and diastolic blood pressure with decreased renal and hepatic blood flow. α1-mediated vasoconstriction occurs via the IP_3-second messenger pathway.

Stimulation of adrenoreceptors leads to a change in concentration of a second messenger (eg, cAMP), which mediates the effects on the target organ. **Norepinephrine**, an adrenergic agonist, is the preferred pharmacologic treatment for **septic shock** as it predominately stimulates a1, a2, and B1 receptors, with little influence on B2 receptors. This leads to the following clinical effects:

1. Stimulation of **α1 adrenoreceptors** leads to **vasoconstriction** in the skin and viscera, resulting in increased systolic and diastolic blood pressure with decreased renal and hepatic blood flow. α1-mediated vasoconstriction occurs via the IP_3-second messenger pathway.
2. Stimulation of **β1 adrenoreceptors** within the heart increases **cAMP** concentrations through G_s-mediated receptor coupling, which leads to increased **cardiac contractility**, **conduction**, and **heart rate**. However, the direct effect of norepinephrine on heart rate is counteracted by an indirect, baroreceptor-mediated reflex bradycardia that occurs following the increase in peripheral resistance. The combined result of these effects is often an unchanged or even decreased heart rate.
3. Stimulation of α2 adrenoreceptors causes a decrease in cAMP in pancreatic β cells and in the intestines, resulting in decreased insulin secretion and reduced intestinal motility. Central α2 adrenoreceptors are not stimulated by intravenous administration of norepinephrine as the molecule does not cross the blood-brain barrier.

(Choice A) Stimulation of β2 adrenoreceptors in bronchial smooth muscle cells leads to increased, rather than decreased, cAMP synthesis, resulting in bronchodilation. Regardless, norepinephrine does not significantly stimulate β2 adrenoreceptors.

(Choices C and D) Norepinephrine-mediated stimulation of α1 adrenoreceptors increases, rather than decreases, IP_3 (increased calcium release) and DAG concentrations in vascular smooth muscle cells. cAMP is increased after β2 adrenoreceptors are stimulated; however, because norepinephrine does not significantly stimulate β2 adrenoreceptors, cAMP concentrations in vascular smooth muscle are not increased.

(Choice E) A significant elevation in IP_3 concentration does not occur in cardiac muscle cells following norepinephrine administration. The cardiac effects of norepinephrine are primarily mediated by β1 adrenoreceptors that are linked to a cAMP, rather than IP_3, signal transduction pathway.

Educational objective:
Norepinephrine stimulates cardiac β1 adrenoreceptors, which increases cAMP concentration within cardiac myocytes and leads to increased contractility, conduction, and heart rate. Peripheral vasoconstriction occurs via stimulation of α1 adrenoreceptors in vascular smooth muscle cells and activation of an IP_3 signaling pathway.

2. Stimulation of **β1 adrenoreceptors** within the heart increases **cAMP** concentrations through G_s-mediated receptor coupling, which leads to increased **cardiac contractility**, **conduction**, and **heart rate**. However, the direct effect of norepinephrine on heart rate is counteracted by an indirect, baroreceptor-mediated reflex bradycardia that occurs following the increase in peripheral resistance. The combined result of these effects is often an unchanged or even decreased heart rate.

3. Stimulation of α2 adrenoreceptors causes a decrease in cAMP in pancreatic β cells and in the intestines, resulting in decreased insulin secretion and reduced intestinal motility. Central α2 adrenoreceptors are not stimulated by intravenous administration of norepinephrine as the molecule does not cross the blood-brain barrier.

(Choice A) Stimulation of β2 adrenoreceptors in bronchial smooth muscle cells leads to increased, rather than decreased, cAMP synthesis, resulting in bronchodilation. Regardless, norepinephrine does not significantly stimulate β2 adrenoreceptors.

(Choices C and D) Norepinephrine-mediated stimulation of α1 adrenoreceptors increases, rather than decreases, IP_3 (increased calcium release) and DAG concentrations in vascular smooth muscle cells. cAMP is increased after β2 adrenoreceptors are stimulated; however, because norepinephrine does not significantly stimulate β2 adrenoreceptors, cAMP concentrations in vascular smooth muscle are not increased.

(Choice E) A significant elevation in IP_3 concentration does not occur in cardiac muscle cells following norepinephrine administration. The cardiac effects of norepinephrine are primarily mediated by β1 adrenoreceptors that are linked to a cAMP, rather than IP_3, signal transduction pathway.

Educational objective:
Norepinephrine stimulates cardiac β1 adrenoreceptors, which increases cAMP concentration within cardiac myocytes and leads to increased contractility, conduction, and heart rate. Peripheral vasoconstriction occurs via stimulation of α1 adrenoreceptors in vascular smooth muscle cells and activation of an IP_3 signaling pathway.

References

- Early administration of norepinephrine increases cardiac preload and cardiac output in septic patients with life-threatening hypotension.

Pharmacology	Cardiovascular System	Sympathomimetic agents
Subject	System	Topic

Exhibit Display

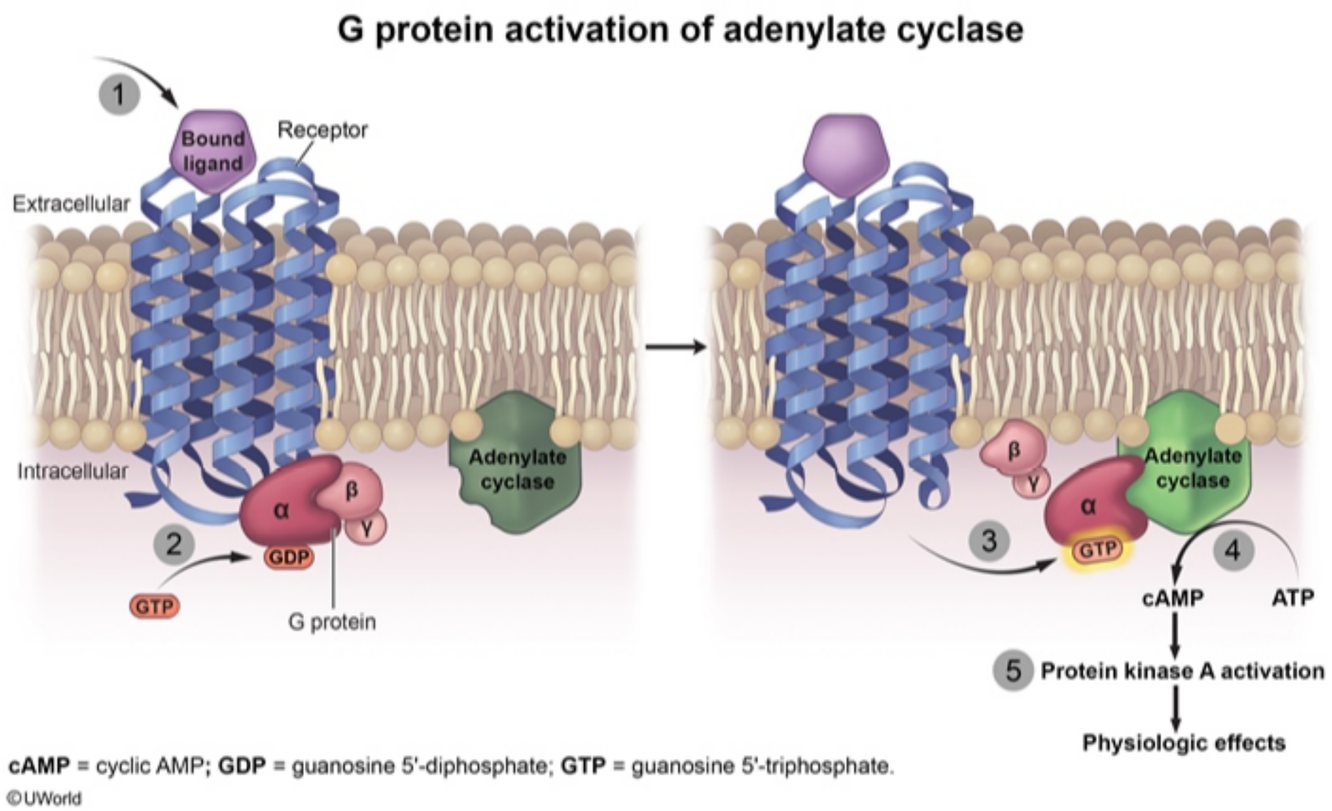

Zoom In | Zoom Out | Reset | Add To New Card | Existing Card

1
2
3
4
5
6
7
8
9
10
11
12
13
14
15
16
17
18
19
20
21
22
23
24
25
26
27
28
29
30
31

A 37-year-old man with no significant medical history comes to the office due to intermittent palpitations. He has a healthy lifestyle, exercises daily, and does not use tobacco, alcohol, or illicit drugs. ECG shows atrial fibrillation with rapid ventricular response. Echocardiogram reveals normal heart function with no significant valvular disease. The patient is started on an antiarrhythmic medication that is known to be effective against both atrial and ventricular arrhythmias. On ECG, this medication causes QRS prolongation with only minimal increase in QT interval duration. Which of the following regions of the action potential curve is most affected by this drug?

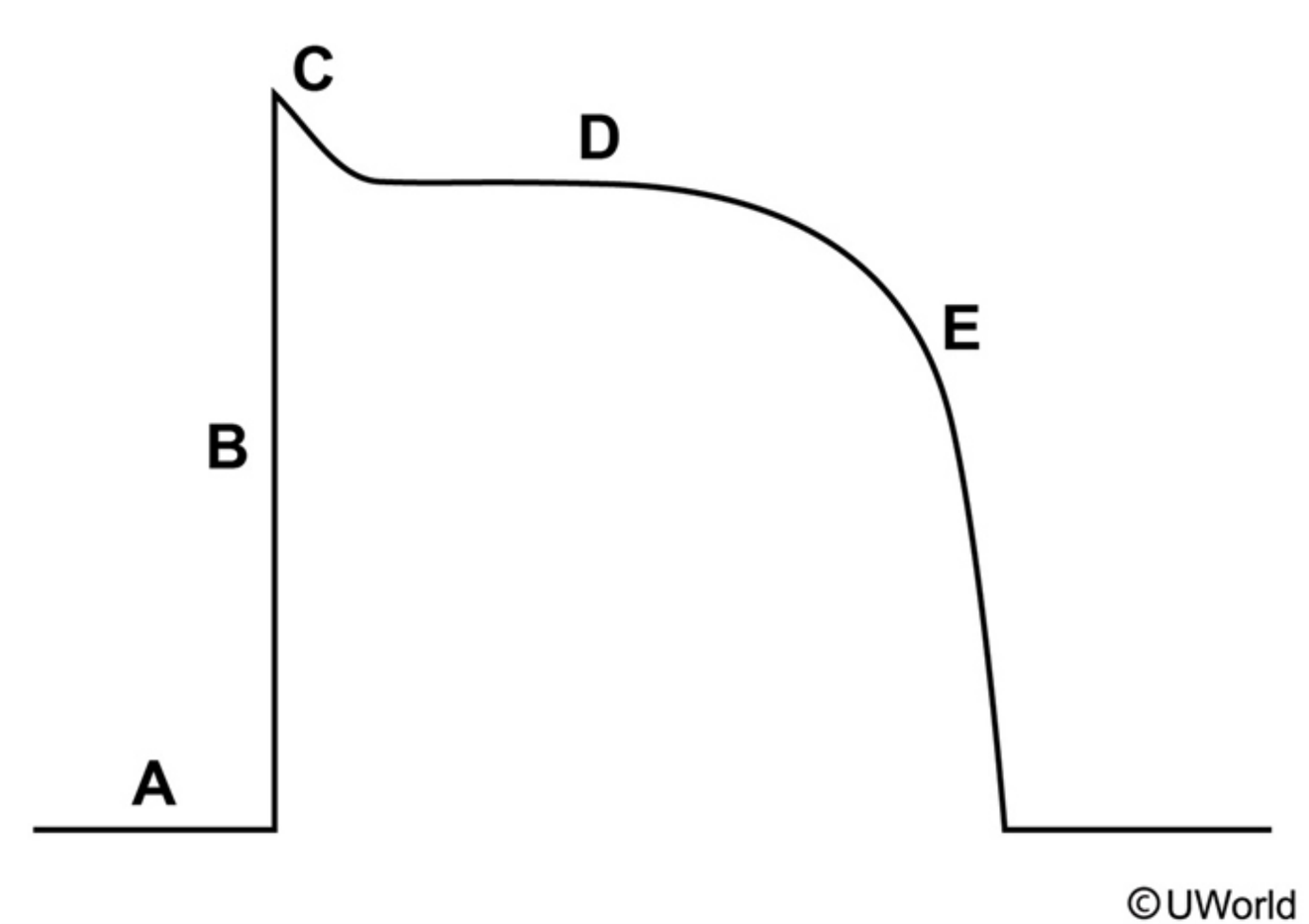

1 2 3 4 5 6 7 8 9 10 11 12 13 14 15 16 17 18 19 20 21 22 23 24 25 26 27 28 29 30 31

normal heart function with no significant valvular disease. The patient is started on an antiarrhythmic medication that is known to be effective against both atrial and ventricular arrhythmias. On ECG, this medication causes QRS prolongation with only minimal increase in QT interval duration. Which of the following regions of the action potential curve is most affected by this drug?

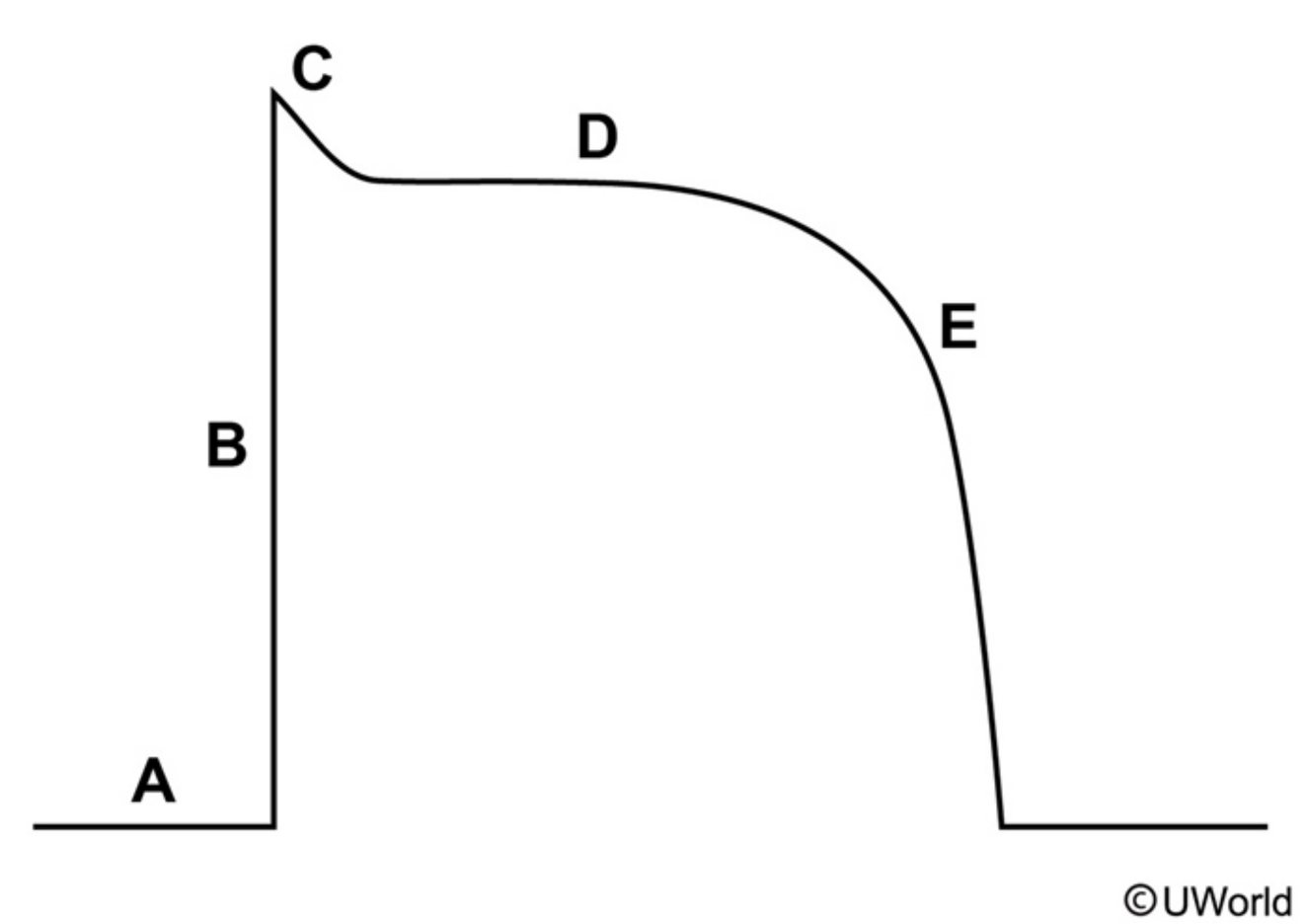

A. A

B. B

1
2
3
4
5
6
7
8
9
10
11
12
13
14
15
16
17
18
19
20
21
22
23
24
25
26
27
28
29
30
31

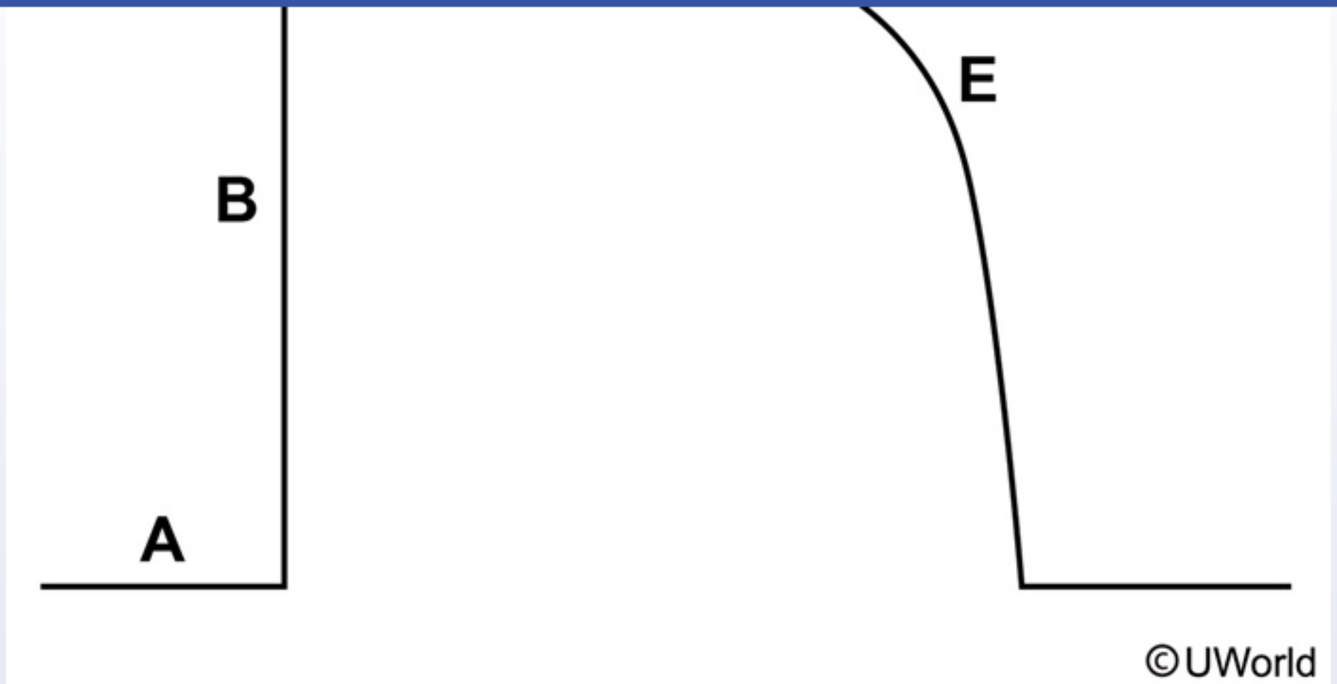

A. A
B. B
C. C
D. D
E. E

Submit

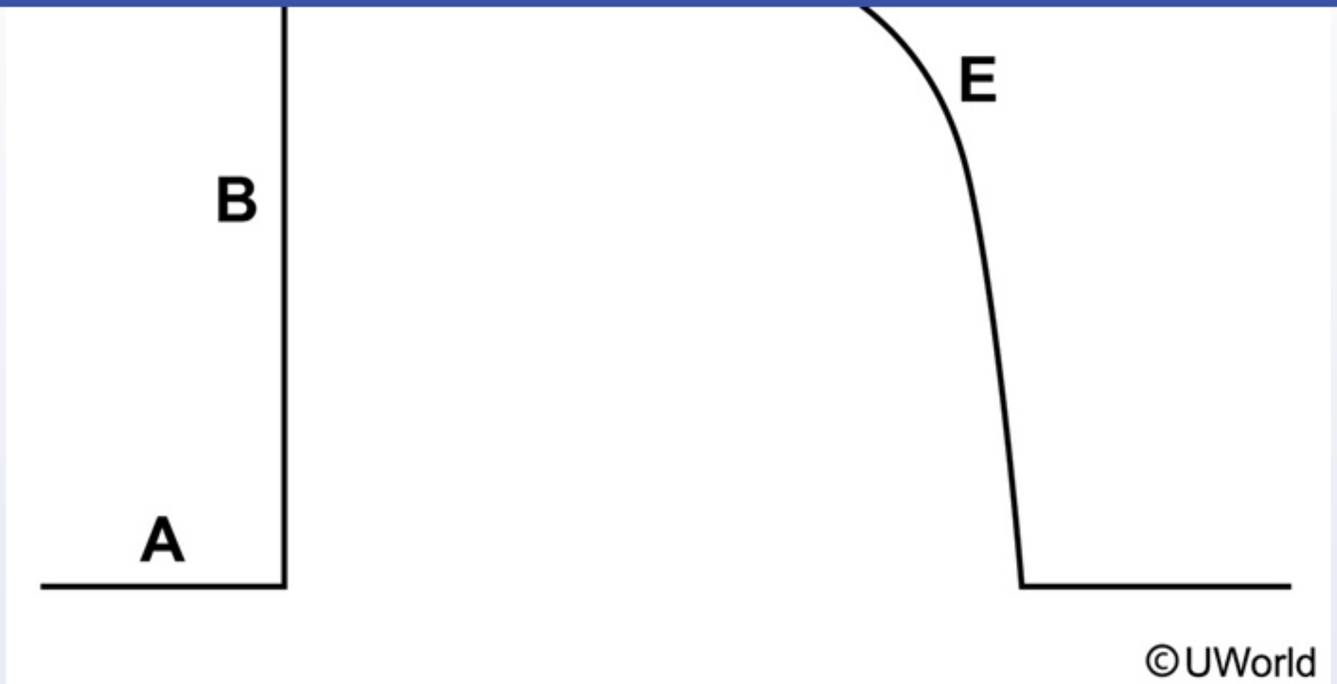

A. A (1%)
B. B (60%) ✓
C. C (3%)
D. D (17%)
E. E (16%)

Omitted
Correct answer

60%
Answered correctly

08 secs
Time Spent

04/25/2020
Last Updated

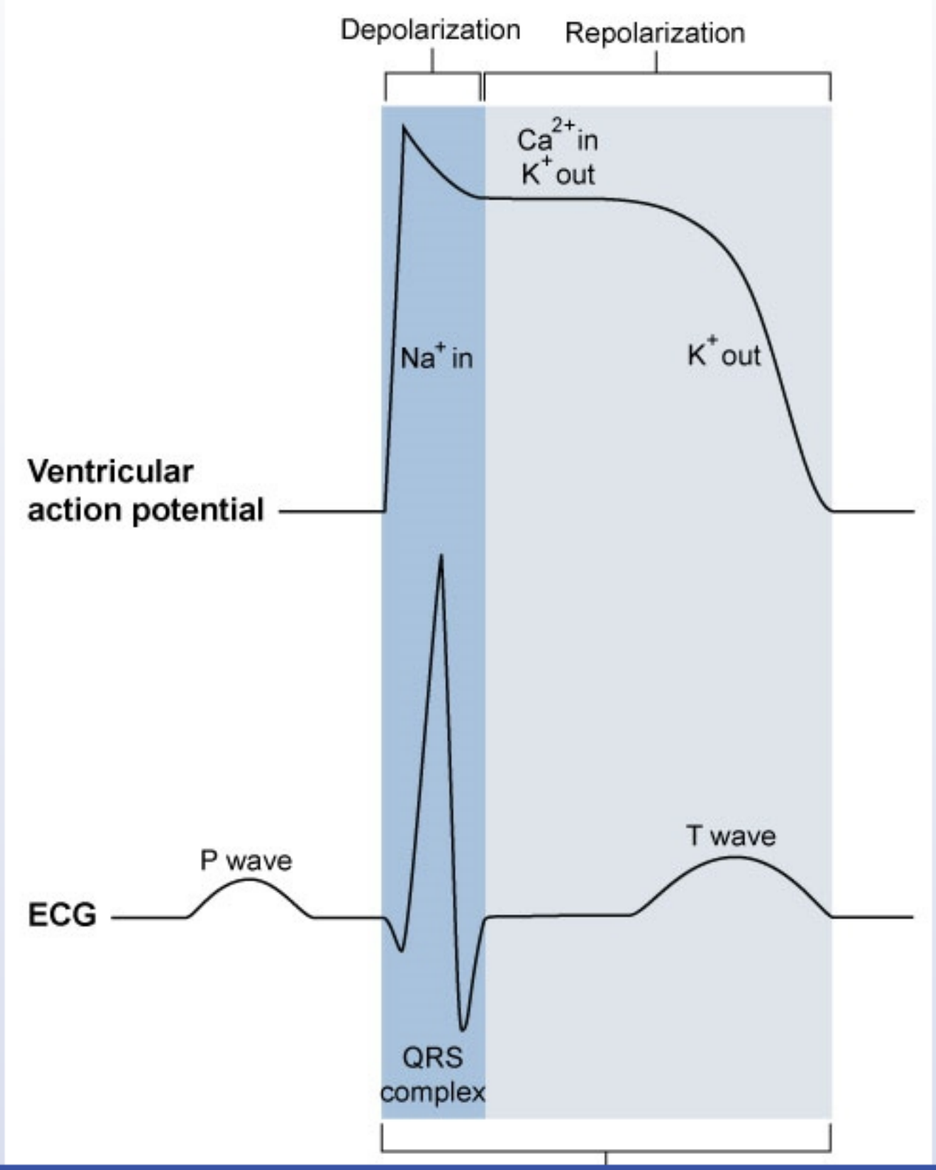
Depolarization
Repolarization
Ca^{2+} in
K^+ out
Na^+ in
K^+ out
Ventricular action potential
P wave
T wave
ECG
QRS complex

This patient with atrial fibrillation was most likely started on a **class IC** antiarrhythmic agent, which typically cause QRS prolongation with little effect on QT interval duration.

The **QRS complex** represents rapid **ventricular depolarization** and corresponds to phase 0 of the ventricular myocyte action potential. The QT interval represents both ventricular depolarization and repolarization (total duration of ventricular action potential). However, since ventricular depolarization (QRS duration) contributes only a small amount of time to the interval, the **QT interval** is primarily a measure of **ventricular repolarization**.

Ventricular depolarization occurs due to the opening of **voltage-dependent sodium channels**. In general, class I antiarrhythmics act by blocking these channels, inhibiting the initial depolarization and **prolonging QRS duration**. Specific actions are as follows:

- Class 1A (eg, procainamide) drugs have intermediate sodium channel blocking activity that increases QRS duration. Their moderate potassium channel-blocking activity also causes significant QT interval prolongation.
- Class 1B drugs (eg, lidocaine) have no significant effect on the QRS duration and do not prolong the QT interval due to their rapid dissociation from the receptor.
- Class IC drugs (eg, flecainide, propafenone) are strong sodium channel blockers that prolong QRS duration in a rate-dependent manner. The QT interval may become slightly prolonged due to QRS widening.

(Choice A) Antiarrhythmic drugs do not affect phase 4 of the myocyte action potential, but they can affect phase 4 of the pacemaker cell action potential, which is characterized by slow depolarization due to sodium influx.

(Choice C) Phase 1 of the myocyte action potential refers to a brief period of repolarization caused by a sharp decrease in sodium conductance and an increase in potassium permeability. It is not modulated to an appreciable extent by antiarrhythmic medications.

(Choice D) Calcium channel blockers (eg, verapamil, diltiazem) inhibit the L-type calcium channels during phase 2 depolarization of the myocardial action potential with additional effects on cardiac slow response tissue. They slow the sinus rate, prolong conduction through the atrioventricular node, and depress myocardial contractility (negative inotropic effect).

(Choice E) Class III antiarrhythmic drugs (eg, amiodarone, sotalol, dofetilide) predominantly block potassium channels and inhibit the outward repolarizing currents during phase 3 of the myocyte action potential. This leads to increased action potential duration and QT interval prolongation.

effect on QT interval duration.

The **QRS complex** represents rapid **ventricular depolarization** and corresponds to phase 0 of the ventricular myocyte action potential. The QT interval represents both ventricular depolarization and repolarization (total duration of ventricular action potential). However, since ventricular depolarization (QRS duration) contributes only a small amount of time to the interval, the **QT interval** is primarily a measure of **ventricular repolarization**.

Ventricular depolarization occurs due to the opening of **voltage-dependent sodium channels**. In general, class I antiarrhythmics act by blocking these channels, inhibiting the initial depolarization and **prolonging QRS duration**. Specific actions are as follows:

- Class 1A (eg, procainamide) drugs have intermediate sodium channel blocking activity that increases QRS duration. Their moderate potassium channel-blocking activity also causes significant QT interval prolongation.
- Class 1B drugs (eg, lidocaine) have no significant effect on the QRS duration and do not prolong the QT interval due to their rapid dissociation from the receptor.
- Class IC drugs (eg, flecainide, propafenone) are strong sodium channel blockers that prolong QRS duration in a rate-dependent manner. The QT interval may become slightly prolonged due to QRS widening.

(Choice A) Antiarrhythmic drugs do not affect phase 4 of the myocyte action potential, but they can affect phase 4 of the pacemaker cell action potential, which is characterized by slow depolarization due to sodium influx.

(Choice C) Phase 1 of the myocyte action potential refers to a brief period of repolarization caused by a sharp decrease in sodium conductance and an increase in potassium permeability. It is not modulated to an appreciable extent by antiarrhythmic medications.

(Choice D) Calcium channel blockers (eg, verapamil, diltiazem) inhibit the L-type calcium channels during phase 2 depolarization of the myocardial action potential with additional effects on cardiac slow response tissue. They slow the sinus rate, prolong conduction through the atrioventricular node, and depress myocardial contractility (negative inotropic effect).

(Choice E) Class III antiarrhythmic drugs (eg, amiodarone, sotalol, dofetilide) predominantly block potassium channels and inhibit the outward repolarizing currents during phase 3 of the myocyte action potential. This leads to increased action potential duration and QT interval prolongation.

Educational objective:
Class 1C antiarrhythmic agents (flecainide) block the fast sodium channels responsible for ventricular depolarization (phase 0), prolonging QRS

these channels, inhibiting the initial depolarization and **prolonging QRS duration**. Specific actions are as follows:

- Class 1A (eg, procainamide) drugs have intermediate sodium channel blocking activity that increases QRS duration. Their moderate potassium channel-blocking activity also causes significant QT interval prolongation.
- Class 1B drugs (eg, lidocaine) have no significant effect on the QRS duration and do not prolong the QT interval due to their rapid dissociation from the receptor.
- Class IC drugs (eg, flecainide, propafenone) are strong sodium channel blockers that prolong QRS duration in a rate-dependent manner. The QT interval may become slightly prolonged due to QRS widening.

(Choice A) Antiarrhythmic drugs do not affect phase 4 of the myocyte action potential, but they can affect phase 4 of the pacemaker cell action potential, which is characterized by slow depolarization due to sodium influx.

(Choice C) Phase 1 of the myocyte action potential refers to a brief period of repolarization caused by a sharp decrease in sodium conductance and an increase in potassium permeability. It is not modulated to an appreciable extent by antiarrhythmic medications.

(Choice D) Calcium channel blockers (eg, verapamil, diltiazem) inhibit the L-type calcium channels during phase 2 depolarization of the myocardial action potential with additional effects on cardiac slow response tissue. They slow the sinus rate, prolong conduction through the atrioventricular node, and depress myocardial contractility (negative inotropic effect).

(Choice E) Class III antiarrhythmic drugs (eg, amiodarone, sotalol, dofetilide) predominantly block potassium channels and inhibit the outward repolarizing currents during phase 3 of the myocyte action potential. This leads to increased action potential duration and QT interval prolongation.

Educational objective:
Class 1C antiarrhythmic agents (flecainide) block the fast sodium channels responsible for ventricular depolarization (phase 0), prolonging QRS duration with little effect on the QT interval. Class 1A and class III agents cause the most QT prolongation.

Pharmacology	Cardiovascular System	Antiarrhythmic drugs
Subject	System	Topic

Copyright © UWorld. All rights reserved.

P wave

Exhibit Display

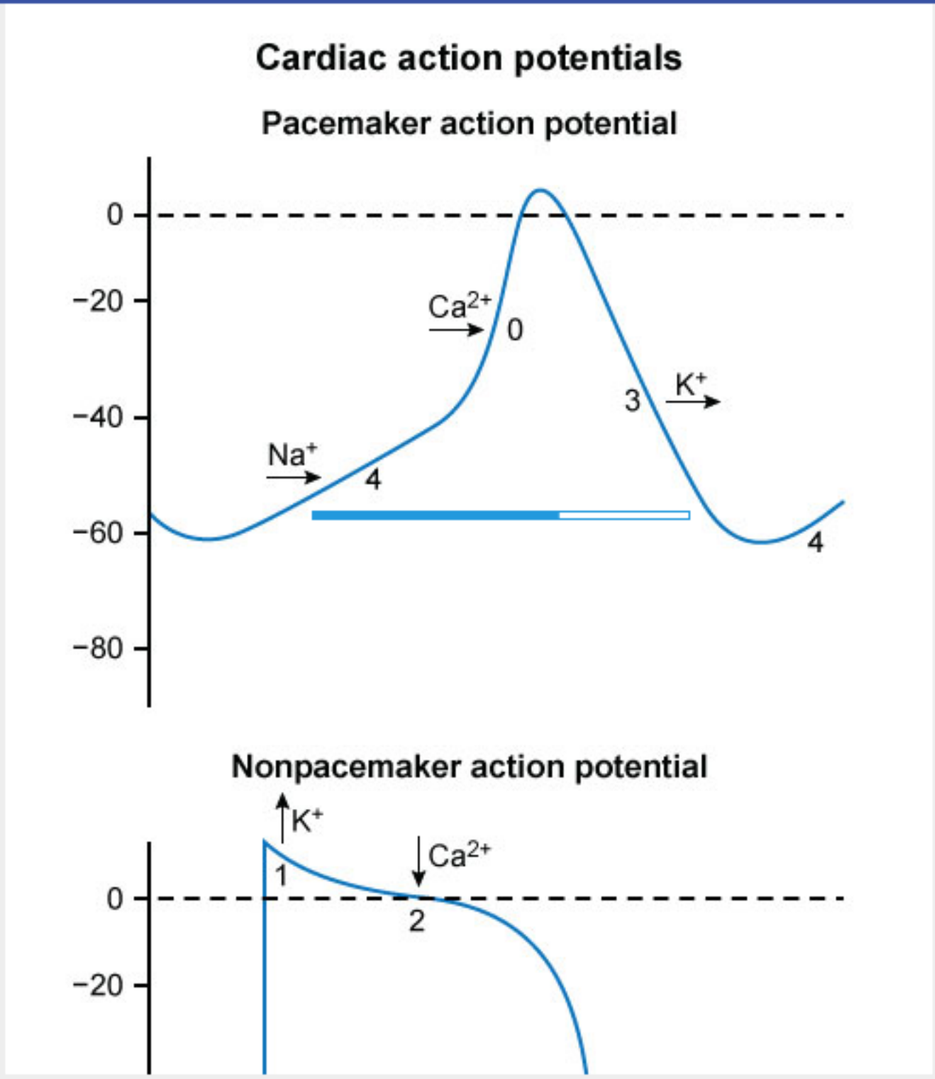

P wave

Exhibit Display

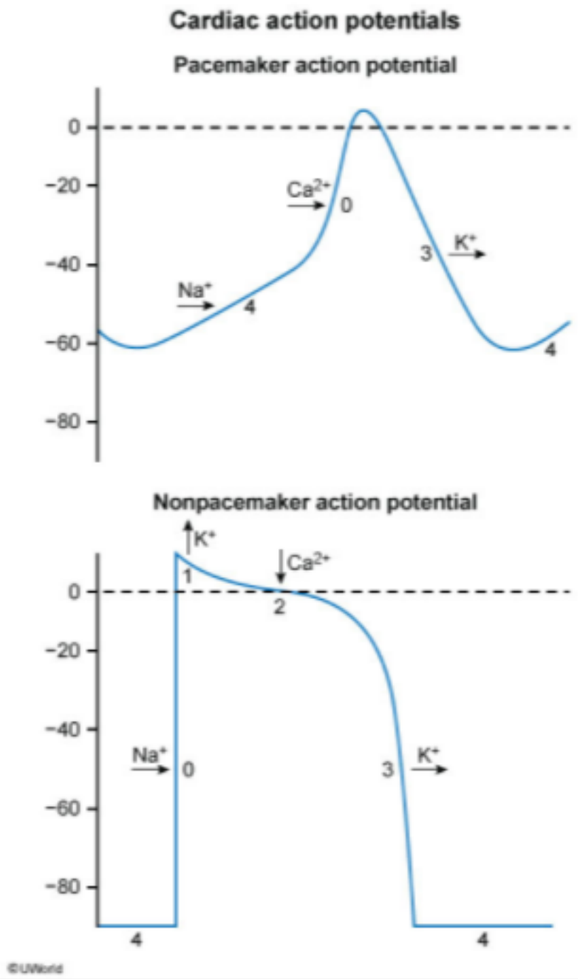

Zoom In | Zoom Out | Reset | Add To New Card | Existing Card

P wave

Exhibit Display

Antiarrhythmic drugs – Vaughan Williams classification

Class	Drugs	Predominant actions
IA	**Sodium channel blockers** • Disopyramide • Procainamide • Quinidine	• Slows AP conduction velocity • Prolongs APD
IB	• Lidocaine • Mexiletine • Phenytoin	• No effect on AP conduction velocity • Shortens APD
IC	• Flecainide • Propafenone	• Slows AP conduction velocity • Minimal effect on APD
II	**Beta receptor blockers** • Atenolol • Metoprolol • Esmolol • Carvedilol	• Slows sinus node discharge rate • Slows AV nodal conduction & prolongs refractoriness
III	**Potassium channel blockers** • Amiodarone • Dronedarone • Dofetilide • Sotalol (also class II)	• No effect on AP conduction velocity • Prolongs APD
IV	**Non-dihydropyridine calcium channel blockers** • Verapamil • Diltiazem	• Slows sinus node discharge rate • Slows AV nodal conduction & prolongs refractoriness

AP = action potential; APD = action potential duration; AV = atrioventricular.

©UWorld

Zoom In | Zoom Out | Reset | Add To New Card | Existing Card

A 79-year-old man is brought to the hospital due to confusion for the past 2 days. The patient has had nausea, decreased appetite, and poor oral intake for several weeks. He has also mentioned that everything around him has "a yellow tint." He has no abdominal pain. Medical history includes long-standing heart failure with reduced ejection fraction and atrial fibrillation. Medications include metoprolol, digoxin, lisinopril, and apixaban. The patient is afebrile. Blood pressure is 130/80 mm Hg and pulse is 58/min. The abdomen is soft and nontender; there is no rigidity or rebound and no masses are present. Age-related changes in which of the following factors most likely accounts for this patient's symptoms?

- A. Intestinal absorption
- B. Liver enzyme activity
- C. Muscle mass
- D. Plasma protein binding
- E. Renal clearance

Submit

A 79-year-old man is brought to the hospital due to confusion for the past 2 days. The patient has had nausea, decreased appetite, and poor oral intake for several weeks. He has also mentioned that everything around him has "a yellow tint." He has no abdominal pain. Medical history includes long-standing heart failure with reduced ejection fraction and atrial fibrillation. Medications include metoprolol, digoxin, lisinopril, and apixaban. The patient is afebrile. Blood pressure is 130/80 mm Hg and pulse is 58/min. The abdomen is soft and nontender; there is no rigidity or rebound and no masses are present. Age-related changes in which of the following factors most likely accounts for this patient's symptoms?

- A. Intestinal absorption (2%)
- B. Liver enzyme activity (24%)
- C. Muscle mass (3%)
- D. Plasma protein binding (2%)
- ✓ E. Renal clearance (66%)

Omitted
Correct answer
E

66%
Answered correctly

02 secs
Time Spent

01/23/2020
Last Updated

Explanation

Symptoms of digoxin toxicity	
Cardiac	• Life-threatening arrhythmias
Gastrointestinal	• Anorexia • Nausea & vomiting

Symptoms of digoxin toxicity	
Cardiac	• **Life-threatening arrhythmias**
Gastrointestinal	• Anorexia • Nausea & vomiting • Abdominal pain
Neurologic	• Fatigue • Confusion • Weakness • **Color vision alterations**

Digoxin is a cardiac glycoside that can be used to treat atrial fibrillation and systolic heart failure. This patient is experiencing symptoms classically associated with **digoxin toxicity**, which include visual changes (particularly **yellow tinting** of objects) and gastrointestinal disturbances. Digoxin is **renally cleared** and has a narrow therapeutic window, so toxicity frequently results from alterations in kidney function. As patients age, renal function decreases progressively. This decrease in renal function is often not accompanied by a concomitant rise in serum creatinine, as creatinine is derived from muscle tissue and lean body mass also decreases with age. Therefore, elderly patients (even those with a normal serum creatinine) should receive reduced doses of renally cleared medications to prevent toxicity.

(Choice A) Intestinal absorption affects the dose of digoxin that reaches the bloodstream. Some preparations of digoxin may have a higher bioavailability than others, and some patients may carry gut bacteria that degrade digoxin before it has the ability to cross into the bloodstream.

(Choice B) Liver enzyme activity plays a small role in the elimination of digoxin, as this agent is primarily excreted unchanged by the kidney.

(Choice C) This patient's lean muscle mass is important to consider when dosing digoxin based on weight, as this serves as the primary site where digoxin is stored in the body. Lean body mass does tend to decrease in an age-related manner, but age-related renal insufficiency is more directly related to toxicity of digoxin in the elderly.

(Choice D) Plasma protein binding of digoxin is not as significant as renal clearance when considering toxicity. Typically less than one-third of the digoxin that gains access to the bloodstream will be protein-bound; the remainder of the dose circulates unbound.

Digoxin is a cardiac glycoside that can be used to treat atrial fibrillation and systolic heart failure. This patient is experiencing symptoms classically associated with **digoxin toxicity**, which include visual changes (particularly **yellow tinting** of objects) and gastrointestinal disturbances. Digoxin is **renally cleared** and has a narrow therapeutic window, so toxicity frequently results from alterations in kidney function. As patients age, renal function decreases progressively. This decrease in renal function is often not accompanied by a concomitant rise in serum creatinine, as creatinine is derived from muscle tissue and lean body mass also decreases with age. Therefore, elderly patients (even those with a normal serum creatinine) should receive reduced doses of renally cleared medications to prevent toxicity.

(Choice A) Intestinal absorption affects the dose of digoxin that reaches the bloodstream. Some preparations of digoxin may have a higher bioavailability than others, and some patients may carry gut bacteria that degrade digoxin before it has the ability to cross into the bloodstream.

(Choice B) Liver enzyme activity plays a small role in the elimination of digoxin, as this agent is primarily excreted unchanged by the kidney.

(Choice C) This patient's lean muscle mass is important to consider when dosing digoxin based on weight, as this serves as the primary site where digoxin is stored in the body. Lean body mass does tend to decrease in an age-related manner, but age-related renal insufficiency is more directly related to toxicity of digoxin in the elderly.

(Choice D) Plasma protein binding of digoxin is not as significant as renal clearance when considering toxicity. Typically less than one-third of the digoxin that gains access to the bloodstream will be protein-bound; the remainder of the dose circulates unbound.

Educational objective:
Digoxin is a cardiac glycoside that is predominantly cleared by the kidneys. Elderly patients typically exhibit age-related renal insufficiency, even in the presence of normal creatinine levels. The dose of digoxin must be reduced in these patients to prevent toxicity.

References

- Digoxin: clinical highlights: a review of digoxin and its use in contemporary medicine.

Pharmacology	Cardiovascular System	Aging
Subject	System	Topic

Copyright © UWorld. All rights reserved.

A 67-year-old man admitted for right lower lobe pneumonia subsequently develops hypotension and lactic acidosis. He is started on a norepinephrine intravenous drip. A few hours later, the antecubital vein being used for the infusion blanches and the tissues surrounding the IV site become cold, hard, and pale. Local injection of the affected tissues with which of the following agents is most likely to be of greatest benefit?

- A. Calcium gluconate
- B. Phentolamine
- C. Heparin
- D. Isoproterenol
- E. Lidocaine

Submit

A 67-year-old man admitted for right lower lobe pneumonia subsequently develops hypotension and lactic acidosis. He is started on a norepinephrine intravenous drip. A few hours later, the antecubital vein being used for the infusion blanches and the tissues surrounding the IV site become cold, hard, and pale. Local injection of the affected tissues with which of the following agents is most likely to be of greatest benefit?

- A. Calcium gluconate (9%)
- ✓ B. Phentolamine (49%)
- C. Heparin (15%)
- D. Isoproterenol (14%)
- E. Lidocaine (9%)

Omitted
Correct answer
B

49%
Answered correctly

01 sec
Time Spent

04/06/2020
Last Updated

Explanation

Development of **venous blanching** along with **induration** and **pallor** of the tissues surrounding the norepinephrine infusion site are signs of **norepinephrine extravasation**. The norepinephrine leak causes intense **α_1 receptor** mediated vasoconstriction which can lead to local **tissue necrosis**. Such necrosis can be prevented by infiltration (using a syringe with a fine hypodermic needle) throughout the affected area with **phentolamine**, an α receptor blocker leading to vasodilatation (thus counteracting the vasoconstrictive effects of norepinephrine). This antidote must be given within 12 hours of extravasation to be effective.

(Choice A) Calcium gluconate is administered for severe hypocalcemia and for severe hyperkalemia (acts as a cardioprotective agent that prevents arrhythmias); it would not lead to the desired effect of vasodilation.

Development of **venous blanching** along with **induration** and **pallor** of the tissues surrounding the norepinephrine infusion site are signs of **norepinephrine extravasation**. The norepinephrine leak causes intense **α_1 receptor** mediated vasoconstriction which can lead to local **tissue necrosis**. Such necrosis can be prevented by infiltration (using a syringe with a fine hypodermic needle) throughout the affected area with **phentolamine**, an α receptor blocker leading to vasodilatation (thus counteracting the vasoconstrictive effects of norepinephrine). This antidote must be given within 12 hours of extravasation to be effective.

(Choice A) Calcium gluconate is administered for severe hypocalcemia and for severe hyperkalemia (acts as a cardioprotective agent that prevents arrhythmias); it would not lead to the desired effect of vasodilation.

(Choice C) Heparin is indicated if there is an arterial thrombosis (cold, pulseless, painful limb), but this patient does not have any risk factors for arterial thrombosis (eg, atrial fibrillation, arterial catheterization) and norepinephrine extravasation is a much more likely cause of his limb symptoms.

(Choice D) Isoproterenol can mediate vasodilation via β_2 receptor activation, particularly in striated muscle, renal, and mesenteric vascular beds, leading to decreased peripheral vascular resistance with increased cardiac output. Subcutaneous tissue blood vessels have a relatively low β_2 receptor density compared to α1 receptors, thus, an alpha blocker would likely be more effective in reversing α_1 receptor mediated vasoconstriction.

(Choice E) Lidocaine can relax vascular smooth muscle via blockade of Na^+ current mediated action potentials. However, in this case, extravasation of norepinephrine is responsible for the vasoconstriction; nerve blockade would not reverse the ischemia.

Educational objective:
Blanching of a vein into which norepinephrine is being infused together with induration and pallor of the tissues surrounding the IV site are signs of norepinephrine extravasation and resulting vasoconstriction. Tissue necrosis is best prevented by local injection of an α receptor blocking drug, such as phentolamine.

Pharmacology	Cardiovascular System	Sympathomimetic agents
Subject	System	Topic

Copyright © UWorld. All rights reserved.

A 24-year-old man comes to the emergency department due to the sudden onset of palpitations. The patient says it feels like "my heart is racing." He had an episode similar to this a year ago that resolved spontaneously. Blood pressure is 126/74 mm Hg and pulse is 164/min. Rapid intravenous administration of a medication to this patient results in instantaneous resolution of the arrhythmia but is accompanied by short-lived flushing, burning in the chest, and shortness of breath. Which of the following medications was used to treat this patient's condition?

- A. Adenosine
- B. Amiodarone
- C. Digoxin
- D. Ibutilide
- E. Lidocaine
- F. Verapamil

Submit

A 24-year-old man comes to the emergency department due to the sudden onset of palpitations. The patient says it feels like "my heart is racing." He had an episode similar to this a year ago that resolved spontaneously. Blood pressure is 126/74 mm Hg and pulse is 164/min. Rapid intravenous administration of a medication to this patient results in instantaneous resolution of the arrhythmia but is accompanied by short-lived flushing, burning in the chest, and shortness of breath. Which of the following medications was used to treat this patient's condition?

- ✓ A. Adenosine (75%)
- B. Amiodarone (6%)
- C. Digoxin (4%)
- D. Ibutilide (1%)
- E. Lidocaine (6%)
- F. Verapamil (5%)

Omitted
Correct answer
A

75%
Answered correctly

02 secs
Time Spent

01/30/2020
Last Updated

Explanation

Pharmacotherapy for supraventricular arrhythmias	
Medication	**Short-term adverse effects**
Flecainide/propafenone	• Monomorphic VT*

Pharmacotherapy for supraventricular arrhythmias	
Medication	**Short-term adverse effects**
Flecainide/propafenone (class IC)	• Monomorphic VT*
Metoprolol (class II)	• Bradycardia & advanced AV block
Amiodarone (class III)	• Bradycardia • Hepatic toxicity, thyroid dysfunction
Ibutilide/dofetilide/sotalol (class III)	• Torsade de pointes
Verapamil/diltiazem (class IV)	• Bradycardia & advanced AV block • Decreased ventricular contractility • Constipation (verapamil)
Adenosine	• Flushing & hypotension • Bronchospasm • High-grade AV block
Digoxin	• Bradycardia & other arrhythmias • Nausea & vomiting ± visual disturbances

*Especially a concern with ischemic or structural heart disease.

AV = atrioventricular; **VT** = ventricular tachycardia.

This patient is exhibiting symptoms consistent with **paroxysmal supraventricular tachycardia (PSVT)**. As the name implies, PSVT comes on suddenly and the focus of automaticity lies above the ventricles (ie, atria or atrioventricular node). When due to development of a **reentrant**

This patient is exhibiting symptoms consistent with **paroxysmal supraventricular tachycardia (PSVT)**. As the name implies, PSVT comes on suddenly and the focus of automaticity lies above the ventricles (ie, atria or atrioventricular node). When due to development of a **reentrant circuit**, the tachyarrhythmia may be terminated by the administration of **adenosine**.

Adenosine is a coronary arteriole vasodilator, but it also affects cardiac conduction. As an anti-arrhythmic, it acts by hyperpolarizing the nodal pacemaker and conducting cells to briefly **block conduction through the atrioventricular node**. Its effects are rapid-onset and short-lived (half-life <10 seconds); by temporarily blocking signal conduction from the atria to the ventricles, administration of the drug will often terminate the reentrant circuit and lead to conversion of PSVT to normal sinus rhythm.

The most frequent **adverse effects** associated with adenosine are flushing, chest burning (due to bronchospasm), hypotension, and high-grade atrioventricular block.

(Choice B) Amiodarone (class III anti-arrhythmic) is one of the broadest-spectrum anti-arrhythmic drugs available, and can be used to treat both supraventricular (eg, PSVT, atrial fibrillation) and ventricular arrhythmias. It has a wide range of adverse effects, including photodermatitis, blue/gray skin discoloration, pulmonary fibrosis, liver toxicity, and hyper- or hypothyroidism.

(Choice C) Digoxin slows conduction through the atrioventricular node and is useful in treating supraventricular tachycardia, especially atrial fibrillation. It causes a well-characterized toxicity in overdose; symptoms include fatigue, yellow-tinted vision, nausea/vomiting, diarrhea, and confusion.

(Choice D) Ibutilide (class III anti-arrhythmic) is used in the treatment of atrial fibrillation and flutter. Its principal adverse effect is QTc prolongation leading to torsades de pointes.

(Choice E) Lidocaine (class IB anti-arrhythmic) is sometimes used for ventricular arrhythmias but has little utility for supraventricular arrhythmias. Lidocaine toxicity most commonly causes neurologic symptoms or arrhythmias.

(Choice F) Verapamil (class IV anti-arrhythmic) is the most cardioselective of the calcium channel blockers, and is often used in the treatment of supraventricular tachycardia. Common adverse reactions noted with verapamil are bradycardia and constipation. Because verapamil decreases cardiac contractility, it can also exacerbate systolic heart failure.

Educational objective:
Adenosine causes hyperpolarization of the nodal pacemaker to briefly block conduction through the atrioventricular node, and it is effective in the initial treatment of paroxysmal supraventricular tachycardia. Common adverse effects include flushing, chest burning (due to bronchospasm).

atrioventricular block.

(Choice B) Amiodarone (class III anti-arrhythmic) is one of the broadest-spectrum anti-arrhythmic drugs available, and can be used to treat both supraventricular (eg, PSVT, atrial fibrillation) and ventricular arrhythmias. It has a wide range of adverse effects, including photodermatitis, blue/gray skin discoloration, pulmonary fibrosis, liver toxicity, and hyper- or hypothyroidism.

(Choice C) Digoxin slows conduction through the atrioventricular node and is useful in treating supraventricular tachycardia, especially atrial fibrillation. It causes a well-characterized toxicity in overdose; symptoms include fatigue, yellow-tinted vision, nausea/vomiting, diarrhea, and confusion.

(Choice D) Ibutilide (class III anti-arrhythmic) is used in the treatment of atrial fibrillation and flutter. Its principal adverse effect is QTc prolongation leading to torsades de pointes.

(Choice E) Lidocaine (class IB anti-arrhythmic) is sometimes used for ventricular arrhythmias but has little utility for supraventricular arrhythmias. Lidocaine toxicity most commonly causes neurologic symptoms or arrhythmias.

(Choice F) Verapamil (class IV anti-arrhythmic) is the most cardioselective of the calcium channel blockers, and is often used in the treatment of supraventricular tachycardia. Common adverse reactions noted with verapamil are bradycardia and constipation. Because verapamil decreases cardiac contractility, it can also exacerbate systolic heart failure.

Educational objective:
Adenosine causes hyperpolarization of the nodal pacemaker to briefly block conduction through the atrioventricular node, and it is effective in the initial treatment of paroxysmal supraventricular tachycardia. Common adverse effects include flushing, chest burning (due to bronchospasm), hypotension, and high-grade atrioventricular block.

References

- Diagnosis and management of common types of supraventricular tachycardia.

Pharmacology	Cardiovascular System	Antiarrhythmic drugs
Subject	System	Topic

Copyright © UWorld. All rights reserved.

1
2
3
4
5
6
7
8
9
10
11
12
13
14
15
16
17
18
19
20
21
22
23
24
25
26
27
28
29
30
31

A 54-year-old man is evaluated for paroxysmal atrial fibrillation. During the episodes, the patient experiences palpitations, chest tightness, light-headedness, and shortness of breath. Medical history is significant for asthma, hypertension, and diet-controlled diabetes mellitus. Prior testing showed normal left ventricular ejection fraction, no evidence of valvular disease, and no obstructive coronary artery disease. It is decided to proceed with dofetilide therapy. Initiation of this therapy increases this patient's risk for which of the following?

A. Bronchospasm
B. Complete atrioventricular block
C. Polymorphic ventricular tachycardia
D. Thyroid dysfunction
E. Venous thromboembolism
F. Visual disturbance

Submit

A 54-year-old man is evaluated for paroxysmal atrial fibrillation. During the episodes, the patient experiences palpitations, chest tightness, light-headedness, and shortness of breath. Medical history is significant for asthma, hypertension, and diet-controlled diabetes mellitus. Prior testing showed normal left ventricular ejection fraction, no evidence of valvular disease, and no obstructive coronary artery disease. It is decided to proceed with dofetilide therapy. Initiation of this therapy increases this patient's risk for which of the following?

- A. Bronchospasm (4%)
- B. Complete atrioventricular block (20%)
- ✓ C. Polymorphic ventricular tachycardia (63%)
- D. Thyroid dysfunction (7%)
- E. Venous thromboembolism (1%)
- F. Visual disturbance (3%)

Omitted
Correct answer
C

63%
Answered correctly

02 secs
Time Spent

03/03/2020
Last Updated

Explanation

Pharmacotherapy for supraventricular arrhythmias	
Medication	**Short-term adverse effects**
Flecainide/propafenone	• Monomorphic VT*

Pharmacotherapy for supraventricular arrhythmias	
Medication	**Short-term adverse effects**
Flecainide/propafenone (class IC)	• Monomorphic VT*
Metoprolol (class II)	• Bradycardia & advanced AV block
Amiodarone (class III)	• Bradycardia • Hepatic toxicity, thyroid dysfunction
Ibutilide/dofetilide/sotalol (class III)	• Torsade de pointes
Verapamil/diltiazem (class IV)	• Bradycardia & advanced AV block • Decreased ventricular contractility • Constipation (verapamil)
Adenosine	• Flushing & hypotension • Bronchospasm • High-grade AV block
Digoxin	• Bradycardia & other arrhythmias • Nausea & vomiting ± visual disturbances

*Especially a concern with ischemic or structural heart disease.

AV = atrioventricular; **VT** = ventricular tachycardia.

Relatively young patients with **symptomatic paroxysmal atrial fibrillation** are often treated with a **rhythm-control** strategy to restore and maintain normal sinus rhythm and to eliminate symptoms. Antiarrhythmic drugs commonly used for rhythm control of atrial fibrillation include class

AV = atrioventricular; **VT** = ventricular tachycardia.

Relatively young patients with **symptomatic paroxysmal atrial fibrillation** are often treated with a **rhythm-control** strategy to restore and maintain normal sinus rhythm and to eliminate symptoms. Antiarrhythmic drugs commonly used for rhythm control of atrial fibrillation include class IC (eg, flecainide, propafenone) and class III (eg, ibutilide, dofetilide) agents.

Dofetilide and ibutilide selectively block the rapid component of the delayed-rectifier potassium current. This **slows repolarization** and prolongs action potential duration and the **effective refractory period** in cardiomyocytes, suppressing the electrical foci that lead to atrial fibrillation. As a result, the **QT interval is prolonged**, leading to an increased risk of **torsade de pointes**, a form of **polymorphic ventricular tachycardia** that can cause syncope and sudden cardiac death. To minimize this risk, dofetilide or ibutilide therapy is started only in the hospital with temporary cardiac monitoring.

(Choice A) Adenosine can trigger bronchospasm, likely by stimulating the release of histamine and leukotrienes from mast cells. Class III antiarrhythmics are not associated with bronchospasm.

(Choice B) Beta blockers (via inhibition of beta-1 receptor–driven chronotropy) and nondihydropyridine calcium channel blockers (via blockade of L-type atrioventricular [AV] node calcium channels) slow AV node conduction and in overdose can cause complete AV block. Digoxin (via enhanced vagal tone) and adenosine can also cause AV block. Although some class III antiarrhythmics (ie, sotalol, amiodarone) have negative chronotropic effects and may slow AV node conduction, dofetilide and ibutilide have no significant effect on AV node conduction.

(Choice D) Amiodarone can disrupt thyroid function and lead to hyper- or hypothyroidism, but dofetilide and other class III antiarrhythmics do not affect thyroid function. Compared with other class III antiarrhythmics, amiodarone is associated with a lower risk of torsade de pointes.

(Choice E) Most antiarrhythmic drugs, including class III, are not associated with an increased risk of venous thromboembolism.

(Choice F) Digoxin toxicity can cause visual disturbances consisting of blurred or yellow vision, but visual disturbance is not an adverse effect of class III antiarrhythmics.

Educational objective:
Dofetilide and ibutilide are class III antiarrhythmics that treat atrial fibrillation by blocking the rapid component of the delayed-rectifier potassium current to slow repolarization and increase the effective refractory period. As a result, the QT interval is prolonged, creating an increased risk of polymorphic ventricular tachycardia (torsade de pointes).

AV = atrioventricular; VT = ventricular tachycardia.

Exhibit Display

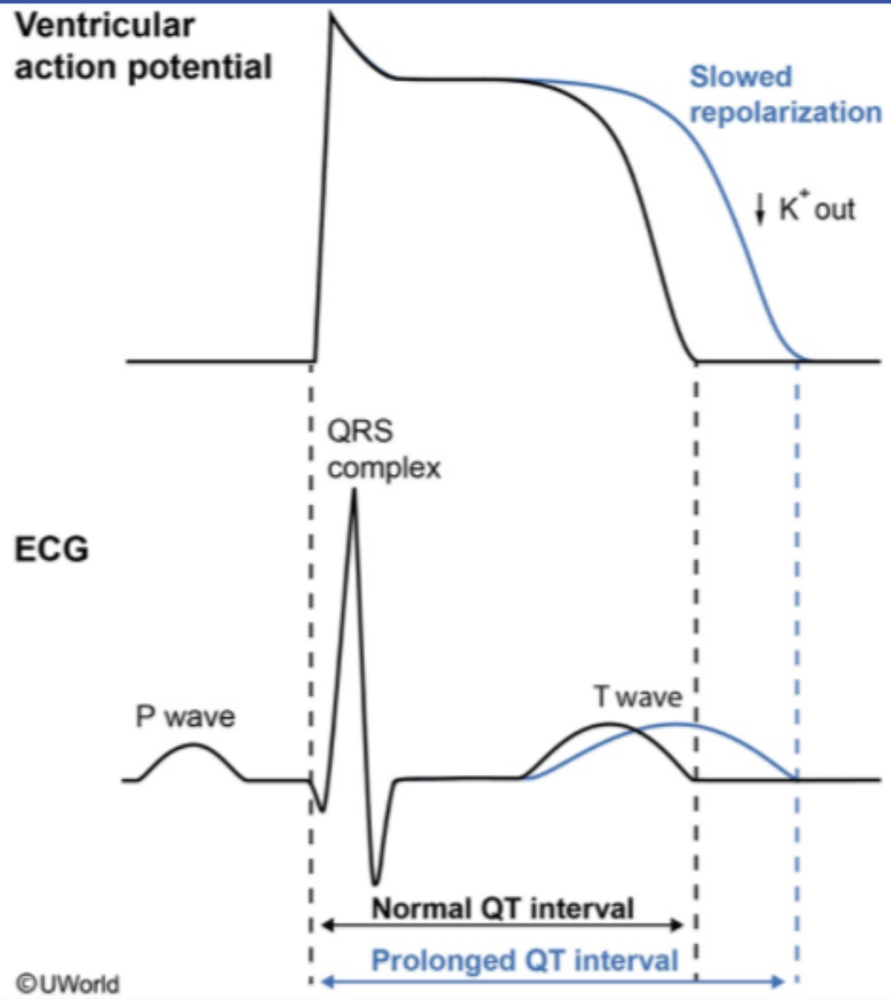

Zoom In Zoom Out Reset Add To Flash Card

polymorphic ventricular tachycardia (torsade de pointes).

can cause syncope and sudden cardiac death. To minimize this risk, dofetilide or ibutilide therapy is started only in the hospital with temporary cardiac monitoring.

(Choice A) Adenosine can trigger bronchospasm, likely by stimulating the release of histamine and leukotrienes from mast cells. Class III antiarrhythmics are not associated with bronchospasm.

(Choice B) Beta blockers (via inhibition of beta-1 receptor–driven chronotropy) and nondihydropyridine calcium channel blockers (via blockade of L-type atrioventricular [AV] node calcium channels) slow AV node conduction and in overdose can cause complete AV block. Digoxin (via enhanced vagal tone) and adenosine can also cause AV block. Although some class III antiarrhythmics (ie, sotalol, amiodarone) have negative chronotropic effects and may slow AV node conduction, dofetilide and ibutilide have no significant effect on AV node conduction.

(Choice D) Amiodarone can disrupt thyroid function and lead to hyper- or hypothyroidism, but dofetilide and other class III antiarrhythmics do not affect thyroid function. Compared with other class III antiarrhythmics, amiodarone is associated with a lower risk of torsade de pointes.

(Choice E) Most antiarrhythmic drugs, including class III, are not associated with an increased risk of venous thromboembolism.

(Choice F) Digoxin toxicity can cause visual disturbances consisting of blurred or yellow vision, but visual disturbance is not an adverse effect of class III antiarrhythmics.

Educational objective:
Dofetilide and ibutilide are class III antiarrhythmics that treat atrial fibrillation by blocking the rapid component of the delayed-rectifier potassium current to slow repolarization and increase the effective refractory period. As a result, the QT interval is prolonged, creating an increased risk of polymorphic ventricular tachycardia (torsade de pointes).

References

- 2014 AHA/ACC/HRS guideline for the management of patients with atrial fibrillation: a report of the American College of Cardiology/American Heart Association Task Force on Practice Guidelines and the Heart Rhythm Society.
- Safety of oral dofetilide for rhythm control of atrial fibrillation and atrial flutter.

Pharmacology	Cardiovascular System	Torsades de pointes
Subject	System	Topic

A 65-year-old man comes to the emergency department due to substernal chest discomfort and intermittent palpitations that began this morning. The patient has a history of coronary artery disease and stable angina that is managed medically. He takes high-dose metoprolol, atorvastatin, and low-dose aspirin. The patient reports that he has been traveling for the past week and ran out of his medications 2 days ago. Temperature is 37 C (98.6 F), blood pressure is 148/82 mm Hg, and pulse is 112/min. ECG reveals sinus tachycardia with a 1-mm ST segment depression in the lateral leads. Which of the following is most likely responsible for this patient's presentation?

A. Increased levels of circulating catecholamines

B. Predominant activation of alpha-adrenergic receptors

C. Reduced activity of cyclic AMP–mediated messaging

D. Reduced cellular sensitivity to circulating catecholamines

E. Upregulation of beta-adrenergic receptors

Submit

A 65-year-old man comes to the emergency department due to substernal chest discomfort and intermittent palpitations that began this morning. The patient has a history of coronary artery disease and stable angina that is managed medically. He takes high-dose metoprolol, atorvastatin, and low-dose aspirin. The patient reports that he has been traveling for the past week and ran out of his medications 2 days ago. Temperature is 37 C (98.6 F), blood pressure is 148/82 mm Hg, and pulse is 112/min. ECG reveals sinus tachycardia with a 1-mm ST segment depression in the lateral leads. Which of the following is most likely responsible for this patient's presentation?

- A. Increased levels of circulating catecholamines (14%)
- B. Predominant activation of alpha-adrenergic receptors (4%)
- C. Reduced activity of cyclic AMP–mediated messaging (6%)
- D. Reduced cellular sensitivity to circulating catecholamines (1%)
- ✓ E. Upregulation of beta-adrenergic receptors (72%)

Omitted
Correct answer
E

72%
Answered correctly

02 secs
Time Spent

03/17/2020
Last Updated

Explanation

This patient with elevated blood pressure, tachycardia, palpitations, and anginal pain following recent discontinuation of metoprolol is most likely experiencing **beta blocker withdrawal syndrome**. With changes in environmental stimulus, the feedback mechanisms in cells adjust the density of cell surface membrane receptors to regulate sensitivity to the stimulus. Prolonged beta-adrenergic blockade, for example, stimulates an increase in surface membrane expression of beta-adrenergic receptors, a process called **upregulation**. When beta-adrenergic blockade is abruptly withdrawn, the increased density of beta-adrenergic receptors creates an amplified response to circulating catecholamines (ie, **increased**

This patient with elevated blood pressure, tachycardia, palpitations, and anginal pain following recent discontinuation of metoprolol is most likely experiencing **beta blocker withdrawal syndrome**. With changes in environmental stimulus, the feedback mechanisms in cells adjust the density of cell surface membrane receptors to regulate sensitivity to the stimulus. Prolonged beta-adrenergic blockade, for example, stimulates an increase in surface membrane expression of beta-adrenergic receptors, a process called **upregulation**. When beta-adrenergic blockade is abruptly withdrawn, the increased density of beta-adrenergic receptors creates an amplified response to circulating catecholamines (ie, **increased sensitivity**).

Because metoprolol is cardioselective and primarily blocks beta-1 receptors, abrupt cessation stimulates beta-1 receptor–mediated **increased heart rate** and **cardiac contractility**. There is also **increased blood pressure** due to increased cardiac output. These changes create **increased oxygen demand** that may cause ischemia (evidenced by ST depression on ECG) and trigger **angina** in patients with underlying coronary artery disease.

(Choice A) Beta blocker withdrawal symptoms result from an increase in the density of beta-adrenergic receptors, leading to an amplified response to circulating catecholamines. The level of circulating catecholamines is unchanged from baseline.

(Choice B) Alpha-adrenergic receptors are predominantly activated in the setting of beta blockade. On cessation of beta blocker therapy, there is redistribution of catecholamines to beta-adrenergic receptors.

(Choice C) Beta-adrenergic receptors function via cyclic AMP second messaging. The increased stimulation of beta-adrenergic receptors following beta blocker cessation leads to increased cyclic AMP activity.

(Choice D) Downregulation of surface membrane receptors occurs when cells are exposed to frequent agonist activity. For example, prolonged use of an alpha-1 agonist nasal spray (eg, phenylephrine) causes downregulation of alpha-1 receptors and reduced sensitivity to endogenous catecholamines. This is opposite to what is occurring in this patient.

Educational objective:
When exposed to a prolonged environmental stimulus, cells can adjust their sensitivity to the stimulus by upregulating or downregulating surface membrane receptors. Prolonged beta blockade leads to upregulation of beta-adrenergic receptors and increased sensitivity to circulating catecholamines, causing an enhanced beta-adrenergic response on abrupt beta blocker cessation (ie, beta blocker withdrawal syndrome).

References

- Abrupt withdrawal of beta-blocking agents in patients with arterial hypertension. Effect on blood pressure, heart rate and plasma

increased oxygen demand that may cause ischemia (evidenced by ST depression on ECG) and trigger **angina** in patients with underlying coronary artery disease.

(Choice A) Beta blocker withdrawal symptoms result from an increase in the density of beta-adrenergic receptors, leading to an amplified response to circulating catecholamines. The level of circulating catecholamines is unchanged from baseline.

(Choice B) Alpha-adrenergic receptors are predominantly activated in the setting of beta blockade. On cessation of beta blocker therapy, there is redistribution of catecholamines to beta-adrenergic receptors.

(Choice C) Beta-adrenergic receptors function via cyclic AMP second messaging. The increased stimulation of beta-adrenergic receptors following beta blocker cessation leads to increased cyclic AMP activity.

(Choice D) Downregulation of surface membrane receptors occurs when cells are exposed to frequent agonist activity. For example, prolonged use of an alpha-1 agonist nasal spray (eg, phenylephrine) causes downregulation of alpha-1 receptors and reduced sensitivity to endogenous catecholamines. This is opposite to what is occurring in this patient.

Educational objective:
When exposed to a prolonged environmental stimulus, cells can adjust their sensitivity to the stimulus by upregulating or downregulating surface membrane receptors. Prolonged beta blockade leads to upregulation of beta-adrenergic receptors and increased sensitivity to circulating catecholamines, causing an enhanced beta-adrenergic response on abrupt beta blocker cessation (ie, beta blocker withdrawal syndrome).

References

- Abrupt withdrawal of beta-blocking agents in patients with arterial hypertension. Effect on blood pressure, heart rate and plasma catecholamines and prolactin.
- Withdrawal of beta blocking drugs.
- Pharmacology of beta-blockers: classical aspects and recent developments.

Pharmacology	Cardiovascular System	Beta blockers
Subject	System	Topic

Copyright © UWorld. All rights reserved.

Increased oxygen demand that may cause ischemia (evidenced by ST depression on ECG) and trigger **angina** in patients with underlying coronary artery disease.

(Choice A) Beta blocker
response to circulating ca

(Choice B) Alpha-adrene
redistribution of catechola

(Choice C) Beta-adrener
following beta blocker ces

(Choice D) Downregulati
use of an alpha-1 agonist
catecholamines. This is o

Educational objective:
When exposed to a prolon
membrane receptors. Pro
catecholamines, causing a

References

- Abrupt withdrawal of b
  catecholamines and p
- Withdrawal of beta blo
- Pharmacology of beta

Pharmacology
Subject

Car
Syst

Exhibit Display

Receptor stimulated	Change in second messenger	Primary effects
Alpha-1	↑ IP_3	• Peripheral vasoconstriction • Urethral constriction • Pupillary dilation
Alpha-2	↓ cAMP	• CNS sympatholytic • ↓ insulin release & intestinal motility
Beta-1	↑ cAMP	• ↑ Cardiac contractility & heart rate • ↑ Renin release by JG cells of kidney
Beta-2	↑ cAMP	• Peripheral vasodilation • Bronchodilation
Muscarinic-2	↓ cAMP	• ↓ Cardiac contractility & heart rate
Muscarinic-3	↑ IP_3	• Bronchoconstriction • ↑ insulin release & intestinal motility • Bladder contraction • Pupillary constriction • Peripheral vasodilation*

*Via release of nitric oxide.
cAMP = cyclic AMP; **IP_3** = inositol 1,4,5-triphosphate; **JG** = juxtaglomerular.

Add To Flash Card

Copyright © UWorld. All rights reserved.

1
2
3
4
5
6
7
8
9
10
11
12
13
14
15
16
17
18
19
20
21
22
23
24
25
26
27
28
29
30
31

A 60-year-old Caucasian male is diagnosed with exertional angina. His treatment regimen includes metoprolol, isosorbide dinitrate and aspirin. He takes isosorbide dinitrate early in the morning and again in the afternoon, but he does not take an evening dose. Such a pattern of drug administration is intended to decrease which of the following?

A. Pharmacokinetic drug interaction
B. Pharmacodynamic drug antagonism
C. Effect potentiation
D. Tolerance development
E. Withdrawal symptoms
F. Drug noncompliance

Submit

A 60-year-old Caucasian male is diagnosed with exertional angina. His treatment regimen includes metoprolol, isosorbide dinitrate and aspirin. He takes isosorbide dinitrate early in the morning and again in the afternoon, but he does not take an evening dose. Such a pattern of drug administration is intended to decrease which of the following?

- A. Pharmacokinetic drug interaction (4%)
- B. Pharmacodynamic drug antagonism (3%)
- C. Effect potentiation (18%)
- ✓ D. Tolerance development (65%)
- E. Withdrawal symptoms (3%)
- F. Drug noncompliance (4%)

Omitted
Correct answer
D

65%
Answered correctly

02 secs
Time Spent

06/17/2020
Last Updated

Explanation

Around-the-clock nitrate administration (in any form) rapidly results in development of tolerance to nitrates. This is why a nitrate-free interval must be provided every day in patients that are using daily long acting nitrates. The mechanism by which this occurs has not been fully demonstrated, but it is theorized that it is due to a decreased vascular sensitivity to nitrates and an increased sensitivity to endogenous vasoconstricting agents. Usually the nitrate-free period is timed to occur during the night when the patient is sleeping and cardiac work is the least.

(Choice A) A pharmacokinetic drug interaction refers to how drugs that are used together in a patient affect the absorption and elimination of each other. An example of this is the ability of rifampin to increase the metabolism and elimination of warfarin by inducing cytochrome P-450. This is

Around-the-clock nitrate administration (in any form) rapidly results in development of tolerance to nitrates. This is why a nitrate-free interval must be provided every day in patients that are using daily long acting nitrates. The mechanism by which this occurs has not been fully demonstrated, but it is theorized that it is due to a decreased vascular sensitivity to nitrates and an increased sensitivity to endogenous vasoconstricting agents. Usually the nitrate-free period is timed to occur during the night when the patient is sleeping and cardiac work is the least.

(Choice A) A pharmacokinetic drug interaction refers to how drugs that are used together in a patient affect the absorption and elimination of each other. An example of this is the ability of rifampin to increase the metabolism and elimination of warfarin by inducing cytochrome P-450. This is not the reason for providing a nitrate-free interval.

(Choice B) Pharmacodynamic drug antagonism refers to the ability of a drug, as part of its mechanism of action, to antagonize, or prevent, the effect of another drug or endogenous substance. An example of this is the effect that labetalol has on alpha-1 and beta adrenergic receptors – it prevents the binding of catecholamines to these receptors.

(Choice C) Effect potentiation refers to one drug's ability to increase the pharmacologic effect of another agent. The drugs mentioned in this question stem do not potentiate the effects of each other, and this is not the reason for providing a nitrate-free period. Beta-adrenergic blockers are often prescribed along with nitrates to prevent reflex tachycardia as well as to provide decreased cardiac work by a mechanism different from that of nitrates.

(Choice E) Withdrawal symptoms occur when a patient forms a physiologic dependence on a drug or medication and that drug or medication is then discontinued. This is common in patients using alcohol, opiates, benzodiazepines, stimulants and some antidepressants. This is not the reason for providing a nitrate-free period in patients taking nitrates.

(Choice F) Drug noncompliance is a problem where patients do not take the medications prescribed to them properly or at all. It is frequent among patients who do not understand their disease, can not afford medications, or simply can not remember to take them. The latter becomes much more frequent when patients are taking multiple medications with many times-per-day dosing schedules. This is also not the reason for providing a nitrate-free period every day in patients taking long-term nitrates.

Educational Objective:
Patients taking daily maintenance nitrates need to have a nitrate-free period every day to avoid tolerance to the drug.

A 78-year-old man with severe dementia is brought to the emergency department due to a daylong history of lethargy, fever, and vomiting. The patient lives in a nursing home, and his caregivers report that he has had poor oral intake over the last week. Medical history is significant for emphysema, heart failure with reduced ejection fraction, hypertension, and diabetes mellitus type 2. On physical examination, the patient is lethargic but arousable. Blood pressure is 60/30 mm Hg and pulse is 120/min and regular. The extremities are warm. Coarse rhonchi are heard over the right lower lung. After receiving several intravenous fluid boluses, the patient is given an intravenous infusion of an agent that increases peripheral vascular resistance, increases blood pressure, and decreases heart rate. Which of the following agents is most likely being described?

A. Dobutamine

B. High-dose dopamine

C. Low-dose epinephrine

D. Milrinone

E. Phenylephrine

Submit

A 78-year-old man with severe dementia is brought to the emergency department due to a daylong history of lethargy, fever, and vomiting. The patient lives in a nursing home, and his caregivers report that he has had poor oral intake over the last week. Medical history is significant for emphysema, heart failure with reduced ejection fraction, hypertension, and diabetes mellitus type 2. On physical examination, the patient is lethargic but arousable. Blood pressure is 60/30 mm Hg and pulse is 120/min and regular. The extremities are warm. Coarse rhonchi are heard over the right lower lung. After receiving several intravenous fluid boluses, the patient is given an intravenous infusion of an agent that increases peripheral vascular resistance, increases blood pressure, and decreases heart rate. Which of the following agents is most likely being described?

- A. Dobutamine (10%)
- B. High-dose dopamine (14%)
- C. Low-dose epinephrine (10%)
- D. Milrinone (3%)
- ✓ E. Phenylephrine (60%)

Omitted
Correct answer
E

60%
Answered correctly

02 secs
Time Spent

05/26/2020
Last Updated

Explanation

Cardiovascular effects of adrenergic agonists

- α_1: peripheral vasoconstriction, ↑ SVR
- β_1: ↑ heart rate & contractility, ↑ cardiac output

1 2 3 4 5 6 7 8 9 10 11 12 13 14 15 16 17 18 19 20 21 22 23 24 25 26 27 28 29 30 31

Cardiovascular effects of adrenergic agonists

- α_1: peripheral vasoconstriction, ↑ SVR
- β_1: ↑ heart rate & contractility, ↑ cardiac output
- β_2: peripheral vasodilation, ↓ SVR
- D_1: renal arteriolar vasodilation

Agonist	Receptor binding	Blood pressure	Heart rate
Dobutamine	$\beta_1 > \beta_2$	–/↓	↑
Dopamine	$D_1 > \beta_1 > \alpha_1$ (low-dose)	–/↓	↑
	$\alpha_1 > \beta_1 > D_1$ (high-dose)	↑	–/↓*
Epinephrine	$\beta_1 > \beta_2 > \alpha_1$ (low-dose)	–/↓	↑
	$\alpha_1 > \beta_1 > \beta_2$ (high-dose)	↑	–/↓*
Isoproterenol	$\beta_1 = \beta_2$	–/↓	↑
Norepinephrine	$\alpha_1 > \beta_1 > \beta_2$	↑	–/↓*
Phenylephrine	α_1	↑	↓*

*Reflex-mediated decrease.

SVR = systemic vascular resistance.

*Reflex-mediated decrease.

SVR = systemic vascular resistance.

Adrenergic agonists are often used to increase blood pressure in patients with shock. **Phenylephrine** is a **selective alpha-1 agonist** with no effect on alpha-2 receptors or beta receptors; it causes peripheral vasoconstriction, resulting in **increased systemic vascular resistance** (SVR) and **increased blood pressure**, but it has **no direct effect on the heart**. Drugs that increase blood pressure by increasing SVR are called **pressors** and are most useful in treating septic shock.

Phenylephrine has indirect effects on the heart mediated via the **baroreceptor reflex**. Increased blood pressure stimulates firing of aortic and carotid baroreceptors. In response, the CNS increases parasympathetic output and decreases sympathetic output, which causes **decreased heart rate** and myocardial contractility. These reflexive changes slightly attenuate the initial increase in blood pressure and lead to overall reduced cardiac output.

(Choices A and D) Dobutamine is primarily a beta-1 agonist with partial activity on beta-2 receptors and minimal effect on alpha receptors. It increases heart rate and myocardial contractility (via beta-1 stimulation) and causes mild vasodilation (via beta-2 stimulation) to decrease SVR. Milrinone is not an adrenergic agonist, but it inhibits phosphodiesterase 3 to increase myocardial contractility and cause peripheral vasodilation (decreases SVR). The combination of increased myocardial contractility (ie, inotropic effect) and reduced SVR induced by these drugs is most useful in treating cardiogenic shock.

(Choice B) Dopamine stimulates dopamine-1 (located primarily in the renal arterioles), beta-1, and alpha-1 receptors, with the relative effects being dose dependent. High-dose dopamine primarily stimulates alpha-1 receptors to increase SVR and blood pressure; ongoing beta-1 receptor stimulation offsets the reflex–mediated decrease in heart rate that occurs with phenylephrine, leaving the heart rate relatively unchanged.

(Choice C) Epinephrine stimulates beta-1, beta-2, and alpha-1 receptors with dose-dependent effects. Low-dose epinephrine primarily stimulates beta-1 receptors, resulting in increased cardiac output due to increased heart rate and contractility. At low doses, the vasodilative beta-2–mediated effects are greater than the vasoconstrictive alpha-1–mediated effects, leading to a slight reduction in SVR.

Educational objective:
Phenylephrine is a selective alpha-1 agonist with no effect on alpha-2 or beta receptors. It causes peripheral vasoconstriction that increases systemic vascular resistance and blood pressure. It has no direct effect on the heart but stimulates a reflex–mediated decrease in heart rate and myocardial contractility.

pressors and are most useful in treating septic shock.

Phenylephrine has indirect effects on the heart mediated via the **baroreceptor reflex**. Increased blood pressure stimulates firing of aortic and carotid baroreceptors. In response, the CNS increases parasympathetic output and decreases sympathetic output, which causes **decreased heart rate** and myocardial contractility. These reflexive changes slightly attenuate the initial increase in blood pressure and lead to overall reduced cardiac output.

(Choices A and D) Dobutamine is primarily a beta-1 agonist with partial activity on beta-2 receptors and minimal effect on alpha receptors. It increases heart rate and myocardial contractility (via beta-1 stimulation) and causes mild vasodilation (via beta-2 stimulation) to decrease SVR. Milrinone is not an adrenergic agonist, but it inhibits phosphodiesterase 3 to increase myocardial contractility and cause peripheral vasodilation (decreases SVR). The combination of increased myocardial contractility (ie, inotropic effect) and reduced SVR induced by these drugs is most useful in treating cardiogenic shock.

(Choice B) Dopamine stimulates dopamine-1 (located primarily in the renal arterioles), beta-1, and alpha-1 receptors, with the relative effects being dose dependent. High-dose dopamine primarily stimulates alpha-1 receptors to increase SVR and blood pressure; ongoing beta-1 receptor stimulation offsets the reflex–mediated decrease in heart rate that occurs with phenylephrine, leaving the heart rate relatively unchanged.

(Choice C) Epinephrine stimulates beta-1, beta-2, and alpha-1 receptors with dose-dependent effects. Low-dose epinephrine primarily stimulates beta-1 receptors, resulting in increased cardiac output due to increased heart rate and contractility. At low doses, the vasodilative beta-2–mediated effects are greater than the vasoconstrictive alpha-1–mediated effects, leading to a slight reduction in SVR.

Educational objective:
Phenylephrine is a selective alpha-1 agonist with no effect on alpha-2 or beta receptors. It causes peripheral vasoconstriction that increases systemic vascular resistance and blood pressure. It has no direct effect on the heart but stimulates a reflex–mediated decrease in heart rate and myocardial contractility.

Pharmacology	Cardiovascular System	Sepsis
Subject	System	Topic

Copyright © UWorld. All rights reserved.

Isoproterenol	$\beta_1 = \beta_2$	–/↓	↑

Exhibit Display

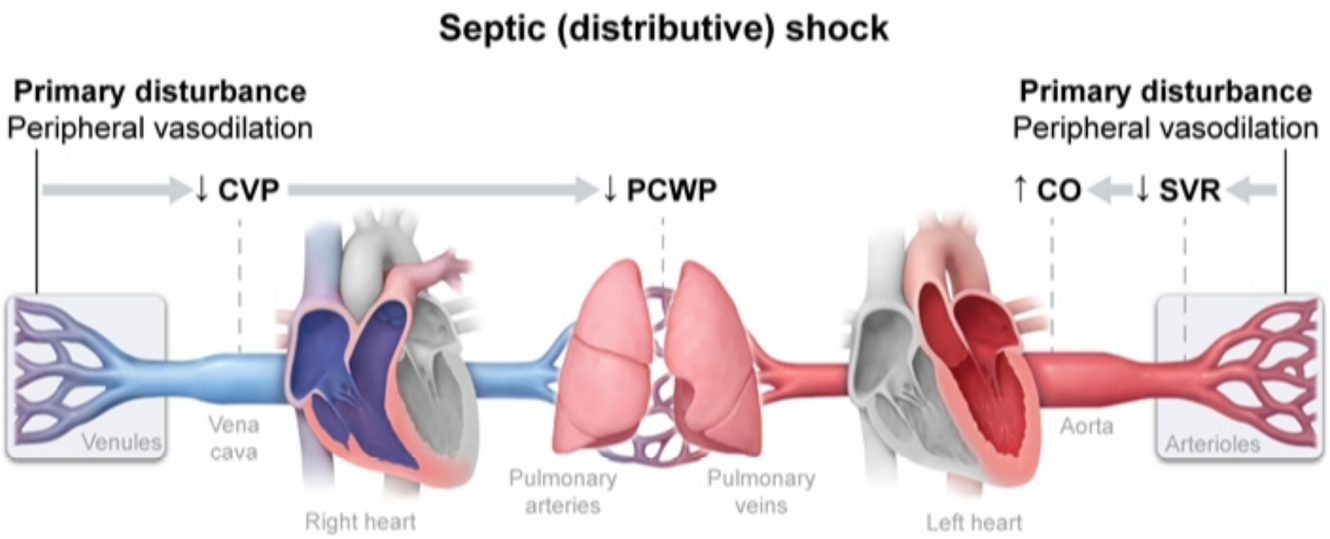

CO = cardiac output; CVP = central venous pressure;
PCWP = pulmonary capillary wedge pressure; SVR = systemic vascular resistance.
©UWorld

Zoom In | Zoom Out | Reset | Add To New Card | Existing Card

Adrenergic agonists are o
effect on alpha-2 receptor
and **increased blood pre**
pressors and are most us

Phenylephrine has indirec
carotid baroreceptors. In
heart rate and myocardia
reduced cardiac output.

(Choices A and D) Dobu
increases heart rate and r
Milrinone is not an adrene
(decreases SVR). The co
useful in treating cardioge

(Choice B) Dopamine sti
being dose dependent. H
stimulation offsets the refl

(Choice C) Epinephrine s
beta-1 receptors, resulting in increased cardiac output due to increased heart rate and contractility. At low doses, the vasodilative beta-2–mediated effects are greater than the vasoconstrictive alpha-1 mediated effects, leading to a slight reduction in SVR.

1
2
3
4
5
6
7
8
9
10
11
12
13
14
15
16
17
18
19
20
21
22
23
24
25
26
27
28
29
30
31

Exhibit Display

Baroreceptor reflex in response to increased blood pressure

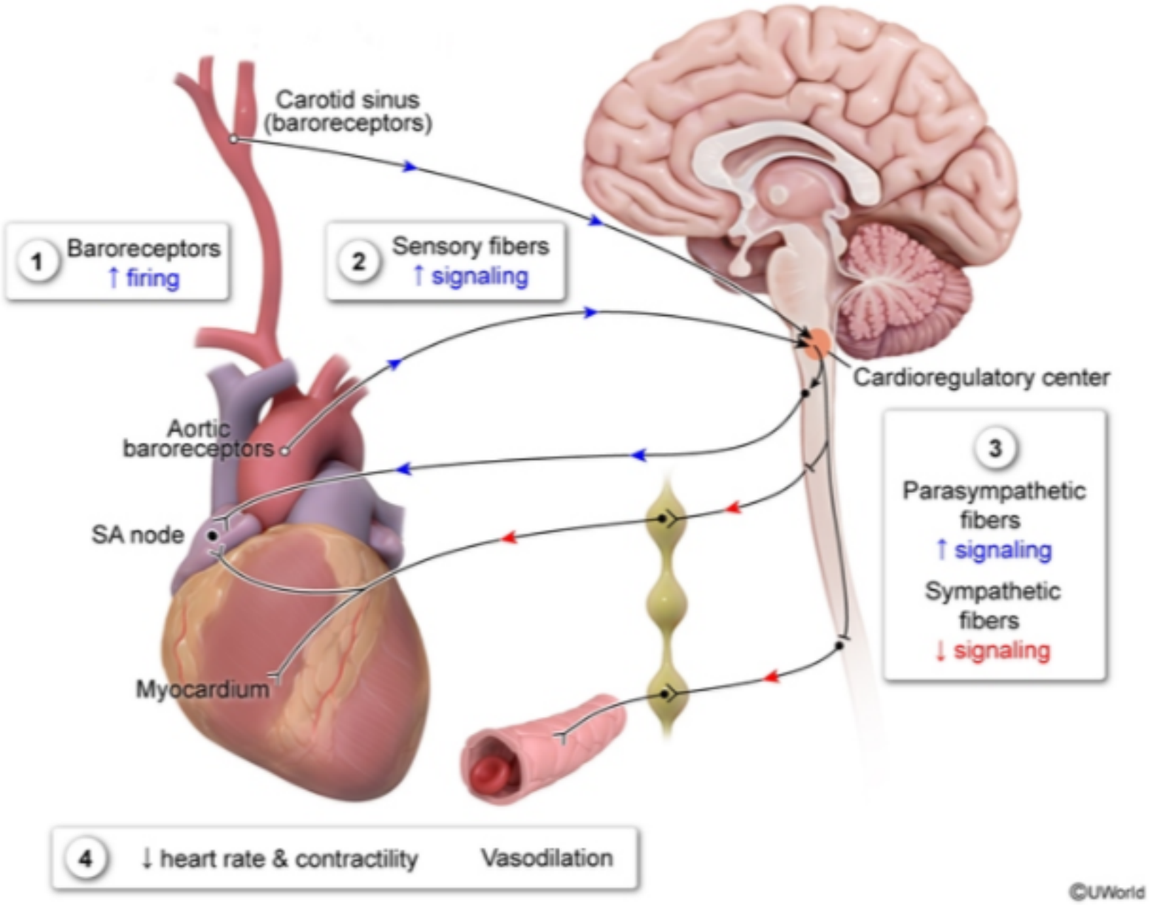

Zoom In | Zoom Out | Reset | Add To New Card | Existing Card

mediated effects are greater than the vasoconstrictive alpha-1 mediated effects, leading to a slight reduction in SVR.

Norepinephrine	$\alpha_1 > \beta_1 > \beta_2$	↑	–|*

Exhibit Display

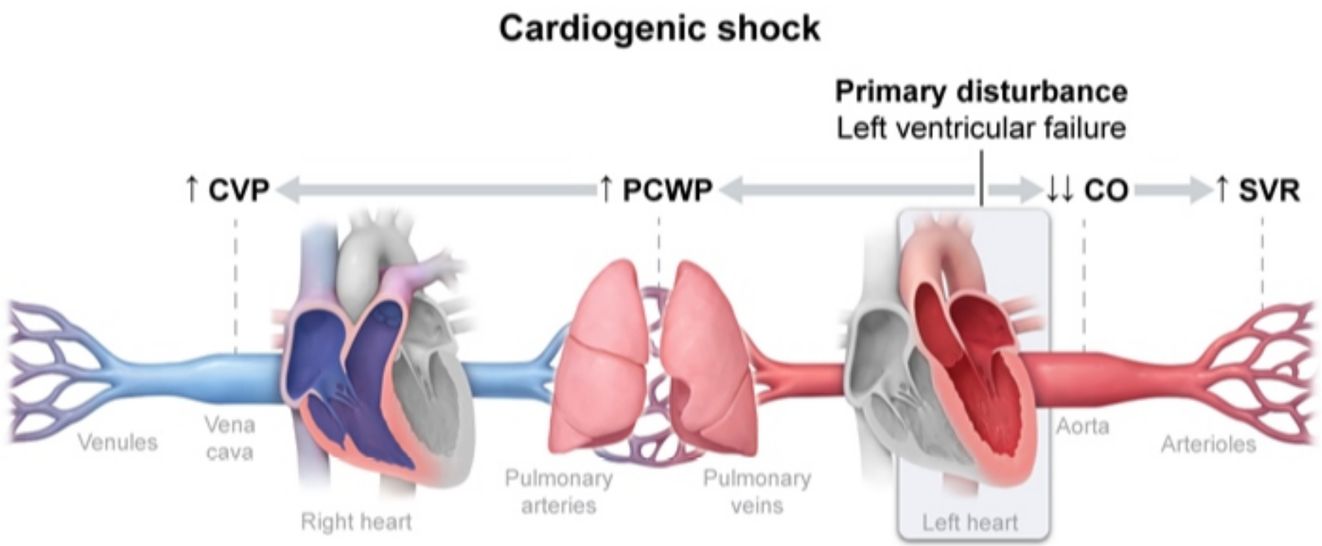

CO = cardiac output; **CVP** = central venous pressure;
PCWP = pulmonary capillary wedge pressure; **SVR** = systemic vascular resistance.

©UWorld

Zoom In | Zoom Out | Reset | Add To New Card | Existing Card

Educational objective:

pressors and are most useful in treating septic shock.

Phenylephrine has indirect effects on the heart mediated via the **baroreceptor reflex**. Increased blood pressure stimulates firing of aortic and carotid baroreceptors. In response, the CNS increases parasympathetic output and decreases sympathetic output, which causes **decreased heart rate** and myocardial contractility. These reflexive changes slightly attenuate the initial increase in blood pressure and lead to overall reduced cardiac output.

(Choices A and D) Dobutamine is primarily a beta-1 agonist with partial activity on beta-2 receptors and minimal effect on alpha receptors. It increases heart rate and myocardial contractility (via beta-1 stimulation) and causes mild vasodilation (via beta-2 stimulation) to decrease SVR. Milrinone is not an adrenergic agonist, but it inhibits phosphodiesterase 3 to increase myocardial contractility and cause peripheral vasodilation (decreases SVR). The combination of increased myocardial contractility (ie, inotropic effect) and reduced SVR induced by these drugs is most useful in treating cardiogenic shock.

(Choice B) Dopamine stimulates dopamine-1 (located primarily in the renal arterioles), beta-1, and alpha-1 receptors, with the relative effects being dose dependent. High-dose dopamine primarily stimulates alpha-1 receptors to increase SVR and blood pressure; ongoing beta-1 receptor stimulation offsets the reflex–mediated decrease in heart rate that occurs with phenylephrine, leaving the heart rate relatively unchanged.

(Choice C) Epinephrine stimulates beta-1, beta-2, and alpha-1 receptors with dose-dependent effects. Low-dose epinephrine primarily stimulates beta-1 receptors, resulting in increased cardiac output due to increased heart rate and contractility. At low doses, the vasodilative beta-2–mediated effects are greater than the vasoconstrictive alpha-1–mediated effects, leading to a slight reduction in SVR.

Educational objective:
Phenylephrine is a selective alpha-1 agonist with no effect on alpha-2 or beta receptors. It causes peripheral vasoconstriction that increases systemic vascular resistance and blood pressure. It has no direct effect on the heart but stimulates a reflex–mediated decrease in heart rate and myocardial contractility.

Pharmacology	Cardiovascular System	Sepsis
Subject	System	Topic

Copyright © UWorld. All rights reserved.

A 49-year-old woman is brought to the emergency department with squeezing chest pain and profuse sweating for the last 2 hours. Medical history includes diet-controlled type 2 diabetes mellitus. ECG reveals ST-segment elevation in leads I, aVL, and V1-V4. The patient is immediately taken to the cardiac catheterization laboratory, where she is found to have complete occlusion of the left anterior descending coronary artery. The blockage is opened with percutaneous coronary intervention with stenting, but afterward she experiences recurrent and sustained episodes of ventricular arrhythmia. She is treated with an antiarrhythmic agent that preferentially binds to rapidly depolarizing and ischemic ventricular myocardial fibers and has minimal effect on normal ventricular myocardium. Which of the following agents was most likely used in this patient?

- A. Adenosine
- B. Digoxin
- C. Diltiazem
- D. Ibutilide
- E. Lidocaine
- F. Metoprolol
- G. Procainamide

Submit

1
2
3
4
5
6
7
8
9
10
11
12
13
14
15
16
17
18
19
20
21
22
23
24
25
26
27
28
29
30
31

A 49-year-old woman is brought to the emergency department with squeezing chest pain and profuse sweating for the last 2 hours. Medical history includes diet-controlled type 2 diabetes mellitus. ECG reveals ST-segment elevation in leads I, aVL, and V1-V4. The patient is immediately taken to the cardiac catheterization laboratory, where she is found to have complete occlusion of the left anterior descending coronary artery. The blockage is opened with percutaneous coronary intervention with stenting, but afterward she experiences recurrent and sustained episodes of ventricular arrhythmia. She is treated with an antiarrhythmic agent that preferentially binds to rapidly depolarizing and ischemic ventricular myocardial fibers and has minimal effect on normal ventricular myocardium. Which of the following agents was most likely used in this patient?

- A. Adenosine (9%)
- B. Digoxin (3%)
- C. Diltiazem (4%)
- D. Ibutilide (5%)
- ✓ E. Lidocaine (62%)
- F. Metoprolol (1%)
- G. Procainamide (13%)

Omitted
Correct answer
E

62%
Answered correctly

02 secs
Time Spent

04/25/2020
Last Updated

Explanation

This patient sustained an anterolateral ST-elevation myocardial infarction (MI) with successful reperfusion following percutaneous coronary

1
2
3
4
5
6
7
8
9
10
11
12
13
14
15
16
17
18
19
20
21
22
23
24
25
26
27
28
29
30
31

This patient sustained an anterolateral ST elevation myocardial infarction (MI) with successful reperfusion following percutaneous coronary intervention. **Ventricular arrhythmias** (premature beats, ventricular tachycardia/fibrillation) are common in the first 24-48 hours after MI and may be treated with antiarrhythmic medications (eg, **amiodarone**, **lidocaine**).

Class IB drugs like lidocaine are the weakest sodium channel blockers (**dissociate the fastest**) compared to other class I antiarrhythmics. They predominantly bind to sodium channels in the **inactivated state**, and dissociation from the channels occurs so rapidly that they have a negligible effect on QRS duration in normal cardiac tissues. Ischemic myocardium has higher than normal (less negative) resting membrane potential, which delays voltage-dependent recovery of sodium channels from the inactivated to the resting state. This allows increased binding of class IB agents; therefore, class IB antiarrhythmics are highly efficacious in inhibiting **ischemia-induced ventricular arrhythmias**.

(Choice A) Adenosine causes transient conduction delay through the atrioventricular (AV) node and is used in the acute treatment of paroxysmal supraventricular tachycardia; it is not indicated in ventricular arrhythmias.

(Choice B) Digoxin enhances vagal tone and leads to an increased effective refractory period and decreased conduction velocity through the AV node. These actions are useful in management of patients with supraventricular tachyarrhythmias.

(Choice C) Diltiazem is a class IV antiarrhythmic drug (calcium channel blocker) that slows the sinus rate, prolongs conduction through the AV node, and depresses myocardial contractility (ie, a negative inotropic effect). It is primarily used as a rate-control agent for the management of atrial tachyarrhythmias (eg, atrial flutter, atrial fibrillation).

(Choice D) Ibutilide is a class III antiarrhythmic drug (potassium channel blocker) and is occasionally used for acute termination of atrial flutter and fibrillation. It prolongs the QT interval and increases the risk of polymorphic ventricular tachycardia (torsades de pointes).

(Choice F) Metoprolol is a selective beta-1 receptor antagonist (class II antiarrhythmic) that acts as a negative inotropic and chronotropic agent (decreased myocardial contractility and heart rate). Beta blockers are frequently used in patients with acute or recent MI; they reduce the risk of ventricular arrhythmia by decreasing automaticity and reduce the size of ischemic myocardium by decreasing myocardial oxygen demand.

(Choice G) Class IA antiarrhythmic drugs (eg, procainamide, disopyramide) tend to bind to sodium channels in the open state and are more specific for suppressing arrhythmias arising from areas of normal automaticity (lidocaine is more specific to inactivated channels that are more predominant in ischemic myocardium). Class IA agents also have significant potassium channel-blocking activity, leading to prolongation of action potential and an increased risk of ventricular arrhythmias.

1
2
3
4
5
6
7
8
9
10
11
12
13
14
15
16
17
18
19
20
21
22
23
24
25
26
27
28
29
30
31

Exhibit Display

Voltage activated sodium channel states

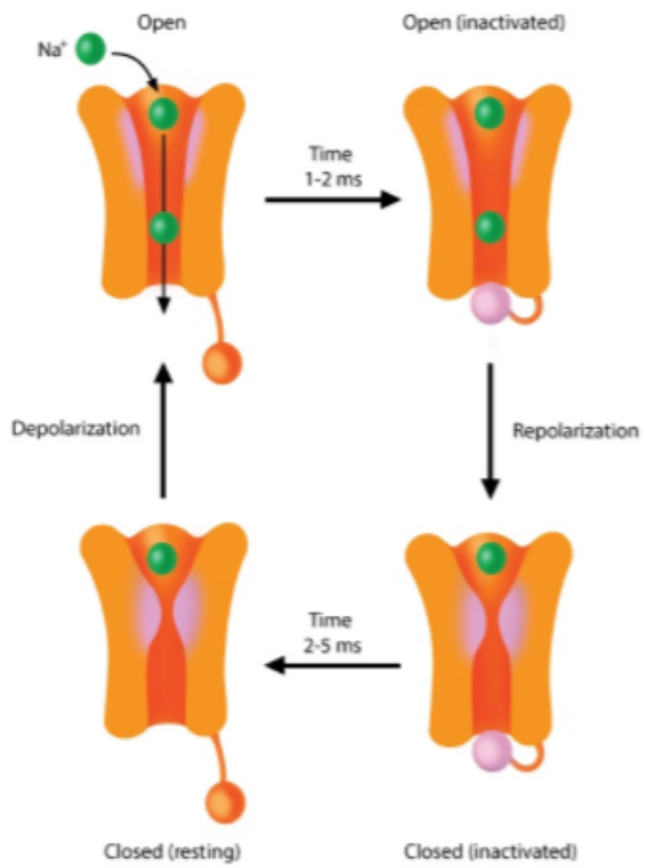

©UWorld

Zoom In Zoom Out Reset Add To New Card | Existing Card

(Choice B) Digoxin enhances vagal tone and leads to an increased effective refractory period and decreased conduction velocity through the AV node. These actions are useful in management of patients with supraventricular tachyarrhythmias.

(Choice C) Diltiazem is a class IV antiarrhythmic drug (calcium channel blocker) that slows the sinus rate, prolongs conduction through the AV node, and depresses myocardial contractility (ie, a negative inotropic effect). It is primarily used as a rate-control agent for the management of atrial tachyarrhythmias (eg, atrial flutter, atrial fibrillation).

(Choice D) Ibutilide is a class III antiarrhythmic drug (potassium channel blocker) and is occasionally used for acute termination of atrial flutter and fibrillation. It prolongs the QT interval and increases the risk of polymorphic ventricular tachycardia (torsades de pointes).

(Choice F) Metoprolol is a selective beta-1 receptor antagonist (class II antiarrhythmic) that acts as a negative inotropic and chronotropic agent (decreased myocardial contractility and heart rate). Beta blockers are frequently used in patients with acute or recent MI; they reduce the risk of ventricular arrhythmia by decreasing automaticity and reduce the size of ischemic myocardium by decreasing myocardial oxygen demand.

(Choice G) Class IA antiarrhythmic drugs (eg, procainamide, disopyramide) tend to bind to sodium channels in the open state and are more specific for suppressing arrhythmias arising from areas of normal automaticity (lidocaine is more specific to inactivated channels that are more predominant in ischemic myocardium). Class IA agents also have significant potassium channel-blocking activity, leading to prolongation of action potential and an increased risk of ventricular arrhythmias.

Educational objective:
Lidocaine is a class IB antiarrhythmic drug that tends to bind to inactivated sodium channels and rapidly dissociates. As a result, it is effective in suppressing ventricular tachyarrhythmias induced by rapidly depolarizing and ischemic myocardium.

References

- Part 8: adult advanced cardiovascular life support: 2010 American Heart Association Guidelines for Cardiopulmonary Resuscitation and Emergency Cardiovascular Care.

Pharmacology	Cardiovascular System	Antiarrhythmic drugs
Subject	System	Topic

Copyright © UWorld. All rights reserved.

A 48-year-old man comes to the office for a follow-up visit. He was diagnosed with hypercholesterolemia 6 months ago and has been strictly following dietary and lifestyle modifications as advised. The patient has no other medical problems. He does not use tobacco, alcohol, or illicit drugs. His father has diabetes mellitus and coronary artery disease. The patient's blood pressure is 126/70 mm Hg and BMI is 33.1 kg/m^2. Physical examination is normal. Laboratory studies show a current LDL level of 190 mg/dL. Which of the following should be obtained before starting statin therapy in this patient?

- A. Apolipoprotein-B level
- B. Complete blood count
- C. Lipoprotein lipase activity assay
- D. Liver transaminase levels
- E. Serum cortisol level
- F. Serum creatinine

Submit

1
2
3
4
5
6
7
8
9
10
11
12
13
14
15
16
17
18
19
20
21
22
23
24
25
26
27
28
29
30
31

A 48-year-old man comes to the office for a follow-up visit. He was diagnosed with hypercholesterolemia 6 months ago and has been strictly following dietary and lifestyle modifications as advised. The patient has no other medical problems. He does not use tobacco, alcohol, or illicit drugs. His father has diabetes mellitus and coronary artery disease. The patient's blood pressure is 126/70 mm Hg and BMI is 33.1 kg/m^2. Physical examination is normal. Laboratory studies show a current LDL level of 190 mg/dL. Which of the following should be obtained before starting statin therapy in this patient?

- A. Apolipoprotein-B level (3%)
- B. Complete blood count (1%)
- C. Lipoprotein lipase activity assay (4%)
- ✓ D. Liver transaminase levels (69%)
- E. Serum cortisol level (0%)
- F. Serum creatinine (20%)

Omitted
Correct answer
D

69%
Answered correctly

02 secs
Time Spent

02/04/2020
Last Updated

Explanation

Antihyperlipidemic medications			
Drug	Mechanism	Major lipid effects	Side effects

Antihyperlipidemic medications			
Drug	**Mechanism**	**Major lipid effects**	**Side effects**
Statins	• Inhibit HMG-CoA reductase	• ↓↓ **LDL** • ↓ Triglycerides	• Hepatotoxicity • Muscle toxicity
Ezetimibe	• ↓ Intestinal cholesterol absorption	• ↓ LDL	• ↑ Hepatotoxicity if given with statins
Bile acid sequestrants	• Prevent reabsorption of bile acids in the intestine	• ↓ LDL	• Nausea, bloating, cramping • Impaired absorption of drug & fat-soluble vitamin
Niacin	• ↓ Fatty acid release • ↓ VLDL synthesis • ↓ HDL clearance	• ↓ LDL • ↑↑ HDL	• Flushing & pruritus • Hepatotoxicity • Hyperuricemia/gout
Fibrates	• Activate PPAR-α • ↓ VLDL synthesis	• ↓↓ **Triglycerides** • ↑ HDL	• Muscle toxicity • Gallstones
Fish oil/omega-3 fatty acids	• ↓ VLDL synthesis • ↓ Apolipoprotein B synthesis	• ↓ Triglycerides • ↑ HDL	• Fishy taste

PPAR-α = peroxisome proliferator-activated receptor-alpha.

This patient has a severe elevation in his **LDL** level. This degree of hyperlipidemia, especially with a family history of coronary artery disease, suggests familial hypercholesterolemia and confers a very high risk for cardiovascular events. **HMG-CoA reductase inhibitors** (statins) are the first-line therapy for most patients with hypercholesterolemia and have been proven to reduce the risk of cardiac events. The statins are structural analogs of HMG-CoA and competitively inhibit HMG-CoA reductase, the enzyme responsible for the rate-limiting step in cholesterol synthesis.

This patient has a severe elevation in his **LDL** level. This degree of hyperlipidemia, especially with a family history of coronary artery disease, suggests familial hypercholesterolemia and confers a very high risk for cardiovascular events. **HMG-CoA reductase inhibitors** (statins) are the first-line therapy for most patients with hypercholesterolemia and have been proven to reduce the risk of cardiac events. The statins are structural analogs of HMG-CoA and competitively inhibit HMG-CoA reductase, the enzyme responsible for the rate-limiting step in cholesterol synthesis.

Serious side effects of statins include **myopathy** and **hepatitis**. Although mild elevations of liver enzymes are common, significant liver injury (aspartate transaminase/alanine transaminase levels more than 3 times the upper limit of normal) is seen in less than 1% of patients and is usually reversible if the medication is discontinued. **Liver function tests** are recommended before starting statin therapy; otherwise, routine monitoring is not necessary unless symptoms of hepatic injury develop (eg, fatigue, malaise, anorexia).

(Choice A) Apolipoprotein-B (Apo-B) is a structural protein found in atherogenic lipoprotein particles. Each lipoprotein particle contains only a single Apo-B molecule, so measurement of Apo-B levels can quantify the LDL particle count. Patients with increased LDL particle counts are at greater risk for cardiovascular events. However, measurement is of limited clinical utility and would not change management in this case.

(Choice B) Statin medications do not cause any significant hematologic toxicity.

(Choice C) Lipoprotein lipase deficiency can cause familial hypertriglyceridemia (heterozygous deficiency) and chylomicronemia (homozygous deficiency) syndromes. These conditions present with elevated serum triglyceride levels but do not cause elevation in LDL levels.

(Choice E) Because cholesterol is a precursor in the synthesis of adrenocortical and gonadal steroid hormones, statin medications can, in theory, cause hypogonadism or hypoadrenalism. Clinically, however, there are no significant alterations in serum cortisol or gonadal steroid levels unless patients are also on other adrenal enzyme inhibitors (eg, ketoconazole, aminoglutethimide).

(Choice F) Statins have no significant renal side effects. In rare instances, they can cause rhabdomyolysis, which can precipitate acute renal failure; however, this occurs less commonly than hepatic dysfunction and would be associated with myalgias and myoglobinuria.

Educational objective:
Common side effects of HMG-CoA reductase inhibitors (statins) include muscle and liver toxicity. Hepatic transaminases should be checked prior to initiating therapy and repeated if symptoms of hepatic injury occur.

References

Statins and the liver

1
2
3
4
5
6
7
8
9
10
11
12
13
14
15
16
17
18
19
20
21
22
23
24
25
26
27
28
29
30
31

(aspartate transaminase/alanine transaminase levels more than 3 times the upper limit of normal) is seen in less than 1% of patients and is usually reversible if the medication is discontinued. **Liver function tests** are recommended before starting statin therapy; otherwise, routine monitoring is not necessary unless symptoms of hepatic injury develop (eg, fatigue, malaise, anorexia).

(Choice A) Apolipoprotein-B (Apo-B) is a structural protein found in atherogenic lipoprotein particles. Each lipoprotein particle contains only a single Apo-B molecule, so measurement of Apo-B levels can quantify the LDL particle count. Patients with increased LDL particle counts are at greater risk for cardiovascular events. However, measurement is of limited clinical utility and would not change management in this case.

(Choice B) Statin medications do not cause any significant hematologic toxicity.

(Choice C) Lipoprotein lipase deficiency can cause familial hypertriglyceridemia (heterozygous deficiency) and chylomicronemia (homozygous deficiency) syndromes. These conditions present with elevated serum triglyceride levels but do not cause elevation in LDL levels.

(Choice E) Because cholesterol is a precursor in the synthesis of adrenocortical and gonadal steroid hormones, statin medications can, in theory, cause hypogonadism or hypoadrenalism. Clinically, however, there are no significant alterations in serum cortisol or gonadal steroid levels unless patients are also on other adrenal enzyme inhibitors (eg, ketoconazole, aminoglutethimide).

(Choice F) Statins have no significant renal side effects. In rare instances, they can cause rhabdomyolysis, which can precipitate acute renal failure; however, this occurs less commonly than hepatic dysfunction and would be associated with myalgias and myoglobinuria.

Educational objective:
Common side effects of HMG-CoA reductase inhibitors (statins) include muscle and liver toxicity. Hepatic transaminases should be checked prior to initiating therapy and repeated if symptoms of hepatic injury occur.

References

- Statins and the liver.

Pharmacology	Cardiovascular System	Drug induced liver injury
Subject	System	Topic

Copyright © UWorld. All rights reserved.

1 2 3 4 5 6 7 8 9 10 11 12 13 14 15 16 17 18 19 20 21 22 23 24 25 26 27 28 29 30 31

A 66-year-old man is evaluated for recurrent syncope. He has had 3 episodes of dizziness and palpitations followed by brief loss of consciousness over the last 6 months. He has no chest pain or dyspnea. The patient has a history of hypertension and hyperlipidemia. There is no family history of sudden death. Initial evaluation shows normal ECG and echocardiogram. A cardiac electrophysiologic study is performed. During the study, intravenous infusion of a medication is administered and produces the responses shown below.

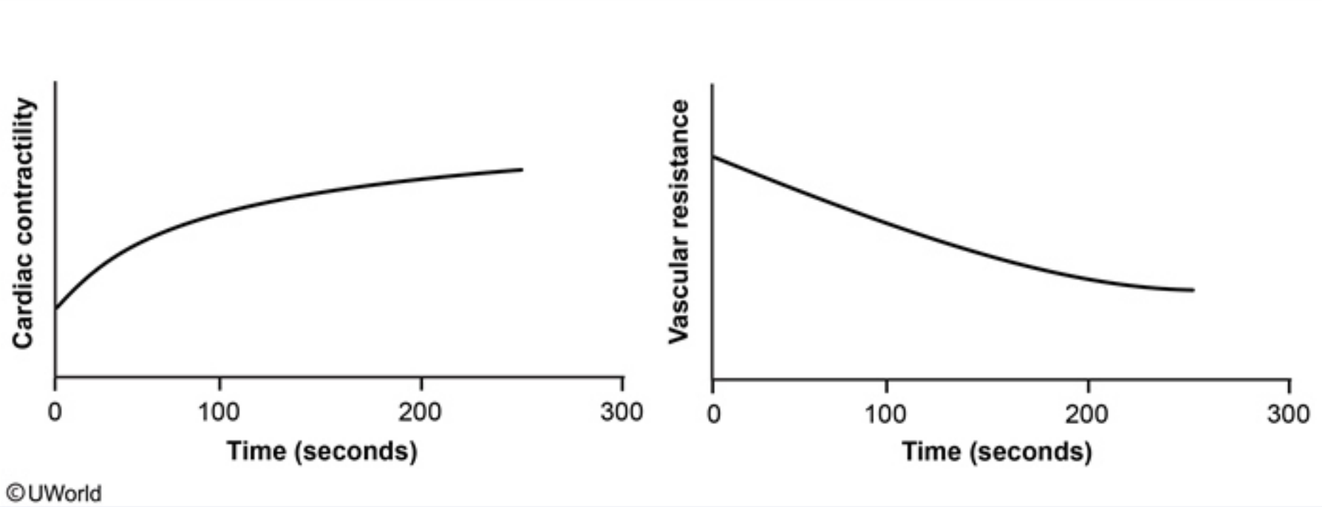

Which of the following medications was most likely administered to this patient?

- A. Acetylcholine
- B. Adenosine
- C. Clonidine
- D. Esmolol
- E. Isoproterenol
- F. Norepinephrine

1
2
3
4
5
6
7
8
9
10
11
12
13
14
15
16
17
18
19
20
21
22
23
24
25
26
27
28
29
30
31

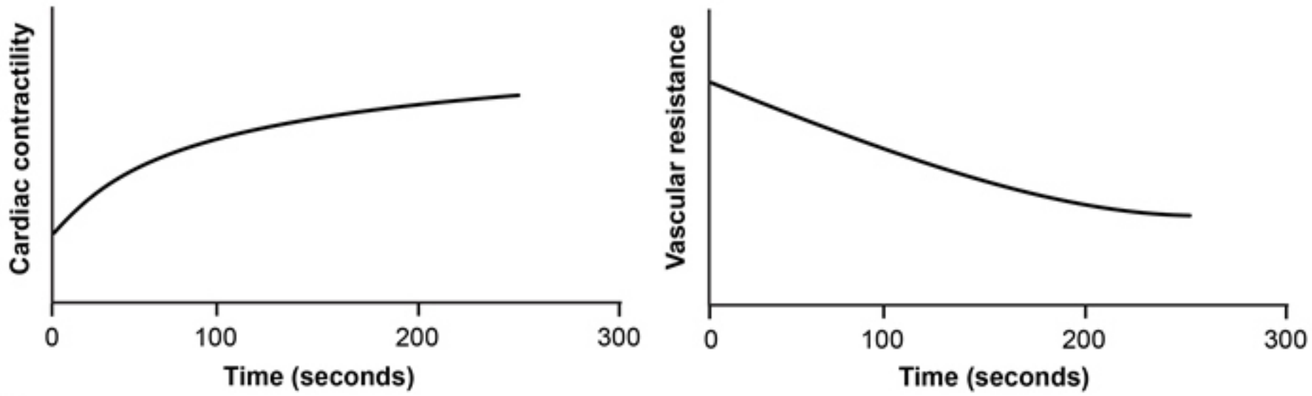

©UWorld

Which of the following medications was most likely administered to this patient?

- A. Acetylcholine
- B. Adenosine
- C. Clonidine
- D. Esmolol
- E. Isoproterenol
- F. Norepinephrine
- G. Phenylephrine

Submit

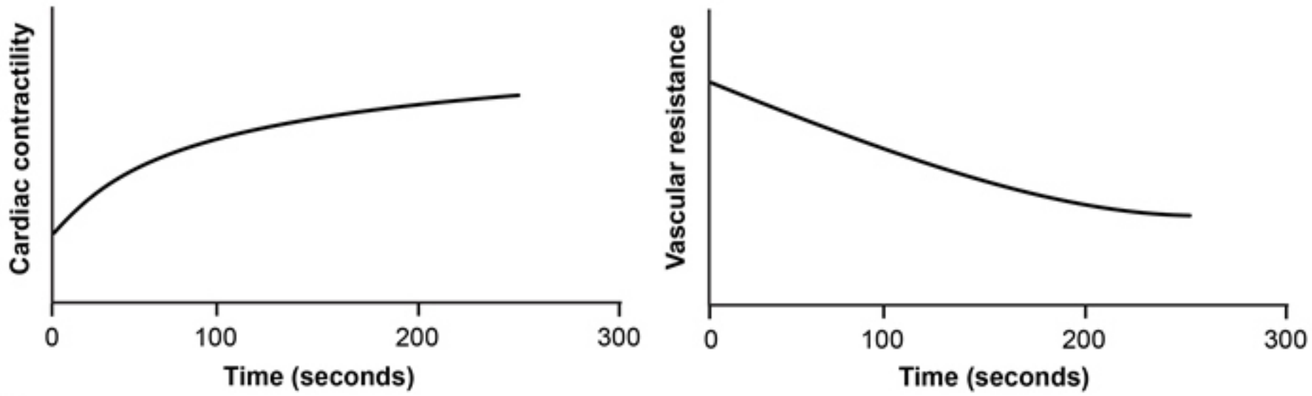

©UWorld

Which of the following medications was most likely administered to this patient?

- A. Acetylcholine (1%)
- B. Adenosine (11%)
- C. Clonidine (5%)
- D. Esmolol (7%)
- ✓ E. Isoproterenol (55%)
- F. Norepinephrine (12%)
- G. Phenylephrine (5%)

Omitted
Correct answer

55%
Answered correctly

12 secs
Time Spent

03/15/2020
Last Updated

Effects of adrenergic drugs			
Receptor	**Target organ**	**Effect of stimulation**	**Examples**
α-1	• Peripheral vasculature • Bladder • Eye	• ↑ Blood pressure (especially systolic) • Contraction of internal urethral sphincter • Mydriasis (contraction of pupillary dilator muscle)	• Epinephrine • Norepinephrine • Phenylephrine
β-1	• Heart	• ↑ Heart rate, contractility & conductance	• Epinephrine • Dopamine • Dobutamine • Isoproterenol
β-2	• Peripheral vasculature (smooth muscle) • Bronchi • Uterus	• Vasodilation, ↓ blood pressure (especially diastolic) • Bronchodilation • Relaxation (tocolysis)	• Isoproterenol • Terbutaline

©UWorld

The effects seen in the graphs above are most similar to those elicited by **isoproterenol**, a nonselective β adrenergic agonist. Isoproterenol **increases cardiac contractility** (positive inotropic effect) by acting on myocardial β-1 adrenergic receptors. It also binds to β-2 adrenergic

©UWorld

The effects seen in the graphs above are most similar to those elicited by **isoproterenol**, a nonselective β adrenergic agonist. Isoproterenol **increases cardiac contractility** (positive inotropic effect) by acting on myocardial β-1 adrenergic receptors. It also binds to β-2 adrenergic receptors and causes vasodilation by relaxation of vascular smooth muscle, leading to **decreased vascular resistance** and mean arterial blood pressure. Isoproterenol has negligible effects on α-1 adrenergic receptors.

(Choice A) Acetylcholine binds to M_2 muscarinic receptors in the heart and M_3 receptors in the vasculature and causes decreased heart rate and conduction velocity and vasodilation (indirectly mediated by endothelial nitric oxide release). Acetylcholine has no significant effect on ventricular contractility.

(Choice B) Adenosine acts on A1 receptors on cardiac cells and activates potassium channels, increasing potassium conductance. This leads to transient conduction delay through the atrioventricular node. Adenosine can also cause peripheral vasodilation, but it attenuates the adrenergic-mediated increase in myocardial contractility.

(Choice C) Clonidine stimulates α_2 adrenoceptors in the brainstem, resulting in reduced sympathetic outflow from the central nervous system, leading to a decrease in peripheral vascular resistance, heart rate, and blood pressure. It has no effect on cardiac contractility.

(Choice D) Esmolol is a selective β-1 adrenergic blocking agent with negative inotropic and chronotropic effects. It would cause a decrease in cardiac contractility.

(Choice F) Norepinephrine acts on α-1 receptors, causing vasoconstriction and an increase in systemic vascular resistance. Norepinephrine also acts as a weak agonist at β-1 receptors, with a modest increase in myocardial contractility.

(Choice G) Phenylephrine is a sympathomimetic drug with pure α adrenergic agonist activity. Infusion of this drug causes vasoconstriction with an increase in systemic vascular resistance.

Educational objective:
Isoproterenol is a β-1 and β-2 adrenergic receptor agonist that causes increased myocardial contractility and decreased systemic vascular resistance.

Pharmacology	Cardiovascular System	Sympathomimetic agents
Subject	System	Topic

1
2
3
4
5
6
7
8
9
10
11
12
13
14
15
16
17
18
19
20
21
22
23
24
25
26
27
28
29
30
31

A 45-year-old man comes to the emergency department due to shortness of breath and fatigue that has progressed over the last 2 weeks. The patient was diagnosed with nonischemic cardiomyopathy 2 years ago and has not been adherent with physician visits and his medical regimen. Blood pressure is 106/58 mm Hg, and pulse is 88/min and regular. The patient appears uncomfortable when lying flat. Jugular venous pressure is elevated. Bibasilar crackles are heard on lung auscultation and an S3 is present. There is 1+ bilateral lower extremity pitting edema. Milrinone infusion is initiated. Which of the following is the most likely response to this therapy?

- A. Angioedema
- B. Antiarrhythmic action
- C. Atrioventricular conduction block
- D. Decreased renal perfusion
- E. Increased right atrial pressure
- F. Vasodilation

Submit

1
2
3
4
5
6
7
8
9
10
11
12
13
14
15
16
17
18
19
20
21
22
23
24
25
26
27
28
29
30
31

A 45-year-old man comes to the emergency department due to shortness of breath and fatigue that has progressed over the last 2 weeks. The patient was diagnosed with nonischemic cardiomyopathy 2 years ago and has not been adherent with physician visits and his medical regimen. Blood pressure is 106/58 mm Hg, and pulse is 88/min and regular. The patient appears uncomfortable when lying flat. Jugular venous pressure is elevated. Bibasilar crackles are heard on lung auscultation and an S3 is present. There is 1+ bilateral lower extremity pitting edema. Milrinone infusion is initiated. Which of the following is the most likely response to this therapy?

- A. Angioedema (2%)
- B. Antiarrhythmic action (9%)
- C. Atrioventricular conduction block (3%)
- D. Decreased renal perfusion (8%)
- E. Increased right atrial pressure (12%)
- ✓ F. Vasodilation (63%)

Omitted
Correct answer
F

63%
Answered correctly

02 secs
Time Spent

02/08/2020
Last Updated

Explanation

Milrinone pharmacology

1
2
3
4
5
6
7
8
9
10
11
12
13
14
15
16
17
18
19
20
21
22
23
24
25
26
27
28
29
30
31

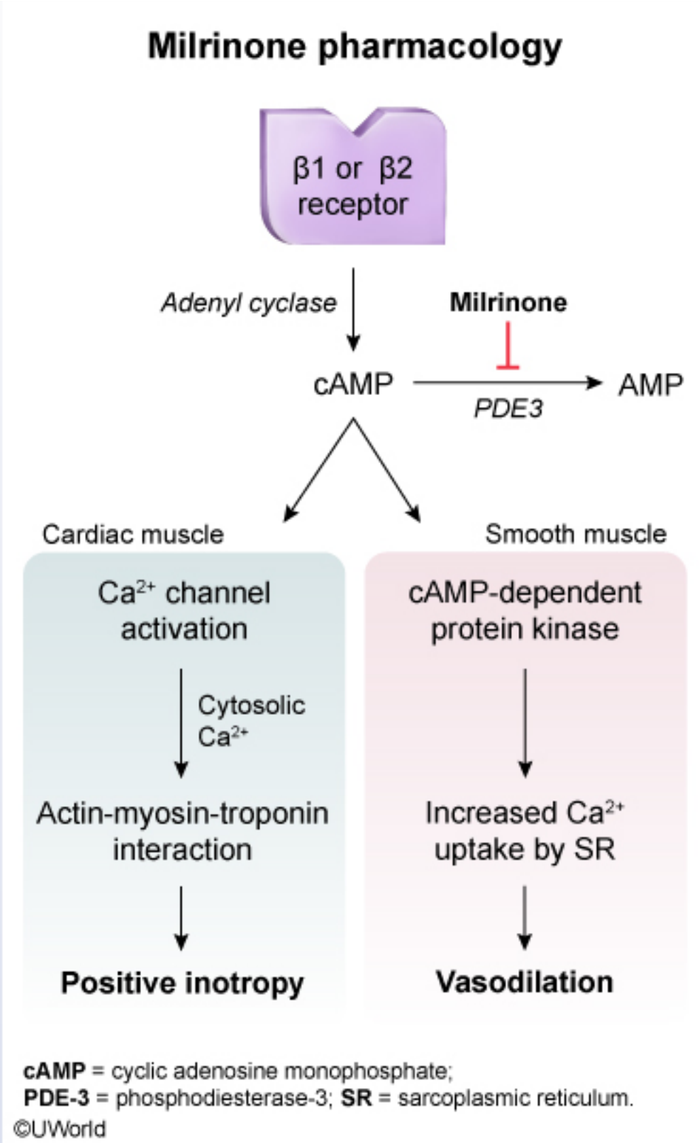

Milrinone is a selective **phosphodiesterase (PDE)-3 enzyme inhibitor** that can be used in patients with refractory heart failure due to left

Milrinone is a selective **phosphodiesterase (PDE)-3 enzyme inhibitor** that can be used in patients with refractory heart failure due to left ventricular systolic dysfunction. The PDE-3 enzyme is normally responsible for degrading cyclic adenosine monophosphate (cAMP) to AMP; the inhibition of cAMP degradation via milrinone has 2 positive effects on heart failure:

- In cardiomyocytes, intracellular calcium influx is increased, which increases cardiac contractility (**positive inotropy**) to improve stroke volume and cardiac output.
- In vascular smooth muscle, uptake of calcium by the sarcoplasmic reticulum is increased, which reduces calcium-myosin light chain kinase interaction to stimulate relaxation and **vasodilation**. Venous vasodilation **reduces preload** and arterial vasodilation **reduces afterload** to provide a cumulative reduction in cardiac work.

Although the vasodilatory action of milrinone can lead to hypotension, this effect is often compensated for by an increase in stroke volume that maintains blood pressure.

(Choice A) Angioedema refers to localized subcutaneous swelling that affects the submucosal tissues of the face, mouth, throat, and genitalia. It is typically seen as a side effect of ACE inhibitors due to inhibition of bradykinin degradation.

(Choice B) Milrinone does not have an antiarrhythmic effect on the myocardium. In fact, its positive inotropic effect may induce ventricular arrhythmias in some patients.

(Choice C) Atrioventricular conduction block can be caused by toxicity due to digoxin, nondihydropyridine calcium channel blockers, or beta blockers; however, PDE inhibitors have minimal chronotropic effect (positive or negative).

(Choice D) Renal perfusion is increased with milrinone due to an increase in cardiac output.

(Choice E) Right atrial pressure is decreased with milrinone due to venous dilation and a consequent reduction in cardiac venous return (preload).

Educational objective:
Milrinone is a phosphodiesterase-3 inhibitor that reduces the degradation of cyclic adenosine monophosphate to provide 2 beneficial effects for treating systolic heart failure. Calcium influx into cardiomyocytes is increased, which increases cardiac contractility. In addition, calcium-myosin light chain kinase interaction is reduced, which causes vasodilation and reduces cardiac preload and afterload.

interaction to stimulate relaxation and **vasodilation**. Venous vasodilation **reduces preload** and arterial vasodilation **reduces afterload** to provide a cumulative reduction in cardiac work.

Although the vasodilatory action of milrinone can lead to hypotension, this effect is often compensated for by an increase in stroke volume that maintains blood pressure.

(Choice A) Angioedema refers to localized subcutaneous swelling that affects the submucosal tissues of the face, mouth, throat, and genitalia. It is typically seen as a side effect of ACE inhibitors due to inhibition of bradykinin degradation.

(Choice B) Milrinone does not have an antiarrhythmic effect on the myocardium. In fact, its positive inotropic effect may induce ventricular arrhythmias in some patients.

(Choice C) Atrioventricular conduction block can be caused by toxicity due to digoxin, nondihydropyridine calcium channel blockers, or beta blockers; however, PDE inhibitors have minimal chronotropic effect (positive or negative).

(Choice D) Renal perfusion is increased with milrinone due to an increase in cardiac output.

(Choice E) Right atrial pressure is decreased with milrinone due to venous dilation and a consequent reduction in cardiac venous return (preload).

Educational objective:
Milrinone is a phosphodiesterase-3 inhibitor that reduces the degradation of cyclic adenosine monophosphate to provide 2 beneficial effects for treating systolic heart failure. Calcium influx into cardiomyocytes is increased, which increases cardiac contractility. In addition, calcium-myosin light chain kinase interaction is reduced, which causes vasodilation and reduces cardiac preload and afterload.

References

- Inotropes.

Pharmacology	Cardiovascular System	Chronic heart failure
Subject	System	Topic

Copyright © UWorld. All rights reserved.

1
2
3
4
5
6
7
8
9
10
11
12
13
14
15
16
17
18
19
20
21
22
23
24
25
26
27
28
29
30
31

A 64-year-old man comes to the office for follow-up of hypertension. At the last 2 visits, his blood pressure was persistently elevated. The patient has been treated with lisinopril for the past 5 years, but his other blood pressure medications have been changed several times due to various adverse effects. Medical history is significant for type 2 diabetes mellitus, coronary artery disease with stable angina, and moderately increased albuminuria. Blood pressure is 145/87 mm Hg and pulse is 70/min. BMI is 31 kg/m^2. Physical examination shows trace bilateral lower extremity edema. ECG is unremarkable. Serum laboratory results are as follows:

Sodium	138 mEq/L
Potassium	5.3 mEq/L
Chloride	104 mEq/L
Bicarbonate	24 mEq/L
Calcium	9.5 mg/dL
Creatinine	1.0 mg/dL

Review of the patient's medical records shows similar serum laboratory results 6 months ago. Which of the following medications should be avoided in this patient?

A. Amlodipine
B. Bumetanide
C. Diltiazem
D. Eplerenone
E. Furosemide
F. Metoprolol

1
2
3
4
5
6
7
8
9
10
11
12
13
14
15
16
17
18
19
20
21
22
23
24
25
26
27
28
29
30
31

adverse effects. Medical history is significant for type 2 diabetes mellitus, coronary artery disease with stable angina, and moderately increased albuminuria. Blood pressure is 145/87 mm Hg and pulse is 70/min. BMI is 31 kg/m^2. Physical examination shows trace bilateral lower extremity edema. ECG is unremarkable. Serum laboratory results are as follows:

Sodium	138 mEq/L
Potassium	5.3 mEq/L
Chloride	104 mEq/L
Bicarbonate	24 mEq/L
Calcium	9.5 mg/dL
Creatinine	1.0 mg/dL

Review of the patient's medical records shows similar serum laboratory results 6 months ago. Which of the following medications should be avoided in this patient?

A. Amlodipine
B. Bumetanide
C. Diltiazem
D. Eplerenone
E. Furosemide
F. Metoprolol

Submit

adverse effects. Medical history is significant for type 2 diabetes mellitus, coronary artery disease with stable angina, and moderately increased albuminuria. Blood pressure is 145/87 mm Hg and pulse is 70/min. BMI is 31 kg/m^2. Physical examination shows trace bilateral lower extremity edema. ECG is unremarkable. Serum laboratory results are as follows:

Sodium	138 mEq/L
Potassium	5.3 mEq/L
Chloride	104 mEq/L
Bicarbonate	24 mEq/L
Calcium	9.5 mg/dL
Creatinine	1.0 mg/dL

Review of the patient's medical records shows similar serum laboratory results 6 months ago. Which of the following medications should be avoided in this patient?

A. Amlodipine (5%)
B. Bumetanide (1%)
C. Diltiazem (2%)
✓ D. Eplerenone (78%)
E. Furosemide (8%)
F. Metoprolol (3%)

Omitted
Correct answer

78%
Answered correctly

04 secs
Time Spent

04/14/2020
Last Updated

Medications that can cause hyperkalemia	
Medication	**Mechanism**
Nonselective beta-adrenergic blockers	Inhibit beta-2–mediated intracellular potassium uptake
ACE inhibitors	Inhibit angiotensin II formation, leading to decreased aldosterone secretion
ARBs	Inhibit AT_1 receptor, leading to decreased aldosterone secretion
K^+-sparing diuretics	Inhibit ENaC or aldosterone receptor
Cardiac glycosides (eg, digoxin)	Inhibit the Na^+/K^+-ATPase pump
NSAIDs	Inhibit local prostaglandin synthesis, leading to decreased renin & aldosterone secretion

ARBs = angiotensin II receptor blockers; **AT_1** = angiotensin II type 1; **ENaC** = epithelial sodium channel; **Na^+/K^+-ATPase** = sodium/potassium adenosine triphosphatase; **NSAIDs** = nonsteroidal anti-inflammatory drugs.

This patient with diabetes complicated by albuminuria, coronary artery disease (CAD), and hypertension is being appropriately treated with an **ACE inhibitor** (eg, lisinopril). ACE inhibitors block the conversion of angiotensin I to angiotensin II, leading to decreased systemic vascular tone, reduced aldosterone secretion, and lowered blood pressure. Decreased aldosterone levels cause increased sodium excretion and **potassium retention**, which can lead to **hyperkalemia**. The risk is greatest in patients with renal insufficiency and those taking potassium-sparing diuretics or medications that decrease glomerular filtration (eg, nonsteroidal anti-inflammatory drugs).

Mineralocorticoid receptor blockers (eg, spironolactone, **eplerenone**), angiotensin II receptor blockers (eg, losartan), and epithelial sodium channel blockers (eg, amiloride, triamterene) are other antihypertensives that can raise potassium levels. Concurrent use with an ACE inhibitor can result in severe hyperkalemia and should be avoided in this patient with mild hyperkalemia at baseline.

(Choices A and C) Dihydropyridine calcium channel blockers (eg, amlodipine, nifedipine) inhibit the L-type calcium channel on vascular smooth muscle, leading to arterial vasodilation. Nondihydropyridine calcium channel blockers (eg, verapamil) reduce heart rate and contractility. Diltiazem

adenosine triphosphatase; **NSAIDs** = nonsteroidal anti-inflammatory drugs.

This patient with diabetes complicated by albuminuria, coronary artery disease (CAD), and hypertension is being appropriately treated with an **ACE inhibitor** (eg, lisinopril). ACE inhibitors block the conversion of angiotensin I to angiotensin II, leading to decreased systemic vascular tone, reduced aldosterone secretion, and lowered blood pressure. Decreased aldosterone levels cause increased sodium excretion and **potassium retention**, which can lead to **hyperkalemia**. The risk is greatest in patients with renal insufficiency and those taking potassium-sparing diuretics or medications that decrease glomerular filtration (eg, nonsteroidal anti-inflammatory drugs).

Mineralocorticoid receptor blockers (eg, spironolactone, **eplerenone**), angiotensin II receptor blockers (eg, losartan), and epithelial sodium channel blockers (eg, amiloride, triamterene) are other antihypertensives that can raise potassium levels. Concurrent use with an ACE inhibitor can result in severe hyperkalemia and should be avoided in this patient with mild hyperkalemia at baseline.

(Choices A and C) Dihydropyridine calcium channel blockers (eg, amlodipine, nifedipine) inhibit the L-type calcium channel on vascular smooth muscle, leading to arterial vasodilation. Nondihydropyridine calcium channel blockers (eg, verapamil) reduce heart rate and contractility. Diltiazem causes both vasodilation and decreased heart rate and contractility. Calcium channel blockers do not cause significant electrolyte abnormalities and may be used in patients at risk for hyperkalemia. Although dihydropyridine calcium channel blockers may cause lower extremity edema, *trace pedal edema* is extremely common and *not a contraindication* for use.

(Choices B and E) Loop diuretics (eg, bumetanide, furosemide) inhibit the $Na^+/K^+/2Cl^-$ symporter in the ascending limb of the loop of Henle. They decrease intravascular volume, leading to an increase in serum aldosterone and a resultant increase in urinary potassium excretion, causing hypokalemia.

(Choice F) Metoprolol is a selective beta-1 blocker that decreases heart rate, cardiac contractility, and renin release, which reduces arterial blood pressure and myocardial oxygen demand. Although nonselective beta blockers (eg, carvedilol) can cause hyperkalemia by inhibiting beta-2–mediated intracellular potassium uptake, this does not typically occur with selective beta-1 blockers. Although beta blockers can mask hypoglycemia in *diabetic patients*, this is *not a contraindication* and they can still be used (cautiously) in patients with CAD to reduce myocardial oxygen demand.

Educational objective:
ACE inhibitors block the conversion of angiotensin I to angiotensin II, thereby reducing vasoconstriction and aldosterone secretion. Decreased aldosterone leads to potassium retention, which can cause hyperkalemia, especially in patients with renal insufficiency and those taking other

1 2 3 4 5 6 7 8 9 10 11 12 13 14 15 16 17 18 19 20 21 22 23 24 25 26 27 28 29 30 31

(Choices A and C) Dihydropyridine calcium channel blockers (eg, amlodipine, nifedipine) inhibit the L-type calcium channel on vascular smooth muscle, leading to arterial vasodilation. Nondihydropyridine calcium channel blockers (eg, verapamil) reduce heart rate and contractility. Diltiazem causes both vasodilation and decreased heart rate and contractility. Calcium channel blockers do not cause significant electrolyte abnormalities and may be used in patients at risk for hyperkalemia. Although dihydropyridine calcium channel blockers may cause lower extremity edema, *trace pedal edema* is extremely common and *not a contraindication* for use.

(Choices B and E) Loop diuretics (eg, bumetanide, furosemide) inhibit the $Na^+/K^+/2Cl^-$ symporter in the ascending limb of the loop of Henle. They decrease intravascular volume, leading to an increase in serum aldosterone and a resultant increase in urinary potassium excretion, causing hypokalemia.

(Choice F) Metoprolol is a selective beta-1 blocker that decreases heart rate, cardiac contractility, and renin release, which reduces arterial blood pressure and myocardial oxygen demand. Although nonselective beta blockers (eg, carvedilol) can cause hyperkalemia by inhibiting beta-2–mediated intracellular potassium uptake, this does not typically occur with selective beta-1 blockers. Although beta blockers can mask hypoglycemia in *diabetic patients*, this is *not a contraindication* and they can still be used (cautiously) in patients with CAD to reduce myocardial oxygen demand.

Educational objective:
ACE inhibitors block the conversion of angiotensin I to angiotensin II, thereby reducing vasoconstriction and aldosterone secretion. Decreased aldosterone leads to potassium retention, which can cause hyperkalemia, especially in patients with renal insufficiency and those taking other medications that raise potassium levels (eg, angiotensin II receptor blockers, mineralocorticoid receptor blockers).

References

- Renin-angiotensin-aldosterone system blockade for cardiovascular diseases: current status.
- Drug-induced hyperkalemia.

Pharmacology	Cardiovascular System	Hyperkalemia
Subject	System	Topic

Copyright © UWorld. All rights reserved.

A 47-year-old man comes to the office due to worsening muscle weakness and dark urine for the past several days. Two weeks ago, the patient was evaluated for dyspepsia and found to have *Helicobacter pylori* infection; he was started on treatment and has had partial symptom improvement. Medical history includes hypertension and hyperlipidemia, for which he takes amlodipine and simvastatin. Temperature is 37.1 C (98.8 F), blood pressure is 130/80 mm Hg, and pulse is 74/min. Physical examination shows diffuse muscle tenderness. Laboratory evaluation reveals elevated blood urea nitrogen and serum creatinine levels. Urine microscopy shows no red or white blood cells. Which of the following medications most likely precipitated this patient's current condition?

A. Amoxicillin

B. Bismuth subsalicylate

C. Calcium carbonate

D. Clarithromycin

E. Metronidazole

Submit

1
2
3
4
5
6
7
8
9
10
11
12
13
14
15
16
17
18
19
20
21
22
23
24
25
26
27
28
29
30
31

A 47-year-old man comes to the office due to worsening muscle weakness and dark urine for the past several days. Two weeks ago, the patient was evaluated for dyspepsia and found to have *Helicobacter pylori* infection; he was started on treatment and has had partial symptom improvement. Medical history includes hypertension and hyperlipidemia, for which he takes amlodipine and simvastatin. Temperature is 37.1 C (98.8 F), blood pressure is 130/80 mm Hg, and pulse is 74/min. Physical examination shows diffuse muscle tenderness. Laboratory evaluation reveals elevated blood urea nitrogen and serum creatinine levels. Urine microscopy shows no red or white blood cells. Which of the following medications most likely precipitated this patient's current condition?

A. Amoxicillin (20%)
B. Bismuth subsalicylate (9%)
C. Calcium carbonate (5%)
✓ D. Clarithromycin (51%)
E. Metronidazole (12%)

Omitted
Correct answer
D

51%
Answered correctly

03 secs
Time Spent

02/19/2020
Last Updated

Explanation

Concurrent medications & statin myopathy	
Cytochrome P-450 (CYP3A4) inhibitors	• Non–dihydropyridine CCBs (eg, verapamil, diltiazem) • Protease inhibitors (eg, ritonavir, saquinavir)

Concurrent medications & statin myopathy	
Cytochrome P-450 (CYP3A4) inhibitors	• Non–dihydropyridine CCBs (eg, verapamil, diltiazem) • Protease inhibitors (eg, ritonavir, saquinavir) • Erythromycin
OATP inhibitors	• Cyclosporine (also a CYP3A4 inhibitor)
Additive myocyte toxicity	• Corticosteroids • Fibrates (eg, gemfibrozil) • Colchicine (also competes with statins for CYP3A4 metabolism)
CCBs = calcium channel blockers; **OATP** = organic anion transport protein.	

This patient has muscle tenderness and weakness. The dark urine suggests **myoglobinuria** due to myocyte necrosis. In the context of ongoing statin therapy for hyperlipidemia, this presentation likely represents statin myopathy. Statin myopathy is due, likely at least in part, to decreased myocyte production of coenzyme Q10 (ubiquinone). Serum muscle breakdown markers (eg, creatine kinase) are often elevated, and severe cases may lead to **rhabdomyolysis** with subsequent **acute kidney injury** (eg, elevated BUN and creatinine).

Statin myopathy is most common in the initial weeks or months of therapy. However, it can occasionally occur later, and can be acutely triggered by medications that increase circulating statin levels. This patient's myopathy is most likely related to the initiation of clarithromycin as part of a multidrug regimen for *Helicobacter pylori*.

Statins, primarily simvastatin, lovastatin, and atorvastatin, are metabolized by **CYP3A4**. This enzyme can be **inhibited by macrolide antibiotics** (eg, erythromycin, clarithromycin), leading to increased statin drug levels and subsequent statin myopathy. (Azithromycin does not significantly inhibit CYP3A4.) Other significant CYP3A4 inhibitors that can induce statin myopathy include ketoconazole, non–dihydropyridine calcium channel blockers (eg, diltiazem), amiodarone, and protease inhibitors (eg, ritonavir). Because pravastatin is not primarily metabolized by CYP3A4, patients who must take a CYP3A4 inhibitor may benefit from switching to this drug.

(Choice A) Amoxicillin does not inhibit CYP3A4 or increase circulating simvastatin levels. Penicillin antibiotics generally have only minor effects

This patient has muscle tenderness and weakness. The dark urine suggests **myoglobinuria** due to myocyte necrosis. In the context of ongoing statin therapy for hyperlipidemia, this presentation likely represents statin myopathy. Statin myopathy is due, likely at least in part, to decreased myocyte production of coenzyme Q10 (ubiquinone). Serum muscle breakdown markers (eg, creatine kinase) are often elevated, and severe cases may lead to **rhabdomyolysis** with subsequent **acute kidney injury** (eg, elevated BUN and creatinine).

Statin myopathy is most common in the initial weeks or months of therapy. However, it can occasionally occur later, and can be acutely triggered by medications that increase circulating statin levels. This patient's myopathy is most likely related to the initiation of clarithromycin as part of a multidrug regimen for *Helicobacter pylori*.

Statins, primarily simvastatin, lovastatin, and atorvastatin, are metabolized by **CYP3A4**. This enzyme can be **inhibited by macrolide antibiotics** (eg, erythromycin, clarithromycin), leading to increased statin drug levels and subsequent statin myopathy. (Azithromycin does not significantly inhibit CYP3A4.) Other significant CYP3A4 inhibitors that can induce statin myopathy include ketoconazole, non–dihydropyridine calcium channel blockers (eg, diltiazem), amiodarone, and protease inhibitors (eg, ritonavir). Because pravastatin is not primarily metabolized by CYP3A4, patients who must take a CYP3A4 inhibitor may benefit from switching to this drug.

(Choice A) Amoxicillin does not inhibit CYP3A4 or increase circulating simvastatin levels. Penicillin antibiotics generally have only minor effects on the cytochrome P-450 system.

(Choice B) Bismuth subsalicylate can cause black stools due to the formation of bismuth sulfate in the gastrointestinal tract. However, this medication does not cause myopathy or myoglobinuria. Excessive intake of bismuth can cause motor weakness, but this is due primarily to neural rather than muscle toxicity.

(Choice C) Polyvalent cations (eg, calcium, iron) can form insoluble chelate complexes with certain antibiotics (eg, tetracyclines, fluoroquinolones) and other drugs (eg, levothyroxine, levodopa), leading to decreased drug absorption. Simvastatin does not form chelate complexes, and decreased absorption would lower, not increase, the risk for myopathy.

(Choice E) Both metronidazole and simvastatin carry a small risk for peripheral neuropathy. In some patients, the effect can be additive and lead to numbness, pain, and paresthesia in the hands and feet. However, this neuropathy would not cause muscle tenderness or myoglobinuria.

Educational objective:
Statins, primarily simvastatin, lovastatin, and atorvastatin, are metabolized by CYP3A4. Drugs that inhibit this enzyme (eg, macrolide antibiotics,

Statins, primarily simvastatin, lovastatin, and atorvastatin, are metabolized by **CYP3A4**. This enzyme can be **inhibited by macrolide antibiotics** (eg, erythromycin, clarithromycin), leading to increased statin drug levels and subsequent statin myopathy. (Azithromycin does not significantly inhibit CYP3A4.) Other significant CYP3A4 inhibitors that can induce statin myopathy include ketoconazole, non–dihydropyridine calcium channel blockers (eg, diltiazem), amiodarone, and protease inhibitors (eg, ritonavir). Because pravastatin is not primarily metabolized by CYP3A4, patients who must take a CYP3A4 inhibitor may benefit from switching to this drug.

(Choice A) Amoxicillin does not inhibit CYP3A4 or increase circulating simvastatin levels. Penicillin antibiotics generally have only minor effects on the cytochrome P-450 system.

(Choice B) Bismuth subsalicylate can cause black stools due to the formation of bismuth sulfate in the gastrointestinal tract. However, this medication does not cause myopathy or myoglobinuria. Excessive intake of bismuth can cause motor weakness, but this is due primarily to neural rather than muscle toxicity.

(Choice C) Polyvalent cations (eg, calcium, iron) can form insoluble chelate complexes with certain antibiotics (eg, tetracyclines, fluoroquinolones) and other drugs (eg, levothyroxine, levodopa), leading to decreased drug absorption. Simvastatin does not form chelate complexes, and decreased absorption would lower, not increase, the risk for myopathy.

(Choice E) Both metronidazole and simvastatin carry a small risk for peripheral neuropathy. In some patients, the effect can be additive and lead to numbness, pain, and paresthesia in the hands and feet. However, this neuropathy would not cause muscle tenderness or myoglobinuria.

Educational objective:
Statins, primarily simvastatin, lovastatin, and atorvastatin, are metabolized by CYP3A4. Drugs that inhibit this enzyme (eg, macrolide antibiotics, ketoconazole, non–dihydropyridine calcium channel blockers, amiodarone) can cause increased statin drug levels and lead to statin myopathy.

References

- Clinical guidance for managing statin and antimicrobial drug-drug interactions.

Pharmacology	Cardiovascular System	Drug induced myopathy
Subject	System	Topic

Copyright © UWorld. All rights reserved.

1
2
3
4
5
6
7
8
9
10
11
12
13
14
15
16
17
18
19
20
21
22
23
24
25
26
27
28
29
30
31

A 68-year-old man comes to the office with a 6-week history of muscle pain and fatigue. He has achy pain that is not related to activity. The patient has tried warm compresses and over-the-counter analgesics without relief. Past medical history is significant for hypertension, mixed hyperlipidemia, and coronary artery disease with an acute myocardial infarction 2 years ago. Physical examination shows diffuse tenderness in the proximal muscles of the upper and lower extremities. Serum creatine kinase activity is elevated. Which of the following drug combinations is most likely responsible for this patient's condition?

- A. Atorvastatin and cholestyramine
- B. Atorvastatin and ezetimibe
- C. Atorvastatin and gemfibrozil
- D. Gemfibrozil and ezetimibe
- E. Niacin and ezetimibe
- F. Niacin and gemfibrozil

Submit

A 68-year-old man comes to the office with a 6-week history of muscle pain and fatigue. He has achy pain that is not related to activity. The patient has tried warm compresses and over-the-counter analgesics without relief. Past medical history is significant for hypertension, mixed hyperlipidemia, and coronary artery disease with an acute myocardial infarction 2 years ago. Physical examination shows diffuse tenderness in the proximal muscles of the upper and lower extremities. Serum creatine kinase activity is elevated. Which of the following drug combinations is most likely responsible for this patient's condition?

- A. Atorvastatin and cholestyramine (7%)
- B. Atorvastatin and ezetimibe (10%)
- ✓ C. Atorvastatin and gemfibrozil (76%)
- D. Gemfibrozil and ezetimibe (1%)
- E. Niacin and ezetimibe (1%)
- F. Niacin and gemfibrozil (2%)

Omitted
Correct answer
C

76%
Answered correctly

03 secs
Time Spent

01/28/2020
Last Updated

Explanation

Statins (eg, atorvastatin) are the first-line therapy for most patients with hypercholesterolemia and are useful in primary and secondary prevention of acute coronary events. Statins inhibit HMG-CoA reductase, the enzyme responsible for the rate-limiting step in synthesis of cholesterol. Statins lower total cholesterol, LDL, and triglyceride levels.

The primary side effects of statins include myopathy and hepatitis. **Statin-associated myopathy** is usually characterized by mild muscular pain

Statins (eg, atorvastatin) are the first-line therapy for most patients with hypercholesterolemia and are useful in primary and secondary prevention of acute coronary events. Statins inhibit HMG-CoA reductase, the enzyme responsible for the rate-limiting step in synthesis of cholesterol. Statins lower total cholesterol, LDL, and triglyceride levels.

The primary side effects of statins include myopathy and hepatitis. **Statin-associated myopathy** is usually characterized by mild muscular pain and resolves with discontinuation of the medication. However, some patients will develop severe myopathy with striking elevations in creatine kinase levels and occasional rhabdomyolysis. The risk of severe myopathy is increased when statins are given concurrently with fibrates (particularly **gemfibrozil**), which impair the hepatic clearance of statins and lead to excessive blood levels. An increased risk of statin myopathy is also likely with concurrent use of niacin or ezetimibe, but to a lesser extent **(Choice B)**.

(Choice A) Concurrent use of bile acid sequestrants (eg, cholestyramine) with statins does not increase the risk of myopathy. However, bile acid sequestrants can reduce the gastrointestinal absorption of statins.

(Choice D) Fibrates can increase drug levels of ezetimibe but this does not have a significant impact on its side effects, which are generally mild and not dose-related. Ezetimibe does not alter the pharmacokinetics of fibrates and does not substantially influence their adverse effects.

(Choices E and F) The primary adverse effects of niacin include flushing, hyperglycemia, and hepatotoxicity. There are no significant interactions with the concurrent use of niacin and ezetimibe or gemfibrozil.

Educational objective:
The primary side effects of statins include myopathy and hepatitis. Fibrates such as gemfibrozil can impair hepatic clearance of statins, increasing the risk of severe myopathy.

References

- Effect of gemfibrozil and fenofibrate on the pharmacokinetics of atorvastatin.

Pharmacology	Cardiovascular System	Drug induced myopathy
Subject	System	Topic

Copyright © UWorld. All rights reserved.

1
2
3
4
5
6
7
8
9
10
11
12
13
14
15
16
17
18
19
20
21
22
23
24
25
26
27
28
29
30
31

A 62-year-old man who underwent mitral valve replacement 1 month ago is being evaluated in the emergency department for low-grade fevers. He has some malaise and dyspnea. Multiple sets of blood cultures are drawn and, within hours, all bottles grow gram-positive cocci in clusters that are catalase-positive and coagulase-negative. The decision is made to begin empiric antibiotic therapy. Initial empiric treatment should include which of the following antibiotics?

A. Ceftriaxone
B. Ciprofloxacin
C. Clindamycin
D. Nafcillin
E. Penicillin G
F. Vancomycin

Submit

A 62-year-old man who underwent mitral valve replacement 1 month ago is being evaluated in the emergency department for low-grade fevers. He has some malaise and dyspnea. Multiple sets of blood cultures are drawn and, within hours, all bottles grow gram-positive cocci in clusters that are catalase-positive and coagulase-negative. The decision is made to begin empiric antibiotic therapy. Initial empiric treatment should include which of the following antibiotics?

- A. Ceftriaxone (10%)
- B. Ciprofloxacin (2%)
- C. Clindamycin (2%)
- D. Nafcillin (19%)
- E. Penicillin G (18%)
- ✓ F. Vancomycin (46%)

Omitted
Correct answer
F

46%
Answered correctly

02 secs
Time Spent

02/07/2020
Last Updated

Explanation

This patient who was recently hospitalized for mitral valve replacement now has fevers and bacteremia with catalase-positive, coagulase-negative, gram-positive cocci in clusters. This is consistent with infection due to **coagulase-negative staphylococci** (CoNS). These organisms produce a polysaccharide **slime** facilitating prosthetic device adherence. As a result, CoNS are a major cause of infection in patients with indwelling catheters or implanted foreign bodies (eg, peritoneal dialysis catheters, vascular grafts) and a common cause of prosthetic valve endocarditis (PVE). For example, *Staphylococcus epidermidis* (a type of CoNS) can cause an indolent endocarditis following valve replacement; if left

Explanation

This patient who was recently hospitalized for mitral valve replacement now has fevers and bacteremia with catalase-positive, coagulase-negative, gram-positive cocci in clusters. This is consistent with infection due to **coagulase-negative staphylococci** (CoNS). These organisms produce a polysaccharide **slime** facilitating prosthetic device adherence. As a result, CoNS are a major cause of infection in patients with indwelling catheters or implanted foreign bodies (eg, peritoneal dialysis catheters, vascular grafts) and a common cause of prosthetic valve endocarditis (PVE). For example, *Staphylococcus epidermidis* (a type of CoNS) can cause an indolent endocarditis following valve replacement; if left untreated, it can lead to intracardiac abscess, prosthetic valve dehiscence, and septic embolization. As CoNS are a component of normal skin flora, it may be difficult initially to distinguish blood culture contamination from true infection; however, recovery of the same organism from several blood culture bottles indicates infection.

Most (>80%) CoNS strains are methicillin-resistant. Therefore, particularly with nosocomial infection (as is likely in this patient), CoNS should be assumed to be **methicillin-resistant** until proven otherwise. **Vancomycin** should be a component of initial therapy. Additional antimicrobial agents (eg, gentamicin and/or rifampin, which kills bacteria on foreign material) are administered in some cases of deep-seated methicillin-resistant CoNS infection or staphylococcal PVE. If susceptibility results later demonstrate a methicillin-susceptible isolate, vancomycin can be switched to a semi-synthetic β-lactamase-resistant penicillin such as nafcillin or oxacillin. Native valve endocarditis due to methicillin-sensitive staphylococci is best treated with nafcillin or oxacillin **(Choice D)**. Very few strains of *S epidermidis* are susceptible to penicillin G **(Choice E)**.

(Choice A) A methicillin-resistant strain of *S epidermidis* will likely be cephalosporin-resistant, as the mechanism of methicillin resistance (*mecA* chromosomal gene) involves alterations in the penicillin-binding protein PBP 2a, which is used by both penicillins and cephalosporins.

(Choice B) Ciprofloxacin is a fluoroquinolone antibiotic. Ciprofloxacin resistance appears to accompany methicillin resistance in staphylococci due to the simultaneous presence of multiple antibiotic resistance genes.

(Choice C) Although clindamycin can be used for the treatment of certain infections caused by oxacillin-resistant *Staphylococcus*, it is not appropriate initial therapy for CoNS bacteremia. Inducible clindamycin resistance exists in some *S aureus* strains, resulting in treatment failure.

Educational objective:
Initial empiric treatment of coagulase-negative staphylococcal infection should include vancomycin due to widespread methicillin resistance, especially in nosocomial infections. If susceptibility results indicate a methicillin-susceptible isolate, vancomycin can be switched to nafcillin or oxacillin.

1 2 3 4 5 6 7 8 9 10 11 12 13 14 15 16 17 18 19 20 21 22 23 24 25 26 27 28 29 30 31

flora, it may be difficult initially to distinguish blood culture contamination from true infection; however, recovery of the same organism from several blood culture bottles indicates infection.

Most (>80%) CoNS strains are methicillin-resistant. Therefore, particularly with nosocomial infection (as is likely in this patient), CoNS should be assumed to be **methicillin-resistant** until proven otherwise. **Vancomycin** should be a component of initial therapy. Additional antimicrobial agents (eg, gentamicin and/or rifampin, which kills bacteria on foreign material) are administered in some cases of deep-seated methicillin-resistant CoNS infection or staphylococcal PVE. If susceptibility results later demonstrate a methicillin-susceptible isolate, vancomycin can be switched to a semi-synthetic β-lactamase-resistant penicillin such as nafcillin or oxacillin. Native valve endocarditis due to methicillin-sensitive staphylococci is best treated with nafcillin or oxacillin **(Choice D)**. Very few strains of *S epidermidis* are susceptible to penicillin G **(Choice E)**.

(Choice A) A methicillin-resistant strain of *S epidermidis* will likely be cephalosporin-resistant, as the mechanism of methicillin resistance (*mecA* chromosomal gene) involves alterations in the penicillin-binding protein PBP 2a, which is used by both penicillins and cephalosporins.

(Choice B) Ciprofloxacin is a fluoroquinolone antibiotic. Ciprofloxacin resistance appears to accompany methicillin resistance in staphylococci due to the simultaneous presence of multiple antibiotic resistance genes.

(Choice C) Although clindamycin can be used for the treatment of certain infections caused by oxacillin-resistant *Staphylococcus*, it is not appropriate initial therapy for CoNS bacteremia. Inducible clindamycin resistance exists in some *S aureus* strains, resulting in treatment failure.

Educational objective:
Initial empiric treatment of coagulase-negative staphylococcal infection should include vancomycin due to widespread methicillin resistance, especially in nosocomial infections. If susceptibility results indicate a methicillin-susceptible isolate, vancomycin can be switched to nafcillin or oxacillin.

References

- Infective endocarditis: diagnosis, antimicrobial therapy, and management of complications: a statement for healthcare professionals from the Committee on Rheumatic Fever, Endocarditis, and Kawasaki Disease, Council on Cardiovascular Disease in the Young, and the Councils on Clinical Cardiology, Stroke, and Cardiovascular Surgery and Anesthesia, American Heart Association: endorsed by the Infectious Diseases Society of America.

Pharmacology	Cardiovascular System	Endocarditis
Subject	System	Topic

1
2
3
4
5
6
7
8
9
10
11
12
13
14
15
16
17
18
19
20
21
22
23
24
25
26
27
28
29
30
31

A 45-year-old man comes to the hospital with acute onset of severe chest pain and diaphoresis. The patient describes the pain as "squeezing," different from any discomfort he has ever had. He has a past medical history of hypertension, and his father underwent coronary artery bypass grafting at age 50. The patient is diagnosed with acute ST-elevation myocardial infarction and undergoes an urgent coronary intervention with stent placement into the right coronary artery. He is also started on high-intensity atorvastatin therapy, along with antiplatelet therapy and appropriate medications to control blood pressure. Four weeks later, the patient's total cholesterol level is 140 mg/dL, down from 200 mg/dL before discharge. Which of the following has most likely increased as the result of the therapy?

A. ApoB-100 concentration

B. Biliary excretion of cholesterol

C. LDL receptor density

D. Plasma free fatty acids

E. VLDL concentration

Submit

A 45-year-old man comes to the hospital with acute onset of severe chest pain and diaphoresis. The patient describes the pain as "squeezing," different from any discomfort he has ever had. He has a past medical history of hypertension, and his father underwent coronary artery bypass grafting at age 50. The patient is diagnosed with acute ST-elevation myocardial infarction and undergoes an urgent coronary intervention with stent placement into the right coronary artery. He is also started on high-intensity atorvastatin therapy, along with antiplatelet therapy and appropriate medications to control blood pressure. Four weeks later, the patient's total cholesterol level is 140 mg/dL, down from 200 mg/dL before discharge. Which of the following has most likely increased as the result of the therapy?

- A. ApoB-100 concentration (8%)
- B. Biliary excretion of cholesterol (8%)
- ✓ C. LDL receptor density (74%)
- D. Plasma free fatty acids (5%)
- E. VLDL concentration (3%)

Omitted
Correct answer
C

74%
Answered correctly

02 secs
Time Spent

05/03/2020
Last Updated

Explanation

HMG-CoA reductase inhibitors (**statins**) inhibit the rate-limiting enzyme in hepatic cholesterol synthesis. In response to these changes, hepatocytes increase their surface expression of the **LDL receptor** to increase uptake of circulating LDL. Treatment generally produces a 20%-50% reduction in serum cholesterol and LDL concentration.

1
2
3
4
5
6
7
8
9
10
11
12
13
14
15
16
17
18
19
20
21
22
23
24
25
26
27
28
29
30
31

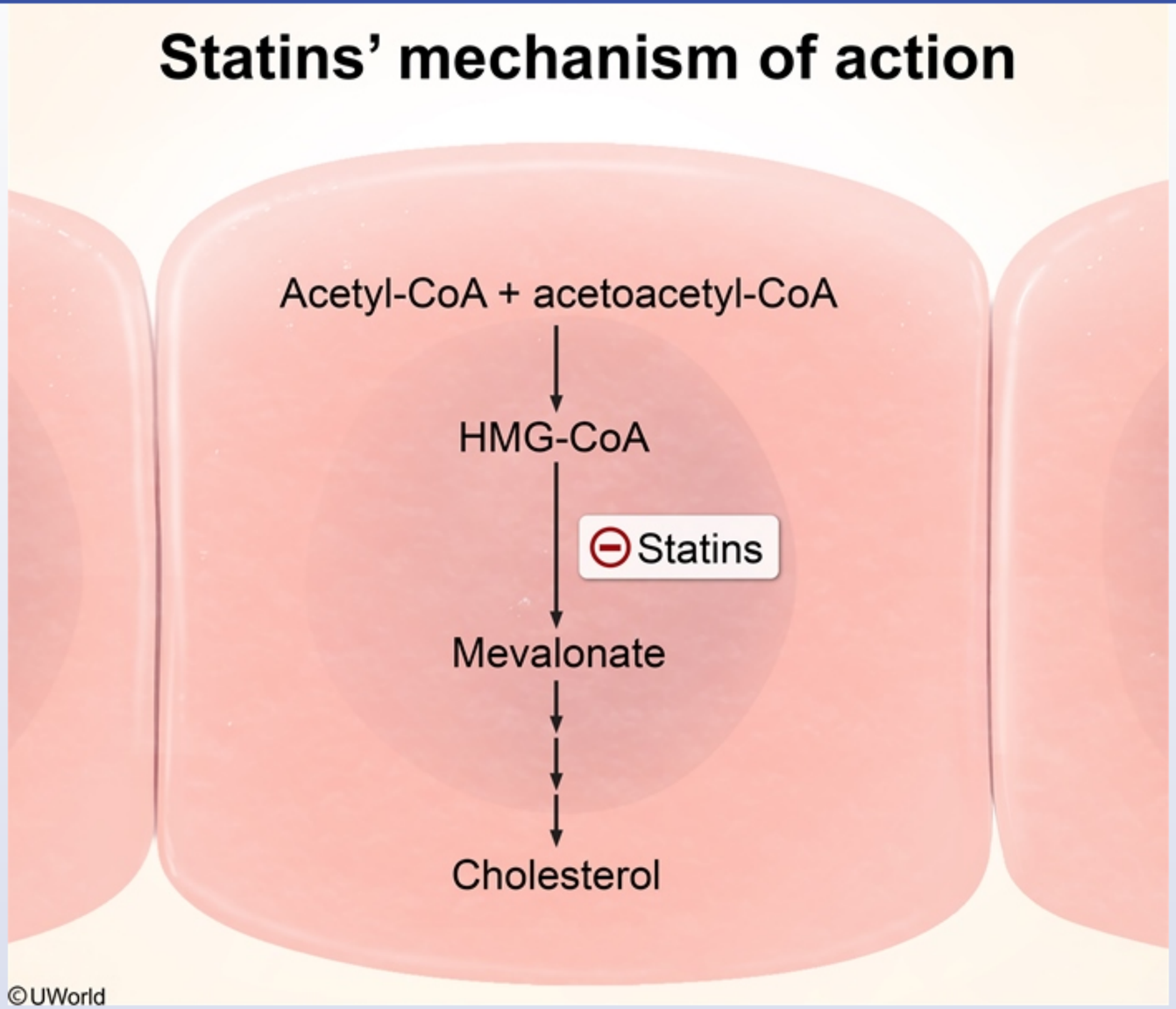

HMG-CoA reductase inhibitors (**statins**) inhibit the rate-limiting enzyme in hepatic cholesterol synthesis. In response to these changes,

1
2
3
4
5
6
7
8
9
10
11
12
13
14
15
16
17
18
19
20
21
22
23
24
25
26
27
28
29
30
31

HMG-CoA reductase inhibitors (**statins**) inhibit the rate-limiting enzyme in hepatic cholesterol synthesis. In response to these changes, hepatocytes increase their surface expression of the **LDL receptor** to increase uptake of circulating LDL. Treatment generally produces a 20%-50% reduction in serum cholesterol and LDL concentration.

High-intensity statin therapy reduces the risk of **acute coronary events**. This risk reduction is greater than that seen with other classes of lipid-lowering medications and is likely due to additional properties of statins. Besides effects on lipids, statins have anti-inflammatory properties, improve endothelial dysfunction, and appear to stabilize atherosclerotic plaques.

(Choice A) ApoB-100 is an apoprotein present in VLDL and LDL. Decreases in circulating LDL and VLDL will cause the ApoB-100 concentration to decrease as well.

(Choice B) The biliary excretion of cholesterol decreases in patients on statins due to decreased de novo hepatic synthesis of cholesterol.

(Choice D) Statins lower serum triglycerides modestly and have only a minimal effect on plasma free fatty acid concentrations.

(Choice E) Statins produce small decreases in VLDL. Fibrates and nicotinic acid therapy decrease hepatic production of VLDL and are the mainstay of treatment for primary hypertriglyceridemia (increased VLDL).

Educational objective:
Treatment with statins causes hepatocytes to increase their LDL receptor density, leading to increased uptake of circulating LDL.

References

- Statins: a new insight into their mechanisms of action and consequent pleiotropic effects.

Pharmacology	Cardiovascular System	Dyslipidemia
Subject	System	Topic

Copyright © UWorld. All rights reserved.

1
2
3
4
5
6
7
8
9
10
11
12
13
14
15
16
17
18
19
20
21
22
23
24
25
26
27
28
29
30
31

A 44-year-old man reports exertional shortness of breath and palpitations. On examination, he has a systolic murmur at the left sternal border and cardiac apex, which gets louder when he stands up. He is diagnosed with obstructive hypertrophic cardiomyopathy and paroxysmal atrial fibrillation, and is started on a medication. Changes in the action potential of ventricular muscle cells before and after administration of medication are shown in the image below

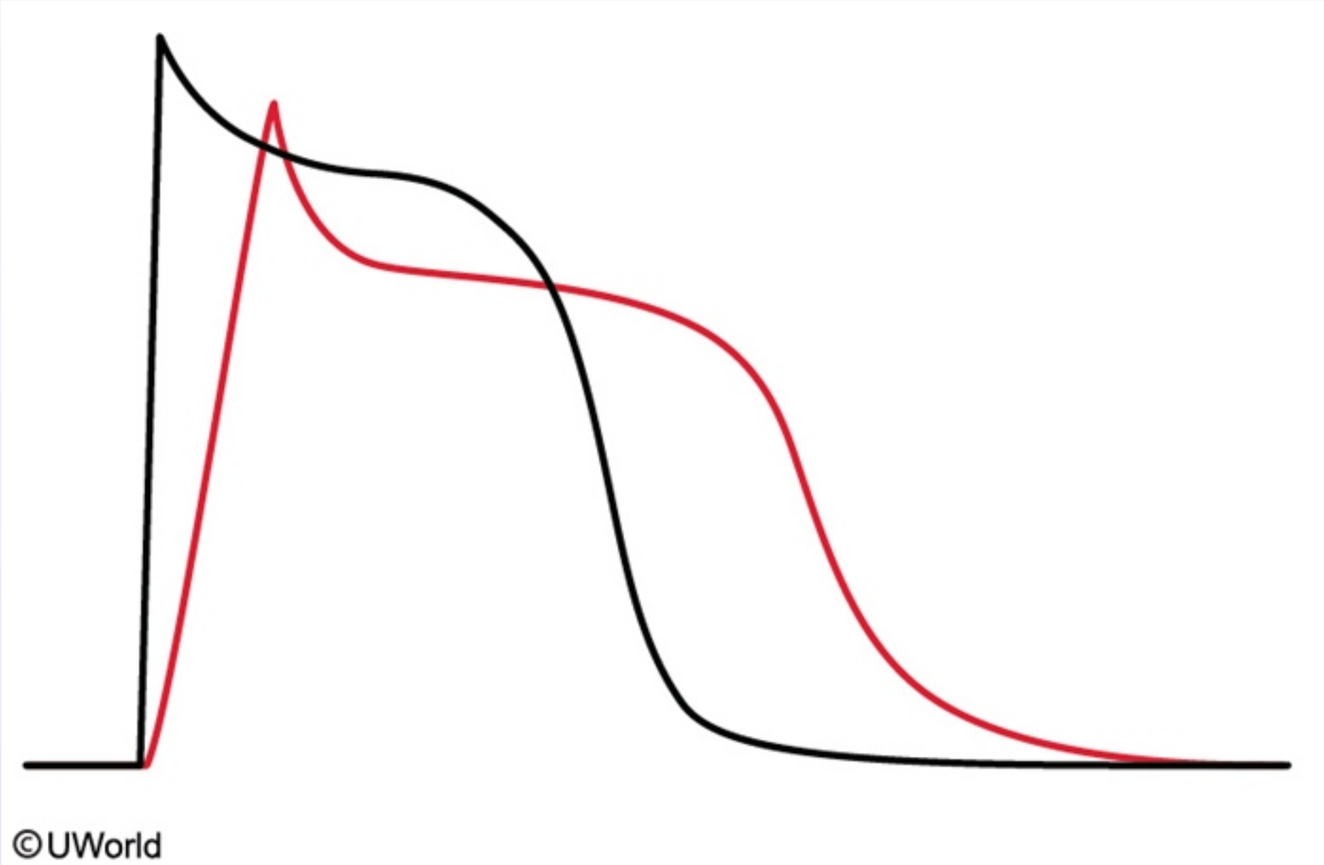

Black curve = Before administration of medication
Red curve = After administration of medication

1
2
3
4
5
6
7
8
9
10
11
12
13
14
15
16
17
18
19
20
21
22
23
24
25
26
27
28
29
30
31

Black curve = Before administration of medication
Red curve = After administration of medication

The patient is most likely being treated with which of the following medications?

- A. Adenosine
- B. Digoxin
- C. Diltiazem
- D. Disopyramide
- E. Flecainide
- F. Lidocaine
- G. Propranolol

Submit

1
2
3
4
5
6
7
8
9
10
11
12
13
14
15
16
17
18
19
20
21
22
23
24
25
26
27
28
29
30
31

Black curve = Before administration of medication
Red curve = After administration of medication

The patient is most likely being treated with which of the following medications?

- A. Adenosine (3%)
- B. Digoxin (5%)
- C. Diltiazem (6%)
- ✓ D. Disopyramide (55%)
- E. Flecainide (15%)
- F. Lidocaine (10%)
- G. Propranolol (3%)

Omitted
Correct answer

55%
Answered correctly

05 secs
Time Spent

03/08/2020
Last Updated

Class I (sodium channel-blocking) antiarrhythmics			
	Specific agents	**Inhibition of phase 0 depolarization**	**Effect on length of action potential**
Class IA	Quinidine, procainamide, disopyramide	Intermediate	Prolonged
Class IB	Lidocaine, mexiletine	Weak	Shortened
Class IC	Flecainide, propafenone	Strong	No change

©UWorld

The illustration shows predominant slowing of phase 0 depolarization and prolongation of phase 3 repolarization (red curve) of ventricular action potential after administration of the drug. This action is usually seen with the use of class IA antiarrhythmics drugs (quinidine, procainamide, and disopyramide).

Class I antiarrhythmic drugs block **sodium channels** and inhibit initial phase 0 depolarization of action potential, thereby slowing conduction. Class IA agents also have moderate potassium channel-blocking activity, leading to a slow rate of repolarization and prolongation of action potential duration in the cardiac myocytes.

(Choice A) Adenosine activates potassium channels and increases potassium conductance by interacting with A1 receptors on the surface of cardiac cells. This causes membrane hyperpolarization, resulting in transient slowing of the sinus rate and an increase in atrioventricular (AV) nodal conduction delay. Adenosine does not modulate the ventricular myocyte action potential.

©UWorld

The illustration shows predominant slowing of phase 0 depolarization and prolongation of phase 3 repolarization (red curve) of ventricular action potential after administration of the drug. This action is usually seen with the use of class IA antiarrhythmics drugs (quinidine, procainamide, and disopyramide).

Class I antiarrhythmic drugs block **sodium channels** and inhibit initial phase 0 depolarization of action potential, thereby slowing conduction. Class IA agents also have moderate potassium channel-blocking activity, leading to a slow rate of repolarization and prolongation of action potential duration in the cardiac myocytes.

(Choice A) Adenosine activates potassium channels and increases potassium conductance by interacting with A1 receptors on the surface of cardiac cells. This causes membrane hyperpolarization, resulting in transient slowing of the sinus rate and an increase in atrioventricular (AV) nodal conduction delay. Adenosine does not modulate the ventricular myocyte action potential.

(Choice B) Digoxin exerts its antiarrhythmic effects by increasing vagal output to the AV node and conduction system, thereby slowing conduction in these tissues. It does not alter the ventricular myocyte action potential, but it does increase intracellular calcium in ventricular myocytes, leading to increased cardiac contractility.

(Choice C) Calcium channel blockers are class IV antiarrhythmic drugs (eg, verapamil, diltiazem) that inhibit L-type calcium channels, slowing depolarization in the sinoatrial and AV nodes and decreasing calcium entry into cardiomyocytes. Calcium channel blockers slow the sinus rate, prolong AV node conduction, and depress myocardial contractility.

(Choice E) Flecainide is a class IC antiarrhythmic that strongly blocks sodium channels. It exhibits a slow rate of receptor dissociation that makes it more effective at higher rates of depolarization (use dependence). Class IC drugs slow phase 0 depolarization but do not affect action potential duration.

(Choice F) Lidocaine is a class IB antiarrhythmic drug that has weak sodium channel-blocking activity at rest; however, it is quite effective in blocking sodium channels in depolarized cardiac myocytes. Class IB drugs also shorten phase 3 repolarization (blockade of "plateau" Na+ current), thereby decreasing action potential duration.

(Choice G) Propranolol is a beta-adrenergic blocking agent that slows conduction through the AV node and prolongs phase 4 depolarization in cardiac pacemaker cells. Beta blockers do not affect ventricular myocyte action potential; their primary site of action is on the AV node and cells

1
2
3
4
5
6
7
8
9
10
11
12
13
14
15
16
17
18
19
20
21
22
23
24
25
26
27
28
29
30
31

©UWorld

Exhibit Display

SA node action potential

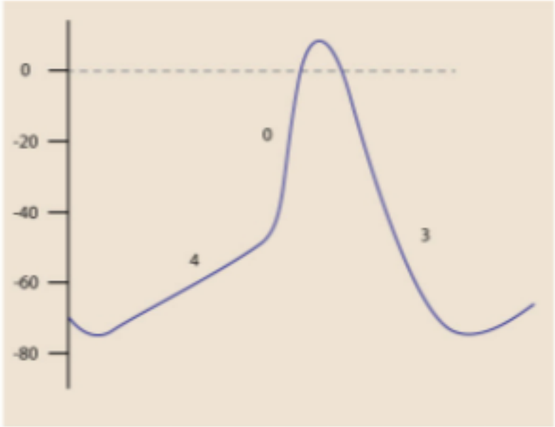

Ventricular muscle action potential

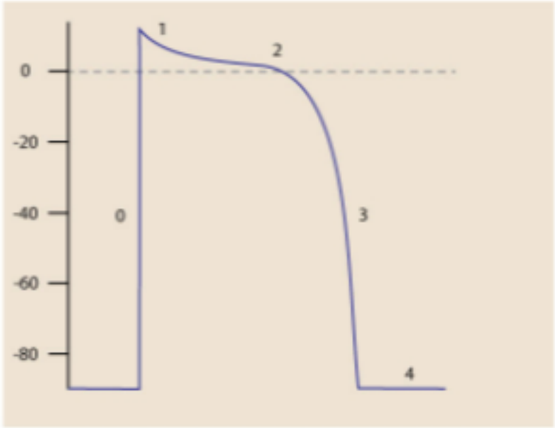

©UWorld

Zoom In | Zoom Out | Reset | Add To New Card | Existing Card

cardiac pacemaker cells. Beta blockers do not affect ventricular myocyte action potential; their primary site of action is on the AV node and cells

nodal conduction delay. Adenosine does not modulate the ventricular myocyte action potential.

(Choice B) Digoxin exerts its antiarrhythmic effects by increasing vagal output to the AV node and conduction system, thereby slowing conduction in these tissues. It does not alter the ventricular myocyte action potential, but it does increase intracellular calcium in ventricular myocytes, leading to increased cardiac contractility.

(Choice C) Calcium channel blockers are class IV antiarrhythmic drugs (eg, verapamil, diltiazem) that inhibit L-type calcium channels, slowing depolarization in the sinoatrial and AV nodes and decreasing calcium entry into cardiomyocytes. Calcium channel blockers slow the sinus rate, prolong AV node conduction, and depress myocardial contractility.

(Choice E) Flecainide is a class IC antiarrhythmic that strongly blocks sodium channels. It exhibits a slow rate of receptor dissociation that makes it more effective at higher rates of depolarization (use dependence). Class IC drugs slow phase 0 depolarization but do not affect action potential duration.

(Choice F) Lidocaine is a class IB antiarrhythmic drug that has weak sodium channel-blocking activity at rest; however, it is quite effective in blocking sodium channels in depolarized cardiac myocytes. Class IB drugs also shorten phase 3 repolarization (blockade of "plateau" Na+ current), thereby decreasing action potential duration.

(Choice G) Propranolol is a beta-adrenergic blocking agent that slows conduction through the AV node and prolongs phase 4 depolarization in cardiac pacemaker cells. Beta blockers do not affect ventricular myocyte action potential; their primary site of action is on the AV node and cells with automaticity.

Educational objective:
The class IA antiarrhythmics (quinidine, procainamide, and disopyramide) are sodium channel-blocking agents that depress phase 0 depolarization. They also prolong repolarization due to moderate potassium channel- blocking activity, increasing action potential duration in cardiac myocytes.

Pharmacology	Cardiovascular System	Antiarrhythmic drugs
Subject	System	Topic

Copyright © UWorld. All rights reserved.

nodal conduction delay. Adenosine does not modulate the ventricular myocyte action potential.

Exhibit Display

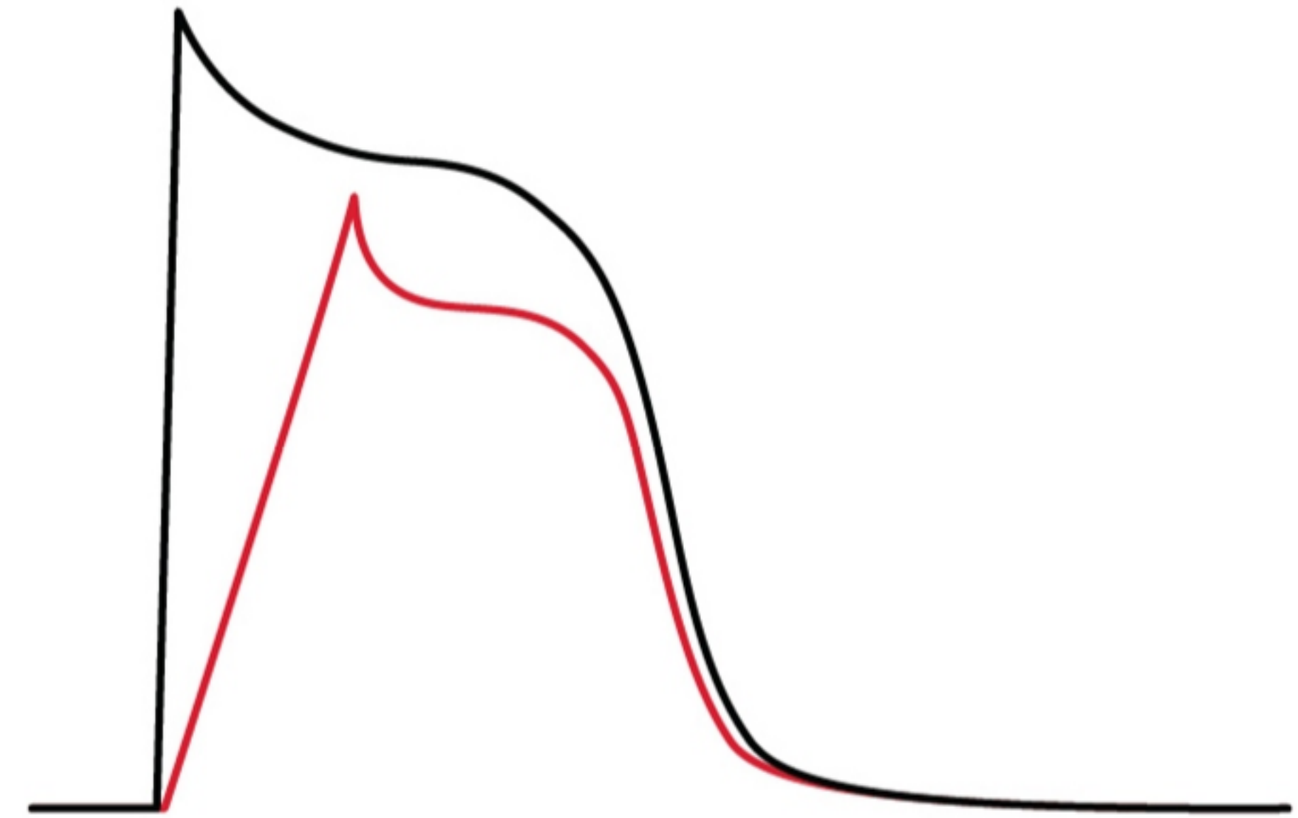

Zoom In | Zoom Out | Reset | Add To New Card | Existing Card

nodal conduction delay. Adenosine does not modulate the ventricular myocyte action potential.

Exhibit Display

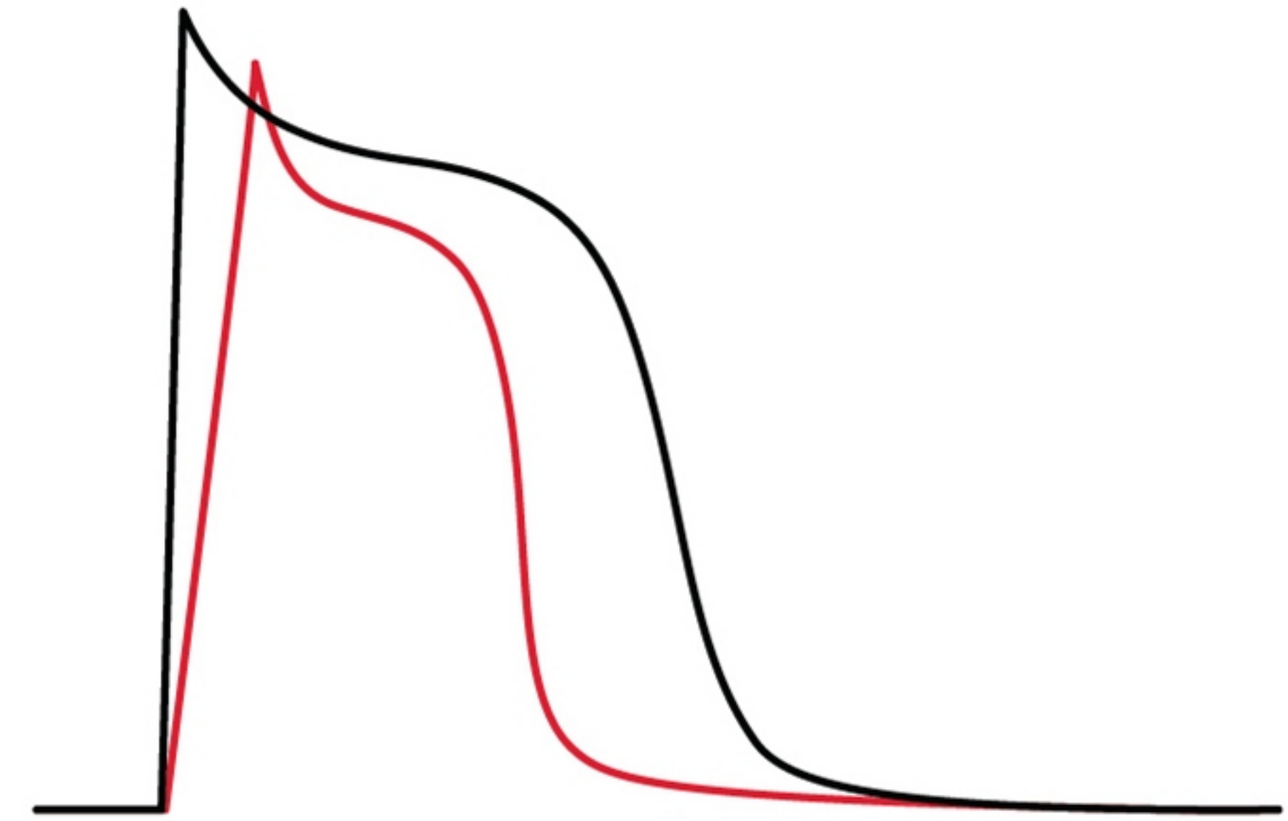

Zoom In | Zoom Out | Reset | Add To New Card | Existing Card

1
2
3
4
5
6
7
8
9
10
11
12
13
14
15
16
17
18
19
20
21
22
23
24
25
26
27
28
29
30
31

A 43-year-old woman comes to the office due to occasional chest discomfort over the past year. She describes the pain as a midline pressure or squeezing sensation that lasts 10-15 minutes and is sometimes accompanied by sweating. The patient has no history of hypertension or diabetes mellitus but is a smoker. Ambulatory ECG monitoring shows transient ST-segment elevations in the anteroseptal leads during an episode of chest pain at night. Coronary angiography reveals no atherosclerotic stenosis, but the administration of acetylcholine elicits similar chest pain and ECG changes. Which of the following best explains the coronary intervention findings in this patient?

A. Decreased systemic resistance
B. Endothelial dysfunction
C. Increased venous return
D. Positive inotropic effect
E. Reflex tachycardia

Submit

A 43-year-old woman comes to the office due to occasional chest discomfort over the past year. She describes the pain as a midline pressure or squeezing sensation that lasts 10-15 minutes and is sometimes accompanied by sweating. The patient has no history of hypertension or diabetes mellitus but is a smoker. Ambulatory ECG monitoring shows transient ST-segment elevations in the anteroseptal leads during an episode of chest pain at night. Coronary angiography reveals no atherosclerotic stenosis, but the administration of acetylcholine elicits similar chest pain and ECG changes. Which of the following best explains the coronary intervention findings in this patient?

- A. Decreased systemic resistance (6%)
- ✓ B. Endothelial dysfunction (52%)
- C. Increased venous return (6%)
- D. Positive inotropic effect (15%)
- E. Reflex tachycardia (18%)

Omitted
Correct answer
B

52%
Answered correctly

02 secs
Time Spent

06/15/2020
Last Updated

Explanation

Vasospastic angina	
Pathogenesis	• Hyperreactivity of coronary smooth muscle due to endothelial dysfunction & autonomic imbalance
	• Young age (<50)

Vasospastic angina	
Pathogenesis	• Hyperreactivity of coronary smooth muscle due to endothelial dysfunction & autonomic imbalance

Clinical presentation	• Young age (<50)
	• Minimal CAD risk factors (other than smoking)
	• Recurrent chest discomfort
	  ◦ At rest or during sleep
	  ◦ Spontaneous resolution ≤15 min

Diagnosis	• ECG: ST-segment elevation during episode • Coronary angiography: no CAD
CAD = coronary artery disease.	

This patient with episodes of **recurrent chest discomfort** that spontaneously **resolve within 10-15 minutes** most likely has **vasospastic angina** (formerly called Prinzmetal angina). It results from coronary **endothelial dysfunction** and autonomic imbalance that lead to **intermittent coronary vasospasm** and **myocardial ischemia**. Affected patients are usually young (eg, age <50) and lack typical risk factors for coronary artery disease (CAD) (eg, hypertension, diabetes mellitus); however, **smoking** is a strong risk factor, likely because it contributes to endothelial dysfunction.

Symptoms of vasospastic angina are thought to be triggered by **excess vagal tone**, and they occur most commonly **at night** when vagal tone is at a peak. The diagnosis is made by ambulatory ECG demonstrating ST-segment elevation during an episode of chest discomfort and coronary angiography revealing an absence of obstructive atherosclerotic CAD. Because of the pathophysiology of the disorder, both **acetylcholine** and **ergot alkaloids** (eg, dihydroergotamine) provoke symptoms and may also aid in diagnosis, as follows:

- Acetylcholine normally stimulates endothelial muscarinic receptors to cause vasodilation via increased release of nitric oxide. However, a **deficiency of endothelial nitric oxide** in affected patients causes increased vagal tone to instead trigger **vasoconstriction** and precipitate vasospastic symptoms.

This patient with episodes of **recurrent chest discomfort** that spontaneously **resolve within 10-15 minutes** most likely has **vasospastic angina** (formerly called Prinzmetal angina). It results from coronary **endothelial dysfunction** and autonomic imbalance that lead to **intermittent coronary vasospasm** and **myocardial ischemia**. Affected patients are usually young (eg, age <50) and lack typical risk factors for coronary artery disease (CAD) (eg, hypertension, diabetes mellitus); however, **smoking** is a strong risk factor, likely because it contributes to endothelial dysfunction.

Symptoms of vasospastic angina are thought to be triggered by **excess vagal tone**, and they occur most commonly **at night** when vagal tone is at a peak. The diagnosis is made by ambulatory ECG demonstrating ST-segment elevation during an episode of chest discomfort and coronary angiography revealing an absence of obstructive atherosclerotic CAD. Because of the pathophysiology of the disorder, both **acetylcholine** and **ergot alkaloids** (eg, dihydroergotamine) provoke symptoms and may also aid in diagnosis, as follows:

- Acetylcholine normally stimulates endothelial muscarinic receptors to cause vasodilation via increased release of nitric oxide. However, a **deficiency of endothelial nitric oxide** in affected patients causes increased vagal tone to instead trigger **vasoconstriction** and precipitate vasospastic symptoms.
- Ergot alkaloids activate 5-HT_2 serotonergic receptors to cause vasoconstriction. Normally, the vasoconstriction is somewhat offset by endothelial release of vasodilatory prostaglandins, but this response is lacking in affected patients due to endothelial dysfunction.

(Choices A and C) Peripheral endothelial function is typically intact in patients with vasospastic angina. As a result, acetylcholine is expected to cause peripheral vasodilation, which decreases venous return (due to venodilation). Systemic vascular resistance is also decreased, which can lower systemic blood pressure and somewhat reduce coronary artery perfusion pressure. However, this is unlikely to cause myocardial ischemia in the absence of obstructive CAD.

(Choice D) Acetylcholine has a negative inotropic effect, reducing cardiac contractility and myocardial oxygen demand.

(Choice E) Increased heart rate can increase myocardial oxygen demand and may exacerbate angina symptoms in patients with obstructive CAD, but it is unlikely to cause myocardial ischemia in the absence of CAD. In addition, acetylcholine directly slows heart rate, counteracting any reflex tachycardia caused by peripheral vasodilation.

Educational objective:
Vasospastic angina is the result of intermittent coronary vasospasm caused by endothelial dysfunction and autonomic imbalance. Although acetylcholine normally stimulates vasodilation, it triggers coronary vasospasm in affected patients due to a deficiency of vasodilatory endothelial

Symptoms of vasospastic angina are thought to be triggered by **excess vagal tone**, and they occur most commonly **at night** when vagal tone is at a peak. The diagnosis is made by ambulatory ECG demonstrating ST-segment elevation during an episode of chest discomfort and coronary angiography revealing an absence of obstructive atherosclerotic CAD. Because of the pathophysiology of the disorder, both **acetylcholine** and **ergot alkaloids** (eg, dihydroergotamine) provoke symptoms and may also aid in diagnosis, as follows:

- Acetylcholine normally stimulates endothelial muscarinic receptors to cause vasodilation via increased release of nitric oxide. However, a **deficiency of endothelial nitric oxide** in affected patients causes increased vagal tone to instead trigger **vasoconstriction** and precipitate vasospastic symptoms.
- Ergot alkaloids activate 5-HT_2 serotonergic receptors to cause vasoconstriction. Normally, the vasoconstriction is somewhat offset by endothelial release of vasodilatory prostaglandins, but this response is lacking in affected patients due to endothelial dysfunction.

(Choices A and C) Peripheral endothelial function is typically intact in patients with vasospastic angina. As a result, acetylcholine is expected to cause peripheral vasodilation, which decreases venous return (due to venodilation). Systemic vascular resistance is also decreased, which can lower systemic blood pressure and somewhat reduce coronary artery perfusion pressure. However, this is unlikely to cause myocardial ischemia in the absence of obstructive CAD.

(Choice D) Acetylcholine has a negative inotropic effect, reducing cardiac contractility and myocardial oxygen demand.

(Choice E) Increased heart rate can increase myocardial oxygen demand and may exacerbate angina symptoms in patients with obstructive CAD, but it is unlikely to cause myocardial ischemia in the absence of CAD. In addition, acetylcholine directly slows heart rate, counteracting any reflex tachycardia caused by peripheral vasodilation.

Educational objective:
Vasospastic angina is the result of intermittent coronary vasospasm caused by endothelial dysfunction and autonomic imbalance. Although acetylcholine normally stimulates vasodilation, it triggers coronary vasospasm in affected patients due to a deficiency of vasodilatory endothelial nitric oxide.

References

- Provocative testing for coronary reactivity and spasm.

- Acetylcholine normally stimulates endothelial muscarinic receptors to cause vasodilation via increased release of nitric oxide. However, a **deficiency of endothelial nitric oxide** in affected patients causes increased vagal tone to instead trigger **vasoconstriction** and precipitate vasospastic symptoms.
- Ergot alkaloids activate 5-HT_2 serotonergic receptors to cause vasoconstriction. Normally, the vasoconstriction is somewhat offset by endothelial release of vasodilatory prostaglandins, but this response is lacking in affected patients due to endothelial dysfunction.

(Choices A and C) Peripheral endothelial function is typically intact in patients with vasospastic angina. As a result, acetylcholine is expected to cause peripheral vasodilation, which decreases venous return (due to venodilation). Systemic vascular resistance is also decreased, which can lower systemic blood pressure and somewhat reduce coronary artery perfusion pressure. However, this is unlikely to cause myocardial ischemia in the absence of obstructive CAD.

(Choice D) Acetylcholine has a negative inotropic effect, reducing cardiac contractility and myocardial oxygen demand.

(Choice E) Increased heart rate can increase myocardial oxygen demand and may exacerbate angina symptoms in patients with obstructive CAD, but it is unlikely to cause myocardial ischemia in the absence of CAD. In addition, acetylcholine directly slows heart rate, counteracting any reflex tachycardia caused by peripheral vasodilation.

Educational objective:
Vasospastic angina is the result of intermittent coronary vasospasm caused by endothelial dysfunction and autonomic imbalance. Although acetylcholine normally stimulates vasodilation, it triggers coronary vasospasm in affected patients due to a deficiency of vasodilatory endothelial nitric oxide.

References

- Provocative testing for coronary reactivity and spasm.

Pharmacology	Cardiovascular System	Vasospastic angina
Subject	System	Topic

Copyright © UWorld. All rights reserved.

1
2
3
4
5
6
7
8
9
10
11
12
13
14
15
16
17
18
19
20
21
22
23
24
25
26
27
28
29
30
31

A 34-year-old woman has recurrent throbbing headaches that occur several times a month and cause significant distress. They are accompanied by nausea and photophobia. She has had 5 emergency department visits for these headaches over the last 6 months. During office visits, her blood pressure ranges from 140/90 mm Hg to 150/95 mm Hg. Neurologic examination is unremarkable. The patient is prescribed metoprolol and is advised that the medication is expected to decrease the frequency of headaches and also lower blood pressure in the long term. Which of the following best explains this medication's effect on blood pressure?

A. Decreased level of circulating catecholamines

B. Decreased level of circulating renin

C. Increased atrioventricular nodal conduction rate

D. Increased renal sodium and water retention

E. Long-term increase in peripheral vascular resistance

Submit

1
2
3
4
5
6
7
8
9
10
11
12
13
14
15
16
17
18
19
20
21
22
23
24
25
26
27
28
29
30
31

A 34-year-old woman has recurrent throbbing headaches that occur several times a month and cause significant distress. They are accompanied by nausea and photophobia. She has had 5 emergency department visits for these headaches over the last 6 months. During office visits, her blood pressure ranges from 140/90 mm Hg to 150/95 mm Hg. Neurologic examination is unremarkable. The patient is prescribed metoprolol and is advised that the medication is expected to decrease the frequency of headaches and also lower blood pressure in the long term. Which of the following best explains this medication's effect on blood pressure?

- A. Decreased level of circulating catecholamines (14%)
- ✓ B. Decreased level of circulating renin (73%)
- C. Increased atrioventricular nodal conduction rate (6%)
- D. Increased renal sodium and water retention (1%)
- E. Long-term increase in peripheral vascular resistance (4%)

Omitted
Correct answer
B

73%
Answered correctly

02 secs
Time Spent

06/22/2020
Last Updated

Explanation

Renin-angiotensin-aldosterone system & antihypertensives

Angiotensinogen

1
2
3
4
5
6
7
8
9
10
11
12
13
14
15
16
17
18
19
20
21
22
23
24
25
26
27
28
29
30
31

Renin-angiotensin-aldosterone system & antihypertensives

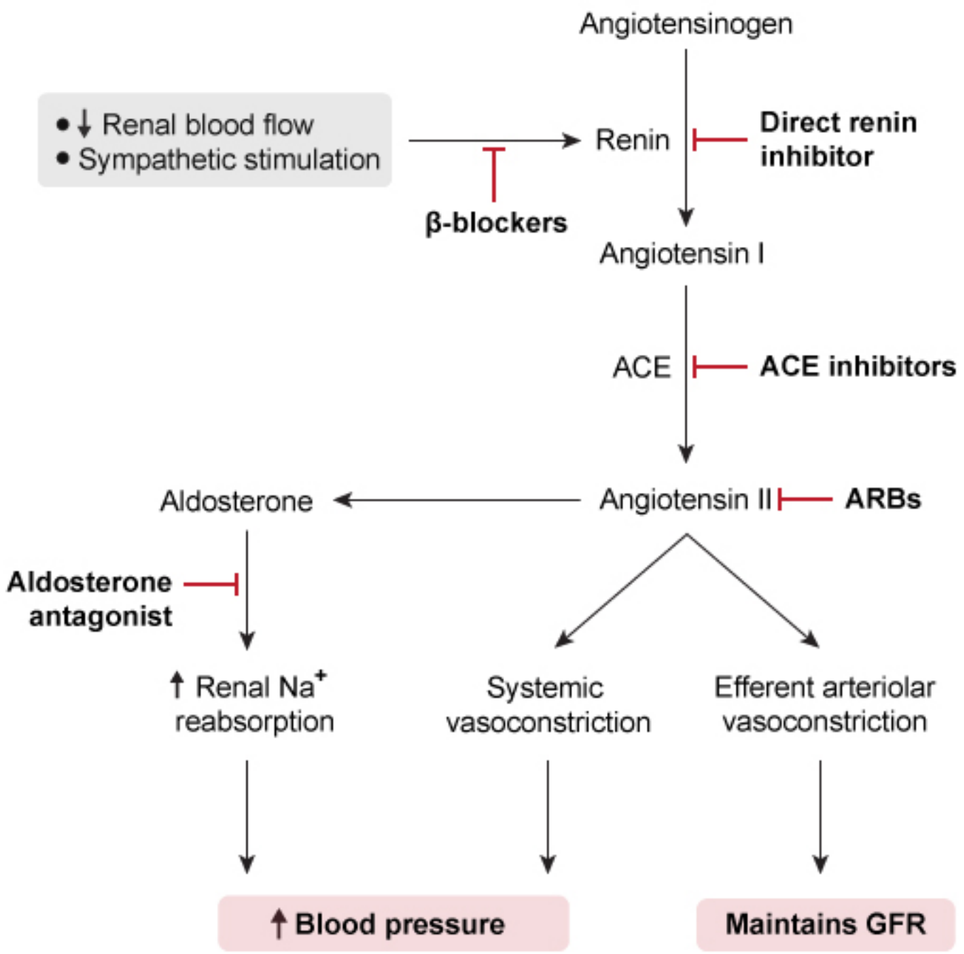

GFR = glomerular filtration rate.

©UWorld

©UWorld

Beta blockers are useful for treating hypertensive patients with comorbid conditions such as migraine, essential tremor, angina pectoris/prior myocardial infarction, and atrial fibrillation. Beta blockers lower blood pressure via 2 mechanisms:

1. Reducing myocardial contractility and heart rate
2. Decreasing renin release by the kidney

Renin release is mediated in part through sympathetic stimulation of beta-1 receptors located on juxtaglomerular cells. Therefore, beta-adrenergic blocking drugs (eg, metoprolol) act to **inhibit renin release**, which in turn reduces the conversion of angiotensinogen to angiotensin I and reduces the levels of angiotensin II (a potent vasoconstrictor) and aldosterone (decreasing renal sodium and water retention) **(Choice D)**.

(Choice A) Beta blockers block the action of endogenous catecholamines on adrenergic beta receptors but have no significant effect on circulating levels of catecholamine.

(Choice C) Beta-adrenergic receptor antagonists depress conduction through the atrioventricular (AV) node and can cause varying degrees of AV block.

(Choice E) Long-term use of beta blockers will cause either no change or modest decreases in the peripheral vascular resistance due to their effects on the renin-angiotensin-aldosterone system.

Educational objective:
Beta blockers inhibit release of renin from renal juxtaglomerular cells through antagonism of beta-1 receptors on these cells. Inhibition of renin release prevents activation of the renin-angiotensin-aldosterone pathway, which results in decreased vasoconstriction and decreased renal sodium and water retention.

References

- Beta-adrenergic receptor blockade as a therapeutic approach for suppressing the renin-angiotensin-aldosterone system in normotensive and hypertensive subjects.

Pharmacology	Cardiovascular System	Primary hypertension
Subject	System	Topic

A 60-year-old man who was recently diagnosed with hypertension comes to the office for follow-up. He was treated with lisinopril but stopped a week ago due to a dry, nagging cough. Past medical history is notable for type 2 diabetes mellitus with moderately increased albuminuria but normal creatinine clearance. His other medications include metformin and rosuvastatin. The patient does not smoke or drink alcohol. His blood pressure is 150/92 mm Hg. BMI is 31 kg/m^2. Physical examination, including the heart and lungs, is unremarkable. Which of the following is the best treatment for this patient's hypertension?

- A. Diltiazem
- B. Hydralazine
- C. Metoprolol
- D. Ramipril
- E. Valsartan

Submit

A 60-year-old man who was recently diagnosed with hypertension comes to the office for follow-up. He was treated with lisinopril but stopped a week ago due to a dry, nagging cough. Past medical history is notable for type 2 diabetes mellitus with moderately increased albuminuria but normal creatinine clearance. His other medications include metformin and rosuvastatin. The patient does not smoke or drink alcohol. His blood pressure is 150/92 mm Hg. BMI is 31 kg/m^2. Physical examination, including the heart and lungs, is unremarkable. Which of the following is the best treatment for this patient's hypertension?

- A. Diltiazem (2%)
- B. Hydralazine (3%)
- C. Metoprolol (5%)
- D. Ramipril (3%)
- ✓ E. Valsartan (85%)

Omitted
Correct answer
E

85%
Answered correctly

02 secs
Time Spent

03/30/2020
Last Updated

Explanation

Diabetes causes impaired autoregulation of glomerular blood flow, leading to significant elevations of intraglomerular pressures and chronic glomerular injury. Patients with diabetes and hypertension are at especially high long-term risk for chronic kidney disease. Angiotensin-converting enzyme (ACE) inhibitors (eg, lisinopril) cause preferential dilation of the glomerular efferent arteriole, lowering intraglomerular pressures and reducing the risk of chronic glomerular injury.

In addition to converting angiotensin I to angiotensin II, ACE normally degrades **bradykinin** and substance P. Inhibition of ACE leads to elevated

1
2
3
4
5
6
7
8
9
10
11
12
13
14
15
16
17
18
19
20
21
22
23
24
25
26
27
28
29
30
31

Explanation

Diabetes causes impaired autoregulation of glomerular blood flow, leading to significant elevations of intraglomerular pressures and chronic glomerular injury. Patients with diabetes and hypertension are at especially high long-term risk for chronic kidney disease. Angiotensin-converting enzyme (ACE) inhibitors (eg, lisinopril) cause preferential dilation of the glomerular efferent arteriole, lowering intraglomerular pressures and reducing the risk of chronic glomerular injury.

In addition to converting angiotensin I to angiotensin II, ACE normally degrades **bradykinin** and substance P. Inhibition of ACE leads to elevated bradykinin and substance P levels and a nonproductive cough. **Angiotensin receptor blockers** (ARBs) have hemodynamic effects similar to those of ACE inhibitors but do not affect bradykinin levels and do not cause a cough. Replacing this patient's ACE inhibitor with an ARB (eg, losartan, valsartan) will eliminate the cough while still providing the same long-term renovascular benefits.

(Choices A, B, and C) Careful blood pressure control can help reduce the long-term risk of kidney injury, regardless of the agent used. However, none of these drugs are as effective as ACE inhibitors or ARBs for preventing the progression of chronic kidney disease.

(Choice D) Replacement of one ACE inhibitor with another carries a high likelihood of inducing the same nonproductive cough.

Educational objective:
Angiotensin-converting enzyme (ACE) inhibitors and angiotensin receptor blockers (ARBs) reduce the risk of chronic kidney disease in patients with hypertension and diabetes. ACE inhibitors raise levels of bradykinin and can cause a nonproductive cough, an effect not seen with ARBs.

References

- The RAAS in the pathogenesis and treatment of diabetic nephropathy.
- Angiotensin-converting enzyme inhibitor-induced cough: ACCP evidence-based clinical practice guidelines.

Pharmacology	Cardiovascular System	ACE inhibitors
Subject	System	Topic

Copyright © UWorld. All rights reserved.

1
2
3
4
5
6
7
8
9
10
11
12
13
14
15
16
17
18
19
20
21
22
23
24
25
26
27
28
29
30
31

Exhibit Display

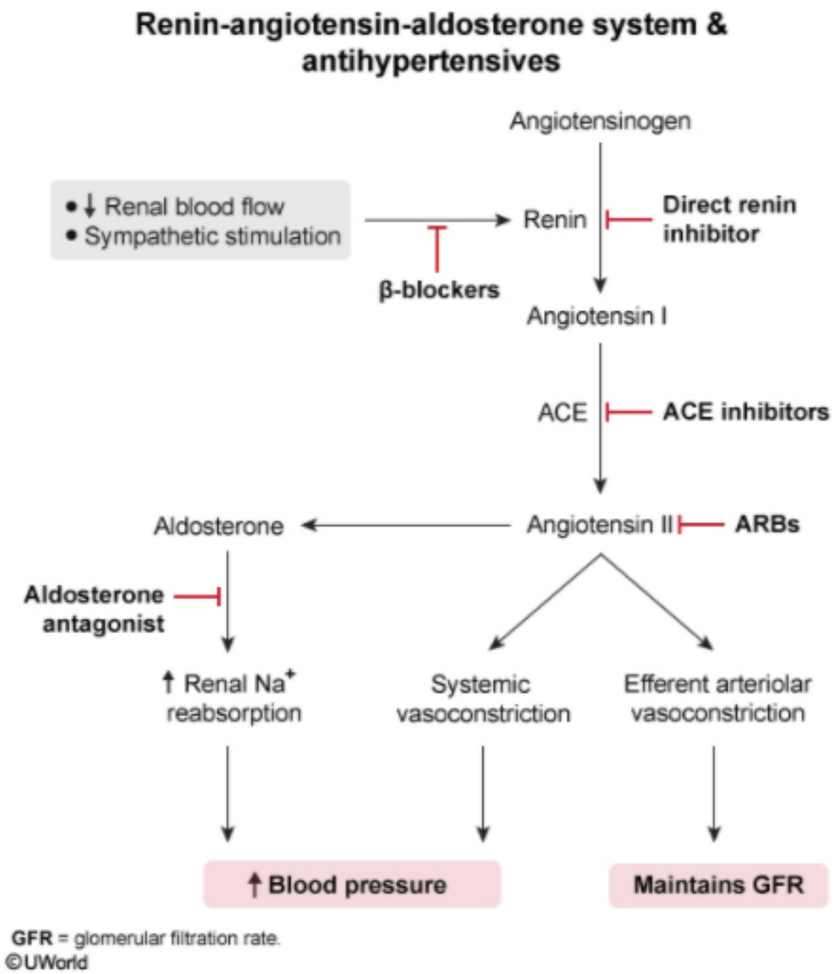

Zoom In | Zoom Out | Reset | Add To New Card | Existing Card

1
2
3
4
5
6
7
8
9
10
11
12
13
14
15
16
17
18
19
20
21
22
23
24
25
26
27
28
29
30
31

A 50-year-old man has recurrent episodes of paroxysmal atrial fibrillation accompanied by uncomfortable palpitations and chest pressure. Echocardiogram reveals normal biventricular function and no significant valvular disease. Coronary angiography reveals no obstructive coronary artery disease. The patient is started on medication to reduce his symptoms. Two weeks later, he is seen in the emergency department for lightheadedness, weakness, and presyncope. ECG reveals sinus bradycardia at a rate of 53/min with QTc prolongation (508 msec). Telemetry monitoring reveals a short episode of self-resolved torsades de pointes. Which of the following medications was most likely used to treat this patient's palpitations?

A. Diltiazem
B. Metoprolol
C. Mexiletine
D. Ranolazine
E. Sotalol

Submit

1
2
3
4
5
6
7
8
9
10
11
12
13
14
15
16
17
18
19
20
21
22
23
24
25
26
27
28
29
30
31

A 50-year-old man has recurrent episodes of paroxysmal atrial fibrillation accompanied by uncomfortable palpitations and chest pressure. Echocardiogram reveals normal biventricular function and no significant valvular disease. Coronary angiography reveals no obstructive coronary artery disease. The patient is started on medication to reduce his symptoms. Two weeks later, he is seen in the emergency department for lightheadedness, weakness, and presyncope. ECG reveals sinus bradycardia at a rate of 53/min with QTc prolongation (508 msec). Telemetry monitoring reveals a short episode of self-resolved torsades de pointes. Which of the following medications was most likely used to treat this patient's palpitations?

A. Diltiazem (12%)

B. Metoprolol (4%)

C. Mexiletine (7%)

D. Ranolazine (3%)

✓ E. Sotalol (71%)

Omitted
Correct answer
E

71%
Answered correctly

02 secs
Time Spent

03/08/2020
Last Updated

Explanation

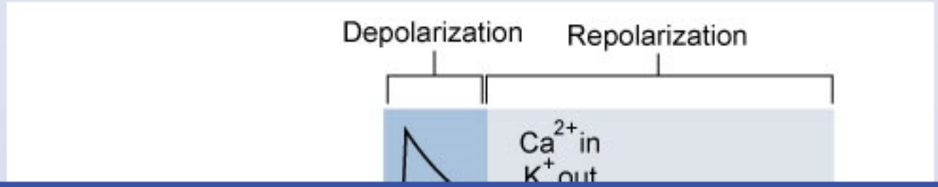

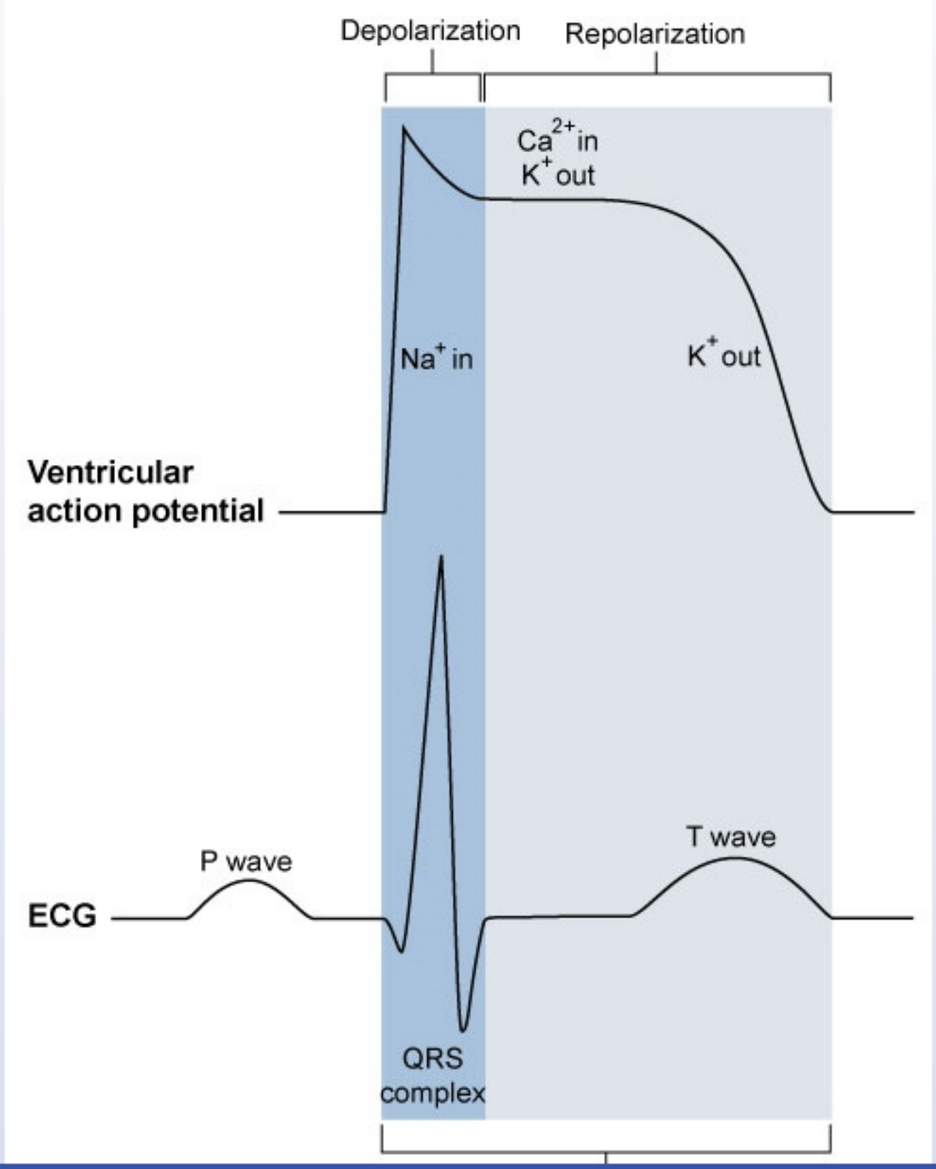
Depolarization
Repolarization
Ca^{2+} in
K^+ out
Na^+ in
K^+ out
Ventricular action potential
P wave
T wave
ECG
QRS complex

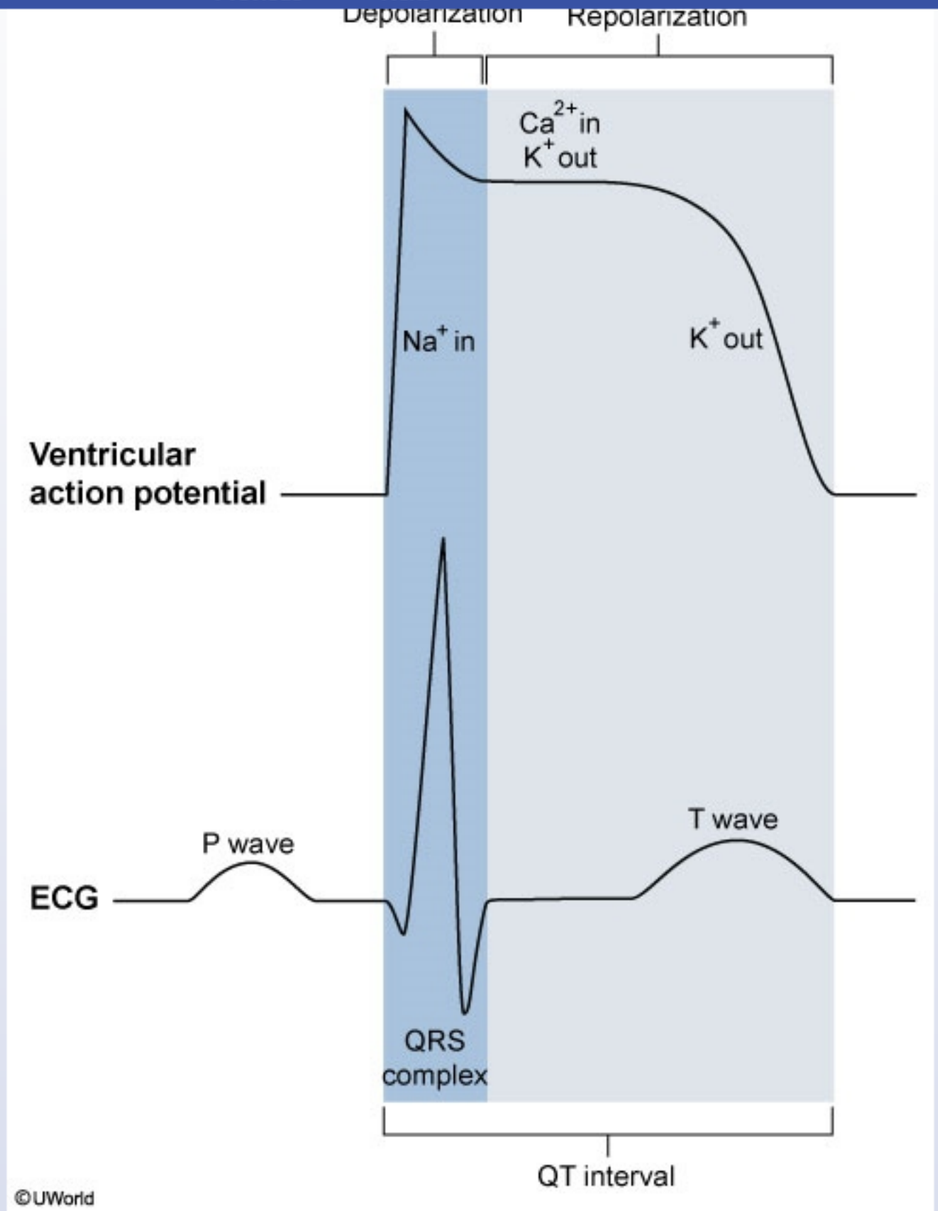
Depolarization
Repolarization
Ca^{2+} in
K^+ out
Na^+ in
K^+ out
Ventricular action potential
P wave
T wave
ECG
QRS complex
QT interval
©UWorld

1
2
3
4
5
6
7
8
9
10
11
12
13
14
15
16
17
18
19
20
21
22
23
24
25
26
27
28
29
30
31

Paroxysmal atrial fibrillation is usually treated with rate or rhythm control strategies. Rate control uses AV nodal-blocking drugs (beta blockers, calcium channel blockers) to prevent rapid ventricular response, whereas **rhythm control** attempts to maintain sinus rhythm with antiarrhythmic drugs (eg, sotalol, flecainide, amiodarone).

The QT interval represents both ventricular depolarization and repolarization (total duration of ventricular action potential). However, ventricular depolarization normally contributes only a small amount of time to the interval, and in practice, the QT interval is primarily used as a measure of ventricular repolarization. **Class III antiarrhythmics** (eg, sotalol, amiodarone, dofetilide) predominantly **block potassium channels** and inhibit outward repolarizing currents during phase 3 of the cardiomyocyte action potential. This leads to increased action potential duration and **QT interval prolongation**, which predisposes to the development of polymorphic ventricular tachycardia (**torsades de pointes** [TdP]). Amiodarone has a lesser proarrhythmic effect than other class III drugs; therefore, TdP is less frequently observed with amiodarone than with sotalol.

(Choice A) Diltiazem is a class IV antiarrhythmic drug (calcium channel blocker) that inhibits L-type calcium channels during phase 2 (cardiomyocyte action potential) and phase 0 (nodal action potential) depolarization. It slows the sinus rate, prolongs conduction through the AV node, and depresses myocardial contractility (negative inotropic effect) but does not prolong the QT interval.

(Choice B) Metoprolol is a class II antiarrhythmic drug that is a selective beta-1 receptor antagonist. It acts as a negative inotropic and chronotropic agent by decreasing myocardial contractility and heart rate. Unlike sotalol, beta blockers do not have any potassium channel-blocking properties and do not prolong the QT interval.

(Choice C) Mexiletine is a class IB antiarrhythmic drug that blocks sodium channels, inhibiting the initial depolarization phase (phase 0) of the cardiomyocyte action potential. It is occasionally used to maintain sinus rhythm in patients with paroxysmal symptomatic atrial fibrillation, but it does not prolong the QT interval.

(Choice D) Ranolazine is an antianginal agent and exerts its effect by inhibiting the late phase of inward sodium channels in ischemic cardiac myocytes. It also blocks potassium channels and causes a dose-dependent increase in QT interval; however, TdP has not been reported in ranolazine use.

Educational objective:
Sotalol has both beta adrenergic-blocking and class III antiarrhythmic (K+ channel-blocking) properties and is occasionally used in treatment of atrial fibrillation. Major side effects of sotalol include bradycardia, proarrhythmia, and most commonly torsades de pointes due to QT interval prolongation.

Paroxysmal atrial fibrillation is usually treated with rate or rhythm control strategies. Rate control uses AV nodal-blocking drugs (beta blockers,

Exhibit Display

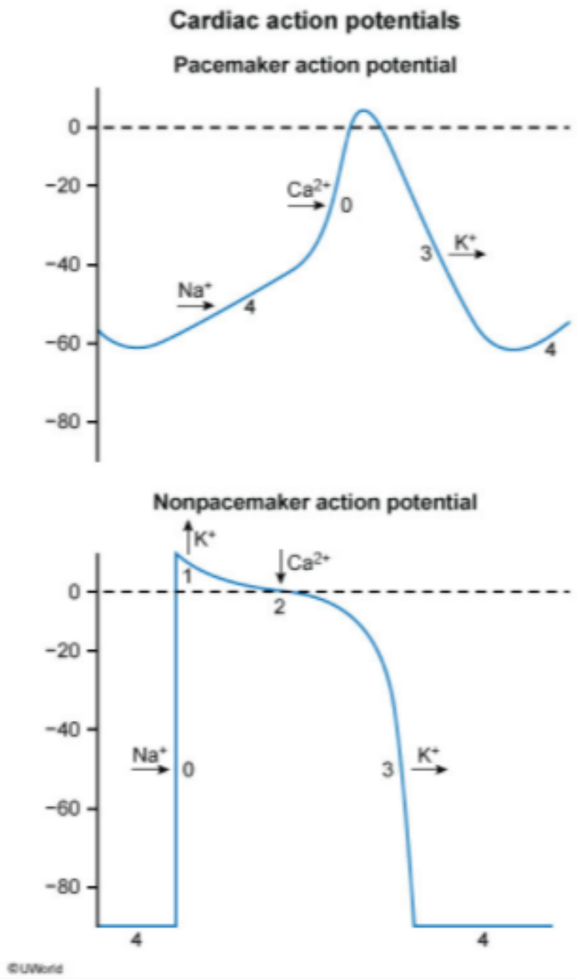

Zoom In | Zoom Out | Reset | Add To New Card | Existing Card

prolongation.

depolarization normally contributes only a small amount of time to the interval, and in practice, the QT interval is primarily used as a measure of ventricular repolarization. **Class III antiarrhythmics** (eg, sotalol, amiodarone, dofetilide) predominantly **block potassium channels** and inhibit outward repolarizing currents during phase 3 of the cardiomyocyte action potential. This leads to increased action potential duration and **QT interval prolongation**, which predisposes to the development of polymorphic ventricular tachycardia (**torsades de pointes** [TdP]). Amiodarone has a lesser proarrhythmic effect than other class III drugs; therefore, TdP is less frequently observed with amiodarone than with sotalol.

(Choice A) Diltiazem is a class IV antiarrhythmic drug (calcium channel blocker) that inhibits L-type calcium channels during phase 2 (cardiomyocyte action potential) and phase 0 (nodal action potential) depolarization. It slows the sinus rate, prolongs conduction through the AV node, and depresses myocardial contractility (negative inotropic effect) but does not prolong the QT interval.

(Choice B) Metoprolol is a class II antiarrhythmic drug that is a selective beta-1 receptor antagonist. It acts as a negative inotropic and chronotropic agent by decreasing myocardial contractility and heart rate. Unlike sotalol, beta blockers do not have any potassium channel-blocking properties and do not prolong the QT interval.

(Choice C) Mexiletine is a class IB antiarrhythmic drug that blocks sodium channels, inhibiting the initial depolarization phase (phase 0) of the cardiomyocyte action potential. It is occasionally used to maintain sinus rhythm in patients with paroxysmal symptomatic atrial fibrillation, but it does not prolong the QT interval.

(Choice D) Ranolazine is an antianginal agent and exerts its effect by inhibiting the late phase of inward sodium channels in ischemic cardiac myocytes. It also blocks potassium channels and causes a dose-dependent increase in QT interval; however, TdP has not been reported in ranolazine use.

Educational objective:
Sotalol has both beta adrenergic-blocking and class III antiarrhythmic (K+ channel-blocking) properties and is occasionally used in treatment of atrial fibrillation. Major side effects of sotalol include bradycardia, proarrhythmia, and most commonly torsades de pointes due to QT interval prolongation.

References

- Drug-induced arrhythmia: pharmacogenomic prescribing?

Pharmacology	Cardiovascular System	Antiarrhythmic drugs
Subject	System	Topic

1
2
3
4
5
6
7
8
9
10
11
12
13
14
15
16
17
18
19
20
21
22
23
24
25
26
27
28
29
30
31

A 68-year-old man comes to the emergency department due to lightheadedness, generalized weakness, and palpitations. The patient has a prolonged history of hypertension and takes amlodipine. He does not use tobacco or alcohol. His blood pressure is 110/60 mm Hg and pulse is 144/min and irregular. ECG shows an irregularly irregular rhythm and absent P waves. The patient is started on beta blocker therapy for rate control, with improvement in his heart rate. Long-term anticoagulation is initiated to prevent atrial thrombus formation, and he is eventually discharged home on warfarin. Which of the following is the best test to monitor the anticoagulation effect of warfarin in this patient?

A. Activated partial thromboplastin time

B. Bleeding time

C. Fibrin split products

D. Fibrinogen levels

E. Prothrombin time

Submit

1
2
3
4
5
6
7
8
9
10
11
12
13
14
15
16
17
18
19
20
21
22
23
24
25
26
27
28
29
30
31

A 68-year-old man comes to the emergency department due to lightheadedness, generalized weakness, and palpitations. The patient has a prolonged history of hypertension and takes amlodipine. He does not use tobacco or alcohol. His blood pressure is 110/60 mm Hg and pulse is 144/min and irregular. ECG shows an irregularly irregular rhythm and absent P waves. The patient is started on beta blocker therapy for rate control, with improvement in his heart rate. Long-term anticoagulation is initiated to prevent atrial thrombus formation, and he is eventually discharged home on warfarin. Which of the following is the best test to monitor the anticoagulation effect of warfarin in this patient?

A. Activated partial thromboplastin time (12%)

B. Bleeding time (2%)

C. Fibrin split products (1%)

D. Fibrinogen levels (0%)

✓ E. Prothrombin time (83%)

Omitted
Correct answer
E

83%
Answered correctly

03 secs
Time Spent

06/07/2020
Last Updated

Explanation

Anticoagulants & their mechanism of action

Intrinsic pathway

Extrinsic pathway

Tissue factor

1
2
3
4
5
6
7
8
9
10
11
12
13
14
15
16
17
18
19
20
21
22
23
24
25
26
27
28
29
30
31

Anticoagulants & their mechanism of action

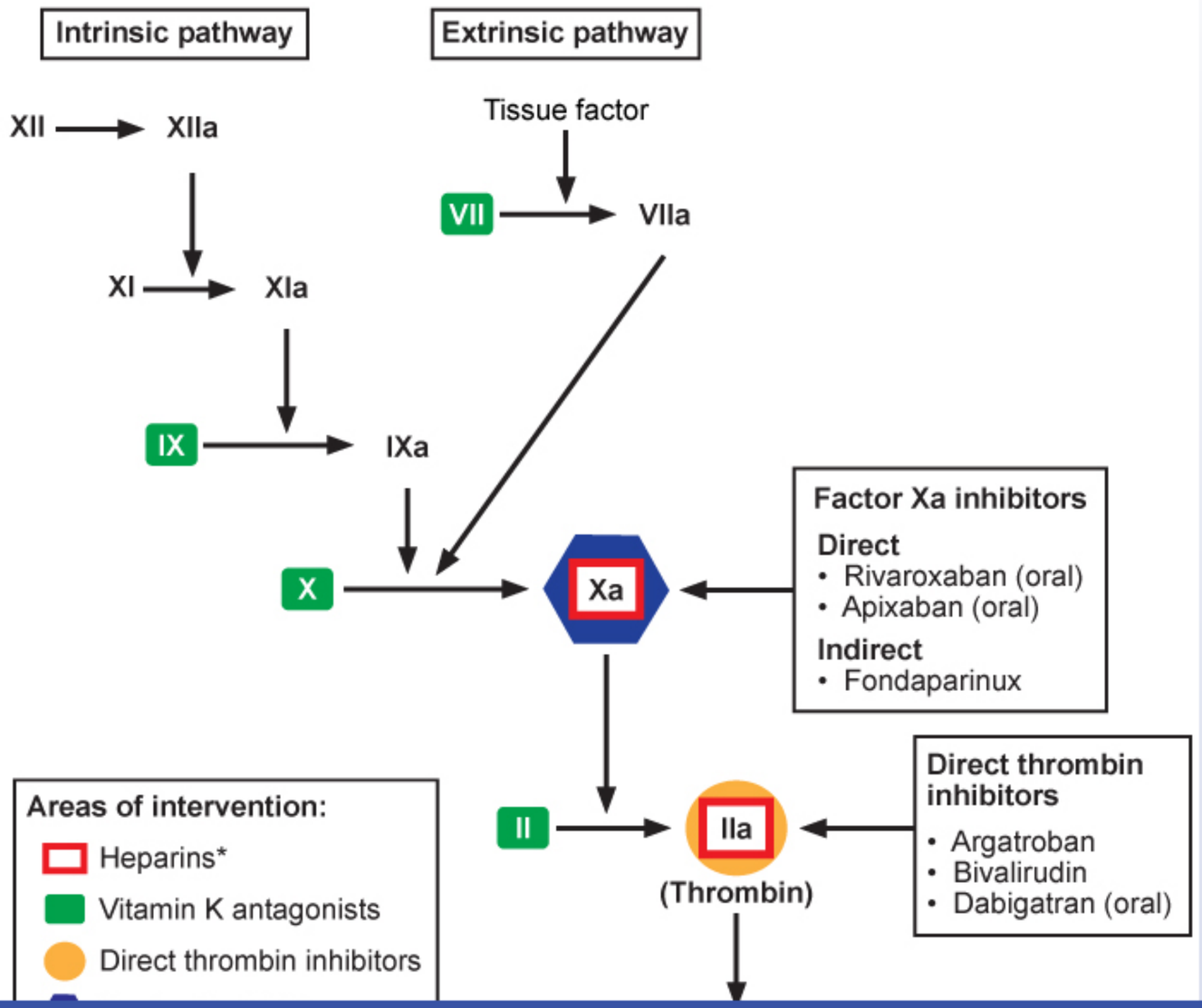

1
2
3
4
5
6
7
8
9
10
11
12
13
14
15
16
17
18
19
20
21
22
23
24
25
26
27
28
29
30
31

Exhibit Display

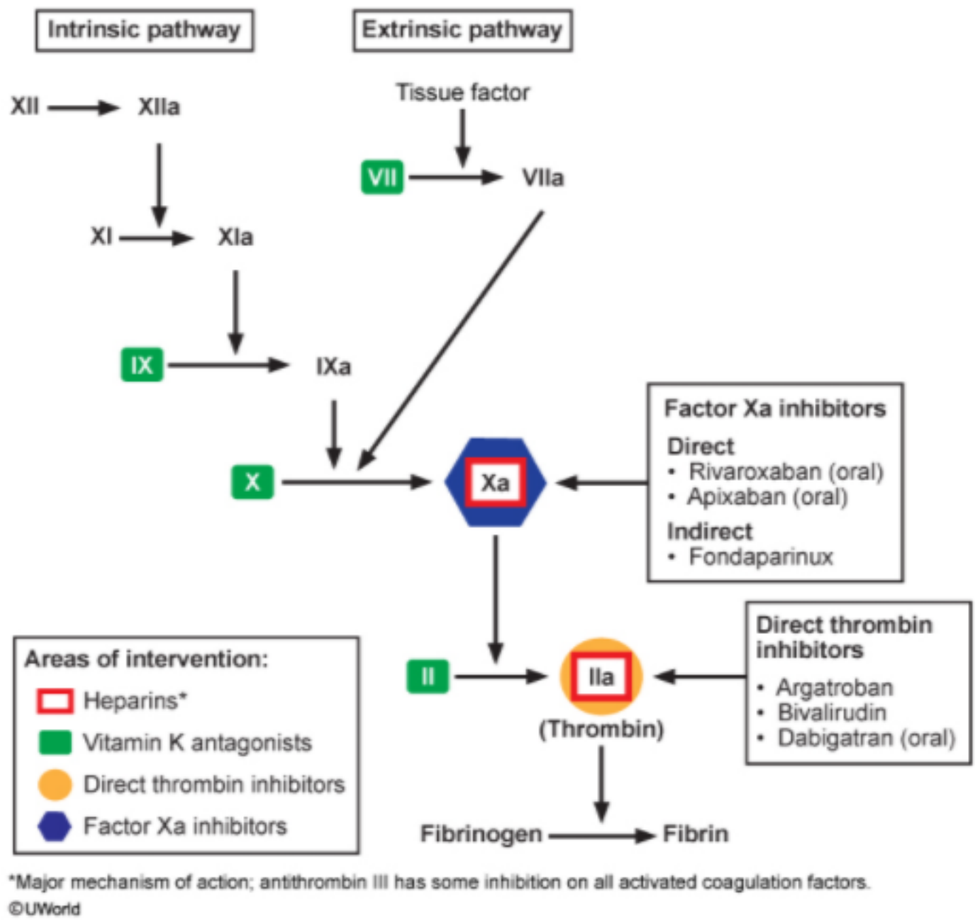

Zoom In | Zoom Out | Reset | Add To New Card | Existing Card

1 2 3 4 5 6 7 8 9 10 11 12 13 14 15 16 17 18 19 20 21 22 23 24 25 26 27 28 29 30 31

This patient's ECG (irregularly irregular rhythm with absent P waves) suggests **atrial fibrillation (AF)**, which alters cardiac flow dynamics, making thrombus formation more common. If this thrombus detaches from the atrial wall, there is a risk of stroke. The oral anticoagulant **warfarin** (Coumadin) reduces thrombus formation risk by inhibiting the activation of vitamin K-dependent clotting factors II, VII, IX, and X **(vitamin K antagonist)**. This leads to decreased levels of these factors, particularly **factor VII**, and therefore prolongs the prothrombin time (PT). Another useful laboratory value is the **International Normalized Ratio (INR)**, a ratio of the patient's PT to a control (usual INR target for AF: 2.0-3.0). Examples of indications include AF, deep venous thrombosis, and pulmonary thromboembolism. Outpatients who take warfarin typically have their INR checked every few weeks (more frequently initially).

The most common side effect is excessive anticoagulation leading to bleeding (which can require vitamin K and fresh frozen plasma if rapid reversal is needed). Skin necrosis can occur during the first few days of treatment due to a transient hypercoagulable state (reduction in protein C anticoagulant activity before affecting other factors' procoagulant activity); for this reason, heparin is typically administered temporarily at the start of warfarin therapy ("heparin bridge"). Warfarin should not be used during pregnancy because it is teratogenic and can cause fetal bleeding.

(Choice A) Activated partial thromboplastin time (aPTT) is used to monitor unfractionated heparin, which primarily affects the intrinsic coagulation pathway.

(Choice B) Bleeding time is used for the assessment of platelet function. Increased bleeding time can be seen with thrombocytopenia, von Willebrand disease, defects of platelet aggregation, disseminated intravascular coagulation (DIC), and aspirin therapy.

(Choices C and D) The combination of a decreased fibrinogen level and the presence of fibrin split products (such as D-dimer) is characteristic of DIC.

Educational objective:
Warfarin is an oral anticoagulant that inhibits the carboxylation of vitamin K-dependent coagulation factors II, VII, IX, and X. It is used in atrial fibrillation, deep venous thrombosis, and pulmonary thromboembolism. Prothrombin time (PT)/International Normalized Ratio (INR) should be monitored regularly during treatment with warfarin. Activated partial thromboplastin time (aPTT) is used for monitoring unfractionated heparin.

Pharmacology	Cardiovascular System	Anticoagulants
Subject	System	Topic

Copyright © UWorld. All rights reserved.

This patient's ECG (irregularly irregular rhythm with absent P waves) suggests **atrial fibrillation (AF)**, which alters cardiac flow dynamics, making

Exhibit Display

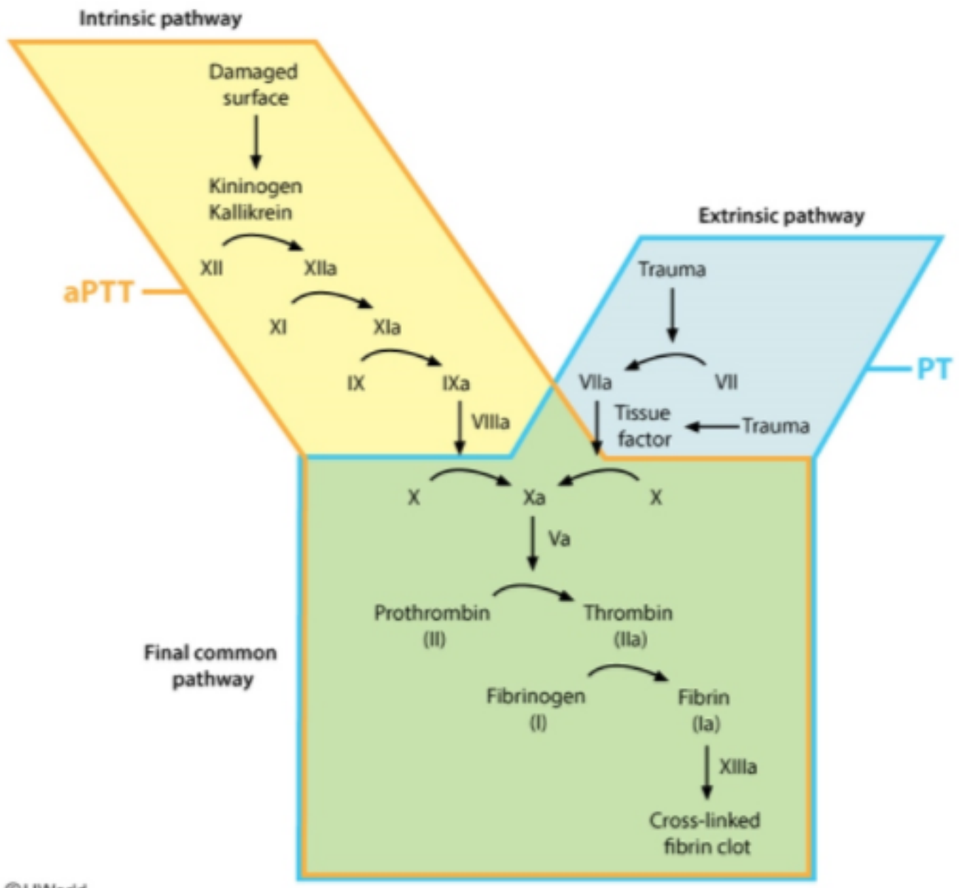

©UWorld
aPTT = activated partial thromboplastin time; **PT** = prothrombin time.

Zoom In | Zoom Out | Reset | Add To New Card | Existing Card

Copyright © UWorld. All rights reserved.

1
2
3
4
5
6
7
8
9
10
11
12
13
14
15
16
17
18
19
20
21
22
23
24
25
26
27
28
29
30
31

A 71-year-old woman comes to the emergency department due to progressive dyspnea and orthopnea for the last week. She has a history of myocardial infarction and systolic heart failure with a left ventricular ejection fraction of 15%. The patient is compliant with her medications, which include carvedilol, furosemide, aspirin, lisinopril, and atorvastatin. Blood pressure is 118/74 mm Hg and pulse is 72/min. Examination reveals elevated jugular venous pressure, bibasilar crackles, an S3 heart sound, and bilateral lower extremity pitting edema. The patient is started on dobutamine infusion, which provides significant symptom relief. Echocardiogram shows mild improvement in cardiac contractility. Which of the following is the likely mechanism underlying this patient's clinical improvement?

A. Cyclic nucleotide phosphodiesterase inhibition
B. G_s protein-adenylate cyclase activation
C. Late-phase inward sodium channel inhibition
D. Sodium-potassium exchange pump inhibition
E. Soluble guanylate cyclase activation
F. Voltage-dependent calcium channel inhibition

Submit

1
2
3
4
5
6
7
8
9
10
11
12
13
14
15
16
17
18
19
20
21
22
23
24
25
26
27
28
29
30
31

A 71-year-old woman comes to the emergency department due to progressive dyspnea and orthopnea for the last week. She has a history of myocardial infarction and systolic heart failure with a left ventricular ejection fraction of 15%. The patient is compliant with her medications, which include carvedilol, furosemide, aspirin, lisinopril, and atorvastatin. Blood pressure is 118/74 mm Hg and pulse is 72/min. Examination reveals elevated jugular venous pressure, bibasilar crackles, an S3 heart sound, and bilateral lower extremity pitting edema. The patient is started on dobutamine infusion, which provides significant symptom relief. Echocardiogram shows mild improvement in cardiac contractility. Which of the following is the likely mechanism underlying this patient's clinical improvement?

A. Cyclic nucleotide phosphodiesterase inhibition (2%)
✓ B. G_s protein-adenylate cyclase activation (79%)
C. Late-phase inward sodium channel inhibition (3%)
D. Sodium-potassium exchange pump inhibition (5%)
E. Soluble guanylate cyclase activation (3%)
F. Voltage-dependent calcium channel inhibition (4%)

Omitted
Correct answer
B

79%
Answered correctly

02 secs
Time Spent

06/05/2020
Last Updated

Explanation

Dobutamine pharmacology

1
2
3
4
5
6
7
8
9
10
11
12
13
14
15
16
17
18
19
20
21
22
23
24
25
26
27
28
29
30
31

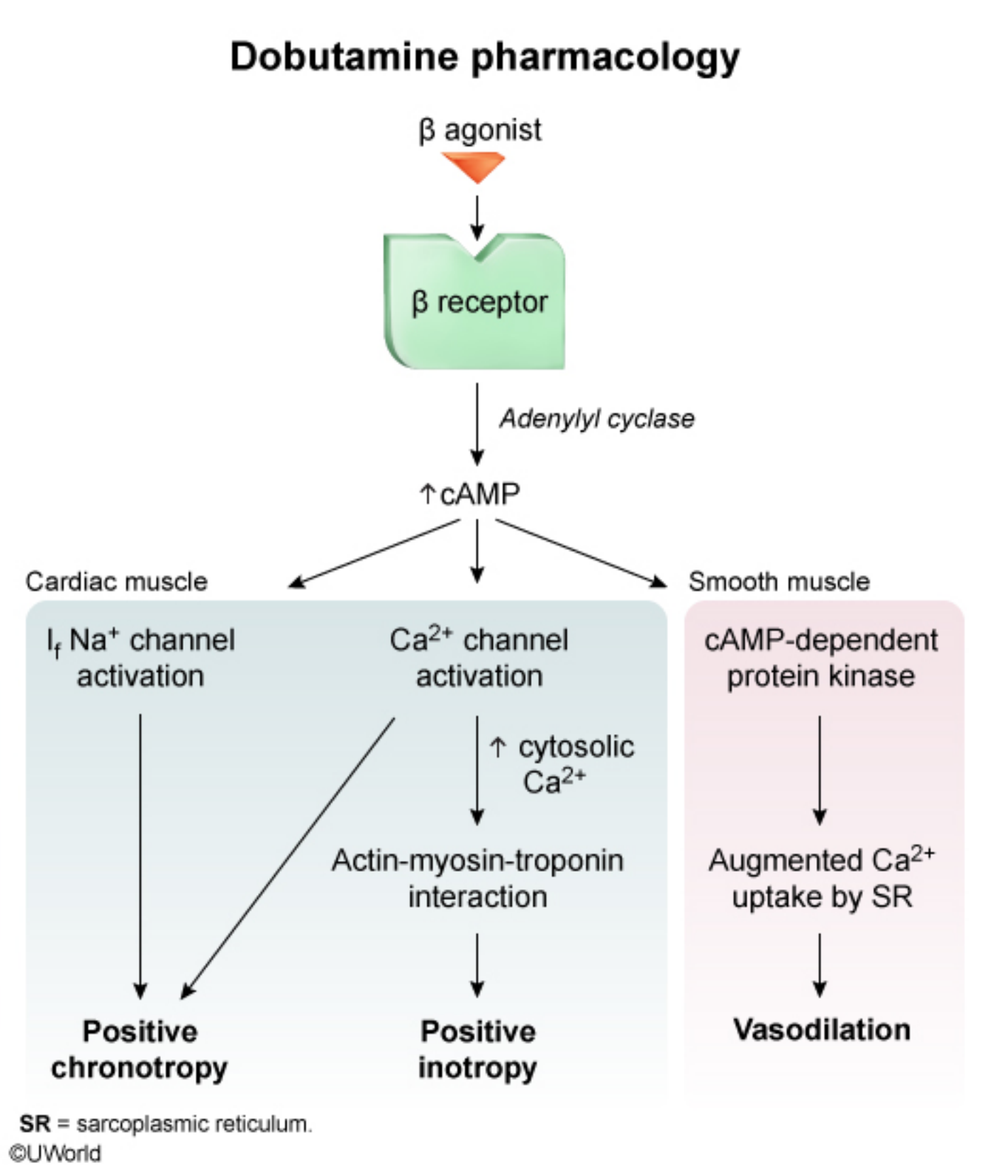

1 2 3 4 5 6 7 8 9 10 11 12 13 14 15 16 17 18 19 20 21 22 23 24 25 26 27 28 29 30 31

Dobutamine is a β-adrenergic agonist with predominant activity on β_1 receptors and weak activity on β_2 and α_1 receptors. Stimulation of β_1-adrenergic receptors causes **G_s protein** GTP binding, leading to activation of adenylyl cyclase and **increased production of cAMP** in the target cells. In cardiac myocytes, increased cAMP causes calcium channel activation and increased cytosolic Ca^{2+} concentration. This causes a conformational change in the troponin complex, facilitating actin-myosin binding and increasing myocardial contractility (**positive inotropy**). Increased cAMP also causes a rise in heart rate by increasing Na^+ and Ca^{2+} channel activation in pacemaker cells (**positive chronotropy**).

In the vasculature, α_1 agonist activity (vasoconstriction) balances the β_2 agonist effect (vasodilation) with resultant mild vasodilation. The net hemodynamic effects are an increase in cardiac contractility and a decrease in systemic vascular resistance without significant change in arterial blood pressure. This increase in cardiac output can improve symptoms and end-organ perfusion in patients with severe left ventricular systolic dysfunction and cardiogenic shock.

(Choice A) Phosphodiesterase inhibitors (eg, milrinone) increase the intracellular levels of cAMP by preventing its enzymatic breakdown in cardiac and vascular tissues, and result in vasodilation and positive inotropic effects.

(Choice C) Ranolazine is an anti-anginal drug that inhibits late-phase inward sodium channels in ischemic myocardial cells during cardiac repolarization. A decrease in intracellular sodium concentration enhances calcium efflux via the sodium-calcium exchanger, which reduces myocardial oxygen consumption.

(Choice D) Digoxin acts by inhibiting the sodium-potassium ATPase pump. This increases intracellular sodium concentration, which in turn decreases activity of the sodium-calcium exchanger that exports calcium from myocardial cells. The corresponding rise in intracellular Ca^{2+} concentration leads to improved myocardial contractility.

(Choice E) Nitrates provide free radical nitric oxide, which activates guanylate cyclase and increases cGMP levels. This in turn leads to dephosphorylation of myosin light chains and causes vascular smooth muscle relaxation.

(Choice F) Calcium channel blockers (eg, verapamil, diltiazem) prevent calcium ions from traversing voltage-dependent calcium channels in vascular smooth muscle and myocardium, leading to vasodilation and a decrease in cardiac contractility.

Educational objective:
Dobutamine is a β-adrenergic agonist with predominant activity on β_1 receptors and weak activity on β_2 and α_1 receptors. Stimulation of β_1 receptors leads to an increased production of cAMP and increased cytosolic Ca^{2+} concentration. This facilitates the interaction between actin and myosin, resulting in increased myocardial contractility.

In the vasculature, α_1 agonist activity (vasoconstriction) balances the β_2 agonist effect (vasodilation) with resultant mild vasodilation. The net hemodynamic effects are an increase in cardiac contractility and a decrease in systemic vascular resistance without significant change in arterial blood pressure. This increase in cardiac output can improve symptoms and end-organ perfusion in patients with severe left ventricular systolic dysfunction and cardiogenic shock.

(Choice A) Phosphodiesterase inhibitors (eg, milrinone) increase the intracellular levels of cAMP by preventing its enzymatic breakdown in cardiac and vascular tissues, and result in vasodilation and positive inotropic effects.

(Choice C) Ranolazine is an anti-anginal drug that inhibits late-phase inward sodium channels in ischemic myocardial cells during cardiac repolarization. A decrease in intracellular sodium concentration enhances calcium efflux via the sodium-calcium exchanger, which reduces myocardial oxygen consumption.

(Choice D) Digoxin acts by inhibiting the sodium-potassium ATPase pump. This increases intracellular sodium concentration, which in turn decreases activity of the sodium-calcium exchanger that exports calcium from myocardial cells. The corresponding rise in intracellular Ca^{2+} concentration leads to improved myocardial contractility.

(Choice E) Nitrates provide free radical nitric oxide, which activates guanylate cyclase and increases cGMP levels. This in turn leads to dephosphorylation of myosin light chains and causes vascular smooth muscle relaxation.

(Choice F) Calcium channel blockers (eg, verapamil, diltiazem) prevent calcium ions from traversing voltage-dependent calcium channels in vascular smooth muscle and myocardium, leading to vasodilation and a decrease in cardiac contractility.

Educational objective:
Dobutamine is a β-adrenergic agonist with predominant activity on β_1 receptors and weak activity on β_2 and α_1 receptors. Stimulation of β_1 receptors leads to an increased production of cAMP and increased cytosolic Ca^{2+} concentration. This facilitates the interaction between actin and myosin, resulting in increased myocardial contractility.

References

- The pharmacology of dobutamine.
- Inotropes and vasopressors: review of physiology and clinical use in cardiovascular disease.

1
2
3
4
5
6
7
8
9
10
11
12
13
14
15
16
17
18
19
20
21
22
23
24
25
26
27
28
29
30
31

Exhibit Display

Digoxin mechanism of action

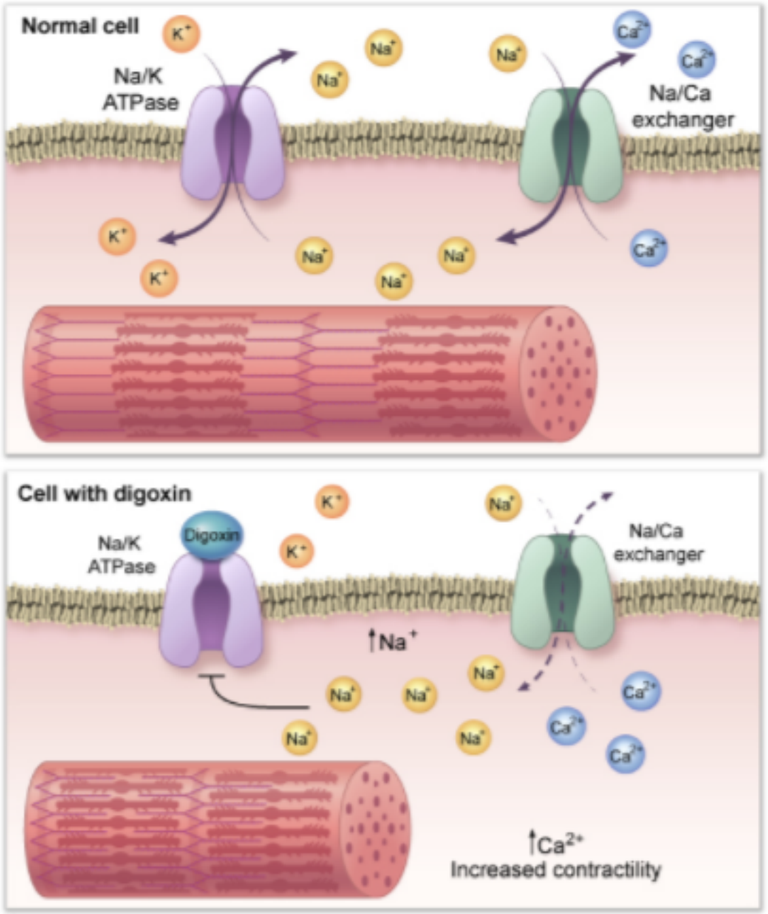

©UWorld

Zoom In | Zoom Out | Reset | Add To New Card | Existing Card

1
2
3
4
5
6
7
8
9
10
11
12
13
14
15
16
17
18
19
20
21
22
23
24
25
26
27
28
29
30
31

A 71-year-old man with chronic stable angina comes to the office for routine follow-up. He has occasional episodes of chest pain that improve after taking sublingual nitroglycerin. The patient also has a history of hypertension and hypercholesterolemia and takes multiple medications for his conditions. Blood pressure is 140/80 mm Hg and pulse is 68/min and regular. Examination reveals normal heart sounds. While discussing a plan to start isosorbide dinitrate therapy, the patient becomes concerned about the high dose of oral isosorbide dinitrate compared to sublingual nitroglycerin. Which of the following is the most likely reason for using a high dose of oral nitrate?

- A. Drug tolerance prevention
- B. High first-pass metabolism
- C. High serum protein binding
- D. High volume of distribution
- E. Low intestinal absorption

Submit

A 71-year-old man with chronic stable angina comes to the office for routine follow-up. He has occasional episodes of chest pain that improve after taking sublingual nitroglycerin. The patient also has a history of hypertension and hypercholesterolemia and takes multiple medications for his conditions. Blood pressure is 140/80 mm Hg and pulse is 68/min and regular. Examination reveals normal heart sounds. While discussing a plan to start isosorbide dinitrate therapy, the patient becomes concerned about the high dose of oral isosorbide dinitrate compared to sublingual nitroglycerin. Which of the following is the most likely reason for using a high dose of oral nitrate?

- A. Drug tolerance prevention (6%)
- ✓ B. High first-pass metabolism (77%)
- C. High serum protein binding (2%)
- D. High volume of distribution (4%)
- E. Low intestinal absorption (8%)

Omitted
Correct answer
B

77%
Answered correctly

03 secs
Time Spent

03/08/2020
Last Updated

Explanation

Nitrates, beta blockers, and calcium channel blockers are the mainstay of therapy for patients with chronic stable angina. Sublingual nitroglycerin is the therapy of choice in acute episodes for immediate relief of angina and for prevention of angina prior to engaging in strenuous physical activity. Chronic nitrate therapy with long-acting oral formulations (isosorbide dinitrate or mononitrate) is used to prevent recurrent anginal episodes in patients with chronic stable angina.

Sublingual nitroglycerin is absorbed rapidly from oral mucosa directly into the venous circulation and has a rapid onset of action within 2-5

1
2
3
4
5
6
7
8
9
10
11
12
13
14
15
16
17
18
19
20
21
22
23
24
25
26
27
28
29
30
31

Nitrates, beta blockers, and calcium channel blockers are the mainstay of therapy for patients with chronic stable angina. Sublingual nitroglycerin is the therapy of choice in acute episodes for immediate relief of angina and for prevention of angina prior to engaging in strenuous physical activity. Chronic nitrate therapy with long-acting oral formulations (isosorbide dinitrate or mononitrate) is used to prevent recurrent anginal episodes in patients with chronic stable angina.

Sublingual nitroglycerin is absorbed rapidly from oral mucosa directly into the venous circulation and has a rapid onset of action within 2-5 minutes. Long-acting **isosorbide dinitrate** is absorbed via the gastrointestinal tract and undergoes **extensive first-pass metabolism** in the liver prior to release in the systemic circulation. This leads to **low bioavailability** and the need for much higher doses of oral formulations as compared to sublingual nitroglycerin.

(Choice A) Chronic nitrate therapy on a regular basis leads to nitrate tolerance, with attenuation of blood pressure response and anti-anginal effects. Higher doses do not prevent nitrate tolerance. On the contrary, use of sublingual nitroglycerin on an intermittent, as-needed basis (nitrate-free intervals) prevents the development of nitrate tolerance.

(Choices C and D) The oral nitrate preparations do not have high serum protein binding or volume of distribution.

(Choice E) Isosorbide dinitrate has rapid and nearly complete intestinal absorption. Its low bioavailability is due to considerable first-pass hepatic metabolism.

Educational objective:
Isosorbide dinitrate has a low bioavailability due to extensive first-pass hepatic metabolism prior to release in systemic circulation. Sublingual nitroglycerin is absorbed directly from oral mucosa into the venous circulation and has a higher bioavailability.

References

- Clinical pharmacokinetics of nitrates.

Pharmacology	Cardiovascular System	Nitrates
Subject	System	Topic

Copyright © UWorld. All rights reserved.

1
2
3
4
5
6
7
8
9
10
11
12
13
14
15
16
17
18
19
20
21
22
23
24
25
26
27
28
29
30
31

A 62-year-old man comes to the office for follow-up of hypertension. He was diagnosed with hypertension 10 years ago and has been treated with a number of different medications. However, the patient has had to discontinue several medications due to side effects such as dizziness, palpitations, and headaches. Currently he takes ramipril and chlorthalidone and is tolerating them well. Blood pressure is 160/92 mm Hg and was 158/89 mm Hg at his most recent prior visit. ECG shows sinus bradycardia (55/min) with PR interval prolongation (280 msec). Which of the following medications would be most effective for lowering this patient's blood pressure without worsening his ECG abnormalities?

- A. Diltiazem
- B. Metoprolol
- C. Nifedipine
- D. Sotalol
- E. Verapamil

Submit

1
2
3
4
5
6
7
8
9
10
11
12
13
14
15
16
17
18
19
20
21
22
23
24
25
26
27
28
29
30
31

A 62-year-old man comes to the office for follow-up of hypertension. He was diagnosed with hypertension 10 years ago and has been treated with a number of different medications. However, the patient has had to discontinue several medications due to side effects such as dizziness, palpitations, and headaches. Currently he takes ramipril and chlorthalidone and is tolerating them well. Blood pressure is 160/92 mm Hg and was 158/89 mm Hg at his most recent prior visit. ECG shows sinus bradycardia (55/min) with PR interval prolongation (280 msec). Which of the following medications would be most effective for lowering this patient's blood pressure without worsening his ECG abnormalities?

A. Diltiazem (5%)
B. Metoprolol (9%)
✓ C. Nifedipine (71%)
D. Sotalol (7%)
E. Verapamil (6%)

Omitted
Correct answer
C

71%
Answered correctly

01 sec
Time Spent

02/16/2020
Last Updated

Explanation

Effects of calcium channel blockers		
Drug	Location of action	Physiologic effects

Explanation

Effects of calcium channel blockers		
Drug	**Location of action**	**Physiologic effects**
Dihydropyridines (Amlodipine, felodipine, nifedipine)	Vascular smooth muscle	Peripheral vasodilation
Verapamil	Cardiac muscle	Reduced heart rate & myocardial contractility
Diltiazem	Vascular smooth muscle & cardiac muscle	Combined effects

©UWorld

Calcium channel blockers are frequently used in the treatment of several cardiovascular disorders, including hypertension, angina pectoris, and certain cardiac arrhythmias. They inhibit the L-type calcium channel on vascular smooth muscle and cardiac cells and are divided into 2 major categories based on their predominant actions:

1. **Dihydropyridines** (nifedipine, amlodipine, felodipine) primarily affect **arterial smooth muscle**, causing vasodilation with little or no effect on cardiac conduction or contractility.
2. **Nondihydropyridines** (verapamil, diltiazem) affect the **myocardium**, slowing heart rate (negative chronotropic effect) and reducing contractility (negative inotropic effect).

This patient's ECG shows sinus bradycardia (rate <60/min) with first-degree atrioventricular (AV) block (PR interval >200 msec). Of the choices above, nifedipine is the most appropriate agent to manage hypertension as it has minimal effect on cardiac conduction. Dihydropyridines can

©UWorld

Calcium channel blockers are frequently used in the treatment of several cardiovascular disorders, including hypertension, angina pectoris, and certain cardiac arrhythmias. They inhibit the L-type calcium channel on vascular smooth muscle and cardiac cells and are divided into 2 major categories based on their predominant actions:

1. **Dihydropyridines** (nifedipine, amlodipine, felodipine) primarily affect **arterial smooth muscle**, causing vasodilation with little or no effect on cardiac conduction or contractility.
2. **Nondihydropyridines** (verapamil, diltiazem) affect the **myocardium**, slowing heart rate (negative chronotropic effect) and reducing contractility (negative inotropic effect).

This patient's ECG shows sinus bradycardia (rate <60/min) with first-degree atrioventricular (AV) block (PR interval >200 msec). Of the choices above, nifedipine is the most appropriate agent to manage hypertension as it has minimal effect on cardiac conduction. Dihydropyridines can cause reflex tachycardia in response to peripheral vasodilation and are therefore useful in hypertensive patients with resting bradycardia.

(Choices A and E) Verapamil is a nondihydropyridine calcium channel blocker with a significant depressive effect on cardiac conduction. Diltiazem has combined effects and acts at both the myocardium and peripheral arterial beds. These medications can worsen bradycardia and AV block and should not be used in patients with underlying conduction abnormalities.

(Choices B and D) Metoprolol is a cardioselective beta blocker with negative chronotropic and dromotropic (decreased AV conduction) effects. Sotalol is a class III antiarrhythmic drug with significant beta-blocking properties. These drugs can worsen bradycardia and AV conduction defects and would not be recommended for this patient.

Educational objective:
Calcium channel blockers inhibit the L-type calcium channel on vascular smooth muscle and cardiac cells. Dihydropyridines (eg, nifedipine, amlodipine) primarily affect peripheral arteries and cause vasodilation. Nondihydropyridines (eg, verapamil, diltiazem) affect the myocardium and can cause bradycardia and slowed atrioventricular conduction.

References

- Calcium channel blockers in cardiovascular pharmacotherapy.

Pharmacology Cardiovascular System Calcium channel blocker

1
2
3
4
5
6
7
8
9
10
11
12
13
14
15
16
17
18
19
20
21
22
23
24
25
26
27
28
29
30
31

A 45-year-old man is brought to a rural emergency department due to severe chest pain, sweating, and nausea. The symptoms began suddenly an hour ago. He has no significant medical history. His father died at age 50 after experiencing sudden-onset chest pain. The patient smokes a pack of cigarettes daily. He does not take any medications and has no known drug allergies. Examination shows normal heart sounds and breath sounds. ECG shows sinus tachycardia with ST segment elevation in leads II, III, and aVF. Medical management for the patient's acute condition is initiated. After initial treatment, the chest pain decreases in intensity and a reperfusion complex ventricular arrhythmia emerges. The arrhythmia is asymptomatic and resolves spontaneously. Which of the following drugs is most likely responsible for rapid reperfusion in this patient?

A. Alteplase
B. Apixaban
C. Argatroban
D. Aspirin
E. Heparin
F. Prasugrel
G. Rosuvastatin

Submit

1
2
3
4
5
6
7
8
9
10
11
12
13
14
15
16
17
18
19
20
21
22
23
24
25
26
27
28
29
30
31

A 45-year-old man is brought to a rural emergency department due to severe chest pain, sweating, and nausea. The symptoms began suddenly an hour ago. He has no significant medical history. His father died at age 50 after experiencing sudden-onset chest pain. The patient smokes a pack of cigarettes daily. He does not take any medications and has no known drug allergies. Examination shows normal heart sounds and breath sounds. ECG shows sinus tachycardia with ST segment elevation in leads II, III, and aVF. Medical management for the patient's acute condition is initiated. After initial treatment, the chest pain decreases in intensity and a reperfusion complex ventricular arrhythmia emerges. The arrhythmia is asymptomatic and resolves spontaneously. Which of the following drugs is most likely responsible for rapid reperfusion in this patient?

- ✓ A. Alteplase (71%)
- B. Apixaban (1%)
- C. Argatroban (2%)
- D. Aspirin (9%)
- E. Heparin (11%)
- F. Prasugrel (2%)
- G. Rosuvastatin (0%)

Omitted
Correct answer
A

71%
Answered correctly

01 sec
Time Spent

02/15/2020
Last Updated

Explanation

1
2
3
4
5
6
7
8
9
10
11
12
13
14
15
16
17
18
19
20
21
22
23
24
25
26
27
28
29
30
31

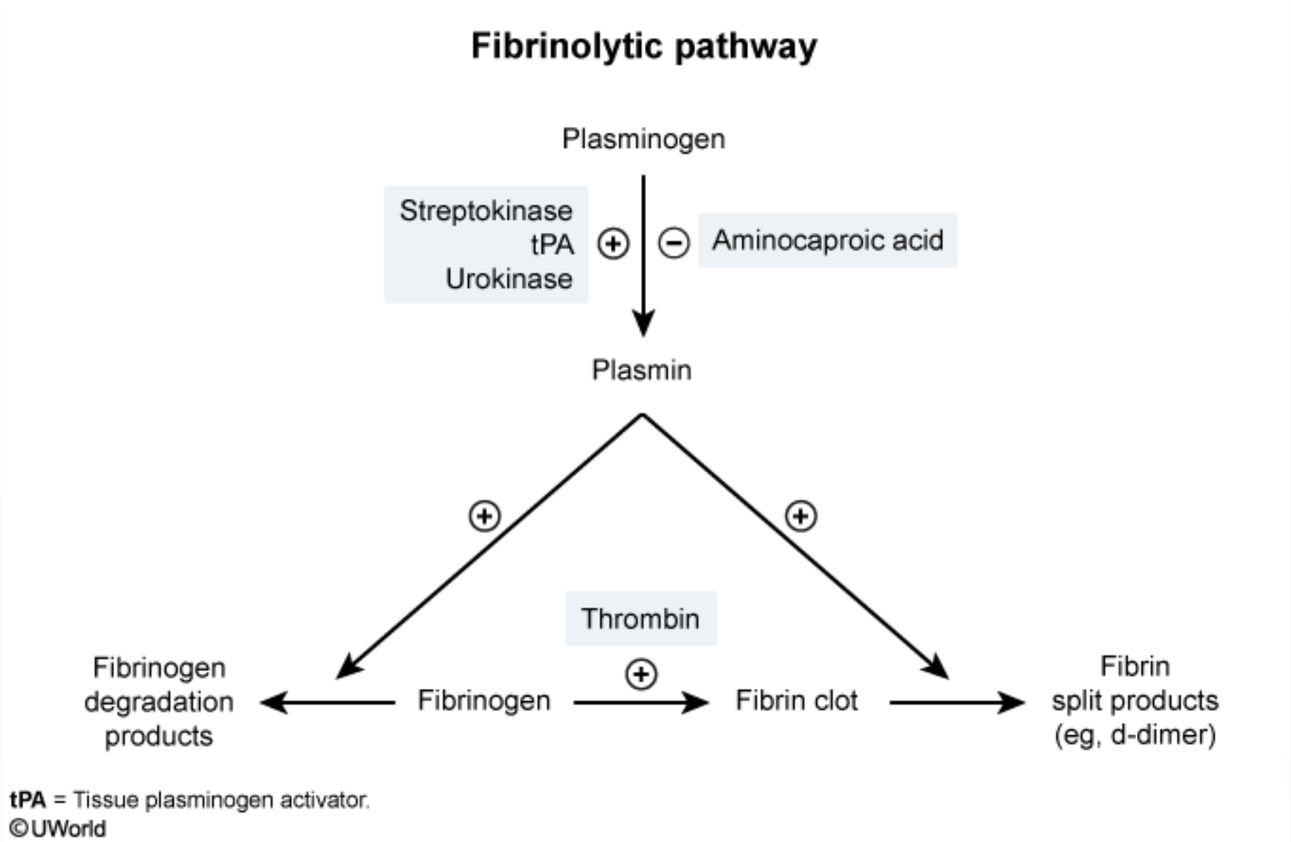

This patient had an **ST-elevation myocardial infarction** (STEMI) and, following medical treatment, experienced symptomatic improvement and reperfusion-related arrhythmia; this is most likely the result of **fibrinolytic (thrombolytic) therapy**. Fibrinolytic agents (eg, **alteplase**) are indicated in patients with acute STEMI who cannot receive percutaneous coronary intervention in a timely manner. Administration of these agents leads to breakdown of fibrin clot and often restoration of myocardial perfusion; some patients develop a self-limiting reperfusion-related arrhythmia (most commonly an accelerated idioventricular rhythm).

In the **fibrinolytic pathway**, tissue plasminogen activator (tPA) is released by the endothelium and cleaves plasminogen to form plasmin. Plasmin then acts to both degrade individual fibrinogen molecules and break down fibrin clot that has already formed. The breakdown of fibrin clot leads to elevated levels of fibrin split products (eg, d-dimer) in the blood.

This patient had an **ST-elevation myocardial infarction** (STEMI) and, following medical treatment, experienced symptomatic improvement and reperfusion-related arrhythmia; this is most likely the result of **fibrinolytic (thrombolytic) therapy**. Fibrinolytic agents (eg, **alteplase**) are indicated in patients with acute STEMI who cannot receive percutaneous coronary intervention in a timely manner. Administration of these agents leads to breakdown of fibrin clot and often restoration of myocardial perfusion; some patients develop a self-limiting reperfusion-related arrhythmia (most commonly an accelerated idioventricular rhythm).

In the **fibrinolytic pathway**, tissue plasminogen activator (tPA) is released by the endothelium and cleaves plasminogen to form plasmin. Plasmin then acts to both degrade individual fibrinogen molecules and break down fibrin clot that has already formed. The breakdown of fibrin clot leads to elevated levels of fibrin split products (eg, d-dimer) in the blood.

Pharmacologic fibrinolytic agents that are used clinically include streptokinase and recombinant forms of tPA (eg, alteplase, tenecteplase). All of these agents inherently increase bleeding risk and are contraindicated in patients with increased risk of bleeding complications (eg, recent hemorrhagic stroke).

(Choices B and C) Apixaban is a direct factor Xa inhibitor used in the treatment and prevention of venous thromboembolism, and argatroban is a direct thrombin inhibitor used to treat heparin-induced thrombocytopenia. Both of these drugs are anticoagulants; neither causes fibrinolysis or is typically used in the treatment of STEMI.

(Choices D and F) Aspirin inhibits cyclooxygenase to reduce thromboxane levels, and P2Y12 receptor blockers (eg, clopidogrel, prasugrel) prevent the binding of adenosine diphosphate to platelets; both actions lead to irreversible inhibition of platelet aggregation. These drugs are used together in acute STEMI to prevent the development of additional platelet thrombus; however, they do not cause lysis of existing thrombus.

(Choice E) Heparin potentiates the activity of antithrombin III to inhibit thrombin and factor Xa and exert an anticoagulation effect. Heparin is used in acute STEMI to prevent further progression of clot formation, but it does not cause thrombolysis.

(Choice G) Statins (eg, rosuvastatin) are used for acute STEMI as they may stabilize atherosclerotic plaques, reduce vascular inflammation, and promote long-term regression of atherosclerosis. However, they do not cause thrombolysis.

Educational objective:
In the fibrinolytic pathway, tissue plasminogen activator (tPA) converts plasminogen to plasmin, which then breaks down fibrin clot. The administration of a tPA analogue (eg, alteplase, tenecteplase, streptokinase) triggers fibrinolysis and can restore myocardial perfusion in patients

Pharmacologic fibrinolytic agents that are used clinically include streptokinase and recombinant forms of tPA (eg, alteplase, tenecteplase). All of these agents inherently increase bleeding risk and are contraindicated in patients with increased risk of bleeding complications (eg, recent hemorrhagic stroke).

(Choices B and C) Apixaban is a direct factor Xa inhibitor used in the treatment and prevention of venous thromboembolism, and argatroban is a direct thrombin inhibitor used to treat heparin-induced thrombocytopenia. Both of these drugs are anticoagulants; neither causes fibrinolysis or is typically used in the treatment of STEMI.

(Choices D and F) Aspirin inhibits cyclooxygenase to reduce thromboxane levels, and P2Y12 receptor blockers (eg, clopidogrel, prasugrel) prevent the binding of adenosine diphosphate to platelets; both actions lead to irreversible inhibition of platelet aggregation. These drugs are used together in acute STEMI to prevent the development of additional platelet thrombus; however, they do not cause lysis of existing thrombus.

(Choice E) Heparin potentiates the activity of antithrombin III to inhibit thrombin and factor Xa and exert an anticoagulation effect. Heparin is used in acute STEMI to prevent further progression of clot formation, but it does not cause thrombolysis.

(Choice G) Statins (eg, rosuvastatin) are used for acute STEMI as they may stabilize atherosclerotic plaques, reduce vascular inflammation, and promote long-term regression of atherosclerosis. However, they do not cause thrombolysis.

Educational objective:
In the fibrinolytic pathway, tissue plasminogen activator (tPA) converts plasminogen to plasmin, which then breaks down fibrin clot. The administration of a tPA analogue (eg, alteplase, tenecteplase, streptokinase) triggers fibrinolysis and can restore myocardial perfusion in patients with ST-elevation myocardial infarction who cannot undergo timely percutaneous coronary intervention.

References

- 2013 ACCF/AHA guideline for the management of ST-elevation myocardial infarction: executive summary: a report of the American College of Cardiology Foundation/American Heart Association Task Force on Practice Guidelines.

Pharmacology	Cardiovascular System	Myocardial infarction
Subject	System	Topic

Copyright © UWorld. All rights reserved.

Pharmacologic fibrinolytic agents that are used clinically include streptokinase and recombinant forms of tPA (eg, alteplase, tenecteplase). All

Exhibit Display

Antiplatelet medications

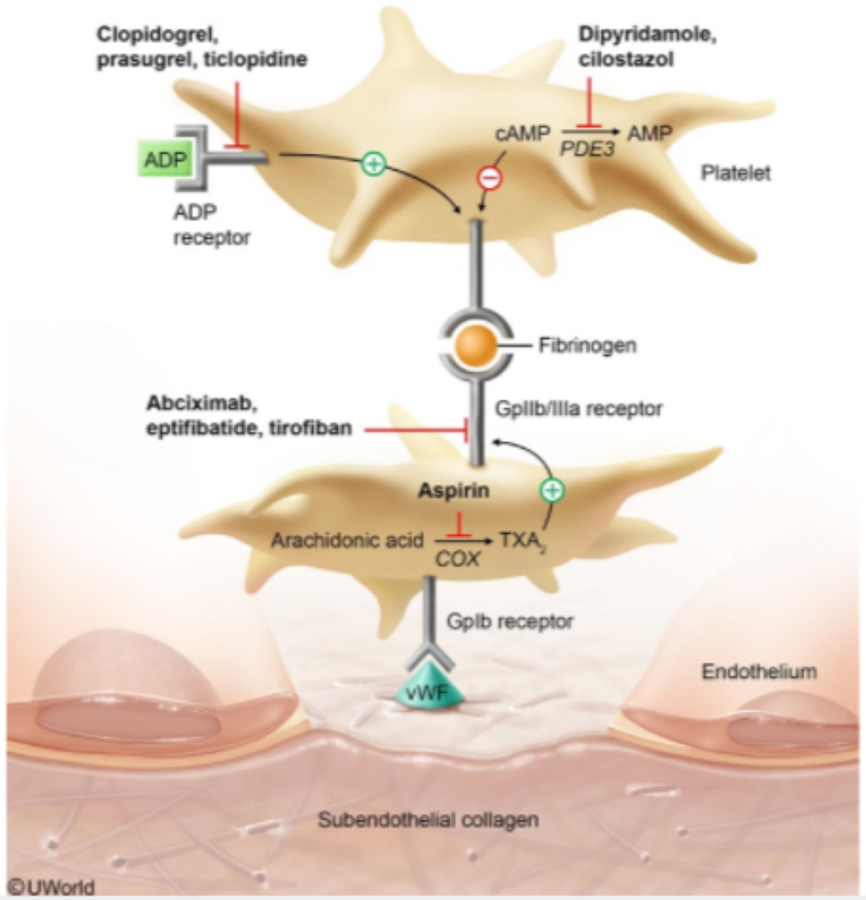

Zoom In | Zoom Out | Reset | Add To New Card | Existing Card

1
2
3
4
5
6
7
8
9
10
11
12
13
14
15
16
17
18
19
20
21
22
23
24
25
26
27
28
29
30
31

A 53-year-old man comes to the emergency department with shortness of breath and chest tightness. The patient was playing in a poker tournament when his symptoms first began. He has a history of hypertension and is not compliant with his medications. His last medical follow-up was a year ago. Blood pressure is 195/115 mm Hg and pulse is 90/min and regular. Lung examination reveals bibasilar crackles. Nitroglycerin infusion is started and results in significant symptomatic improvement. Repeat blood pressure is 165/90 mm Hg. Which of the following intracellular events is most likely responsible for the beneficial effects of this patient's treatment?

A. Actin phosphorylation
B. Calcium release from sarcoplasmic reticulum
C. Enhanced cyclic mononucleotide degradation
D. Inositol triphosphate accumulation
E. Myosin dephosphorylation
F. Tyrosine kinase activation

Submit

1
2
3
4
5
6
7
8
9
10
11
12
13
14
15
16
17
18
19
20
21
22
23
24
25
26
27
28
29
30
31

A 53-year-old man comes to the emergency department with shortness of breath and chest tightness. The patient was playing in a poker tournament when his symptoms first began. He has a history of hypertension and is not compliant with his medications. His last medical follow-up was a year ago. Blood pressure is 195/115 mm Hg and pulse is 90/min and regular. Lung examination reveals bibasilar crackles. Nitroglycerin infusion is started and results in significant symptomatic improvement. Repeat blood pressure is 165/90 mm Hg. Which of the following intracellular events is most likely responsible for the beneficial effects of this patient's treatment?

- A. Actin phosphorylation (3%)
- B. Calcium release from sarcoplasmic reticulum (8%)
- C. Enhanced cyclic mononucleotide degradation (22%)
- D. Inositol triphosphate accumulation (11%)
- ✓ E. Myosin dephosphorylation (49%)
- F. Tyrosine kinase activation (4%)

Omitted
Correct answer
E

49%
Answered correctly

03 secs
Time Spent

06/23/2020
Last Updated

Explanation

Mechanism of action of vasodilators

Vessel lumen

1
2
3
4
5
6
7
8
9
10
11
12
13
14
15
16
17
18
19
20
21
22
23
24
25
26
27
28
29
30
31

Mechanism of action of vasodilators

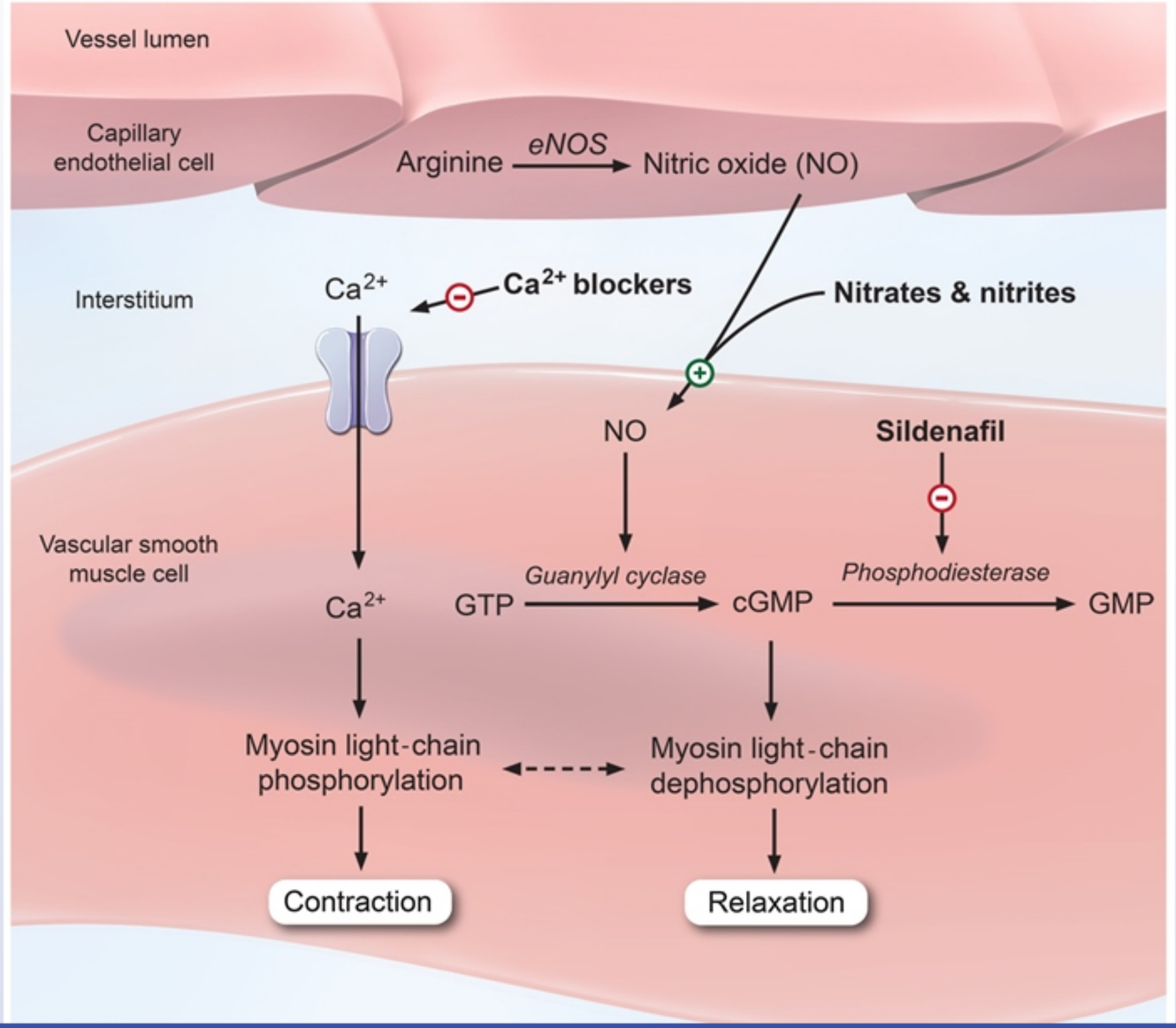

GMP = guanosine monophosphate; **GTP** = guanosine 5′-triphosphate.

This patient's clinical presentation is consistent with acute pulmonary edema due to severely elevated blood pressure (**hypertensive emergency**). In such cases, intravenous vasodilators (nitroglycerine, sodium nitroprusside) are often used to improve the acute heart failure by reducing preload and afterload.

Nitrates are metabolized within vascular smooth muscle cells to nitric oxide, which activates guanylate cyclase and promotes the conversion of guanosine triphosphate (GTP) to cyclic guanosine monophosphate (**cGMP**). Increased levels of cGMP lead to **decreased intracellular calcium** (reduces the activity of myosin light-chain kinase) and activation of myosin light chain phosphatase. This promotes **myosin light-chain dephosphorylation** and vascular smooth muscle **relaxation**.

(Choice A) Actin phosphorylation has no role in smooth or skeletal muscle relaxation. In smooth muscle, a stimulus to contract leads to increased intracellular calcium, which leads to myosin phosphorylation. Once myosin is phosphorylated, it is able to bind directly to actin and cause muscle contraction.

(Choice B) Calcium release from sarcoplasmic reticulum would lead to increased contraction of the cardiac myocytes. It is not involved in the mechanism of action of nitrates on vascular smooth muscle cells.

(Choice C) Nitrates do not cause an increase in cyclic mononucleotide degradation. On the contrary, they activate guanylate cyclase and promote conversion of GTP to cGMP, which ultimately leads to smooth muscle relaxation.

(Choice D) Inositol triphosphate binds to its receptor on the endoplasmic reticulum and leads to the release of Ca^{2+} into the cytoplasm. In vascular smooth muscle cells, this increased concentration of cytoplasmic Ca^{2+} results in increased smooth muscle contraction.

(Choice F) Tyrosine kinases play a role in a wide variety of intracellular processes and pathways. The effects of insulin and insulin-like growth factor occur via activation of receptor tyrosine kinases, which in turn cause phosphorylation of tyrosine residues on intracellular proteins important for signal transduction.

Educational objective:
Nitrates (via conversion to nitric oxide) activate guanylate cyclase and increase intracellular levels of cyclic guanosine monophosphate (cGMP). Increased levels of cGMP lead to myosin light-chain dephosphorylation, resulting in vascular smooth muscle relaxation.

References

(reduces the activity of myosin light-chain kinase) and activation of myosin light chain phosphatase. This promotes **myosin light-chain dephosphorylation** and vascular smooth muscle **relaxation**.

(Choice A) Actin phosphorylation has no role in smooth or skeletal muscle relaxation. In smooth muscle, a stimulus to contract leads to increased intracellular calcium, which leads to myosin phosphorylation. Once myosin is phosphorylated, it is able to bind directly to actin and cause muscle contraction.

(Choice B) Calcium release from sarcoplasmic reticulum would lead to increased contraction of the cardiac myocytes. It is not involved in the mechanism of action of nitrates on vascular smooth muscle cells.

(Choice C) Nitrates do not cause an increase in cyclic mononucleotide degradation. On the contrary, they activate guanylate cyclase and promote conversion of GTP to cGMP, which ultimately leads to smooth muscle relaxation.

(Choice D) Inositol triphosphate binds to its receptor on the endoplasmic reticulum and leads to the release of Ca^{2+} into the cytoplasm. In vascular smooth muscle cells, this increased concentration of cytoplasmic Ca^{2+} results in increased smooth muscle contraction.

(Choice F) Tyrosine kinases play a role in a wide variety of intracellular processes and pathways. The effects of insulin and insulin-like growth factor occur via activation of receptor tyrosine kinases, which in turn cause phosphorylation of tyrosine residues on intracellular proteins important for signal transduction.

Educational objective:
Nitrates (via conversion to nitric oxide) activate guanylate cyclase and increase intracellular levels of cyclic guanosine monophosphate (cGMP). Increased levels of cGMP lead to myosin light-chain dephosphorylation, resulting in vascular smooth muscle relaxation.

References

- Identification of the enzymatic mechanism of nitroglycerin bioactivation.

Pharmacology	Cardiovascular System	Nitrates
Subject	System	Topic

Copyright © UWorld. All rights reserved.

1
2
3
4
5
6
7
8
9
10
11
12
13
14
15
16
17
18
19
20
21
22
23
24
25
26
27
28
29
30
31

An 82-year-old man is brought to the emergency department after a syncopal episode. He has no chest pain or dyspnea but has severe constipation of recent onset. He was hospitalized 2 weeks ago for atrial fibrillation with rapid ventricular response and was discharged home with oral medications after appropriate management. His past medical history is also significant for hypertension and severe chronic obstructive pulmonary disease requiring oxygen therapy. His blood pressure is 105/60 mm Hg and pulse is 50/min. Examination reveals bilateral decreased breath sounds, no wheezing, and normal heart sounds. ECG shows new-onset second-degree atrioventricular block. Which of the following drugs is the most likely cause of his current condition?

A. Amlodipine
B. Diltiazem
C. Indapamide
D. Lidocaine
E. Propranolol
F. Terazosin
G. Valsartan

Submit

1
2
3
4
5
6
7
8
9
10
11
12
13
14
15
16
17
18
19
20
21
22
23
24
25
26
27
28
29
30
31

An 82-year-old man is brought to the emergency department after a syncopal episode. He has no chest pain or dyspnea but has severe constipation of recent onset. He was hospitalized 2 weeks ago for atrial fibrillation with rapid ventricular response and was discharged home with oral medications after appropriate management. His past medical history is also significant for hypertension and severe chronic obstructive pulmonary disease requiring oxygen therapy. His blood pressure is 105/60 mm Hg and pulse is 50/min. Examination reveals bilateral decreased breath sounds, no wheezing, and normal heart sounds. ECG shows new-onset second-degree atrioventricular block. Which of the following drugs is the most likely cause of his current condition?

- A. Amlodipine (12%)
- ✓ B. Diltiazem (45%)
- C. Indapamide (3%)
- D. Lidocaine (8%)
- E. Propranolol (27%)
- F. Terazosin (2%)
- G. Valsartan (1%)

Omitted
Correct answer
B

45%
Answered correctly

01 sec
Time Spent

03/16/2020
Last Updated

Explanation

This patient's severe constipation and new-onset second-degree atrioventricular (AV) block (causing syncope) in the setting of new medication use

This patient's severe constipation and new-onset second-degree atrioventricular (AV) block (causing syncope) in the setting of new medication use for atrial fibrillation (AF) is likely due to **calcium channel blocker (CCB) therapy**. **Diltiazem** and **verapamil** are nondihydropyridine CCBs that are frequently used for hypertension, angina pectoris, and supraventricular arrhythmias (atrial flutter, AF, paroxysmal supraventricular tachycardia).

These drugs exert their primary action by blocking the **L-type calcium channels**, thereby decreasing phase 0 depolarization and conduction velocity in the sinoatrial and AV nodes. This leads to **slowing of the sinus rate** and conduction through the AV node, which can then cause bradycardia and varying degrees of AV block. The drugs also have a **negative inotropic effect** and are relatively contraindicated in patients with congestive heart failure due to left ventricular systolic dysfunction. **Constipation** is a major side effect of nondihydropyridine CCBs (verapamil > diltiazem).

(Choice A) Amlodipine is a dihydropyridine CCB that has a predominant vasodilator effect with little or no negative effect on cardiac conduction or contractility. The major side effects of dihydropyridines include headache, dizziness, flushing, and peripheral edema.

(Choice C) Indapamide is a thiazide diuretic used for treatment of hypertension. It has no role in the management of AF.

(Choice D) Lidocaine is occasionally used in management of symptomatic ventricular arrhythmias, usually in the setting of acute myocardial infarction. It is not used in management of atrial arrhythmias.

(Choice E) Beta blockers (BBs) are commonly used for heart rate control in patients with AF and can cause or worsen AV block. However, propranolol is a nonselective BB that impairs bronchodilation and would not have been prescribed to this patient with asthma severe chronic obstructive pulmonary disease. In addition, constipation is not a significant side effect of BB therapy.

(Choice F) Terazosin is an alpha-1 adrenergic antagonist used in the treatment of benign prostatic hyperplasia and mild to moderate hypertension. Major side effects include lightheadedness and orthostatic hypotension.

(Choice G) Valsartan is an angiotensin II receptor blocker used in management of hypertension and heart failure due to left ventricular systolic dysfunction. Common side effects include hypotension and hyperkalemia.

Educational objective:
Common side effects of nondihydropyridine calcium channel blockers (eg, diltiazem, verapamil) include constipation, bradycardia, atrioventricular conduction block (negative chronotropic effect), and worsening of heart failure in patients with reduced left ventricular function (negative inotropic effect).

for atrial fibrillation (AF) is likely due to **calcium channel blocker (CCB) therapy**. **Diltiazem** and **verapamil** are nondihydropyridine CCBs that are frequently used for hypertension, angina pectoris, and supraventricular arrhythmias (atrial flutter, AF, paroxysmal supraventricular tachycardia).

These drugs exert their primary action by blocking the **L-type calcium channels**, thereby decreasing phase 0 depolarization and conduction velocity in the sinoatrial and AV nodes. This leads to **slowing of the sinus rate** and conduction through the AV node, which can then cause bradycardia and varying degrees of AV block. The drugs also have a **negative inotropic effect** and are relatively contraindicated in patients with congestive heart failure due to left ventricular systolic dysfunction. **Constipation** is a major side effect of nondihydropyridine CCBs (verapamil > diltiazem).

(Choice A) Amlodipine is a dihydropyridine CCB that has a predominant vasodilator effect with little or no negative effect on cardiac conduction or contractility. The major side effects of dihydropyridines include headache, dizziness, flushing, and peripheral edema.

(Choice C) Indapamide is a thiazide diuretic used for treatment of hypertension. It has no role in the management of AF.

(Choice D) Lidocaine is occasionally used in management of symptomatic ventricular arrhythmias, usually in the setting of acute myocardial infarction. It is not used in management of atrial arrhythmias.

(Choice E) Beta blockers (BBs) are commonly used for heart rate control in patients with AF and can cause or worsen AV block. However, propranolol is a nonselective BB that impairs bronchodilation and would not have been prescribed to this patient with asthma severe chronic obstructive pulmonary disease. In addition, constipation is not a significant side effect of BB therapy.

(Choice F) Terazosin is an alpha-1 adrenergic antagonist used in the treatment of benign prostatic hyperplasia and mild to moderate hypertension. Major side effects include lightheadedness and orthostatic hypotension.

(Choice G) Valsartan is an angiotensin II receptor blocker used in management of hypertension and heart failure due to left ventricular systolic dysfunction. Common side effects include hypotension and hyperkalemia.

Educational objective:
Common side effects of nondihydropyridine calcium channel blockers (eg, diltiazem, verapamil) include constipation, bradycardia, atrioventricular conduction block (negative chronotropic effect), and worsening of heart failure in patients with reduced left ventricular function (negative inotropic effect).

References

1
2
3
4
5
6
7
8
9
10
11
12
13
14
15
16
17
18
19
20
21
22
23
24
25
26
27
28
29
30
31

A 6-day-old boy in the neonatal intensive care unit has a heart murmur. The patient was born at 27 weeks gestation and intubated due to surfactant deficiency. Birth weight was 1.14 kg (2 lb 8 oz). Temperature is 37 C (98.6 F), blood pressure is 66/12 mm Hg, and pulse is 182/min. A continuous murmur with systolic accentuation is best heard at the left heart border. There are bounding femoral and palmar pulses. Abdominal examination is unremarkable. Blood culture is sterile. Elevated levels of which of the following substances is most likely contributing to this patient's condition?

A. Endothelin-1
B. Leukotriene D4
C. Prostaglandin E2
D. Thromboxane A2
E. Vasopressin

Submit

A 6-day-old boy in the neonatal intensive care unit has a heart murmur. The patient was born at 27 weeks gestation and intubated due to surfactant deficiency. Birth weight was 1.14 kg (2 lb 8 oz). Temperature is 37 C (98.6 F), blood pressure is 66/12 mm Hg, and pulse is 182/min. A continuous murmur with systolic accentuation is best heard at the left heart border. There are bounding femoral and palmar pulses. Abdominal examination is unremarkable. Blood culture is sterile. Elevated levels of which of the following substances is most likely contributing to this patient's condition?

- A. Endothelin-1 (4%)
- B. Leukotriene D4 (1%)
- ✓ C. Prostaglandin E2 (90%)
- D. Thromboxane A2 (2%)
- E. Vasopressin (1%)

Omitted
Correct answer
C

90%
Answered correctly

02 secs
Time Spent

04/09/2020
Last Updated

Explanation

Patent ductus arteriosus	
Etiology	• Ductus is patent in utero due to PGE_2 production by placenta • PDA results when PGE_2 levels fail to decrease after delivery
	• Continuous, machinelike murmur (left-to-right shunting)

Patent ductus arteriosus	
Etiology	• Ductus is patent in utero due to PGE_2 production by placenta • PDA results when PGE_2 levels fail to decrease after delivery
Clinical features	• Continuous, machinelike murmur (left-to-right shunting) • Wide pulse pressure & bounding pulses • Signs of cardiovascular strain (tachycardia, cardiomegaly), Eisenmenger (right-to-left shunting; late finding)

PDA = patent ductus arteriosus; **PGE2** = prostaglandin E_2.

This preterm infant has a continuous murmur, bounding pulses, and a wide pulse pressure; findings consistent with a patent ductus arteriosus (PDA).

The ductus arteriosus is a fetal vascular connection that connects the trunk of the pulmonary artery to the proximal descending aorta; it shunts right ventricular output directly into the systemic circulation, bypassing the lungs. **Patency** of the ductus arteriosus is maintained in utero due to smooth muscle dilation induced by **placental prostaglandin E2** (PGE2) and the relative hypoxemia of the fetal circulation. After birth, closure of the ductus arteriosus is normally initiated by loss of placental PGE2 and the vasoconstrictive effects of increased systemic oxygen levels (eg, increased endothelin-1 production) **(Choice A)**.

Persistence of the ductus arteriosus after birth occurs most commonly in **preterm** infants and is associated with elevated postnatal PGE2 and/or increased sensitivity to prostaglandins. The decrease in pulmonary vascular resistance caused by lung inflation results in reversal of flow across the ductus arteriosus, with blood flowing from the aorta into the pulmonary circulation (ie, **left-to-right shunt**); this results in a continuous machinelike murmur and lower diastolic pressures (responsible for pulse findings).

Although individuals with small shunts may be asymptomatic, increased blood flow across the PDA can eventually lead to heart failure or progressive pulmonary hypertension (causing Eisenmenger syndrome in older patients). Nonsteroidal anti-inflammatory drugs (eg, **indomethacin**, ibuprofen) are sometimes used to help initiate PDA **closure** by inhibiting the synthesis of PGE2.

(Choice B) Treatment with nonsteroidal anti-inflammatory drugs can increase leukotriene synthesis; elevated leukotriene D4 levels cause vasoconstriction and would, therefore, facilitate closure of a PDA.

This preterm infant has a continuous murmur, bounding pulses, and a wide pulse pressure; findings consistent with a patent ductus arteriosus (PDA).

The ductus arteriosus is a fetal vascular connection that connects the trunk of the pulmonary artery to the proximal descending aorta; it shunts right ventricular output directly into the systemic circulation, bypassing the lungs. **Patency** of the ductus arteriosus is maintained in utero due to smooth muscle dilation induced by **placental prostaglandin E2** (PGE2) and the relative hypoxemia of the fetal circulation. After birth, closure of the ductus arteriosus is normally initiated by loss of placental PGE2 and the vasoconstrictive effects of increased systemic oxygen levels (eg, increased endothelin-1 production) **(Choice A)**.

Persistence of the ductus arteriosus after birth occurs most commonly in **preterm** infants and is associated with elevated postnatal PGE2 and/or increased sensitivity to prostaglandins. The decrease in pulmonary vascular resistance caused by lung inflation results in reversal of flow across the ductus arteriosus, with blood flowing from the aorta into the pulmonary circulation (ie, **left-to-right shunt**); this results in a continuous machinelike murmur and lower diastolic pressures (responsible for pulse findings).

Although individuals with small shunts may be asymptomatic, increased blood flow across the PDA can eventually lead to heart failure or progressive pulmonary hypertension (causing Eisenmenger syndrome in older patients). Nonsteroidal anti-inflammatory drugs (eg, **indomethacin**, ibuprofen) are sometimes used to help initiate PDA **closure** by inhibiting the synthesis of PGE2.

(Choice B) Treatment with nonsteroidal anti-inflammatory drugs can increase leukotriene synthesis; elevated leukotriene D4 levels cause vasoconstriction and would, therefore, facilitate closure of a PDA.

(Choice D) Thromboxane A2 increases platelet production and aggregation. Much of the antithrombotic effect of aspirin is through its inhibition of cyclooxygenase enzymes, resulting in decreased thromboxane A2 synthesis.

(Choice E) Vasopressin (ie, antidiuretic hormone) promotes water reabsorption in the kidney and causes arteriolar constriction. Elevated levels cause water retention and hyponatremia, but would not contribute to the pathogenesis of PDA.

Educational objective:
Patency of the ductus arteriosus is maintained in utero due to placental production of prostaglandin E2 (PGE2) and low oxygen levels in the fetal circulation. Persistence after birth (ie, patent ductus arteriosus) is associated with elevated postnatal PGE2 and typically presents with a continuous murmur, widened pulse pressure, and bounding pulses in a preterm infant.

The ductus arteriosus is a fetal vascular connection that connects the trunk of the pulmonary artery to the proximal descending aorta; it shunts right ventricular output directly into the systemic circulation, bypassing the lungs. **Patency** of the ductus arteriosus is maintained in utero due to smooth muscle dilation induced by **placental prostaglandin E2** (PGE2) and the relative hypoxemia of the fetal circulation. After birth, closure of the ductus arteriosus is normally initiated by loss of placental PGE2 and the vasoconstrictive effects of increased systemic oxygen levels (eg, increased endothelin-1 production) **(Choice A)**.

Persistence of the ductus arteriosus after birth occurs most commonly in **preterm** infants and is associated with elevated postnatal PGE2 and/or increased sensitivity to prostaglandins. The decrease in pulmonary vascular resistance caused by lung inflation results in reversal of flow across the ductus arteriosus, with blood flowing from the aorta into the pulmonary circulation (ie, **left-to-right shunt**); this results in a continuous machinelike murmur and lower diastolic pressures (responsible for pulse findings).

Although individuals with small shunts may be asymptomatic, increased blood flow across the PDA can eventually lead to heart failure or progressive pulmonary hypertension (causing Eisenmenger syndrome in older patients). Nonsteroidal anti-inflammatory drugs (eg, **indomethacin**, ibuprofen) are sometimes used to help initiate PDA **closure** by inhibiting the synthesis of PGE2.

(Choice B) Treatment with nonsteroidal anti-inflammatory drugs can increase leukotriene synthesis; elevated leukotriene D4 levels cause vasoconstriction and would, therefore, facilitate closure of a PDA.

(Choice D) Thromboxane A2 increases platelet production and aggregation. Much of the antithrombotic effect of aspirin is through its inhibition of cyclooxygenase enzymes, resulting in decreased thromboxane A2 synthesis.

(Choice E) Vasopressin (ie, antidiuretic hormone) promotes water reabsorption in the kidney and causes arteriolar constriction. Elevated levels cause water retention and hyponatremia, but would not contribute to the pathogenesis of PDA.

Educational objective:
Patency of the ductus arteriosus is maintained in utero due to placental production of prostaglandin E2 (PGE2) and low oxygen levels in the fetal circulation. Persistence after birth (ie, patent ductus arteriosus) is associated with elevated postnatal PGE2 and typically presents with a continuous murmur, widened pulse pressure, and bounding pulses in a preterm infant.

References

- Current perspectives on pathobiology of patent ductus arteriosus.
- Managing the patent ductus arteriosus: current treatment options

- Signs of cardiovascular strain (tachycardia, cardiomegaly); Eisenmenger (right-to-left shunting, late finding)

Exhibit Display

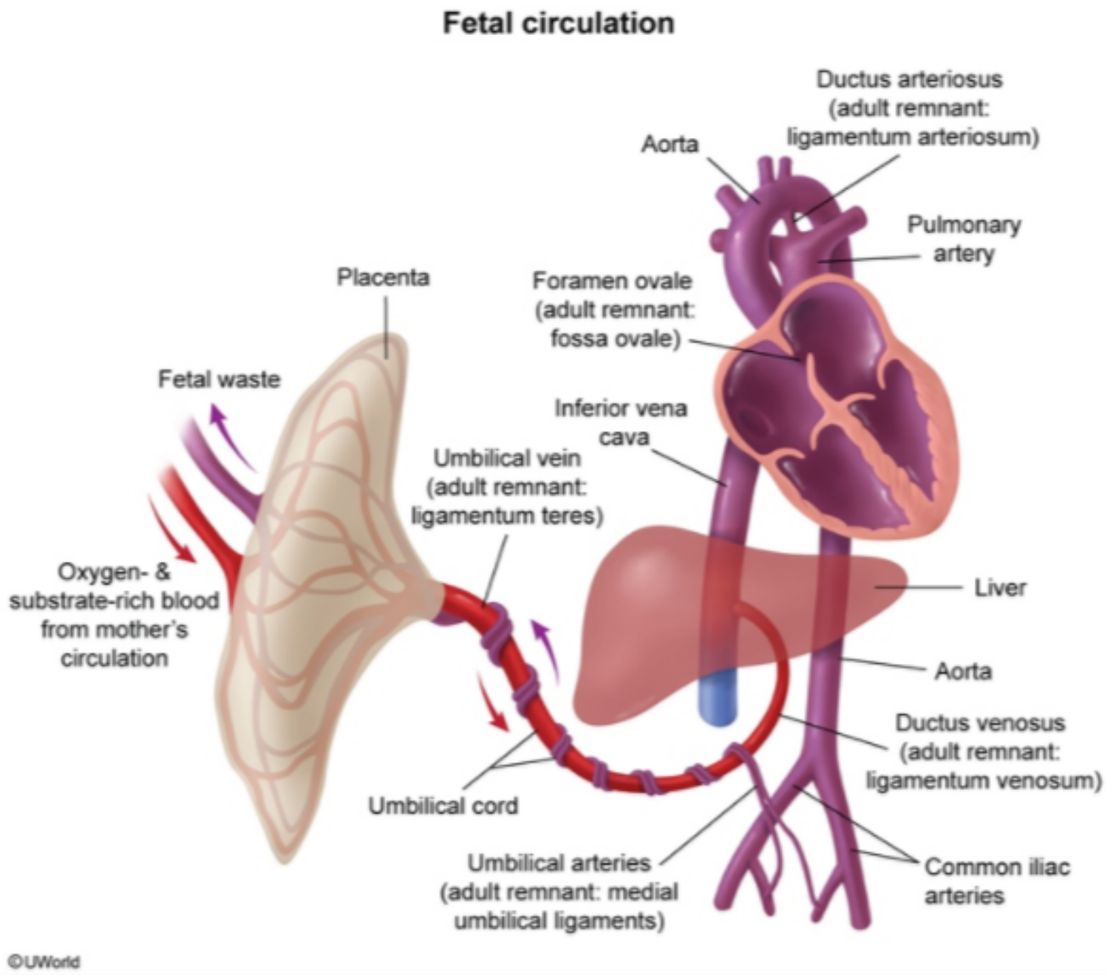

Zoom In | Zoom Out | Reset | Add To New Card | Existing Card

Patency of the ductus arteriosus is maintained in utero due to placental production of prostaglandin E2 (PGE2) and low oxygen levels in the fetal

- Signs of cardiovascular strain (tachycardia, cardiomegaly); Eisenmenger (right-to-left shunting, late finding)

Exhibit Display

Patent ductus arteriosus

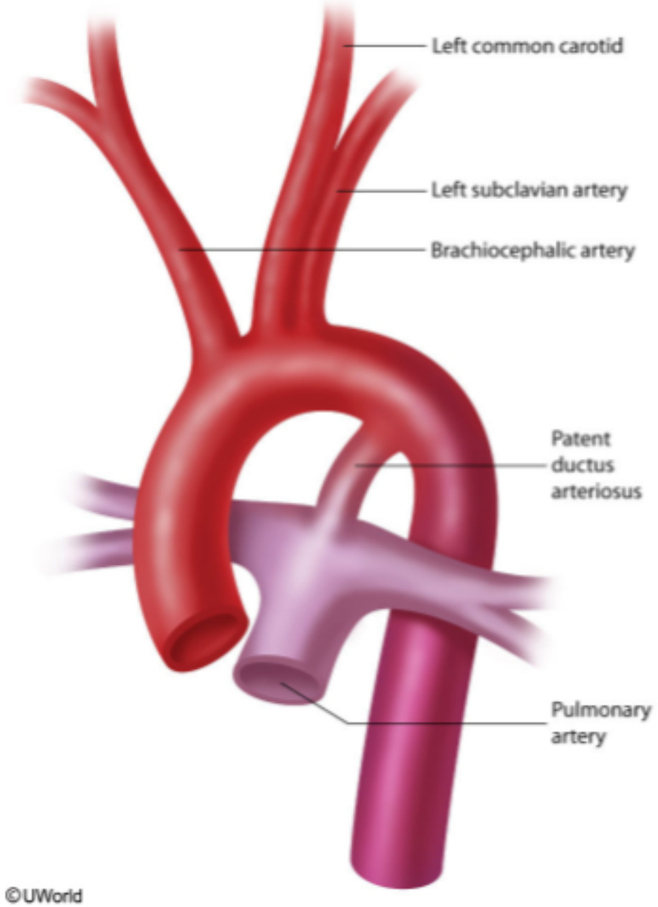

©UWorld

Zoom In | Zoom Out | Reset | Add To New Card | Existing Card

Patency of the ductus arteriosus is maintained in utero due to placental production of prostaglandin E2 (PGE2) and low oxygen levels in the fetal

- Signs of cardiovascular strain (tachycardia, cardiomegaly); Eisenmenger (right-to-left shunting, late finding)

Exhibit Display

Arachidonic acid pathway in NSAID-exacerbated respiratory disease

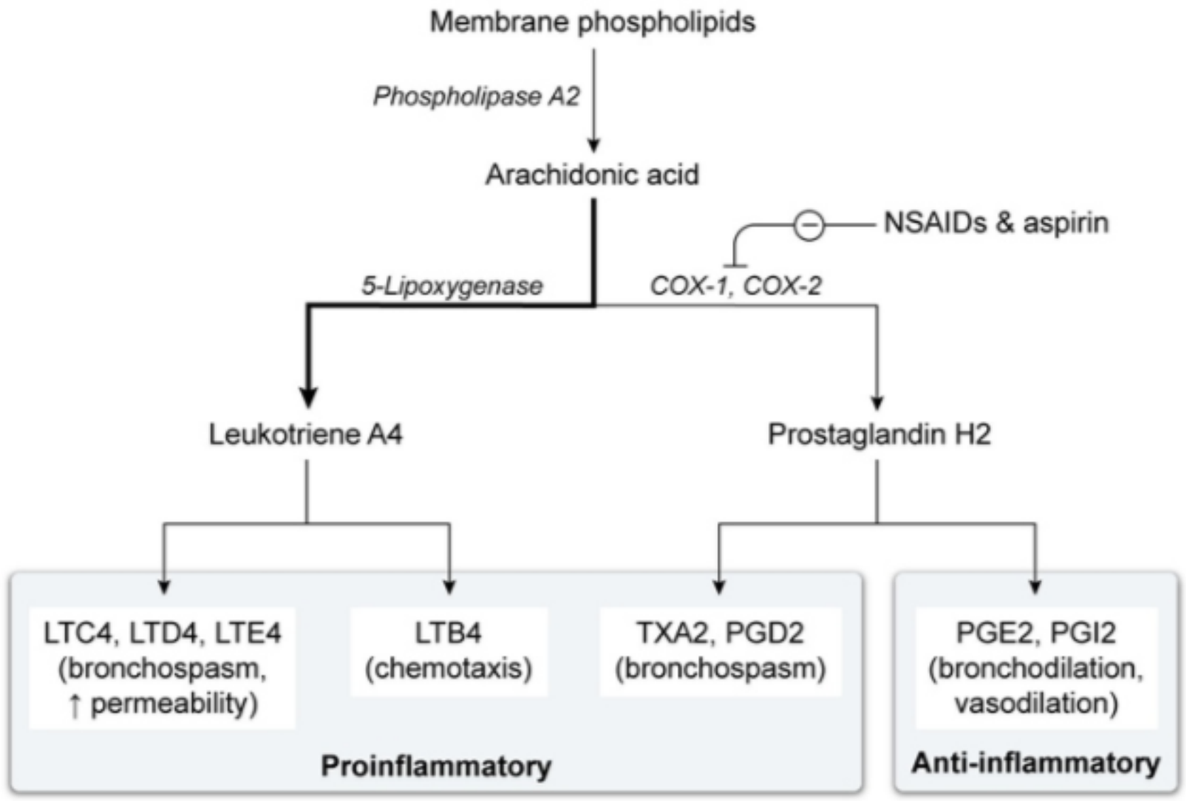

COX = cyclooxygenase; **LT** = leukotriene; **NSAIDs** = nonsteroidal anti-inflammatory drugs; **PG** = prostaglandin; **TX** = thromboxane.

©UWorld

Zoom In Zoom Out Reset Add To New Card | Existing Card

Patency of the ductus arteriosus is maintained in utero due to placental production of prostaglandin E2 (PGE2) and low oxygen levels in the fetal

the ductus arteriosus is normally initiated by loss of placental PGE2 and the vasoconstrictive effects of increased systemic oxygen levels (eg, increased endothelin-1 production) **(Choice A)**.

Persistence of the ductus arteriosus after birth occurs most commonly in **preterm** infants and is associated with elevated postnatal PGE2 and/or increased sensitivity to prostaglandins. The decrease in pulmonary vascular resistance caused by lung inflation results in reversal of flow across the ductus arteriosus, with blood flowing from the aorta into the pulmonary circulation (ie, **left-to-right shunt**); this results in a continuous machinelike murmur and lower diastolic pressures (responsible for pulse findings).

Although individuals with small shunts may be asymptomatic, increased blood flow across the PDA can eventually lead to heart failure or progressive pulmonary hypertension (causing Eisenmenger syndrome in older patients). Nonsteroidal anti-inflammatory drugs (eg, **indomethacin**, ibuprofen) are sometimes used to help initiate PDA **closure** by inhibiting the synthesis of PGE2.

(Choice B) Treatment with nonsteroidal anti-inflammatory drugs can increase leukotriene synthesis; elevated leukotriene D4 levels cause vasoconstriction and would, therefore, facilitate closure of a PDA.

(Choice D) Thromboxane A2 increases platelet production and aggregation. Much of the antithrombotic effect of aspirin is through its inhibition of cyclooxygenase enzymes, resulting in decreased thromboxane A2 synthesis.

(Choice E) Vasopressin (ie, antidiuretic hormone) promotes water reabsorption in the kidney and causes arteriolar constriction. Elevated levels cause water retention and hyponatremia, but would not contribute to the pathogenesis of PDA.

Educational objective:
Patency of the ductus arteriosus is maintained in utero due to placental production of prostaglandin E2 (PGE2) and low oxygen levels in the fetal circulation. Persistence after birth (ie, patent ductus arteriosus) is associated with elevated postnatal PGE2 and typically presents with a continuous murmur, widened pulse pressure, and bounding pulses in a preterm infant.

References

- Current perspectives on pathobiology of patent ductus arteriosus.
- Managing the patent ductus arteriosus: current treatment options.
- Understanding the pathobiology in patent ductus arteriosus in prematurity—beyond prostaglandins and oxygen.

A 76-year-old man is brought to the emergency department with severe midsternal chest pain and diaphoresis. Past medical history is significant for hypertension, type 2 diabetes mellitus, and asymptomatic right carotid artery stenosis. His blood pressure is 120/70 mm Hg and pulse is 75/min. Lungs are clear on auscultation. ECG shows ST segment elevations greater than 1 mm in leads II, III, and aVF. The patient receives aspirin immediately upon arrival followed by alteplase and a low-dose beta blocker. A single dose of intravenous morphine is given for pain control. Several hours later, the patient is found to be comatose with asymmetric pupils and an irregular breathing pattern. What is the most likely cause of this patient's current condition?

- A. Carotid artery thrombosis
- B. Dissection of the ascending aorta
- C. Interventricular septum perforation
- D. Intracerebral hemorrhage
- E. Myocardial reperfusion injury
- F. Opioid overdose
- G. Pulmonary embolism

Submit

A 76-year-old man is brought to the emergency department with severe midsternal chest pain and diaphoresis. Past medical history is significant for hypertension, type 2 diabetes mellitus, and asymptomatic right carotid artery stenosis. His blood pressure is 120/70 mm Hg and pulse is 75/min. Lungs are clear on auscultation. ECG shows ST segment elevations greater than 1 mm in leads II, III, and aVF. The patient receives aspirin immediately upon arrival followed by alteplase and a low-dose beta blocker. A single dose of intravenous morphine is given for pain control. Several hours later, the patient is found to be comatose with asymmetric pupils and an irregular breathing pattern. What is the most likely cause of this patient's current condition?

- A. Carotid artery thrombosis (12%)
- B. Dissection of the ascending aorta (1%)
- C. Interventricular septum perforation (1%)
- ✓ D. Intracerebral hemorrhage (57%)
- E. Myocardial reperfusion injury (7%)
- F. Opioid overdose (17%)
- G. Pulmonary embolism (2%)

Omitted
Correct answer
D

57%
Answered correctly

02 secs
Time Spent

02/17/2020
Last Updated

Explanation

This patient's presentation of chest pain and diaphoresis along with a history of systemic atherosclerosis and type 2 diabetes mellitus is suggestive

This patient's presentation of chest pain and diaphoresis along with a history of systemic atherosclerosis and type 2 diabetes mellitus is suggestive of acute coronary syndrome. ECG findings are consistent with an inferior ST elevation **myocardial infarction** (STEMI). Percutaneous coronary intervention (PCI) or **fibrinolysis** to achieve myocardial reperfusion is recommended for acute MI patients who present within 12 hours of symptom onset. **PCI is preferred** over fibrinolytic therapy due to lower rates of intracerebral hemorrhage (ICH) and recurrent MI; however, it may not be available at all institutions. In such cases, treatment with fibrinolytics (tenecteplase, alteplase) improves clinical outcomes in the absence of contraindications (eg, gastrointestinal bleeding, recent surgery).

Alteplase binds fibrin in the thrombus (clot) and **converts** entrapped **plasminogen to plasmin**. Plasmin hydrolyzes key bonds in the fibrin matrix **causing clot lysis** and restoration of coronary arterial blood flow. The most common adverse effect of fibrinolytic therapy is **hemorrhage**. This patient has signs of ICH, such as decreased level of consciousness, asymmetric pupils, and irregular breathing.

(Choice A) Carotid artery thrombosis can cause an ischemic stroke with fluctuating symptoms that may progress with periods of improvement. Abrupt onset of symptoms along with loss of consciousness after treatment with thrombolytics favors ICH over thrombotic stroke.

(Choice B) Aortic dissection typically presents with severe, tearing chest pain that radiates to the interscapular area. It occurs most commonly in patients with hypertension and Marfan/Ehlers-Danlos syndrome. Chest x-ray typically reveals a widened mediastinum.

(Choice C) Interventricular septum perforation results in a left-to-right shunt and symptoms of acute heart failure. It presents with chest pain, dyspnea, symptoms of cardiogenic shock, and a harsh holosystolic murmur on the left sternal border.

(Choice E) Reperfusion of ischemic myocardium may result in paradoxical cardiomyocyte dysfunction, a phenomenon known as reperfusion injury. This can occur in patients treated with PCI, thrombolytics, or coronary artery bypass grafting. Clinical manifestations include arrhythmias, myocardial stunning (prolonged but reversible contractile dysfunction), and myocyte death.

(Choice F) Opioid overdose typically presents with small, constricted pupils (miosis) and respiratory depression (respirations usually <12/min).

(Choice G) Pulmonary embolism (PE) presents with acute onset of dyspnea, pleuritic chest pain, and possibly hemoptysis. Tachycardia, hypotension, cyanosis, and loss of consciousness can occur when PE is severe.

Educational objective:
Fibrinolytic therapy for acute ST segment elevation myocardial infarction is a reasonable reperfusion technique for patients with no contraindications to thrombolysis. Fibrinolytic agents such as alteplase bind to fibrin in the thrombus (clot) and activate plasmin, which leads to

contraindications (eg, gastrointestinal bleeding, recent surgery).

Alteplase binds fibrin in the thrombus (clot) and **converts** entrapped **plasminogen to plasmin**. Plasmin hydrolyzes key bonds in the fibrin matrix **causing clot lysis** and restoration of coronary arterial blood flow. The most common adverse effect of fibrinolytic therapy is **hemorrhage**. This patient has signs of ICH, such as decreased level of consciousness, asymmetric pupils, and irregular breathing.

(Choice A) Carotid artery thrombosis can cause an ischemic stroke with fluctuating symptoms that may progress with periods of improvement. Abrupt onset of symptoms along with loss of consciousness after treatment with thrombolytics favors ICH over thrombotic stroke.

(Choice B) Aortic dissection typically presents with severe, tearing chest pain that radiates to the interscapular area. It occurs most commonly in patients with hypertension and Marfan/Ehlers-Danlos syndrome. Chest x-ray typically reveals a widened mediastinum.

(Choice C) Interventricular septum perforation results in a left-to-right shunt and symptoms of acute heart failure. It presents with chest pain, dyspnea, symptoms of cardiogenic shock, and a harsh holosystolic murmur on the left sternal border.

(Choice E) Reperfusion of ischemic myocardium may result in paradoxical cardiomyocyte dysfunction, a phenomenon known as reperfusion injury. This can occur in patients treated with PCI, thrombolytics, or coronary artery bypass grafting. Clinical manifestations include arrhythmias, myocardial stunning (prolonged but reversible contractile dysfunction), and myocyte death.

(Choice F) Opioid overdose typically presents with small, constricted pupils (miosis) and respiratory depression (respirations usually <12/min).

(Choice G) Pulmonary embolism (PE) presents with acute onset of dyspnea, pleuritic chest pain, and possibly hemoptysis. Tachycardia, hypotension, cyanosis, and loss of consciousness can occur when PE is severe.

Educational objective:
Fibrinolytic therapy for acute ST segment elevation myocardial infarction is a reasonable reperfusion technique for patients with no contraindications to thrombolysis. Fibrinolytic agents such as alteplase bind to fibrin in the thrombus (clot) and activate plasmin, which leads to thrombolysis. The most common adverse effect of thrombolysis is hemorrhage (eg, gastrointestinal, intracerebral).

Pharmacology	Cardiovascular System	Myocardial infarction
Subject	System	Topic

Copyright © UWorld. All rights reserved.

A 72-year-old man is brought to the hospital due to severe substernal chest pain and shortness of breath for the last several hours. The pain started suddenly when he was outside working in the garden. Medical history includes diet-controlled diabetes mellitus and hypertension. Physical examination reveals bilateral crackles and a third heart sound. ECG shows ST elevation in multiple leads. The patient is diagnosed with an acute myocardial infarction complicated by acute severe heart failure. He is started on dobutamine infusion and prepared for coronary catheterization. Which of the following is most likely to be increased due to the medication used in this patient?

A. Cardiac diastolic filling time

B. Myocardial oxygen consumption

C. Peripheral vascular resistance

D. Pulmonary capillary wedge pressure

E. Right ventricular end diastolic pressure

Submit

A 72-year-old man is brought to the hospital due to severe substernal chest pain and shortness of breath for the last several hours. The pain started suddenly when he was outside working in the garden. Medical history includes diet-controlled diabetes mellitus and hypertension. Physical examination reveals bilateral crackles and a third heart sound. ECG shows ST elevation in multiple leads. The patient is diagnosed with an acute myocardial infarction complicated by acute severe heart failure. He is started on dobutamine infusion and prepared for coronary catheterization. Which of the following is most likely to be increased due to the medication used in this patient?

- A. Cardiac diastolic filling time (23%)
- ✓ B. Myocardial oxygen consumption (53%)
- C. Peripheral vascular resistance (8%)
- D. Pulmonary capillary wedge pressure (5%)
- E. Right ventricular end diastolic pressure (8%)

Omitted
Correct answer
B

53%
Answered correctly

02 secs
Time Spent

05/29/2020
Last Updated

Explanation

Dobutamine pharmacology

β agonist

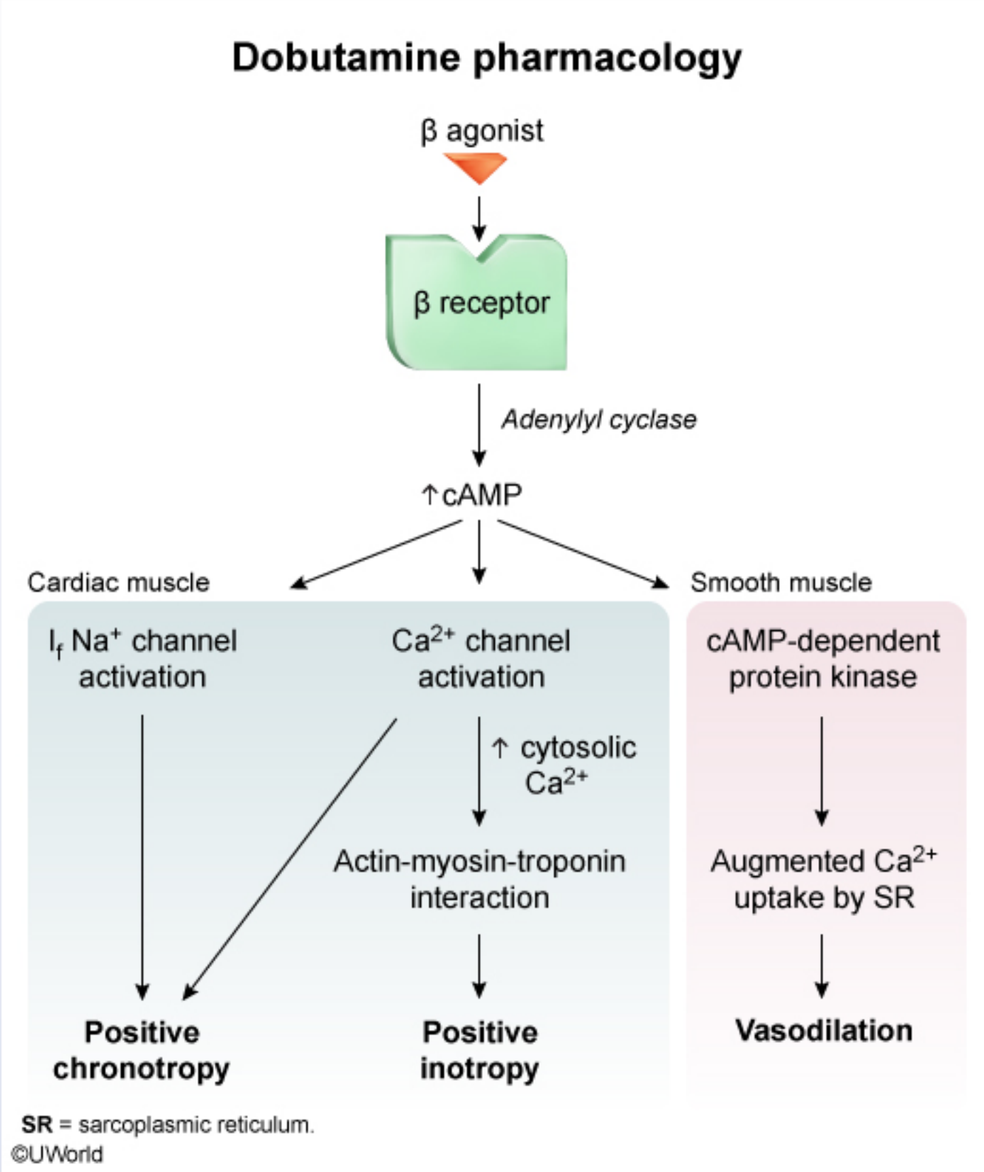
Dobutamine pharmacology
β agonist
β receptor
Adenylyl cyclase
↑cAMP
Cardiac muscle
Smooth muscle
I_f Na^+ channel activation
Ca^{2+} channel activation
↑ cytosolic Ca^{2+}
Actin-myosin-troponin interaction
Positive chronotropy
Positive inotropy
cAMP-dependent protein kinase
Augmented Ca^{2+} uptake by SR
Vasodilation
SR = sarcoplasmic reticulum.
©UWorld

©UWorld

Dobutamine is a beta adrenergic agonist with predominant activity on **beta-1 receptors**, weaker activity on beta-2 receptors, and minimal activity on alpha-1 receptors. It is used for management of refractory heart failure associated with severe left ventricular systolic dysfunction and **cardiogenic shock**. Stimulation of beta adrenergic receptors results in increased production of cAMP in target cells and causes the following effects:

- **Positive inotropy and chronotropy**: Increased cardiac contractility (potent effect) and heart rate (weaker effect), leading to increased cardiac output (improves end-organ perfusion) and decreased left ventricular filling pressures (improves pulmonary congestion/edema)
- Mild **vasodilation**: Decreased systemic vascular resistance that often causes a slight reduction in blood pressure; this avoids the increase in afterload seen with other vasopressor/inotropic agents (eg, norepinephrine) but limits its usefulness in severely hypotensive patients

The strong inotropic effect of dobutamine significantly **increases myocardial oxygen consumption**, which can trigger or exacerbate myocardial ischemia. As such, dobutamine should not be used routinely in patients with decompensated heart failure. However, in patients with cardiogenic shock, this drawback is often **outweighed** by improvement in cardiac output and end-organ perfusion.

(Choice A) Dobutamine is a weak chronotropic agent that causes an increase in heart rate. This leads to a decrease in cardiac diastolic filling time.

(Choice C) In the vasculature, the beta-2 agonist effects (vasodilation) of dobutamine are somewhat stronger than its alpha-1 agonist activity (vasoconstriction), resulting in overall mild vasodilation. The net hemodynamic effects are a decrease in systemic vascular resistance with or without a slight reduction in blood pressure.

(Choices D and E) Dobutamine causes decreased pulmonary capillary wedge pressure and left and right ventricular filling pressures due to the increased cardiac contractility and output.

Educational objective:
Dobutamine is a beta adrenergic agonist with predominant activity on beta-1 receptors. It causes an increase in heart rate and cardiac contractility, leading to an increase in myocardial oxygen consumption.

References

- Dobutamine in left heart failure after acute myocardial infarction.

- **Positive inotropy and chronotropy**: Increased cardiac contractility (potent effect) and heart rate (weaker effect), leading to increased cardiac output (improves end-organ perfusion) and decreased left ventricular filling pressures (improves pulmonary congestion/edema)
- Mild **vasodilation**: Decreased systemic vascular resistance that often causes a slight reduction in blood pressure; this avoids the increase in afterload seen with other vasopressor/inotropic agents (eg, norepinephrine) but limits its usefulness in severely hypotensive patients

The strong inotropic effect of dobutamine significantly **increases myocardial oxygen consumption**, which can trigger or exacerbate myocardial ischemia. As such, dobutamine should not be used routinely in patients with decompensated heart failure. However, in patients with cardiogenic shock, this drawback is often **outweighed** by improvement in cardiac output and end-organ perfusion.

(Choice A) Dobutamine is a weak chronotropic agent that causes an increase in heart rate. This leads to a decrease in cardiac diastolic filling time.

(Choice C) In the vasculature, the beta-2 agonist effects (vasodilation) of dobutamine are somewhat stronger than its alpha-1 agonist activity (vasoconstriction), resulting in overall mild vasodilation. The net hemodynamic effects are a decrease in systemic vascular resistance with or without a slight reduction in blood pressure.

(Choices D and E) Dobutamine causes decreased pulmonary capillary wedge pressure and left and right ventricular filling pressures due to the increased cardiac contractility and output.

Educational objective:
Dobutamine is a beta adrenergic agonist with predominant activity on beta-1 receptors. It causes an increase in heart rate and cardiac contractility, leading to an increase in myocardial oxygen consumption.

References

- Dobutamine in left heart failure after acute myocardial infarction.
- A review of cardiogenic shock in acute myocardial infarction.

Pharmacology	Cardiovascular System	Cardiogenic shock
Subject	System	Topic

A 56-year-old woman comes to clinic for follow-up of heart failure with reduced ejection fraction. In the last 3 months, the patient has been hospitalized twice due to acute decompensation of heart failure that required treatment with intravenous furosemide. Since her most recent discharge, she has been taking high doses of oral furosemide, but she continues to have progressive lower extremity edema and weight gain. Serum creatinine is 1.2 mg/dL and serum potassium is 4.1 mEq/L. The addition of metolazone may assist in treating this patient because of which of the following effects of loop diuretics?

- A. Increased calcium delivery to the distal tubules
- B. Increased sodium delivery to the distal tubules
- C. Increased tubular reabsorption of bicarbonate
- D. Increased tubular reabsorption of uric acid
- E. Reduced tubular reabsorption of glucose
- F. Reduced tubular reabsorption of potassium

Submit

A 56-year-old woman comes to clinic for follow-up of heart failure with reduced ejection fraction. In the last 3 months, the patient has been hospitalized twice due to acute decompensation of heart failure that required treatment with intravenous furosemide. Since her most recent discharge, she has been taking high doses of oral furosemide, but she continues to have progressive lower extremity edema and weight gain. Serum creatinine is 1.2 mg/dL and serum potassium is 4.1 mEq/L. The addition of metolazone may assist in treating this patient because of which of the following effects of loop diuretics?

- A. Increased calcium delivery to the distal tubules (11%)
- ✓ B. Increased sodium delivery to the distal tubules (60%)
- C. Increased tubular reabsorption of bicarbonate (3%)
- D. Increased tubular reabsorption of uric acid (2%)
- E. Reduced tubular reabsorption of glucose (2%)
- F. Reduced tubular reabsorption of potassium (18%)

Omitted
Correct answer
B

60%
Answered correctly

01 sec
Time Spent

03/04/2020
Last Updated

Explanation

Diuretic effects on total body electrolyte levels					
Diuretic type	Na^+	K^+	HCO_3^-	Ca^{2+}	Uric acid

Diuretic effects on total body electrolyte levels					
Diuretic type	**Na^+**	**K^+**	**HCO_3^-**	**Ca^{2+}**	**Uric acid**
Loop (eg, furosemide)	↓↓↓	↓↓	↑↑	↓	↑
Thiazide (eg, HCTZ, metolazone)	↓↓	↓	↑	↑	↑
Potassium sparing (eg, spironolactone, amiloride)	↓	↑	↓	—	—
Carbonic anhydrase inhibitor (eg, acetazolamide)	↓	↓	↓	—	—
HCTZ = hydrochlorothiazide.					

This patient has **decompensated heart failure** with ongoing volume retention despite high doses of oral furosemide (ie, loop diuretic) therapy. **Thiazide diuretics**, especially metolazone, **potentiate the diuretic effect of loop diuretics** and can be helpful in treating refractory volume overload.

Sodium is the major determinant of **volume status**. Loop diuretics function by inhibiting the Na-K-2Cl cotransporter in the ascending limb of the loop of Henle to block sodium absorption and encourage the excretion of sodium and water in the urine. However, the sodium excretion caused by loop diuretics is limited by the reabsorption of sodium in the distal convoluted tubule; the Na-Cl cotransporter in the distal tubule counteracts some of the effect of loop diuretics by absorbing much of the sodium that is not absorbed in the loop of Henle. **Inhibition of the Na-Cl cotransporter** with metolazone **prevents reabsorption** of the **increased sodium delivered to the distal tubule**, significantly increasing total sodium excretion.

(Choice A) Loop diuretics inhibit calcium absorption in the loop of Henle, leading to increased calcium delivery to the distal tubule. However,

This patient has **decompensated heart failure** with ongoing volume retention despite high doses of oral furosemide (ie, loop diuretic) therapy. **Thiazide diuretics**, especially metolazone, **potentiate the diuretic effect of loop diuretics** and can be helpful in treating refractory volume overload.

Sodium is the major determinant of **volume status**. Loop diuretics function by inhibiting the Na-K-2Cl cotransporter in the ascending limb of the loop of Henle to block sodium absorption and encourage the excretion of sodium and water in the urine. However, the sodium excretion caused by loop diuretics is limited by the reabsorption of sodium in the distal convoluted tubule; the Na-Cl cotransporter in the distal tubule counteracts some of the effect of loop diuretics by absorbing much of the sodium that is not absorbed in the loop of Henle. **Inhibition of the Na-Cl cotransporter** with metolazone **prevents reabsorption** of the **increased sodium delivered to the distal tubule**, significantly increasing total sodium excretion.

(Choice A) Loop diuretics inhibit calcium absorption in the loop of Henle, leading to increased calcium delivery to the distal tubule. However, calcium has minimal effect on volume status. Thiazide diuretics increase calcium absorption in the distal tubule, making up for some of the calcium loss caused by loop diuretics.

(Choice C) Loop diuretics stimulate hydrogen ion excretion and bicarbonate reabsorption, creating a tendency toward metabolic alkalosis. Carbonic anhydrase inhibitors (eg, acetazolamide) block bicarbonate absorption in the proximal tubule and are sometimes used to minimize the metabolic alkalosis caused by loop diuretics.

(Choice D) Both loop and thiazide diuretics increase the reabsorption of uric acid and, therefore, may increase the risk of gout attacks.

(Choice E) Both loop and thiazide diuretics have minimal effect on tubular glucose reabsorption. Sodium-glucose cotransporter-2 inhibitors (eg, empagliflozin) block glucose resorption in the proximal tubule to lower serum glucose levels while also stimulating an osmotic diuresis.

(Choice F) The increased distal tubular delivery of sodium caused by loop diuretics stimulates increased potassium secretion by the principal cells in the late distal tubule and collecting duct. This potassium loss is amplified with the addition of a thiazide diuretic. Potassium-sparing diuretics (eg, spironolactone) can help offset the potassium loss caused by loop and thiazide diuretics.

Educational objective:
Thiazide diuretics, especially metolazone, potentiate the diuretic effect of loop diuretics (eg, furosemide) by blocking the reabsorption of the increased distal tubular sodium delivery caused by loop diuretics.

Exhibit Display

Site of inhibition for various diuretics

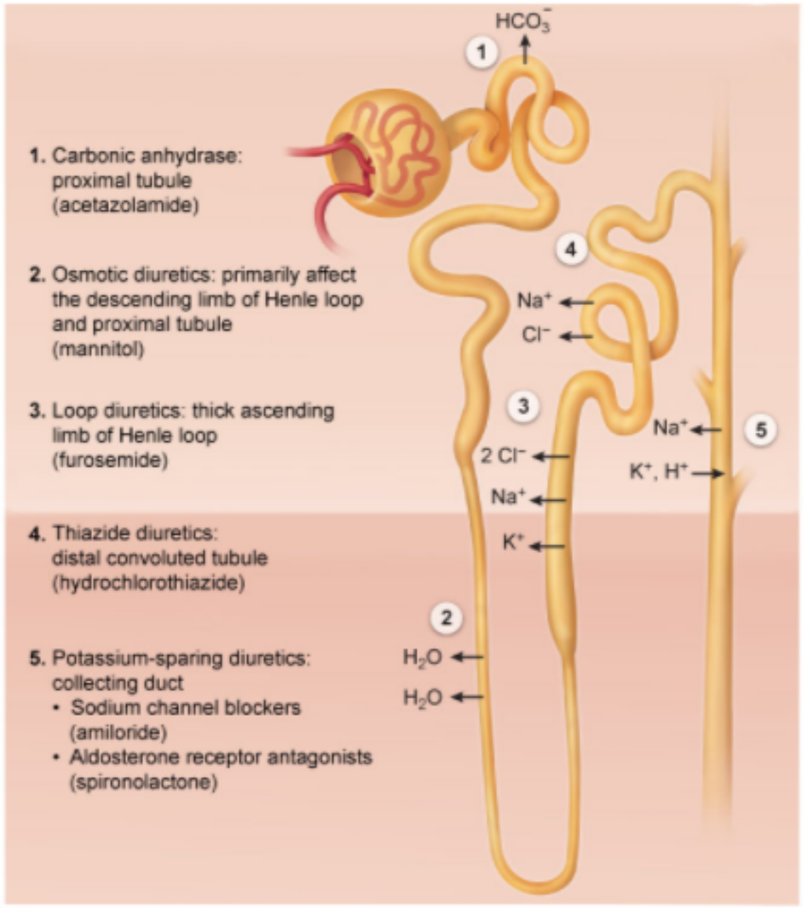

Zoom In Zoom Out Reset Add To Flash Card

increased distal tubular sodium delivery caused by loop diuretics.

by loop diuretics is limited by the reabsorption of sodium in the distal convoluted tubule; the Na-Cl cotransporter in the distal tubule counteracts some of the effect of loop diuretics by absorbing much of the sodium that is not absorbed in the loop of Henle. **Inhibition of the Na-Cl cotransporter** with metolazone **prevents reabsorption** of the **increased sodium delivered to the distal tubule**, significantly increasing total sodium excretion.

(Choice A) Loop diuretics inhibit calcium absorption in the loop of Henle, leading to increased calcium delivery to the distal tubule. However, calcium has minimal effect on volume status. Thiazide diuretics increase calcium absorption in the distal tubule, making up for some of the calcium loss caused by loop diuretics.

(Choice C) Loop diuretics stimulate hydrogen ion excretion and bicarbonate reabsorption, creating a tendency toward metabolic alkalosis. Carbonic anhydrase inhibitors (eg, acetazolamide) block bicarbonate absorption in the proximal tubule and are sometimes used to minimize the metabolic alkalosis caused by loop diuretics.

(Choice D) Both loop and thiazide diuretics increase the reabsorption of uric acid and, therefore, may increase the risk of gout attacks.

(Choice E) Both loop and thiazide diuretics have minimal effect on tubular glucose reabsorption. Sodium-glucose cotransporter-2 inhibitors (eg, empagliflozin) block glucose resorption in the proximal tubule to lower serum glucose levels while also stimulating an osmotic diuresis.

(Choice F) The increased distal tubular delivery of sodium caused by loop diuretics stimulates increased potassium secretion by the principal cells in the late distal tubule and collecting duct. This potassium loss is amplified with the addition of a thiazide diuretic. Potassium-sparing diuretics (eg, spironolactone) can help offset the potassium loss caused by loop and thiazide diuretics.

Educational objective:
Thiazide diuretics, especially metolazone, potentiate the diuretic effect of loop diuretics (eg, furosemide) by blocking the reabsorption of the increased distal tubular sodium delivery caused by loop diuretics.

References

- Combination of loop diuretics with thiazide-type diuretics in heart failure.

Pharmacology	Cardiovascular System	Loop diuretics
Subject	System	Topic

Copyright © UWorld. All rights reserved.

A 64-year-old man comes to the office due to exertional chest pain over the last 6 months. He is a lifelong 1 pack per day cigarette smoker and has a history of type 2 diabetes mellitus and peripheral artery disease. The patient undergoes treadmill exercise stress testing and develops substernal chest pain on moderate exertion accompanied by ECG changes that resolve immediately upon rest. He refuses invasive cardiac testing. The patient is started on low-dose aspirin therapy for secondary prevention of cardiovascular disease but experiences shortness of breath and wheezing with the medication. Which of the following is the best alternate therapy for this patient?

- A. Apixaban
- B. Cilostazol
- C. Clopidogrel
- D. Enoxaparin
- E. Eptifibatide
- F. Naproxen
- G. Warfarin

Submit

A 64-year-old man comes to the office due to exertional chest pain over the last 6 months. He is a lifelong 1 pack per day cigarette smoker and has a history of type 2 diabetes mellitus and peripheral artery disease. The patient undergoes treadmill exercise stress testing and develops substernal chest pain on moderate exertion accompanied by ECG changes that resolve immediately upon rest. He refuses invasive cardiac testing. The patient is started on low-dose aspirin therapy for secondary prevention of cardiovascular disease but experiences shortness of breath and wheezing with the medication. Which of the following is the best alternate therapy for this patient?

- A. Apixaban (2%)
- B. Cilostazol (6%)
- ✓ C. Clopidogrel (70%)
- D. Enoxaparin (5%)
- E. Eptifibatide (1%)
- F. Naproxen (5%)
- G. Warfarin (7%)

Omitted
Correct answer
C

70%
Answered correctly

02 secs
Time Spent

01/09/2020
Last Updated

Explanation

This patient's clinical history is consistent with stable angina (**angina pectoris**) due to underlying coronary heart disease (CHD). Patients with stable angina should be started on aspirin to decrease the risk of adverse cardiovascular events. Aspirin impairs prostaglandin synthesis by irreversibly inhibiting cyclooxygenase (COX). Inhibition of COX-1 in platelets prevents synthesis of thromboxane A2, a potent stimulator of platelet

This patient's clinical history is consistent with stable angina (**angina pectoris**) due to underlying coronary heart disease (CHD). Patients with stable angina should be started on aspirin to decrease the risk of adverse cardiovascular events. Aspirin impairs prostaglandin synthesis by irreversibly inhibiting cyclooxygenase (COX). Inhibition of COX-1 in platelets prevents synthesis of thromboxane A2, a potent stimulator of platelet aggregation and vasoconstriction. This helps reduce the risk of occlusive thrombus formation and subsequent myocardial infarction.

Some patients are unable to tolerate aspirin due to exacerbation of preexisting respiratory symptoms (eg, rhinitis, asthma) or development of allergic reactions (eg, urticaria, angioedema, anaphylaxis). In these patients, alternate antiplatelet agents should be used for prevention of cardiovascular events. **Clopidogrel** irreversibly **blocks** the $P2Y_{12}$ component of **ADP receptors** on the platelet surface and prevents platelet aggregation. Clopidogrel is as **effective as aspirin** for **prevention of cardiovascular events** and should be used in patients with aspirin allergy.

(Choices A and G) Apixaban is a direct factor Xa inhibitor that prevents platelet activation and fibrin clot formation. Warfarin inhibits an enzyme required for synthesis of active vitamin K, resulting in decreased synthesis of vitamin K-dependent clotting factors (II, VII, IX, and X). Both apixaban and warfarin are typically used for prevention and/or treatment of thromboembolic events, not coronary artery disease.

(Choice B) Cilostazol is a phosphodiesterase inhibitor that is occasionally used in patients with symptomatic peripheral vascular disease (ie, claudication).

(Choice D) Low molecular weight heparins (LMWHs; enoxaparin, dalteparin) are indirect thrombin inhibitors that bind with antithrombin and convert it from a slow to a rapid inactivator of thrombin and factor Xa. They are used in patients with acute coronary syndrome (unstable angina or myocardial infarction) but have no role in the management of patients with stable angina.

(Choice E) Eptifibatide is a platelet glycoprotein IIb/IIIa inhibitor that inhibits the final common pathway of platelet aggregation. Eptifibatide is occasionally used in some patients with acute coronary syndrome, but it is not used for patients with stable CHD.

(Choice F) Naproxen is a nonsteroidal anti-inflammatory drug (NSAID) that is used for pain management in patients with osteoarthritis. Use of both nonselective and selective COX-2 NSAIDs increases the risk of adverse cardiovascular events.

Educational objective:
Clopidogrel irreversibly blocks the $P2Y_{12}$ component of ADP receptors on the platelet surface and prevents platelet aggregation. Clopidogrel is as effective as aspirin in the prevention of cardiovascular events in patients with coronary heart disease.

This patient's clinical history is consistent with stable angina (**angina pectoris**) due to underlying coronary heart disease (CHD). Patients with stable angina should be started on aspirin to decrease the risk of adverse cardiovascular events. Aspirin impairs prostaglandin synthesis by irreversibly inhibiting cyclooxygenase (COX). Inhibition of COX-1 in platelets prevents synthesis of thromboxane A2, a potent stimulator of platelet aggregation and vasoconstriction. This helps reduce the risk of occlusive thrombus formation and subsequent myocardial infarction.

Some patients are unable to tolerate aspirin due to exacerbation of preexisting respiratory symptoms (eg, rhinitis, asthma) or development of allergic reactions (eg, urticaria, angioedema, anaphylaxis). In these patients, alternate antiplatelet agents should be used for prevention of cardiovascular events. **Clopidogrel** irreversibly **blocks** the $P2Y_{12}$ component of **ADP receptors** on the platelet surface and prevents platelet aggregation. Clopidogrel is as **effective as aspirin** for **prevention of cardiovascular events** and should be used in patients with aspirin allergy.

(Choices A and G) Apixaban is a direct factor Xa inhibitor that prevents platelet activation and fibrin clot formation. Warfarin inhibits an enzyme required for synthesis of active vitamin K, resulting in decreased synthesis of vitamin K-dependent clotting factors (II, VII, IX, and X). Both apixaban and warfarin are typically used for prevention and/or treatment of thromboembolic events, not coronary artery disease.

(Choice B) Cilostazol is a phosphodiesterase inhibitor that is occasionally used in patients with symptomatic peripheral vascular disease (ie, claudication).

(Choice D) Low molecular weight heparins (LMWHs; enoxaparin, dalteparin) are indirect thrombin inhibitors that bind with antithrombin and convert it from a slow to a rapid inactivator of thrombin and factor Xa. They are used in patients with acute coronary syndrome (unstable angina or myocardial infarction) but have no role in the management of patients with stable angina.

(Choice E) Eptifibatide is a platelet glycoprotein IIb/IIIa inhibitor that inhibits the final common pathway of platelet aggregation. Eptifibatide is occasionally used in some patients with acute coronary syndrome, but it is not used for patients with stable CHD.

(Choice F) Naproxen is a nonsteroidal anti-inflammatory drug (NSAID) that is used for pain management in patients with osteoarthritis. Use of both nonselective and selective COX-2 NSAIDs increases the risk of adverse cardiovascular events.

Educational objective:
Clopidogrel irreversibly blocks the $P2Y_{12}$ component of ADP receptors on the platelet surface and prevents platelet aggregation. Clopidogrel is as effective as aspirin in the prevention of cardiovascular events in patients with coronary heart disease.

References

- Collaborative meta-analysis of randomized trials of antiplatelet therapy for prevention of death, myocardial infarction, and stroke in high-risk

Physiologists conduct a series of experiments on hypophysectomized animals to investigate the effects of cortisol on vascular reactivity. Their initial tests show that administration of cortisol alone does not elicit a vascular response. Next, the researchers measure vascular reactivity to an infusion of norepinephrine both with and without pretreatment with cortisol. The results of their experiments are shown in the graph below.

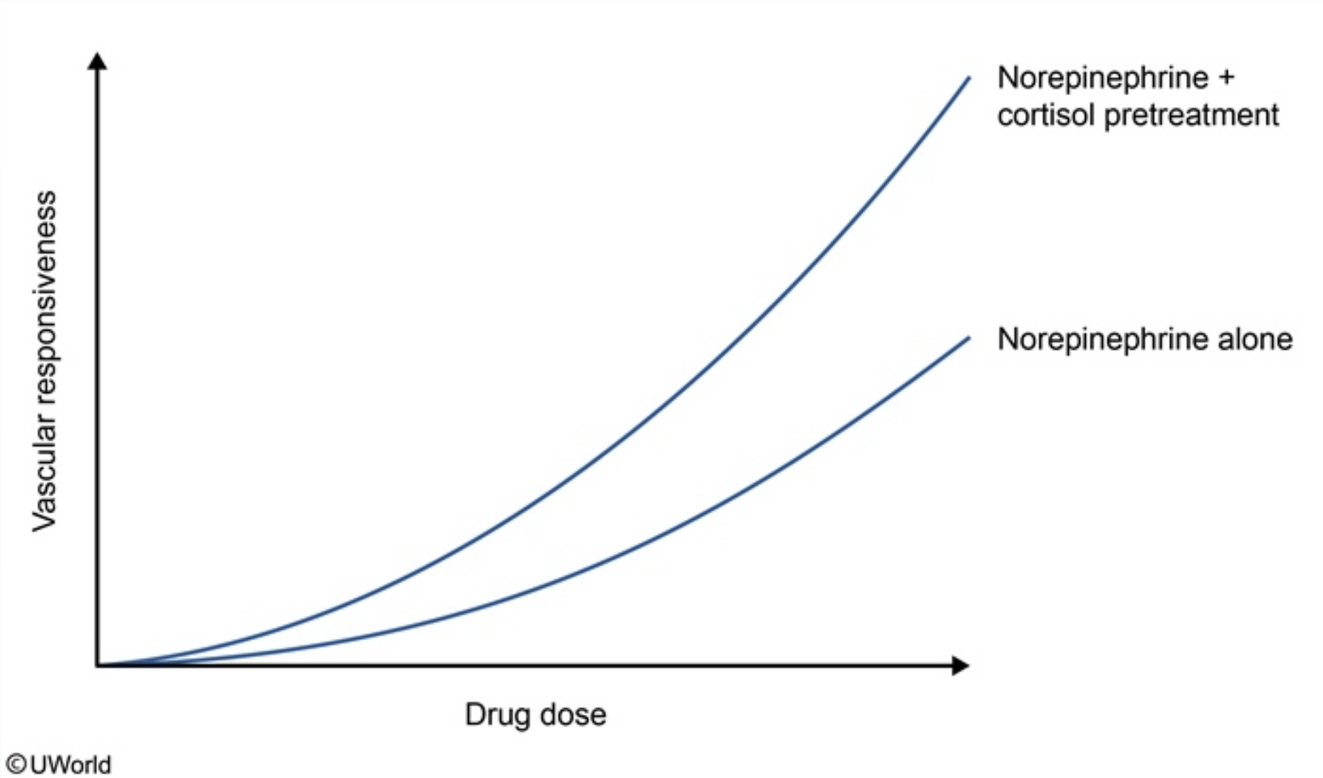

Which of the following pharmacologic principles best describes the effect of cortisol in this experiment?

A. Additive effect

B. Alteration in metabolism

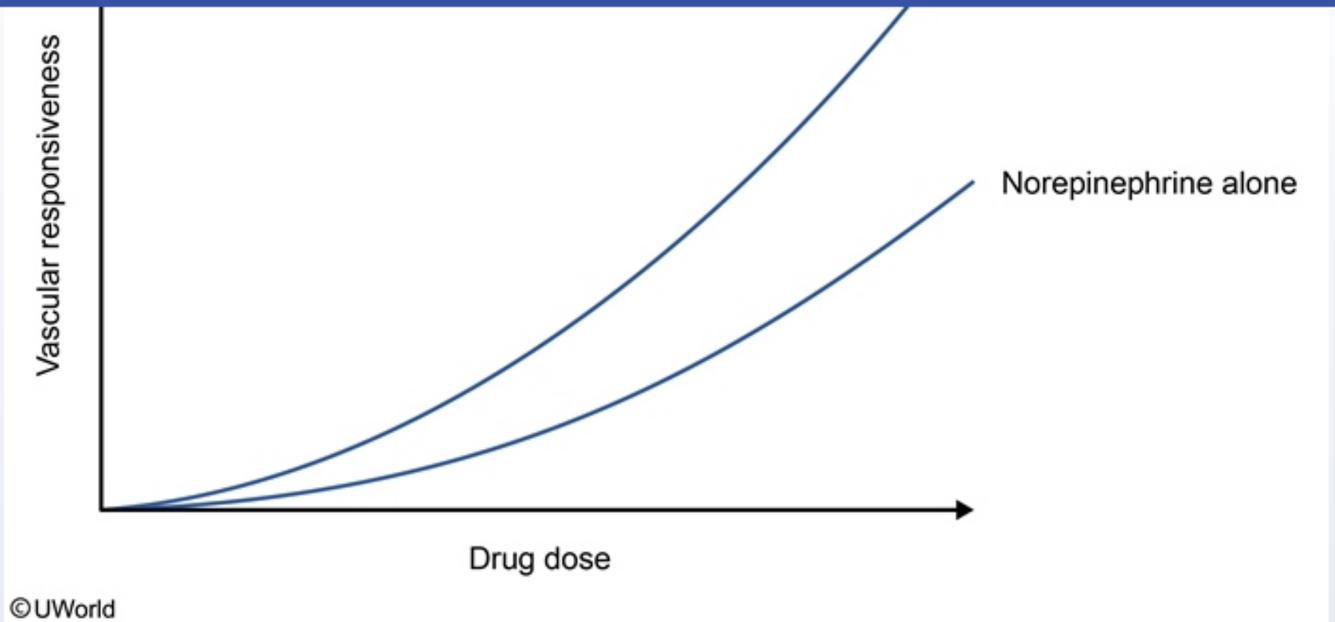

Which of the following pharmacologic principles best describes the effect of cortisol in this experiment?

- A. Additive effect
- B. Alteration in metabolism
- C. Permissiveness
- D. Synergistic effect
- E. Tachyphylaxis

Submit

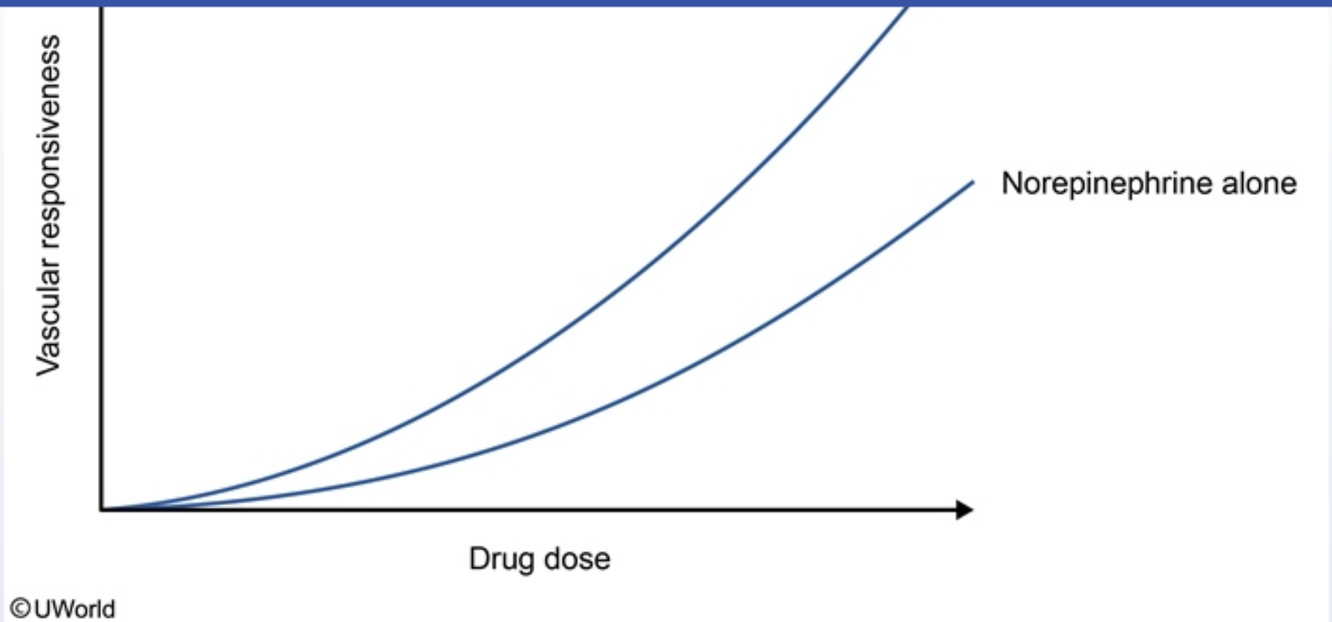

Which of the following pharmacologic principles best describes the effect of cortisol in this experiment?

- A. Additive effect (17%)
- B. Alteration in metabolism (2%)
- ✓ C. Permissiveness (29%)
- D. Synergistic effect (50%)
- E. Tachyphylaxis (0%)

Omitted
Correct answer

29%
Answered correctly

04 secs
Time Spent

02/24/2020
Last Updated

Although **cortisol** has no direct vasoactive properties, it **augments the vasoconstrictive effects of catecholamines** and angiotensin II. The above graph shows that the administration of norepinephrine produced a limited degree of vasoconstriction that was markedly increased following pretreatment with cortisol. This phenomenon is termed **permissiveness**; it occurs when a hormone has **no direct effect** on a physiologic process but **allows another hormone to exert its maximal effect** on that process. Cortisol exerts its potentiating effect on vasoconstriction in part through upregulation of alpha-1 adrenergic receptors on vascular smooth muscle cells. In adrenal insufficiency, low cortisol levels can contribute to hypotensive crisis by decreasing vascular responsiveness to norepinephrine and angiotensin II.

Cortisol also has a permissive effect on catecholamine-mediated bronchodilation and glucagon-mediated release of glucose from the liver.

(Choices A and D) The combination of 2 drugs with similar actions can have a synergistic or additive effect. When the combined effect of 2 drugs is equal to the sum of their individual effects, it is termed an additive response (eg, 1 + 1 = 2). When the combined effect exceeds the sum of the individual drugs' effects, the interaction is called synergistic (eg, 1 + 1 > 2). In this case, cortisol's influence on vascular responsiveness is best described as permissive rather than synergistic because cortisol has no intrinsic vasoconstrictive effect (eg, 1 + 0 > 1).

(Choice B) Alterations in metabolism can change a drug's pharmacokinetic and pharmacodynamic properties. For example, certain drugs (eg, amiodarone, fluconazole) can inhibit the P450 cytochrome oxidase system, decreasing the metabolism of other drugs metabolized through this pathway, which can lead to additive or synergistic responses.

(Choice E) Tachyphylaxis describes decreased drug responsiveness in a short period following one or more doses (ie, rapidly developing tolerance). Time is not quantified in the graph; therefore, drug response over time cannot be assessed.

Educational objective:
A permissive hormone has no effect on a physiologic process by itself but allows another hormone to exert its maximal effect on that process. Cortisol exerts a permissive effect on catecholamines to potentiate vasoconstriction and bronchodilation; it also has a permissive effect on glucagon to increase glucose release from the liver.

References

- Glucocorticoids and vascular reactivity.

Pharmacology Cardiovascular System Dose response curves

Exhibit Display

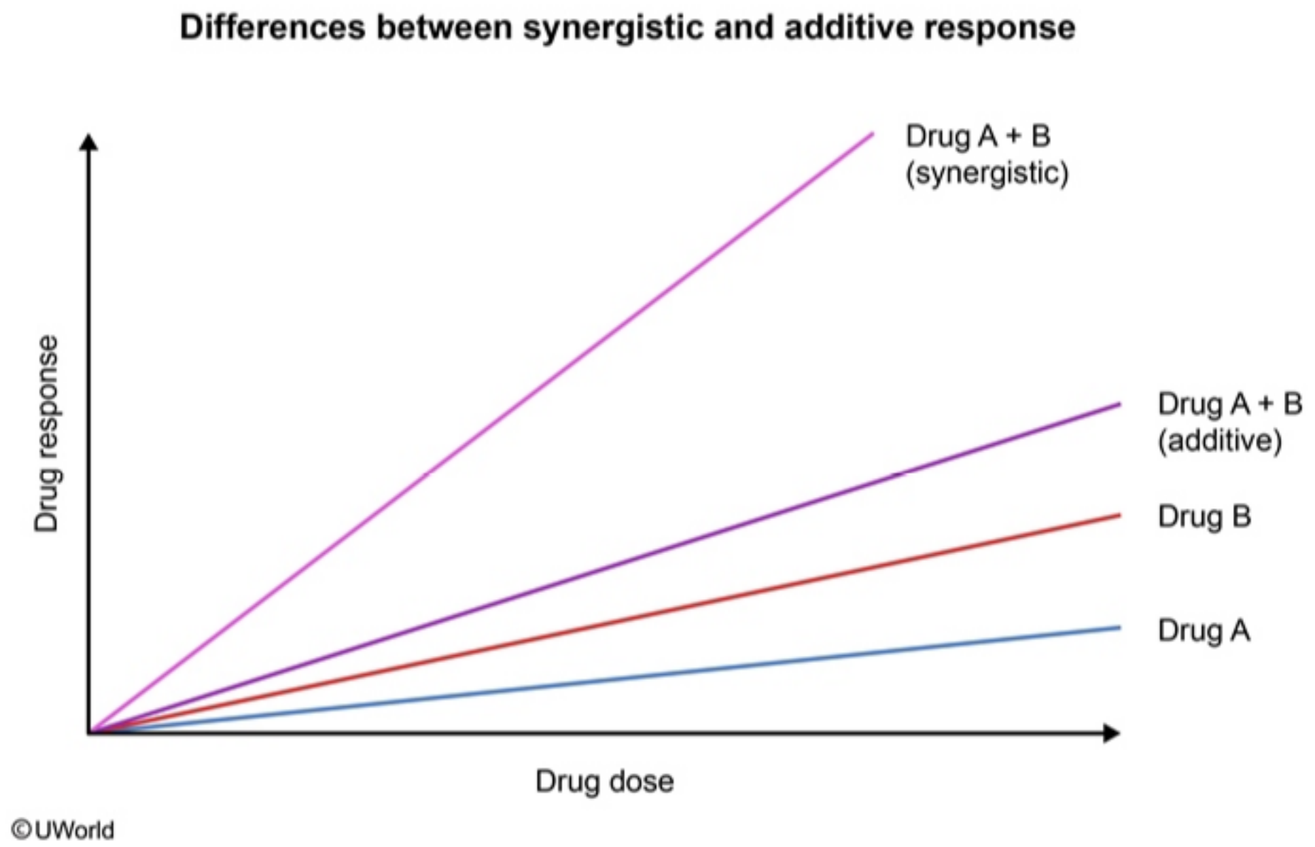

Zoom In Zoom Out Reset Add To New Card | Existing Card

Pharmacology Cardiovascular System Dose response curves

A 64-year-old woman comes to the hospital due to sudden-onset right arm weakness and difficulty speaking, which completely resolved within 20 minutes. The patient has had no shaking movements, headache, nausea, photophobia, or anxiety. She has a history of hypertension and hypercholesterolemia and takes amlodipine and rosuvastatin, respectively. Her blood pressure is 125/70 mm Hg and pulse is 78/min and regular. Neurologic examination is unremarkable. Fingerstick glucose is within normal limits. ECG shows normal sinus rhythm. Carotid Doppler reveals mild left common carotid artery stenosis. MRI of the brain and echocardiogram are unremarkable. If the patient is started on an additional medication that is indicated for her condition, which of the following adverse effects is most likely to occur?

- A. Central nervous system depression
- B. Gastrointestinal bleeding
- C. Hyperpnea and vertigo
- D. Orthostatic hypotension
- E. Sexual dysfunction
- F. Urinary bladder cancer

Submit

A 64-year-old woman comes to the hospital due to sudden-onset right arm weakness and difficulty speaking, which completely resolved within 20 minutes. The patient has had no shaking movements, headache, nausea, photophobia, or anxiety. She has a history of hypertension and hypercholesterolemia and takes amlodipine and rosuvastatin, respectively. Her blood pressure is 125/70 mm Hg and pulse is 78/min and regular. Neurologic examination is unremarkable. Fingerstick glucose is within normal limits. ECG shows normal sinus rhythm. Carotid Doppler reveals mild left common carotid artery stenosis. MRI of the brain and echocardiogram are unremarkable. If the patient is started on an additional medication that is indicated for her condition, which of the following adverse effects is most likely to occur?

- A. Central nervous system depression (2%)
- ✓ B. Gastrointestinal bleeding (63%)
- C. Hyperpnea and vertigo (2%)
- D. Orthostatic hypotension (28%)
- E. Sexual dysfunction (2%)
- F. Urinary bladder cancer (0%)

Omitted
Correct answer
B

63%
Answered correctly

02 secs
Time Spent

05/10/2020
Last Updated

Explanation

NSAID-induced gastrointestinal bleeding

COX-1 inhibition

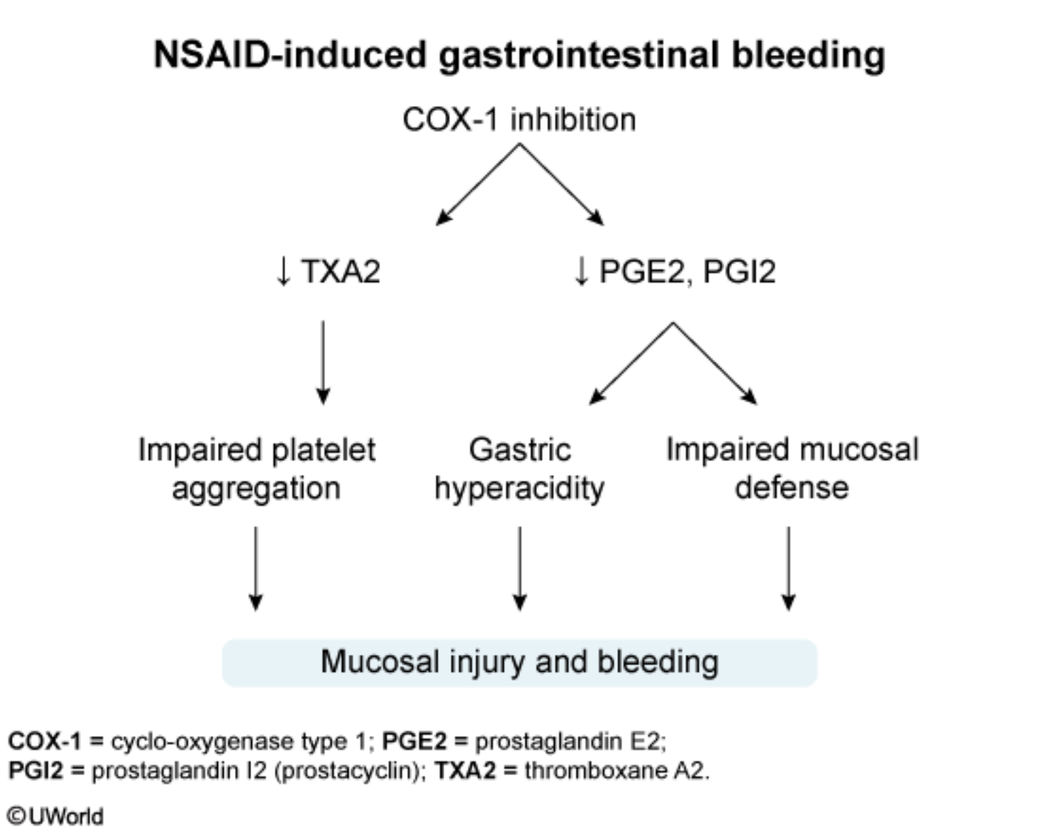

This patient, with hypertension, hypercholesterolemia, and sudden-onset neurologic deficits (eg, right arm weakness, difficulty speaking) that fully resolved within minutes, most likely had a **transient ischemic attack** (TIA). In addition to optimal blood pressure control and statin therapy, **low-dose aspirin** is commonly used to **prevent ischemic stroke** in patients with TIA. It works by irreversibly acetylating/inhibiting the cyclooxygenase (COX) enzymes. At low doses, aspirin predominantly **inhibits COX-1**, preventing platelet synthesis of thromboxane A2, which **impairs platelet aggregation** and reduces vasoconstriction.

At least 2 distinct COX-1-dependent mechanisms contribute to the increased risk of upper **gastrointestinal (GI) bleeding** associated with aspirin therapy: Inhibition of platelet aggregation and impairment of prostaglandin-dependent GI mucosal protection. The risk of upper GI bleeding

©UWorld

This patient, with hypertension, hypercholesterolemia, and sudden-onset neurologic deficits (eg, right arm weakness, difficulty speaking) that fully resolved within minutes, most likely had a **transient ischemic attack** (TIA). In addition to optimal blood pressure control and statin therapy, **low-dose aspirin** is commonly used to **prevent ischemic stroke** in patients with TIA. It works by irreversibly acetylating/inhibiting the cyclooxygenase (COX) enzymes. At low doses, aspirin predominantly **inhibits COX-1**, preventing platelet synthesis of thromboxane A2, which **impairs platelet aggregation** and reduces vasoconstriction.

At least 2 distinct COX-1-dependent mechanisms contribute to the increased risk of upper **gastrointestinal (GI) bleeding** associated with aspirin therapy: Inhibition of platelet aggregation and impairment of prostaglandin-dependent GI mucosal protection. The risk of upper GI bleeding increases with higher doses but is increased 2- to 3-fold even with low-dose aspirin. Proton pump inhibitors can help reduce the risk of upper GI bleeding in patients taking aspirin.

(Choice A) Central nervous system depression is commonly seen with benzodiazepine use as these agents potentiate the effect of GABA (a major inhibitory neurotransmitter) on GABA-A receptors.

(Choice C) Very high doses of aspirin can cause salicylism (eg, vertigo, tinnitus, hearing loss) and hyperpnea (stimulates respiratory drive). Hyperpnea may result in respiratory alkalosis, whereas systemic salicylate accumulation often leads to a concurrent metabolic acidosis.

(Choice D) Orthostatic hypotension may occur with use of antihypertensive medications due to vasodilation (eg, nitrates, calcium channel blockers) and volume depletion (eg, loop and thiazide diuretics).

(Choice E) Sexual dysfunction is a common side effect of antidepressants (eg, selective serotonin inhibitors, tricyclics) and some antihypertensives (eg, thiazide diuretics, spironolactone, clonidine).

(Choice F) Pioglitazone (a thiazolidinedione) increases insulin sensitivity in patients with type II diabetes mellitus by binding to peroxisome proliferator-activated receptors. Long-term use may be associated with urinary bladder cancer.

Educational objective:
Gastrointestinal (GI) mucosal injury and bleeding are the most common side effects of aspirin. These are due primarily to cyclooxygenase-1 inhibition, which results in impaired prostaglandin-dependent GI mucosal defense and decreased platelet aggregation.

References

therapy: Inhibition of platelet aggregation and impairment of prostaglandin-dependent GI mucosal protection. The risk of upper GI bleeding increases with higher doses but is increased 2- to 3-fold even with low-dose aspirin. Proton pump inhibitors can help reduce the risk of upper GI bleeding in patients taking aspirin.

(Choice A) Central nervous system depression is commonly seen with benzodiazepine use as these agents potentiate the effect of GABA (a major inhibitory neurotransmitter) on GABA-A receptors.

(Choice C) Very high doses of aspirin can cause salicylism (eg, vertigo, tinnitus, hearing loss) and hyperpnea (stimulates respiratory drive). Hyperpnea may result in respiratory alkalosis, whereas systemic salicylate accumulation often leads to a concurrent metabolic acidosis.

(Choice D) Orthostatic hypotension may occur with use of antihypertensive medications due to vasodilation (eg, nitrates, calcium channel blockers) and volume depletion (eg, loop and thiazide diuretics).

(Choice E) Sexual dysfunction is a common side effect of antidepressants (eg, selective serotonin inhibitors, tricyclics) and some antihypertensives (eg, thiazide diuretics, spironolactone, clonidine).

(Choice F) Pioglitazone (a thiazolidinedione) increases insulin sensitivity in patients with type II diabetes mellitus by binding to peroxisome proliferator-activated receptors. Long-term use may be associated with urinary bladder cancer.

Educational objective:
Gastrointestinal (GI) mucosal injury and bleeding are the most common side effects of aspirin. These are due primarily to cyclooxygenase-1 inhibition, which results in impaired prostaglandin-dependent GI mucosal defense and decreased platelet aggregation.

References

- Long-term use of aspirin and the risk of gastrointestinal bleeding.
- Systematic review and meta-analysis of adverse events of low-dose aspirin and clopidogrel in randomized controlled trials.

Pharmacology	Cardiovascular System	Antiplatelet therapy
Subject	System	Topic

Copyright © UWorld. All rights reserved.

A 54-year-old man is transferred to the hospital from his cardiologist's office due to atrial fibrillation with rapid ventricular response. His symptoms began 24 hours earlier with palpitations, lightheadedness, and chest tightness. The patient has had similar episodes several times during the last year. Past history is notable for mitral valve repair 3 years ago for severe symptomatic mitral regurgitation. The patient undergoes direct current cardioversion due to worsening hemodynamic instability, with resolution of the arrhythmia and all associated symptoms. He is considered for long-term amiodarone therapy to prevent future arrhythmic episodes. Which of the following should be tested before initiating this medication?

- A. 24-hour urinary cortisol
- B. 24-hour urinary metanephrines
- C. Oral glucose tolerance test
- D. Serum prolactin
- E. Serum testosterone
- F. Serum TSH

Submit

A 54-year-old man is transferred to the hospital from his cardiologist's office due to atrial fibrillation with rapid ventricular response. His symptoms began 24 hours earlier with palpitations, lightheadedness, and chest tightness. The patient has had similar episodes several times during the last year. Past history is notable for mitral valve repair 3 years ago for severe symptomatic mitral regurgitation. The patient undergoes direct current cardioversion due to worsening hemodynamic instability, with resolution of the arrhythmia and all associated symptoms. He is considered for long-term amiodarone therapy to prevent future arrhythmic episodes. Which of the following should be tested before initiating this medication?

A. 24-hour urinary cortisol (4%)
B. 24-hour urinary metanephrines (9%)
C. Oral glucose tolerance test (7%)
D. Serum prolactin (1%)
E. Serum testosterone (1%)
✓ F. Serum TSH (77%)

Omitted
Correct answer
F

77%
Answered correctly

03 secs
Time Spent

02/27/2020
Last Updated

Explanation

Major side effects of amiodarone	
	• Sinus bradycardia, heart block

Major side effects of amiodarone	
Cardiac	• Sinus bradycardia, heart block • Proarrhythmia - QT prolongation
Pulmonary	• Chronic interstitial pneumonitis
Endocrine	• Hypothyroidism • Hyperthyroidism
Gastrointestinal/ hepatic	• Elevated transaminases, hepatitis
Ocular	• Corneal micro-deposits • Optic neuropathy
Dermatologic	• Blue-gray skin discoloration
Neurologic	• Peripheral neuropathy

©UWorld

Amiodarone is a class III anti-arrhythmic agent used to suppress life-threatening rhythm disturbances. Because it is 40% iodine by weight, am**IOD**arone can cause a number of alterations in thyroid function. It can cause **hypothyroidism** due to decreased production of thyroid hormone. Individuals with pre-existing autoimmune thyroid disease are at greatest risk and so should be screened for subclinical hypothyroidism with a **serum TSH** assay prior to initiating amiodarone therapy. Amiodarone can also cause **hyperthyroidism** due to increased **thyroid hormone synthesis** or **destructive thyroiditis** with release of preformed thyroid hormone.

©UWorld

Amiodarone is a class III anti-arrhythmic agent used to suppress life-threatening rhythm disturbances. Because it is 40% iodine by weight, am**IOD**arone can cause a number of alterations in thyroid function. It can cause **hypothyroidism** due to decreased production of thyroid hormone. Individuals with pre-existing autoimmune thyroid disease are at greatest risk and so should be screened for subclinical hypothyroidism with a **serum TSH** assay prior to initiating amiodarone therapy. Amiodarone can also cause **hyperthyroidism** due to increased **thyroid hormone synthesis** or **destructive thyroiditis** with release of preformed thyroid hormone.

(Choices A and B) Amiodarone is not associated with altered function of the adrenal cortex or medulla.

(Choice C) The oral glucose tolerance test is used to screen for diabetes mellitus, primarily in pregnant women. Amiodarone is not associated with significant alterations in insulin sensitivity or blood glucose levels.

(Choice D) Release of prolactin is primarily regulated by inhibitory effects of dopamine from the hypothalamus. Release is stimulated to a small degree by thyrotropin-releasing hormone and therefore may be mildly affected by amiodarone. However, these effects would not be clinically significant.

(Choice E) Amiodarone can cause erectile dysfunction, which may be related to its alpha and beta adrenoreceptor blocking effect. Amiodarone does not significantly alter serum testosterone levels.

Educational objective:
Amiodarone is 40% iodine by weight. It can cause hypothyroidism due to decreased production of thyroid hormone. Amiodarone can also cause hyperthyroidism due to increased thyroid hormone synthesis or destructive thyroiditis with release of preformed thyroid hormone.

References

- Effects of amiodarone therapy on thyroid function.

Pharmacology	Cardiovascular System	Amiodarone
Subject	System	Topic

Copyright © UWorld. All rights reserved.

A 60-year-old man with known coronary artery disease comes to the office due to exertional chest tightness for the last 6 months. The symptoms occur when he walks more than 3 blocks, especially in cold weather. The patient underwent coronary artery bypass graft surgery 3 years ago for progressive angina. Past medical history also includes asthma, benign prostate hyperplasia, and peripheral artery disease. The physician discusses adding isosorbide dinitrate to his current therapy but the patient is concerned about adverse effects. Which of the following is most likely to occur in this patient with the add-on therapy?

- A. Atrioventricular conduction delay
- B. Cold extremities
- C. Constipation
- D. Joint pains
- E. Nocturnal wheezing
- F. Throbbing headaches
- G. Urinary retention

Submit

A 60-year-old man with known coronary artery disease comes to the office due to exertional chest tightness for the last 6 months. The symptoms occur when he walks more than 3 blocks, especially in cold weather. The patient underwent coronary artery bypass graft surgery 3 years ago for progressive angina. Past medical history also includes asthma, benign prostate hyperplasia, and peripheral artery disease. The physician discusses adding isosorbide dinitrate to his current therapy but the patient is concerned about adverse effects. Which of the following is most likely to occur in this patient with the add-on therapy?

- A. Atrioventricular conduction delay (4%)
- B. Cold extremities (11%)
- C. Constipation (3%)
- D. Joint pains (1%)
- E. Nocturnal wheezing (4%)
- ✓ F. Throbbing headaches (67%)
- G. Urinary retention (6%)

Omitted
Correct answer
F

67%
Answered correctly

02 secs
Time Spent

06/22/2020
Last Updated

Explanation

Nitrates are frequently used for symptomatic relief in patients with chronic stable angina. The anti-ischemic effect of nitrates is mediated by systemic vasodilation (predominantly venodilation) with a decrease in left ventricular end-diastolic volume and wall stress, resulting in decreased

Nitrates are frequently used for symptomatic relief in patients with chronic stable angina. The anti-ischemic effect of nitrates is mediated by systemic vasodilation (predominantly venodilation) with a decrease in left ventricular end-diastolic volume and wall stress, resulting in decreased myocardial oxygen demand and relief of angina symptoms.

The main adverse effects seen with nitrate therapy include **headaches, cutaneous flushing**, lightheadedness, **hypotension**, and reflex tachycardia. Nitrates must be avoided in patients with hypertrophic cardiomyopathy (due to increased outflow tract obstruction), right ventricular infarction (due to reduction in preload, impairing cardiac output), and those on phosphodiesterase inhibitors (synergism increases the risk of severe hypotension).

(Choice A) Atrioventricular conduction delay is a potential adverse effect of several drugs used for management of chronic stable angina. These include calcium channel blockers (eg, verapamil, diltiazem) and beta blockers (eg, metoprolol, propranolol).

(Choice B) Cold extremities due to Raynaud phenomenon are associated with medications such as amphetamines, ergotamine, and chemotherapeutic agents.

(Choice C) Constipation is a common side effect of opioid analgesics, iron supplements, calcium channel blockers such as verapamil, and anticholinergic medications such as atropine.

(Choice D) Thiazide diuretics can lead to hyperuricemia and precipitate an acute gout attack.

(Choice E) Nocturnal wheezing can be a symptom of asthma or gastroesophageal reflux disease. In addition, the use of beta blockers in patients with underlying bronchospastic disease can cause increased bronchoconstriction and lead to wheezing.

(Choice G) Urinary retention is typically associated with medications that exhibit anticholinergic properties such as tricyclic antidepressants (eg, amitriptyline) and antihistamines (eg, diphenhydramine).

Educational objective:
The main adverse effects seen with nitrate therapy include headaches and cutaneous flushing along with lightheadedness and hypotension due to systemic vasodilation.

References

- Mechanisms of action of nitrates.

A 62-year-old man is hospitalized for chest pain and palpitations. His past medical history is significant for coronary artery disease, ischemic cardiomyopathy, paroxysmal atrial fibrillation, and hypertension. Blood pressure on admission is 135/78 mm Hg and pulse is 78/min. During hospitalization, the patient has 2 episodes of brief loss of consciousness. ECG recording during the episodes shows polymorphic QRS complexes that change in amplitude and cycle length. Between the episodes, his ECG shows QT interval prolongation but is otherwise unremarkable. Which of the following medications is most likely responsible for this patient's condition?

- A. Digoxin
- B. Diltiazem
- C. Lidocaine
- D. Metoprolol
- E. Sotalol

Submit

A 62-year-old man is hospitalized for chest pain and palpitations. His past medical history is significant for coronary artery disease, ischemic cardiomyopathy, paroxysmal atrial fibrillation, and hypertension. Blood pressure on admission is 135/78 mm Hg and pulse is 78/min. During hospitalization, the patient has 2 episodes of brief loss of consciousness. ECG recording during the episodes shows polymorphic QRS complexes that change in amplitude and cycle length. Between the episodes, his ECG shows QT interval prolongation but is otherwise unremarkable. Which of the following medications is most likely responsible for this patient's condition?

- A. Digoxin (16%)
- B. Diltiazem (8%)
- C. Lidocaine (10%)
- D. Metoprolol (2%)
- ✓ E. Sotalol (62%)

Omitted
Correct answer
E

62%
Answered correctly

02 secs
Time Spent

02/18/2020
Last Updated

Explanation

This patient's presentation (syncope and ECG findings) is suggestive of **long QT syndrome** with associated torsades de pointes (TdP, "twisting of points"). TdP is a form of polymorphic ventricular tachycardia characterized by QRS complexes of varying amplitude and cycle length giving the appearance that the tip of the QRS complex is "twisting" around the ECG baseline. TdP is differentiated from other forms of polymorphic ventricular tachycardia because it is always associated with a prolonged QT interval. It may terminate spontaneously or can degenerate into ventricular fibrillation and sudden cardiac death.

Explanation

This patient's presentation (syncope and ECG findings) is suggestive of **long QT syndrome** with associated torsades de pointes (TdP, "twisting of points"). TdP is a form of polymorphic ventricular tachycardia characterized by QRS complexes of varying amplitude and cycle length giving the appearance that the tip of the QRS complex is "twisting" around the ECG baseline. TdP is differentiated from other forms of polymorphic ventricular tachycardia because it is always associated with a prolonged QT interval. It may terminate spontaneously or can degenerate into ventricular fibrillation and sudden cardiac death.

QT prolongation may be acquired or congenital. **Acquired QT prolongation** is most frequently caused by electrolyte imbalances (hypokalemia, hypomagnesemia) and pharmacologic agents such as **class IA and III antiarrhythmics** (eg, quinidine, sotalol), antibiotics (eg, macrolides, fluoroquinolones), methadone, and antipsychotics (eg, haloperidol). Sotalol is a class III antiarrhythmic agent (K^+ channel blocking) used for treatment of atrial fibrillation. It prolongs action potential duration, resulting in QT interval prolongation.

(Choice A) Digoxin slows conduction through the atrioventricular node by augmenting vagal parasympathetic tone, and it increases cardiac contractility by inhibiting Na^+/K^+-ATPase (increasing intracellular calcium). It also decreases the action potential duration and can cause QT interval shortening.

(Choices B and D) Diltiazem (nondihydropyridine calcium channel blocker) and metoprolol (beta-1 selective antagonist) slow the sinus node discharge rate and atrioventricular nodal conduction. These agents prolong the PR interval but do not affect the QT interval.

(Choice C) Lidocaine is a class IB antiarrhythmic drug that acts by blocking sodium channels and inhibiting phase 0 depolarization. It does not prolong the QT interval.

Educational objective:
Torsades de pointes (TdP) refers to polymorphic ventricular tachycardia that occurs in the setting of a congenital or acquired prolonged QT interval. TdP is most commonly precipitated by medications that prolong the QT interval such as certain antiarrhythmics (sotalol, quinidine), antipsychotics (haloperidol), and antibiotics (macrolides, fluoroquinolones).

Pharmacology	Cardiovascular System	Torsades de pointes
Subject	System	Topic

Explanation

Exhibit Display

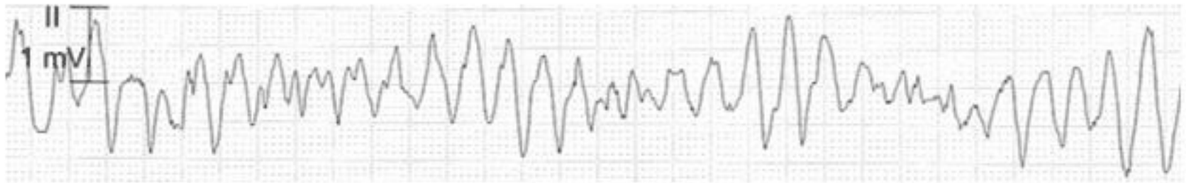

Zoom In | Zoom Out | Reset | Add To New Card | Existing Card

A 47-year-old man with known coronary artery disease comes to the emergency department with chest tightness, sweating, and palpitations. His symptoms began abruptly 2 hours ago while he was at work. Six months ago, the patient underwent percutaneous angioplasty of the right coronary artery. Past medical history also includes anxiety and panic attacks. Blood pressure is 180/90 mm Hg and pulse is 110/min with a regular rhythm. An esmolol infusion produces rapid symptom relief and heart rate slowing. Which of the following portions of the ECG will be affected most significantly by the medication?

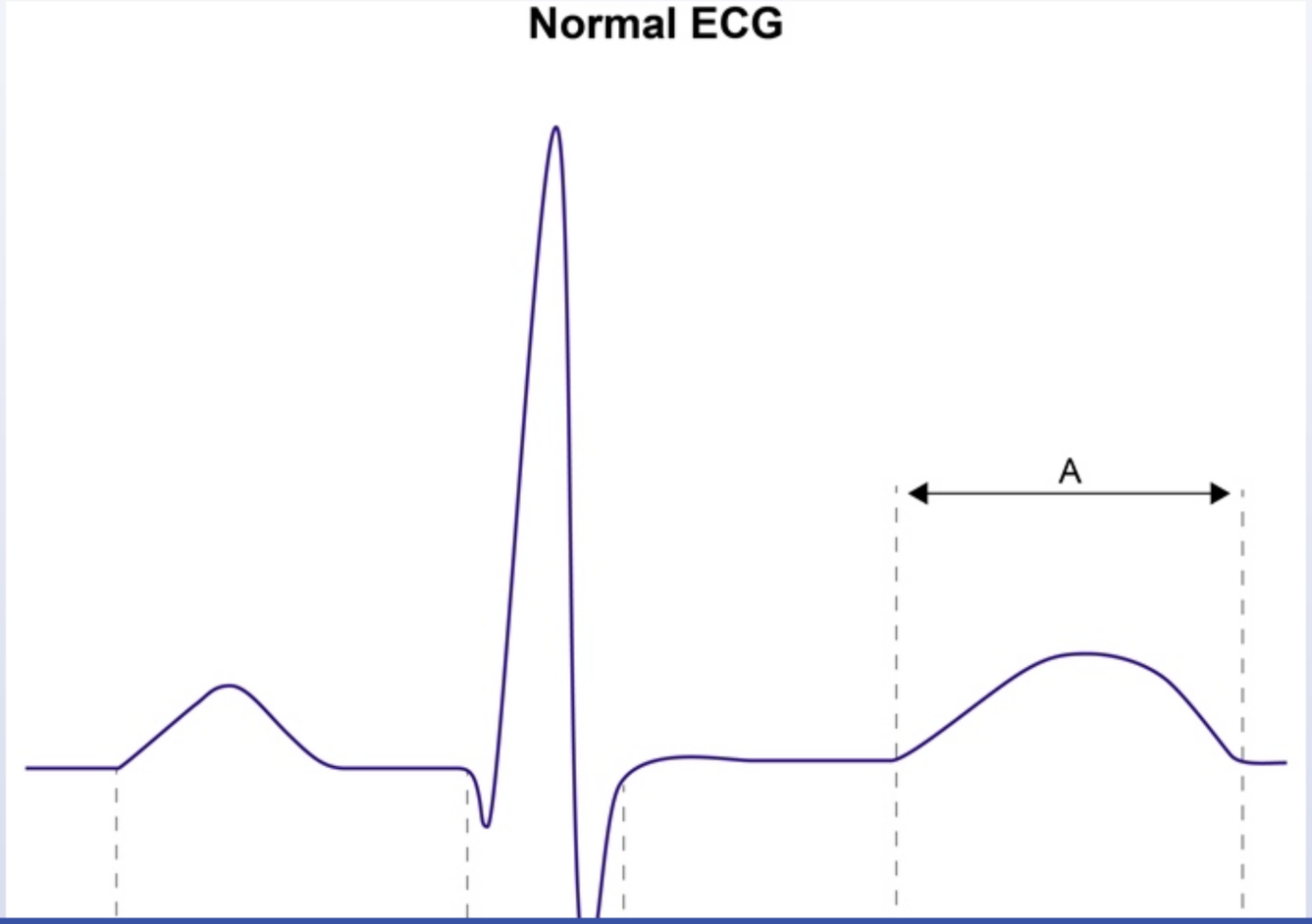

affected most significantly by the medication?

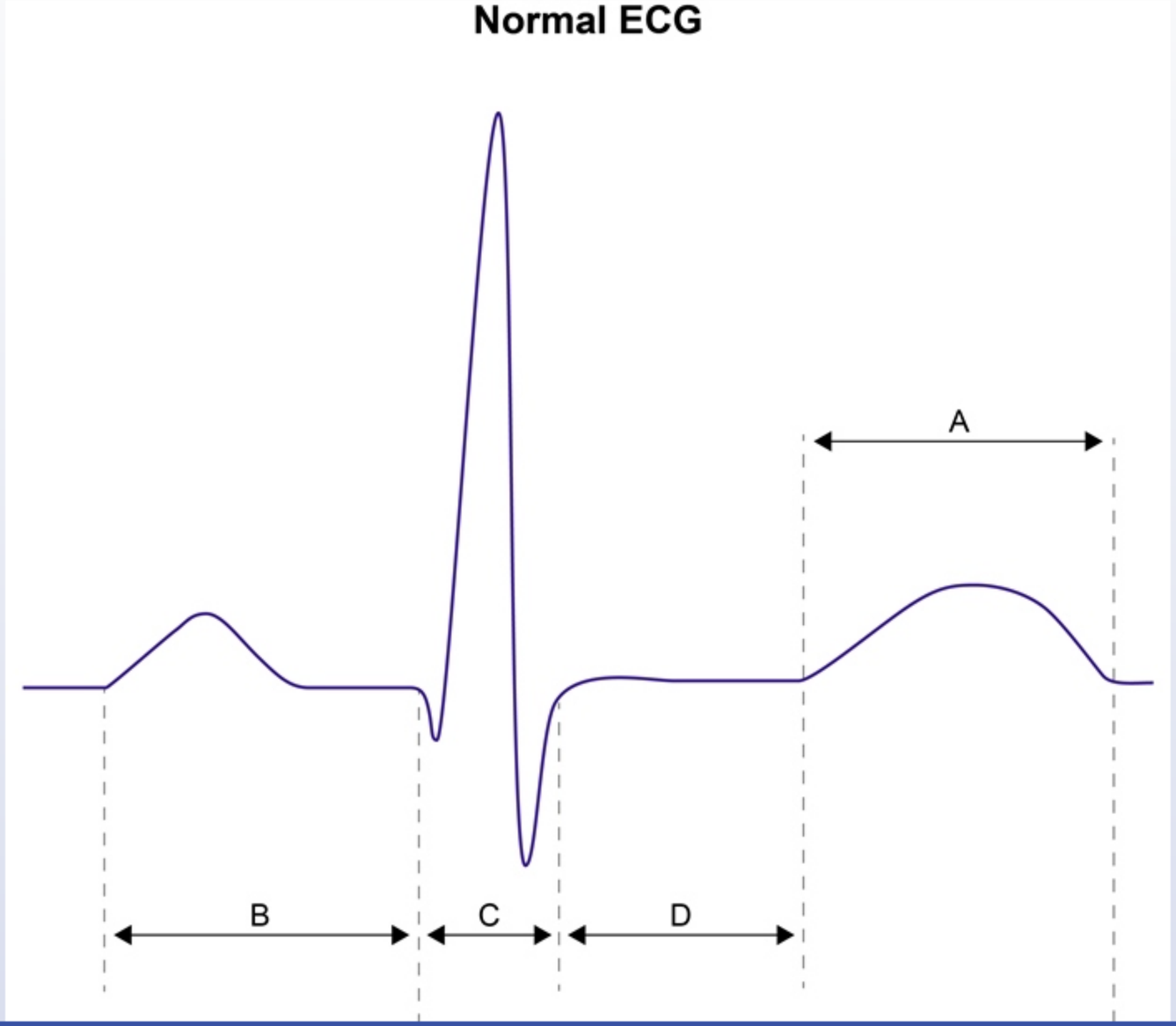

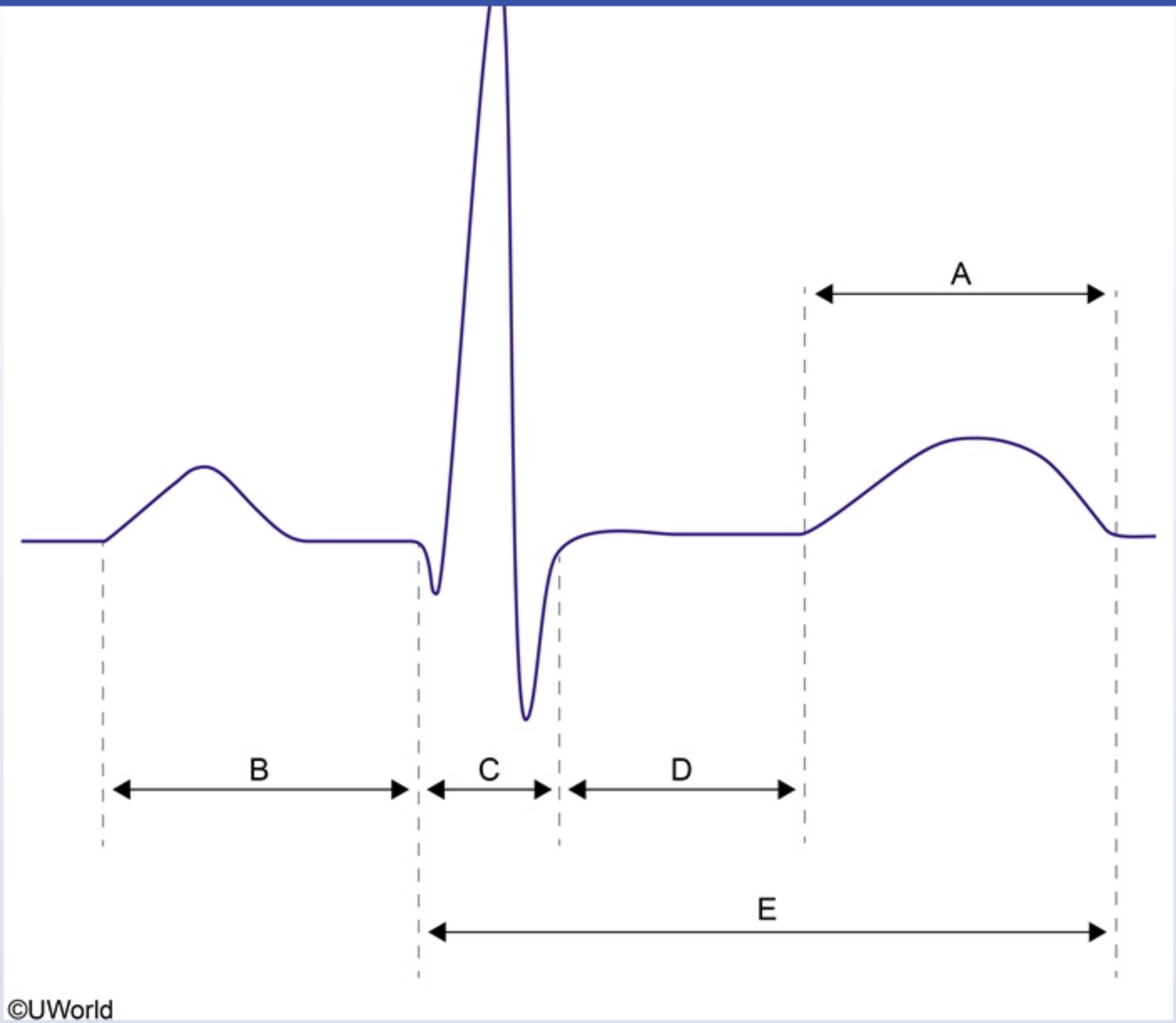

A A

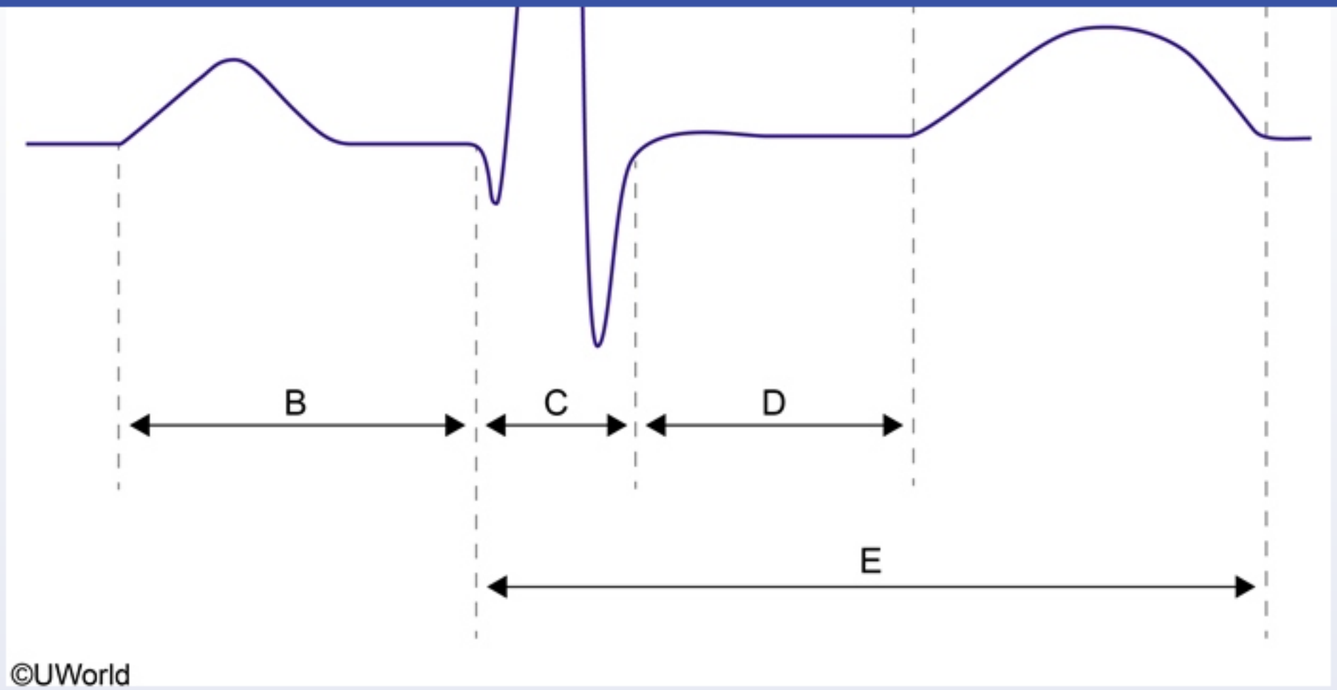

A. A

B. B

C. C

D. D

E. E

Submit

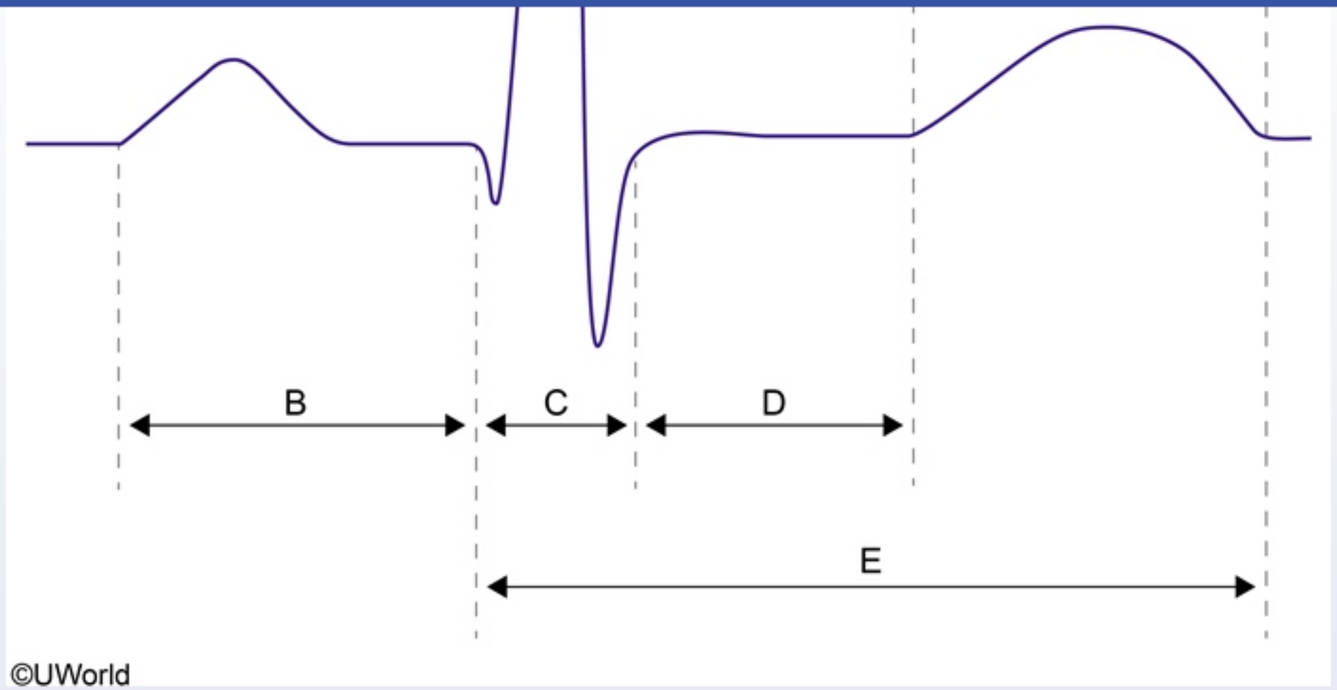

A. A (4%)

✓ B. B (63%)

C. C (15%)

D. D (4%)

E. E (12%)

Omitted
Correct answer

63%
Answered correctly

14 secs
Time Spent

06/22/2020
Last Updated

Explanation

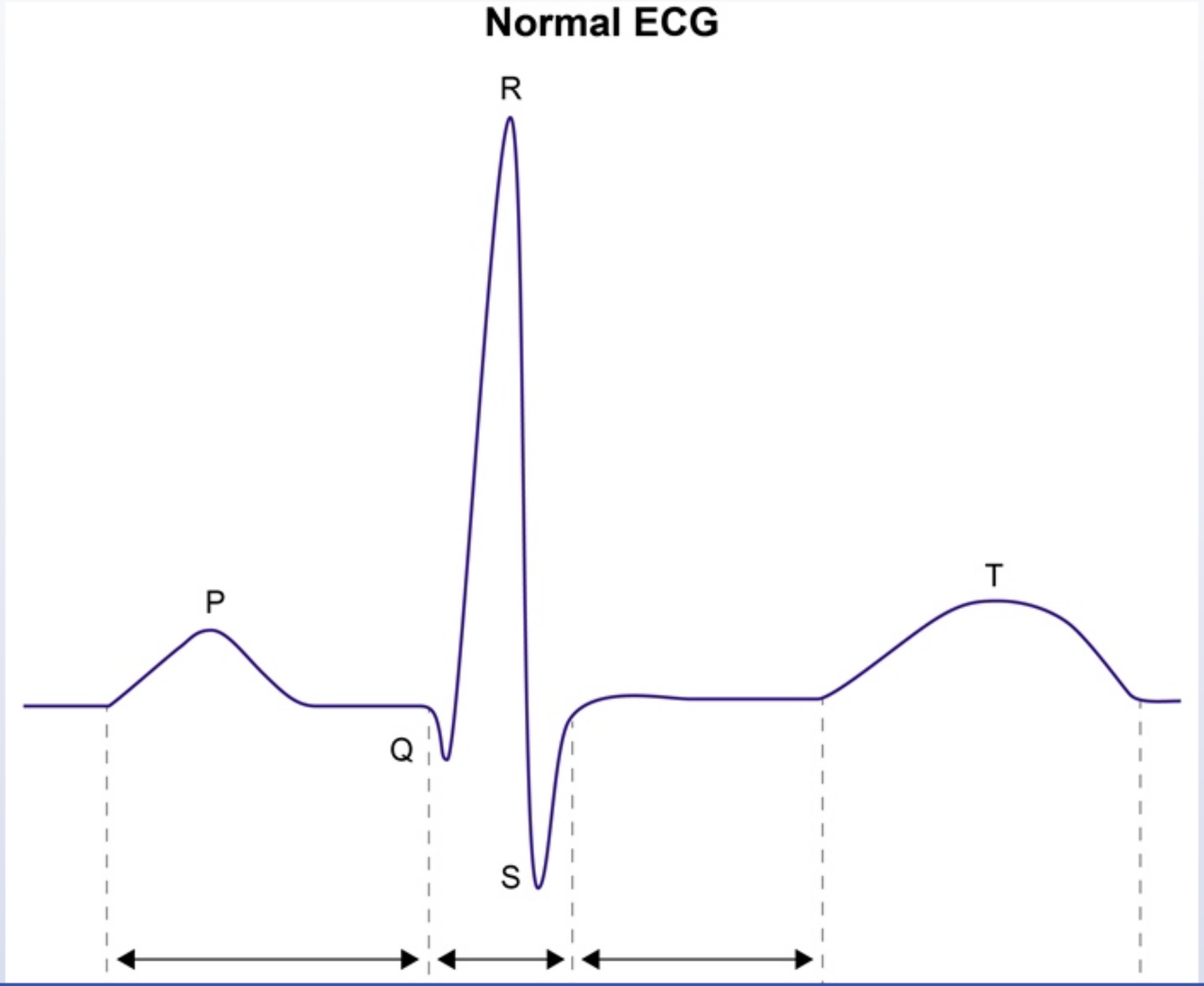

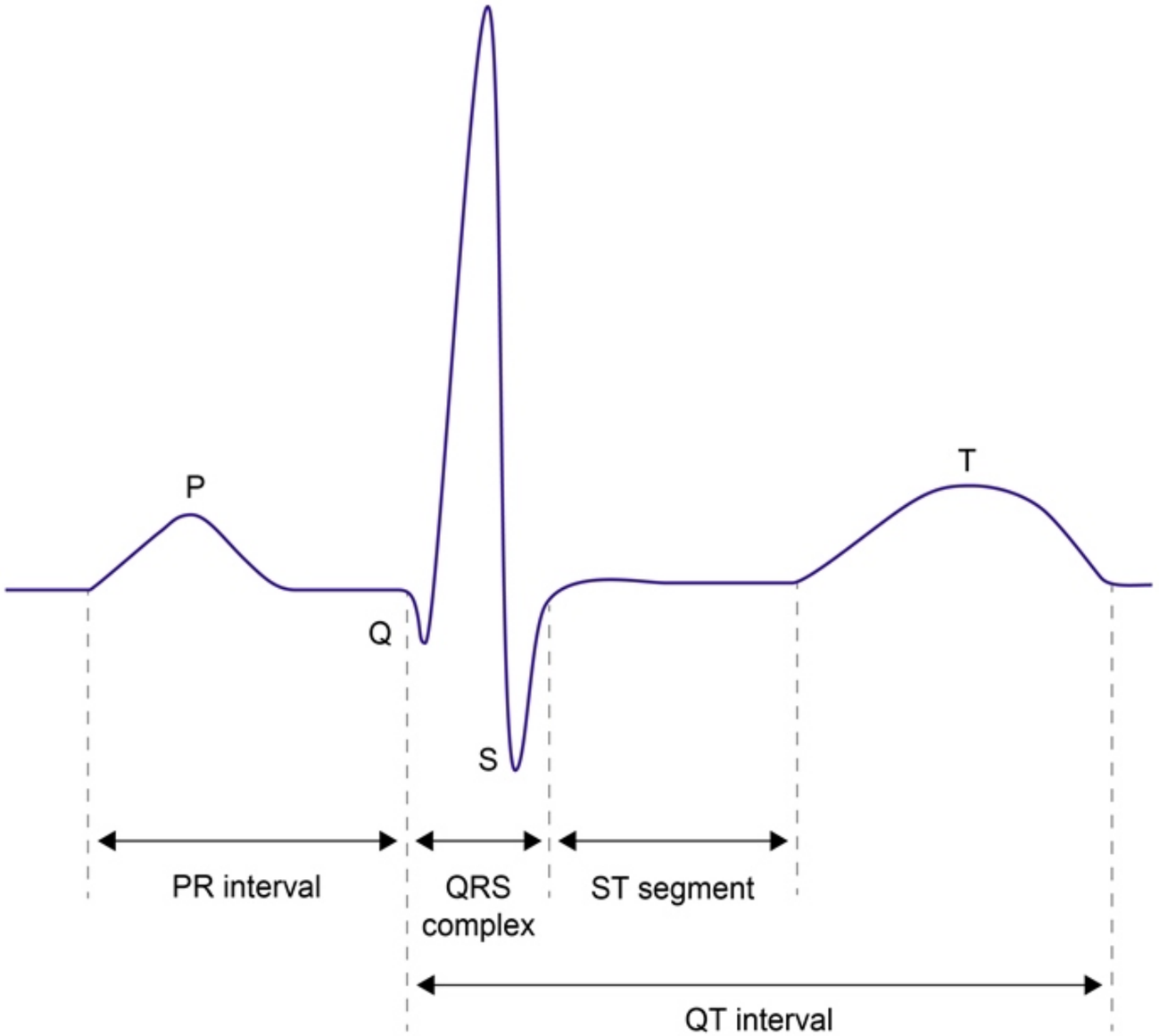

©UWorld

©UWorld

On an ECG, the P wave represents atrial depolarization and the QRS complex represents ventricular depolarization. The **PR interval** is the period from the beginning of atrial depolarization (**start of P wave**) to the beginning of ventricular depolarization (**start of QRS complex**). The longer the PR interval, the longer it takes for an electrical stimulus to travel from the SA node to the ventricles via the AV node, bundle of His, and fascicular branches. Drugs that slow AV nodal conduction, such as **beta blockers**, will **prolong** the PR interval. Beta blockers (except sotalol, which also has class III properties) do not have any specific effects on QRS or QT interval durations.

(Choice A) The T wave represents ventricular repolarization. It is not affected by beta-adrenergic blockers. Myocardial ischemia can cause T wave inversion.

(Choice C) The QRS complex represents ventricular depolarization. It is not affected by beta-adrenergic blockers. A widened QRS complex can occur in the setting of ventricular automaticity, left or right bundle branch blocks, or ventricular pacemakers.

(Choice D) The ST-segment is a period of electrocardiographic inactivity that extends between ventricular depolarization and repolarization. It is not affected by beta-adrenergic blockers. ST-segment elevation or depression is usually a sign of myocardial ischemia.

(Choice E) The QT interval represents the time needed for ventricular depolarization and repolarization (ventricular electrical systole). Long QT syndrome can be congenital or acquired. Antiarrhythmics such as quinidine and sotalol are most frequently associated with acquired long QT. However, most beta blockers have a minimal effect on the resting QT interval.

Educational objective:
Beta blockers decrease AV nodal conduction, leading to an increased AV nodal refractory period. This correlates to PR interval prolongation on an ECG.

Pharmacology	Cardiovascular System	Antiarrhythmic drugs
Subject	System	Topic

Copyright © UWorld. All rights reserved.

A 69-year-old man comes to the office due to a 6-month history of chest tightness when he walks uphill or climbs stairs. The discomfort radiates to his throat and lasts 5-10 minutes before slowly subsiding. Medical history is significant for hyperlipidemia and type 2 diabetes mellitus. His father had coronary artery bypass surgery at age 60 and his mother suffered a stroke. Vital signs are normal. Cardiac examination reveals no murmurs or additional heart sounds. The patient is prescribed a medication that is metabolized to S-nitrosothiols in the vascular smooth muscle cells, and he reports rapid and significant symptom relief. Which of the following components of the cardiovascular system is most susceptible to the medication prescribed to this patient?

- A. Cardiac muscle
- B. Large arteries
- C. Large veins
- D. Precapillary sphincters
- E. Small arteries and arterioles

Submit

A 69-year-old man comes to the office due to a 6-month history of chest tightness when he walks uphill or climbs stairs. The discomfort radiates to his throat and lasts 5-10 minutes before slowly subsiding. Medical history is significant for hyperlipidemia and type 2 diabetes mellitus. His father had coronary artery bypass surgery at age 60 and his mother suffered a stroke. Vital signs are normal. Cardiac examination reveals no murmurs or additional heart sounds. The patient is prescribed a medication that is metabolized to S-nitrosothiols in the vascular smooth muscle cells, and he reports rapid and significant symptom relief. Which of the following components of the cardiovascular system is most susceptible to the medication prescribed to this patient?

- A. Cardiac muscle (2%)
- B. Large arteries (5%)
- ✓ C. Large veins (64%)
- D. Precapillary sphincters (2%)
- E. Small arteries and arterioles (25%)

Omitted
Correct answer
C

64%
Answered correctly

04 secs
Time Spent

05/01/2020
Last Updated

Explanation

This patient has **stable angina pectoris** and experienced rapid symptomatic relief following receipt of a **nitrate**. Pharmacologic nitrates (eg, nitroglycerin, isosorbide mononitrate, isosorbide dinitrate) are metabolized to **nitric oxide and S-nitrosothiols** via mitochondrial aldehyde dehydrogenase within vascular smooth muscle cells. These compounds in turn activate guanylate cyclase and promote the conversion of guanosine triphosphate to cyclic guanosine monophosphate (cGMP), which leads to dephosphorylation of myosin light chains and causes

This patient has **stable angina pectoris** and experienced rapid symptomatic relief following receipt of a **nitrate**. Pharmacologic nitrates (eg, nitroglycerin, isosorbide mononitrate, isosorbide dinitrate) are metabolized to **nitric oxide and S-nitrosothiols** via mitochondrial aldehyde dehydrogenase within vascular smooth muscle cells. These compounds in turn activate guanylate cyclase and promote the conversion of guanosine triphosphate to cyclic guanosine monophosphate (cGMP), which leads to dephosphorylation of myosin light chains and causes vascular smooth muscle relaxation.

Nitrates predominantly affect the **large veins**, where smooth muscle relaxation leads to **venodilation** and increased venous capacitance. Cardiac venous return **(preload) is reduced**, leading to a reduction in left ventricular end-diastolic volume and pressure and a consequent decrease in left ventricular wall stress. **Decreased myocardial oxygen demand** leads to relief of anginal symptoms.

(Choice A) Both beta blockers and nondihydropyridine calcium channel blockers (eg, verapamil) are negative inotropic and chronotropic agents. They exert antianginal effects via direct actions on cardiac myocytes to reduce myocardial contractility and heart rate, and thereby decrease myocardial oxygen demand. Nitrates have no direct effect on cardiac myocytes.

(Choice B) Sodium nitroprusside generates nitric oxide while in the bloodstream (rather than within vascular smooth muscle cells) and is much less selective for the large veins than nitrates. It causes relatively balanced vasodilation of both the large arteries and veins, and is useful for reducing blood pressure in patients with hypertensive emergency.

(Choice D) Precapillary sphincters are bands of smooth muscle that regulate blood flow from arterioles into mesenteric capillary beds. The effect of nitrates on precapillary sphincters is minimal compared to that on the large veins.

(Choice E) Dihydropyridine calcium channel blockers (eg, nifedipine, amlodipine, nicardipine) block L-type calcium channels in vascular smooth muscle cells to trigger vasodilation. This effect is exerted on small arteries and arterioles in both the peripheral and coronary circulation, resulting in 2 therapeutic effects on stable angina. The peripheral vasodilation reduces afterload leading to a decrease in cardiac work and myocardial oxygen demand, and the coronary vasodilation increases myocardial oxygen supply.

Educational objective:
Pharmacologic nitrates (eg, nitroglycerin, isosorbide mononitrate, isosorbide dinitrate) are metabolized to nitric oxide and S-nitrothiols in vascular smooth muscle cells, leading to an increase in cyclic guanosine monophosphate (cGMP) that stimulates vasodilation. Large veins are predominantly affected, leading to increased venous capacitance and reduced venous return (preload), which decreases left ventricular wall stress

Exhibit Display

Mechanism of action of vasodilators

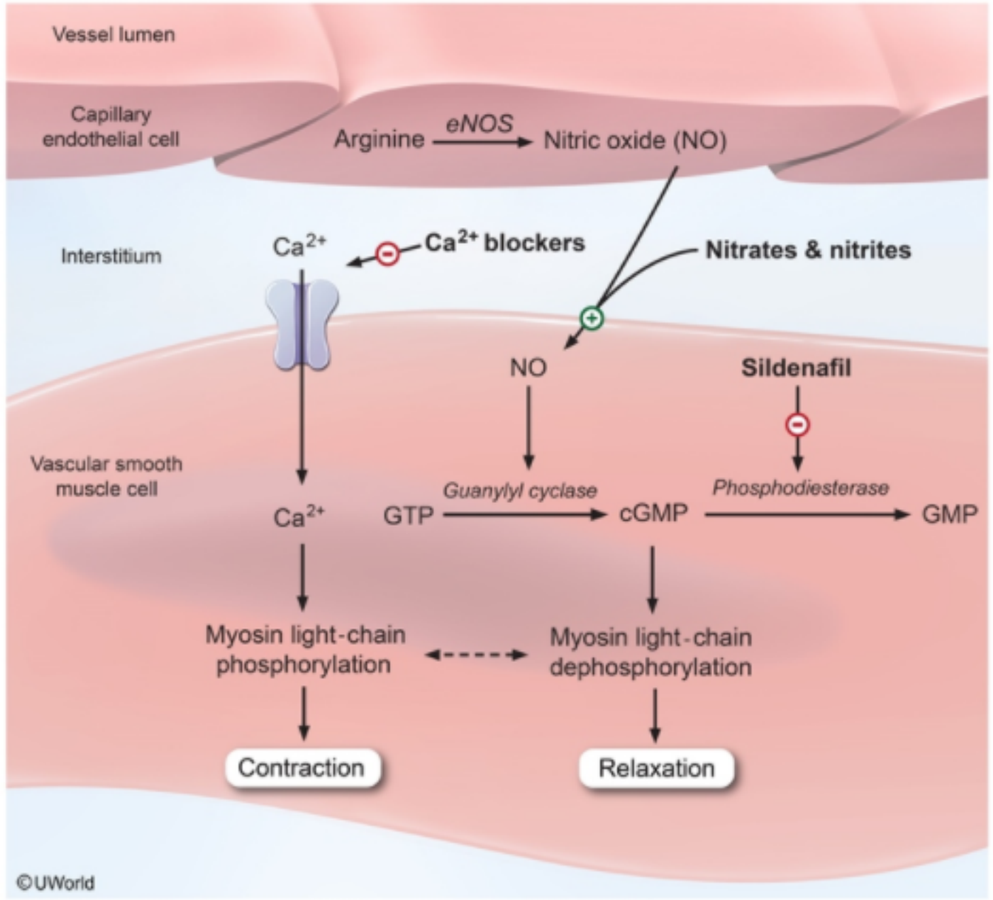

cGMP = cyclic guanosine monophosphate; **eNOS** = endothelial nitric oxide synthase; **GMP** = guanosine monophosphate; **GTP** = guanosine 5′-triphosphate.

Zoom In | Zoom Out | Reset | Add To New Card | Existing Card

(Choice A) Both beta blockers and nondihydropyridine calcium channel blockers (eg, verapamil) are negative inotropic and chronotropic agents. They exert antianginal effects via direct actions on cardiac myocytes to reduce myocardial contractility and heart rate, and thereby decrease myocardial oxygen demand. Nitrates have no direct effect on cardiac myocytes.

(Choice B) Sodium nitroprusside generates nitric oxide while in the bloodstream (rather than within vascular smooth muscle cells) and is much less selective for the large veins than nitrates. It causes relatively balanced vasodilation of both the large arteries and veins, and is useful for reducing blood pressure in patients with hypertensive emergency.

(Choice D) Precapillary sphincters are bands of smooth muscle that regulate blood flow from arterioles into mesenteric capillary beds. The effect of nitrates on precapillary sphincters is minimal compared to that on the large veins.

(Choice E) Dihydropyridine calcium channel blockers (eg, nifedipine, amlodipine, nicardipine) block L-type calcium channels in vascular smooth muscle cells to trigger vasodilation. This effect is exerted on small arteries and arterioles in both the peripheral and coronary circulation, resulting in 2 therapeutic effects on stable angina. The peripheral vasodilation reduces afterload leading to a decrease in cardiac work and myocardial oxygen demand, and the coronary vasodilation increases myocardial oxygen supply.

Educational objective:
Pharmacologic nitrates (eg, nitroglycerin, isosorbide mononitrate, isosorbide dinitrate) are metabolized to nitric oxide and S-nitrothiols in vascular smooth muscle cells, leading to an increase in cyclic guanosine monophosphate (cGMP) that stimulates vasodilation. Large veins are predominantly affected, leading to increased venous capacitance and reduced venous return (preload), which decreases left ventricular wall stress and myocardial oxygen demand to relieve anginal symptoms.

References

- Mechanisms of action of nitrates.
- Identification of the enzymatic mechanism of nitroglycerin bioactivation.

Pharmacology	Cardiovascular System	Angina
Subject	System	Topic

Copyright © UWorld. All rights reserved.

A 57-year-old man is seen in the office after an episode of acute pancreatitis. Hospital evaluation found no evidence of gallstones. The patient does not consume alcohol, but he does have a history of severe hypertriglyceridemia. He was treated with a fibrate medication in the past but could not tolerate it due to liver toxicity. He has no history of diabetes mellitus or hypertension. On examination, the patient has no abdominal tenderness. Laboratory studies show normal hepatic and pancreatic enzyme levels, but the patient again has a severely elevated triglyceride level. The physician prescribes the appropriate medications and explains that the patient is likely to experience skin flushing and warmth after taking the pills. Which of the following is the primary agent mediating these side effects?

- A. Histamine
- B. Platelet-activating factor
- C. Prostaglandin
- D. Serotonin
- E. Substance P

Submit

A 57-year-old man is seen in the office after an episode of acute pancreatitis. Hospital evaluation found no evidence of gallstones. The patient does not consume alcohol, but he does have a history of severe hypertriglyceridemia. He was treated with a fibrate medication in the past but could not tolerate it due to liver toxicity. He has no history of diabetes mellitus or hypertension. On examination, the patient has no abdominal tenderness. Laboratory studies show normal hepatic and pancreatic enzyme levels, but the patient again has a severely elevated triglyceride level. The physician prescribes the appropriate medications and explains that the patient is likely to experience skin flushing and warmth after taking the pills. Which of the following is the primary agent mediating these side effects?

- A. Histamine (26%)
- B. Platelet-activating factor (1%)
- ✓ C. Prostaglandin (49%)
- D. Serotonin (17%)
- E. Substance P (5%)

Omitted
Correct answer
C

49%
Answered correctly

02 secs
Time Spent

05/31/2020
Last Updated

Explanation

Nicotinic acid, or **niacin**, has been used in the treatment of hyperlipidemia for almost 4 decades. It is effective in raising HDL cholesterol levels, as well as lowering triglycerides and LDL levels.

Niacin's main side effects are cutaneous **flushing**, warmth, and itching; these are primarily mediated by release of **prostaglandins** (particularly PGD_2 and PGE_2). **Aspirin**, which inhibits prostaglandin synthesis, can significantly reduce these side effects if given 30-60 minutes before niacin

Nicotinic acid, or **niacin**, has been used in the treatment of hyperlipidemia for almost 4 decades. It is effective in raising HDL cholesterol levels, as well as lowering triglycerides and LDL levels.

Niacin's main side effects are cutaneous **flushing**, warmth, and itching; these are primarily mediated by release of **prostaglandins** (particularly PGD_2 and PGE_2). **Aspirin**, which inhibits prostaglandin synthesis, can significantly reduce these side effects if given 30-60 minutes before niacin administration. The side effects are also reduced with slow-release preparations or if niacin is taken with meals. They are worst when niacin is first initiated and tend to fade over time due to tachyphylaxis.

(Choice A) Vancomycin-induced "red man syndrome" is mediated by histamine release due to non-IgE- mediated mast cell degranulation.

(Choice B) Platelet-activating factor is a powerful phospholipid activator produced by a number of cells, including neutrophils, basophils, platelets, and endothelial cells. It is a mediator of platelet aggregation.

(Choice D) Serotonin syndrome is a potential side effect of selective serotonin reuptake inhibitors. It is characterized by abnormal mental status, autonomic hyperactivity, and muscular rigidity with hyperreflexia.

(Choice E) Substance P is a polypeptide neurotransmitter involved in mediating pain signals in the peripheral and central nervous systems. Topical capsaicin causes release of substance P, resulting in burning pain in the area of application. Prolonged use causes depletion of substance P, and the pain diminishes with time.

Educational objective:
Niacin is used in the treatment of hyperlipidemia. It increases HDL levels and decreases LDL levels and triglycerides. Niacin causes cutaneous flushing, which is mediated by prostaglandins and can be diminished by pretreatment with aspirin.

References

- Aspirin reduces cutaneous flushing after administration of an optimized extended-release niacin formulation.
- Niacin use and cutaneous flushing: mechanisms and strategies for prevention.

Pharmacology	Cardiovascular System	Dyslipidemia
Subject	System	Topic

A 68-year-old man comes to the office due to several weeks of progressive exertional dyspnea and lower extremity edema. Medical history is significant for non-Hodgkin lymphoma, which is in remission after chemotherapy 8 years ago. Blood pressure is 126/76 mm Hg and pulse is 88/min. Auscultation reveals bibasilar lung crackles and 1+ bilateral lower extremity edema. Echocardiogram shows biventricular dilation and a left ventricular ejection fraction of 35%. Stress myocardial perfusion scan is negative for inducible ischemia. After initial stabilization, long-term use of which of the following medications will most likely improve survival in this patient?

- A. Amiodarone
- B. Amlodipine
- C. Carvedilol
- D. Digoxin
- E. Diltiazem
- F. Flecainide
- G. Furosemide

Submit

A 68-year-old man comes to the office due to several weeks of progressive exertional dyspnea and lower extremity edema. Medical history is significant for non-Hodgkin lymphoma, which is in remission after chemotherapy 8 years ago. Blood pressure is 126/76 mm Hg and pulse is 88/min. Auscultation reveals bibasilar lung crackles and 1+ bilateral lower extremity edema. Echocardiogram shows biventricular dilation and a left ventricular ejection fraction of 35%. Stress myocardial perfusion scan is negative for inducible ischemia. After initial stabilization, long-term use of which of the following medications will most likely improve survival in this patient?

- A. Amiodarone (2%)
- B. Amlodipine (4%)
- ✓ C. Carvedilol (53%)
- D. Digoxin (19%)
- E. Diltiazem (3%)
- F. Flecainide (0%)
- G. Furosemide (16%)

Omitted
Correct answer
C

53%
Answered correctly

02 secs
Time Spent

03/19/2020
Last Updated

Explanation

This patient's clinical presentation is consistent with **decompensated systolic heart failure** (HF) due to nonischemic cardiomyopathy, likely as a result of chemotherapy for non-Hodgkin lymphoma. **After initial stabilization**, long-term use of **beta blockers** (eg, carvedilol, metoprolol) has

This patient's clinical presentation is consistent with **decompensated systolic heart failure** (HF) due to nonischemic cardiomyopathy, likely as a result of chemotherapy for non-Hodgkin lymphoma. **After initial stabilization**, long-term use of **beta blockers** (eg, carvedilol, metoprolol) has been shown to improve survival in patients with HF due to left ventricular systolic dysfunction.

Beta blockade decreases myocardial work and oxygen demand by slowing the ventricular rate and reducing contractility. It also lowers peripheral resistance (afterload) by decreasing circulating levels of vasoconstricting hormones (eg, renin, endothelin). These effects are cardioprotective and help reduce cardiomyocyte death and limit deleterious cardiac remodeling. Beta blockers should not be initiated in patients with unstable (decompensated) HF, as they can further impair cardiac output; they should be introduced slowly after the patient has been stabilized.

Other drugs that improve long-term survival in patients with systolic HF include **ACE inhibitors**, **angiotensin II receptor blockers**, and **aldosterone antagonists** (eg, spironolactone, eplerenone).

(Choice A) Amiodarone is a class III antiarrhythmic agent used for management of supraventricular and ventricular arrhythmias.

(Choices B and E) Calcium channel blockers (eg, amlodipine, diltiazem) do not provide any benefit or improve survival in patients with HF due to left ventricular systolic dysfunction.

(Choice D) Digoxin is used as an adjunctive therapy in patients with HF due to systolic dysfunction. It improves symptoms and reduces the rate of hospitalization, but has not been shown to improve overall survival.

(Choice F) Flecainide is a class IC antiarrhythmic drug that is occasionally used for management of supraventricular arrhythmias in patients with a structurally normal heart. It has no role in the management of patients with HF.

(Choice G) Diuretics (eg, furosemide) are used as first-line agents for rapid symptom control in patients with acute congestive HF. They have not been shown to improve long-term survival.

Educational objective:
Drugs that have been shown to improve long-term survival in patients with heart failure due to left ventricular systolic dysfunction include beta blockers, ACE inhibitors, angiotensin II receptor blockers, and aldosterone antagonists.

References

- 2013 ACCF/AHA guideline for the management of heart failure: executive summary: a report of the American College of Cardiology

help reduce cardiomyocyte death and limit deleterious cardiac remodeling. Beta blockers should not be initiated in patients with unstable (decompensated) HF, as they can further impair cardiac output; they should be introduced slowly after the patient has been stabilized.

Other drugs that improve long-term survival in patients with systolic HF include **ACE inhibitors**, **angiotensin II receptor blockers**, and **aldosterone antagonists** (eg, spironolactone, eplerenone).

(Choice A) Amiodarone is a class III antiarrhythmic agent used for management of supraventricular and ventricular arrhythmias.

(Choices B and E) Calcium channel blockers (eg, amlodipine, diltiazem) do not provide any benefit or improve survival in patients with HF due to left ventricular systolic dysfunction.

(Choice D) Digoxin is used as an adjunctive therapy in patients with HF due to systolic dysfunction. It improves symptoms and reduces the rate of hospitalization, but has not been shown to improve overall survival.

(Choice F) Flecainide is a class IC antiarrhythmic drug that is occasionally used for management of supraventricular arrhythmias in patients with a structurally normal heart. It has no role in the management of patients with HF.

(Choice G) Diuretics (eg, furosemide) are used as first-line agents for rapid symptom control in patients with acute congestive HF. They have not been shown to improve long-term survival.

Educational objective:
Drugs that have been shown to improve long-term survival in patients with heart failure due to left ventricular systolic dysfunction include beta blockers, ACE inhibitors, angiotensin II receptor blockers, and aldosterone antagonists.

References

- 2013 ACCF/AHA guideline for the management of heart failure: executive summary: a report of the American College of Cardiology Foundation/American Heart Association Task Force on practice guidelines.

Pharmacology	Cardiovascular System	Chronic heart failure
Subject	System	Topic

Copyright © UWorld. All rights reserved.

A 68-year-old man comes to the office due to thigh and leg pain that worsens with exertion. He is unable to walk through the local mall with his wife without discomfort. Past medical history is significant for hypertension and diabetes mellitus. The patient smokes 2 packs of cigarettes a day and consumes alcohol occasionally. Physical examination of the extremities shows weak dorsalis pedis pulses in both feet. Further evaluation confirms moderate peripheral arterial disease involving both lower extremities. Which of the following drugs would best provide symptomatic improvement due to direct dilation of arteries and inhibition of platelet aggregation?

- A. Abciximab
- B. Argatroban
- C. Aspirin
- D. Cilostazol
- E. Heparin
- F. Tissue plasminogen activator
- G. Warfarin

Submit

A 68-year-old man comes to the office due to thigh and leg pain that worsens with exertion. He is unable to walk through the local mall with his wife without discomfort. Past medical history is significant for hypertension and diabetes mellitus. The patient smokes 2 packs of cigarettes a day and consumes alcohol occasionally. Physical examination of the extremities shows weak dorsalis pedis pulses in both feet. Further evaluation confirms moderate peripheral arterial disease involving both lower extremities. Which of the following drugs would best provide symptomatic improvement due to direct dilation of arteries and inhibition of platelet aggregation?

- A. Abciximab (8%)
- B. Argatroban (9%)
- C. Aspirin (36%)
- ✓ D. Cilostazol (39%)
- E. Heparin (2%)
- F. Tissue plasminogen activator (2%)
- G. Warfarin (1%)

Omitted
Correct answer
D

39%
Answered correctly

01 sec
Time Spent

06/01/2020
Last Updated

Explanation

Several molecules, including thrombin, adenosine diphosphate, and thromboxane A2, activate platelets by acting on cell surface receptors. However, interference with post-receptor signaling can alter platelet function. In particular, cyclic adenosine monophosphate (cAMP) activates a

Several molecules, including thrombin, adenosine diphosphate, and thromboxane A2, activate platelets by acting on cell surface receptors. However, interference with post-receptor signaling can alter platelet function. In particular, cyclic adenosine monophosphate (cAMP) activates a family of enzymes known as the cAMP-dependent protein kinases, or protein kinase A, and leads to inhibition of platelet aggregation. Agents that increase intra-platelet cAMP levels decrease platelet aggregation by preventing platelet shape change and granule release.

Cilostazol reduces **platelet activation** by inhibiting platelet phosphodiesterase, the enzyme responsible for the breakdown of cAMP. It is also a direct arterial **vasodilator**. The net effect is a decrease in claudication **symptoms** and an increase in pain-free walking distances in patients with peripheral arterial disease (PAD). Patients with PAD should be initiated on a graded exercise program, which has also been shown to improve symptoms.

(Choices A, E, and F) Abciximab is a monoclonal antibody that inhibits platelet aggregation by targeting the platelet IIb/IIIa receptor. Heparin is an anticoagulant that potentiates antithrombin III, resulting in the inactivation of thrombin and other factors. Tissue plasminogen activator (alteplase) converts plasminogen to plasmin and causes fibrinolysis. These agents are used in the acute management of cardiovascular events but are not useful for long-term management.

(Choice B) Argatroban is a direct thrombin inhibitor primarily used in the treatment of heparin-induced thrombocytopenia.

(Choice C) Aspirin is an irreversible cyclooxygenase 1 & 2 inhibitor that has been shown to reduce the risk of cardiovascular events in high-risk patients. Patients with clinically significant PAD should take antiplatelet agents (aspirin or clopidogrel) to reduce the risk of cardiovascular events (secondary prevention), but antiplatelet agents do not improve PAD symptoms.

(Choice G) Warfarin is an oral anticoagulant that is a competitive inhibitor of vitamin K epoxide reductase and reduces production of vitamin K-dependent coagulation factors (II, VII, IX, X, protein C, protein S). It is used in the long-term treatment and prevention of thromboembolic events but does not reduce claudication in symptomatic PAD.

Educational objective:
Symptomatic management of peripheral artery disease (PAD) includes a graded exercise program and cilostazol. Cilostazol is a phosphodiesterase inhibitor that inhibits platelet aggregation and acts as a direct arterial vasodilator. Patients with PAD should also receive an antiplatelet agent (aspirin or clopidogrel) for secondary prevention of coronary heart disease and stroke.

References

symptoms.

(Choices A, E, and F) Abciximab is a monoclonal antibody that inhibits platelet aggregation by targeting the platelet IIb/IIIa receptor. Heparin is an anticoagulant that potentiates antithrombin III, resulting in the inactivation of thrombin and other factors. Tissue plasminogen activator (alteplase) converts plasminogen to plasmin and causes fibrinolysis. These agents are used in the acute management of cardiovascular events but are not useful for long-term management.

(Choice B) Argatroban is a direct thrombin inhibitor primarily used in the treatment of heparin-induced thrombocytopenia.

(Choice C) Aspirin is an irreversible cyclooxygenase 1 & 2 inhibitor that has been shown to reduce the risk of cardiovascular events in high-risk patients. Patients with clinically significant PAD should take antiplatelet agents (aspirin or clopidogrel) to reduce the risk of cardiovascular events (secondary prevention), but antiplatelet agents do not improve PAD symptoms.

(Choice G) Warfarin is an oral anticoagulant that is a competitive inhibitor of vitamin K epoxide reductase and reduces production of vitamin K-dependent coagulation factors (II, VII, IX, X, protein C, protein S). It is used in the long-term treatment and prevention of thromboembolic events but does not reduce claudication in symptomatic PAD.

Educational objective:
Symptomatic management of peripheral artery disease (PAD) includes a graded exercise program and cilostazol. Cilostazol is a phosphodiesterase inhibitor that inhibits platelet aggregation and acts as a direct arterial vasodilator. Patients with PAD should also receive an antiplatelet agent (aspirin or clopidogrel) for secondary prevention of coronary heart disease and stroke.

References

- Safety and efficacy of cilostazol in the management of intermittent claudication.
- Management of lower extremity peripheral arterial disease.

Pharmacology	Cardiovascular System	Peripheral vascular disease
Subject	System	Topic

Copyright © UWorld. All rights reserved.

A 38-year-old Caucasian female presents to your office for a routine check-up, and requests a simple and reliable method of contraception. She remarks, "I have already had three children. I would not like to have more any time soon. Do you think I could start on birth control pills?" She has no significant past medical history, and does not take any medications other than a daily multivitamin. Her family history is significant for stroke in her mother and type 2 diabetes mellitus in her father. Which of the following factors would most affect your decision to prescribe oral contraceptives to this patient?

- A. Diet
- B. Physical activity level
- C. Smoking status
- D. Parity
- E. Glucose intolerance
- F. Serum HDL level

Submit

A 38-year-old Caucasian female presents to your office for a routine check-up, and requests a simple and reliable method of contraception. She remarks, "I have already had three children. I would not like to have more any time soon. Do you think I could start on birth control pills?" She has no significant past medical history, and does not take any medications other than a daily multivitamin. Her family history is significant for stroke in her mother and type 2 diabetes mellitus in her father. Which of the following factors would most affect your decision to prescribe oral contraceptives to this patient?

- A. Diet (1%)
- B. Physical activity level (1%)
- ✓ C. Smoking status (81%)
- D. Parity (3%)
- E. Glucose intolerance (3%)
- F. Serum HDL level (7%)

Omitted
Correct answer
C

81%
Answered correctly

02 secs
Time Spent

06/24/2020
Last Updated

Explanation

When taken as prescribed, oral contraceptive pills are a reliable and reversible form of female contraception. They typically contain a combination of estrogen and progestin, and are taken in cycles interrupted by menstrual bleeding. The estrogen in oral contraceptives prevents pregnancy by suppressing the midcycle gonadotropin surge, thereby inhibiting ovulation. Progesterone is added to counteract the increased risk of endometrial cancer associated with unopposed effect of estrogen. Additionally, progesterone may enhance the contraceptive efficacy by decreasing the

When taken as prescribed, oral contraceptive pills are a reliable and reversible form of female contraception. They typically contain a combination of estrogen and progestin, and are taken in cycles interrupted by menstrual bleeding. The estrogen in oral contraceptives prevents pregnancy by suppressing the midcycle gonadotropin surge, thereby inhibiting ovulation. Progesterone is added to counteract the increased risk of endometrial cancer associated with unopposed effect of estrogen. Additionally, progesterone may enhance the contraceptive efficacy by decreasing the permeability of the cervical mucus to sperm.

Side effects of oral contraceptives may include: breakthrough menstrual bleeding, breast tenderness, and weight gain. Additionally, there is a risk of more serious, though rare, events, such as deep vein thrombosis, pulmonary embolism, ischemic stroke, and myocardial infarction. The risk of cardiovascular events due to oral contraceptive pills is increased in smokers and patients over the age of 35. In particular, individuals who smoke more than 15 cigarettes per day have a much higher incidence of cardiovascular events.

(Choices A and B) Use of oral contraceptive pills may cause weight gain. However, there is no relation of weight gain to the more serious potential health risks associated with oral contraceptives.

(Choice D) The risks of oral contraceptive pills are similar in females regardless of past pregnancy or childbearing status.

(Choice E) Oral contraceptive pills can induce insulin resistance and cause glucose intolerance. However, the risk of glucose intolerance was most significant with the first generation of high-dose estrogen oral contraceptives. With the reduced quantities of estrogen in the newer 2nd and 3rd generation oral contraceptive pills, glucose intolerance has become much less common. Adequately controlled diabetes mellitus, in the absence of other cardiovascular risk factors, is not a contraindication to the use of oral contraception.

(Choice F) Although low HDL is a known cardiovascular risk factor, there is no data to suggest that patients with low HDL have especially heightened cardiovascular risks while using oral contraceptives. The guideline for oral contraceptive use in patients with hypercholesterolemia is dependent instead upon the LDL level. Oral contraceptives are generally safe to use in patients with an LDL below 160 mg/dL without any other cardiovascular risk factors.

Educational objective:
The absolute contraindications to the use of OCPs are:

1. Prior history of thromboembolic event or stroke
2. History of an estrogen-dependent tumor

potential health risks associated with oral contraceptives.

(Choice D) The risks of oral contraceptive pills are similar in females regardless of past pregnancy or childbearing status.

(Choice E) Oral contraceptive pills can induce insulin resistance and cause glucose intolerance. However, the risk of glucose intolerance was most significant with the first generation of high-dose estrogen oral contraceptives. With the reduced quantities of estrogen in the newer 2nd and 3rd generation oral contraceptive pills, glucose intolerance has become much less common. Adequately controlled diabetes mellitus, in the absence of other cardiovascular risk factors, is not a contraindication to the use of oral contraception.

(Choice F) Although low HDL is a known cardiovascular risk factor, there is no data to suggest that patients with low HDL have especially heightened cardiovascular risks while using oral contraceptives. The guideline for oral contraceptive use in patients with hypercholesterolemia is dependent instead upon the LDL level. Oral contraceptives are generally safe to use in patients with an LDL below 160 mg/dL without any other cardiovascular risk factors.

Educational objective:
The absolute contraindications to the use of OCPs are:

1. Prior history of thromboembolic event or stroke
2. History of an estrogen-dependent tumor
3. Women over age 35 years who smoke heavily
4. Hypertriglyceridemia
5. Decompensated or active liver disease (would impair steroid metabolism)
6. Pregnancy

References

- Smoking increases the risk of venous thrombosis and acts synergistically with oral contraceptive use.

Pharmacology	Cardiovascular System	Contraception
Subject	System	Topic

Copyright © UWorld. All rights reserved.

A 50-year-old man is brought to the ER with severe dizziness and confusion. He states that he had an episode of chest pain and took several tablets of nitroglycerin. His current medications include a daily aspirin for heart attack prevention, an occasional acetaminophen for headaches and occasionally tadalafil for erectile dysfunction. His blood pressure is 50/20 mmHg and his heart rate is 120 beats/min. Which of the following cellular changes is most likely responsible for this patient's symptoms?

A. Receptor downregulation
B. G_s protein phosphorylation
C. Cyclic GMP accumulation
D. Tyrosine kinase overactivity
E. Enhanced phospholipid metabolism
F. Tolerance development

Submit

A 50-year-old man is brought to the ER with severe dizziness and confusion. He states that he had an episode of chest pain and took several tablets of nitroglycerin. His current medications include a daily aspirin for heart attack prevention, an occasional acetaminophen for headaches and occasionally tadalafil for erectile dysfunction. His blood pressure is 50/20 mmHg and his heart rate is 120 beats/min. Which of the following cellular changes is most likely responsible for this patient's symptoms?

- A. Receptor downregulation (2%)
- B. G_s protein phosphorylation (4%)
- ✓ C. Cyclic GMP accumulation (87%)
- D. Tyrosine kinase overactivity (2%)
- E. Enhanced phospholipid metabolism (1%)
- F. Tolerance development (2%)

Omitted
Correct answer
C

87%
Answered correctly

02 secs
Time Spent

06/23/2020
Last Updated

Explanation

The interaction between nitrates and phosphodiesterase inhibitors used in erectile dysfunction (tadalafil, sildenafil, vardenafil) is well known and very important to understand. Nitrates are converted to nitric oxide by vascular smooth muscle cells, and nitric oxide causes increased intracellular cGMP as a second-messenger. Increased cGMP concentration leads to vascular smooth muscle relaxation. Additionally, cGMP is metabolized within the cells by phosphodiesterase, and phosphodiesterase inhibitors will lead to increased intracellular cGMP. cGMP accumulation in vascular smooth muscle cells due to both enhanced synthesis (nitrates) and inhibited degradation (PDE inhibitors) is responsible

The interaction between nitrates and phosphodiesterase inhibitors used in erectile dysfunction (tadalafil, sildenafil, vardenafil) is well known and very important to understand. Nitrates are converted to nitric oxide by vascular smooth muscle cells, and nitric oxide causes increased intracellular cGMP as a second-messenger. Increased cGMP concentration leads to vascular smooth muscle relaxation. Additionally, cGMP is metabolized within the cells by phosphodiesterase, and phosphodiesterase inhibitors will lead to increased intracellular cGMP. cGMP accumulation in vascular smooth muscle cells due to both enhanced synthesis (nitrates) and inhibited degradation (PDE inhibitors) is responsible for profound hypotension due to extreme vasodilatation when these drugs are used together.

(Choice A) Receptor downregulation or tachyphylaxis occurs with many drug classes including topical glucocorticoids, opiates, L-dopa and more. It is one mechanism by which the body develops tolerance to drugs on a cellular level, but it is not the cause of hypotension in this patient who took nitrates together with a PDE inhibitor.

(Choice B) G_s protein phosphorylation leads to activation of the G_s protein, a stimulatory protein which acts as a part of the adenylate cyclase second messenger system. It has no role in cGMP pathways that are affected by nitrates and PDE inhibitors.

(Choice D) Tyrosine kinase overactivity would lead to an exaggeration of the effects of insulin or insulin-like growth factor. Tyrosine kinase has no role in the effect of nitrates or PDE inhibitors on vascular smooth muscle.

(Choice E) Enhanced phospholipid metabolism would lead to an increase in the production of prostaglandins (via diacylglycerol) and inositol triphosphate (leading to calcium release from the endoplasmic reticulum). This is the inositol triphosphate second-messenger system, and it mediates the effects of alpha-1 adrenergic receptors, angiotensin II receptors, oxytocin receptors and vascular vasopressin receptors. It is not involved in the action of nitrates or PDE inhibitors.

(Choice F) Tolerance refers to the need for a larger dose of drug to achieve the same clinical effect achieved previously with a smaller dose of drug. Development of tolerance can occur by multiple mechanisms such as a change in cellular response to drug (decreased receptors, decreased response to receptor stimulation), as well as increased rate of drug elimination by the body. Tolerance is not the reason for this patient to experience hypotension with this drug combination.

Educational Objective:
Using nitrates together with phosphodiesterase (PDE) inhibitors used for erectile dysfunction and pulmonary hypertension causes a profound systemic hypotension because they both increase intracellular cGMP which causes vascular smooth muscle relaxation. Their use together is absolutely contraindicated.

for profound hypotension due to extreme vasodilatation when these drugs are used together.

(Choice A) Receptor downregulation or tachyphylaxis occurs with many drug classes including topical glucocorticoids, opiates, L-dopa and more. It is one mechanism by which the body develops tolerance to drugs on a cellular level, but it is not the cause of hypotension in this patient who took nitrates together with a PDE inhibitor.

(Choice B) G_s protein phosphorylation leads to activation of the G_s protein, a stimulatory protein which acts as a part of the adenylate cyclase second messenger system. It has no role in cGMP pathways that are affected by nitrates and PDE inhibitors.

(Choice D) Tyrosine kinase overactivity would lead to an exaggeration of the effects of insulin or insulin-like growth factor. Tyrosine kinase has no role in the effect of nitrates or PDE inhibitors on vascular smooth muscle.

(Choice E) Enhanced phospholipid metabolism would lead to an increase in the production of prostaglandins (via diacylglycerol) and inositol triphosphate (leading to calcium release from the endoplasmic reticulum). This is the inositol triphosphate second-messenger system, and it mediates the effects of alpha-1 adrenergic receptors, angiotensin II receptors, oxytocin receptors and vascular vasopressin receptors. It is not involved in the action of nitrates or PDE inhibitors.

(Choice F) Tolerance refers to the need for a larger dose of drug to achieve the same clinical effect achieved previously with a smaller dose of drug. Development of tolerance can occur by multiple mechanisms such as a change in cellular response to drug (decreased receptors, decreased response to receptor stimulation), as well as increased rate of drug elimination by the body. Tolerance is not the reason for this patient to experience hypotension with this drug combination.

Educational Objective:
Using nitrates together with phosphodiesterase (PDE) inhibitors used for erectile dysfunction and pulmonary hypertension causes a profound systemic hypotension because they both increase intracellular cGMP which causes vascular smooth muscle relaxation. Their use together is absolutely contraindicated.

Pharmacology	Cardiovascular System	Nitrates
Subject	System	Topic

Copyright © UWorld. All rights reserved.

A 66-year-old man comes to the emergency department due to several episodes of lightheadedness and a recent fall. The symptoms are especially pronounced in the morning when he gets up from bed. The patient takes medications for hypertension, stable angina pectoris, gout, and benign prostate hyperplasia. He also has osteoarthritis of the right knee and takes occasional nonsteroidal anti-inflammatory drugs. His blood pressure is 120/80 mm Hg and pulse is 70/min in the supine position, and 90/60 mm Hg and 87/min on standing, respectively. Cardiopulmonary examination is normal. Blockade of which of the following receptors is most likely contributing to this patient's current condition?

A. α1-adrenergic
B. α2-adrenergic
C. β1-adrenergic
D. β2-adrenergic
E. D1-dopaminergic

Submit

A 66-year-old man comes to the emergency department due to several episodes of lightheadedness and a recent fall. The symptoms are especially pronounced in the morning when he gets up from bed. The patient takes medications for hypertension, stable angina pectoris, gout, and benign prostate hyperplasia. He also has osteoarthritis of the right knee and takes occasional nonsteroidal anti-inflammatory drugs. His blood pressure is 120/80 mm Hg and pulse is 70/min in the supine position, and 90/60 mm Hg and 87/min on standing, respectively. Cardiopulmonary examination is normal. Blockade of which of the following receptors is most likely contributing to this patient's current condition?

- ✓ A. α1-adrenergic (82%)
- B. α2-adrenergic (4%)
- C. β1-adrenergic (8%)
- D. β2-adrenergic (4%)
- E. D1-dopaminergic (0%)

Omitted
Correct answer
A

82%
Answered correctly

07 secs
Time Spent

03/10/2020
Last Updated

Explanation

Cardiovascular effects of adrenergic drugs				
Drug class	**Examples**	**Heart rate**	**Cardiac contractility**	**Systemic vascular resistance**
α1 agonist	• Midodrine • Phenylephrine	↓ (reflex)	↓ (reflex)	↑

Cardiovascular effects of adrenergic drugs				
Drug class	**Examples**	**Heart rate**	**Cardiac contractility**	**Systemic vascular resistance**
α1 agonist	• Midodrine • Phenylephrine	↓ (reflex)	↓ (reflex)	↑
α2 agonist	• Clonidine	↓ (via central receptors)		↓ (via central receptors)
α1 antagonist	• Doxazosin • Terazosin	↑ (reflex)		↓
α1/ α2 antagonist	• Phenoxybenzamine	↑ (reflex)		↓
β agonist	• Isoproterenol	↑	↑	↓ (via β2 agonist effect)
β1 antagonist	• Metoprolol • Atenolol	↓	↓	

This patient has **orthostatic (postural) hypotension**, which is characterized by a drop in blood pressure on **standing** from the supine position (≥20 mm Hg systolic and/or ≥10 mm Hg diastolic). Standing causes pooling of a significant amount of blood (500-1000 mL) into the veins below the heart. This initiates the following sequence of events in otherwise healthy individuals:

1. Decreased venous return to the heart
2. Decreased ventricular filling and subsequent drop in cardiac output
3. Drop in blood pressure that evokes compensatory baroreceptor reflex
4. Increased sympathetic tone that increases peripheral vascular resistance (α1-adrenoreceptors) as well as heart rate and myocardial contractility (β1-adrenoreceptors)

The **α1-adrenergic antagonists** (terazosin, doxazosin) are commonly used for symptomatic benign prostate hyperplasia and are often associated with orthostatic hypotension, resulting in **lightheadedness** and **syncope** due to cerebral hypoperfusion upon standing. Other etiologies of orthostatic hypotension include volume depletion (hypovolemia due to hemorrhage, hyperglycemia, or diuretics) and autonomic dysfunction

This patient has **orthostatic (postural) hypotension**, which is characterized by a drop in blood pressure on **standing** from the supine position (≥20 mm Hg systolic and/or ≥10 mm Hg diastolic). Standing causes pooling of a significant amount of blood (500-1000 mL) into the veins below the heart. This initiates the following sequence of events in otherwise healthy individuals:

1. Decreased venous return to the heart
2. Decreased ventricular filling and subsequent drop in cardiac output
3. Drop in blood pressure that evokes compensatory baroreceptor reflex
4. Increased sympathetic tone that increases peripheral vascular resistance (α1-adrenoreceptors) as well as heart rate and myocardial contractility (β1-adrenoreceptors)

The **α1-adrenergic antagonists** (terazosin, doxazosin) are commonly used for symptomatic benign prostate hyperplasia and are often associated with orthostatic hypotension, resulting in **lightheadedness** and **syncope** due to cerebral hypoperfusion upon standing. Other etiologies of orthostatic hypotension include volume depletion (hypovolemia due to hemorrhage, hyperglycemia, or diuretics) and autonomic dysfunction (Parkinson disease, diabetes).

(Choice B) Blockade of presynaptic α2-adrenergic receptors results in increased release of norepinephrine from peripheral nerve terminals. This effect results in increased blood pressure and heart rate.

(Choice C) The β1-adrenergic receptors are found predominantly in the heart. Their stimulation increases heart rate, contractility, and conduction. Blockade of β1-adrenoreceptors would prevent this patient's heart rate from increasing appropriately upon standing (normally about 10-25/min).

(Choice D) Stimulation of β2-adrenergic receptors causes bronchodilation, vasodilation in skeletal muscles, and uterine relaxation. Blockade of β2-adrenoreceptors is associated with peripheral vasoconstriction and bronchoconstriction and would not cause orthostatic hypotension.

(Choice E) D1-adrenergic (dopaminergic) receptors are located in the walls of renal, splanchnic, and mesenteric blood vessels. Stimulation of these receptors causes vasodilation and increased renal and splanchnic blood flow. Blockade of D1 receptors does not result in orthostatic hypotension.

Educational objective:
Orthostatic hypotension is a frequent cause of lightheadedness and syncope and is defined as a decrease in systolic (≥20 mm Hg) or diastolic (≥10 mm Hg) blood pressure on standing from the supine position. Medications (α1-adrenergic antagonists, diuretics), volume depletion, and

4. Increased sympathetic tone that increases peripheral vascular resistance (α1-adrenoreceptors) as well as heart rate and myocardial contractility (β1-adrenoreceptors)

The **α1-adrenergic antagonists** (terazosin, doxazosin) are commonly used for symptomatic benign prostate hyperplasia and are often associated with orthostatic hypotension, resulting in **lightheadedness** and **syncope** due to cerebral hypoperfusion upon standing. Other etiologies of orthostatic hypotension include volume depletion (hypovolemia due to hemorrhage, hyperglycemia, or diuretics) and autonomic dysfunction (Parkinson disease, diabetes).

(Choice B) Blockade of presynaptic α2-adrenergic receptors results in increased release of norepinephrine from peripheral nerve terminals. This effect results in increased blood pressure and heart rate.

(Choice C) The β1-adrenergic receptors are found predominantly in the heart. Their stimulation increases heart rate, contractility, and conduction. Blockade of β1-adrenoreceptors would prevent this patient's heart rate from increasing appropriately upon standing (normally about 10-25/min).

(Choice D) Stimulation of β2-adrenergic receptors causes bronchodilation, vasodilation in skeletal muscles, and uterine relaxation. Blockade of β2-adrenoreceptors is associated with peripheral vasoconstriction and bronchoconstriction and would not cause orthostatic hypotension.

(Choice E) D1-adrenergic (dopaminergic) receptors are located in the walls of renal, splanchnic, and mesenteric blood vessels. Stimulation of these receptors causes vasodilation and increased renal and splanchnic blood flow. Blockade of D1 receptors does not result in orthostatic hypotension.

Educational objective:
Orthostatic hypotension is a frequent cause of lightheadedness and syncope and is defined as a decrease in systolic (≥20 mm Hg) or diastolic (≥10 mm Hg) blood pressure on standing from the supine position. Medications (α1-adrenergic antagonists, diuretics), volume depletion, and autonomic dysfunction are common causes of orthostatic hypotension.

References

- A review of the etiology, associated comorbidities, and treatment of orthostatic hypotension.
- Alpha1-Adrenoceptor subtype selectivity and lower urinary tract symptoms.

Pharmacology Cardiovascular System Orthostatic hypotension

A 71-year-old woman comes to the office for follow-up. She has a history of systolic heart failure and was hospitalized 2 weeks ago for an exacerbation, which was treated with intravenous diuretics. Since discharge the patient has been taking oral diuretics and says her shortness of breath has improved, but she is now experiencing muscle weakness and cramping. Blood pressure is 128/72 mm Hg and pulse is 80/min. Physical examination shows mildly decreased muscle strength in the lower extremities. Laboratory evaluation reveals a serum potassium level of 2.2 mEq/L. The patient receives potassium supplements, which improve the weakness. Another diuretic is added to her medical regimen to help prevent this adverse effect in the future. This additional medication predominantly acts on which of the following nephron segments?

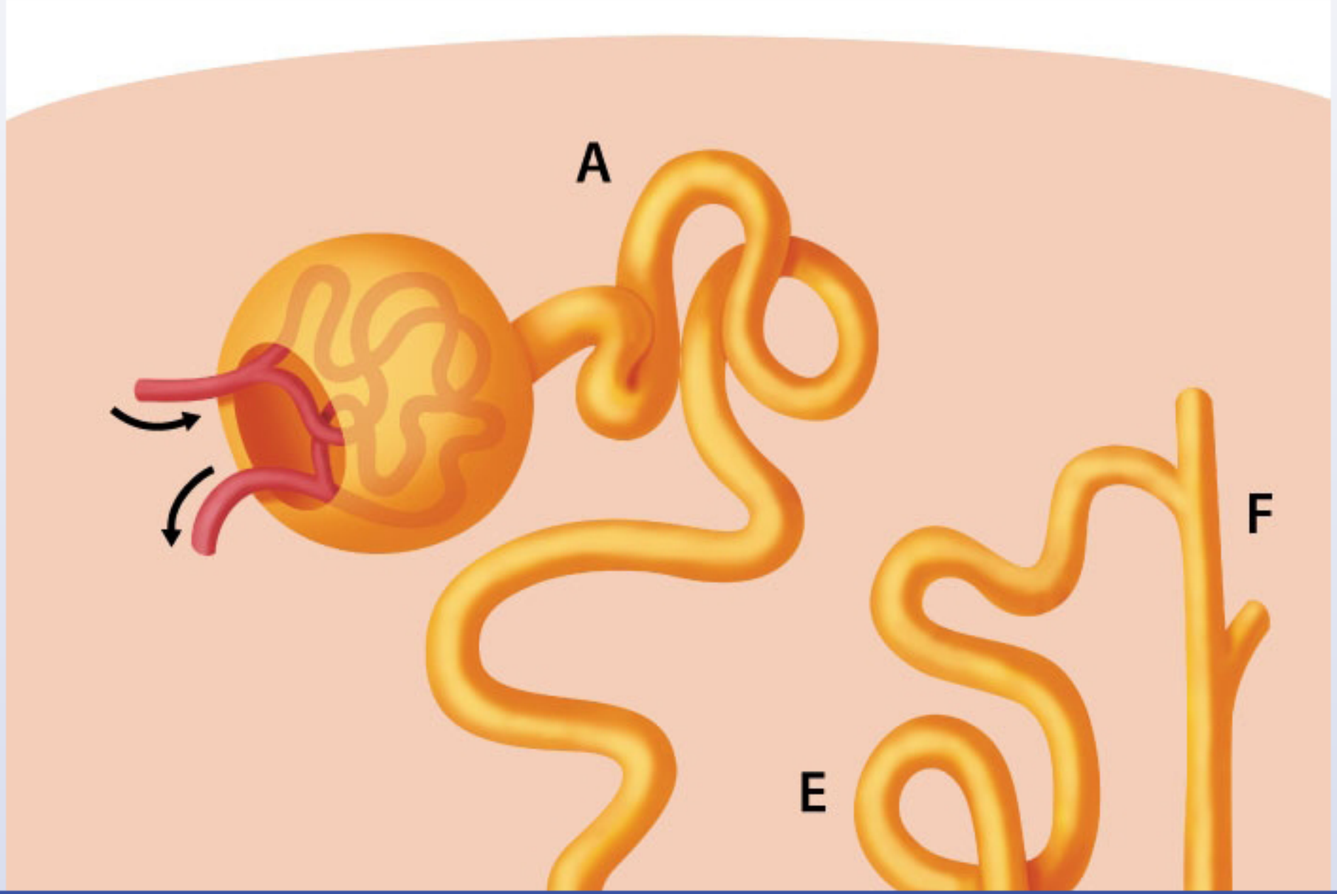

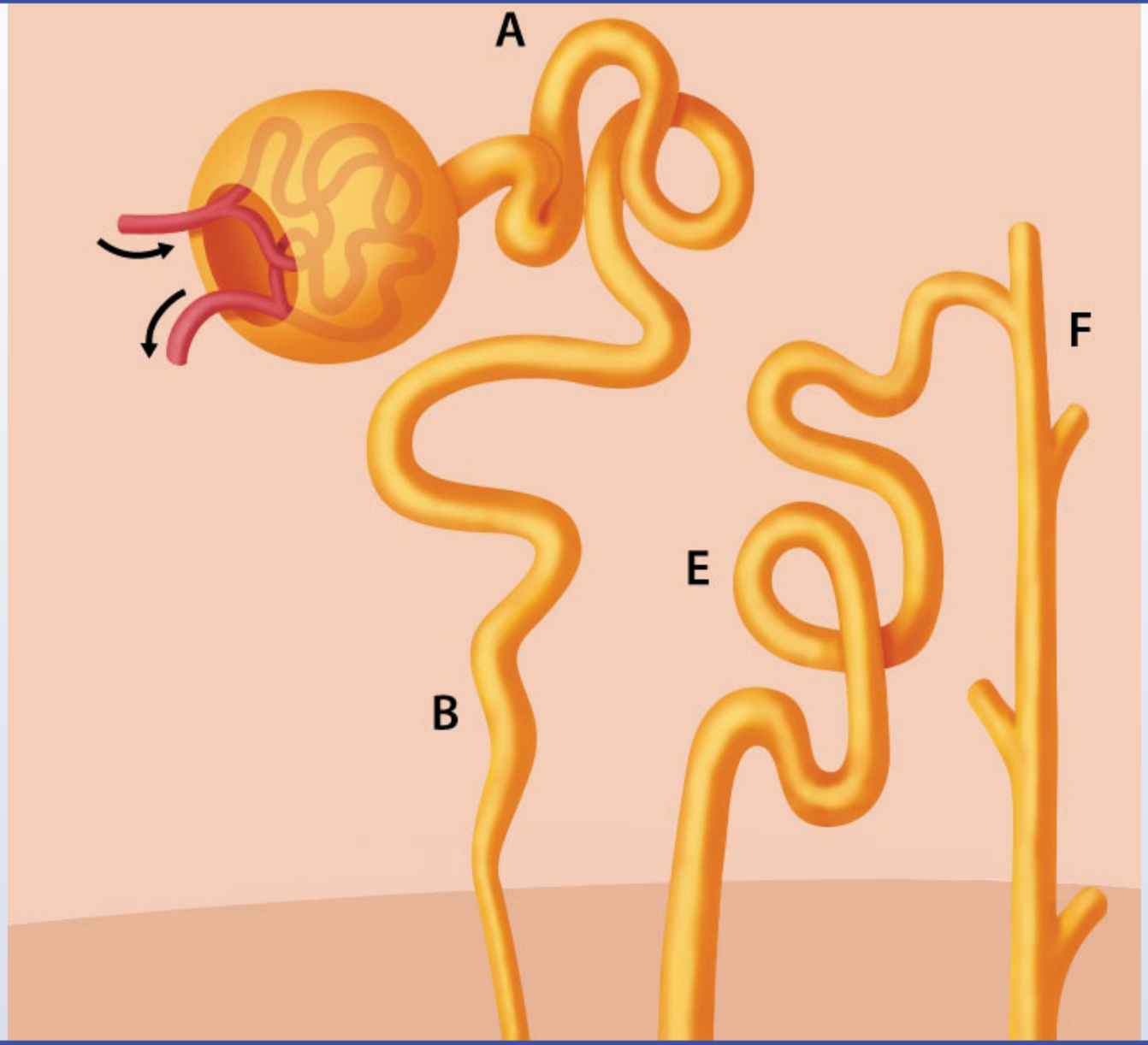
A
B
E
F

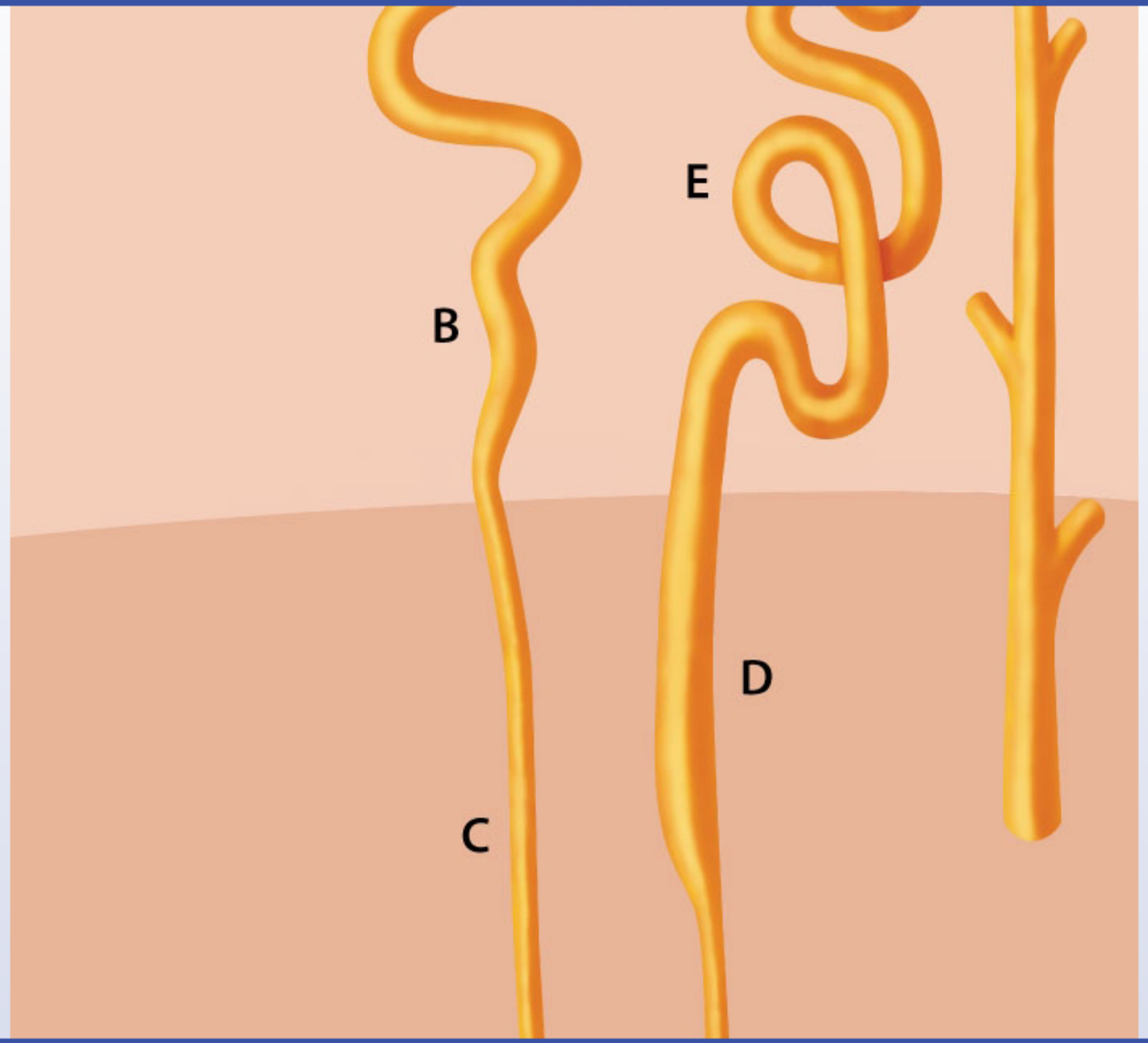
E
B
D
C



A. A

B. B

C. C

D. D

E. E

F. F

Submit



A. A (1%)

B. B (0%)

C. C (1%)

D. D (4%)

E. E (10%)

✓ F. F (82%)

Omitted
Correct answer

82%
Answered correctly

13 secs
Time Spent

01/27/2020
Last Updated

Site of inhibition for various diuretics

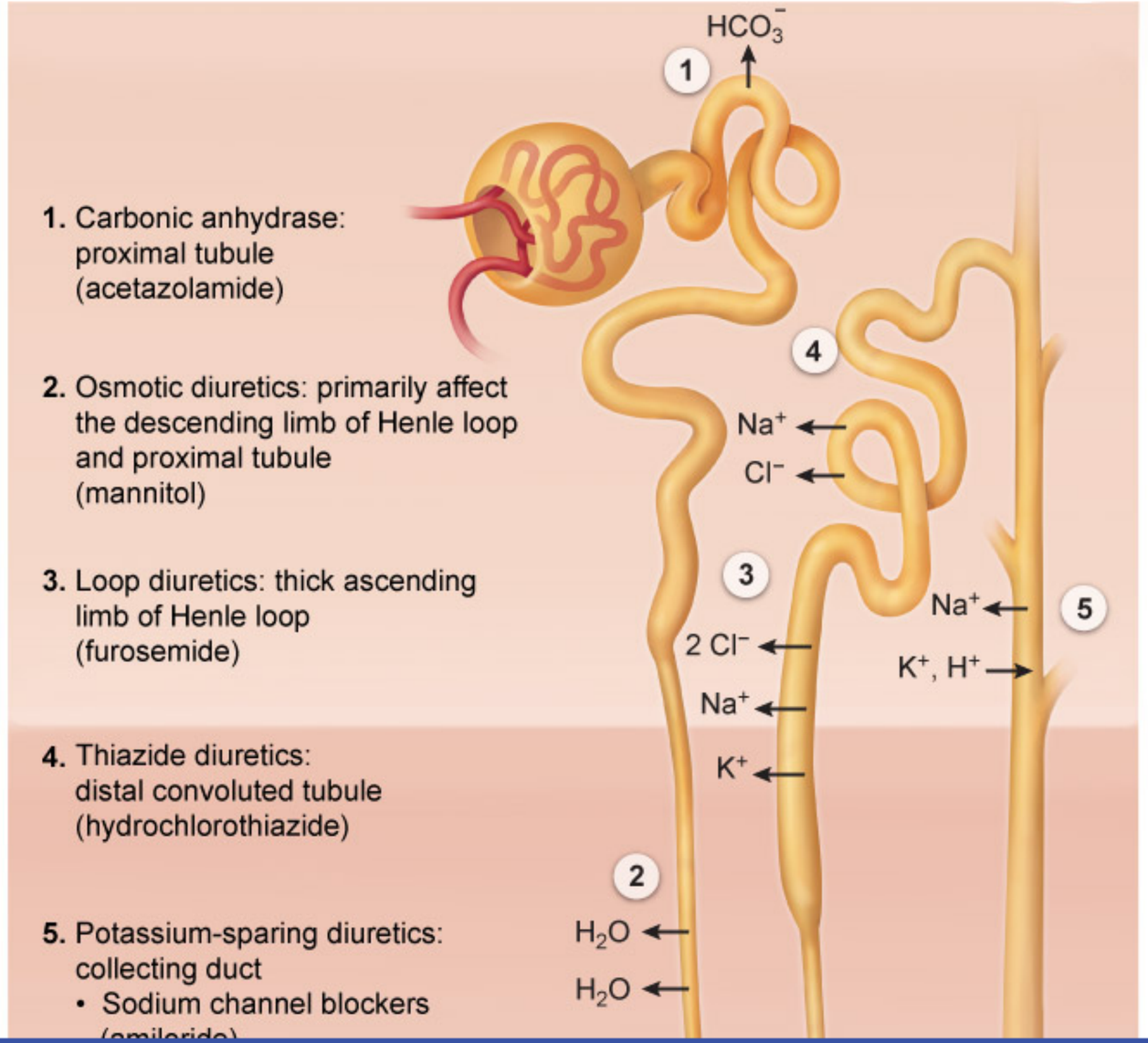

1. Carbonic anhydrase: proximal tubule (acetazolamide)
2. Osmotic diuretics: primarily affect the descending limb of Henle loop and proximal tubule (mannitol)
3. Loop diuretics: thick ascending limb of Henle loop (furosemide)
4. Thiazide diuretics: distal convoluted tubule (hydrochlorothiazide)
5. Potassium-sparing diuretics: collecting duct
   - Sodium channel blockers (amiloride)

Site of inhibition for various diuretics

Exhibit Display

Site of inhibition for various diuretics

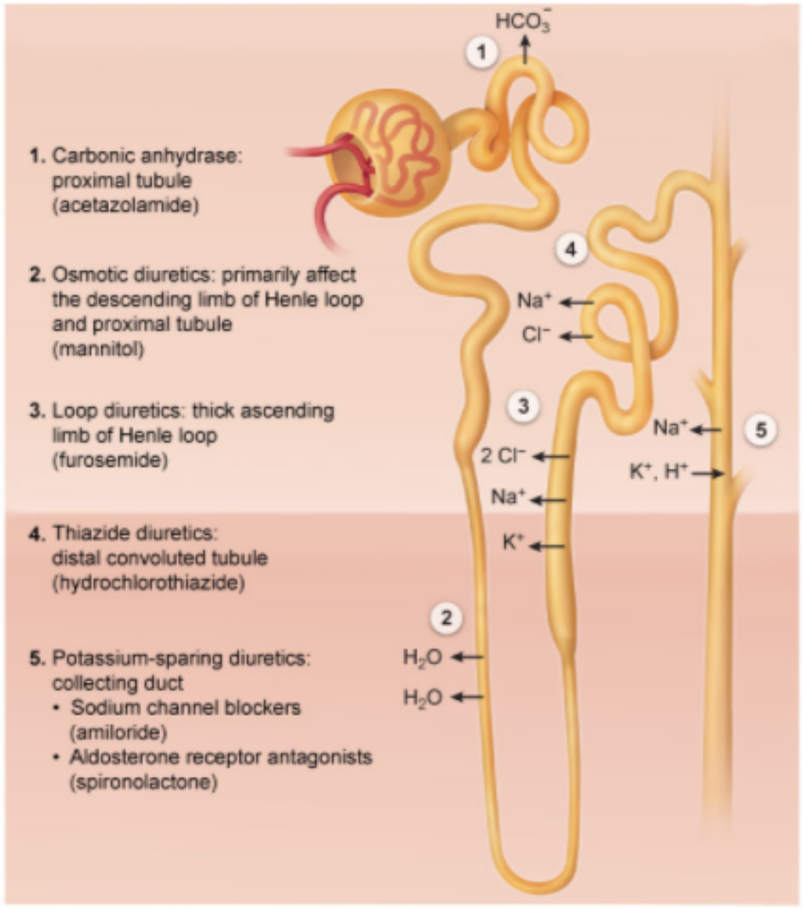

©UWorld

Zoom In | Zoom Out | Reset | Add To New Card | Existing Card

This patient has symptomatic hypokalemia, likely due to treatment with loop diuretics (eg, furosemide) used to reduce the symptoms of heart failure (eg, dyspnea, edema). The physician most likely added a **potassium-sparing diuretic** to this patient's treatment regimen to minimize potassium loss caused by loop diuretic use. All diuretics except for the potassium-sparing class cause potassium loss by increasing sodium delivery to the **late distal tubule** and **cortical collecting duct**, where aldosterone-induced sodium reabsorption occurs at the expense of potassium. Potassium-sparing diuretics act primarily by antagonizing this effect of aldosterone.

Some potassium-sparing diuretics, such as amiloride and triamterene, function by directly blocking the epithelial sodium channels (ENaCs) in the apical membrane of principal cells. Others, including spironolactone and eplerenone, competitively inhibit the aldosterone receptor, causing downregulation of both the apical ENaCs and basolateral Na^+/K^+ pumps. Spironolactone and eplerenone (a more specific receptor antagonist than spironolactone with fewer side effects) are preferred in patients with heart failure because they can also prevent the deleterious effects of **aldosterone-induced cardiac remodeling**.

(Choice A) Carbonic anhydrase inhibitors (eg, acetazolamide, dorzolamide) block sodium and bicarbonate reabsorption in the proximal convoluted tubule. These weak diuretics are typically used to treat altitude sickness or glaucoma.

(Choices B and C) Osmotic diuretics (eg, mannitol) function by preventing sodium and water reabsorption, mainly in the proximal tubule and the descending limb of the loop of Henle. These are typically used for cerebral edema with increased intracranial pressure.

(Choice D) Loop diuretics (eg, furosemide, bumetanide, torsemide) inhibit the Na-K-2Cl symporter in the thick ascending limb of the loop of Henle. This patient is likely already receiving this medication for symptomatic treatment of her heart failure; further dosage increase would worsen hypokalemia.

(Choice E) Thiazide diuretics (eg, hydrochlorothiazide, chlorthalidone) act in the early distal convoluted tubule. These drugs are commonly used in the treatment of hypertension and are sometimes added to loop diuretics in patients with refractory edema, but they would likely worsen hypokalemia.

Educational objective:
All diuretics except for the potassium-sparing class cause potassium loss by increasing sodium delivery to the late distal tubule and cortical collecting duct, where aldosterone-induced sodium reabsorption occurs at the expense of potassium. Potassium-sparing diuretics (eg, spironolactone, amiloride) act on the late distal tubule and cortical collecting duct to antagonize the effects of aldosterone.

potassium. Potassium-sparing diuretics act primarily by antagonizing this effect of aldosterone.

Some potassium-sparing diuretics, such as amiloride and triamterene, function by directly blocking the epithelial sodium channels (ENaCs) in the apical membrane of principal cells. Others, including spironolactone and eplerenone, competitively inhibit the aldosterone receptor, causing downregulation of both the apical ENaCs and basolateral Na^+/K^+ pumps. Spironolactone and eplerenone (a more specific receptor antagonist than spironolactone with fewer side effects) are preferred in patients with heart failure because they can also prevent the deleterious effects of **aldosterone-induced cardiac remodeling**.

(Choice A) Carbonic anhydrase inhibitors (eg, acetazolamide, dorzolamide) block sodium and bicarbonate reabsorption in the proximal convoluted tubule. These weak diuretics are typically used to treat altitude sickness or glaucoma.

(Choices B and C) Osmotic diuretics (eg, mannitol) function by preventing sodium and water reabsorption, mainly in the proximal tubule and the descending limb of the loop of Henle. These are typically used for cerebral edema with increased intracranial pressure.

(Choice D) Loop diuretics (eg, furosemide, bumetanide, torsemide) inhibit the Na-K-2Cl symporter in the thick ascending limb of the loop of Henle. This patient is likely already receiving this medication for symptomatic treatment of her heart failure; further dosage increase would worsen hypokalemia.

(Choice E) Thiazide diuretics (eg, hydrochlorothiazide, chlorthalidone) act in the early distal convoluted tubule. These drugs are commonly used in the treatment of hypertension and are sometimes added to loop diuretics in patients with refractory edema, but they would likely worsen hypokalemia.

Educational objective:
All diuretics except for the potassium-sparing class cause potassium loss by increasing sodium delivery to the late distal tubule and cortical collecting duct, where aldosterone-induced sodium reabsorption occurs at the expense of potassium. Potassium-sparing diuretics (eg, spironolactone, amiloride) act on the late distal tubule and cortical collecting duct to antagonize the effects of aldosterone.

Pharmacology	Cardiovascular System	Aldosterone antagonists
Subject	System	Topic

Copyright © UWorld. All rights reserved.

A 17-year-old girl is brought to the emergency department after an episode of syncope. The patient was sitting on the couch watching television when she suddenly passed out. She had no symptoms prior to the event and regained consciousness spontaneously after approximately 2 minutes. Her family noticed a brief twitching while the patient was unconscious, but she had no tongue biting or bowel or bladder incontinence. The patient is taking an antimicrobial agent for a recent infection but has no other chronic medical conditions. Her uncle died suddenly 2 years ago. A detailed evaluation reveals a decrease-in-function mutation in the *KCNH2* gene, which codes for a voltage-gated potassium channel that is active during the repolarization phase of cardiomyocyte action potential. The patient's medication was causing further impairment of the ion channel function, leading to the incident of syncope. This patient was most likely taking which of the following medications?

A. Acyclovir
B. Amoxicillin
C. Cephalexin
D. Doxycycline
E. Erythromycin
F. Terbinafine

Submit

A 17-year-old girl is brought to the emergency department after an episode of syncope. The patient was sitting on the couch watching television when she suddenly passed out. She had no symptoms prior to the event and regained consciousness spontaneously after approximately 2 minutes. Her family noticed a brief twitching while the patient was unconscious, but she had no tongue biting or bowel or bladder incontinence. The patient is taking an antimicrobial agent for a recent infection but has no other chronic medical conditions. Her uncle died suddenly 2 years ago. A detailed evaluation reveals a decrease-in-function mutation in the *KCNH2* gene, which codes for a voltage-gated potassium channel that is active during the repolarization phase of cardiomyocyte action potential. The patient's medication was causing further impairment of the ion channel function, leading to the incident of syncope. This patient was most likely taking which of the following medications?

- A. Acyclovir (4%)
- B. Amoxicillin (3%)
- C. Cephalexin (3%)
- D. Doxycycline (15%)
- ✓ E. Erythromycin (63%)
- F. Terbinafine (9%)

Omitted
Correct answer
E

63%
Answered correctly

06 secs
Time Spent

04/08/2020
Last Updated

Explanation

Causes of QT prolongation

Causes of QT prolongation	
Acquired	• Medications ◦ Macrolides & fluoroquinolones ◦ Antiemetics (eg, ondansetron) ◦ Azoles (eg, fluconazole) ◦ Antipsychotics, TCAs & methadone ◦ Class IA antiarrhythmics (eg, quinidine) ◦ Class III antiarrhythmics (eg, dofetilide) • Electrolyte abnormalities (eg, ↓ Mg, ↓ K)
Congenital	• Romano-Ward syndrome (autosomal dominant) • Jervell & Lange-Nielson syndrome (autosomal recessive)

TCAs = tricyclic antidepressants.

A decrease-in-function mutation affecting the *KCNH2* gene is one of the most common causes of **congenital long QT syndrome** (LQTS); it can be inherited in autosomal dominant (Romano-Ward syndrome) or autosomal recessive (Jervell and Lange-Nielsen syndrome) fashion. The mutation **impairs the function** of the **voltage-gated potassium channels** controlling the delayed rectifier potassium current that allows **repolarization** of the cardiomyocyte action potential. Delayed repolarization manifests as a prolonged QT interval on ECG and predisposes to the development of **torsades de pointes** (TdP) (a form of polymorphic ventricular tachycardia), which can cause syncope or sudden cardiac death.

Most patients with underlying congenital LQTS do not develop TdP unless exposed to an external influence. **Medications** are the most common cause of **acquired LQTS** and the most important exacerbating factor in patients with congenital LQTS. Most medications that prolong the QT interval do so by delaying the repolarizing potassium current via blockade of the same voltage-gated potassium channels affected by the *KCNH2* gene mutation. **Macrolide antibiotics** (eg, erythromycin, azithromycin) prolong the QT interval and increase the risk of TdP, especially in patients with underlying congenital LQTS.

Other medications that prolong the QT interval include fluoroquinolone antibiotics (eg, ciprofloxacin, moxifloxacin) and many antipsychotics (eg, haloperidol, risperidone) and antiemetics (eg, ondansetron, metoclopramide). The coadministration of multiple QT-prolonging medications may

A decrease-in-function mutation affecting the *KCNH2* gene is one of the most common causes of **congenital long QT syndrome** (LQTS); it can be inherited in autosomal dominant (Romano-Ward syndrome) or autosomal recessive (Jervell and Lange-Nielsen syndrome) fashion. The mutation **impairs the function** of the **voltage-gated potassium channels** controlling the delayed rectifier potassium current that allows **repolarization** of the cardiomyocyte action potential. Delayed repolarization manifests as a prolonged QT interval on ECG and predisposes to the development of **torsades de pointes** (TdP) (a form of polymorphic ventricular tachycardia), which can cause syncope or sudden cardiac death.

Most patients with underlying congenital LQTS do not develop TdP unless exposed to an external influence. **Medications** are the most common cause of **acquired LQTS** and the most important exacerbating factor in patients with congenital LQTS. Most medications that prolong the QT interval do so by delaying the repolarizing potassium current via blockade of the same voltage-gated potassium channels affected by the *KCNH2* gene mutation. **Macrolide antibiotics** (eg, erythromycin, azithromycin) prolong the QT interval and increase the risk of TdP, especially in patients with underlying congenital LQTS.

Other medications that prolong the QT interval include fluoroquinolone antibiotics (eg, ciprofloxacin, moxifloxacin) and many antipsychotics (eg, haloperidol, risperidone) and antiemetics (eg, ondansetron, metoclopramide). The coadministration of multiple QT-prolonging medications may precipitate TdP in patients without congenital LQTS.

(Choice A) Some antiviral medications may prolong the QT interval—including protease inhibitors used in the treatment of HIV (eg, saquinavir, atazanavir)—however, acyclovir does not.

(Choices B, C, and D) Penicillins (eg, amoxicillin), cephalosporins (eg, cephalexin), and tetracyclines (eg, doxycycline) have not been shown to prolong the QT interval.

(Choice F) Azoles (eg, fluconazole, voriconazole) prolong the QT interval; however, most other antifungal medications, including terbinafine (a squalene epoxidase inhibitor), do not.

Educational objective:
Congenital long QT syndrome is commonly caused by a mutation that slows the delayed rectifier potassium current that repolarizes the cardiomyocyte action potential. Certain medications (eg, macrolide antibiotics, antipsychotics, antiemetics) also slow the potassium repolarization current and prolong the QT interval. Excessive QT prolongation can trigger serious cardiac arrhythmia (ie, torsades de pointes), resulting in syncope or sudden cardiac death.

Exhibit Display

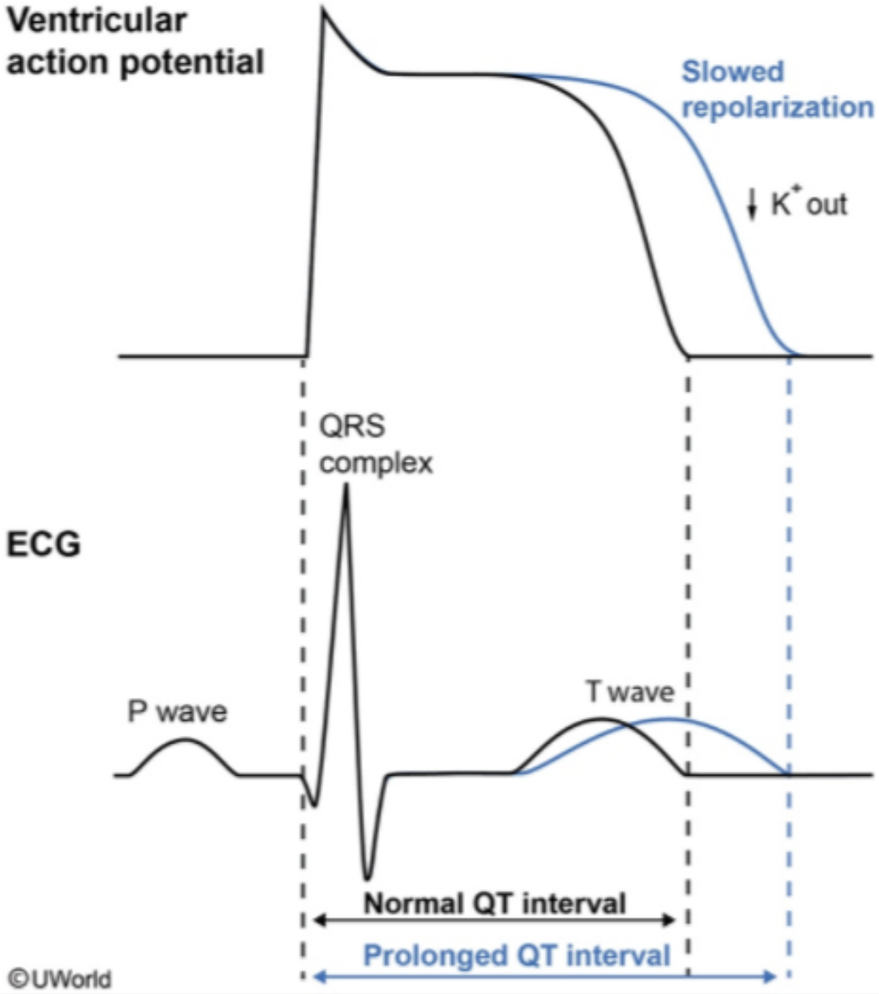

Zoom In | Zoom Out | Reset | Add To New Card | Existing Card

Exhibit Display

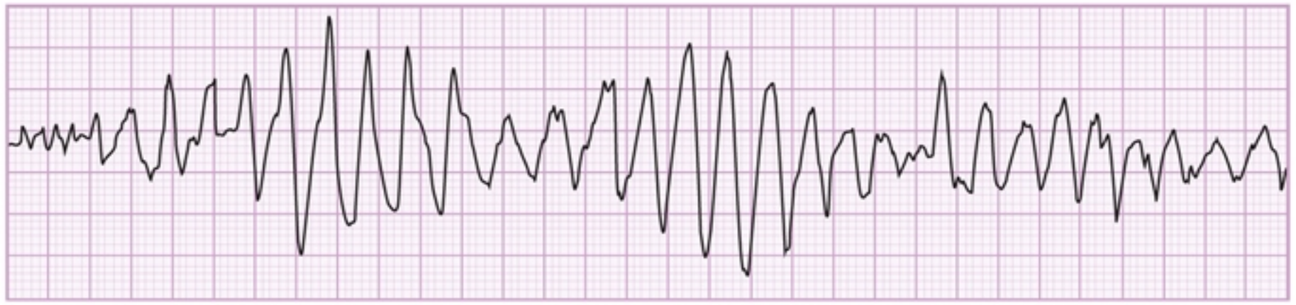

©UWorld

Zoom In Zoom Out Reset Add To New Card | Existing Card

development of **torsades de pointes** (TdP) (a form of polymorphic ventricular tachycardia), which can cause syncope or sudden cardiac death.

Most patients with underlying congenital LQTS do not develop TdP unless exposed to an external influence. **Medications** are the most common cause of **acquired LQTS** and the most important exacerbating factor in patients with congenital LQTS. Most medications that prolong the QT interval do so by delaying the repolarizing potassium current via blockade of the same voltage-gated potassium channels affected by the *KCNH2* gene mutation. **Macrolide antibiotics** (eg, erythromycin, azithromycin) prolong the QT interval and increase the risk of TdP, especially in patients with underlying congenital LQTS.

Other medications that prolong the QT interval include fluoroquinolone antibiotics (eg, ciprofloxacin, moxifloxacin) and many antipsychotics (eg, haloperidol, risperidone) and antiemetics (eg, ondansetron, metoclopramide). The coadministration of multiple QT-prolonging medications may precipitate TdP in patients without congenital LQTS.

(Choice A) Some antiviral medications may prolong the QT interval—including protease inhibitors used in the treatment of HIV (eg, saquinavir, atazanavir)—however, acyclovir does not.

(Choices B, C, and D) Penicillins (eg, amoxicillin), cephalosporins (eg, cephalexin), and tetracyclines (eg, doxycycline) have not been shown to prolong the QT interval.

(Choice F) Azoles (eg, fluconazole, voriconazole) prolong the QT interval; however, most other antifungal medications, including terbinafine (a squalene epoxidase inhibitor), do not.

Educational objective:
Congenital long QT syndrome is commonly caused by a mutation that slows the delayed rectifier potassium current that repolarizes the cardiomyocyte action potential. Certain medications (eg, macrolide antibiotics, antipsychotics, antiemetics) also slow the potassium repolarization current and prolong the QT interval. Excessive QT prolongation can trigger serious cardiac arrhythmia (ie, torsades de pointes), resulting in syncope or sudden cardiac death.

Pharmacology	Cardiovascular System	Long QT syndrome
Subject	System	Topic

Copyright © UWorld. All rights reserved.

An 82-year-old man is brought to the emergency department with fatigue and palpitations. The patient was playing chess at the park when his symptoms developed suddenly. He immediately called an ambulance as he has never experienced symptoms like this before. Past medical history is significant for asthma, gout, and hypertension. Blood pressure is 110/70 mm Hg, pulse is 130/min, and rhythm is irregularly irregular. The lungs are clear on auscultation. Intravenous digoxin is administered. Two hours later, the patient appears comfortable; his pulse is 82/min and still irregularly irregular. Which of the following best explains the heart rate lowering effects of the medication?

- A. Decreased action potential duration
- B. Decreased atrial refractoriness
- C. Delayed after-depolarizations
- D. Increased parasympathetic tone
- E. Increased ventricular contractility

Submit

An 82-year-old man is brought to the emergency department with fatigue and palpitations. The patient was playing chess at the park when his symptoms developed suddenly. He immediately called an ambulance as he has never experienced symptoms like this before. Past medical history is significant for asthma, gout, and hypertension. Blood pressure is 110/70 mm Hg, pulse is 130/min, and rhythm is irregularly irregular. The lungs are clear on auscultation. Intravenous digoxin is administered. Two hours later, the patient appears comfortable; his pulse is 82/min and still irregularly irregular. Which of the following best explains the heart rate lowering effects of the medication?

- A. Decreased action potential duration (6%)
- B. Decreased atrial refractoriness (5%)
- C. Delayed after-depolarizations (16%)
- ✓ D. Increased parasympathetic tone (48%)
- E. Increased ventricular contractility (22%)

Omitted
Correct answer
D

48%
Answered correctly

01 sec
Time Spent

06/10/2020
Last Updated

Explanation

This patient developed **atrial fibrillation with rapid ventricular response** (AF with RVR) and was treated with digoxin for ventricular **rate control**. Although calcium channel blockers and beta blockers are preferred for rate control, digoxin is sometimes used. **Digoxin** slows the ventricular rate during AF primarily by **increasing parasympathetic tone**, which leads to inhibition of atrioventricular (AV) nodal conduction.

Several mechanisms may explain the parasympathomimetic effects of digoxin. Inhibition of the sodium-potassium ATPase pump in vagal afferent fibers sensitizes arterial baroreceptors (eg, carotid, aortic) and cardiac receptors, augmenting afferent input from the cardiovascular system to the

Explanation

This patient developed **atrial fibrillation with rapid ventricular response** (AF with RVR) and was treated with digoxin for ventricular **rate control**. Although calcium channel blockers and beta blockers are preferred for rate control, digoxin is sometimes used. **Digoxin** slows the ventricular rate during AF primarily by **increasing parasympathetic tone**, which leads to inhibition of atrioventricular (AV) nodal conduction.

Several mechanisms may explain the parasympathomimetic effects of digoxin. Inhibition of the sodium-potassium ATPase pump in vagal afferent fibers sensitizes arterial baroreceptors (eg, carotid, aortic) and cardiac receptors, augmenting afferent input from the cardiovascular system to the brain. Digoxin also enhances efferent parasympathetic ganglionic transmission, leading to increased vagal output.

Slowed AV conduction is useful in AF and flutter with RVR (heart rate ≥100/min) because the focus of increased automaticity in these conditions is located in the atria and the rapidity of the ventricular response depends on the refractory period of the AV node. When AV node conduction is slowed, the atria will continue to fibrillate/flutter, but the ventricles will contract at a more normal rate. RVR is serious as inadequate diastolic filling time can lead to poor cardiac output and backup of blood in the lungs (heart failure).

(Choices A and B) Decreased action potential duration leads to a decreased refractory period and would allow the cardiac pacemaker cells (or ectopic foci) to fire with greater frequency. Decreased atrial refractoriness would give the atria the ability to depolarize at a higher rate and increase the risk of reentry circuit formation. These states predispose to AF.

(Choice C) Delayed after-depolarizations are abnormal depolarizations of cardiac myocytes that occur after repolarization has completed. They can occur in states of hyperexcitability (eg, very high intracellular calcium, high catecholamine stimulation states). Digoxin toxicity can cause delayed after-depolarizations via its mechanism of increasing intracellular calcium, leading to ventricular tachycardia and death.

(Choice E) Digoxin can improve systolic heart failure symptoms (eg, dyspnea, orthopnea) by increasing ventricular contractility. Digoxin inhibits the sodium-potassium ATPase pump, which results in increased intracellular sodium. This leads to increased intracellular calcium, which enhances excitation-contraction coupling and allows maximal cross-linking of actin and myosin for greater contractility. In contrast, the chronotropic effects of digoxin result indirectly from the increase in vagal tone.

Educational objective:
Digoxin is used for ventricular rate control in atrial fibrillation as it decreases atrioventricular nodal conduction by increasing parasympathetic vagal tone. Digoxin is also used in heart failure due to its positive inotropic effect. These effects are accomplished via inhibition of the sodium-potassium ATPase pump.

brain. Digoxin also enhances efferent parasympathetic ganglionic transmission, leading to increased vagal output.

Slowed AV conduction is useful in AF and flutter with RVR (heart rate ≥100/min) because the focus of increased automaticity in these conditions is located in the atria and the rapidity of the ventricular response depends on the refractory period of the AV node. When AV node conduction is slowed, the atria will continue to fibrillate/flutter, but the ventricles will contract at a more normal rate. RVR is serious as inadequate diastolic filling time can lead to poor cardiac output and backup of blood in the lungs (heart failure).

(Choices A and B) Decreased action potential duration leads to a decreased refractory period and would allow the cardiac pacemaker cells (or ectopic foci) to fire with greater frequency. Decreased atrial refractoriness would give the atria the ability to depolarize at a higher rate and increase the risk of reentry circuit formation. These states predispose to AF.

(Choice C) Delayed after-depolarizations are abnormal depolarizations of cardiac myocytes that occur after repolarization has completed. They can occur in states of hyperexcitability (eg, very high intracellular calcium, high catecholamine stimulation states). Digoxin toxicity can cause delayed after-depolarizations via its mechanism of increasing intracellular calcium, leading to ventricular tachycardia and death.

(Choice E) Digoxin can improve systolic heart failure symptoms (eg, dyspnea, orthopnea) by increasing ventricular contractility. Digoxin inhibits the sodium-potassium ATPase pump, which results in increased intracellular sodium. This leads to increased intracellular calcium, which enhances excitation-contraction coupling and allows maximal cross-linking of actin and myosin for greater contractility. In contrast, the chronotropic effects of digoxin result indirectly from the increase in vagal tone.

Educational objective:
Digoxin is used for ventricular rate control in atrial fibrillation as it decreases atrioventricular nodal conduction by increasing parasympathetic vagal tone. Digoxin is also used in heart failure due to its positive inotropic effect. These effects are accomplished via inhibition of the sodium-potassium ATPase pump.

References

- Endocardial stimulation of efferent parasympathetic nerves to the atrioventricular node in humans: optimal stimulation sites and the effects of digoxin.
- Digoxin in the management of cardiovascular disorders.
- Digitalis and the autonomic nervous system.

A 78-year-old woman is admitted to the hospital due to altered mental status. Medical history is significant for pyelonephritis, type 2 diabetes mellitus, coronary artery disease, and heart failure with reduced ejection fraction. Temperature is 36.2 C (97.2 F), blood pressure is 80/50 mm Hg, pulse is 120/min, and respirations are 24/min. Oxygen saturation is 90% on room air. Examination shows bilateral crackles. After she is started on appropriate treatment, including initiation of norepinephrine infusion, her blood pressure increases and her heart rate slightly decreases. This patient's change in heart rate is most likely due to norepinephrine's effect on which of the following receptors?

A. Alpha-1 receptors in blood vessels
B. Alpha-2 receptors in the medulla
C. Beta-1 receptors in the heart
D. Beta-2 receptors in blood vessels
E. Dopamine receptors in blood vessels

Submit

A 78-year-old woman is admitted to the hospital due to altered mental status. Medical history is significant for pyelonephritis, type 2 diabetes mellitus, coronary artery disease, and heart failure with reduced ejection fraction. Temperature is 36.2 C (97.2 F), blood pressure is 80/50 mm Hg, pulse is 120/min, and respirations are 24/min. Oxygen saturation is 90% on room air. Examination shows bilateral crackles. After she is started on appropriate treatment, including initiation of norepinephrine infusion, her blood pressure increases and her heart rate slightly decreases. This patient's change in heart rate is most likely due to norepinephrine's effect on which of the following receptors?

- ✓ A. Alpha-1 receptors in blood vessels (71%)
- B. Alpha-2 receptors in the medulla (7%)
- C. Beta-1 receptors in the heart (17%)
- D. Beta-2 receptors in blood vessels (3%)
- E. Dopamine receptors in blood vessels (0%)

Omitted
Correct answer
A

71%
Answered correctly

02 secs
Time Spent

05/27/2020
Last Updated

Explanation

Cardiovascular effects of adrenergic agonists

- α_1: peripheral vasoconstriction, ↑ SVR
- β_1: ↑ heart rate & contractility, ↑ cardiac output
- β_2: peripheral vasodilation, ↓ SVR

Cardiovascular effects of adrenergic agonists

- α_1: peripheral vasoconstriction, ↑ SVR
- β_1: ↑ heart rate & contractility, ↑ cardiac output
- β_2: peripheral vasodilation, ↓ SVR
- D_1: renal arteriolar vasodilation

Agonist	Receptor binding	Blood pressure	Heart rate
Dobutamine	$\beta_1 > \beta_2$	–/↓	↑
Dopamine	$D_1 > \beta_1 > \alpha_1$ (low-dose)	–/↓	↑
	$\alpha_1 > \beta_1 > D_1$ (high-dose)	↑	–/↓*
Epinephrine	$\beta_1 > \beta_2 > \alpha_1$ (low-dose)	–/↓	↑
	$\alpha_1 > \beta_1 > \beta_2$ (high-dose)	↑	–/↓*
Isoproterenol	$\beta_1 = \beta_2$	–/↓	↑
Norepinephrine	$\alpha_1 > \beta_1 > \beta_2$	↑	–/↓*
Phenylephrine	α_1	↑	↓*

*Reflex-mediated decrease.

SVR = systemic vascular resistance.

SVR = systemic vascular resistance.

Norepinephrine has both vasopressor and inotropic effects and is commonly used in patients with shock. It directly and **potently stimulates alpha-1 receptors** to trigger peripheral vasoconstriction, causing **increased systemic vascular resistance** (SVR) and increased blood pressure. Norepinephrine also directly stimulates beta-1 receptors to facilitate increased heart rate, myocardial contractility, and cardiac output **(Choice C)**.

In addition to the direct effects of norepinephrine, the alpha-1–mediated increase in SVR triggers indirect effects via the **baroreceptor reflex**. Increased blood pressure stimulates increased firing of the aortic and carotid baroreceptors. In response, the CNS increases parasympathetic output and decreases sympathetic output, decreasing heart rate and contractility. These reflexive effects on the heart **oppose the effects of direct beta-1–receptor stimulation**. Because of the marked increase in SVR with norepinephrine, the reflexive decrease in heart rate usually completely offsets or overrides the directly-mediated increase in heart rate, resulting in an **unchanged or slightly decreased heart rate**.

A similar offsetting effect occurs with high-dose dopamine and high-dose epinephrine due to baroreceptor-mediated feedback from predominant alpha-1 receptor stimulation.

(Choices B and E) Stimulation of alpha-2 receptors in the CNS (eg, with clonidine) decreases sympathetic output, causing peripheral vasodilation, decreased heart rate, and reduced blood pressure. Stimulation of dopamine-1 receptors (eg, with dopamine) causes renal arteriolar vasodilation and increases renal blood flow. Norepinephrine has no significant effect on either dopamine-1 or central alpha-2 receptors (does not cross blood brain barrier).

(Choice D) Although norepinephrine also causes mild, direct stimulation of vasodilatory beta-2 receptors, its peripheral vasoconstrictive effect (mediated by alpha-1 receptors) predominates, making it a very potent vasopressor.

Educational objective:
Norepinephrine potently stimulates alpha-1 receptors to cause peripheral vasoconstriction, increasing systemic vascular resistance and blood pressure. This triggers a baroreceptor–mediated reflexive decrease in heart rate that completely offsets or overrides the direct beta-1–mediated increase in heart rate caused by norepinephrine, resulting in overall unchanged or slightly decreased heart rate.

Pharmacology	Cardiovascular System	Sepsis
Subject	System	Topic

SVR = systemic vascular resistance.

Exhibit Display

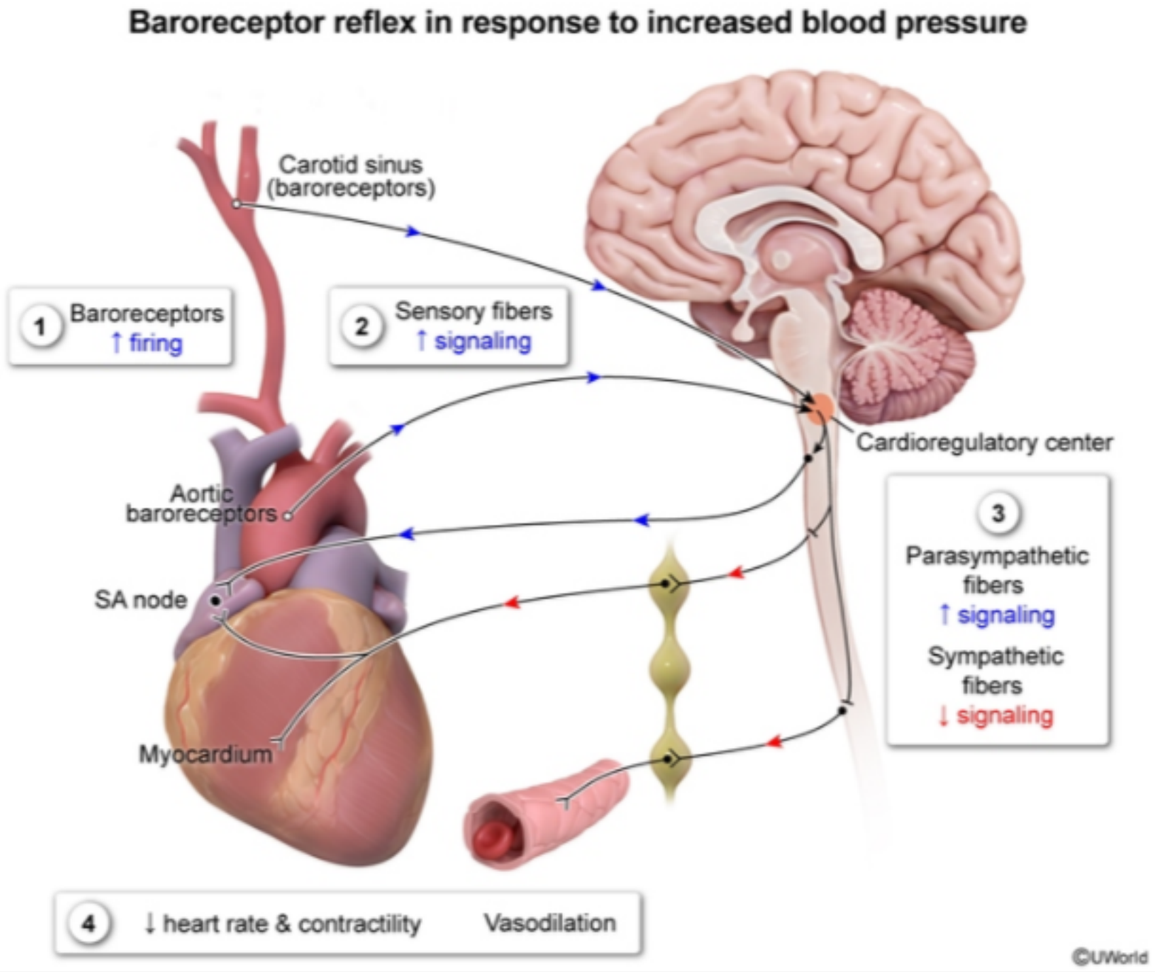

Zoom In Zoom Out Reset Add To Flash Card

Subject System Topic

Norepinephrine has both vasopressor and inotropic effects and is commonly used in patients with shock. It directly and **potently stimulates alpha-1 receptors** to trigger peripheral vasoconstriction, causing **increased systemic vascular resistance** (SVR) and increased blood pressure. Norepinephrine also directly stimulates beta-1 receptors to facilitate increased heart rate, myocardial contractility, and cardiac output **(Choice C)**.

In addition to the direct effects of norepinephrine, the alpha-1–mediated increase in SVR triggers indirect effects via the **baroreceptor reflex**. Increased blood pressure stimulates increased firing of the aortic and carotid baroreceptors. In response, the CNS increases parasympathetic output and decreases sympathetic output, decreasing heart rate and contractility. These reflexive effects on the heart **oppose the effects of direct beta-1–receptor stimulation**. Because of the marked increase in SVR with norepinephrine, the reflexive decrease in heart rate usually completely offsets or overrides the directly-mediated increase in heart rate, resulting in an **unchanged or slightly decreased heart rate**.

A similar offsetting effect occurs with high-dose dopamine and high-dose epinephrine due to baroreceptor-mediated feedback from predominant alpha-1 receptor stimulation.

(Choices B and E) Stimulation of alpha-2 receptors in the CNS (eg, with clonidine) decreases sympathetic output, causing peripheral vasodilation, decreased heart rate, and reduced blood pressure. Stimulation of dopamine-1 receptors (eg, with dopamine) causes renal arteriolar vasodilation and increases renal blood flow. Norepinephrine has no significant effect on either dopamine-1 or central alpha-2 receptors (does not cross blood brain barrier).

(Choice D) Although norepinephrine also causes mild, direct stimulation of vasodilatory beta-2 receptors, its peripheral vasoconstrictive effect (mediated by alpha-1 receptors) predominates, making it a very potent vasopressor.

Educational objective:
Norepinephrine potently stimulates alpha-1 receptors to cause peripheral vasoconstriction, increasing systemic vascular resistance and blood pressure. This triggers a baroreceptor–mediated reflexive decrease in heart rate that completely offsets or overrides the direct beta-1–mediated increase in heart rate caused by norepinephrine, resulting in overall unchanged or slightly decreased heart rate.

Pharmacology	Cardiovascular System	Sepsis
Subject	System	Topic

Copyright © UWorld. All rights reserved.